

2014

Anatomic determinants of sacral dysmorphism and implications for safe iliosacral screw placement

Scott P. Kaiser

University of California - San Francisco

Michael J. Gardner

Washington University School of Medicine in St. Louis

Joseph Liu

Hospital for Special Surgery

M. L. Chip Routh Jr.

University of Texas

Saam Morshed

University of California - San Francisco

Follow this and additional works at: http://digitalcommons.wustl.edu/open_access_pubs

Recommended Citation

Kaiser, Scott P.; Gardner, Michael J.; Liu, Joseph; Routh, M. L. Chip Jr.; and Morshed, Saam, "Anatomic determinants of sacral dysmorphism and implications for safe iliosacral screw placement." *The Journal of Bone and Joint Surgery*.96,14. e120. (2014). http://digitalcommons.wustl.edu/open_access_pubs/3236

Anatomic Determinants of Sacral Dysmorphism and Implications for Safe Iliosacral Screw Placement

Scott P. Kaiser, MD, Michael J. Gardner, MD, Joseph Liu, MD, M.L. Chip Routt Jr., MD, and Saam Morshed, MD, PhD

Investigation performed at San Francisco General Hospital, San Francisco, California

Background: Upper sacral segment dysplasia increases the risk of cortical perforation during iliosacral screw insertion. Dysmorphic sacra have narrow and angled upper osseous corridors. However, there is no validated definition of this anatomic variation. We hypothesized that pelves could be quantitatively grouped by anatomic measurements.

Methods: One hundred and four computed tomography (CT) scans and virtual outlet views of uninjured pelves were analyzed for the presence of the five qualitative characteristics of upper sacral segment dysplasia. CT scans were reformatted to measure the cross-sectional area, angulation, and length of the osseous corridor. Principal components analysis was used to identify multivariable explanations of anatomic variability, and discriminant analysis was used to assess how well such combinations can classify dysmorphic pelves.

Results: The prevalences of the five radiographic qualitative characteristics of upper sacral segment dysplasia, as determined by two reviewers, ranged from 28% to 53% in the cohort. The rates of agreement between the two reviewers ranged from 70% to 81%, and kappa coefficients ranged from 0.26 to 0.59. Cluster analysis revealed three pelvic phenotypes based on the maximal length of the osseous corridor in the upper two sacral segments. Forty-one percent of the pelves fell into the dysmorphic cluster. The five radiographic qualitative characteristics of dysmorphism were significantly more frequent ($p < 0.007$) in this cluster. A combination of upper sacral coronal and axial angulation effectively explained the variance in the data, and an inverse linear relationship between these angles and a long upper sacral segment corridor was identified. A sacral dysmorphism score was derived with the equation: (first sacral coronal angle) + 2(first sacral axial angle). An increase in the sacral dysmorphism score correlated with a lower likelihood of a safe transsacral first sacral corridor. No subjects with a sacral dysmorphism score >70 had a safe transsacral first sacral corridor.

Conclusions: Sacral dysmorphism was found in 41% of the pelves. The major determinants of sacral dysmorphism are upper sacral segment coronal and axial angulation. The sacral dysmorphism score quantifies dysmorphism and can be used in preoperative planning of iliosacral screw placement.

Peer Review: This article was reviewed by the Editor-in-Chief and one Deputy Editor, and it underwent blinded review by two or more outside experts. The Deputy Editor reviewed each revision of the article, and it underwent a final review by the Editor-in-Chief prior to publication. Final corrections and clarifications occurred during one or more exchanges between the author(s) and copyeditors.

Percutaneous iliosacral screw fixation has been widely adopted as a safe method for treatment of unstable pelvic ring injuries¹⁻⁷. The use of iliosacral screws is increasing, probably as a result of increased training in the technique, an increase in the incidence of pelvic ring injuries, and increased survival of patients with unstable pelvic ring injuries^{8,9}.

Published series have demonstrated successful outcomes of percutaneous iliosacral screw fixation^{5,6,10,11}. These studies have shown high rates of radiographic and clinical success, but

also a risk of neurovascular injury¹²⁻¹⁶. The structures most directly at risk are the sacral nerve roots, which lie in tunnels directly superior and inferior to the target osseous corridor. Also at risk are the lumbar nerve roots along the anterior cortex and the spinal canal posteriorly¹⁷. The constriction zone of the osseous corridor has been likened to a vestibule, and avoidance of neurologic or vascular injury by the fixation device depends on passing the screw without a cortical breach^{18,19}. Understanding variations in the three-dimensional anatomy of

Disclosure: None of the authors received payments or services, either directly or indirectly (i.e., via his or her institution), from a third party in support of any aspect of this work. One or more of the authors, or his or her institution, has had a financial relationship, in the thirty-six months prior to submission of this work, with an entity in the biomedical arena that could be perceived to influence or have the potential to influence what is written in this work. No author has had any other relationships, or has engaged in any other activities, that could be perceived to influence or have the potential to influence what is written in this work. The complete **Disclosures of Potential Conflicts of Interest** submitted by authors are always provided with the online version of the article.

TABLE I Qualitative Characteristics

Characteristic	% of Pelves with Finding		Agreement (%)	Kappa
	Reviewer 1	Reviewer 2		
Upper sacral segment not recessed in pelvis	33	33	75	0.37
Mamillary bodies	53	52	80	0.59
Misshapen sacral foramen	28	31	70	0.26
Residual disc	35	36	71	0.36
Acute alar slope	35	36	81	0.59

the sacrum is essential to prevent misplacement of an iliosacral screw.

Certain unstable fracture patterns, such as vertical sacral fractures, are at higher risk of displacement after iliosacral fixation^{11,20}. Obtaining fixation in the contralateral cortex by placing the screw in a transiliac transsacral fashion can increase the strength of fixation^{20,21}. In order to pass a transsacral screw safely, it must traverse the ipsilateral and contralateral osseous corridors, which must be of sufficient size and of complementary orientation to allow screw placement without a cortical breach²¹. A change in trajectory of only 4° can result in cortical perforation²². Concise understanding of this aspect of sacral anatomy and its corresponding fluoroscopic landmarks enables safe placement of percutaneous iliosacral screws^{2,23-26}.

Upper sacral segment dysplasia refers to a sacral phenotype in which the size and orientation of the upper sacral segment does not allow safe passage of a transiliac, transsacral screw²⁷. The morphology of the osseous corridor in upper sacral segment dysplasia has been previously described as having five associated qualitative characteristics identifiable on an outlet radiograph²⁸⁻³⁰. Patients with the qualitative characteristics of upper sacral segment dysplasia have narrower and more angulated upper sacral segments²⁹. Despite this appreciation for the presence of variations in pelvic morphology, to our knowledge no objective or quantifiable definition has been developed to differentiate dysmorphic from non-dysmorphic pelvis. The purpose of this study was to identify the qualitative and quantitative characteristics of sacral morphology that are most predictive of the presence of an osseous corridor for fixation and to use these identified characteristics to specifically define upper sacral segment dysplasia.

Materials and Methods

We analyzed a consecutive series of 104 uninjured pelvis for which computed tomography (CT) scans had been obtained during a two-month period in 2010 at a level-I trauma center. CT was conducted with a GE LightSpeed VCT sixty-four-slice scanner (GE Healthcare, Waukesha, Wisconsin) with a collimation of 64 × 1.25 mm. Images were processed on an Advantage Workstation 4.4 (GE Healthcare). Institutional review board approval was obtained.

Inclusion criteria included an age over eighteen years, and imaging included the lowest rib-bearing vertebra and the entire pelvis. Exclusion criteria included any pelvic ring injury, radiographic contrast medium or implants obscuring the lumbosacral junction, lumbar scoliosis of >20°, or spina bifida. Collected demographic data included age, sex, race, height, weight, and diagnosis for which the CT scan had been ordered.

Quantification of the Osseous Safe Corridor

Each CT scan was reformatted along the axis of the sacrum to obtain cross-sectional imaging of the first and second sacral osseous corridor, or “safe zone” for iliosacral screw placement (Fig. 1). Measurements included coronal and axial angulation, cross-sectional area, and length of a 10-mm-diameter osseous corridor in the first and second sacral segments. Coronal angulation was measured as the angle subtended by a line drawn perpendicular to the axis of the osseous corridor and a line connecting the top of the iliac crests. Axial angulation was measured as the angle subtended by a line drawn perpendicular to the axis of the osseous corridor and a line connecting the posterior iliac spines. The cross-sectional area of the corridor was the least of three measurements of a best-fit oval on contiguous slices perpendicular to the axis of the sacral osseous corridor on axial reformats. The maximum length of iliosacral screw that could be used safely was measured by the longest line that could be drawn along the axis of the osseous corridor with no less than 5 mm of distance to the cortex on either side of the line in the coronal reformats. A 10-mm-diameter corridor perpendicular to the axis of the safe zone was chosen as a conservative size for passage of an iliosacral screw^{29,37}. The maximum length of this safe corridor was determined for the first and second sacral segments, and cluster analysis was used to test the hypothesis that pelvis would group according to these variables.

Qualitative Analysis

Volumetric holography was used to create virtual outlet images for qualitative analysis. In outlet reconstructions, neutral horizontal rotation was corrected by aligning lumbar spinous processes with the symphysis pubis. The vertical rotation was adjusted to align the superior cortex of the pubis with the second sacral segment body. Two orthopaedic traumatologists reviewed each outlet reconstruction and determined the presence or absence of each of the radiographic qualitative characteristics of sacral dysmorphism³¹: (1) an upper sacral segment not recessed in the pelvis, (2) the presence of mamillary processes, (3) an acute alar slope, (4) a residual disc between the first and second sacral segments, and (5) noncircular upper sacral neural foramina. The axial CT scan was reviewed for the presence or absence of a “tongue-in-groove” sacroiliac morphology.

Statistical Analysis

Clinical, demographic, anthropometric, and anatomic characteristics were compared by using means and proportions. Interobserver reliability of qualitative clinical criteria for upper sacral segment dysplasia³² was measured on the basis of agreement rates and calculation of kappa coefficients. Weighted kappa coefficients were used for characteristics with more than two categories. Hierarchical cluster analysis was used to test the hypothesis that sacra would cluster by measurable anatomic factors. The goal of this analysis was to identify higher-order groupings of subjects based on all collected anthropometric and anatomic information.

Next, we assessed which collection of traits explain membership into identified clusters using principal components analysis. The goals of principal components analysis are to extract the most important data from a complex data set, compress the data by keeping only important information, simplify description of the data, and analyze structure of observations and variables³³. The number of components retained was based on scree plot analysis and eigenvalues greater than one³⁴. The results of the cluster analysis were mapped against the variables determined to be most significant by principal components analysis. Model reduction

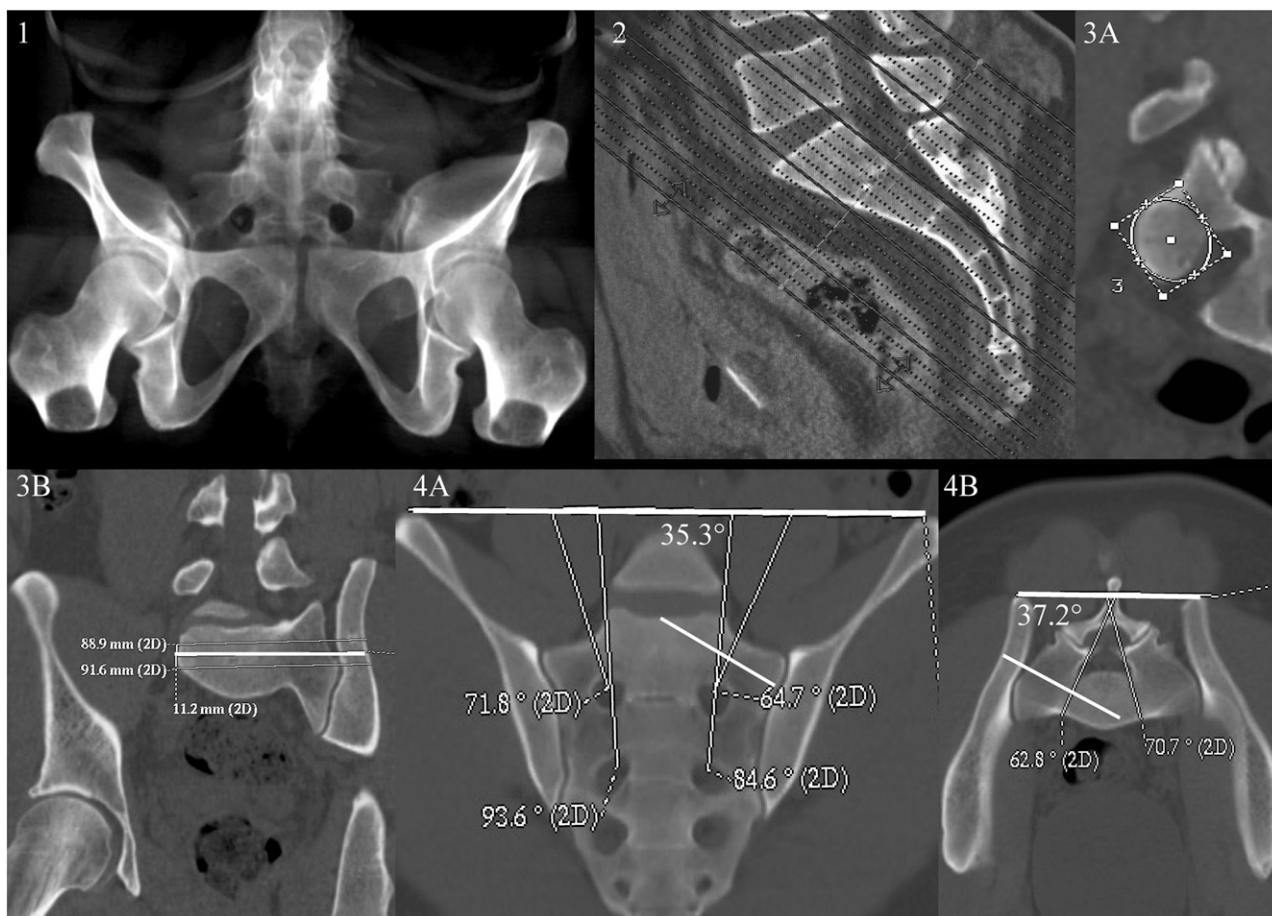


Fig. 1
Method of reformatting CT studies for qualitative and quantitative analyses. 1: An outlet reconstruction of a subject who exhibits all five qualitative characteristics of sacral dysmorphism: a first sacral segment not recessed in the pelvis, an acute slope to the sacral ala, mamillary processes, noncircular sacral foramina, and a residual disc between the first and second sacral segments. 2: The axis of coronal and axial CT reformats were reset so that the axis was perpendicular to the superior end plate of the first sacral segment. 3A and 3B: Reformats were then made perpendicular to the first and second sacral osseous corridors. 4A and 4B: The minimum cross-sectional area of the osseous corridor and maximum length of a 10-mm-diameter corridor along the axis of the osseous corridor were measured. The coronal and axial angulations of the first and second sacral segments were measured. 2D = two dimensional.

was used to determine which variables within the components accounted for the majority of variance. Linear discriminant analysis identified which variables were most important in discriminating between morphologic subgroups. STATA/SE statistical software (College Station, Texas) was used for the analysis.

Source of Funding

Funding for this study was provided by the Department of Orthopaedic Surgery, University of California San Francisco. There were no external sources of funding.

Results

One hundred and four consecutive CT scans of uninjured pelvises were analyzed. The demographics of the study population were 60% female, an average age of forty-nine years (range, eighteen to eighty-nine years), 29% Latino, 26% Asian, 22% white, 18% black, and 5% other. The average height was 165 cm (range, 147 to 196 cm), average weight was 81 kg (range, 50 to 169 kg), and average body mass index (BMI) was 29 kg/m² (range, 19 to 50 kg/m²). Indications for imaging were

flank/abdominal/back pain (65%), hematuria (22%), trauma (3%), and other indications (10%).

Qualitative Analysis

Outlet views were constructed with use of three-dimensional volumetric holography. Two orthopaedic trauma surgeons independently reviewed the outlet views and an axial CT scan and determined in binary fashion whether each of the six qualitative characteristics of sacral dysmorphism were present. The prevalences of the characteristics as determined by the two reviewers ranged between 28% to 53%. The agreement rates ranged from 75% to 81%, and the kappa values ranged from fair to moderate (Table I)³⁵. The highest kappa values were for the presence of mamillary bodies and acute alar slope.

In the quantitative analysis, minimal cross-sectional area, coronal and axial angulation, and maximum estimated iliosacral screw length were significantly greater in the first sacral segment than in the second ($p < 0.001$ for all; Table II). Each

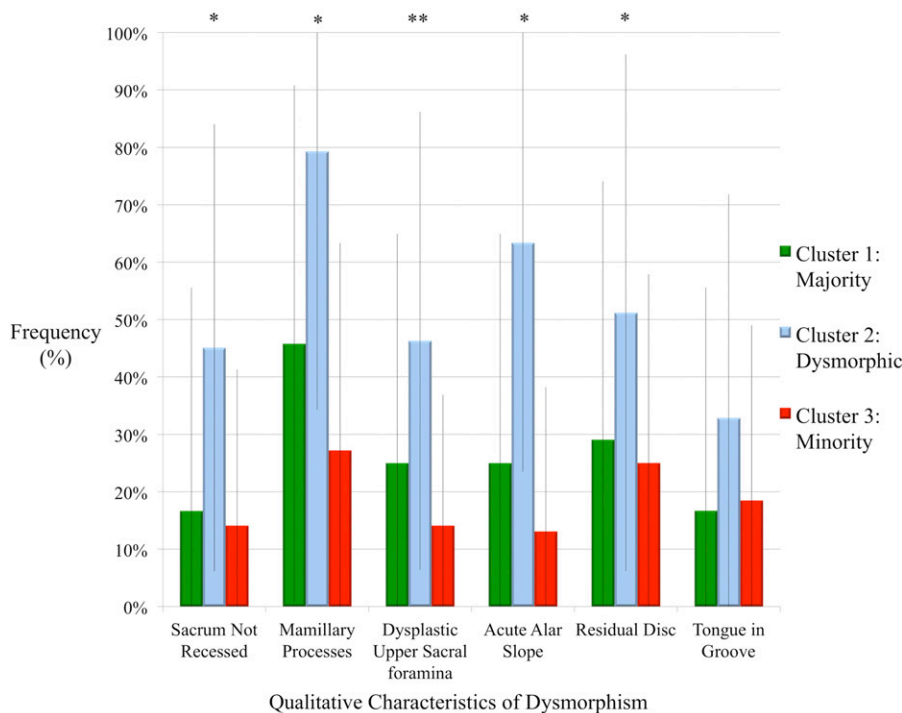


Fig. 2

Frequencies of qualitative characteristics of dysmorphism by cluster. Cluster 2 represents the dysmorphic phenotype in which a transsacral screw cannot be placed safely in the first sacral segment. The five qualitative characteristics seen on the outlet image were present significantly more frequently in the dysmorphic cluster. * $p < 0.00001$. ** $p = 0.0001$. The frequency of the tongue-in-groove characteristic, seen on the axial CT scan, was not found to differ significantly among the clusters ($p = 0.107$).

subject was measured bilaterally, and there were no differences in any measurements between sides.

In the multivariate analysis, three distinct clusters emerged on the basis of the length of the measurable 10-mm-diameter safe osseous corridor (see Appendix). In the majority phenotype (Cluster 1), there was a measurable safe corridor for passage of a long screw in the first sacral segment. The safe corridor measured >120 mm in the first sacral segment in all subjects in this cluster. In the dysmorphic phenotype (Cluster 2), insertion of a long screw was not possible in the first sacral segment but was possible in the second segment. In all subjects in this cluster, the safe corridor measured <120 mm in the first sacral segment and >110 mm in the second sacral segment. The dysmorphic phenotype was identified in 41% of the cohort. Cluster 3 represented a minority phenotype (12%), in which the measurable safe corridor was short in both sacral segments. The length of the measurable osseous 10-mm-diameter corridor and the angulation of the corridor in the coronal and axial planes varied significantly among the three clusters ($p < 0.001$ for all). The mean measurements of length and angulation of the first sacral segment are presented in Table III.

The principal components analysis identified the main determinants of morphologic variability. The first component stressed the importance of anatomic relationships in the lumbar spine and sacrum, including the number of ribbed lumbar vertebrae, number of sacral foramina, second sacral cross-sectional area, first sacral coronal and axial angulation, second sacral coronal angulation, and pelvic incidence. The second component was characterized by racial characteristics, with Latino race carrying the highest factor loading.

Variables that factored significantly in the first two components were then assessed, with use of discriminant analysis,

for a linear combination that separated the three clusters. Model reduction performed in hierarchical fashion resulted in a significant discriminant function ($p < 0.0001$). The most efficient explanation of variance of data (74% accuracy) was achieved with reduction to the two variables of first sacral coronal angulation and first sacral axial angulation. Logistic regression derived a linear relationship between the combination of first sacral coronal and axial angles and the ability to place a transsacral screw in the first sacral segment. This linear combination was best represented by the equation: $-0.122(\text{first sacral coronal angle}) - 0.268(\text{first sacral axial angle})$. The calculated area under the receiver operating characteristic curve (AUROC) for this equation was 0.93. We then simplified this relationship without decreasing the AUROC. We propose a sacral dysmorphism score as a means to accurately predict the presence of a long safe osseous corridor in the first sacral segment: $\text{sacral dysmorphism score} = (\text{first sacral coronal angle}) + 2(\text{first sacral axial angle})$.

When the overall cohort is divided by quintile, there is an inverse relationship between the magnitude of the sacral dysmorphism score and the probability of the presence of a long safe corridor in the first sacral segment (see Appendix). The higher this score, the less likely there is to be a safe transsacral corridor. There were no safe transsacral corridors in any subject with a dysmorphism score >70 .

Principal components analysis did not show any qualitative characteristics to be determinants of variability. However, when they were compared by cluster, the five qualitative characteristics of sacral dysmorphism identified on the outlet images were found to be present significantly more frequently in the dysmorphic cluster ($p < 0.007$) (Fig. 2). The sixth characteristic, "tongue-in-groove" sacroiliac morphology,

TABLE II Quantitative Measures of Safe Zone

	Mean and Standard Deviation		P Value
	First Sacral Segment	Second Sacral Segment	
Minimum cross-sectional area (mm^2)	417.4 ± 81.1	213.3 ± 87.9	<0.001
Coronal angulation (deg)	22.6 ± 11.1	5.2 ± 4.9	<0.001
Axial angulation (deg)	11 ± 10.5	3.4 ± 4.6	<0.001
Maximum iliosacral screw length (mm)	119.2 ± 35.7	128.1 ± 20.4	<0.001

was not significantly more frequent in the dysmorphic cluster ($p = 0.107$).

Case Example

The clinical utility of the sacral dysmorphism score is demonstrated in Figure 3. A twenty-eight-year-old woman was struck

by a light-rail car, resulting in a lateral compression pelvic ring injury with a transforaminal sacral fracture, bilateral pubic and ischial ramus fractures, and a left femoral fracture. Her sacral dysmorphism score was 87. After closed reduction, iliosacral screws were placed into the first and second sacral segments. A short screw that ended in the S1 vertebral body was used, to

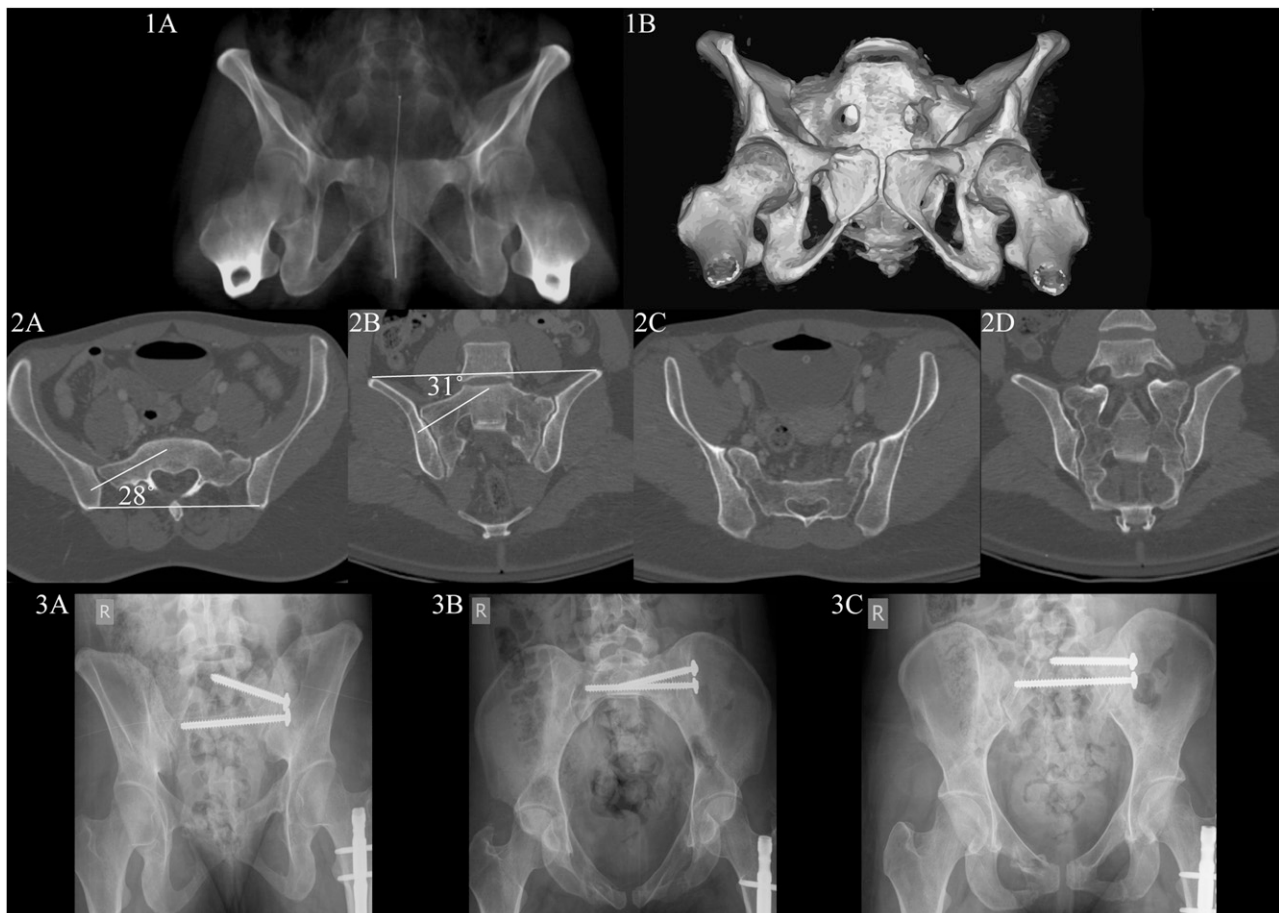

Fig. 3

Case example. A twenty-eight-year-old woman with a lateral compression pelvic ring injury with a transforaminal sacral fracture, bilateral pubic and ischial ramus fractures, and a left femoral fracture. 1A: The holographic reconstruction outlet shows qualitative characteristics of sacral dysmorphism. 1B: The three-dimensional reconstruction outlet view. 2A and 2B: The CT scan was reformatted along the axis of the sacrum. On the basis of the axial and coronal reformats of the first sacral segment, the sacral dysmorphism score was calculated as 87. 2C and 2D: Axial and coronal reformats of the second sacral segment show a transosseous corridor with little angulation. 3A, 3B, and 3C: On the basis of preoperative planning, screw fixation in both the first and the second sacral segment was employed, with the screw placed in a transsacral fashion in the second sacral segment but not in the upper sacral segment.

TABLE III First Sacral Segment Length and Angulation by Cluster

Variable/Cluster	Mean and Standard Deviation	P Value
Corridor length (mm)		<0.001
1: Majority	155.2 ± 12.7	
2: Dymorphic	87.9 ± 10.7	
3: Minority	86.6 ± 10.7	
Coronal angulation (deg)		<0.001
1: Majority	15.8 ± 8.3	
2: Dymorphic	29.6 ± 9.4	
3: Minority	23.8 ± 8.4	
Axial angulation (deg)		<0.001
1: Majority	5.0 ± 6.7	
2: Dymorphic	18.5 ± 9.5	
3: Minority	14.9 ± 10.1	

take into account her dymorphic anatomy. Her anatomy was “welcoming” to a transsacral screw in S2.

Discussion

Awareness of upper sacral segment dysplasia has increased, but we are not aware of any published definition of this entity. The purpose of this study was to construct a surgically relevant description of sacral morphology based on quantifiable parameters and discern correlates with the anatomic variations observed. This study showed that (1) qualitative definitions based on outlet radiographs are moderately reliable and valid in diagnosing upper sacral segment dysplasia, (2) the length of an osseous corridor for a 10-mm-diameter iliosacral screw in each of the first and second sacral segments is the criterion by which sacra most tightly cluster, and (3) multivariable combinations of anatomic and racial features explain much of the variation in clinical phenotype. We found that axial and coronal angulation of the upper sacral segment can accurately discriminate dymorphic sacra.

Rouff et al. first described the qualitative characteristics of upper sacral segment dysplasia.⁵ Six qualitative characteristics were associated with the dymorphic sacrum; five are best seen on an outlet-view radiograph. The sixth is a tongue-in-groove appearance of the sacroiliac articulation on a CT axial cut (Fig. 4). Other studies have shown that patients with all of these characteristics have a more narrow and angled osseous corridor in the first sacral segment compared with those who exhibit none of these characteristics.^{23,28,29} Using these criteria to adjust operative planning, surgeons can achieve percutaneous fixation of pelvic fractures with low rates of neurovascular injury, ranging from 0% to 1%.^{2,6}

We studied a large cohort of uninjured pelvis to represent the variance in morphology within the general population. The prevalence of each qualitative characteristic in our cohort was between 28% to 53%, with high agreement rates (70% to 80%) and moderate agreement according to the kappa analysis (0.29 to 0.59). The prevalence of sacral dymorphism in our subjects was similar to those in prior studies, in which the prevalences ranged from 30% to 50%.²⁷⁻²⁹

Multivariate analysis produced clustering of our population into three distinct phenotypes determined by the estimated screw length. We propose that sacral dymorphism is present when a transsacral screw cannot be safely passed in the first sacral segment but can be safely placed in the second segment. Previous authors have defined this pattern.^{28,29} Using this definition of sacral dymorphism, we found a 41% prevalence of the condition. This is at the higher end of the prevalences reported in other studies^{29,36}; a possible explanation for that is the ethnic composition of our cohort, with a 73% prevalence of minority ethnicities. In the principal components analysis, Latino, African American, and Asian ethnicity were identified as significant determinants of variation in sacral morphology. Additional research and larger sample sizes are warranted to explore variation in sacral morphology by ethnicity.

Coronal and axial angulations of the corridor in the first sacral segment are the main determinants of variation in sacral morphology. Gardner et al. previously reported greater coronal and axial angulations in dymorphic sacra.²⁹ In our study, coronal and axial angulations were the main determinants of clustering by the length of a safe osseous corridor.

We did not find the qualitative characteristics of sacral dymorphism to be significant determinants of variability. This is likely due to the high prevalence of each characteristic within the cohort. When the dymorphic and non-dymorphic clusters were compared, there was a significantly greater frequency of each of the five radiographic characteristics within the dymorphic cluster. This suggests that the qualitative characteristics correlate with dymorphism but no single characteristic or combination of characteristics defines dymorphism. The tongue-in-groove characteristic, seen on axial CT, is a less reliable marker for

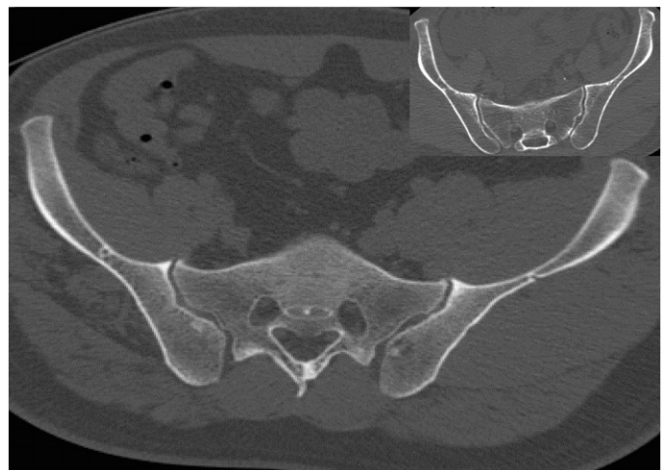

Fig. 4

An example of the tongue-in-groove characteristic, seen on axial CT imaging. The term is an analogy derived from woodworking, in which boards are brought together by using an interlocking tongue from one board into a groove on the other. In the larger image, there is a protrusion of the ilium (tongue) that fits into a concavity on the sacrum. In the inset image, the characteristic is not present. We found that there was no significant difference in the prevalence of the tongue-in-groove characteristic between the dymorphic and nondymorphic clusters.

dysmorphism. Our study provides a quantitative means of determining dysmorphism, through use of CT reformats, measurement of the true axial and coronal angulation of the corridor, and calculation of the sacral dysmorphism score.

The sacral dysmorphism score is calculated by the summation of the first sacral segment coronal angulation and twice the first sacral segment axial angulation. The sacral dysmorphism score correlates with the presence of a safe transsacral osseous corridor, and provides an objective way to preoperatively plan iliosacral screw fixation.

In our study, the higher the sacral dysmorphism score, the lower the likelihood of the presence of a safe transsacral osseous corridor. No patient with a dysmorphic score higher than 70 had an osseous corridor that traversed the sacrum. We propose that the sacral dysmorphism score can assist the surgeon in determining whether it is technically appropriate to place a transsacral screw when treating a pelvic fracture.


In practice, surgeons often target the screw oblique to the axis of the first sacral corridor in order to achieve a transsacral screw. This practice can increase the maximum iliosacral screw length that can be used, but at the expense of a functional decrease in the surrounding osseous corridor and increase in the risk of cortical perforation. We measured the length of an osseous corridor along the safe zone axis of 10 mm in diameter. Ten millimeters was chosen to provide 1 to 2 mm of circumference around a 6.3 to 8-mm-diameter screw, and has been previously established as a reasonably “safe”-diameter corridor by experienced surgeons^{4,29,37}. The smallest cross-sectional area that we measured in a first sacral osseous corridor was 206 mm². In comparison, an 8-mm iliosacral screw has a cross-sectional area of 50.2 mm². Therefore, while passage of a transsacral screw was considered “unsafe” for nearly half of the subjects on the basis of a combination of corridor diameter and angulation, none had a unilateral corridor that was too small for passage of an 8-mm screw. It is likely that patients in the minority group (Cluster 3) were classified as such because of our conservative 10-mm threshold and not because of a substantive difference in first sacral coronal or axial angulation. Table III demonstrates that these angles for the minority cluster fall between those in the majority and dysmorphic groups, suggesting that they represent an average of these larger groups; however, subjects were probably assigned to the minority group because of the diminutive size (small safe-zone cross-sectional areas) of their pelvis. If an experienced surgeon passes an 8-mm-diameter or narrower screw at an angle not along the axis of the osseous corridor, it would be technically possible to pass it in a transsacral fashion without cortical perforation in an unknown percentage of the subjects for whom we determined the screw passage to be “unsafe.”

Our findings can be adapted in practice by all surgeons who apply instrumentation to the sacrum. We recommend that CT scans obtained to evaluate pelvic fractures be reformatted along the axis of the sacrum, and that the sacral dysmorphism score be calculated to quantify the morphology of the upper sacral segment prior to iliosacral screw fixation. Future clinical research is recommended to validate and test the ability to use reformatted CT imaging and the sacral dysmorphism score to plan screw length and angulation. The complex three-dimensional

morphology of the sacral osseous corridor presents a challenge to surgeons applying instrumentation, and may represent an ideal application of computer navigation technology.

In conclusion, upper sacral segment dysplasia can be defined as a constellation of morphological features that increase the risk of cortical perforation of a transsacral screw, potentially leading to neurovascular injury. The two most important quantitative characteristics that determine upper sacral segment dysplasia are coronal and axial angulation of the first sacral segment. Patients with upper sacral segment dysplasia more frequently show the qualitative characteristics of sacral dysmorphism on pelvic outlet radiographs. The presence of the five qualitative characteristics of sacral dysmorphism on the outlet image should prompt closer preoperative attention to the morphology of the first sacral segment. The sacral dysmorphism score determined from CT reformats along the plane of the sacrum can be used to estimate the presence of an unsafe corridor. A high sacral dysmorphism score correlates with anatomy that precludes the safe placement of a transsacral screw. We recommend use of these CT reformats and the sacral dysmorphism score in preoperative planning to direct the choice of technique for placement of iliosacral screws.

Appendix

 A table showing the sacral dysmorphism scores by quintile in the cohort and a figure demonstrating the three clusters graphed according to the first and second sacral corridor lengths are available with the online version of this article as a data supplement at jbjs.org. ■

Scott P. Kaiser, MD
Department of Orthopaedic Surgery,
University of California San Francisco,
500 Parnassus Avenue,
MU-320W, San Francisco, CA 94143.
E-mail address: kaisersp@orthosurg.ucsf.edu

Michael J. Gardner, MD
Department of Orthopaedics,
Washington University School of Medicine in St. Louis,
660 South Euclid Avenue,
Campus Box 8233, St. Louis, MO 63110

Joseph Liu, MD
Hospital for Special Surgery,
535 East 70th Street,
New York, NY 10021

M.L. Chip Routh Jr., MD
University of Texas,
6431 Fannin Street,
Houston, TX 77030

Saam Morshed, MD, PhD
University of California,
San Francisco,
2550 23rd Street,
Building 9, 2nd Floor,
San Francisco, CA 94110

References

1. Enninghorst N, Toth L, King KL, McDougall D, Mackenzie S, Balogh ZJ. Acute definitive internal fixation of pelvic ring fractures in polytrauma patients: a feasible option. *J Trauma*. 2010 Apr;68(4):935-41.
2. Gardner MJ, Farrell ED, Nork SE, Segina DN, Routh ML Jr. Percutaneous placement of iliosacral screws without electrodiagnostic monitoring. *J Trauma*. 2009 May;66(5):1411-5.
3. Cole JD, Blum DA, Ansel LJ. Outcome after fixation of unstable posterior pelvic ring injuries. *Clin Orthop Relat Res*. 1996 Aug;(329):160-79.
4. Moed BR, Geer BL. S2 iliosacral screw fixation for disruptions of the posterior pelvic ring: a report of 49 cases. *J Orthop Trauma*. 2006 Jul;20(6):378-83.
5. Routh ML Jr, Kregor PJ, Simonian PT, Mayo KA. Early results of percutaneous iliosacral screws placed with the patient in the supine position. *J Orthop Trauma*. 1995 Jun;9(3):207-14.
6. Schweitzer D, Zylberberg A, Córdova M, Gonzalez J. Closed reduction and iliosacral percutaneous fixation of unstable pelvic ring fractures. *Injury*. 2008 Aug;39(8):869-74. Epub 2008 Jul 14.
7. Shuler TE, Boone DC, Gruen GS, Peitzman AB. Percutaneous iliosacral screw fixation: early treatment for unstable posterior pelvic ring disruptions. *J Trauma*. 1995 Mar;38(3):453-8.
8. Pohlemann T, Bosch U, Gänsslen A, Tscherne H. The Hannover experience in management of pelvic fractures. *Clin Orthop Relat Res*. 1994 Aug;(305):69-80.
9. Tile M. Acute pelvic fractures: I. Causation and classification. *J Am Acad Orthop Surg*. 1996 May;4(3):143-51.
10. Keating JF, Werier J, Blachut P, Broekhuysen H, Meek RN, O'Brien PJ. Early fixation of the vertically unstable pelvis: the role of iliosacral screw fixation of the posterior lesion. *J Orthop Trauma*. 1999 Feb;13(2):107-13.
11. Griffin DR, Starr AJ, Reinert CM, Jones AL, Whitlock S. Vertically unstable pelvic fractures fixed with percutaneous iliosacral screws: does posterior injury pattern predict fixation failure? *J Orthop Trauma*. 2006 Jan;20(1 Suppl):S30-6; discussion S36.
12. Sagi HC, Lindvall EM. Inadvertent intraforaminal iliosacral screw placement despite apparent appropriate positioning on intraoperative fluoroscopy. *J Orthop Trauma*. 2005 Feb;19(2):130-3.
13. Altman DT, Jones CB, Routh ML Jr. Superior gluteal artery injury during iliosacral screw placement. *J Orthop Trauma*. 1999 Mar-Apr;13(3):220-7.
14. Ko PS, Kou SK. A rare complication of percutaneous iliosacral screw in a vertically unstable pelvic disruption in a child. *Injury*. 2001 Mar;32(2):159-61.
15. Peeters G, Govaers K, Himpens J. Successful laparoscopic exploration and screw extraction for intractable pain after anterior iliosacral arthrodesis. *J Orthop Trauma*. 2010 Oct;24(10):e83-5.
16. Weil YA, Nousiainen MT, Helfet DL. Removal of an iliosacral screw entrapping the L5 nerve root after failed posterior pelvic ring fixation: a case report. *J Orthop Trauma*. 2007 Jul;21(6):414-7.
17. Templeman D, Schmidt A, Freese J, Weisman I. Proximity of iliosacral screws to neurovascular structures after internal fixation. *Clin Orthop Relat Res*. 1996 Aug;(329):194-8.
18. Reilly MC, Bono CM, Litkouhi B, Sirkin M, Behrens FF. The effect of sacral fracture malreduction on the safe placement of iliosacral screws. *J Orthop Trauma*. 2003 Feb;17(2):88-94.
19. Routh ML Jr, Simonian PT, Mills WJ. Iliosacral screw fixation: early complications of the percutaneous technique. *J Orthop Trauma*. 1997 Nov;11(8):584-9.
20. Griffin DR, Starr AJ, Reinert CM, Jones AL, Whitlock S. Vertically unstable pelvic fractures fixed with percutaneous iliosacral screws: does posterior injury pattern predict fixation failure? *J Orthop Trauma*. 2003 Jul;17(6):399-405.
21. Gardner MJ, Routh ML Jr. Transiliac-transsacral screws for posterior pelvic stabilization. *J Orthop Trauma*. 2011 Jun;25(6):378-84.
22. Templeman D, Schmidt A, Freese J, Weisman I. Proximity of iliosacral screws to neurovascular structures after internal fixation. *Clin Orthop Relat Res*. 1996 Aug;(329):194-8.
23. Day CS, Prayson MJ, Shuler TE, Towers J, Gruen GS. Transsacral versus modified pelvic landmarks for percutaneous iliosacral screw placement—a computed tomographic analysis and cadaveric study. *Am J Orthop (Belle Mead NJ)*. 2000 Sep;29(9 Suppl):16-21.
24. Graves ML, Routh ML Jr. Iliosacral screw placement: are uniplanar changes realistic based on standard fluoroscopic imaging? *J Trauma*. 2011 Jul;71(1):204-8; discussion 208.
25. Wolinsky P, Lee M. The effect of C-arm malrotation on iliosacral screw placement. *J Orthop Trauma*. 2007 Aug;21(7):427-34.
26. Xu R, Ebraheim NA, Robke J, Yeasting RA. Radiologic evaluation of iliosacral screw placement. *Spine (Phila Pa 1976)*. 1996 Mar 1;21(5):582-8.
27. Miller AN, Routh ML Jr. Variations in sacral morphology and implications for iliosacral screw fixation. *J Am Acad Orthop Surg*. 2012 Jan;20(1):8-16.
28. Conflitti JM, Graves ML, Chip Routh ML Jr. Radiographic quantification and analysis of dysmorphic upper sacral osseous anatomy and associated iliosacral screw insertions. *J Orthop Trauma*. 2010 Oct;24(10):630-6.
29. Gardner MJ, Morshed S, Nork SE, Ricci WM, Chip Routh ML Jr. Quantification of the upper and second sacral segment safe zones in normal and dysmorphic sacra. *J Orthop Trauma*. 2010 Oct;24(10):622-9.
30. Karachalios T, Zibis AH, Zintzaras E, Bargiotas K, Karantanas AH, Malizos KN. An anatomical update on the morphologic variations of S1 and S2. *Orthopedics*. 2010 Oct 11;33(10):733.
31. Routh ML Jr, Simonian PT, Agnew SG, Mann FA. Radiographic recognition of the sacral alar slope for optimal placement of iliosacral screws: a cadaveric and clinical study. *J Orthop Trauma*. 1996;10(3):171-7.
32. Routh ML Jr, Kregor PJ, Simonian PT, Mayo KA. Early results of percutaneous iliosacral screws placed with the patient in the supine position. *J Orthop Trauma*. 1995 Jun;9(3):207-14.
33. Abdi H, Williams LJ. Principal component analysis. *WIREs Comput Stat*. 2010 Jul-Aug;2(4):433-59.
34. Jackson DA. Stopping rules in principal components analysis: a comparison of heuristic and statistical approaches. *Ecology*. 1993;74(8):2204.
35. Landis JR, Koch GG. The measurement of observer agreement for categorical data. *Biometrics*. 1977 Mar;33(1):159-74.
36. Wu LP, Li YK, Li YM, Zhang YQ, Zhong SZ. Variable morphology of the sacrum in a Chinese population. *Clin Anat*. 2009 Jul;22(5):619-26.
37. Ziran BH, Wasan AD, Marks DM, Olson SA, Chapman MW. Fluoroscopic imaging guides of the posterior pelvis pertaining to iliosacral screw placement. *J Trauma*. 2007 Feb;62(2):347-56; discussion 356.