

## Washington University School of Medicine Digital Commons@Becker

---

### Open Access Publications

---

2010

# Sliding-clip renorrhaphy provides superior closing tension during robot-assisted partial nephrectomy

Brian M. Benway

*Washington University School of Medicine in St. Louis*

Jose M. Cabello

*Washington University School of Medicine in St. Louis*

Robert S. Figenshau

*Washington University School of Medicine in St. Louis*

Sam B. Bhayani

*Washington University School of Medicine in St. Louis*

Follow this and additional works at: [http://digitalcommons.wustl.edu/open\\_access\\_pubs](http://digitalcommons.wustl.edu/open_access_pubs)

---

### Recommended Citation

Benway, Brian M.; Cabello, Jose M.; Figenshau, Robert S.; and Bhayani, Sam B., "Sliding-clip renorrhaphy provides superior closing tension during robot-assisted partial nephrectomy." *Journal of Endourology*.24,4. 605-608. (2010).  
[http://digitalcommons.wustl.edu/open\\_access\\_pubs/2827](http://digitalcommons.wustl.edu/open_access_pubs/2827)

This Open Access Publication is brought to you for free and open access by Digital Commons@Becker. It has been accepted for inclusion in Open Access Publications by an authorized administrator of Digital Commons@Becker. For more information, please contact [engeszer@wustl.edu](mailto:engeszer@wustl.edu).

# Sliding-Clip Renorrhaphy Provides Superior Closing Tension During Robot-Assisted Partial Nephrectomy

Brian M. Benway, M.D., Jose M. Cabello, M.D.,  
Robert S. Figenshau, M.D., and Sam B. Bhayani, M.D.

## Abstract

**Objective:** Recently, our institution refined a technique for robot-assisted renorrhaphy utilizing sliding Weck Hem-O-Lock clips, which are tightened by the surgeon seated at the console and locked into place with a LapraTy clip. In addition to the relative ease of implementation, we believe that our technique also provides a superior strength of closure over other commonly used techniques.

**Methods:** An *in vivo* porcine model was used to compare a sliding-clip technique against an assistant-placed LapraTy-only closure, and a surgeon-placed simple suture closure. A force gauge was used to record the maximum tension that could be applied during each closure method before the suture ripped through the renal parenchyma, thus illustrating the relative strength of each closure.

**Results:** The simple suture closure performed relatively poorly, ripping through parenchyma at a mean force of 11.3 N. The LapraTy-only method allowed a maximum applicable mean force of 16.7 N. The sliding Weck clip with a LapraTy bolster provided the tightest closure, allowing for a mean force of 32.7 N before ripping through parenchyma. Statistical analysis reveals that a sliding-clip technique provides a significantly tighter closure than both of the other tested methods.

**Conclusion:** A sliding-clip technique allows for more tension to be safely applied to the closure of a partial nephrectomy defect than other commonly used methods. We believe that this is primarily attributable to the larger footprint of the Hem-O-Lock clip, which allows for the tension to be distributed over a greater surface area. The LapraTy then ensures the security of the closure by holding the Weck clip in place. Further studies are necessary to determine if this increased tension translates into appreciably better hemostasis.

## Introduction

**I**N THE HANDS of an experienced surgeon, laparoscopic partial nephrectomy is capable of providing similar oncologic outcomes to an open approach, while minimizing recovery times.<sup>1,2</sup> However, the need for adept intracorporeal suturing skills and rapid renal reconstruction may involve a steep learning curve,<sup>3</sup> which may limit the procedure to high-volume centers of excellence.<sup>4–6</sup> Robot-assisted partial nephrectomy (RAPN) is an emerging technique that significantly decreases the technical challenges associated with hilar dissection and renorrhaphy.<sup>7,8</sup>

Regardless of the approach, the renorrhaphy remains one of the most technically challenging portions of the case, especially under the time constraints of warm ischemia.<sup>5,8</sup> To address this challenge, alternatives to traditional tied closures have been introduced<sup>6,9–12</sup>; however, many of these tech-

niques rely upon a skilled assistant working with angles that at times are less-than-ideal.<sup>10,13,14</sup>

Recently, we reported our refined technique for renal reconstruction, which is distinguished from other techniques by the use of sliding clips that are under the control of the surgeon at the console,<sup>15–17</sup> with minimal use of bolsters and hemostatic agents. This renorrhaphy technique is unique in that it affords the surgeon seated at the console complete control over the tension applied to the renorrhaphy, and in our experience, it appears to offer a more secure closure than any other previously described method. However, this subjective appraisal has not yet been supported with objective data.

To that end, we developed an animal model designed to objectively evaluate three of the most common techniques for renal reconstruction. More specifically, we examined the maximum tension that can be placed upon each repair before

disrupting the capsule, thereby defining the upper limit of tension that may be safely applied to each closure.

## Materials and Methods

Under appropriate institutional animal care requirements, a total of three domestic swine underwent lower pole heminephrectomy under anesthesia, using standard robotic technique.<sup>7,13,17-19</sup>

For the renorrhaphy, three different methods for renal reconstruction were evaluated: (1) a traditional knot-tied suture closure (similar to an open procedure); (2) assistant-controlled clip closure, utilizing LapraTy clips (Ethicon EndoSurgery, Piscataway, NJ); and (3) sliding-clip renorrhaphy, utilizing sliding Weck Hem-O-Lock (Teleflex, Research Triangle Park, NC) clips under complete control of the surgeon. No bolsters were used for any of the closure methods.

The ends of the suture were left long enough to protrude from the trocar. To this free end of the suture material, a digital force gauge (Chatillon, Largo, FL) was utilized to measure the maximum allowable tension on the closure before the suture ripped through the renal capsule, thus indicating the relative maximum strength of each closure. Multiple measurements of each closure technique were recorded.

Though a detailed description of the technique for sliding-clip renorrhaphy can be found elsewhere,<sup>15,17,19</sup> we briefly summarize the technique here. A 0 or no. 1 polyglactin suture is prepared on the back table by cutting to a length of 15 cm. A knot is tied at the end, above which a LapraTy clip is placed, followed by a Weck Hem-O-Lock clip. The capsular stitches are then placed, after which the assistant places a Weck Hem-O-Lock clip on the loose end, a few centimeters from the capsule. The Hem-O-Lock clip is then slid into place using the robotic needle driver, providing tension that is under complete control of the surgeon. In addition, the motion scaling offered by the robot allows for fine adjustments to the closure to be made based on visual cues. A LapraTy clip is then placed to lock the Weck clip into position (Fig. 1).

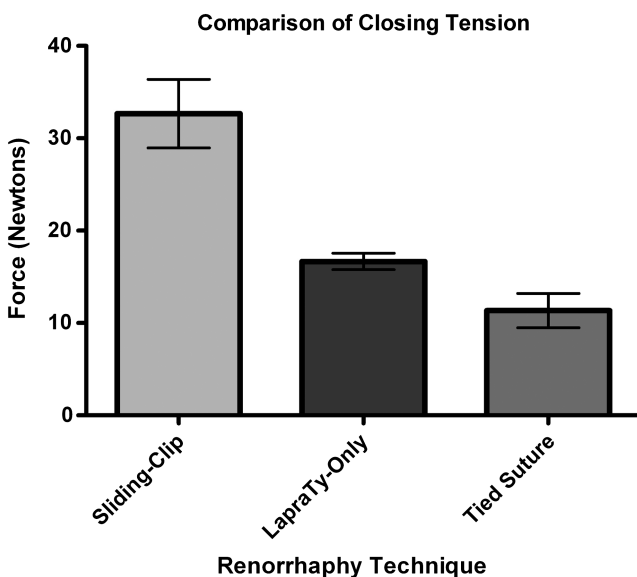


FIG. 1. Comparison of closing tension provided by three robot-assisted renorrhaphy techniques.

Following the completion of the procedure, the animals were humanely euthanized according to standard protocols. The results were analyzed using a one-way analysis of variance, and a Tukey's HSD test was employed for *post hoc* analysis.

## Results

The simple robotic tied suture closure ripped through the capsule at a mean maximum force of 11.3 N (range, 9–15 N; median, 10 N). The assistant-placed LapraTy closure disrupted the capsule at a mean maximum force of 16.7 N (range, 15–18 N; median, 17 N). Using the sliding-clip technique, a mean maximum tension of 32.7 N (range, 28–40 N; median, 30 N) could be applied before the capsule tore.

A one-way analysis of variance demonstrates a significant difference in the maximum force that is able to be applied in each method ( $p = 0.002$ ). *Post hoc* analysis with Tukey's HSD test set at an overall alpha level of 0.01 reveals that there is no significant difference between the knot-tied suture and the LapraTy-only closure, whereas sliding-clip renorrhaphy provides significantly more tension than both the simple suture and LapraTy-only closures.

## Discussion

Laparoscopic partial nephrectomy has been established as a viable alternative to open partial nephrectomy, boasting equivalent oncologic outcomes with improved recovery times.<sup>2</sup> However, even in the hands of an experienced laparoscopist, the procedure remains technically challenging, especially with respect to renal reconstruction.<sup>3</sup>

RAPN is an emerging technique that seeks to reduce the technical challenge associated with a pure laparoscopic approach. However, one potential downside of the robotic approach is an increased reliance upon the assistant to perform some of the more critical aspects of the case. This is especially true if a clip renorrhaphy is performed using standard laparoscopic principles, as the assistant then controls the tension placed upon the closure. Our sliding-clip technique, however, affords the surgeon nearly total control over the closure and places fewer demands upon the assistant.

There are many potential factors that may contribute to the superior renorrhaphy provided by a sliding-clip technique. The relatively large footprint of the Hem-O-Lock clip allows for the tension placed on the closure to be distributed over a greater surface area, a property also suggested by Canales et al.<sup>12</sup> In addition, the ease of sliding the Hem-O-Lock clips over the suture material prevents snagging on the suture, which could cause the surgeon to overcompensate and overshoot the desired tension. A sliding-clip technique affords the surgeon precise control over the tension of the renorrhaphy at all times, even allowing for adjustment of the tension if necessary.

Early results using sliding-clip renorrhaphy technique show promise. One recent report found that introduction of a sliding-clip renorrhaphy technique during RAPN was associated with a nearly 8-minute decrease in warm ischemic time, compared with a tied-suture approach under robot assistance.<sup>17</sup> In the largest single-institution comparison series to date, RAPN with sliding-clip renorrhaphy was not only associated with shorter overall operative times, but also with significantly shorter warm ischemia times than laparoscopic

partial nephrectomy performed by the same surgeon.<sup>16</sup> Only one bleeding complication has occurred in our institutional RAPN experience, in a patient who required early heparinization for a pulmonary embolus.<sup>16,17,20</sup>

Despite the early promise of the sliding-clip technique, there are several potential criticisms of our present study that warrant comment. First, it could be argued that an assistant could be capable of placing a Hem-O-Lock clip under the same tension as the surgeon using our method. Although, in theory, this may be entirely possible, the reality is that assistants are often working with nonarticulating instruments at angles that are often suboptimal. In addition, the fulcrum effect of traditional laparoscopic instruments may prove a hindrance to the precision required to fine-tune the tension placed upon the repair.

Another potential criticism is that our data were skewed by the omission of pledgets from the LapraTy and traditional suture closures. However, as the quality of pledgets can vary between institutions, based upon the type of material used and the size to which they are cut, it would have proven difficult to standardize the materials for this study in a manner that would be applicable to other institutions. Certainly, however, this is one aspect of closure technique that would benefit from further investigation.

One potentially major criticism of the sliding-clip technique is that the additional tension is superfluous, and that it may not contribute to measurably better hemostasis than other techniques that place the repair on less tension. As the endpoint in this particular study was disruption of the renal capsule, we were unable to critically evaluate hemostasis in our present animal model. Likewise, there is a paucity of human data that directly compares renorrhaphy techniques. As such, a second study comparing perioperative blood loss under typical closure conditions would need to be performed to prospectively compare the quality of hemostasis achieved by each technique. However, given the apparent rarity of bleeding complications, such a study may be problematic because of the large number of subjects that would be required to lend the study sufficient power.

Also, the durability of the tension provided by the sliding-clip technique is presently unknown. While a LapraTy is used to secure the closure, our experience demonstrates that with calculated force, the LapraTy can be made to slide over the suture, albeit to a far lesser degree than the Hem-O-Lock clips. Therefore, it is possible that over time, the tension does relax to some degree, though the practical effect this would have upon the closure would not be easily qualified. At the very least, we would expect that over the long term, our preferred closure would be equivocal or superior to LapraTy-only closures, which could be subject to the same potential for relaxation.

Finally, as the Weck Hem-O-Lock clip is nondegradable, its ultimate fate is unclear. As the experience with this technique is early, it is not yet known if these clips are prone to migration or erosion when placed under tension and in direct contact with the renal capsule. However, one recent study evaluating LapraTy closure for partial nephrectomy found that at 8 weeks, the LapraTy clips were encapsulated, and no erosion or migration was noted.<sup>11</sup> Long-term follow-up data will be necessary to evaluate this critical aspect of our technique.

## Conclusions

Though the experience is early, our data demonstrate that sliding-clip renorrhaphy provides superior tension on the closure during renal reconstruction. Although further studies will be necessary to determine if this additional tension provides a practical benefit in terms of the quality of repair, early outcomes using the technique are promising.

## Disclosure Statement

Dr. Bhayani is a consultant for Intuitive Surgical Corp.

## References

1. Lane BR, Gill IS. 5-Year outcomes of laparoscopic partial nephrectomy. *J Urol* 2007;177:70–74; discussion 74.
2. Gill IS, Kavoussi LR, Lane BR, Blute ML, Babineau D, Colombo JR Jr., et al. Comparison of 1,800 laparoscopic and open partial nephrectomies for single renal tumors. *J Urol* 2007;178:41–46.
3. Link RE, Bhayani SB, Allaf ME, Varkarakis I, Inagaki T, Rogers C, et al. Exploring the learning curve, pathological outcomes and perioperative morbidity of laparoscopic partial nephrectomy performed for renal mass. *J Urol* 2005;173:1690–1694.
4. Hollenbeck BK, Taub DA, Miller DC, Dunn RL, Wei JT. National utilization trends of partial nephrectomy for renal cell carcinoma: A case of underutilization? *Urology* 2006;67:254–259.
5. Aron M, Koenig P, Kaouk JH, Nguyen MM, Desai MM, Gill IS. Robotic and laparoscopic partial nephrectomy: A matched-pair comparison from a high-volume centre. *BJU Int* 2008;102:86–92.
6. Weight CJ, Lane BR, Gill IS. Laparoscopic partial nephrectomy for selected central tumours: Omitting the bolster. *BJU Int* 2007;100:375–378.
7. Rogers CG, Singh A, Blatt AM, Linehan WM, Pinto PA. Robotic partial nephrectomy for complex renal tumors: Surgical technique. *Eur Urol* 2008;53:514–521.
8. Rogers CG, Menon M, Weise ES, Gettman MT, Frank I, Shephard DL, et al. Robotic partial nephrectomy: A multi-institutional analysis. *J Robotic Surg* 2008;2:141–143.
9. Abaza R, Picard J. A novel technique for laparoscopic or robotic partial nephrectomy: Feasibility study. *J Endourol* 2008;22:1715–1719.
10. Orvieto MA, Chien GW, Tolhurst SR, Rapp DE, Steinberg GD, Mikhail AA, et al. Simplifying laparoscopic partial nephrectomy: Technical considerations for reproducible outcomes. *Urology* 2005;66:976–980.
11. Orvieto MA, Lotan T, Lyon MB, Zorn KC, Mikhail AA, Rapp DE, et al. Assessment of the LapraTy clip for facilitating reconstructive laparoscopic surgery in a porcine model. *Urology* 2007;69:582–585.
12. Canales BK, Lynch AC, Fernandes E, Anderson JK, Ramani AP. Novel technique of knotless hemostatic renal parenchymal suture repair during laparoscopic partial nephrectomy. *Urology* 2007;70:358–359.
13. Gettman MT, Blute ML, Chow GK, Neururer R, Bartsch G, Peschel R. Robotic-assisted laparoscopic partial nephrectomy: Technique and initial clinical experience with DaVinci robotic system. *Urology* 2004;64:914–918.
14. Caruso RP, Phillips CK, Kau E, Taneja SS, Stifelman MD. Robot assisted laparoscopic partial nephrectomy: Initial experience. *J Urol* 2006;176:36–39.

15. Bhayani SB, Figenshau RS. The Washington University renorrhaphy for robotic partial nephrectomy: A detailed description of the technique displayed at the 2008 World Robotic Urologic Symposium. *J Robotic Surg* 2008;2:139–140.
16. Wang AJ, Bhayani SB. Robotic partial nephrectomy versus laparoscopic partial nephrectomy for renal cell carcinoma: Single-surgeon analysis of >100 consecutive procedures. *Urology* 2009;73:306–310.
17. Benway BM, Wang AJ, Cabello JM, Bhayani SB. Robotic partial nephrectomy with sliding-clip renorrhaphy: Technique and outcomes. *Eur Urol* 2009;55:592–599.
18. Bhayani SB. da Vinci robotic partial nephrectomy for renal cell carcinoma: An atlas of the four-arm technique. *J Robotic Surg* 2008;1:279–285.
19. Cabello JM, Benway BM, Bhayani SB. Robotic-assisted partial nephrectomy: Surgical technique using a 3-arm approach and sliding-clip renorrhaphy. *Int Braz J Urol* 2009;35:199–203.
20. Bhayani SB, Das N. Robotic assisted laparoscopic partial nephrectomy for suspected renal cell carcinoma: Retrospective review of surgical outcomes of 35 cases. *BMC Surg* 2008;8:16.

Address correspondence to:

*Brian M. Benway, M.D.*

*Division of Urologic Surgery*

*Department of Surgery*

*Washington University School of Medicine*

*600 S. Euclid Ave.*

*Campus Box 8242*

*Saint Louis, MO 63110*

*E-mail: benwayb@wudosis.wustl.edu*

**Abbreviation Used**

RAPN = robot-assisted partial nephrectomy