

2008

# Robotic renal hilar control and robotic clip placement for partial nephrectomy

Robert Figenshau

*Washington University School of Medicine in St. Louis*

Sam Bhayani

*Washington University School of Medicine in St. Louis*

Ramakrishna Venkatesh

*Washington University School of Medicine in St. Louis*

Agnes Wang

*Washington University School of Medicine in St. Louis*

Follow this and additional works at: [http://digitalcommons.wustl.edu/open\\_access\\_pubs](http://digitalcommons.wustl.edu/open_access_pubs)

---

## Recommended Citation

Figenshau, Robert; Bhayani, Sam; Venkatesh, Ramakrishna; and Wang, Agnes, "Robotic renal hilar control and robotic clip placement for partial nephrectomy." *Journal of Endourology*.22,12. 2657-2660. (2008).  
[http://digitalcommons.wustl.edu/open\\_access\\_pubs/2900](http://digitalcommons.wustl.edu/open_access_pubs/2900)

This Open Access Publication is brought to you for free and open access by Digital Commons@Becker. It has been accepted for inclusion in Open Access Publications by an authorized administrator of Digital Commons@Becker. For more information, please contact [engeszer@wustl.edu](mailto:engeszer@wustl.edu).

## *Tricks of the Trade*

# Robotic Renal Hilar Control and Robotic Clip Placement for Partial Nephrectomy\*

Robert Figenshau, M.D., Sam Bhayani, M.D., Ramakrishna Venkatesh, M.D., and Agnes Wang

### Abstract

We demonstrate two techniques in this video clip that can be used when performing robotic-assisted laparoscopic partial nephrectomy. First, we use the fourth arm of the robot with a long-tip grasper to occlude the renal artery during the resection of the mass. Second, we show a novel method for securing the mattress sutures when performing the repair of the kidney. Both maneuvers help to increase the safety of the procedure and decrease the warm ischemia time to the kidney.

### Introduction

THE APPLICATION OF ROBOTIC TECHNOLOGY in laparoscopic renal surgery is intuitive. A problem with this approach is that the surgeon loses some of the control of the case by not being immediately at the bedside. The surgeon depends on the bedside assistant to pass and place instruments and clips into the abdomen. This can be a difficult, frustrating, and potentially dangerous task for the inexperienced assistant. The surgeon depends on the assistant to perform certain critical maneuvers, such as placing laparoscopic bulldog clamps on the renal vessels and placing clips for hemostasis. In an effort to keep a maximum amount of control in the hands of the surgeon, we have developed two techniques that help in the performance of a robot-assisted laparoscopic partial nephrectomy.

We report the use of the fourth arm for control of the renal artery during a robot-assisted laparoscopic partial nephrectomy. We also demonstrate a technique using Weck clips for securing parenchymal mattress sutures that allows the surgeon, and not the assistant, to secure the clips under the desired amount of tension.

### Technique

The port for the fourth robotic arm is placed in the lower quadrant in the midclavicular line (Fig. 1). The port should

not be placed too medially or too close to the other robotic arms. The instrument we selected is the Long-Tip Forceps, part number 420048. We chose this instrument for its atraumatic jaw and medium grip strength. The forceps can be applied to just the renal artery, as in this demonstration case (Fig. 2). We have also applied it to occlude both the renal artery and vein like a “robotic laparoscopic Satinsky clamp.” The surgeon has complete control. The fourth arm should be marked at the bedside, so the instrument is not inadvertently disturbed while it is applied at the renal hilum.

We also found it frustrating for the assistant to place clips on the hemostatic mattress sutures under the proper tension. With this technique, the assistant simply places a Weck clip on the suture (Fig. 3); the surgeon slides the clip on the suture to the desired tension. A similar laparoscopic technique has been reported by Canales and colleagues.<sup>1</sup> We also place Lapra-Ty clips as well to secure the Weck clips.

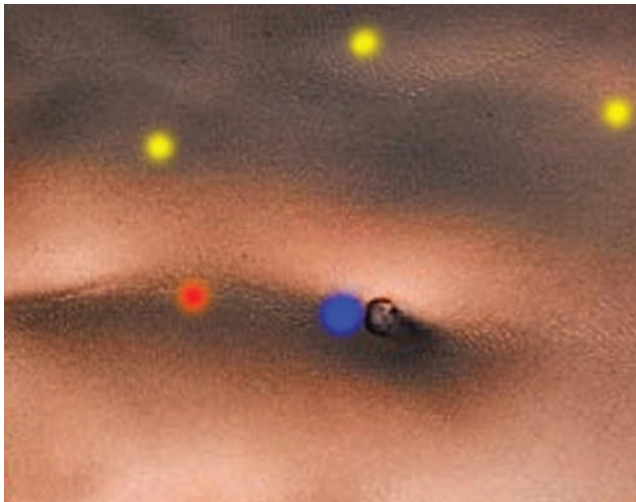
These two simple maneuvers have helped us to keep control of critical steps of the operation under the control of the surgeon and reduce the potential for frustration for the surgical team and injury to the patient.

### Disclosure Statement

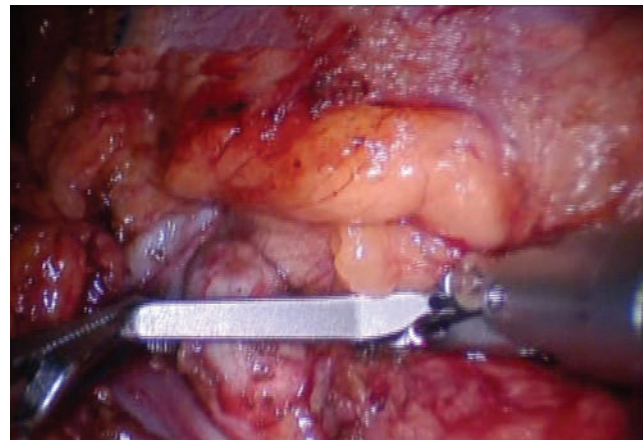
No competing financial interests exist.

Division of Urology, Washington University, St. Louis, Missouri.

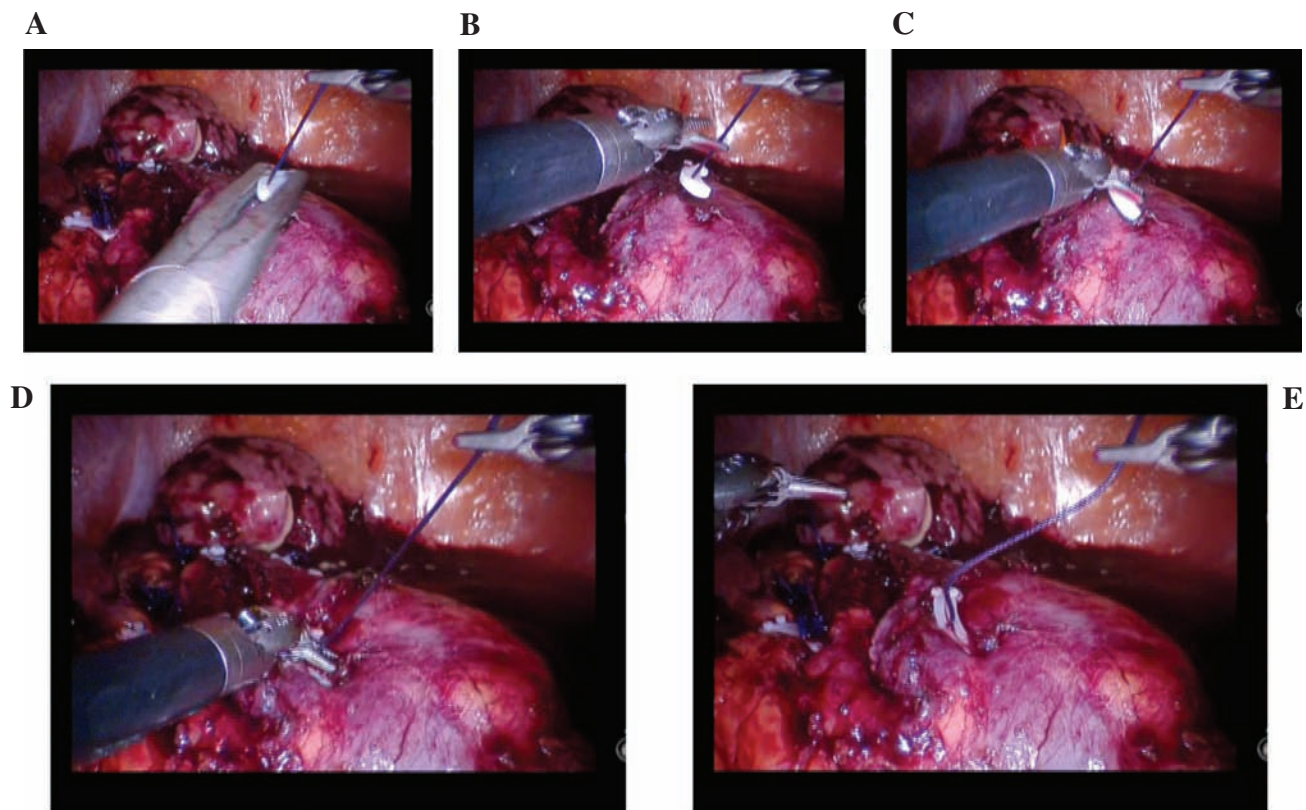
\*A video demonstrating these techniques is available online at [www.liebertpub.com/end](http://www.liebertpub.com/end).



**FIG. 1.** Port placement for robot-assisted partial nephrectomy. Blue dot is for the telescope. Red dot is for the assistant port. The yellow dots are for the 8 mm robotic instrument ports.



**FIG. 2.** The renal artery being clamped with the fourth arm of the robot using a bowel forceps.



**FIG. 3.** (A) The assistant places the Weck clip loosely on the suture. (B) The right robotic arm applies tension to the suture. (C) The left robotic arm slides the Weck clip down the suture. (D) The surgeon takes visual cues from the indentation of the renal capsule. (E) The Weck clip is in place, and the mattress suture is held under hemostatic tension. We also use a Lapra-Ty clip to prevent the Weck clip from slipping.

**Reference**

1. Canales BK, Lynch AC, Fernandes E, Anderson JK, Ramani AP. Novel technique of knotless hemostatic renal parenchymal suture repair during laparoscopic partial nephrectomy. *Urology* 2007;70:358-359.

Address reprint requests to:

*Dr. Robert Figenshau  
Washington University  
4960 Children's Place  
St. Louis, MO 63110*

*E-mail: figenshaur@wustl.edu*

