

Washington University School of Medicine Digital Commons@Becker

Open Access Publications

2012

Enzyme-replacement therapy in life-threatening hypophosphatasia

Michael P. Whyte

Washington University School of Medicine in St. Louis

William H. McAlister

Washington University School of Medicine in St. Louis

et al

Follow this and additional works at: http://digitalcommons.wustl.edu/open_access_pubs

Recommended Citation

Whyte, Michael P.; McAlister, William H.; and et al, "Enzyme-replacement therapy in life-threatening hypophosphatasia." *The New England Journal of Medicine*.366,10. 904-913. (2012).
http://digitalcommons.wustl.edu/open_access_pubs/2887

This Open Access Publication is brought to you for free and open access by Digital Commons@Becker. It has been accepted for inclusion in Open Access Publications by an authorized administrator of Digital Commons@Becker. For more information, please contact engeszer@wustl.edu.

Enzyme-Replacement Therapy in Life-Threatening Hypophosphatasia

Michael P. Whyte, M.D., Cheryl R. Greenberg, M.D., Nada J. Salman, M.D., Michael B. Bober, M.D., Ph.D., William H. McAlister, M.D., Deborah Wenkert, M.D., Bradley J. Van Sickle, M.D., Ph.D., Jill H. Simmons, M.D., Terence S. Edgar, M.D., Martin L. Bauer, M.D., Mohamed A. Hamdan, M.D., Nick Bishop, M.D., Richard E. Lutz, M.D., Mairead McGinn, M.D., Stanley Craig, M.D., Jean N. Moore, M.D., John W. Taylor, D.O., Robert H. Cleveland, M.D., William R. Cranley, M.D., Ruth Lim, M.D., Tom D. Thacher, M.D., Jill E. Mayhew, P.T., Matthew Downs, M.P.H., José Luis Millán, Ph.D., Alison M. Skrinar, M.P.H., Philippe Crine, Ph.D., and Hal Landy, M.D.

ABSTRACT

BACKGROUND

Hypophosphatasia results from mutations in the gene for the tissue-nonspecific isozyme of alkaline phosphatase (TNSALP). Inorganic pyrophosphate accumulates extracellularly, leading to rickets or osteomalacia. Severely affected babies often die from respiratory insufficiency due to progressive chest deformity or have persistent bone disease. There is no approved medical therapy. ENB-0040 is a bone-targeted, recombinant human TNSALP that prevents the manifestations of hypophosphatasia in *Tnslp* knockout mice.

METHODS

We enrolled infants and young children with life-threatening or debilitating perinatal or infantile hypophosphatasia in a multinational, open-label study of treatment with ENB-0040. The primary objective was the healing of rickets, as assessed by means of radiographic scales. Motor and cognitive development, respiratory function, and safety were evaluated, as well as the pharmacokinetics and pharmacodynamics of ENB-0040.

RESULTS

Of the 11 patients recruited, 10 completed 6 months of therapy; 9 completed 1 year. Healing of rickets at 6 months in 9 patients was accompanied by improvement in developmental milestones and pulmonary function. Elevated plasma levels of the TNSALP substrates inorganic pyrophosphate and pyridoxal 5'-phosphate diminished. Increases in serum parathyroid hormone accompanied skeletal healing, often necessitating dietary calcium supplementation. There was no evidence of hypocalcemia, ectopic calcification, or definite drug-related serious adverse events. Low titers of anti-ENB-0040 antibodies developed in four patients, with no evident clinical, biochemical, or autoimmune abnormalities at 48 weeks of treatment.

CONCLUSIONS

ENB-0040, an enzyme-replacement therapy, was associated with improved findings on skeletal radiographs and improved pulmonary and physical function in infants and young children with life-threatening hypophosphatasia. (Funded by Enobia Pharma and Shriners Hospitals for Children; ClinicalTrials.gov number, NCT00744042.)

From the Center for Metabolic Bone Disease and Molecular Research, Shriners Hospital for Children (M.P.W., D.W.), the Division of Bone and Mineral Diseases, Washington University School of Medicine at Barnes-Jewish Hospital (M.P.W.), and Mallinckrodt Institute of Radiology, St. Louis Children's Hospital at Washington University School of Medicine (W.H.M.) — all in St. Louis; the University of Manitoba and Winnipeg Regional Health Authority; Winnipeg, Canada (C.R.G.); Tawam Hospital, Al Ain, United Arab Emirates (N.J.S., M.A.H.); Alfred I. DuPont Hospital for Children, Wilmington, DE (M.B.B.); Vanderbilt Children's Hospital, Nashville (B.J.V.S., J.H.S.); Prevea Health Clinic (T.S.E., J.W.T.) and St. Vincent's Hospital (J.W.T.) — both in Green Bay, WI; University of Arkansas for Medical Sciences, College of Medicine, Little Rock (M.L.B.); Sheffield Children's Hospital, Sheffield (N.B.), and Royal Belfast Hospital for Sick Children, Belfast (M.M., S.C.) — both in the United Kingdom; University of Nebraska Medical Center, Omaha (R.E.L.); St. John's Hospital, Springfield, MO (J.N.M.); Children's Hospital Boston (R.H.C.), Boston Medical Center (W.R.C.), and Massachusetts General Hospital (R.L.) — all in Boston; Mayo Clinic, Rochester, MN (T.D.T.); Enobia Pharma, Montreal (J.E.M., A.M.S., P.C., H.L.); Statistics Collaborative, Washington, DC (M.D.); and Sanford-Burnham Medical Research Institute, La Jolla, CA (J.L.M.). Address reprint requests to Dr. Whyte at Shriners Hospital for Children, 2001 S. Lindbergh Blvd., St. Louis, MO 63131, or at mwhyte@shrinersnet.org.

This article (10.1056/NEJMoa1106173) was updated on March 8, 2012.

N Engl J Med 2012;366:904-13.
Copyright © 2012 Massachusetts Medical Society.

HYPOPHOSPHATASIA IS THE INBORN ERROR of metabolism that is characterized by low serum alkaline-phosphatase activity from loss-of-function mutations, typically missense, within the gene for the tissue-nonspecific isozyme of alkaline phosphatase (TNSALP).¹ Natural substrates of TNSALP that accumulate in hypophosphatasia include inorganic pyrophosphate,² an inhibitor of mineralization,³ and pyridoxal 5'-phosphate (PLP), the principal circulating form of vitamin B₆.⁴ High extracellular levels of inorganic pyrophosphate block hydroxyapatite crystal growth^{3,5} and cause rickets or osteomalacia. Hypercalcemia and hyperphosphatemia can develop in severely affected patients.¹ The deranged vitamin B₆ metabolism shows that TNSALP functions as a cell-surface enzyme⁶ and explains why pyridoxine-responsive seizures may occur when TNSALP deficiency is profound.⁷

The manifestations of hypophosphatasia range from neonatal death with almost no skeletal mineralization to dental problems in adults without any bone symptoms.^{1,5} Such differences in expression are explained partly by autosomal recessive and autosomal dominant patterns of inheritance.¹ From a clinical nosology based on the patient's age when skeletal disease first develops,⁸ autosomal recessive inheritance explains all perinatal cases and nearly all infantile cases of hypophosphatasia.⁹⁻¹¹ Perinatal hypophosphatasia is characterized by extreme skeletal hypomineralization, and survival is rare.^{1,12} Infantile hypophosphatasia develops before 6 months of age with rickets, failure to thrive, hypotonia, and myopathy and is often complicated by hypercalcemia, nephrocalcinosis, epilepsy, and craniosynostosis.^{7,13-18} Deciduous teeth are lost because insufficient cementum links them to the periodontal ligament.¹⁹ Although spontaneous improvement sometimes occurs in infantile hypophosphatasia,²⁰ substantial bone disease and weakness often persist.^{1,5} Skeletal deterioration typically results in death from respiratory insufficiency.¹⁴⁻¹⁷

Attempts to treat patients with infantile hypophosphatasia by administering intravenous infusions of plasma enriched in soluble alkaline phosphatase from patients with Paget's disease^{14,15} or alkaline phosphatase purified from human placentas²¹ have been unsuccessful, suggesting that skeletal mineralization requires the presence of TNSALP on osteoblasts, chondrocytes, and matrix vesicles.^{5,22,23} There is no approved medical treatment for hypophosphatasia.

ENB-0040 (asfotase alfa; Enobia Pharma) is an investigational, recombinant protein comprising the TNSALP ectodomain, the constant region of the human IgG1 Fc domain, and a terminal deca-aspartate motif for bone targeting.²⁴ In *Tnsalp* knockout mice, which constitute an animal model of infantile hypophosphatasia,²⁵ treatment with daily subcutaneous injections of ENB-0040 at doses that result in serum levels ranging from 650 to 1000 U per liter preserve the mineralization of bones and teeth.^{24,26,27} A phase 1 study involving adult patients with hypophosphatasia showed peak and trough ENB-0040 levels in this range after one intravenous dose of 3 mg per kilogram of body weight and weekly subcutaneous doses of 2 mg per kilogram.²⁸ We conducted a clinical trial of treatment with ENB-0040 for at least 1 year in infants and young children with life-threatening hypophosphatasia.

METHODS

STUDY DESIGN AND PATIENTS

In an open-label study, we evaluated the safety, tolerability, bioavailability, pharmacokinetics,²⁹ pharmacodynamics, and efficacy of treatment with ENB-0040. Efficacy assessments included skeletal changes, as evaluated by means of radiography, and gross motor, fine motor, and cognitive development, as measured with the Bayley Scales of Infant and Toddler Development, third edition (Bayley-III), a norm-referenced instrument used to assess developmental functioning of children from 1 to 42 months of age and to identify children with developmental delay. Raw scores of successfully completed items are converted to scaled and composite scores allowing comparison with children in a standardized sample. Developmental age-equivalent scores in months allow raw-score comparisons with typically developing children.³⁰ All patients were to receive ENB-0040 for 6 months and then have the opportunity to enroll in an open-label extension study.

Eligibility criteria were an age of 3 years or less, symptoms of hypophosphatasia occurring before the age of 6 months, hypophosphatasemia, an elevated plasma PLP level, hypophosphatasia-related skeletal disease as assessed radiographically, failure to thrive, rachitic chest deformity or pyridoxine-responsive seizures, and nontraumatic or poorly healing fractures, hypercalcemia, craniosynostosis, nephrocalcinosis, or respiratory compromise from hypophosphatasia. Patients were

Table 1. Characteristics of the Patients at Baseline.*

Characteristic	Patient 1	Patient 2	Patient 3	Patient 4	Patient 5
Form of hypophosphatasia	Perinatal	Infantile	Infantile	Infantile	Perinatal
Age — mo	7.5	6	33	18	36
Sex	Female	Female	Female	Female	Female
TNSALP genotype	c.881A>C p.D294A c.547G>A p.D183H†	c.407G>A p.Arg136His c.1133A>T p.Asp378Val‡	c.658G>A p.Gly220Arg c.659G>C p.Gly220Ala§	c.1077C>G p.Ile359Met c.1133A>T p.Asp378Val‡	c.98C>T p.A33V c.98C>T p.A33V†
Serum ALP (normal range) — U/liter¶	20 (117–352)	8 (<390)	33 (108–317)	58 (80–425)	19 (79–267)
Plasma PLP — × ULN	10	5	4	>3	2
Severity of rickets	Severe	Severe	Extremely severe	Severe	Moderate
Respiratory status	CPAP	Progressive respiratory deterioration	Tracheostomy and ventilation	Tracheostomy and ventilation	Supplemental oxygen by nasal cannula
Failure to thrive	Yes	Yes	Yes	Yes	Yes
Nephrocalcinosis	Yes	Yes	Yes	Yes	No
Gross motor function — age-equivalent in mo**	<1	No data — too fragile to test	<1	<1	7
Feeding	Tube	Tube	Tube	Tube	Oral

* ALP denotes alkaline phosphatase, CPAP continuous positive airway pressure, PLP pyridoxal 5'-phosphate, TNSALP tissue-nonspecific isozyme of alkaline phosphatase, and ULN upper limit of the normal range.

† TNSALP mutation analysis was performed by Centre d'Etudes de Biologie Prénatale, Université de Versailles (Versailles, France).

‡ TNSALP mutation analysis was performed by Connective Tissue Gene Tests (Allentown, PA).

§ TNSALP mutation analysis was performed by Steven Mumm, Ph.D., of the Washington University School of Medicine (St. Louis).

¶ The normal range is for the center where the patient was treated.

|| Extremely severe rickets was defined as the partial or complete absence of visible bones on radiographs, severe rickets as a near absence of metaphyseal features with large radiolucent "tongues" and sclerosis, and moderate rickets as rachitic changes (metaphyseal flaring and fraying, widening of physes, areas of subphyseal demineralization, and bowing).

** Gross motor function was assessed with the use of the Bayley Scales of Infant and Toddler Development, third edition (Bayley-III), a norm-referenced instrument used to assess developmental functioning of children from 1 to 42 months of age and to identify children with developmental delay. Raw scores of successfully completed items are converted to scaled and composite scores allowing comparison with children in a standardized sample. Developmental age-equivalent scores in months allow raw-score comparisons with typically developing children.³⁰

excluded if they had a major coexisting disease, a treatable form of rickets, previous exposure to bisphosphonates, hypocalcemia or hypophosphatemia, or a serum 25-hydroxyvitamin D level of less than 20 ng per milliliter (50 nM) or if they had received another experimental treatment for hypophosphatasia (e.g., bone marrow transplantation).^{16,17}

STUDY OVERSIGHT

The study design was developed through a collaboration between the sponsor, Enobia Pharma, and the authors. The protocol was approved by the local institutional review boards, and written informed consent was obtained from the patients' parents. Safety and efficacy were monitored quarterly and on an ad hoc basis by an independent data and safety monitoring board. The primary

statistical analyses were performed by Statistics Collaborative. Other organizations involved in the management and analysis of study data are listed in the Methods section in the Supplementary Appendix (available with the full text of this article at NEJM.org). All the authors evaluated the study findings, made the decision to submit the manuscript for publication, and vouch for the completeness and accuracy of the reported data and the fidelity of the study to the protocol. The first author wrote the first draft of the manuscript, and the other authors aided in its revision. The study protocol, including the statistical analysis plan, is available at NEJM.org.

STUDY TREATMENT

Patients received ENB-0040 (at a concentration of 40 mg per milliliter) as a single intravenous infu-

Patient 6	Patient 7	Patient 8	Patient 9	Patient 10	Patient 11
Perinatal	Perinatal	Infantile	Infantile	Perinatal	Infantile
0.6	1	30	6	2	4
Male	Male	Male	Female	Female	Male
c.119C>T p.Ala40Val c.1231A>G p.Thr411Ala‡	c.215T>C p.Ile72Thr c.881A>C p.Asp294Ala‡	c.212G>A p.Arg71His c.571G>A p.Gly191Lys†	c.212G>A p.R71H c.571G>A p.E191K†	c.920C>T p.P307L c.1171C>T p.R391C‡	c.350A>G p.Tyr117Cys c.1001G>A p.Gly334Asp‡
21 (73–266)	20 (73–266)	42 (76–308)	23 (59–425)	6 (32–91)	93 (143–320)
17	8	18	14	Receiving pyridoxine	3
Extremely severe	Severe	Moderate	Severe	Severe	Severe
Endotracheal intubation and ventilation	Progressive respiratory deterioration	Ambient air	Progressive respiratory deterioration	Progressive respiratory deterioration	Progressive respiratory deterioration
Yes	Yes	Yes	Yes	Yes	Yes
Yes	Kidney stones	No	Yes	Yes	Yes
No data — too fragile to test	<1	9	<1	1	<1
Tube	Tube	Oral	Tube	Oral	Oral

sion at a dose of 2 mg per kilogram, followed by subcutaneous injections three times per week at a dose of 1 mg per kilogram. The subcutaneous dose could be increased up to 3 mg per kilogram if there was worsening failure to thrive, deteriorating pulmonary function, or no radiographic evidence of skeletal improvement.

STATISTICAL ANALYSIS

The primary efficacy end point was a change in the skeletal manifestations of hypophosphatasia, including rickets, as assessed on radiography. Two methods of assessment were used. First, three radiologists rated changes from baseline to week 48 using a 7-point scale (radiographic global impression of change [RGI-C]), which is based on ratings of the characteristics of severe hypophosphatasia (including irregularity of the provisional zone of calcification; physeal widening; metaphyseal flaring, fraying, radiolucencies, and patchy osteosclerosis; altered ratio of mid-diaphyseal cortex-to-bone thickness; gracile bones; absence of some or all bones; and recent fractures). A reduction of 3 points represented severe worsening, and an increase of 3 points indicated complete healing of the skeletal disease. For each patient, the mean score among the radiologists was used for analysis, with a response to treatment defined as a mean increase of 2 or more points (i.e., substantial healing).

The proportion of patients with a response, with the 95% exact confidence interval, was calculated at weeks 24 and 48.³¹ Two-sided Wilcoxon signed-rank tests³² were used to determine whether the median scores differed from 0 (i.e., no change).

Second, a single reader rated the growth-plate abnormalities at the wrists and knees, using a 10-point rickets-severity scale (RSS),³³ with higher scores representing more severe rickets. All radiographs were rated with masking of sequence and patient identifiers. Changes from baseline were calculated at weeks 24 and 48, with the use of Wilcoxon signed-rank tests to determine whether median changes differed from 0 (see the Supplementary Appendix).

Additional efficacy studies included evaluations of respiratory status and motor and cognitive function. Bone biopsy and densitometry were precluded by the small size of the patients and their precarious clinical status.

RESULTS

CHARACTERISTICS OF THE PATIENTS

A total of 11 patients, 7 girls and 4 boys, were enrolled between October 2008 and December 2009; they ranged in age at baseline from 2 weeks to 3 years (Table 1). Five patients had perinatal hypophosphatasia, and six had infantile hypophosphatasia.

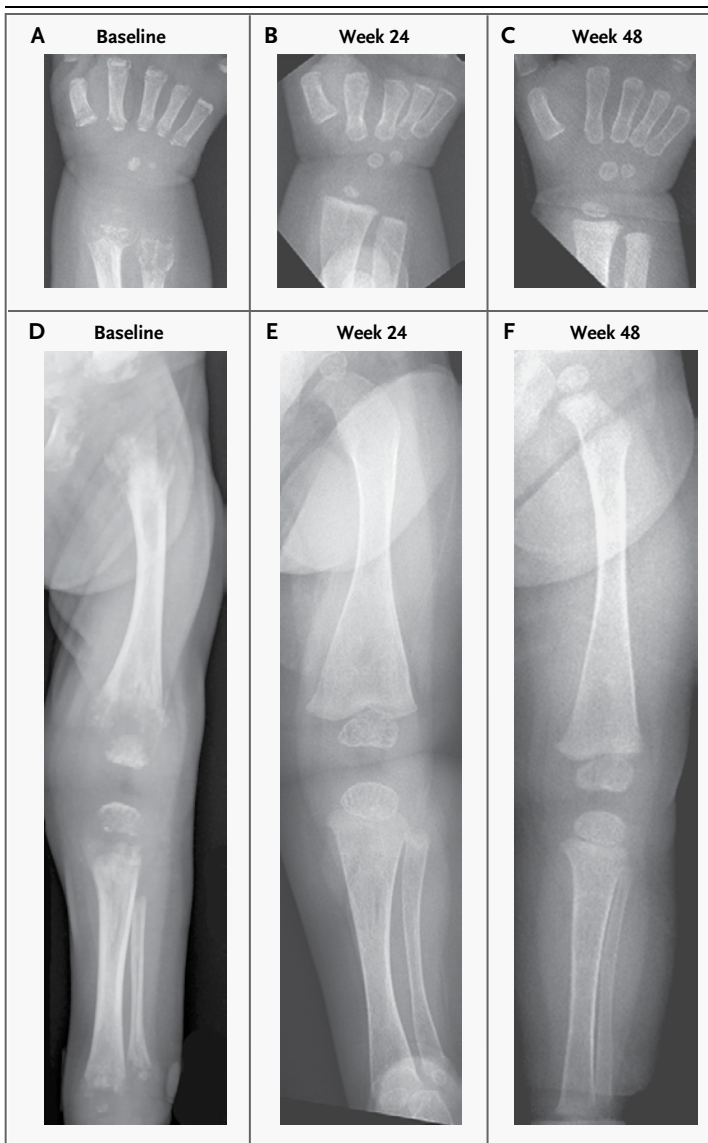


Figure 1. Radiographic Findings at Baseline and at Weeks 24 and 48 in Patient 2.

A radiograph obtained at baseline shows that the right radius and ulna metaphyses are flared and contain only focal, irregular calcification (Panel A). At week 24, these metaphyses are mineralized, with distinct provisional zones of calcification, and the metacarpals have wider widths and better-defined cortices and no longer have lytic areas at their bases (Panel B). At week 48, the radius and ulna have better modeling (Panel C). The striking rickets involving the left lower limb in the baseline radiograph (Panel D) shows marked improvement at week 24 but with a modeling defect featuring an expanded distal femur (Panel E), which is improved at week 48 (Panel F).

phatasia. All had symptoms before the age of 6 months, including failure to thrive, fractures, and substantial motor delay or regression. Patients with erupted teeth had lost dentition. All but two patients had nephrocalcinosis or renal stones. The

infants received calcium-restricted formulas (with the use of feeding tubes) for hypercalcemia, and vitamin D supplementation, if it was being administered, was continued. All had hypophosphatasemia. Levels of plasma PLP were 2 to 18 times the upper limit of the normal range in 10 patients, with a higher level in the 1 patient who received pyridoxine for vitamin B₆-responsive seizures. One patient was homozygous for a *TNSALP* missense mutation. The others were compound heterozygotes of 18 additional *TNSALP* missense mutations (Table 1). The case summaries, laboratory findings, and radiographic changes are provided in the Supplementary Appendix.

TREATMENT FINDINGS

Consent for treatment was withdrawn for 1 of the 11 patients because of irritability, oxygen desaturation, rigors, and low-grade fever during receipt of the intravenous dose. The other 10 patients completed 6 months of treatment and entered the extension study. One patient died from sepsis after 7.5 months of therapy. Nine patients are currently participating in the extension study, with an average treatment duration of 18 months (range, 12 to 26) (see the Supplementary Appendix).

Immediately after the intravenous infusion, the serum ENB-0040 level was as high as 14,200 U per liter (normal range for *TNSALP*, approximately 100 to 400). After the patients received the subcutaneous dose of 1 mg per kilogram three times per week, trough activity averaged 580 U per liter, and with higher doses (i.e., subcutaneous injections of up to 3 mg per kilogram three times per week), values in or near the anticipated range of efficacy were observed in all patients (see the Results section in the Supplementary Appendix).^{24,26} The weight-normalized model and the allometric (body size) model²⁹ fit the data similarly. However, the allometric model provided the better fit for the data, showing a bioavailability of ENB-0040 of 72% and an estimated half-life of approximately 5 days.

PRIMARY END POINT

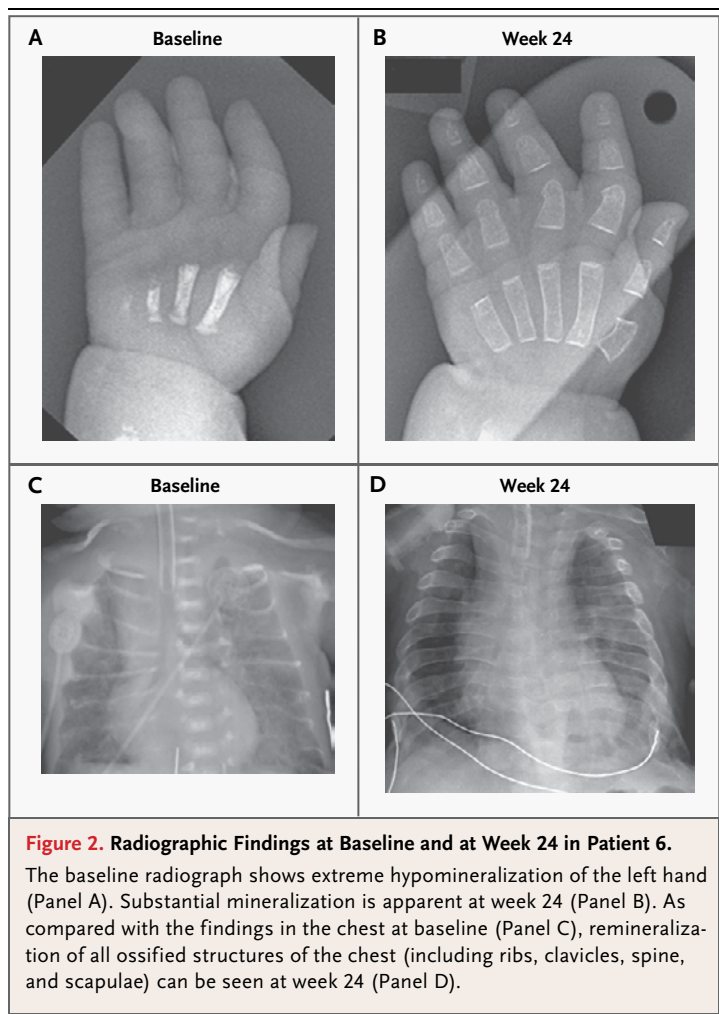
Baseline radiographs in all patients showed hypophosphatasia-associated skeletal disease. Skeletal healing became apparent as early as week 3 in Patient 2 and was striking at week 24 (Fig. 1 and 2) in all patients except Patient 3, who had no visible bone at baseline. No skeletal deterioration was observed, except in Patient 4, whose consent for treat-

ment was withdrawn during the intravenous infusion and who subsequently had marked skeletal demineralization (Fig. 3). Improvements in skeletal quality included diffusely increased mineral content, corrected or improved endochondral and membranous bone formation, fracture mending, reduced deformity, resolution of radiolucencies and sclerosis, and extensive modeling and remodeling.

RGI-C scores improved from baseline to week 24 and from baseline to week 48, with 9 of 10 patients (90%; 95% confidence interval [CI], 55 to 100) and 8 of 9 patients (89%; 95% CI, 52 to 100), respectively, meeting the criterion for a treatment response (see the Results section in the Supplementary Appendix). The patient who died from sepsis was judged to have had a response at 24 weeks. The median RGI-C score was increased by 2.0 points at week 24 and by 2.3 points at week 48 ($P=0.004$ for both comparisons), indicating substantial and continued healing of rickets. Nearly all patients with a response had improvement in physeal widening, metaphyseal flaring, irregularity of the provisional zone of calcification, and metaphyseal radiolucencies. The patient with no visible bone at baseline did not have an initial response to treatment but did have some remineralization at 48 weeks. The RSS score³³ also improved significantly. With the exclusion of the patient who had no visible bone, the median RSS score at baseline was 9.5. At weeks 24 and 48, the median score was reduced by 3.5 points (in 9 patients, $P=0.004$) and by 8.8 points (in 8 patients, $P=0.008$), respectively (see the Supplementary Appendix).

SECONDARY END POINTS

At baseline, all but 1 patient had gracile or nonvisible ribs on radiographs, accompanied by respiratory compromise ranging from progressive insufficiency to frank ventilatory failure requiring full mechanical ventilation (Table 1 and Video 1). Respiratory function tended to decline initially during ENB-0040 therapy in the infants who were not receiving ventilatory support but then improved in all patients, along with better mineralization of the rib cage (Fig. 2), which was evident as early as week 12. At week 48, 6 of the 9 patients were breathing ambient air without ventilatory support (as compared with 1 of 11 at baseline), 1 was receiving supplemental oxygen through a nasal cannula, 1 was receiving mechanical ventilation only at night, and 1 remained on full mechanical ventilation (see the Supplementary Appendix).



Performance on the Bayley-III instrument³⁰ was assessed at baseline in all but two patients (whose medical condition was too fragile) and at weeks 24 and 48. At baseline, all the patients had gross motor delays. None could bear weight through the legs owing to skeletal abnormalities and muscle weakness, including the four patients who were 18 months of age or older (Video 2). Improvements in age-equivalent scores for gross motor, fine motor, and cognitive development were noted in seven of the eight patients with complete evaluations. Of the nine patients who were treated for 48 weeks, all but two were bearing weight through the legs; four were walking or taking early steps, one was standing, two were crawling, and one was sitting (Videos 3, 4, and 5). Patient 3, who at baseline had no radiographically visible bone, had a tracheostomy, and had no spontaneous movement, moved all limbs against gravity at 48 weeks.



Videos showing patients at baseline and after therapy are available at NEJM.org

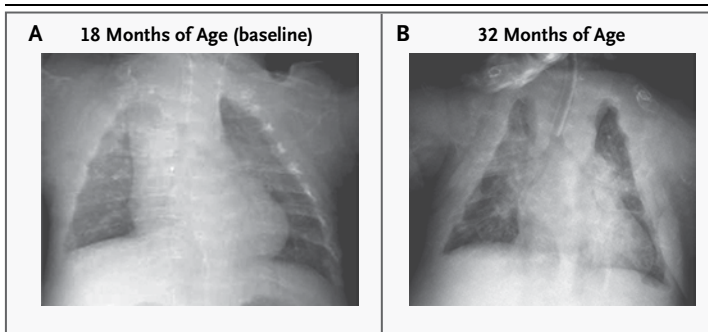


Figure 3. Radiographic Findings in Patient 4.

A baseline radiograph shows generalized osteopenia of the chest but little deformity (Panel A). Consent for treatment was withdrawn during the initial intravenous infusion of ENB-0040, and the patient received no further treatment. A radiograph obtained 14 months after withdrawal shows substantial skeletal deterioration (Panel B).

Serum parathyroid hormone was at a low-normal level in 5 of 6 patients at baseline, despite dietary calcium restriction, and usually increased during treatment, generally together with the radiographic improvements. Dietary calcium restriction was then liberalized for all infants, and for some, the intake was increased to a level above age-appropriate recommendations to control the rise in parathyroid hormone. The level of plasma PLP was elevated in all patients at baseline (Table 1). For the 10 patients who did not receive supplementation with vitamin B₆, the median level was 262 ng per milliliter (1060 nM) at baseline, 46 ng per milliliter (186 nM) at 24 weeks, and 23 ng per milliliter (93 nM) at 48 weeks ($P=0.004$ and $P=0.02$, respectively). Plasma levels of inorganic pyrophosphate were measured before and after treatment in five patients; the median level decreased from 5.2 nM at baseline to 1.1 and 1.9 nM at weeks 24 and 48, respectively (see the Supplementary Appendix).

ADVERSE EVENTS

The most common therapy-related adverse event was a reaction at the subcutaneous-injection site, consisting of mild, localized, transient erythema. There was no evidence of ectopic calcification from the treatment, including on funduscopic examination; nephrocalcinosis did not progress after the initial 6 months of treatment and it even improved in some patients. Serious adverse events were generally consistent with severe hypophosphatasia (Table 2, and the Supplementary Appendix). Three serious adverse events (one case each of respira-

tory distress, craniosynostosis, and conductive hearing loss) were considered by the investigators to be possibly related to the study treatment. ENB-0040 did not appear to have an effect on craniosynostosis, a progressive complication of severe hypophosphatasia,¹⁸ and craniectomies were performed in two patients.

No important concerns emerged from serum chemical or hematologic tests or urinalyses. Serum calcium and inorganic-phosphate levels showed only transient minor fluctuations, and there were no clinical signs of hypocalcemia from calcium-avid bones (“hungry bones”). There were no treatment-related adverse events suggestive of hypersensitivity, nor was there evidence of tachyphylaxis. During the first 6 months, four of the nine patients tested positive for anti-ENB-0040 antibodies, but titers remained relatively low (range, 2 to 128) and did not appear to influence clinical outcomes in the follow-up period.

DISCUSSION

Hypophosphatasia is almost always fatal when severe skeletal disease is obvious at birth.^{1,5,12} The prognosis for patients with infantile hypophosphatasia is uncertain at presentation, but clinical and skeletal deterioration¹⁴⁻¹⁷ or vitamin B₆-responsive seizures⁷ indicate a lethal course.

There is no approved medical therapy for hypophosphatasia.^{1,5} Early, unsuccessful attempts to treat infantile hypophosphatasia with repeated intravenous infusions of soluble alkaline phosphatases^{14,15,21} suggested that TNSALP must be within the skeletal matrix to mineralize cartilage and bone.¹⁵ Avoiding extraskeletal excesses of alkaline phosphatase seemed important because diminished extracellular production of inorganic pyrophosphate causes generalized arterial calcification of infancy.³⁴ For life-threatening hypophosphatasia, attempts to transplant cells derived from healthy mesenchyme to form TNSALP-replete osteoblasts appeared to benefit, but not cure, two girls with infantile hypophosphatasia.^{16,17} In case reports,³⁵ teriparatide (parathyroid hormone amino acid 1-34), which stimulates the biosynthesis of TNSALP in osteoblasts, appeared to be beneficial in some adults with hypophosphatasia.¹

In this study, we found that bone-targeted enzyme replacement with ENB-0040 was effective in infants and young children with life-threatening or severely debilitating hypophosphatasia. Of the

nine patients who were treated for at least 1 year, four had perinatal hypophosphatasia and five had infantile hypophosphatasia. One had lost nearly all radiographically apparent skeletal mineral during prolonged ventilation and immobilization but still had a positive response to ENB-0040 therapy. Serum calcium levels were generally high at diagnosis (unlike calcium levels in other forms of rickets)^{1,5} and initially required dietary calcium restriction in all patients, most of whom had nephrocalcinosis.

Skeletal remineralization occurred during treatment, without symptomatic hypocalcemia from calcium-avid bones, and was often accompanied by increases in serum parathyroid hormone levels that called for liberalization of dietary calcium but not additional vitamin D. A positive mineral balance throughout the skeleton was obvious on radiography after several weeks or months of treatment, and both membranous and endochondral bone healed in most patients, with amelioration of nearly all complications of hypophosphatasia. Substantial radiographic improvement in skeletal abnormalities was noted at week 24 in all but one patient, with continued healing through week 48. In the one patient who had no radiographically visible mineral at baseline, calcification was observed after 9 months of therapy. This delay probably reflected the profound deficit of skeletal mineral in the patient, although sufficient hydroxyapatite was apparently present for targeting with ENB-0040. After the start of therapy, deciduous teeth erupted in all the patients, with only one patient having hypophosphatasia-related loss of a tooth.

Although the pathogenesis is not understood,^{1,5} hypophosphatasia causes weakness, seemingly from a static myopathy.³⁶ Improvement in ventilatory function and in fine and gross motor skills was observed in all the patients in our study. Muscle weakness, hyperphosphatemia, and osteomalacia that are reminiscent of hypophosphatasia occur with toxic doses of the first-generation bisphosphonate, etidronate (a synthetic analogue of inorganic pyrophosphate),^{37,38} suggesting that an accumulation of inorganic pyrophosphate in hypophosphatasia may have a myopathic effect. It is possible that the improved motor function in our patients reflected hydrolysis of inorganic pyrophosphate or some as-yet-unrecognized TNSALP substrate.³⁹

Although treatment with ENB-0040 markedly

Table 2. Serious Adverse Events during the Treatment Period.*

Event	0–6 Months of Treatment (N=11)		7–12 Months of Treatment (N=10)	
	Events	Patients	Events	Patients
	no.	no. (%)	no.	no. (%)
Total serious adverse events	31	7 (64)	27	8 (80)
Infection	9	5 (45)	8	5 (50)
Pneumonia	3	2 (18)	2	2 (20)
Tracheitis	0	0	2	2 (20)
Respiratory, thoracic, or mediastinal disorder	10	4 (36)	7	3 (30)
Respiratory distress	4	2 (18)	0	0
Respiratory failure	2	2 (18)	2	1 (10)
Nervous-system disorder	3	3 (27)	2	2 (20)
Convulsion	2	2 (18)	0	0
Increased intracranial pressure	1	1 (9)	2	2 (20)
General disorder or administration-site condition	2	2 (18)	0	0
Decreased oxygen saturation	2	2 (18)	0	0
Musculoskeletal or connective-tissue disorder — craniosynostosis	2	2 (18)	5	4 (40)
Surgical or medical procedure	0	0	2	2 (20)

* “Total serious adverse events” includes all serious adverse events, regardless of the incidence. Multiple events could occur in a single patient. The following serious adverse events occurred with a frequency of 10% or less during the treatment period and are not listed in the table: gastroenteritis (salmonella), hepatitis, H1N1 influenza, lower respiratory tract infection (viral), pneumonia due to respiratory syncytial virus, bronchiolitis due to respiratory syncytial virus, sepsis, asthma, dyspnea, hypoxemia, obstructive airway disorder, restrictive pulmonary disease, respiratory insufficiency, chronic disease of tonsils and adenoids, catheter-related complication, pyrexia, scoliosis, tachycardia, craniosynostosis, collapse of lung, craniectomy, gastrostomy-tube placement, bilateral conductive hearing loss, and renal stones. For complete data, see Table 5 in the Supplementary Appendix.

increased serum alkaline phosphatase levels in our patients, we found no evidence that it led to ectopic mineralization. We were concerned that subcutaneous injections of ENB-0040 might precipitate calcium and phosphate locally, because especially high levels of alkaline phosphatase would be present transiently near fibrillar collagen,⁴⁰ but this was not observed. Despite the presence of calcification in the kidneys of eight patients at baseline, no new occurrences of nephrocalcinosis were reported, and nephrocalcinosis resolved in one patient. Perhaps this finding reflected a reduction, but not overcorrection, of extracellular concentrations of inorganic pyrophosphate mirrored by plasma PLP levels that approached or achieved the normal range. Cra-

niosynostosis and skull dysmorphology occur in approximately 40% of infants with hypophosphatasia.¹⁸ A similar percentage of our patients had craniosynostosis, suggesting that treatment with ENB-0040 does not alter its natural history.

In conclusion, ENB-0040, a recombinant human TNSALP coupled to a deca-aspartate motif for bone targeting, was administered by one intravenous infusion and then subcutaneous injections in children with perinatal or infantile hypophosphatasia. Treatment was associated with healing of the skeletal manifestations of hypophosphatasia as well as improved respiratory and motor function. Improvement is still being observed in the patients receiving continued ENB-0040 therapy, with more than 3 years of treatment in some children. ENB-0040 appears to be a potential enzyme-replacement therapy in patients with life-threatening hypophosphatasia, a metabolic bone disease.

Presented in part at the 91st Annual Meeting of the Endocrine Society, Washington, DC, June 10–13, 2009; the 31st Annual Meeting of the American Society for Bone and Mineral Research, Denver, September 11–15, 2009; the 59th Annual Meeting of the American Society of Human Genetics, Honolulu, October 20–24, 2009; the 9th Biennial Meeting of the International Skeletal Dysplasia Society, Boston, July 17–19, 2009; the Annual Meeting of the American College of Medical Genetics, Albuquerque, NM, March 24–28, 2010; and the 3rd Joint Meeting of the European Calcified Tissue Society and International Bone and Mineral Society, Athens, May 7–11, 2011.

Supported by Enobia Pharma and Shriners Hospitals for Children.

Disclosure forms provided by the authors are available with the full text of this article at NEJM.org.

We thank the parents for entrusting us with the care of their children and for sometimes enduring long periods away from home (and we mourn our patient who succumbed to sepsis); Stephen P. Coburn, Ph.D. (Indiana University–Purdue University, Fort Wayne) for teaching us the significance of altered vitamin B₆ metabolism in hypophosphatasia; the staff of the Manitoba Institute of Child Health and the Canadian Organization for Rare Disorders; Vivienne McKenzie and Dawn Russell of Shriners Hospital for Children (St. Louis) for assistance with the radiographic images and the illustrations in the Supplementary Appendix; and Sharon McKenzie for help with the preparation of the manuscript.

REFERENCES

- Whyte MP. Hypophosphatasia. In: Glorieux FH, Jueppner H, Pettifor J, eds. *Pediatric bone: biology and diseases*. 3rd ed. San Diego, CA: Academic Press, 2012: 771-94.
- Russell RG. Excretion of inorganic pyrophosphate in hypophosphatasia. *Lancet* 1965;2:461-4.
- Fleisch H, Russell RG, Straumann F. Effect of pyrophosphate on hydroxyapatite and its implications in calcium homeostasis. *Nature* 1966;212:901-3.
- Whyte MP, Mahuren DJ, Vrabel LA, Coburn SP. Markedly increased circulating pyridoxal-5'-phosphate levels in hypophosphatasia: alkaline phosphatase acts in vitamin B₆ metabolism. *J Clin Invest* 1985;76:752-6.
- Whyte MP. Hypophosphatasia: nature's window on alkaline phosphatase function in humans. In: Bilezikian JP, Raisz LG, Martin TJ, eds. *Principles of bone biology*. 3rd ed. San Diego, CA: Academic Press, 2008:1573-98.
- Whyte MP, Mahuren JD, Fedde KN, Cole FS, McCabe ER, Coburn SP. Perinatal hypophosphatasia: tissue levels of vitamin B₆ are unremarkable despite markedly increased circulating concentrations of pyridoxal-5'-phosphate: evidence for an ectoenzyme role for tissue-nonspecific alkaline phosphatase. *J Clin Invest* 1988; 81:1234-9.
- Baumgartner-Sigl S, Haberlandt E, Mumm S, et al. Pyridoxine-responsive seizures as the first symptom of infantile hypophosphatasia caused by two novel missense mutations (c.677T>C, p.M226T; c.1112C>T, p.T371I) of the tissue-nonspecific alkaline phosphatase gene. *Bone* 2007;40:1655-61.
- Fraser D. Hypophosphatasia. *Am J Med* 1957;22:730-46.
- Weiss MJ, Cole DE, Ray K, et al. A missense mutation in the human liver/bone/kidney alkaline phosphatase gene causing a lethal form of hypophosphatasia. *Proc Natl Acad Sci U S A* 1988;85:7666-9.
- Mumm S, Jones J, Finnegan P, Henthorn PS, Podgornik MN, Whyte MP. Denaturing gradient gel electrophoresis analysis of the tissue nonspecific alkaline phosphatase isoenzyme gene in hypophosphatasia. *Mol Genet Metab* 2002;75:143-53.
- Mornet E. Tissue non-specific alkaline phosphatase gene mutations database. University of Versailles-Saint Quentin en Yvelines, France: SESEP Laboratory and the Human Molecular Genetics, 2006 (http://www.sesep.uvsq.fr/03_hypo_mutations.php).
- Wenkert D, McAlister WH, Coburn SP, et al. Hypophosphatasia: nonlethal disease despite skeletal presentation in utero (17 new cases and literature review). *J Bone Miner Res* 2011;26:2389-98.
- Rathbun JC. Hypophosphatasia: a new developmental anomaly. *Am J Dis Child* 1948;75:822-31.
- Whyte MP, Valdes R Jr, Ryan LM, McAlister WH. Infantile hypophosphatasia: enzyme replacement therapy by intravenous infusion of alkaline phosphatase-rich plasma from patients with Paget bone disease. *J Pediatr* 1982;101:379-86.
- Whyte MP, McAlister WH, Patton LS, et al. Enzyme replacement therapy for infantile hypophosphatasia attempted by intravenous infusions of alkaline phosphatase-rich Paget plasma: results in three additional patients. *J Pediatr* 1984;105: 926-33.
- Whyte MP, Kurtzberg J, McAlister WH, et al. Marrow cell transplantation for infantile hypophosphatasia. *J Bone Miner Res* 2003;18:624-36.
- Cahill RA, Wenkert D, Perlman SA, et al. Infantile hypophosphatasia: transplantation therapy trial using bone fragments and cultured osteoblasts. *J Clin Endocrinol Metab* 2007;92:2923-30.
- Collmann H, Mornet E, Gattenlöhner S, Beck C, Girschick H. Neurosurgical aspects of childhood hypophosphatasia. *Childs Nerv Syst* 2009;25:217-23.
- van den Bos T, Handoko G, Niehof A, et al. Cementum and dentin in hypophosphatasia. *J Dent Res* 2005;84:1021-5.
- Ish-Shalom S, Budden F, Fraser D, et al. A follow-up of hypophosphatasia from infancy to adulthood. Presented at the 8th Annual Scientific Meeting of the American Society for Bone and Mineral Research, Anaheim, CA, June 21–24, 1986. abstract.
- Whyte MP, Habib D, Coburn SP, et al. Failure of hyperphosphatasemia by intravenous infusion of purified placental alkaline phosphatase to correct severe hypophosphatasia: evidence against a role for circulating ALP in skeletal mineralization. *J Bone Miner Res* 1992;7:Suppl:S155. abstract.
- Anderson HC, Hsu HHT, Morris DC, Fedde KN, Whyte MP. Matrix vesicles in osteomalacic hypophosphatasia bone contain apatite-like mineral crystals. *Am J Pathol* 1997;151:1555-61.
- Millán JL. *Mammalian alkaline phosphatases: from biology to applications in medicine and biotechnology*. Weinheim, Germany: Wiley-VCH Verlag, 2006.
- Millán JL, Narisawa S, Lemire I, et al. Enzyme replacement therapy for murine

- hypophosphatasia. *J Bone Miner Res* 2008;23:777-87.
25. Fedde KN, Blair L, Silverstein J, et al. Alkaline phosphatase knock-out mice recapitulate the metabolic and skeletal defects of infantile hypophosphatasia. *J Bone Miner Res* 1999;14:2015-26.
26. Yadav MC, Lemire I, Leonard P, et al. Dose response of bone-targeted enzyme replacement for murine hypophosphatasia. *Bone* 2011;49:250-6.
27. McKee MD, Nakano Y, Masica DL, et al. Enzyme replacement prevents dental defects in a model of hypophosphatasia. *J Dent Res* 2011;90:470-6.
28. Greenberg CR, Kishnani P, Landy H, et al. Hypophosphatasia: enzyme replacement with ENB-0040, a bone-targeted human recombinant tissue nonspecific alkaline phosphatase (TNSALP) fusion protein. Presented at the 16th Annual Clinical Genetics Meeting of the American College of Medical Genetics, Tampa, FL, March 25-29, 2009.
29. Beal SL, Sheiner LB, NONMEM Project Group. NONMEM users guide, part I. San Francisco: University of California, San Francisco, 1989.
30. Bayley scales of infant and toddler development, 3rd ed (Bayley-III). San Antonio, TX: Psychological Corporation, 2005.
31. Clopper CJ, Pearson E. The use of confidence or fiducial limits illustrated in the case of binomial. *Biometrika* 1934;26:404-13.
32. Wilcoxon F. Individual comparisons by ranking methods. *Biomet Bull* 1945;6:80-3.
33. Thacher TD, Fischer PR, Pettifor JM, Lawson JO, Manaster BJ, Reading JC. Radiographic scoring method for the assessment of the severity of nutritional rickets. *J Trop Pediatr* 2000;46:132-9.
34. Rutsch F, Ruf N, Vaingankar S, et al. Mutations in ENPP1 are associated with "idiopathic" infantile arterial calcification. *Nat Genet* 2003;34:379-81.
35. Whyte MP, Mumm S, Deal C. Adult hypophosphatasia treated with teriparatide. *J Clin Endocrinol Metab* 2007;92:1203-8.
36. Seshia SS, Derbyshire G, Haworth JC, Hoogstraten J. Myopathy with hypophosphatasia. *Arch Dis Child* 1990;65:130-1.
37. Preston CJ, Yates AJ, Beneton MN, et al. Effective short term treatment of Paget's disease with oral etidronate. *Br Med J (Clin Res Ed)* 1986;292:79-80.
38. Fleisch H. Bisphosphonates in bone disease. 2nd ed. New York: Parthenon, 1995:149-50.
39. Whyte MP, Eddy MC, D'Avignon A. ³¹P-nuclear magnetic resonance spectroscopy (NMRS) in hypophosphatasia: diagnostic urine profile indicating multiple new natural substrates for bone alkaline phosphatase. *J Bone Miner Res* 2000;15: Suppl 1:S483. abstract.
40. Murshed M, Harmey D, Millán JL, McKee MD, Karsenty G. Unique coexpression in osteoblasts of broadly expressed genes accounts for the spatial restriction of ECM mineralization to bone. *Genes Dev* 2005;19:1093-104.

Copyright © 2012 Massachusetts Medical Society.

NEJM 200TH ANNIVERSARY AND SOCIAL MEDIA

Follow NEJMTeam on Twitter and click "Like" on the *New England Journal of Medicine* page on Facebook for links to the latest articles, stories, and multimedia available at the NEJM 200th Anniversary website, <http://NEJM200.NEJM.org>.

Tweets incorporating the hashtag #NEJM200 also appear in a Twitter feed at the anniversary website.