

2008

A woman from Honduras with a painful forearm and fever

Erik R. Dubberke

Washington University School of Medicine in St. Louis

Gary J. Weil

Washington University School of Medicine in St. Louis

Follow this and additional works at: http://digitalcommons.wustl.edu/open_access_pubs

Recommended Citation

Dubberke, Erik R. and Weil, Gary J., "A woman from Honduras with a painful forearm and fever." *American Journal of Tropical Medicine and Hygiene*. 78,5. 697-698. (2008).

http://digitalcommons.wustl.edu/open_access_pubs/1775

This Open Access Publication is brought to you for free and open access by Digital Commons@Becker. It has been accepted for inclusion in Open Access Publications by an authorized administrator of Digital Commons@Becker. For more information, please contact engeszer@wustl.edu.

Images in Clinical Tropical Medicine

A Woman from Honduras with a Painful Forearm and Fever

Erik R. Dubberke and Gary J. Weil*

Infectious Diseases Division, Department of Internal Medicine, Washington University School of Medicine, St. Louis, Missouri

A 33-year-old woman presented with a chief complaint of pain in her left forearm (fractured radius). She had recently arrived in Missouri from Honduras via Texas. She stated that she had fallen and injured her arm when she was fleeing border agents. A routine review of systems revealed a history of fever with shaking chills. In addition to a swollen, tender forearm, she had a temperature of 39.2°C, pallor, and splenomegaly. Her blood hemoglobin level was 6.6 g/dL with 5% reticulocytes. Thin blood smears showed heavy *Plasmodium vivax* infection (~10,000 parasites/ μ L or about 1%) with char-

acteristic ameboid trophozoites in young erythrocytes (Panel A), gametocytes (Panel B), and schizonts (not shown). The presence of many multiply infected erythrocytes, with some cells containing three ring forms (Panel C), seemed unusual for *P. vivax*. However, Simpson and others reported that multiply infected cells occur more often in *P. vivax* infections than one would expect by chance; they are not uncommon in patients with high parasitemias, which rarely exceed 2% in *vivax* malaria.¹ This is believed to be related to the preference of *P. vivax* for young erythrocytes and reticulocytes. Be that as it may, we were concerned about dual infection in this patient because *P. falciparum* is also present in Honduras. The patient was successfully treated with mefloquine and later placed on primaquine. A blood specimen tested at CDC by PCR was positive for *P. vivax* only. This case reminds clinicians to have a high index of suspicion for malaria as a cause of fever in

* Address correspondence to Gary J. Weil, Washington University School of Medicine, Infectious Diseases Division, Campus Box 8051, 660 S. Euclid Avenue, St. Louis, MO 63108. E-mail: gweil@wustl.edu

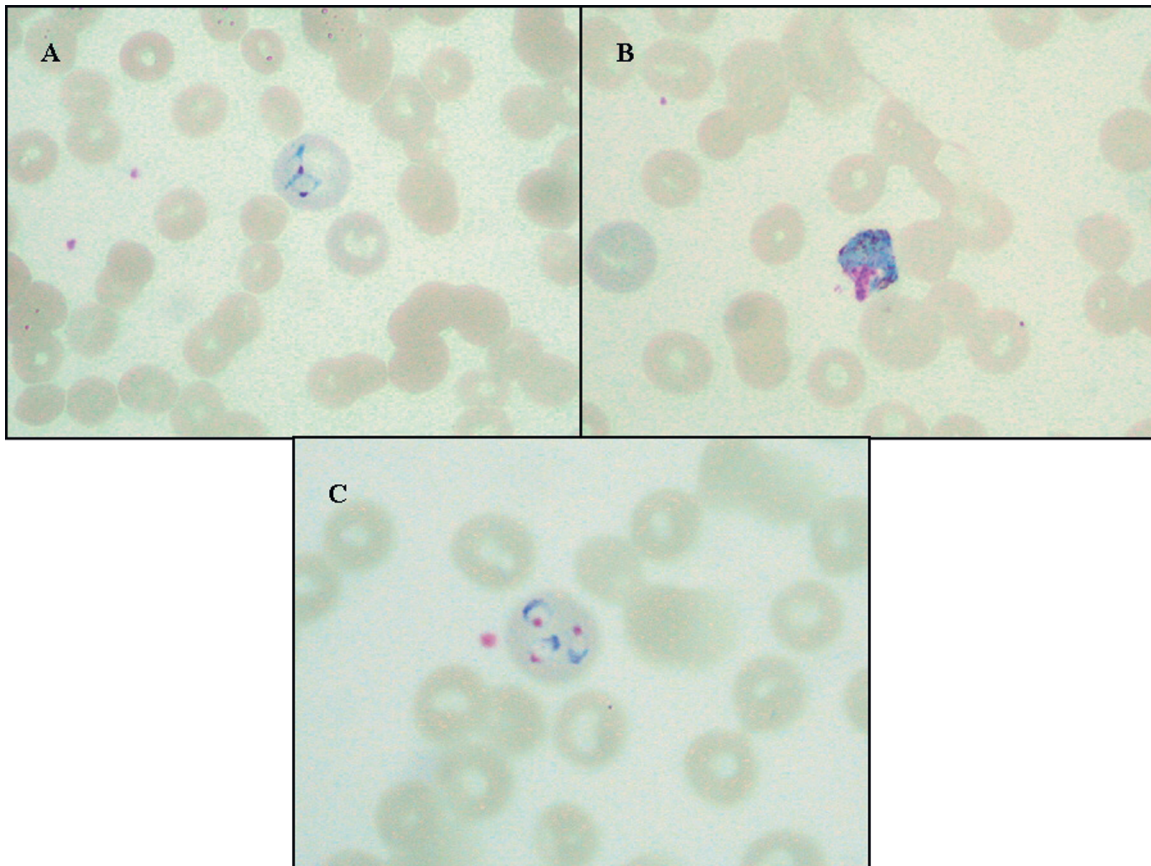


FIGURE 1. Thin blood smears revealed *Plasmodium vivax* parasites. Panel A shows an ameboid trophozoite in a large erythrocyte; B, a gametocyte with prominent pigment; C, three ring trophozoites in a large erythrocyte. This figure appears in color at www.ajtmh.org.

travelers and immigrants from the tropics including those from Central America.²

Received January 18, 2008. Accepted for publication February 15, 2008.

Authors' addresses: Eric R. Dubberke and Gary J. Weil, Infectious Diseases Division, Campus Box 8051, Washington University School of Medicine, 660 S. Euclid Ave., St. Louis, MO 63110, Tel: 314-454-7782, Fax: 314-454-5293, E-mail: gweil@wustl.edu.

REFERENCES

1. Simpson JA, Silamut K, Chotivanich K, Pukrittayakamee S, White NJ, 1999. Red cell selectivity in malaria: a study of multiple-infected erythrocytes. *Trans R Soc Trop Med Hyg* 93: 165–168.
2. Skarbinski J, James EM, Causer LM, Barber AM, Mali S, Nguyen-Dinh P, Roberts JM, Parise ME, Slutsker L, Newman RD, 2006. Malaria surveillance—United States, 2004. *MMWR* 55: 23–37.