

Washington University School of Medicine Digital Commons@Becker

Open Access Publications

2014

Probiotic-associated aspiration pneumonia due to *Lactobacillus rhamnosus*

Christopher D. Doern

Virginia Commonwealth University

Sean T. Nguyen

Children's Medical Center

Folashade Afolabi

University of Texas Southwestern Medical Center at Dallas

Carey-Ann D. Burnham

Washington University School of Medicine in St. Louis

Follow this and additional works at: http://digitalcommons.wustl.edu/open_access_pubs

Recommended Citation

Doern, Christopher D.; Nguyen, Sean T.; Afolabi, Folashade; and Burnham, Carey-Ann D., "Probiotic-associated aspiration pneumonia due to *Lactobacillus rhamnosus*." *Journal of Clinical Microbiology*.52,8. 3124-3126. (2014).
http://digitalcommons.wustl.edu/open_access_pubs/3140

This Open Access Publication is brought to you for free and open access by Digital Commons@Becker. It has been accepted for inclusion in Open Access Publications by an authorized administrator of Digital Commons@Becker. For more information, please contact engeszer@wustl.edu.

Probiotic-Associated Aspiration Pneumonia Due to *Lactobacillus rhamnosus*

Christopher D. Doern, Sean T. Nguyen, Folashade Afolabi
and Carey-Ann D. Burnham

J. Clin. Microbiol. 2014, 52(8):3124. DOI:
10.1128/JCM.01065-14.

Published Ahead of Print 4 June 2014.

Updated information and services can be found at:
<http://jcm.asm.org/content/52/8/3124>

These include:

REFERENCES

This article cites 33 articles, 11 of which can be accessed free
at: <http://jcm.asm.org/content/52/8/3124#ref-list-1>

CONTENT ALERTS

Receive: RSS Feeds, eTOCs, free email alerts (when new
articles cite this article), [more»](#)

Information about commercial reprint orders: <http://journals.asm.org/site/misc/reprints.xhtml>
To subscribe to to another ASM Journal go to: <http://journals.asm.org/site/subscriptions/>

Probiotic-Associated Aspiration Pneumonia Due to *Lactobacillus rhamnosus*

Christopher D. Doern,^a Sean T. Nguyen,^b Folashade Afolabi,^c  Carey-Ann D. Burnham^d

Virginia Commonwealth University Health System, Department of Pathology, Richmond, Virginia, USA^a; Children's Medical Center, Department of Pharmacy, Dallas, Texas, USA^b; Department of Pediatrics, University of Texas Southwestern Medical Center, Dallas, Texas, USA^c; Washington University School of Medicine, Department of Pathology and Immunology and Department of Pediatrics, St. Louis, Missouri, USA^d

Lactobacilli are low-virulence, commensal organisms of the gastrointestinal and genitourinary tracts and are commonly used as “probiotic supplements.” Herein, we describe an episode of respiratory syncytial virus (RSV) bronchiolitis with bacterial superinfection secondary to administration of *Lactobacillus rhamnosus* in an 11-month-old female with trisomy 21.

CASE REPORT

An 11-month-old female with trisomy 21 presented with vomiting and fever. The patient had a past medical history significant for esophageal atresia, which was repaired 10 months earlier, subsequently requiring multiple balloon dilations. The patient had dysphagia and was gastrostomy tube (G-tube) dependent. Approximately 1 week prior to admission, the patient was admitted for an esophageal dilation and developed hematemesis, which required intubation and admission to the pediatric intensive care unit (PICU). She was extubated the next day and ultimately discharged home after 4 days of hospitalization given the lack of evidence for esophageal perforation on esophagram and clinical improvement. She had been doing well until 1 day prior to admission, when she had an episode of emesis and developed a fever to 101°F. In the emergency department, a chest X ray was performed and interpreted as concerning for a right-sided infiltrate versus atelectasis. The patient was administered intravenous clindamycin and admitted for presumed aspiration pneumonia. Overnight, the patient remained febrile and became hypoxic. A respiratory pathogen panel (RPP) (BioFire; FilmArray, Salt Lake City, UT) was performed and found to be positive for respiratory syncytial virus (RSV), which subsequently led to a discontinuation of clindamycin. The patient remained febrile for 3 days, and O₂ saturations continued to be between 80 and 90%. A repeat chest X ray demonstrated progression of pneumonia, demonstrated by complete opacification secondary to her atelectasis of the right lung. At that time, ceftriaxone was initiated, and a pulmonary consult was sought. During this assessment, she was diagnosed with RSV bronchiolitis and presumed bacterial superinfection, which required an admission to the PICU for further management of her hypoxia and increasing respiratory distress. Following admission to the PICU, a bronchoalveolar lavage (BAL) was performed, and the BAL fluid sample was submitted to microbiology for RPP testing as well as bacterial and fungal culture. The RPP was again positive for RSV, while fungal cultures were negative. The BAL fluid specimen Gram stain showed many white blood cells (WBC), rare ciliated respiratory epithelial cells, rare alveolar macrophages, many red blood cells (RBC), and many Gram-positive rods. The bacterial culture grew >100,000 CFU/ml of Gram-positive rods and <1,000 CFU/ml of mixed respiratory flora. The Gram-positive

rod grew both aerobically and anaerobically and was alpha-hemolytic and catalase negative. The organism was identified by matrix-assisted laser desorption ionization–time of flight mass spectrometry (MALDI-TOF MS). Both the Biotyper version 3.0 (Bruker Daltonics, Billerica, MA) and the Vitek MS (IVD Knowledge Base v2.0) (bioMérieux, Marcy l’Etoile, France) identified the organism as *Lactobacillus rhamnosus*. Using gradient diffusion testing performed on blood Mueller-Hinton agar and incubated for 24 h (Etest; bioMérieux, Marcy l’Etoile, France), the isolate was found to be susceptible to penicillin (MIC, 0.5 µg/ml) but resistant to vancomycin (MIC, ≥256 µg/ml) (1). Given these findings, ceftriaxone was discontinued and intravenous ampicillin-sulbactam was administered for 10 days. The patient gradually recovered over a 2-week period. Two endotracheal tube aspirates were collected 1 and 15 days after initiation of ampicillin-sulbactam, which were negative for the presence of *Lactobacillus* by both direct Gram stain and culture.

During the course of this patient’s illness, it was discovered that she had been taking the *Lactobacillus rhamnosus*-containing probiotic Culturelle (probiotic strain referred to as “LGG”) (Culturelle, Cromwell, CT) for 3 months prior to her illness. A capsule of the probiotic was obtained and cultured, and the isolated organism was confirmed to be *L. rhamnosus* by MALDI-TOF MS. Strain typing of the *L. rhamnosus* isolates was performed using repetitive sequence PCR (REP-PCR) with the primer RW3A as previously described (2, 3). PCR products were resolved on the Agilent 2100 (Agilent, Santa Clara, CA), and the relatedness of the strains was evaluated using DiversiLab software (bioMérieux, Durham, NC). The probiotic strain and the patient’s strain were identical, with a similarity index of >99%. A control strain of *Lactobacillus rhamnosus* isolated by the lab during the same time frame was also analyzed and found to be unrelated to the index patient’s isolate (similarity index of

Received 15 April 2014 Returned for modification 10 May 2014

Accepted 28 May 2014

Published ahead of print 4 June 2014

Editor: K. C. Carroll

Address correspondence to Christopher D. Doern, cdoern@mcvh-vcu.edu.

Copyright © 2014, American Society for Microbiology. All Rights Reserved.

doi:10.1128/JCM.01065-14

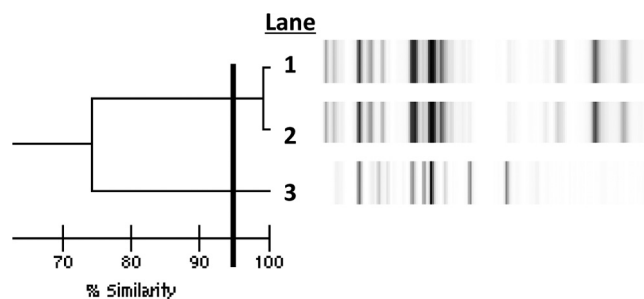


FIG 1 Strain typing of *Lactobacillus* strains. The dendrogram illustrates the results of repetitive sequence PCR (repPCR). Lane 1, patient BAL strain; lane 2, Culturelle strain; lane 3, unrelated *Lactobacillus rhamnosus* control strain. The solid horizontal line denotes a similarity index of 95%.

<70% to the index isolate) (Fig. 1). To our knowledge, this is the first reported case of *Lactobacillus* pneumonia related to supplementation with probiotics.

Discussion and review of the literature. We have described a case of probiotic-associated pneumonia secondary to RSV infection in a patient with trisomy 21 and a history of esophageal atresia but who was otherwise thought to be immunocompetent. Herein, we provide both clinical and microbiological evidence that the probiotic strain (LGG) was a cause of disease in this patient. Clinically, the treating physicians had suspicion of bacterial superinfection based on the patient's deteriorating respiratory status as well as imaging studies. In addition, the patient was managed as though she had a *Lactobacillus* infection, where empirical vancomycin and ceftriaxone were switched to ampicillin-sulbactam in response to isolation of *Lactobacillus* in culture. Laboratory evidence was also consistent with an infection; the specimen's Gram stain demonstrated inflammatory cells as well as abundant Gram-positive rods. The culture results supported this finding with abundant and predominant growth of *Lactobacillus rhamnosus* and strongly suggested a pathogenic role.

The mechanism by which the patient developed this infection is not clear. We hypothesize that the patient aspirated the probiotic strain while being predisposed to serious bacterial infection as a result of her ongoing RSV infection. Indeed, the patient would later be diagnosed with a tracheoesophageal fistula, further supporting this hypothesis. RSV-infected individuals are at risk for secondary bacterial infection, and those with trisomy 21 are at particular risk for severe RSV infection (4, 5). Despite the patient's risk factors, *Lactobacillus* pneumonia is very rare. A review of the literature identified only 11 cases of *Lactobacillus* pneumonia (6–14). The rarity of cases makes it difficult to draw conclusions about risk factors for disease, but being immunocompromised (especially having AIDs) appears to be the primary risk factor.

Lactobacilli are low-virulence organisms that are commensals of the genitourinary and gastrointestinal tracts and are commonly used as probiotic supplements (15). In the rare instances where *Lactobacillus* causes disease, it is usually in the form of bacteremia in patients who are either immunocompromised or have intravenous catheters (16). This is the first published case of probiotic-associated pneumonia. It is one of only 19 previous cases in which the infecting *Lactobacillus* isolate was confirmed by strain typing to be identical to the probiotic strain being taken by the patient

(17–23). Eighteen of these 19 cases were bloodstream infections, with the 19th being a case of liver abscess. Interestingly, 5 of the 19 confirmed cases were pediatric patients, 3 of which had short gut syndrome (22).

To date, a number of other studies have associated probiotic use with infection. The majority of cases are bloodstream infections, but other disease manifestations, such as urinary tract infection and peritonitis, have also been reported (24–28). Several studies have looked at the safety of LGG probiotic use at the institutional level and found that its use is safe and does not lead to an increase in infectious complications. Whelan and Meyers conducted a literature review of randomized and nonrandomized trials with the goal of investigating the safety of probiotic use (29). Of the 72 articles that fulfilled their inclusion criteria, they found 20 case reports of adverse events in 32 patients. Of these, the majority of infections were due to *Saccharomyces boulardii*, with only 5 identified cases resulting from LGG, all of which were bloodstream infections. Honeycutt and colleagues conducted a randomized placebo-controlled trial in which they asked whether probiotic use could reduce the rates of nosocomial infection in a pediatric intensive care unit (30). The numbers were small in this study, and they were not able to show that LGG administration reduced infection in this patient population. Importantly though, they did not identify any LGG infections during the study. These findings are contrary to those of Luong et al., who found an increase LGG disease in their hospital immediately after the hospital formulary switched from *Lactobacillus acidophilus* or *Lactobacillus helveticus* to *Lactobacillus rhamnosus* (31).

In conclusion, we describe the first case of probiotic-associated *L. rhamnosus* pneumonia. Our case is of particular interest because it occurred secondary to a respiratory viral infection. One of the reported benefits of *L. rhamnosus* probiotic use is to help prevent the development of severe respiratory tract infection, especially those due to respiratory viruses, including RSV (32–34). These data provide an important example of how normal non-pathogenic probiotic strains can cause real disease in vulnerable patient populations. With that being said, it is important to point out that while probiotics are frequently consumed, there is an extremely low incidence of infection due to these strains. The purpose of this report is to serve as an example of how extenuating circumstances can render a patient susceptible to probiotic infection.

REFERENCES

1. Clinical and Laboratory Standards Institute. 2014. Performance standards for antimicrobial susceptibility testing; 24th informational supplement. CLSI M100-S24. Clinical and Laboratory Standards Institute, Wayne, PA.
2. El Feghaly RE, Stamm JE, Fritz SA, Burnham CA. 2012. Presence of the bla(Z) beta-lactamase gene in isolates of *Staphylococcus aureus* that appear penicillin susceptible by conventional phenotypic methods. *Diagn. Microbiol. Infect. Dis.* 74:388–393. <http://dx.doi.org/10.1016/j.diagmicrobio.2012.07.013>.
3. Fritz SA, Hogan PG, Camins BC, Ainsworth AJ, Patrick C, Martin MS, Krauss MJ, Rodriguez M, Burnham CA. 2013. Mupirocin and chlorhexidine resistance in *Staphylococcus aureus* in patients with community-onset skin and soft tissue infections. *Antimicrob. Agents Chemother.* 57:559–568. <http://dx.doi.org/10.1128/AAC.01633-12>.
4. Bloemers BL, van Furth AM, Weijerman ME, Gemke RJ, Broers CJ, van den Ende K, Kimpen JL, Strengers JL, Bont LJ. 2007. Down syndrome: a novel risk factor for respiratory syncytial virus bronchiolitis—a prospective birth-cohort study. *Pediatrics* 120:e1076–e1081. <http://dx.doi.org/10.1542/peds.2007-0788>.

5. Zachariah P, Ruttenber M, Simoes EA. 2012. Down syndrome and hospitalizations due to respiratory syncytial virus: a population-based study. *J. Pediatr.* 160:827e1–831.e1. <http://dx.doi.org/10.1016/j.jpeds.2011.11.004>.
6. Wood GC, Boucher BA, Croce MA, Fabian TC. 2002. *Lactobacillus* species as a cause of ventilator-associated pneumonia in a critically ill trauma patient. *Pharmacotherapy* 22:1180–1182. <http://dx.doi.org/10.1592/phco.22.13.1180.33530>.
7. Namnyak SS, Blair AL, Hughes DF, McElhinney P, Donnelly MR, Corey J. 1992. Fatal lung abscess due to *Lactobacillus casei* ss *rhamnosus*. *Thorax* 47:666–667. <http://dx.doi.org/10.1136/thx.47.8.666>.
8. Querol JM, Manresa F, Izquierdo J, Cismal M. 1989. *Lactobacillus* pneumonia in a patient with oesophageal carcinoma. *Eur. Respir. J.* 2:589–591.
9. Abgrall S, Joly V, Derkinderen P, Decre D, Carbon C, Yeni P. 1997. *Lactobacillus casei* infection in an AIDS patient. *Eur. J. Clin. Microbiol. Infect. Dis.* 16:180–182. <http://dx.doi.org/10.1007/BF01709485>.
10. Rogasi PG, Vigano S, Pecile P, Leoncini F. 1998. *Lactobacillus casei* pneumonia and sepsis in a patient with AIDS. Case report and review of the literature. *Ann. Ital. Med. Int.* 13:180–182.
11. Sriskandan S, Lacey S, Fischer L. 1993. Isolation of vancomycin-resistant lactobacilli from three neutropenic patients with pneumonia. *Eur. J. Clin. Microbiol. Infect. Dis.* 12:649–650. <http://dx.doi.org/10.1007/BF01973653>.
12. Jones SD, Fullerton DA, Zamora MR, Badesch DB, Campbell DN, Grover FL. 1994. Transmission of *Lactobacillus* pneumonia by a transplanted lung. *Ann. Thorac. Surg.* 58:887–889. [http://dx.doi.org/10.1016/0003-4975\(94\)90779-X](http://dx.doi.org/10.1016/0003-4975(94)90779-X).
13. Fruchart C, Salah A, Gray C, Martin E, Stamatoullas A, Bonmarchand G, Lemeland JF, Tilly H. 1997. *Lactobacillus* species as emerging pathogens in neutropenic patients. *Eur. J. Clin. Microbiol. Infect. Dis.* 16:681–684. <http://dx.doi.org/10.1007/BF01708560>.
14. Rahman M. 1982. Chest infection caused by *Lactobacillus casei* ss *rhamnosus*. *Br. Med. J. (Clin. Res. ed)* 284:471–472. <http://dx.doi.org/10.1136/bmj.284.6314.471-a>.
15. Didari T, Solki S, Mozaffari S, Nikfar S, Abdollahi M. 2014. A systematic review of the safety of probiotics. *Expert Opin. Drug Saf.* 13:227–239. <http://dx.doi.org/10.1517/14740338.2014.872627>.
16. Gouriet F, Million M, Henri M, Fournier PE, Raoult D. 2012. *Lactobacillus rhamnosus* bacteremia: an emerging clinical entity. *Eur. J. Clin. Microbiol. Infect. Dis.* 31:2469–2480. <http://dx.doi.org/10.1007/s10096-012-1599-5>.
17. Land MH, Rouster-Stevens K, Woods CR, Cannon ML, Cnota J, Shetty AK. 2005. *Lactobacillus* sepsis associated with probiotic therapy. *Pediatrics* 115:178–181. <http://dx.doi.org/10.1542/peds.2004-2137>.
18. Rautio M, Jousimies-Somer H, Kauma H, Pietarinen I, Saxelin M, Tynkkynen S, Koskela M. 1999. Liver abscess due to a *Lactobacillus rhamnosus* strain indistinguishable from *L. rhamnosus* strain GG. *Clin. Infect. Dis.* 28:1159–1160. <http://dx.doi.org/10.1086/514766>.
19. Kochan P, Chmielarczyk A, Szymaniak L, Brykczynski M, Galant K, Zych A, Pakosz K, Giedrys-Kalemba S, Lenouvel E, Heczko PB. 2011. *Lactobacillus rhamnosus* administration causes sepsis in a cardio-surgical patient—is the time right to revise probiotic safety guidelines? *Clin. Microbiol. Infect.* 17:1589–1592. <http://dx.doi.org/10.1111/j.1469-0691.2011.03614.x>.
20. Kunz AN, Noel JM, Fairchok MP. 2004. Two cases of *Lactobacillus* bacteremia during probiotic treatment of short gut syndrome. *J. Pediatr. Gastroenterol. Nutr.* 38:457–458. <http://dx.doi.org/10.1097/00005176-200404000-00017>.
21. Mackay AD, Taylor MB, Kibbler CC, Hamilton-Miller JM. 1999. *Lactobacillus* endocarditis caused by a probiotic organism. *Clin. Microbiol. Infect.* 5:290–292. <http://dx.doi.org/10.1111/j.1469-0691.1999.tb00144.x>.
22. De Groote MA, Frank DN, Dowell E, Glode MP, Pace NR. 2005. *Lactobacillus rhamnosus* GG bacteremia associated with probiotic use in a child with short gut syndrome. *Pediatr. Infect. Dis. J.* 24:278–280. <http://dx.doi.org/10.1097/01.inf.0000154588.79356.e6>.
23. Salminen MK, Rautelin H, Tynkkynen S, Poussa T, Saxelin M, Valtonen V, Jarvinen A. 2004. *Lactobacillus* bacteremia, clinical significance, and patient outcome, with special focus on probiotic *L. rhamnosus* GG. *Clin. Infect. Dis.* 38:62–69. <http://dx.doi.org/10.1086/380455>.
24. Ledoux D, Labombardi VJ, Karter D. 2006. *Lactobacillus acidophilus* bacteraemia after use of a probiotic in a patient with AIDS and Hodgkin's disease. *Int. J. STD AIDS* 17:280–282. <http://dx.doi.org/10.1258/095646206776253507>.
25. Vahabnezhad E, Mochon AB, Wozniak LJ, Ziring DA. 2013. *Lactobacillus* bacteremia associated with probiotic use in a pediatric patient with ulcerative colitis. *J. Clin. Gastroenterol.* 47:437–439. <http://dx.doi.org/10.1097/MCG.0b013e318279abf0>.
26. Mehta A, Rangarajan S, Borate U. 2013. A cautionary tale for probiotic use in hematopoietic SCT patients—*Lactobacillus acidophilus* sepsis in a patient with mantle cell lymphoma undergoing hematopoietic SCT. *Bone Marrow Transplant.* 48:461–462. <http://dx.doi.org/10.1038/bmt.2012.153>.
27. Tena D, Martinez NM, Losa C, Fernandez C, Medina MJ, Saez-Nieto JA. 2013. Acute acalculous cholecystitis complicated with peritonitis caused by *Lactobacillus plantarum*. *Diagn. Microbiol. Infect. Dis.* 76:510–512. <http://dx.doi.org/10.1016/j.diagmicrobio.2013.03.018>.
28. Darbro BW, Petroelje BK, Doern GV. 2009. *Lactobacillus delbrueckii* as the cause of urinary tract infection. *J. Clin. Microbiol.* 47:275–277. <http://dx.doi.org/10.1128/JCM.01630-08>.
29. Whelan K, Myers CE. 2010. Safety of probiotics in patients receiving nutritional support: a systematic review of case reports, randomized controlled trials, and nonrandomized trials. *Am. J. Clin. Nutr.* 91:687–703. <http://dx.doi.org/10.3945/ajcn.2009.28759>.
30. Honeycutt TC, El Khashab M, Wardrop RM, III, McNeal-Trice K, Honeycutt AL, Christy CG, Mistry K, Harris BD, Meliones JN, Kocis KC. 2007. Probiotic administration and the incidence of nosocomial infection in pediatric intensive care: a randomized placebo-controlled trial. *Pediatr. Crit. Care Med.* 8:452–458, 464. <http://dx.doi.org/10.1097/01.PCC.0000282176.41134.E6>.
31. Luong ML, Sareyyupoglu B, Nguyen MH, Silveira FP, Shields RK, Potoski BA, Pasculle WA, Clancy CJ, Toyoda Y. 2010. *Lactobacillus* probiotic use in cardiothoracic transplant recipients: a link to invasive *Lactobacillus* infection? *Transpl. Infect. Dis.* 12:561–564. <http://dx.doi.org/10.1111/j.1399-3062.2010.00580.x>.
32. Chiba E, Tomosada Y, Vizoso-Pinto MG, Salva S, Takahashi T, Tsukida K, Kitazawa H, Alvarez S, Villena J. 2013. Immunobiotic *Lactobacillus rhamnosus* improves resistance of infant mice against respiratory syncytial virus infection. *Int. Immunopharmacol.* 17:373–382. <http://dx.doi.org/10.1016/j.intimp.2013.06.024>.
33. Morrow LE, Kollef MH, Casale TB. 2010. Probiotic prophylaxis of ventilator-associated pneumonia: a blinded, randomized, controlled trial. *Am. J. Respir. Crit. Care Med.* 182:1058–1064. <http://dx.doi.org/10.1164/rccm.200912-1853OC>.
34. Luoto R, Ruuskanen O, Waris M, Kalliomaki M, Salminen S, Isolauri E. 2014. Prebiotic and probiotic supplementation prevents rhinovirus infections in preterm infants: a randomized, placebo-controlled trial. *J. Allergy Clin. Immunol.* 133:405–413. <http://dx.doi.org/10.1016/j.jaci.2013.08.020>.