

Washington University School of Medicine Digital Commons@Becker

Open Access Publications

11-1-2005

The ponticulus posticus: Implications for screw insertion into the first cervical lateral mass

Jason P. Young

St. Louis University School of Medicine

Paul H. Young

St. Louis University School of Medicine

Paul A. Anderson

University of Wisconsin - Madison

K. Daniel Riew

Washington University School of Medicine in St. Louis

Follow this and additional works at: http://digitalcommons.wustl.edu/open_access_pubs

 Part of the [Medicine and Health Sciences Commons](#)

Recommended Citation

Young, Jason P.; Young, Paul H.; Anderson, Paul A.; and Riew, K. Daniel, "The ponticulus posticus: Implications for screw insertion into the first cervical lateral mass." *The Journal of Bone and Joint Surgery*.87,11. 2495-2498. (2005).
http://digitalcommons.wustl.edu/open_access_pubs/1108

This Open Access Publication is brought to you for free and open access by Digital Commons@Becker. It has been accepted for inclusion in Open Access Publications by an authorized administrator of Digital Commons@Becker. For more information, please contact engeszer@wustl.edu.

THE PONTICULUS POSTICUS: IMPLICATIONS FOR SCREW INSERTION INTO THE FIRST CERVICAL LATERAL MASS

BY JASON P. YOUNG, BS, PAUL H. YOUNG, MD, MICHAEL J. ACKERMANN, BS, MPT,
PAUL A. ANDERSON, MD, AND K. DANIEL RIEW, MD

*Investigation performed at the Cervical Spine Service, Department of Orthopaedic Surgery,
Barnes-Jewish Hospital at Washington University School of Medicine, and Department of Neurosurgery,
St. Louis University School of Medicine, St. Louis, Missouri*

Background: The arcuate foramen is an important osseous anomaly of the first cervical vertebra (the atlas) that must be taken into consideration during placement of lateral mass screws into the atlas.

Methods: The prevalence of this anomaly in our patient population was determined through a retrospective review of 464 lateral radiographs of the neck. The anatomy of the arcuate foramen was identified in a study of cadavers.

Results: Seventy-two arcuate foramina, complete or incomplete, were identified on the 464 lateral radiographs of the neck; thus, the prevalence was 15.5% in our patient population.

Conclusions: Although the arcuate foramen is a common anomaly, it is often not recognized. Proper identification of this anomaly on preoperative lateral radiographs should alert the surgeon to avoid using the ponticulus posticus as a starting point for a lateral mass screw in order to not injure the vertebral artery.

Level of Evidence: Diagnostic Level IV. See Instructions to Authors for a complete description of levels of evidence.

Placement of lateral mass screws into the atlas (the first cervical vertebra) has become a popular means of treating atlantoaxial instability¹. However, it can sometimes be a difficult procedure, as the region contains venous plexuses as well as the greater occipital nerve. To avoid these difficulties, some surgeons have recommended that, in the presence of a broad posterior arch of the atlas, the insertion of the screw be started in the dorsal aspect of the posterior arch instead of at the base of the lateral mass. We recently encountered an anatomical specimen containing an anomaly of the posterior arch of the atlas containing the vertebral artery. In this specimen, the sulcus or groove for the vertebral artery on the dorsal aspect of the atlas was completely covered by an anomalous ossification, termed the *ponticulus posticus* (Latin for *little posterior bridge*)². The resulting foramen contains the vertebral artery and is referred to as the *arcuate foramen*². Many terms have been used in the literature to describe this anomaly, including *Kimmerle anomaly*³, *foramen sagittale*, and *a retrocondylar vertebral artery*. The purpose of this study was to determine the frequency of the anomaly and to identify its

anatomical features in relation to surgical approaches to the posterior aspect of the atlas.

Materials and Methods

Radiographic Analysis

We examined 464 lateral radiographs of the cervical spine: 336 were a consecutive series of digital images of the cervical spine obtained from the radiology department of a large metropolitan teaching hospital, and 128 were a consecutive series of radiographs of the cervical spine obtained from the office of one of the authors (P.H.Y.). Each radiograph was carefully inspected to look for the presence of a ponticulus posticus and arcuate foramen. Because we inspected only a neutral lateral radiograph, we were not able to determine if the anomaly was unilateral or bilateral. The protocol was approved by the institutional review board of our institution.

Anatomical Dissection

A cadaver specimen identified as having a ponticulus posticus during a hands-on cervical spine course was fully dissected. In

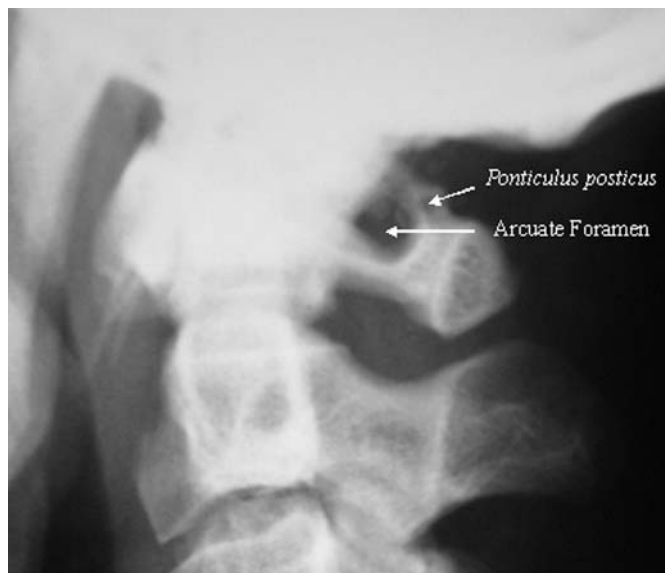

Fig. 1
Lateral radiograph of the cervical spine, demonstrating an arcuate foramen of the first cervical vertebra and a ponticulus posticus.

In addition, twenty other preserved cadavers, selected at random, were dissected. A separate group of six cervical spine osseous specimens that had previously been dissected out were also examined. The anatomical characteristics of the specimens were studied, and the specimens were photographed.

Results

Radiographic Analysis

Analysis of the 464 lateral radiographs of the neck revealed seventy-two complete or incomplete arcuate foramina (Fig. 1). Thus, the prevalence of an arcuate foramen in this patient population was 15.5%.

Anatomical Dissection

The anatomical dissections revealed an arcuate foramen in three of the twenty specimens. One of them had a unilateral partial foramen, and the other two had a unilateral complete foramen. Of the six cervical spine osseous specimens, three demonstrated an arcuate foramen: one was bilateral and complete, one was unilateral and partial, and one was unilateral and complete.

When examining a specimen with an arcuate foramen through a standard dorsal approach, we found that it was easy to mistake the broad ponticulus posticus for a widened posterolateral aspect of the posterior arch of the atlas, when in reality it is a foramen containing the vertebral artery (Figs. 2 and 3). The placement of a lateral mass screw into the atlas in this situation can predispose the vertebral artery to injury. We found that one way of identifying this anomaly was to dissect laterally until the lateral margin of the foramen was identified. Whereas the normal posterior arch of the atlas *thins* out laterally and does not curve up cranially, a ponticulus posticus *broadens* laterally to cover the underlying artery, which can be

found on the lateral border of the ponticulus. Dissecting the artery at the first cervical arterial groove and following its course medially and cranially can also help to identify a ponticulus posticus.

Discussion

An important common anomaly of the posterolateral aspect of the posterior arch of the atlas is the arcuate foramen, which contains the vertebral artery. Reports have described this anomaly in relation to posterior cranial fossa strokes and as a possible cause of cervicogenic headache^{4,5}. Despite the relatively high prevalence of this anomaly, we found only one case report demonstrating the clinical importance of the arcuate foramen in relation to the placement of screws into the first cervical lateral mass. Harms and Melcher described placement of such screws for the treatment of atlantoaxial instability¹. Because placement of lateral mass screws at the first cervical level can be difficult, some surgeons have recommended starting the insertion of the screw in the superior aspect of the posterior arch of the atlas, when anatomically

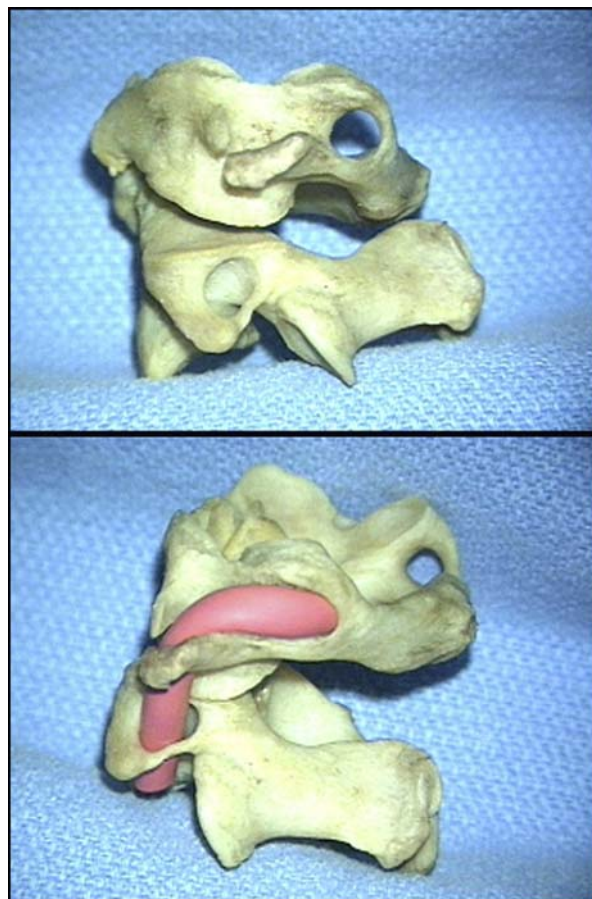


Fig. 2
Lateral views of osseous specimens of the first and second cervical vertebrae, demonstrating an arcuate foramen of the atlas (top) and revealing the course of the vertebral artery within the arcuate foramen formed by the ponticulus posticus (bottom).

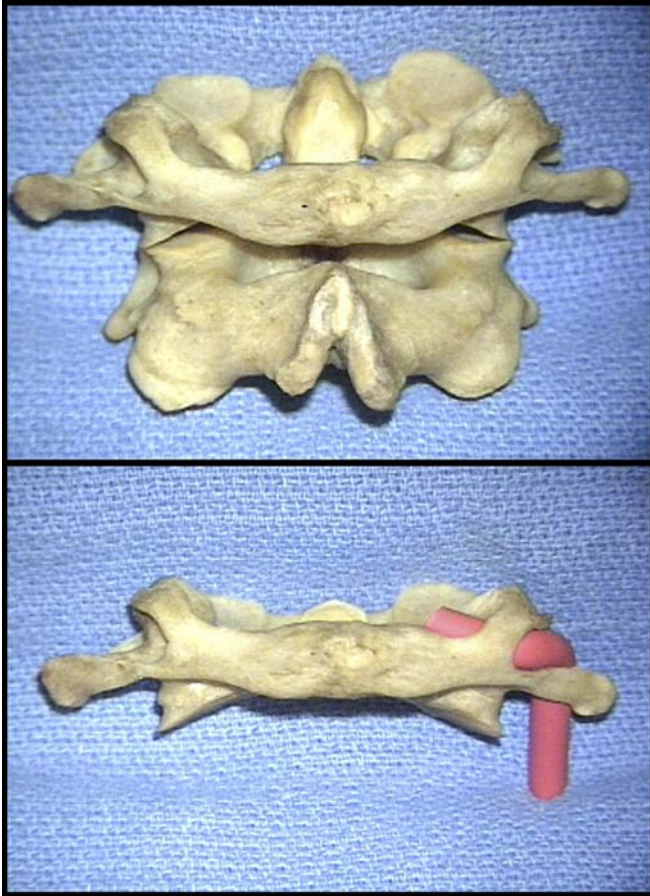


Fig. 3
Anteroposterior views of osseous specimens of the first and second cervical vertebrae, demonstrating a ponticulus posticus bilaterally (top) and revealing the vertebral artery coursing medially within the arcuate foramen and deep to the ponticulus posticus (bottom).

possible⁶. While this may be reasonable for most patients, in individuals with an arcuate foramen, the anomaly has the potential for being misidentified as a broad dorsal arch. A screw placed into a ponticulus posticus can potentially injure the vertebral artery, leading to stroke and death. We undertook this radiographic and anatomical dissection study to better characterize this common anomaly and to alert surgeons of the potential dangers of misidentifying it.

We found that an arcuate foramen is quite common; it was present in 15.5% (seventy-two) of the 464 patients in our study population. From the dorsal view, it is possible to misidentify a ponticulus posticus as a broad dorsal arch of the atlas. Our dissections revealed that, whereas the normal posterior arch of the atlas *thins* out laterally and does not curve up cranially, a ponticulus posticus *broadens* laterally and extends cranially. The artery can be found on the lateral border of the ponticulus, entering the arcuate foramen. By dissecting the artery at the first cervical arterial groove and following its course medially and cranially, one can readily identify a ponticulus posticus. More importantly, however, a preoperative

lateral radiograph demonstrates this anomaly. If the radiograph is inconclusive and there appears to be a broad posterior arch intraoperatively, it may be best to dissect out the cranial aspect of the posterior arch to identify and protect the vertebral artery.

There are few reports on the clinical relevance of this anomaly. Huang and Glaser reported an arcuate foramen in a sixty-seven-year-old woman with rheumatoid arthritis who presented with radicular symptoms of both extremities⁷. The planned procedure included posterior fixation with polyaxial screws from the first to the fourth cervical vertebrae. As the surgeons approached the atlas, they dissected the lateral mass only to discover the anomalous course of the vertebral artery. They then chose not to place the screws and instead used sublaminar wiring at the first and second cervical vertebrae, as described by Brooks and Jenkins⁸. Huang and Glaser noted, in retrospect, that the preoperative lateral radiographs of the neck had revealed the anomaly.

The anatomical importance of this anomaly is unknown. It has been suggested that the arcuate foramen is commonly present in quadrupeds (early primates) and acts as an additional lateral extension for the attachment of the posterior atlantooccipital membrane². In humans, however, the vertical loading of the superior articular process of the atlas supports the weight of the head; thus, the roof of the tunnel has disappeared². It is unknown if its occurrence in humans is due to an acquired ossification of the atlantooccipital membrane resulting from the pulsatile vertebral artery, or whether it is a variant of osseous architecture in the region of the craniovertebral junction, as might be suggested by the observation, by Lamberty and Zivanovic, of a cartilaginous ponticulus posticus in fetuses and children⁹. The prevalence, however, does not appear to vary with age. Thus, it seems to be a congenital osseous anomaly of the atlas with varying degrees of ossification.

In conclusion, our study suggests that the ponticulus posticus is a common anomaly that can easily be mistaken for a broad posterior arch of the atlas. We recommend that, before placing a screw into what appears to be a widened posterior arch of the atlas, the surgeon review the lateral radiograph of the neck to check for the presence of an arcuate foramen. ■

Jason P. Young, BS
Paul H. Young, MD
Michael J. Ackermann, BS, MPT
Department of Neurosurgery, St. Louis University School of Medicine,
and Practical Anatomy Workshop, 3839 Lindell Boulevard, St. Louis,
MO 63108

Paul A. Anderson, MD
Department of Orthopaedic Surgery and Rehabilitation, University of
Wisconsin, 600 Highland Avenue, K4/738 CSC, Madison, WI 53792-0001

K. Daniel Riew, MD
Department of Orthopaedic Surgery, Barnes-Jewish Hospital at Wash-
ington University School of Medicine, One Barnes-Jewish Hospital

Plaza, 11300 West Pavilion, St. Louis, MO 63110. E-mail address:
riewd@wustl.edu

The authors did not receive grants or outside funding in support of their research or preparation of this manuscript. They did not receive payments or other benefits or a commitment or agreement to provide such benefits from a commercial entity. No commercial entity paid

or directed, or agreed to pay or direct, any benefits to any research fund, foundation, educational institution, or other charitable or nonprofit organization with which the authors are affiliated or associated.

doi:10.2106/JBJS.E.00184

References

1. Harms J, Melcher RP. Posterior C1-C2 fusion with polyaxial screw and rod fixation. *Spine*. 2001;26:2467-71.
2. Hasan M, Shukla S, Siddiqui MS, Singh D. Posterolateral tunnels and ponticuli in human atlas vertebrae. *J Anat*. 2001;199:339-43.
3. Kimmerle A. Ponticulus posticus. *Rontgenpraxis*. 1930;2:479-83.
4. Cushing KE, Ramesh V, Gardner-Medwin D, Todd NV, Gholkar A, Baxter P, Griffiths PD. Tethering of the vertebral artery in the congenital arcuate foramen of the atlas vertebra: a possible cause of vertebral artery dissection in children. *Dev Med Child Neurol*. 2001;43:491-6.
5. Wight S, Osborne N, Breen AC. Incidence of ponticulus posterior of the atlas in migraine and cervicogenic headache. *J Manipulative Physiol Ther*. 1999;22:15-20.
6. Stillerman CB, Wilson JA. Atlanto-axial stabilization with posterior transarticular screw fixation: technical description and report of 22 cases. *Neurosurgery*. 1993;32:948-54.
7. Huang MJ, Glaser JA. Complete arcuate foramen precluding C1 lateral mass screw fixation in a patient with rheumatoid arthritis: case report. *Iowa Orthop J*. 2003;23:96-9.
8. Brooks AL, Jenkins EB. Atlanto-axial arthrodesis by the wedge compression method. *J Bone Joint Surg Am*. 1978;60:279-84.
9. Lamberty BG, Zivanovic S. The retro-articular vertebral artery ring of the atlas and its significance. *Acta Anat*. 1973;85:113-22.