

## Washington University School of Medicine Digital Commons@Becker

---

### Open Access Publications

---

2-1-2006

# Prospective measurement of function and pain in patients with non-neoplastic compression fractures treated with vertebroplasty

Heidi Prather

*Washington University School of Medicine in St. Louis*

Linda Van Dillen

*Washington University School of Medicine in St. Louis*

John P. Metzler

*Washington University School of Medicine in St. Louis*

K. Daniel Riew

*Washington University School of Medicine in St. Louis*

Louis A. Gilula

*Washington University School of Medicine in St. Louis*

Follow this and additional works at: [http://digitalcommons.wustl.edu/open\\_access\\_pubs](http://digitalcommons.wustl.edu/open_access_pubs)

 Part of the [Medicine and Health Sciences Commons](#)

---

### Recommended Citation

Prather, Heidi; Van Dillen, Linda; Metzler, John P.; Riew, K. Daniel; and Gilula, Louis A., "Prospective measurement of function and pain in patients with non-neoplastic compression fractures treated with vertebroplasty." *The Journal of Bone and Joint Surgery*.88,2. 334-341. (2006).

[http://digitalcommons.wustl.edu/open\\_access\\_pubs/1071](http://digitalcommons.wustl.edu/open_access_pubs/1071)

This Open Access Publication is brought to you for free and open access by Digital Commons@Becker. It has been accepted for inclusion in Open Access Publications by an authorized administrator of Digital Commons@Becker. For more information, please contact [engeszer@wustl.edu](mailto:engeszer@wustl.edu).

# PROSPECTIVE MEASUREMENT OF FUNCTION AND PAIN IN PATIENTS WITH NON-NEOPLASTIC COMPRESSION FRACTURES TREATED WITH VERTEBROPLASTY

BY HEIDI PRATHER, DO, LINDA VAN DILLEN, PT, PhD,  
JOHN P. METZLER, MD, K. DANIEL RIEW, MD, AND LOUIS A. GILULA, MD

*Investigation performed at Washington University School of Medicine, St. Louis, Missouri*

**Background:** There has been an increasing number of reports regarding the benefits of vertebroplasty for the treatment of vertebral compression fractures. In this investigation, validated outcome tools were utilized to document the impact of vertebroplasty on pain and function.

**Methods:** Fifty patients were recruited at a tertiary university hospital. Patients had been treated for intractable pain due to osteoporotic compression fracture(s) for at least four weeks. The vertebroplasty procedures were performed by a radiologist. The subjects were followed prospectively for one year and received conservative treatment in conjunction with the vertebroplasty. Validated outcome tools, including a visual analog scale, the Oswestry scale, and the Roland-Morris functional activity questionnaire, were used to evaluate changes in pain and functional capabilities.

**Results:** Fifty patients, thirty-one women and nineteen men (mean age, 68.6 years), were followed prospectively for one year. One hundred and three fractures (fifty-nine thoracic and forty-four lumbar) were treated. The visual analog scale showed the greatest improvement between the baseline score (mean, 7.76) and the score at one month (mean, 2.9), and the score remained improved at one year (mean, 2.9). The Oswestry and Roland-Morris questionnaires demonstrated significant ( $p < 0.0001$ ) functional improvement between the baseline and one-month scores. With the numbers available, there were no significant changes in any variable from one month to one year ( $p > 0.05$ ).

**Conclusions:** Vertebroplasty is an effective treatment for patients with intractable pain due to osteoporotic vertebral compression fractures. Improvement in pain scores and functional capabilities that were found at one month were maintained at one year.

**Level of Evidence:** Therapeutic Level IV. See Instructions to Authors for a complete description of levels of evidence.

Osteoporotic vertebral compression fractures can cause substantial impairment and disability. These fractures often do not require hospitalization but can require months to heal. Conservative management, including analgesics, therapeutic modalities, bracing, and exercise, usually facilitates healing and pain relief within four to eight weeks. However, some individuals do not respond to conservative treatment and go on to have intractable pain. Operative management of vertebral compression fractures is generally reserved for patients with spinal deformity or neurological compromise. Surgery is often viewed as a last resort

because of the high rate of coexisting morbidities, poor fusion rates secondary to difficulty in obtaining purchase for implants in osteoporotic bone, and reduced osteogenesis in the elderly<sup>1</sup>. In addition, acute complications such as transient ileus, urinary retention, and occasionally spinal cord compression can occur<sup>2,3</sup>. Chronic effects include kyphosis with occasional breathing difficulties, deconditioning, insomnia, and depression.

Vertebroplasty, which is the percutaneous infusion of polymethylmethacrylate into the compressed vertebra, is an alternative treatment for patients with intractable pain due to

osteoporotic compression fracture(s)<sup>3-5</sup>. The purpose of the procedure is to relieve pain by reinforcing the fractured vertebra. Early relief of pain may be expected to improve function as well, ultimately reducing impairment and disability. This should place elderly individuals at less risk for subsequent health complications as a result of immobilization. Several reports<sup>2,3,6-8</sup> have described the technical aspects of vertebroplasty for osteoporotic fractures and the pain relief reported by patients treated with the procedure. The outcomes described in these studies include changes in mobility and usage of analgesic medication. A number of the studies<sup>4,8,9</sup> included patients who were treated with vertebroplasty for fractures related to a tumor. Patients with cancer and those with osteoporosis may report pain differently as a result of factors unrelated to the fracture. It is possible that patients with cancer do not have the same level of functional improvement as patients with non-neoplastic vertebral fracture. To our knowledge, no one has used validated outcome measures to determine the functional improvements in conjunction with the pain relief in patients treated with vertebroplasty for osteoporotic fracture. The purpose of the current study was to determine if vertebroplasty can offer patients with intractable pain related to osteoporotic compression fracture pain relief and improved function.

### Materials and Methods

Fifty-two consecutive patients with non-neoplastic vertebral compression fracture(s) were prospectively enrolled in the study. Two of those patients decided not to answer the questionnaires completely after enrolling and were not included in the study. An additional (fifty-third) patient lived a substantial distance from our center and did not want to receive follow-up there and thus had declined to be enrolled.

The procedure, including the potential benefits and risks, was discussed with the patient. The potential complications of vertebroplasty that were described included bleeding, bone infection or fracture, damage to nerve roots or the spinal cord, leakage of material into the surrounding epidural or paravertebral spaces, and passage of material into the venous system with embolization to the pulmonary vasculature or compression of neural tissues. The participants then signed two written informed-consent forms, one for the procedure and one to enroll in the study. The study received institutional review board approval through the Human Studies Committee at Washington University School of Medicine.

Conservative management, lasting for at least four weeks and including pain medication(s), bed rest, bracing, and therapeutic exercise directed by a physical therapist, had failed for all patients. The appropriateness of the vertebroplasty for each patient was determined by a group of physicians practicing in four different disciplines, including two physiatrists, one neurosurgeon, one radiologist, and three orthopaedic spine surgeons, in a university-based hospital setting. The physiatrists or referring spine surgeon provided evaluation and treatment prior to the procedure. Follow-up care was provided by the physiatrists. The follow-up questionnaires

were returned by the patient at the time of follow-up or were administered by telephone by a research assistant trained in telephone interview techniques. The radiologist had extensive experience with vertebroplasty and performed or was involved in all of the procedures. One of the spine surgeons reviewed all questionable imaging studies to confirm spinal stability and to help determine whether the patient was a candidate for surgery or vertebroplasty. Magnetic resonance imaging was utilized to assess acuity and other characteristics of the fracture, patency of the spinal canal, and disc abnormalities. All patients in this study had decreased signal on T1-weighted images and increased signal on T2-weighted images of the compressed vertebra, indicating an acute or subacute fracture, and the compression fractures were confirmed by the radiologist. No burst fractures that included the posterior elements were included in this study. Computed tomography was not routinely performed, and the status of the posterior wall of the vertebral body was not used to determine a patient's eligibility for the vertebroplasty.

A history was recorded and a physical examination was performed for all patients to determine if the compression fracture correlated with the symptoms. In addition to a full neurological and musculoskeletal examination, the patient was asked to flex and extend the spine to its end range of motion in order to provoke pain. If pain was elicited at the site of the fracture, the provocative test was considered to be positive. Flexion loads the fractured vertebra and usually causes pain in the acute setting. Extension may cause pain as well, especially when a retropulsed fragment is in the spinal canal. We speculated that this may elicit osseous as well as neurogenic pain as the canal is narrowed with extension. If there was an adjacent-level fracture(s) that correlated with the site of pain, all of the fractures were treated. If a fracture was noted at a distance from the site of pain and pain could not be provoked on physical examination, that fracture was not treated. Patients were followed for a minimum of one year by one of the two physiatrists, neither of whom had performed the procedure.

The patient completed a baseline questionnaire, which included information regarding general health, previous medical care for osteoporosis, and previous conservative management for the pain due to vertebral compression fracture(s).

Laboratory work, including a complete blood-cell count, platelet count, measurement of the prothrombin time, and measurement of the partial thromboplastin time, was done to rule out bleeding disorders. A standardized physical examination that included the neurological and musculoskeletal systems was performed by one of the surgeons or physiatrists. The multidisciplinary group of physicians reviewed the case of each patient who was being considered for vertebroplasty. All imaging studies pertaining to the area of pain were reviewed and were compared with the history and the findings of the physical examination. At a minimum, imaging included frontal and lateral spine radiographs and magnetic resonance imaging, unless the patient could not have magnetic resonance imaging, in which case a computed tomography scan with or without bone scintigraphy was performed. Inclusion and ex-

**TABLE I Inclusion and Exclusion Criteria for Offering Vertebroplasty**

Inclusion Criteria	Exclusion Criteria
Intractable pain related to the compression fracture for $\geq 4$ wk	Abnormal laboratory findings
No neurological compromise	Spine pain that did not clinically correlate with the vertebral fracture
Axial spine pain that worsens with active spine flexion	Neurological compromise
No other suspicious sources of pain as determined by imaging and clinical history	Patient determined to be medically unstable by primary care physician
No laboratory evidence or history of a bleeding disorder	Unstable fracture
Patient determined to be medically stable for the procedure by primary care physician	

clusion criteria for offering patients a vertebroplasty are listed in Table I.

The vertebroplasty was performed by the radiologist as described by Jensen et al.<sup>3</sup> and as modified by the radiologist. A unipedicular approach was used more commonly than a bipedicular approach. Osteobond copolymer bone cement (Zimmer, Warsaw, Indiana) was injected. The blood pressure, heart rate, and result of pulse oximetry were monitored and oxygen was supplied through a nasal cannula throughout the procedure. A nurse trained in conscious sedation administered neuroleptic analgesics (fentanyl and midazolam) under the direction of the radiologist. A transpedicular approach with an 11-gauge Jamshidi-type needle (MD Tech Bone Biopsy Set; Medical Devices Technology, Gainesville, Florida) was used. A technically successful procedure was defined by an effective transpedicular puncture of the vertebral body with instillation of bone cement. The amount of bone cement that was injected and any complications were recorded.

The outcome tools were administered by individuals other than the physician performing the procedure to limit patient-reporting bias. Validated outcome measures<sup>10-12</sup>, including a visual analog scale, in which 0 indicated no pain and 10 indicated the worst possible pain, and pain diagrams showing the location and quality of the pain, were used to document pain levels. The Roland-Morris questionnaire<sup>10</sup> and the Oswestry low back pain disability questionnaire<sup>11</sup> were used to measure functional abilities. On the pre-procedure visual analog scale, the patient rated maximal pain in the past twenty-four hours. On the post-procedure visual analog scale, which was administered by the radiologist between one and two hours after the vertebroplasty, the patient was asked to rate the pain that he or she was feeling at that time to document an immediate clinical response to the procedure. The patient was given discharge instructions, including recommendations for follow-up with his or her primary care physician for osteoporosis management as well as an extension-based spine-stabilization physical therapy program to increase comfort and overcome the effects of the relative immobilization that had been caused by the previous intractable pain.

Follow-up questionnaires were administered at two weeks and at one, three, six, and twelve months after the procedure. Patients who were not responding to the procedure

and those in whom new pain developed were examined by one of the surgeons or physiatrists, and radiographic imaging was performed as directed by the patient's history and findings on physical examination. New vertebral compression fractures were recorded. New pain was managed, according to the patient's needs, with medications, rest, bracing, and physical therapy. Patients in whom a new fracture developed independently chose whether to undergo vertebroplasty for the subsequent fracture(s).

Statistical analyses were conducted to assess the effect of vertebroplasty on pain, distress, and functional ability. The variables assessed at baseline, two weeks, and one, three, six, and twelve months were analyzed with a random coefficient model created by PROC MIXED, from the SAS statistical software package (SAS, Cary, North Carolina). The visual analog score was the only variable assessed immediately following the vertebroplasty, and it was not assessed at six or twelve months. Because of the difference in the occasions for measurement with the visual analog scale relative to the other variables, a paired t test was used to assess the effect of vertebroplasty on visual analog scale scores. A series of paired t tests was conducted to determine the significance of the improvement in individual items on the Roland-Morris questionnaire following the vertebroplasty. Data regarding patients in whom new fracture(s) developed after the vertebroplasty were analyzed with the Fisher exact test.

## Results

Fifty patients, thirty-one women and nineteen men with a mean age of 68.6 years (range, thirty-six to ninety-one years), were followed prospectively for one year. Ten patients died of causes unrelated to the vertebral fracture(s) prior to the one-year follow-up date. All fifty patients had follow-up data for six months, and forty were followed for one year. One hundred and three fractures, including fifty-nine involving a thoracic vertebra and forty-four involving a lumbar vertebra, were treated. The mean duration of the pain prior to the procedure, as reported by the patients, was fourteen months (range, one to seventy-two months). An average of 2.06 vertebral levels (range, one to four levels) was managed at each treatment session. Only 39% of the patients could remember the event that occurred at the time that the pain began. The

**TABLE II Comparison of Demographic Information Between Study Participants and Nonparticipants**

	Participants* (N = 50)	Nonparticipants* (N = 3)
Mean age (yr)	68.6 (36-91)	74 (57-88)
Gender	31 F, 19 M	2 F, 1 M
Mean no. of medications	1.6 (1-2)	1.6 (1-2)
Mean no. of fractures	2.06 (1-4)	2.6 (2-3)
Mean no. of comorbidities	4.2 (1-11)	4 (3-6)
Mean pain duration (mo)	14 (1-72)	7.6 (7-9)

\*The numbers in parentheses indicate the range.

majority of the patients (61%) reported an insidious onset of pain. Fifty-five percent of the patients had been diagnosed with osteoporosis prior to the fracture for which they were being treated with the vertebroplasty. Forty-five percent of the patients required a cane to walk, and 32% required a wheelchair for mobility in the community. Previous conservative treatment had consisted of exercises for 14% of the patients, bracing for 22%, and a spinal injection for 27%. All patients were receiving a variety of medications for pain, including nonsteroidal anti-inflammatory drugs, acetaminophen, tramadol, narcotics, gabapentin, tricyclic anti-depressants, and muscle relaxants. The general health questionnaire revealed that the patients had an average of 4.2 medical conditions (range, one to eleven conditions).

Three patients had elected not to participate in the study because they lived a distance from our center or they were not willing to complete the questionnaires. No significant differences regarding demographics were noted between those who participated in the study and those who chose not to participate. However, the group who chose to enroll in the study reported, on the average, a longer duration of pain than those who did not participate (Table II).

A total of fourteen new fractures developed in ten patients after the vertebroplasty. Nine of the new fractures were within one or two vertebral levels cephalad or caudad to the level that had been previously treated with the vertebroplasty, and five new fractures were at levels remote from the previously treated fracture. Seven of the ten patients elected to undergo another vertebroplasty for treatment of the subsequent fracture(s), and three patients chose conservative treatment. Of the fifty patients treated, seven had received glucocorticosteroids for various medical conditions prior to or at the time of the vertebroplasty. New fracture(s) developed in all seven of those pa-

tients (a total of eight new fractures) after the vertebroplasty (Table III). A Fisher exact test<sup>13</sup> was used to calculate the exact probability of obtaining the data pattern that we observed. A chi-square test is typically used with a 2 × 2 table, but it was not utilized in our analysis because of the zero value (representing the fact that all patients who had taken steroids sustained a new fracture) involved in the test. The obtained Fisher statistic was 25.46, which was highly significant ( $p = 0.0$ ). Of the eight fractures in the group of patients who had taken steroids, five were at sites within one to two levels of the previously treated fracture. Five of the seven patients elected to undergo another vertebroplasty for treatment of the new fracture.

The visual analog scale showed significant improvement ( $p < 0.0001$ ) from a baseline mean of  $7.76 \pm 2.18$  to an immediate post-procedure mean of  $3.1 \pm 2.9$ . The visual analog score remained improved ( $p < 0.0001$ ) two weeks after the procedure, with a mean of  $3.7 \pm 2.5$ ; at four weeks after the procedure, with a mean of  $2.9 \pm 2.2$ ; and at twelve weeks after the procedure, with a mean of  $2.9 \pm 7.0$ . No significant changes were found after the four-week measurement, as all scores remained improved (mean at one year, 2.9).

The Oswestry low back pain disability questionnaire and the Roland-Morris questionnaire (Fig. 1) demonstrated significant ( $p < 0.0001$ ) functional improvement from baseline to one month after the procedure. With the numbers available, there were no significant changes in any variable from one month to one year ( $p > 0.05$ ). A summary of the results of the paired t tests for the individual items on the Roland-Morris questionnaire is presented in Table IV. Sixty-nine t tests were conducted (13 items × 3 comparisons). A p value of 0.005 was selected as a cutoff for significance, and p values between 0.05 and 0.005 were considered to be marginally significant. The activities on the Roland-Morris questionnaire

**TABLE III 2 × 2 Contingency Table of Number of Subjects Taking and Not Taking Steroids Who Did and Did Not Sustain a Refracture**

	Taking Steroids	Not Taking Steroids	Total
Refracture	7	3	10
No refracture	0	40	40
Total	7	43	50

**TABLE IV Functional Activities with and without Significant Improvement as Measured with the Roland-Morris Questionnaire**

Activities with Most Significant Improvement*	Activities with No Significant Improvement†
Transfers in and out of bed	Laundry
Standing	Gardening
Sleeping	Public transportation
Sitting	Toileting
Dressing	Lifting heavy objects
Shopping	Participation in hobbies
Bathing	Strenuous housework

\*P < 0.0001. †P > 0.005.

that showed the most significant improvement were transfers in and out of bed, standing, sleeping, and sitting, with p values of <0.0001 for the comparison between baseline and one month, 0.005 to <0.0001 for the comparison between baseline and three months, and 0.0008 to <0.0001 for the comparison between baseline and six months. Functions that did not improve significantly ( $p > 0.05$ ) following vertebroplasty were toileting, lifting heavy objects, participation in hobbies, and strenuous housework.

Ten of the fifty patients died after the six-month follow-up examination and prior to the one-year follow-up date. None of the deaths were thought to be related to the vertebro-

plasty. The patients ranged in age from seventy-five to eighty-seven years old at the time of death. A series of graphs was created to examine the potential effect of the missing data on the results (Figs. 2-A and 2-B). Because of their similarity and the small standard error bars, these graphs suggested that the observed pattern of improvement following vertebroplasty was unlikely to have been an artifact of missing data.

### Discussion

Percutaneous vertebroplasty is becoming more popular for treating patients with osteoporotic vertebral compression fractures. In the current study, we evaluated outcomes of vertebroplasty in patients with intractable pain due to osteoporotic vertebral compression fracture(s) for which comprehensive conservative management had failed. The conservative management varied and was based on the patient's condition and the primary treating physician's preferences for therapeutic modalities. In general, this group of patients had complex conditions, with a mean of 4.2 other reported medical problems, reduced mobility, and an average fourteen-month duration of pain before the vertebroplasty procedure. Patients were offered vertebroplasty on the basis of a multidisciplinary physician review.

No adverse events were recorded as a result of the procedure in the fifty patients in this study. The results indicate a clear improvement in function and decrease in pain within two weeks after the procedure. There were no additional significant improvements with regard to pain relief or function after three months, as demonstrated by the Roland-Morris and Oswestry questionnaires. However, the improvements acquired in the

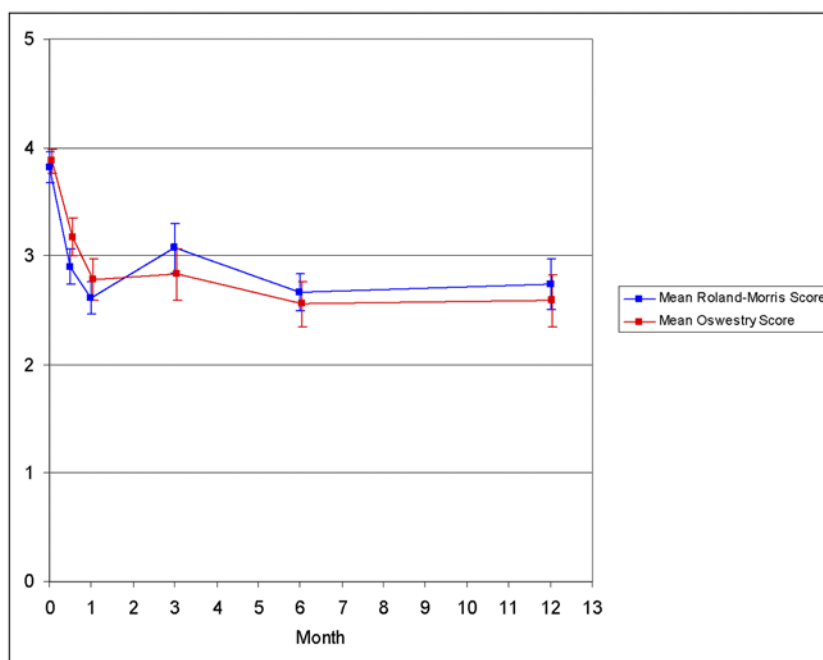


Fig. 1

Mean scores (with standard error bars) according to the Roland-Morris questionnaire and the Oswestry low back pain disability questionnaire at baseline, two weeks, one month, three months, six months, and twelve months after the vertebroplasty.



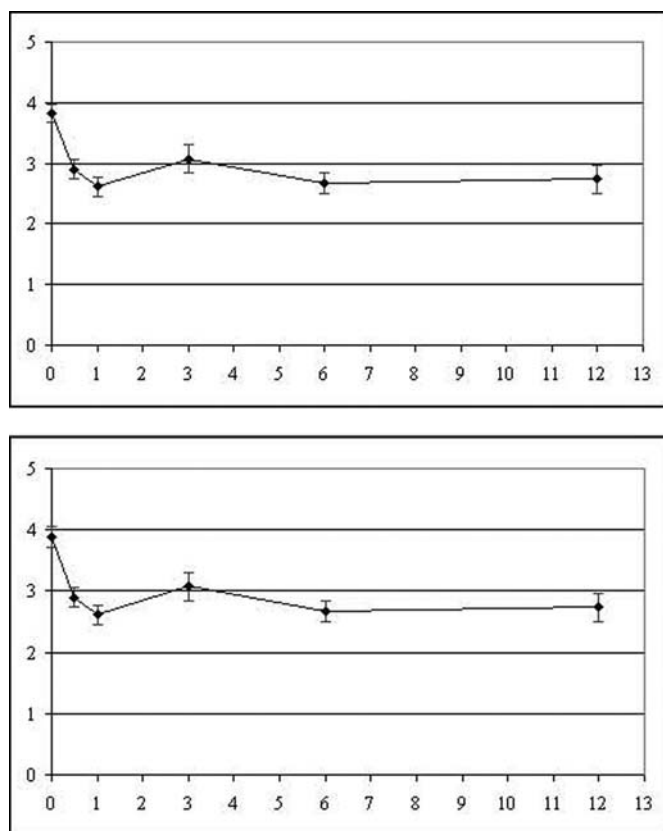


Fig. 2-A

Mean scores (with standard error bars) according to the Roland-Morris questionnaire (averaged across items), at baseline, two weeks, one month, three months, six months, and twelve months after the vertebroplasty. Top: Scores for all fifty patients, including those who died prior to the twelve-month follow-up date. Bottom: Scores for forty patients—that is, not including those who died prior to the twelve-month follow-up date.

first three months were maintained at six and twelve months. The patient's perceptions of pain and functional improvement were evaluated with validated prospective questionnaires rather than a global assessment by the treating physician or measurement of outcome at just one point in time. The results indicate that vertebroplasty has a significant beneficial impact on function and pain, with the benefits continuing at six months and one year. We can infer from these results that decreased pain and improved mobility have the potential to reduce morbidity and should reduce long-term health-care costs.

The functional activities that showed significant improvement were basic tasks required to maintain independent living. Only one item that is a basic requirement for independent living, toileting, did not improve. We speculated that a person must have substantial proximal strength to perform toileting independently. Many of our patients were quite debilitated, partly as a result of inactivity and decreased mobility secondary to the pain that they had experienced prior to the vertebroplasty. As a result, we recommend that basic activities

of daily living be evaluated and physical therapy be started, when indicated, after vertebroplasty.

All of the patients who had taken glucocorticosteroids sustained a new fracture after the vertebroplasty. Although new fractures are a known risk of vertebroplasty<sup>4,5,8,14-16</sup>, the etiologies are multifactorial and have not been entirely identified. These factors include dynamic mobility of the fracture<sup>17</sup>, location of the new fracture adjacent to the treated vertebra<sup>14,18</sup>, cement extravasation at the time of the procedure<sup>16</sup>, and the type and amount of filling by the cement<sup>19-21</sup>. To our knowledge, the extent of the osteoporosis and previous treatment to improve bone metabolism and musculoskeletal fitness have not been evaluated as factors contributing to the development of new fractures. In a study by Uppin et al.<sup>14</sup>, new fractures developed in twenty-two (12.4%) of 177 patients after treatment with vertebroplasty. Sixty-seven percent of thirty-six new fractures were at a level adjacent to the vertebral body that had been treated, and 67% of the fractures occurred within thirty days after the initial vertebroplasty. Uppin et al. focused primarily

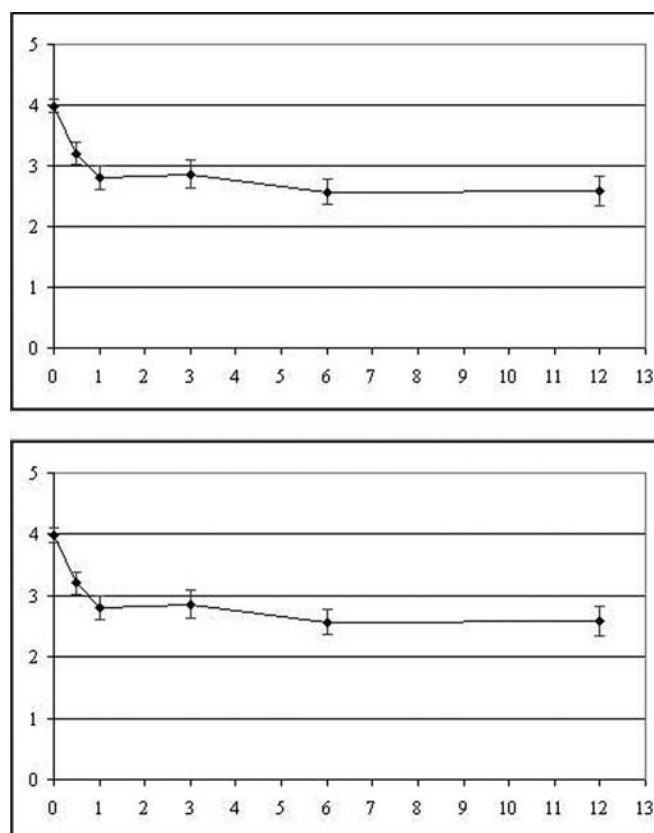


Fig. 2-B

Mean scores (with standard error bars) according to the Oswestry low back pain disability questionnaire (averaged across items), at baseline, two weeks, one month, three months, six months, and twelve months after the vertebroplasty. Top: Scores for all fifty patients, including those who died prior to the twelve-month follow-up date. Bottom: Scores for forty patients—that is, not including those who died prior to the twelve-month follow-up date.

on identifying the location of subsequent fractures, and they reported information only on patients who returned for additional interventions. It is possible that patients who sustained subsequent fractures but did not seek procedural intervention were not included. Seven (32%) of the twenty-two patients who returned for a procedure to treat a new fracture in that study had steroid-induced osteoporosis. In a study by Perez-Higueras et al.<sup>5</sup>, three of thirteen patients sustained a new fracture, and two of the three elected to be treated with vertebroplasty again. In a study by Lindsay et al.<sup>22</sup>, women with osteoporosis who had not been treated with vertebroplasty and who had sustained one fracture had a 19.2% prevalence of an additional fracture within a year. Therefore, it can be reasonably assumed that some of the fractures that occurred after the vertebroplasties in our study would have occurred if a vertebroplasty had not been performed.

To our knowledge, the risk of a new vertebral body collapse following a vertebroplasty in patients with steroid-induced osteoporosis has not been studied. Initially, glucocorticosteroids affect trabecular bone by causing a high rate of surface resorption and high bone-turnover rate. As a result, glucocorticosteroids are associated with a four to fivefold increase in the prevalence of vertebral fracture as compared with the prevalence in patients who are not treated with corticosteroids<sup>23</sup>. Two studies<sup>24,25</sup> have suggested that patients with vertebral fractures due to corticosteroids have higher bone-mineral-density values than those with fractures due to other forms of osteoporosis. Rehman et al.<sup>26</sup> found that bone mineral density measured with quantitative computed tomography, but not with dual-energy x-ray absorptiometry, was an independent predictor of vertebral fractures in postmenopausal women with steroid-induced osteoporosis. With this in mind, patients offered vertebroplasty for compression fractures due to steroid-induced osteoporosis should be counseled on the probable additional risk of a new fracture after the vertebroplasty.

This study had several weaknesses. Ten of the fifty patients died before the one-year follow-up date, which resulted in missing data after six months. Also, although physical therapy was prescribed for all patients, compliance was not measured. Forty-five percent of the patients had not been diagnosed with osteoporosis prior to the vertebral fracture, indicating that osteoporosis continues to be a silent entity. The medical management was determined by the primary care physician and, if necessary, the patient was referred to the bone-mineral-health service at our center. As a result, medical management varied within the group. We did not include a control group for comparison, as optimal conservative care had failed for all patients. However, we thought that offering no treatment (as a control) to a group of patients with intractable pain was clinically unacceptable. Instead, this study

served to demonstrate pain relief and improvement in functional outcomes in patients for whom conservative management had failed.

In this study, we reported on the utility of vertebroplasty. Kyphoplasty, a procedure that includes inflating a percutaneously placed balloon within the fractured vertebra and then infusing cement within the cavity created by the balloon, has not been studied. Our study included only outpatients for whom previous treatment had failed, who elected to undergo vertebroplasty, and who agreed to be followed for one year. To our knowledge, no studies have been performed to compare the benefits of vertebroplasty with those of kyphoplasty in humans with non-neoplastic fractures<sup>27</sup>. Our study focused on patients with pain for whom conservative management had failed and who had few or no remaining therapeutic options other than vertebroplasty. In this population, vertebroplasty significantly decreased pain and improved function. Future prospective studies are needed to compare standard conservative treatment with vertebroplasty and with kyphoplasty. Additional studies are also needed to better determine the risk factors for the development of new fractures after vertebroplasty and to verify that the rate of incidental fractures after vertebroplasty is actually higher than what occurs in a population without vertebroplasty. ■

Heidi Prather, DO  
John P. Metzler, MD  
K. Daniel Riew, MD

Department of Orthopaedic Surgery, Washington University School of Medicine, 1 Barnes-Jewish Hospital Plaza Drive, Suite 11300 West Pavilion, St. Louis, MO 63110

Linda Van Dillen, PT, PhD

Program in Physical Therapy, Washington University School of Medicine, 4444 Forest Park Boulevard, Box 8502, St. Louis, MO 63108

Louis A. Gilula, MD

Mallinckrodt Institute of Radiology, Washington University School of Medicine, 510 South Kingshighway Boulevard, St. Louis, MO 63110

The authors did not receive grants or outside funding in support of their research for or preparation of this manuscript. They did not receive payments or other benefits or a commitment or agreement to provide such benefits from a commercial entity. No commercial entity paid or directed, or agreed to pay or direct, any benefits to any research fund, foundation, educational institution, or other charitable or nonprofit organization with which the authors are affiliated or associated.

doi:10.2106/JBJS.D.02670

## References

1. Bronk JT, Urabe K, Liang T, Bolander ME. The effect of age on fracture repair in a rat femur model. *Trans Orthop Res Soc.* 1996;21:200.
2. Bostrom MP, Lane JM. Future directions. Augmentation of osteoporotic vertebral bodies. *Spine.* 1997;22(24 Suppl):38S-42S. Erratum in: *Spine.* 1998;23:1992.

3. Jensen ME, Evans AJ, Mathis JM, Kallmes DF, Cloft HJ, Dion JE. Percutaneous polymethylmethacrylate vertebroplasty in the treatment of osteoporotic vertebral body compression fractures: technical aspects. *AJNR Am J Neuroradiol.* 1997;18:1897-904.



4. Barr JD, Barr MS, Lemley TJ, McCann RM. Percutaneous vertebroplasty for pain relief and spinal stabilization. *Spine*. 2000;25:923-8.
5. Perez-Higueras A, Alvarez L, Rossi RE, Quinones D, Al-Assir I. Percutaneous vertebroplasty: long-term clinical and radiological outcome. *Neuroradiology*. 2002;44:950-4.
6. Mathis JM, Petri M, Naff N. Percutaneous vertebroplasty treatment of steroid-induced osteoporotic compression fractures. *Arthritis Rheum*. 1998;41:171-5.
7. Gangi A, Kastler BA, Dietemann JL. Percutaneous vertebroplasty guided by a combination of CT and fluoroscopy. *AJNR Am J Neuroradiol*. 1994;15:83-6.
8. Deramond H, Depriester C, Galibert P, Le Gars D. Percutaneous vertebroplasty with polymethylmethacrylate. Technique, indications, and results. *Radiol Clin North Am*. 1998;36:533-46.
9. Kaemmerlen P, Thiesse P, Jonas P, Berard CL, Duquesnel J, Bascoulegue Y, La-pras C. Percutaneous injection of orthopedic cement in metastatic vertebral lesions. *N Engl J Med*. 1989;321:121.
10. Roland M, Morris R. A study of the natural history of back pain. Part I: development of a reliable and sensitive measure of disability in low-back pain. *Spine*. 1983;8:141-4.
11. Fairbank JC, Couper J, Davies JB, O'Brien JP. The Oswestry low back pain disability questionnaire. *Physiotherapy*. 1980;66:271-3.
12. Beaton DE, Schemitsch E. Measures of health-related quality of life and physical function. *Clin Orthop Relat Res*. 2003;413:90-105.
13. Agresti A. *Categorical data analysis*. 2nd ed. Hoboken, NJ: Wiley-Interscience; 2002. p 44-5.
14. Uppin AA, Hirsch JA, Centenera LV, Pfiefer BA, Pazianos AG, Choi IS. Occurrence of new vertebral body fracture after percutaneous vertebroplasty in patients with osteoporosis. *Radiology*. 2003;226:119-24.
15. Cyteval C, Sarrabere MP, Roux JO, Thomas E, Jorgensen C, Blotman F, Sany J, Taourel P. Acute osteoporotic vertebral collapse: open study on percutaneous injection of acrylic surgical cement in 20 patients. *AJR Am J Roentgenol*. 1999;173:1685-90.
16. Grados F, Depriester C, Cayrolle G, Hardy N, Deramond H, Fardellone P. Long-term observations of vertebral osteoporotic fractures treated by percutaneous vertebroplasty. *Rheumatology (Oxford)*. 2000;39:1410-4.
17. McKiernan F, Jensen R, Faciszewski T. The dynamic mobility of vertebral compression fractures. *J Bone Miner Res*. 2003;18:24-9.
18. Berlemann U, Ferguson SJ, Nolte LP, Heini PF. Adjacent vertebral failure after vertebroplasty. A biomechanical investigation. *J Bone Joint Surg Br*. 2002;84:748-52.
19. Heini PF, Berlemann U, Kaufmann M, Lippuner K, Fankhauser C, van Landuyt P. Augmentation of mechanical properties in osteoporotic vertebral bones—a biomechanical investigation of vertebroplasty efficacy with different bone cements. *Eur Spine J*. 2001;10:164-71.
20. Belkoff SM, Mathis JM, Jasper LE, Deramond H. An ex vivo biomechanical evaluation of a hydroxyapatite cement for use with vertebroplasty. *Spine*. 2001;26:1542-6.
21. Liebschner MA, Rosenberg WS, Keaveny TM. Effects of bone cement volume and distribution on vertebral stiffness after vertebroplasty. *Spine*. 2001;26:1547-54.
22. Lindsay R, Silverman SL, Cooper C, Hanley DA, Barton I, Broy SB, Licata A, Benhamou L, Geusens P, Flowers K, Stracke H, Seeman E. Risk of new vertebral fracture in the year following a fracture. *JAMA*. 2001;285:320-3.
23. Sambrook P, Lane NE. Corticosteroid osteoporosis. *Best Pract Res Clin Rheumatol*. 2001;15:401-13.
24. Luengo M, Picado C, Del Rio L, Guanabens N, Montserrat JM, Setoain J. Vertebral fractures in steroid dependent asthma and involutional osteoporosis: a comparative study. *Thorax*. 1991;46:803-6.
25. Peel NF, Moore DJ, Barrington NA, Bax DE, Eastell R. Risk of vertebral fracture and relationship to bone mineral density in steroid treated rheumatoid arthritis. *Ann Rheum Dis*. 1995;54:801-6.
26. Rehman Q, Lang T, Modin G, Lane NE. Quantitative computed tomography of the lumbar spine, not dual x-ray absorptiometry, is an independent predictor of prevalent vertebral fractures in postmenopausal women with osteopenia receiving long-term glucocorticoid and hormone-replacement therapy. *Arthritis Rheum*. 2002;46:1292-7.
27. Truumees E, Hilibrand A, Vaccaro AR. Percutaneous vertebral augmentation. *Spine J*. 2004;4:218-29.