

# An Asian Indian Woman with Wolfram Syndrome on Insulin Pump: Successful Pregnancy and Beyond

Jothydev Kesavadev, M.D.,<sup>1</sup> Anupam Kumar, MBBS,<sup>1</sup> Arun Shankar, MBBS,<sup>1</sup>  
Gopikrishnan Gopalakrishnan, BPharm,<sup>1</sup> Marshall A. Permutt, M.D.,<sup>2</sup>  
Jon Wasson, B.S.,<sup>2</sup> and Sunitha Jothydev, M.A.<sup>1</sup>

## Abstract

Wolfram syndrome (WS), or DIDMOAD (diabetes insipidus, diabetes mellitus, optic atrophy, and deafness), is a rare autosomal recessive neurodegenerative disorder with a median life expectancy of 30 years and occurs in one in 770,000 live births. To date only five successful pregnancies have been reported among WS subjects worldwide. Here we describe the sixth report of successful pregnancy in a WS patient and the first from India. The subject is still on an insulin pump, now 31 years old and doing well. She developed diabetes at 5 years of age, optic atrophy at 14 years, and diabetes insipidus at 25 years and had a successful delivery in 2007 while on an insulin pump. Sequencing of exonic regions of the *WFS1* gene showed five changes, two of which were pathogenic (exon 8). Magnetic resonance imaging of brain showed generalized neurodegenerative changes. The benefits of continuous subcutaneous insulin infusion and that of tight metabolic control in prevention of abortions and fetal malformations in diabetes associated with pregnancy are well documented. The impression of probable pleiotropic action of insulin pumps over and above that of glycemic reduction is gaining momentum. Recent evidence supports use of insulin pumps in alleviating neuropathic pain in diabetes, probably by virtue of its action in minimizing mean amplitude of glycemic excursions not possible with conventional insulin shots. WS is a progressive neurodegenerative disorder, which will probably help us in understanding the positive impact of continuous subcutaneous insulin infusion in prolonging the life span and retarding neuronal damage in WS.

## Introduction

**W**OLFRAM SYNDROME (WS) is a rare progressive neurodegenerative disorder, with a predominantly autosomal recessive inheritance pattern. The acronym of DIDMOAD constitutes the most common features of the syndrome—diabetes insipidus, diabetes mellitus, optic atrophy, and deafness. Apart from these, patients with WS may develop further neurological, urological, and psychiatric features. Previously only five cases of successful pregnancy in WS have been reported worldwide.<sup>1</sup>

Here we report the sixth case (and the first from India) of successful pregnancy in such a patient. She was started on an insulin pump, considering that her diabetes was poorly controlled, and that she had long-term plans to marry and conceive. She is still on continuous subcutaneous insulin infusion (CSII), and the child is now 3 years old. Although the WS-induced neurodegenerative changes are gradually progressing, the prolonged longevity and maintenance of improved quality of life are compelling evidence in favor of CSII.

## Case Report

A 27-year-old woman enrolled with us in August 2005 for comprehensive management of her childhood-onset diabetes mellitus. She was diagnosed as having diabetes mellitus by the age of 5 years. This was followed by development of progressive defective vision in both eyes since the age of 14 years, and she was diagnosed as having primary bilateral optic atrophy. At the age of 25 years, she had one admission for an acute psychosis and attempted suicide, after which she fully recovered. During this period of hospitalization, she developed severe electrolyte imbalances and was evaluated in detail. A diagnosis of diabetes insipidus was made, and she was started on desmopressin. She attained menarche at the age of 14 years and has regular menstrual cycles since then.

Her family history is significant in that she was born of a consanguineous marriage and has a brother who also has the same spectrum of disorders.

During the first visit in August 2005, her hemoglobin A1c (HbA1c) level was 8.3%. Other laboratory values were within

<sup>1</sup>Jothydev's Diabetes and Research Center, Mudavanmugal, Trivandrum, Kerala, India.

<sup>2</sup>Division of Endocrinology, Metabolism and Lipid Research, Washington University School of Medicine, St. Louis, Missouri.

acceptable limits. Initial ophthalmologic evaluation confirmed a defective vision, with a visual acuity of 6/60 in both eyes. Fundus examination showed features suggestive of primary bilateral optic atrophy and early posterior polar cataract. Color vision was also significantly impaired.

At our center, she was initially started on a basal-bolus regimen consisting of once-daily insulin glargine and three times-daily premeal insulin aspart. She was put on regular telephone follow-up. Despite modifications in diet, exercise, and medications, she had wide fluctuations in her blood sugar levels. She underwent continuous glucose monitoring (CGMS<sup>®</sup> System Gold<sup>™</sup>, Medtronic, Northridge, CA) for 3 days. Considering the wide excursions in her glycemic levels, her future plans to conceive, higher socioeconomic status, self-learning skills, and motivation, we started her on an insulin pump.<sup>2</sup> After the insulin pump was set up, her HbA1c was maintained between 5.2% and 5.9%. She was physically and mentally in perfect health except for bilateral diminution of vision.

She got married and became pregnant in December 2006. Throughout the course of pregnancy diabetes mellitus was aggressively managed. In our center we make use of the Diabetes Tele Management System (DTMS<sup>™</sup>)<sup>3</sup> wherein four to 11 blood glucose measurements are done at home with a glucometer and dosages are modified through telephone or internet. Correction boluses of aspart insulin were administered through the pump whenever self-monitored glucose values were above 125 mg%, thus maintaining an A1c below 6% throughout the course of her pregnancy (Table 1). The dose of desmopressin did not require any alteration as her diabetes insipidus remained stable.

Since conception, she was under regular care of the obstetrician. All her physical and laboratory parameters were reassuring during this period. She was admitted to the hospital in the next to last month of her pregnancy. This enabled strict monitoring of her homeostasis and for due adjustments to be made. A cesarean section was done, and a healthy male baby weighing 3.10 kg was delivered. Postoperatively, hourly glucose monitoring was done for a 24-h period, and the insulin dose was adjusted accordingly. She had an uneventful postpartum period. The baby was also evaluated in detail, and like in previously reported cases, the baby was in normal health.

The patient was discharged with advice to undergo regular postnatal checkups and follow-up with us for the management of her blood glucose levels. Two weeks into the postpartum period, she visited the center for her routine checkup. A magnetic resonance imaging (MRI) scan taken during this period showed features suggestive of generalized atrophy of cortex, brainstem, and cerebellum. Ultrasound evaluation of her genitourinary system revealed bilateral hydronephrosis and hydroureters. Ophthalmologic findings suggested further deterioration of vision (R -5/60 and L -4/60).

Routine evaluation done in early March 2010 gave an HbA1c of 7.8% and normal liver function tests (aspartate aminotransaminase, 28 IU/L; alanine aminotransaminase, 30 IU/L), kidney function tests (urea, 16 mg/dL; creatinine, 0.7 mg/dL), and total cholesterol (116 mg/dL). The electrolyte analysis showed a serum sodium of 134.1 mEq/L and serum potassium of 3.9 mEq/L. Furthermore, the serum osmolality showed a normal value of 288 mOsm/kg, and the 24-h urine total volume was 2,200 mL. The nerve conduction velocity report on motor nerve conduction showed normal distal latency, whereas the sensory conduction study showed bilateral distal peak latency prolonged from both median nerves. The MRI report showed diffuse cerebral and cerebellar atrophy associated with mild atrophy of the pons and midbrain. Fundus examination showed her best corrected visual acuity as 3/60 in both eyes, and her near vision was N12 with a 5.0D sphere. Her intraocular pressure was 18 in both eyes, and there were no diabetic retinopathy changes. The echocardiogram showed mild mitral valve prolapse and no mitral regurgitation.

Genetic analysis for WS was performed by polymerase chain reaction amplification and direct sequencing by Bio-serve Biotechnologies India Pvt. Ltd. (Hyderabad, India) (licensed by the World Health Organization to perform bioassays).

The methodology used for the gene sequencing was as follows: DNA was isolated from whole blood and was quantitated and diluted to a concentration of 100 ng/ $\mu$ L. The diluted DNA was used in the polymerase chain reaction with the specified primers in the supplied literature. The polymerase chain reaction products were gel-eluted and subjected to sequencing; the primers used for sequencing were the same primers used for amplification.

TABLE 1. BLOOD GLUCOSE LEVELS AND ANNUAL HEMOGLOBIN A1C VALUES OVER A PERIOD OF 5 YEARS, BEFORE AND AFTER BEING ON CONTINUOUS SUBCUTANEOUS INSULIN INFUSION

Parameter	Value (mg/dL)					
	2005 (before initiation of insulin pump therapy)	2006 (after initiation of insulin pump therapy)	2007	2008	2009	2010
Blood sugar						
Fasting	287	92	106	121	89	102
Pre-breakfast	159	117	134	129	103	152
Post-breakfast	272	114	102	113	106	149
Pre-lunch	198	124	159	214	116	127
Post-lunch	53	119	116	156	112	176
Pre-dinner	397	132	142	184	137	145
Post-dinner	192	118	121	140	123	142
HbA1c	8.3%	5.8%	6.2%	7.1%	6.9%	7.2%

HbA1c, hemoglobin A1c.

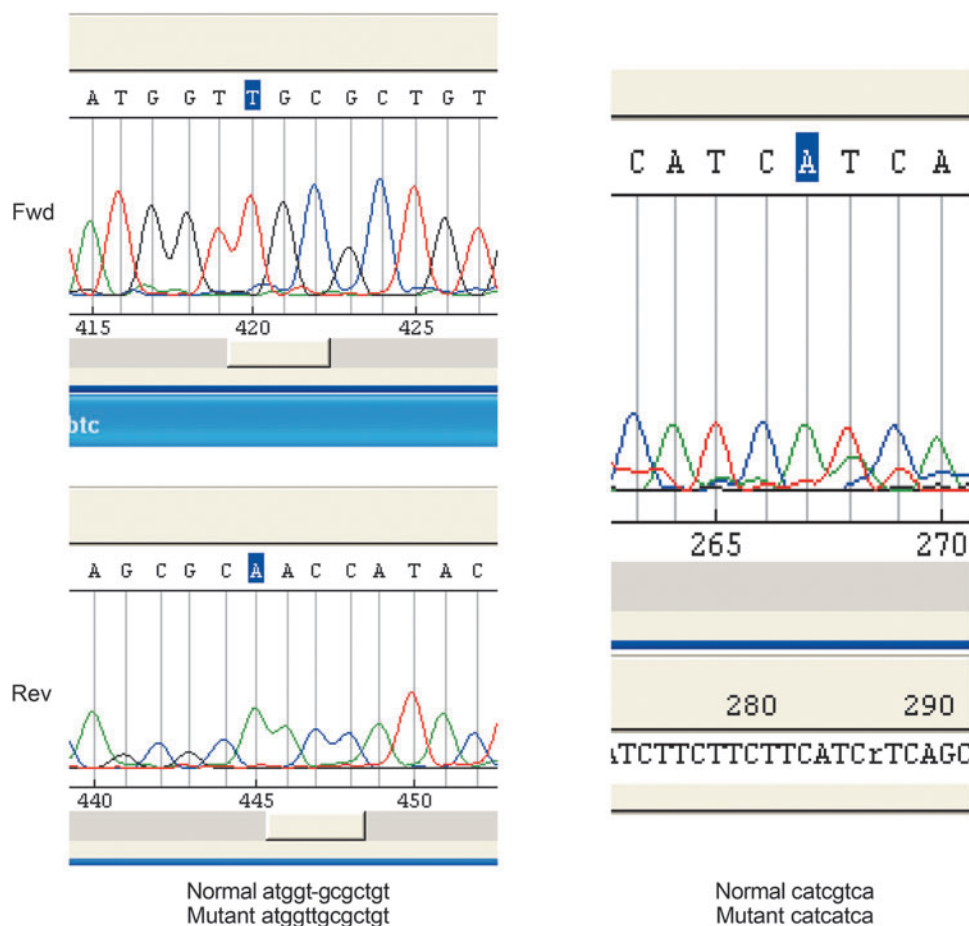


FIG. 1. Sequencing trace data of T insertion and G>A in exon 8 of the Wolfram syndrome gene *WFS1*. Fwd, forward; Rev, reverse. Color version available online at [www.liebertonline.com/dia](http://www.liebertonline.com/dia)

Sequencing of the exonic regions of *WFS1* gene showed five changes with the sample: (1) G>T polymorphism in the 5' flanking region of exon 1; (2) G>A polymorphism in the flanking region of exon 6; (3) G>A mutation in exon 8; (4) T insertion mutation in exon 8; and (5) C>T polymorphism in exon 8.

Based on the trace data all these are homozygous changes. The genetic analysis of exon 8 in the *WFS1* gene of this patient showed two likely disease-causing homozygous mutations: T insertion causes truncation (711 AA instead of 891) (Fig. 1), and G>A exon 8 is missense V>I.

## Discussion

WS is a progressive neurodegenerative disorder that constitutes an association of diabetes mellitus and optic atrophy. It was first described by Wolfram in 1938 in four siblings as noted by Sunder et al.<sup>4</sup> It is sometimes called DIDMOAD, the acronym for the major manifestations of the disorder, namely, diabetes insipidus, diabetes mellitus, optic atrophy, and deafness. The prevalence of WS according to studies conducted in the United Kingdom was 1:770,000, whereas independent studies in North America had shown a rate of 1:100,000.<sup>5</sup> The pattern of inheritance is mostly autosomal recessive, but the influence that certain variations in the mitochondrial genome may exert, to result in the increased

predisposition to this disorder, has also been suggested. The gene responsible for the syndrome, identified in 1998, has been linked to the short arm of chromosome 4p. It has been termed *Wolframin* gene or *WFS1*. Mutations in *WFS1* can be found in the majority of the patients with this disorder, although most of the mutations are new and vary with families.<sup>5</sup> *WFS1* spans 33.4 kb of genomic DNA and includes eight exons: exon 1 is noncoding, exons 2–7 are coding, and exon 8 is 2.6 kb long. *WFS1* mRNA encodes an 890-amino acid polypeptide with nine putative transmembrane domains and a 100-kDa molecular mass. Wolframin protein is an endoglycosidase H-sensitive membrane glycoprotein that localizes in the endoplasmic reticulum. In the endoplasmic reticulum, it regulates membrane trafficking and protein processing and has a crucial role in cell death through the apoptotic pathway.<sup>6</sup> The mechanisms responsible for the phenotype of carbohydrate intolerance and loss of pancreatic  $\beta$  cells in this disorder may be attributed to lack of expression of *WFS1* in  $\beta$  cells, resulting in the diabetes mellitus phenotype. The  $\beta$  cell death occurs by an accelerated process of apoptosis, and lack of *WFS1* is associated with dilated endoplasmic reticulum and increased markers of endoplasmic reticulum stress, significantly contributing to the reduction in  $\beta$  cell survival.<sup>7</sup>

The diagnosis of WS is essentially clinical and requires the presence of only diabetes mellitus and optic atrophy by the

age of 15 years (it has a positive predictive value of 83% and a negative predictive value of 1%). The addition of other features does not augment the diagnostic precision by very much. In the absence of a specific diagnostic marker, the presence of diabetes mellitus and optic atrophy can be considered the diagnostic criteria.<sup>8</sup> The disorder is usually found in children born of consanguineous marriages, like in our patient. However, a history of consanguinity is not essential for the occurrence of this syndrome. The prevalence and age of onset of other components like diabetes insipidus, deafness, and other clinical features are variable. Previous studies showed that although diabetes mellitus and optic atrophy had a 100% prevalence, the occurrence of the other abnormalities varies.<sup>8</sup> Optic atrophy is the most common ophthalmologic finding in these patients. Additional features include mainly color blindness and cataract.<sup>9</sup> The findings in our patient support this. MRI scan of the brain showed findings suggestive of generalized atrophy of cortex, brainstem, and cerebellum. This is in concurrence with the MRI findings in the previously studied cases of WS.<sup>5</sup> In comparison with the previous MRI scans of the patient, the current MRI scan revealed further progression of the neurological findings. Ultrasound of the genitourinary system showed bilateral hydronephrosis and hydroureters. Dilatation of the urinary tract could be attributed to the volume overload as a result of diabetes insipidus.<sup>8</sup> Pure tone audiometry was normal, and deafness was ruled out. However, deafness had a prevalence of only 62% in studies conducted earlier, and its absence does not alter the diagnosis. Acute psychotic episodes and attempts at suicide, as in our patient, are well documented in previous studies. Other possible manifestations may include paranoid delusions, progressive dementia, depression, hallucinations, and violent behavior.<sup>10</sup> Patients with this disorder have a reduced lifespan, with the median age of death being 30 years. Common causes of mortality are the complications of diabetes mellitus, respiratory failure, recurrent infections, status epilepticus, and suicide due to endogenous depression.<sup>8</sup>

Pregnancy in WS has been a rarity. Only five cases have been reported worldwide. Successful pregnancy in WS has not been reported from India so far. It is rare because of the menstrual irregularities and abnormal functioning of the hypothalamo-pituitary-ovarian axis.<sup>8</sup> The diabetes insipidus seemed to have mounted a stiff challenge to efficient management of the antenatal and postpartum periods in previously reported cases.<sup>1</sup> Our patient has been on regular desmopressin since the age of 25 years, and her diabetes insipidus remained stable during the antenatal period, ensured by close follow-up of her electrolyte status and osmolality. For better control of her blood glucose levels, she was initially put on multiple daily injections of insulin. Despite regular modifications in the insulin dosages, dietary regulations, and exercise, her HbA1c never came below 7%. During this period, she was visibly enthusiastic in regular self-monitoring of blood glucose and administering extra boluses of rapid-acting insulin based on the sugar values. Her willingness to monitor blood sugar and self-management skills were encouraging signs for family members and the team associated with Diabetes Tele Management System (DTMS<sup>®</sup>). At this juncture, she appeared to be an appropriate candidate for pump therapy, the option of using an insulin pump was discussed, and she seemed to be receptive to this modality.<sup>11</sup> Under the comprehensive care level, as recommended by the Interna-

tional Diabetes Federation, for patients with pregnancy and antecedent diabetes, insulin delivery might be optimized by the use of CSII.<sup>12</sup> She belonged to a higher socioeconomic status, was a postgraduate by education, and was very well acquainted with the use of electronic media, gadgets, and computers. Moreover, the center has adequately trained and certified pump trainers to back the dedicated 24-h helpline of the DTMS<sup>®</sup>. The blood sugar during the antenatal period was also efficiently managed through CSII, and it considerably enhanced her quality of life and overall well-being. Considering the unstable nature of the blood glucose levels, its wide excursions, and the detrimental effects it could pose for the growing fetus, we would like to emphasize the importance of using an insulin pump for the management of diabetes mellitus during pregnancy.<sup>13</sup> Her husband and relations at home were helping her throughout with her insulin pump, and this supportive mechanism ensured continuing success with CSII.

In a real-life study published recently, 46 type 2 diabetes subjects using multiple daily injections when switched over to CSII for 6 months reported not only significant reduction in HbA1c levels but also improvement in quality of life. After 6 months of CSII, 83% of subjects noted an improvement in sexual function as opposed to when they were using multiple daily injections. With respect to peripheral neuropathic pain, 87% of subjects reported that they experienced significant reduction in pain after initiation of CSII.<sup>14</sup> This probably indicates the influence of CSII on mean amplitude of glycemic excursions, an action not to be expected with conventional insulin shots.

Four years postpartum, she is still on CSII. Because WS is a progressive neurodegenerative disorder, this case report will probably help us understand the positive impact of CSII in prolonging the life span and retarding neuronal damage in WS.

## Conclusions

We propose that in any case of childhood-onset diabetes mellitus with associated optic atrophy, before the age of 15 years, the possibility of WS should be considered. Females with WS can give birth to healthy babies provided the diabetes mellitus, diabetes insipidus, and associated disorders are intensively monitored and aggressively managed. The successful outcome with insulin pump therapy over a 5-year period in WS provides an opportunity to understand the benefits of CSII in retarding the progression of neurodegenerative changes and possibly longevity beyond the usual glycemic control.

## Acknowledgments

We thank Jayasree Lally, Diabetes Tele Management Officer of Jothydev's Diabetes & Research Center, Trivandrum, Kerala, India, who helped us with the care and evaluation of the subject.

## Author Disclosure Statement

J.K. wrote the manuscript and researched data, A.K. wrote the manuscript, A.S. contributed to the discussion, G.G. reviewed and edited the manuscript, M.A.P. contributed to the discussion and reviewed and edited the manuscript, J.W. contributed to the discussion and reviewed and edited the manuscript, and S.J. contributed to the discussion.

## References

1. Rugolo S, Mirabella D, Palumbo MA, Chiantello R, Fiore G: Complete Wolfram's syndrome and successful pregnancy. *Eur J Obstet Gynecol Reprod Biol* 2002;105:192–193.
2. Kesavadev J, Das AK, Unnikrishnan R 1<sup>st</sup>, Joshi SR, Ramachandran A, Shamsudeen J, Krishnan G, Jothydev S, Mohan V: Use of insulin pumps in India: suggested guidelines based on experience and cultural differences. *Diabetes Technol Ther* 2010;12:823–831.
3. Kesavadev J, Shankar A, Shamsudeen J, Dinkar G, Pillai PBS, Gopalakrishnan G, Ajai N, Sathish J, Jothydev S: Telefollow up and SMBG via "DTMS"—a cost effective tool for A1c lowering [abstract]. *Diabetes* 2010;59(Suppl 1):A546. [professional.diabetes.org/Abstracts\\_Display.aspx?TYP=1&CID=80992](http://professional.diabetes.org/Abstracts_Display.aspx?TYP=1&CID=80992) (accessed October 29, 2010).
4. Sunder JH, Danowski TS, Kenny FM, Khurana RC, Sun A, Nolan S, Stephan T: Pedigrees with diabetes insipidus, diabetes mellitus, and optic atrophy. *J Med Genet* 1972;9:408–412.
5. Minton JAL, Rainbow LA, Ricketts C, Barrett TG: Wolfram syndrome. *Rev Endocr Metab Disord* 2003;4:53–59.
6. d'Annunzio G, Minuto N, D'Amato E, de Toni T, Lombardo F, Pasquali L, Lorini R: Wolfram syndrome (diabetes insipidus, diabetes, optic atrophy, and deafness): clinical and genetic study. *Diabetes Care* 2008;31:1743–1745.
7. Inoue H, Tanizawa Y, Wasson J, Behn P, Kalidas K, Bernal-Mizrachi E, Mueckler M, Marshall H, Donis-Keller H, Crock P, Rogers D, Mikuni M, Kumashiro H, Higashi K, Sobue G, Oka Y, Permutt MA: A gene encoding a transmembrane protein is mutated in patients with diabetes mellitus and optic atrophy (Wolfram syndrome). *Nat Genet* 1998;20:143–148.
8. Barrett TG, Bunday SE, Macleod AF: Neurodegeneration and diabetes: UK nationwide study of Wolfram (DIDMOAD) syndrome. *Lancet* 1995;346:1458–1463.
9. Al-Till M, Jarrah NS, Ajlouni KM: Ophthalmologic findings in fifteen patients with Wolfram syndrome. *Eur J Ophthalmol* 2002;12:84–88.
10. Hildebrand MS, Sorensen JL, Jensen M, Kimberling WJ, Smith RJ: Autoimmune disease in a DFNA6/14/38 family carrying a novel missense mutation in WFS1. *Am J Med Genet A* 2008;146A:2258–2265.
11. Pickup JC, Keen H, Viberti GC, Bilous RW: Patient reactions to long-term outpatient treatment with continuous subcutaneous insulin infusion. *Br Med J (Clin Res Ed)* 1981;282:766–768.
12. IDF Clinical Guidelines Task Force: Global guideline for type 2 diabetes: recommendations for standard, comprehensive, and minimal care. *Diabet Med* 2006;23:579–593.
13. Lapolla A, Dalfrà MG, Masin M, Bruttomesso D, Piva I, Crepaldi C, Tortul C, Dalla Barba B, Fedele D: Analysis of outcome of pregnancy in type 1 diabetics treated with insulin pump or conventional insulin therapy. *Acta Diabetol* 2003;40:143–149.
14. Kesavadev J, Balakrishnan S, Ahammed S, Jothydev S: Reduction of glycosylated hemoglobin following 6 months of continuous subcutaneous insulin infusion in an Indian population with type 2 diabetes. *Diabetes Technol Ther* 2009;11:517–521.

Address correspondence to:

*Jothydev Kesavadev, M.D.*

*CEO and Director*

*Jothydev's Diabetes & Research Center*

*JDC Junction, Konkalam Road*

*Mudavannugal*

*Trivandrum-695032, Kerala, India*

*E-mail: jothydev@gmail.com*

*Website: www.jothydev.net*

