

## DUPLEX DOPPLER SONOGRAPHIC ASSESSMENT OF THE EFFECTS OF DIETHYLCARBAMAZINE AND ALBENDAZOLE THERAPY ON ADULT FILARIAL WORMS AND ADJACENT HOST TISSUES IN BANCROFTIAN FILARIASIS

OMAR HUSSEIN, MAGED EL SETOUHY, EHAB S. AHMED, AMR M. KANDIL, REDA M. R. RAMZY, HANAN HELMY, AND GARY J. WEIL

*Department of Radiology, Department of Community, Environmental, and Occupational Medicine, and Research and Training Center on Vectors of Diseases, Faculty of Medicine, Ain Shams University, Cairo, Egypt; Infectious Diseases Division, Department of Internal Medicine, Washington University School of Medicine, St. Louis, Missouri*

**Abstract.** We used duplex Doppler sonography to assess effects of diethylcarbamazine and albendazole therapy (DEC/ALB) on adult *Wuchereria bancrofti* *in vivo*. The study was performed in clinically normal Egyptian adults with blood microfilaria counts > 80/mL. Motile adult worms were observed before treatment in dilated scrotal lymphatic vessels in 28 of 36 men (78%) and over the proximal extremities in 5 of 22 women (23%). Most worm nests were inactivated in the months following treatment (90% at 12 months). Circulating filarial antigen levels (a marker for living adult worms) also fell dramatically following treatment. Some men had intrascrotal calcifications and/or non-palpable hydroceles detectable by ultrasound before they were treated. New hydroceles and intrascrotal calcifications appeared after treatment in many cases. However, most of these were transient and of no clinical significance. Prevalence rates for hydrocele and intrascrotal calcifications 24 months after treatment were essentially the same as those prior to treatment. These results show that DEC/ALB is highly active against adult *W. bancrofti*. They also suggest that host responses to dying adult worms are important in the pathogenesis of filarial hydroceles.

### INTRODUCTION

Bancroftian filariasis is a deforming and disabling disease caused by the filarial nematode *Wuchereria bancrofti*. The most common clinical manifestations of the disease are hydrocele, lymphedema, and elephantiasis. This parasite affects approximately 100 million people in some 80 countries, mostly in the developing world.<sup>1</sup> Technical advances in diagnosis and treatment led to initiation of a Global Program for Elimination of Lymphatic Filariasis (reviewed by Ottesen and others<sup>2</sup> and Molyneux and others<sup>3</sup>). This program comprises mass drug administration (MDA) of anthelmintics to populations residing in endemic areas to reduce transmission of the parasite and provision of care and services to people already affected by the disease. The chemotherapy side of the program calls for MDA to a target population of 1.2 billion people by the year 2020. The recommended MDA regimen for all areas outside of sub-Saharan Africa is DEC/ALB (a single, oral dose of diethylcarbamazine, 6 mg/kg, and albendazole, 400 mg once per year for 4–5 years). Clinical studies have shown that single-dose DEC/ALB treatment is safe and effective for reducing blood microfilaria (MF) counts for up to two years.<sup>4–6</sup> Results from these trials also suggest that DEC/ALB has partial activity against adult filarial worms; circulating filarial antigen levels decreased following single-dose DEC/ALB, and some treated subjects developed scrotal pain and/or subcutaneous nodules that are believed to result from dying adult worms.<sup>4,5</sup> However, more information is needed on effects of DEC/ALB on adult filarial worms and on local reactions associated with worm death.

The recognition that medical ultrasound can be used to visualize adult *W. bancrofti* *in vivo* represented a major advance in the field of filariasis.<sup>7</sup> Brazilian investigators coined the term “filarial dance sign” to describe the ultrasound appearance of motile adult filarial worms in dilated lymphatic vessels in the scrota of infected men. Early studies showed that the location of worm nests is highly stable in individual subjects over time.<sup>8</sup> Ultrasound can also be used to monitor effects of treatment on adult filarial worms; one study re-

ported complete inactivation of 41.5% of worm nests following a 10-day course of treatment with DEC.<sup>9</sup> Other studies reported the presence of subclinical pathology (intrascrotal calcifications and subclinical hydroceles) in asymptomatic men with normal clinical examinations<sup>10,11</sup> and changes in these findings following treatment with DEC.<sup>10</sup> Faris and others also emphasized the value of using color pulsed-Doppler to distinguish movement associated with filarial worms from that associated with the flow of blood in arteries and veins.<sup>10</sup> Mand and others concurred with this opinion and posted video clips illustrating ultrasound findings in African subjects with Bancroftian filariasis.<sup>12</sup>

We have recently reported results of a clinical trial that compared single-dose DEC/ALB with seven daily doses of the same medications.<sup>13</sup> We found that multi-dose therapy was more effective than single-dose treatment in reducing and clearing microfilaremia from the blood of infected subjects. That report also briefly summarized results of ultrasound studies performed as part of the clinical trial. We now present a detailed report on ultrasound results from the clinical trial, with follow-up extending to 24 months after treatment. This study provided important new information on the effects of DEC/ALB on adult *W. bancrofti* and on the appearance and evolution of local pathology associated with adult worms following treatment.

### METHODS

**Patient selection.** This project was performed as part of a study of treatment of asymptomatic *W. bancrofti* infections in Egyptian subjects. The methods used and results of this trial have been published in detail.<sup>13</sup> Briefly, asymptomatic adults with night blood MF counts > 80 MF/mL were invited to participate in the study. Subjects with evidence of clinical filariasis by physical examination (hydrocele or lymphedema) or a history of treatment for filariasis in the prior 12 months were excluded from the study, as were pregnant or lactating women.

**Randomization and therapy.** Eligible subjects were randomly assigned to treatment groups with block stratification for sex and blood MF count. The trial was not blinded. Study subjects were treated with either a single oral dose of 6 mg/kg of DEC citrate (Pharmamed, Zejtun, Malta) plus 400 mg of ALB (GlaxoSmithKline, Uxbridge, United Kingdom) or with the same medications daily for seven days. Treatment was directly observed by study personnel. All subjects were re-treated with a single oral dose of DEC (6 mg/kg) and ALB (400 mg) one year after the first round of treatment.

**Tests for *W. bancrofti* infection.** Venous blood samples were collected between the hours of 9:00 PM and 1:00 AM before and after treatment for parasitology and serology studies. Microfilariae were detected by membrane filtration (5  $\mu$ M; Nuclepore Corp., Pleasanton, CA) of 1 mL of venous blood and microscopic examination of stained filters. Filarial antigenemia, a marker for adult worm infection intensity, was detected in plasma samples by enzyme immunoassay as previously described in detail.<sup>14</sup>

**Ultrasound methods.** Effects of therapy on adult worms were directly assessed by duplex Doppler sonography. All examinations were performed by one experienced sonologist with an ultrasound instrument equipped with a linear phased array color Doppler transducer (270 SSD Color Doppler, 6 cm linear transducer, 5–7.5 MHz; Toshiba, Tokyo, Japan) as previously described.<sup>10</sup> Inguinal and axillary regions and upper arms and thighs were examined in men and women. Scrotum examinations were performed in men, and breasts were examined in women. Complete ultrasound examinations were performed shortly before treatment and at 3, 6, 12, 18, and 24 months after treatment. Abnormal ultrasound findings were recorded and photographed. Color flow mapping with pulsed Doppler was used to distinguish the bidirectional movements of adult filarial worms in dilated lymphatic vessels (dancing worms) from unidirectional blood flow in veins and arteries. The diagnosis of hydrocele by ultrasound was based on the presence of fluid ( $\geq 2$  mm thickness) surrounding the testis and epididymis.<sup>15</sup> Subclinical hydroceles were detectable by ultrasound but not by palpation.

The sonologist studied subjects blindly, without knowing their treatment assignments. Post-treatment examinations were first performed without knowledge of prior findings. Subjects were then re-examined with special attention to areas with abnormalities seen in earlier examinations. Ultrasound findings after treatment were compared with pretreatment results to evaluate loss of motile filarial worms. The primary endpoint for this study was predefined to be loss of all motile worms in subjects who had motile worms before

therapy. The secondary endpoint was the percent decrease (by group) in the number of worm nests observed with motile adult filarial worms.

**Data analysis.** Database management and statistical analyses were performed with a statistical software package (SPSS, Chicago, IL). Proportions were compared by chi-square analysis or Fisher's exact test (two-tailed). The Mann-Whitney U test was used to assess the significance of group differences for continuous variables.

**Ethical clearance.** This study was reviewed and approved by institutional review boards at Ain Shams University and at Washington University School of Medicine. Written informed consent was required for participation in the study.

## RESULTS

**Pretreatment evaluation.** Pretreatment data in Table 1 show that the two treatment groups were generally comparable in terms of infection intensities and pre-treatment ultrasound findings, although filarial antigen levels were significantly higher in the multi-dose treatment group.

Motile filarial worms were observed before therapy in 28 of 36 men (78%) and in 5 of 22 women (23%). All dancing worms in men were observed in dilated lymphatic vessels within the scrotum (Figure 1). Approximately equal percentages of worm nests were seen on the right and left sides of the scrotum (46 and 54%, respectively). Fifty-eight percent (36) of the nests were located in lymphatic vessels adjacent to the upper pole of the testis, 39% (24) in the lower pole, and 3% (2) in the midzone. The number of nests identified in positive male subjects ranged from 1 to 6 (mean  $\pm$  SD = 2.3  $\pm$  1.4, median = 2). Subclinical intrascrotal pathology was common in untreated men (Figure 1); 56% had subclinical hydroceles (not palpated by examiners) and 50% had intrascrotal calcifications. All dancing worms observed in women were located in dilated superficial lymphatic vessels over the proximal extremities (left inguinal area in three women and over the proximal anterior left arm in two women) (Figure 2). Only one worm nest was observed in each of the women with nests identified by ultrasound. Intra-lymphatic calcifications were seen in 4 of 22 women (16.7%).

There was no significant difference in mean MF counts or parasite antigen levels between subjects with and without visible motile worms, and there was no significant correlation between the number of nests identified by ultrasound and either blood MF count or filarial antigen level in the total study population. However, when the analysis was restricted to males, these parameters were related, but the correlations

TABLE 1  
Pretreatment comparison of treatment groups\*

Parameter	Single-dose group	Multi-dose group	P
Age, years, mean (SD)	36.7 (16.1)	30.4 (10.5)	0.14†
Sex	18 M, 10 F	18 M, 12 F	0.95‡
MF/mL, median (range)	344 (90–3,720)	348 (100–4,431)	0.72†
Filarial antigenemia, median (range)	76.2 (13–1,248)	178.2 (14–1994)	0.04†
Motile adult worms by US	16/28 (57.1%)	17/30 (56.7%)	0.97‡
Lymphatic calcifications	10/28 (37%)	10/30 (33%)	0.93‡
Subclinical hydrocele (men)	10/18 (56%)	10/18 (56%)	1.0‡

\* MF = microfilariae; US = ultrasound.

† By Mann-Whitney test.

‡ By chi-square test.

were not quite statistically significant (MF counts versus nests,  $r = 0.30$ ,  $P = 0.08$ ; antigen levels versus nests,  $r = 0.31$ ,  $P = 0.06$ ). Interestingly, men with subclinical hydroceles pre-treatment had significantly fewer worm nests than men without hydroceles (mean  $\pm$  SD =  $0.9 \pm 0.8$  versus  $2.9 \pm 1.7$ ;  $P < 0.001$ ). However, age, MF counts, and filarial antigen levels were not significantly different in men with and without sub-clinical hydroceles before treatment.

**Ultrasound assessment of the effects of DEC/ALB treatment on adult *W. bancrofti*.** Adult worm nest locations were stable in repeated examinations after treatment; some of the nests disappeared only after many months. With one or two exceptions, no nests were seen on post-treatment examinations that were not observed in the same locations prior to treatment.

Motile adult filarial worms were greatly decreased following therapy in men and women and in both treatment groups. In some cases with persistent motile worms, the frequency of movement and amplitude of pulsed Doppler traces were decreased following treatment. The ultrasound appearance of nests after treatment varied from nest to nest and also changed over time. In some cases, motile worms were replaced after treatment by small, non-motile echodense objects within dilated lymphatic vessels. Calcifications appeared in locations formerly occupied by motile worms in some cases. Lymphatic vessel dilation persisted in some cases, but dilatation completely resolved in other cases.

Table 2 shows categorical data on total inactivation of worm nests by subject (the predefined primary endpoint for

the study). Multi-dose treatment was more effective at three months, but there was no significant difference between the treatment groups at later time points. Twenty-three of 25 subjects with worm nests visible before treatment had complete inactivation of all worm nests 24 months after treatment (12 months after the second round of treatment).

Quantitative data on inactivation of adult worm nests are shown in Figure 3. This was a pre-defined secondary endpoint of the study. Differences between the two treatment groups were not statistically significant. For all subjects (both groups combined), 91%, 90%, and 97% of the worm nests observed in study subjects prior to treatment were inactive by 6, 12, and 24 months following therapy, respectively. The filarial antigen test provides a second means of monitoring survival of adult worms following treatment. There was no significant difference in clearance of antigenemia between the two treatment groups. Mean  $\pm$  SD antigen levels were reduced from pre-treatment levels by  $84.3 \pm 9.5\%$  and  $91.1 \pm 7.2\%$  at 12 and 24 months after treatment, respectively. Total clearance of filarial antigenemia was observed in 30% and 50% of subjects 12 and 24 months after treatment, respectively.

**Ultrasound assessment of changes in scrotal tissues following DEC/ALB treatment.** Ultrasound findings in men before and after treatment are summarized in Table 3, and cases are shown in Figures 4–6. Subclinical hydroceles and intrascrotal calcifications were increased after treatment in both groups, but both of these parameters returned toward pre-treatment levels at later time points. There was no significant difference

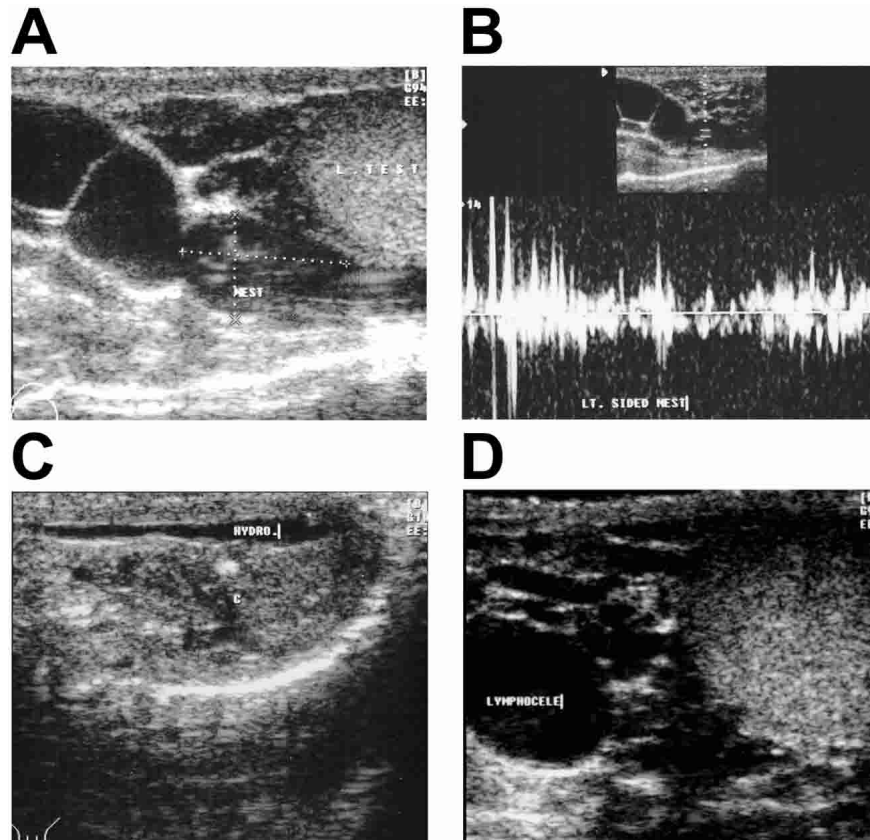


FIGURE 1. Composite of scrotal ultrasound findings in different men before therapy. **A**, Tortuous, dilated lymphatic vessel with septations, adjacent to the left testicle. The location of a nest with motile filarial worms is marked. **B**, Pulsed Doppler trace of a dancing worm. **C**, Intrascrotal calcification. **D**, Small, complex hydrocele with lymphocele.

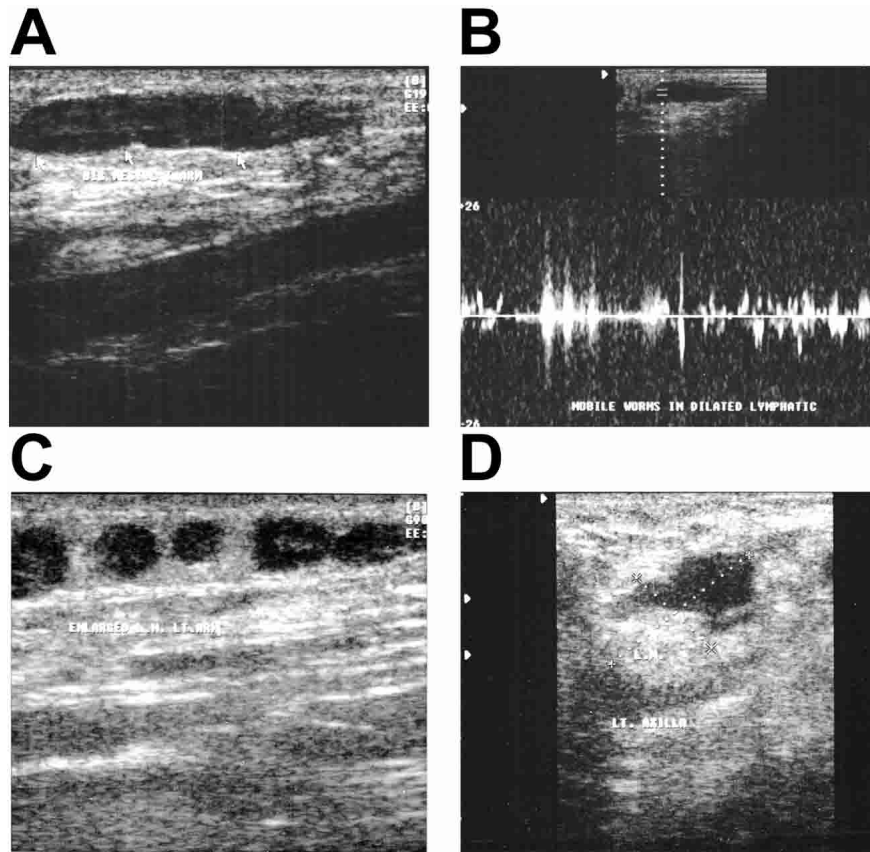


FIGURE 2. Large dilated lymphatic vessel with a worm nest (A) and a pulsed Doppler trace (B) taken over the proximal arm of a 19-year-old woman. The pulsed Doppler trace demonstrates bidirectional flow consistent with a filarial worm nest. The other panels show enlarged lymph nodes adjacent to subcutaneous fat in the proximal arm (C) and axilla (D) of the same subject.

in the rates of development of hydroceles or calcifications between the two treatment groups. Fourteen of 16 men without hydroceles prior to treatment developed hydroceles detectable by ultrasound following treatment. These were often transient, but they persisted to 24 months in some cases; three men in this group had small palpable hydroceles 24 months after treatment. Some men with subclinical hydroceles before treatment had worsening of this finding following treatment. However, this was often transient, and some men (5 of 16) with pretreatment subclinical hydroceles had resolution of this finding 24 months after the first round of treatment.

#### DISCUSSION

The main objectives of this study were to use duplex Doppler sonography to document effects of DEC/ALB on adult *W. bancrofti* and to document effects of treatment on the

appearance and evolution of local pathology associated with adult worms. However, our pre-treatment observations are interesting in their own right; high proportions of male subjects in the study had motile adult worms, intrascrotal calcifications, and subclinical hydroceles visible by ultrasound prior to treatment. These results confirm and expand on results previously reported by our group.<sup>10</sup> Motile worms were also observed in 5 of 22 women studied. This is the first report of motile worms over the proximal extremities and lymphatic vessel calcifications in women with filariasis. Most prior studies of ultrasound in filariasis have focused on men. While dancing worms have been observed in girls,<sup>16</sup> they have been only rarely reported in women; one study reported the presence of a single worm nest (in the breast) in only 1 of 18 microfilaremic women studied in Brazil.<sup>17</sup> No breast lesions were observed in the present study.

TABLE 2

Complete inactivation of adult filarial worms as assessed by ultrasound following diethylcarbamazine/albendazole (DEC/ALB) treatment, by treatment group\*

	Pre-Rx	3 Mo	6 Mo	12 Mo	18 Mo	24 Mo
Single dose	0/16 (0%)	7/16 (44%)	11/15 (73%)	12/15 (75%)	12/14 (86%)	12/13 (92%)
Multidose	0/17 (0%)	15/17 (88%)	13/15 (87%)	12/14 (86%)	10/12 (83%)	11/12 (92%)
Combined	0/33 (0%)	22/33 (67%)	24/30 (80%)	24/29 (83%)	22/26 (85%)	23/25 (92%)
<i>P</i>		<0.01†	NS‡	NS‡	NS‡	NS‡

\* Subjects were treated with single-dose or multi-dose DEC/ALB at time zero and re-treated with single-dose DEC/ALB 12 months (Mo) later. Data shown are for subjects with motile worms observed before treatment. *P* values are for differences between treatment groups. Pre-Rx = pretreatment; NS = not significant.

† By chi-square test.

‡ By Fisher's exact test.

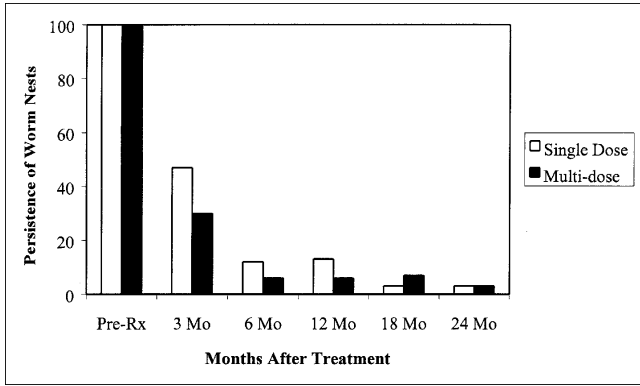


FIGURE 3. Persistence of filarial worm nests (percent of all motile nests observed pretreatment remaining motile) after treatment, by treatment group. Subjects were treated with single or multi-dose diethylcarbamazine/albendazole (DEC/ALB) at time zero and re-treated with single dose of DEC/ALB 12 months (Mo) later. Data shown are for subjects with motile worms observed before treatment. Group differences were not statistically significant (by Mann-Whitney U test).

The absence of motile worms detectable by ultrasound in some infected men and most women and the weak correlation between the number of worm nests observed and circulating filarial antigen levels in men (with no relationship at all in women) suggest that ultrasound only detects a minority of adult worms in filariasis patients. We can only speculate on where the rest of the worms reside. We found that subjects with subclinical hydroceles prior to treatment had significantly fewer adult worm nests than subjects without hydroceles. This is consistent with findings in our prior study, which found that dancing worms were uncommon in subjects with palpable hydroceles.<sup>10</sup> Results from both studies are consistent with the hypothesis that death of adult filarial worms is important in the pathogenesis of filarial hydroceles.

Tobian and others have recently reported that age and filarial antigen levels were significantly correlated with the presence of hydroceles in untreated men in Papua New Guinea.<sup>11</sup> Our results did not confirm those findings. However, the Papua New Guinea study was population-based and included amicrofilaremic men and men with palpable hydroceles, while our study was limited to clinically normal subjects with MF counts > 80/mL.

Ultrasound studies documented dramatic effects of DEC/ALB therapy on adult filarial worms and host anatomy. As

previously reported, the location of worm nests was stable over time.<sup>8</sup> Most adult worms were killed by both of the treatment regimens studied, with no significant difference between them. Filarial antigen data also suggested that DEC/ALB treatment killed most adult filarial worms. Prior studies have reported that therapy with DEC alone completely inactivated 41.5% of filarial worm nests (as assessed by ultrasound)<sup>9</sup> and reduced filarial antigen levels by 40% 12 months after single dose treatment<sup>18</sup> and by 50–70% after multi-dose treatment.<sup>19,20</sup> Our results (90% inactivation of worm nests and 84% reduction in filarial antigen levels 12 months after treatment) suggest that DEC/ALB may be more effective against adult *W. bancrofti* than DEC alone. However, it is risky to compare results obtained in trials conducted at different times and in different endemic areas. A new clinical trial of DEC alone versus DEC/ALB would be required to directly test this hypothesis.

Ultrasound studies showed that DEC/ALB treatment also had dramatic effects on host anatomy, especially in men. Many men developed new hydroceles and/or intrascrotal calcifications following treatment. Most of these changes were subclinical, but new hydroceles were palpable and persistent in some cases. In addition, some men with subclinical hydroceles prior to treatment had worsening of their hydroceles following treatment. We previously reported development of hydroceles and calcifications in men following DEC treatment.<sup>10</sup> We have no evidence that DEC/ALB treatment causes more severe clinical or subclinical scrotal reactions than DEC alone. However, this could be the case if DEC/ALB is more lethal to adult worms than DEC monotherapy.

The appearance of new hydroceles and intrascrotal calcifications following treatment suggests that inflammatory responses associated with the death of adult filarial worms (with local release of parasite antigens and intracellular *Wolbachia* endosymbiotic bacteria)<sup>21</sup> may be involved in the pathogenesis of filarial hydroceles. Thus, DEC/ALB treatment may accelerate natural processes that lead to hydroceles and intrascrotal calcifications. The presence of calcifications in some subjects prior to treatment is consistent with this hypothesis. There is no doubt that treatment benefited subjects by clearing their adult worms, and some subjects had resolution of subclinical hydroceles present at baseline following therapy. However, treatment was also associated with costs in some subjects in the form of systemic adverse events (usually mild and transient)<sup>13</sup> and local pathology (usually subclinical and innocuous). We do not consider these adverse events to

TABLE 3

Ultrasound assessment of changes in hydrocele and scrotal calcification rates in men following diethylcarbamazine/albendazole (DEC/ALB) treatment, by treatment group\*

	Pre-Rx	3 Mo	6 Mo	12 Mo	18 Mo	24 Mo
<b>Hydroceles</b>						
Single dose	10/18 (56%)	18/18 (100%)	11/17 (65%)	10/16 (63%)	7/14 (50%)	9/14 (64%)
Multi dose	10/18 (56%)	16/18 (89%)	12/17 (71%)	8/16 (50%)	10/15 (67%)	5/15 (33%)
Combined	20/36 (56%)	34/36 (94%)	23/34 (68%)	18/32 (56%)	17/29 (59%)	14/29 (48%)
<b>Calcifications</b>						
Single dose	8/18 (44%)	11/18 (61%)	16/17 (94%)	13/16 (81%)	10/14 (71%)	8/14 (57%)
Multi dose	10/18 (56%)	13/18 (72%)	13/17 (77%)	10/16 (63%)	9/15 (60%)	7/15 (47%)
Combined	18/36 (50%)	24/36 (67%)	29/34 (85%)	23/32 (72%)	19/29 (66%)	15/29 (52%)

\* Subjects were treated with single-dose or multi-dose DEC/ALB at time zero and re-treated with single-dose DEC/ALB 12 months (Mo) later. Group differences were not statistically significant at any time point. Hydrocele frequency in the combined groups was significantly increased over baseline three months after treatment ( $P < 0.001$ ). The frequency of scrotal calcifications was significantly increased six months after treatment ( $P = 0.04$ ). Pre-Rx = pretreatment.

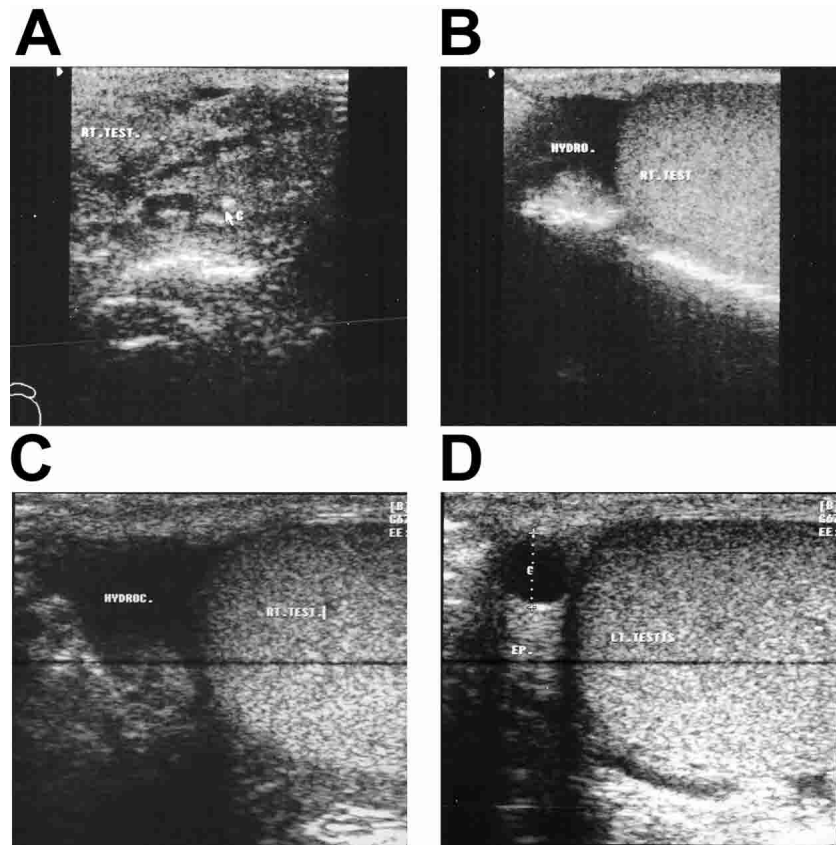


FIGURE 4. This subject had six motile worm nests detected by ultrasound prior to treatment with no hydrocele or calcification. He developed scrotal discomfort following treatment. Shown are post-treatment findings of a new calcification that developed three months after treatment (A), a new hydrocele in the right scrotum three months (B) and 18 months following treatment (C), and a left-sided epididymal cyst that developed after treatment (D). Interestingly, the right-sided hydrocele in this patient was no longer present at 24 months (not shown in the Figure).

be sufficiently severe to outweigh the benefits of MDA, which is a valuable tool for filariasis elimination programs. However, program managers need to be aware that these reactions can occur. Reaction rates are likely to be more common in areas with high infection prevalence rates and high infection intensities.

In summary, our study confirmed the value of duplex Doppler sonography for non-invasively visualizing adult

*W. bancrofti* and for monitoring effects of antifilarial treatment. Therapy with DEC/ALB appears to be highly effective for killing adult *W. bancrofti* (approximately 90% at 12 months). This treatment was often followed by *de novo* development of hydroceles (and worsening of hydroceles already present before treatment in some cases). These results support the hypothesis that dying adult worms are important in the pathogenesis of filarial hydroceles.

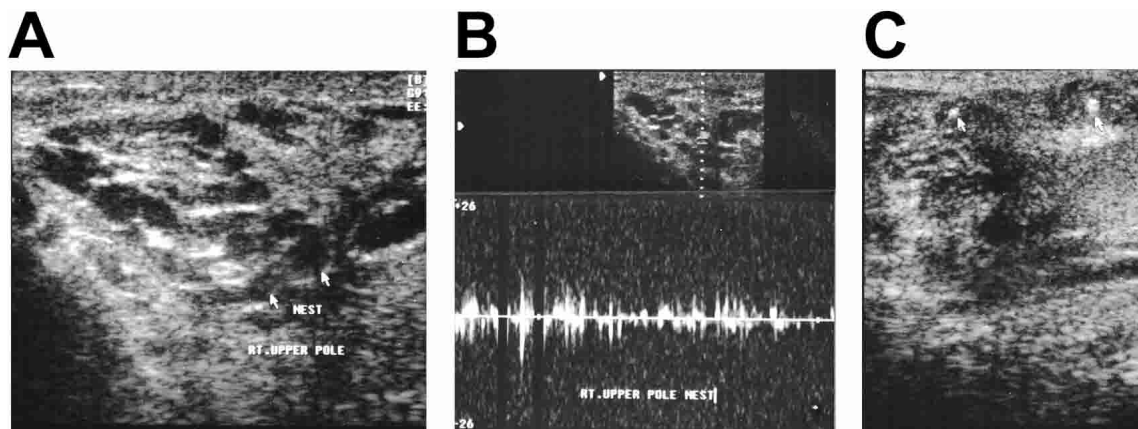


FIGURE 5. Pretreatment ultrasound appearance (A) and pulsed Doppler tracing (B) from a man with lymphatic vessel dilation and several filarial nests identified at the upper pole of the right testis. This subject experienced scrotal discomfort one week after treatment. C, Intrascrotal calcifications and decreased lymphatic vessel dilation in this area 12 months after treatment with diethylcarbamazine/albendazole.

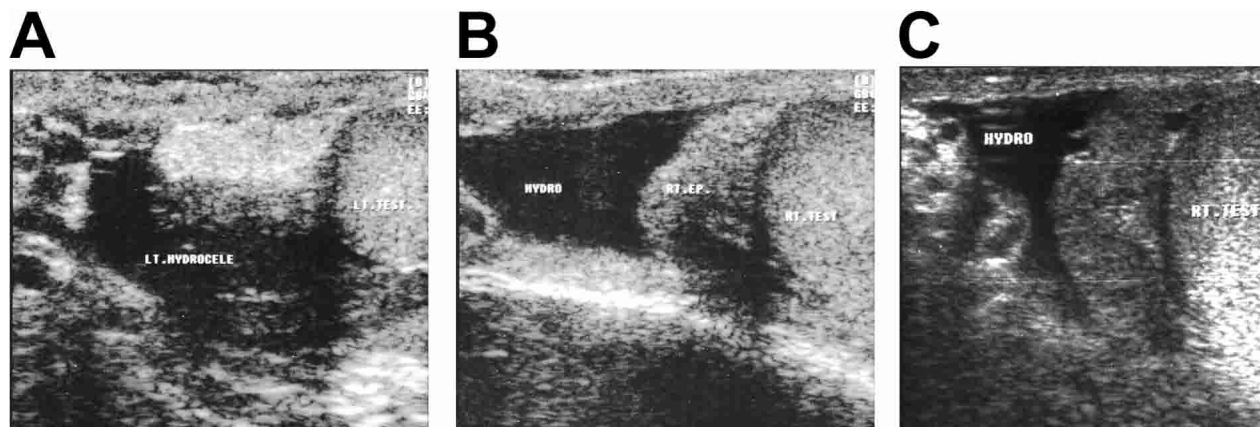


FIGURE 6. This subject had five filarial worm nests but no hydrocele or calcifications prior to treatment. He developed scrotal discomfort following treatment. Shown are bilateral hydroceles present three months after treatment (A and B). The hydroceles were smaller but still present 24 months after treatment (C).

Received April 15, 2004. Accepted for publication June 16, 2004.

**Acknowledgments:** We are grateful for technical assistance provided by the field research teams and laboratory staff at the Research and Training Center on Vectors of Diseases at Ain Shams University. The late Professor Rifky Faris helped to plan this study.

**Financial support:** This work was supported by National Institutes of Health grant AI-35855.

**Authors' addresses:** Omar Hussein and Maged El Setouhy, Faculty of Medicine, Ain Shams University, Abbassia, Cairo, Egypt. Telephone and Fax: 20-2-683-9622. Ehab S. Ahmed, Amr M. Kandil, Reda M. R. Ramzy, and Hanan Helmy, Research and Training Center on Vectors of Diseases, Faculty of Science Building, Ain Shams University, Abbassia, Cairo, Egypt, Telephone and Fax: 20-2-6839622. Gary J. Weil, Infectious Diseases Division, Department of Internal Medicine, Washington University School of Medicine, Campus Box 8051, 660 South Euclid Avenue, St. Louis, MO 63110, Telephone: 314-454-7782, Fax: 314-454-5293, E-mail: gweil@im.wustl.edu.

## REFERENCES

1. Michael E, Bundy DA, Grenfell BT, 1996. Reassessing the global prevalence and distribution of lymphatic filariasis. *Parasitology* 112: 409-428.
2. Ottesen EA, Duke BO, Karam M, Behbehani K, 1997. Strategies and tools for the control/elimination of lymphatic filariasis. *Bull World Health Organ* 75: 491-503.
3. Molyneux D, Neira M, Liese B, Heymann D, 2001. Elimination of lymphatic filariasis as a public health problem: setting the scene for elimination. *Trans R Soc Trop Med Hyg* 94: 589-591.
4. Ismail MM, Jayakody RL, Weil GJ, Nirmalan N, Jayasinghe KS, Abeyewickrema W, Sheriff MH, Rajaratnam HN, Amarasekera N, de Silva DC, Michalski ML, Dissanaikie AS, 1998. Efficacy of single dose combinations of albendazole, ivermectin, and diethylcarbamazine for the treatment of bancroftian filariasis. *Trans R Soc Trop Med Hyg* 92: 94-97.
5. Ismail MM, Jayakody RL, Weil GJ, Fernando D, de Silva MSG, Balasooriya WK, 2001. Long-term efficacy of single-dose combinations of albendazole, ivermectin, and diethylcarbamazine for the treatment of lymphatic filariasis. *Trans R Soc Trop Med Hyg* 95: 332-335.
6. Horton J, Ottesen E, Lazdins J, Addiss D, Awadzi K, Beach M, Belazario V, Dunyo S, Espinel M, Gyapong J, Hossain M, Ismail M, Jayakody R, Lammie P, Makunde W, Richard-Abenoble D, Selve B, Shenow R, Simonsen P, Wamae C, Weerasooriya M, 2000. An analysis of the safety of the single dose, two drug regimens used in programmes to eliminate lymphatic filariasis. *Parasitology* 121: S147-S160.
7. Amaral F, Dreyer G, Figueredo-Silva JN, Cavalcanti A, Samico SC, Santos A, Coutino A, 1994. Live adult worms detected by ultrasound in human bancroftian filariasis. *Am J Trop Med Hyg* 50: 753-757.
8. Dreyer G, Addiss D, Roberts J, Noroes J, Medeiros Z, 1994. Ultrasonic evidence for stability of adult worm location in bancroftian filariasis. *Trans R Soc Trop Med Hyg* 88: 558.
9. Noroes J, Dreyer G, Santos A, Mendes VG, Medeiros Z, Addiss D, 1997. Assessment of the effect of diethylcarbamazine on adult *Wuchereria bancrofti* in vivo. *Trans R Soc Trop Med Hyg* 91: 78-81.
10. Faris R, Hussein O, El-Setouhy M, Ramzy RM, Weil GJ, 1998. Bancroftian filariasis in Egypt: Visualization of adult worms and subclinical lymphatic pathology by scrotal ultrasound. *Am J Trop Med Hyg* 59: 864-867.
11. Tobian A, Tarongka N, Biasor M, Bockarie M, Kazura J, King C, 2003. Sensitivity and specificity of ultrasound detection and risk factors for filarial-associated hydroceles. *Am J Trop Med Hyg* 68: 638-642.
12. Mand S, Marfo-Debrekyei Y, Dittrich M, Fischer K, Adjei O, Hoerauf A, 2003. Animated documentation of the filarial dance sign (FDS) in bancroftian filariasis. *Filarial J* 2: 3.
13. El-Setouhy M, Ramzy R, Ahmed E, Kandil A, Hussain O, Farid H, Helmy H, Weil G, 2004. A randomized clinical trial comparing single- and multi-dose combination therapy with diethylcarbamazine and albendazole for treatment of Bancroftian filariasis. *Am J Trop Med Hyg* 70: 191-196.
14. Ramzy RMR, Gad AM, Faris R, Weil GJ, 1991. Evaluation of a monoclonal antibody-based antigen assay for diagnosis of *Wuchereria bancrofti* infection in Egypt. *Am J Trop Med Hyg* 44: 691-695.
15. Martin B, 1992. *Atlas of Scrotal Ultrasound*. New York: Springer-Verlag.
16. Dreyer G, Figueredo-Silva J, Carvalho K, Amaral F, Ottesen E, 2001. Lymphatic filariasis in children: adenopathy and its evolution in two young girls. *Am J Trop Med Hyg* 65: 204-207.
17. Dreyer G, Brandao A, Amaral F, Medeiros Z, Addiss D, 1996. Detection by ultrasound of living adult *Wuchereria bancrofti* in the female breast. *Mem Inst Oswaldo Cruz* 91: 95-96.
18. Kazura J, Greenberg J, Perry R, Weil G, Alpers KDM, 1993. Comparison of single-dose diethylcarbamazine and ivermectin for treatment of bancroftian filariasis in Papua New Guinea. *Am J Trop Med Hyg* 49: 804-811.
19. Weil G, Sethumadhavan K, Santhanam S, Jain D, Ghosh T, 1988. Persistence of parasite antigenemia following diethylcarbamazine therapy of bancroftian filariasis. *Am J Trop Med Hyg* 38: 589-595.
20. Weil G, Lammie P, Richards F, Eberhard M, 1991. Changes in circulating parasite antigen levels after diethylcarbamazine and ivermectin treatment of bancroftian filariasis. *J Infect Dis* 161: 814-816.
21. Taylor M, 2003. *Wolbachia* in the inflammatory pathogenesis of human filariasis. *Ann N Y Acad Sci* 990: 444-449.