

Washington University School of Medicine Digital Commons@Becker

Open Access Publications

8-21-2013

Molecular characterization of articular cartilage from young adults with femoroacetabular impingement

Shingo Hashimoto

Washington University School of Medicine in St. Louis

Muhammad Farooq Rai

Washington University School of Medicine in St. Louis

Corey S. Gill

Washington University School of Medicine in St. Louis

Zhiqi Zhang

Washington University School of Medicine in St. Louis

Linda J. Sandell

Washington University School of Medicine in St. Louis

See next page for additional authors

Follow this and additional works at: http://digitalcommons.wustl.edu/open_access_pubs

Recommended Citation

Hashimoto, Shingo; Rai, Muhammad Farooq; Gill, Corey S.; Zhang, Zhiqi; Sandell, Linda J.; and Clohisy, John C., "Molecular characterization of articular cartilage from young adults with femoroacetabular impingement." *The Journal of Bone and Joint Surgery*.95,16. 1457-1464. (2013).

http://digitalcommons.wustl.edu/open_access_pubs/1652

This Open Access Publication is brought to you for free and open access by Digital Commons@Becker. It has been accepted for inclusion in Open Access Publications by an authorized administrator of Digital Commons@Becker. For more information, please contact engeszer@wustl.edu.

Authors

Shingo Hashimoto, Muhammad Farooq Rai, Corey S. Gill, Zhiqi Zhang, Linda J. Sandell, and John C. Clohisy

Molecular Characterization of Articular Cartilage from Young Adults with Femoroacetabular Impingement

Shingo Hashimoto, MD, PhD, Muhammad Farooq Rai, PhD, Corey S. Gill, MD, Zhiqi Zhang, MD, Linda J. Sandell, PhD, and John C. Clohisy, MD

Investigation performed at Washington University School of Medicine at Barnes-Jewish Hospital, St. Louis, Missouri

Background: Femoroacetabular impingement is a frequent cause of hip pain and may lead to secondary osteoarthritis, yet little is known about the molecular events linking mechanical hip impingement and articular cartilage degeneration. The first goal of this study was to quantify the expression of inflammatory cytokine and chemokine, matrix-degrading, and extracellular matrix genes in articular cartilage harvested from control hips and hips with femoroacetabular impingement and end-stage osteoarthritis. The second goal was to analyze the relative expression of these genes in articular cartilage harvested at various stages of osteoarthritis.

Methods: Cartilage samples were obtained from thirty-two hips undergoing hip preservation surgery for femoroacetabular impingement or hip arthroplasty. Three control cartilage samples were also analyzed. Specimens were graded intraoperatively with regard to the severity of cartilage damage, the radiographic osteoarthritis grade was recorded, and quantitative RT-PCR (real-time polymerase chain reaction) was performed to determine relative gene expression.

Results: Except for interleukin-1 β (IL-1 β) and CXCL2, the mRNA (messenger RNA) expression of all other chemokine (IL-8, CXCL1, CXCL3, CXCL6, CCL3, and CCL3L1), matrix-degrading (matrix metalloproteinase [MMP]-13 and ADAMTS-4), and structural matrix (COL2A1 [collagen, type II, alpha] and ACAN [aggrecan]) genes was higher overall in cartilage from hips with femoroacetabular impingement compared with hips with osteoarthritis and normal controls. The differences reached significance ($p \leq 0.05$) for seven of these ten quantified genes, with CXCL3, CXCL6, and COL2A1 being elevated in the femoroacetabular impingement group compared with only the control group and IL-8, CCL3L1, ADAMTS-4, and ACAN being elevated compared with both the osteoarthritis and control groups. When samples were grouped according to the stage of the degenerative cascade, mRNA expression was relatively higher in one of the two middle stages of femoroacetabular impingement (chondromalacia or cleavage/thinning), with the difference reaching significance for IL-8, CXCL2, CXCL3, CCL3L1, and ACAN. ACAN expression was diminished in hips with osteoarthritis compared with femoroacetabular impingement but elevated compared with the control articular cartilage.

Conclusions: Articular cartilage from the impingement zone of hips with femoroacetabular impingement (and particularly those hips in the cleavage/thinning stage) expressed higher levels of certain inflammatory, anabolic, and catabolic genes, representing a heightened metabolic state.

Clinical Relevance: The articular cartilage from the impingement zone of hips with femoroacetabular impingement was metabolically hyperactive, supporting the concept that such impingement is a structural precursor to hip osteoarthritis.

Disclosure: One or more of the authors received payments or services, either directly or indirectly (i.e., via his or her institution), from a third party in support of an aspect of this work. In addition, one or more of the authors, or his or her institution, has had a financial relationship, in the thirty-six months prior to submission of this work, with an entity in the biomedical arena that could be perceived to influence or have the potential to influence what is written in this work. No author has had any other relationships, or has engaged in any other activities, that could be perceived to influence or have the potential to influence what is written in this work. The complete **Disclosures of Potential Conflicts of Interest** submitted by authors are always provided with the online version of the article.



A commentary by Darryl D. D'Lima, MD, PhD, is linked to the online version of this article at jbjs.org.

Recent advances in understanding structural hip disease have bolstered the theory of secondary osteoarthritis^{1,2}. In this model of hip osteoarthritis pathophysiology, joint degeneration is secondary to an abnormal mechanical environment commonly caused by femoroacetabular impingement. This impingement results from a distinct morphologic abnormality of the acetabular rim (pincer deformity) and/or the femoral head-neck junction (cam deformity). These structural malformations produce dynamic, repetitive abutment between the proximal aspect of the femur and the acetabular rim leading to labrochondral dissociation, articular cartilage detachment, and progressive joint degeneration³⁻⁵. In this model of secondary hip osteoarthritis, underlying structural abnormalities of the acetabulum and proximal aspect of the femur causing femoroacetabular impingement mediate progressive osteoarthritis and eventually hip joint failure^{1,4}. Despite increasing knowledge regarding femoroacetabular impingement and secondary osteoarthritis, this theory remains controversial and the role of femoroacetabular impingement in the pathophysiology of osteoarthritis continues to be questioned⁶.

Our understanding of the biology of osteoarthritis has expanded markedly in recent years. Current information indicates

that articular cartilage degeneration, characteristic of osteoarthritis, is mediated by several distinct molecular mediators such as cytokines, chemokines, and metalloproteinases⁷ that are released by intra-articular and periarticular soft tissues (Table I). Cytokines are cell-signaling proteins produced by chondrocytes and synovial cells within the hip joint that act to stimulate inflammation and regulate extracellular matrix homeostasis⁷. Interleukin-1 β (IL-1 β) is a cytokine that strongly increases inflammation and is thought to play a pivotal role in both early and late-stage osteoarthritis⁸. IL-1 β causes articular cartilage destruction in part by stimulating production of MMP (matrix metalloproteinase)-13 and ADAMTS (a disintegrin and metalloproteinase with thrombospondin motifs)-4, the enzymes responsible for cleavage of the major structural proteins in the cartilage matrix (type-II collagen and aggrecan, respectively)⁹⁻¹¹. Additionally, more recent investigations have implicated certain chemoattractive cytokines (chemokines) as potential mediators of articular cartilage degeneration¹²⁻¹⁵. Chemokines represent a large family of structurally related inflammatory and immune system mediators that may have important roles in normal articular cartilage physiology and

TABLE I Candidate Genes Important in the Potential Biological Link Between Femoroacetabular Impingement and Secondary Osteoarthritis

NCBI* Accession No.	Gene Name	Symbol	Alias	Forward Primer	Reverse Primer	Metabolic Role
NM_000576.2	Interleukin-1 beta	IL-1 β	—	(5'-TCCAGGAGAATGACCTGAGC-3')	(5'-GTGATCGTACAGGTGCATCG-3')	Inflammation
NM_000584.3	Interleukin-8	IL-8	—	(5'-GAAGGTGCAGTTTTGCCAAG-3')	(5'-TGTGGTCCACTCTCAATCCTC-3')	Inflammation
NM_001511.2	Chemokine (C-X-C) motif ligand 1	CXCL1	GRO- α	(5'-GGGAATTCACCCCAAGAAC-3')	(5'-GATGCAGGATTGAGGCAAG-3')	Inflammation
NM_002089.3	Chemokine (C-X-C) motif ligand 2	CXCL2	GRO- β	(5'-TGCAGGGAATTCACCTCAAG-3')	(5'-TCTTAACCATGGGCGATGC-3')	Inflammation
NM_002090.2	Chemokine (C-X-C) motif ligand 3	CXCL3	GRO- γ	(5'-ACCGAAGTCATAGCCCACTC-3')	(5'-GGTGCTCCCTTGTTCAGTA-3')	Inflammation
NM_002993.3	Chemokine (C-X-C) motif ligand 6	CXCL6	GCP-2	(5'-GTTTACGCGTTACGCTGAGAG-3')	(5'-ACTTCCACCTGGAGCACTG-3')	Inflammation
NM_002983.2	Chemokine (C-C) motif ligand 3	CCL3	MIP-1 α	(5'-GCAACCAGTTCTCTGCATCA-3')	(5'-TGGCTGCTCGTCTCAAAGTA-3')	Inflammation
NM_021006.4	Chemokine (C-C) motif ligand 3-like 1	CCL3L1	LD78 β	(5'-GTCTCTCTGCACCACTTGC-3')	(5'-GGAAGATGACTGGGCTTG-3')	Inflammation
NM_002427.3	Matrix metalloproteinase 13	MMP-13	Collagenase 3	(5'-TGGTCCAGGAGATGAAGACC-3')	(5'-TCCTCGGAGACTGGTAATGG-3')	Degradation (catabolism)
NM_005099.4	A disintegrin and metalloproteinase with thrombospondin motifs 4	ADAMTS-4	—	(5'-GGCTAAAGCGCTACCTGCTA-3')	(5'-GAGTCAACCAAGCTGACA-3')	Degradation (catabolism)
NM_033150.2	Collagen, type II, alpha	COL2A1	—	(5'-CCCAGAGGTGACAAAGGAGA-3')	(5'-CACCTTGGTCTCCAGAAGGA-3')	Synthesis (anabolism)
NM_013227.3	Aggrecan	ACAN	—	(5'-GGCACTAGTCAACCCCTTGG-3')	(5'-CTGAACCCCTGGTAACCCCTGA-3')	Synthesis (anabolism)
NM_002046.3	Glyceraldehyde- 3-phosphate dehydrogenase	GAPDH	G3PDH	(5'-ACCCAGAAGACTGTGGATGG-3')	(5'-GAGGCAGGGATGATGTTCTG-3')	Housekeeping

*NCBI = National Center for Biotechnology Information.

TABLE II Source of Cartilage Samples

	Control	FAI*	OA*
Hips (no.)	3	25	7
Mean age (range) (yr)	28 (15 to 44)	24.1 (13 to 37)	52.7 (37 to 73)
Sex	3 female	17 male, 8 female	5 male, 2 female
Tissue source	Surgical specimen (DDH control†)	Surgical specimen	Surgical specimen

*FAI = femoroacetabular impingement, and OA = osteoarthritis. †DDH = developmental dysplasia of hip. The cartilage was harvested to prevent secondary FAI after acetabular reorientation²⁶ and was used as a control tissue as there were no signs of tissue degeneration at the time of surgery.

disease states^{16,17}. Chemokine production is upregulated by proinflammatory molecules such as IL-1 β and tumor necrosis factor alpha (TNF- α), and chemokines may play a role in osteoarthritis by recruiting inflammatory cells to injured cartilage, by directly stimulating inflammation and production of degradative enzymes such as MMP-13, or by stimulating the death of chondrocytes through apoptosis^{16,18,19}.

Despite our improved understanding of hip pathomechanics and osteoarthritis pathobiology, the cellular and molecular “links” between the pathologic mechanical environment and the metabolic alterations of articular cartilage in hip osteoarthritis are not understood. An improved understanding of these biologic cascades will facilitate future disease staging and therapeutic strategies for pre-arthritis and early arthritic hip disease. Nevertheless, characterization of the cellular and molecular events that mediate articular cartilage degeneration remains problematic because of the current limitations of animal models of hip osteoarthritis, the questionable relevance of in vitro osteoarthritis models, and the inherent limitations in obtaining and studying human cartilage tissues from pre-arthritis and/or early arthritic hips.

Over the past decade, there has been an increased utilization of hip joint preservation procedures designed to surgically “normalize” or improve the mechanical environment of pre-arthritis and early arthritic hips^{20,21}. A common component of hip joint preservation procedures for femoroacetabular impingement is resection of a prominent anterolateral femoral head-neck junction to relieve mechanical impingement²²⁻²⁵. The articular cartilage harvested from this tissue provides unique biologic specimens for the analysis of metabolic activity and gene expression in articular chondrocytes.

We quantified mRNA (messenger RNA) expression of genes that are potentially important in the development of secondary osteoarthritis in hips with femoroacetabular impingement. The first goal of this study was to quantify the expression of genes for inflammatory cytokines and chemokines (IL-1 β , IL-8, CXCL1, CXCL2, CXCL3, CXCL6, CCL3, and CCL3L1), degradative enzymes (MMP-13 and ADAMTS-4), and major structural proteins in the cartilage extracellular matrix (COL2A1 and ACAN) (see Table I for definitions) in articular cartilage harvested from normal hips and hips with femoroacetabular impingement and end-stage osteoarthritis. The second goal was to analyze the relative expression of these genes in articular cartilage harvested at various stages of the osteoarthritic cascade.

Materials and Methods

Patients and Cartilage Samples

We analyzed articular cartilage tissues from thirty-two patients (thirty-two hips) undergoing hip preservation surgery for femoroacetabular impingement, total hip replacement, or hip resurfacing (Table II). All tissues were obtained from the anterolateral femoral head-neck junction in the area of mechanical impingement. For comparison, articular cartilage samples without signs of tissue degeneration (control samples) were obtained from patients undergoing hip preservation surgery involving acetabular reorientation for developmental dysplasia of the hip. The anterolateral head-neck junction (which was without signs of articular cartilage degeneration) was then removed from the latter patients to prevent potential secondary femoroacetabular impingement²⁶. The three patients (all female) from whom a control cartilage sample was obtained for comparison had a mean age of twenty-eight years (range, fifteen to forty-four years). Each patient signed a research consent form for the study, which was approved by the university's institutional review board. All surgical procedures were performed by a single surgeon (J.C.C.) from 2009 to 2011.

Twenty-five of the thirty-two non-control patients (and hips) were treated with hip preservation surgery and formed the primary study group. All of these hips were treated for symptomatic femoroacetabular impingement with open femoral head-neck osteochondroplasty; arthroscopic procedures performed during the study period to treat femoroacetabular impingement were excluded because of the difficulties encountered in tissue harvesting and processing. The mean age of these eight female and seventeen male patients was 24.1 years (range, thirteen to thirty-seven years). All patients had a clinical diagnosis of femoroacetabular impingement as determined by one of the authors (J.C.C.). All had groin pain, restricted hip internal rotation in flexion, and a positive anterior impingement test. All were evaluated with preoperative radiographs made according to a previously published protocol²⁷ and were found to have structural abnormalities consistent with cam or combined cam and pincer impingement. Additionally, the radiographic assessment of the osteoarthritis grade according to the Tönnis classification system²⁸ was recorded. Twelve (48%) of the hips were Tönnis grade 0 (no radiographic evidence of osteoarthritis), nine (36%) were grade 1 (sclerosis only), and four (16%) were grade 2 (moderate joint-space narrowing). None were Tönnis grade 3 (advanced osteoarthritis with severe joint-space narrowing). All patients had undergone prior unsuccessful nonsurgical treatment.

The remaining seven non-control patients were treated with primary total hip replacement or hip resurfacing for end-stage osteoarthritis. The mean age of these two female and five male patients was 52.7 years (range, thirty-seven to seventy-three years). All had a diagnosis of osteoarthritis with hip morphology consistent with femoroacetabular impingement and Tönnis grade-3 osteoarthritis on radiographs. Specimens were obtained from the anterolateral femoral head-neck junction of these hips in a fashion identical to that in the hips with femoroacetabular impingement. These served as a comparison group of biologic specimens representing end-stage hip osteoarthritis.

At the time of surgery, the integrity of the articular cartilage at the femoral head-neck junction was evaluated macroscopically and was classified

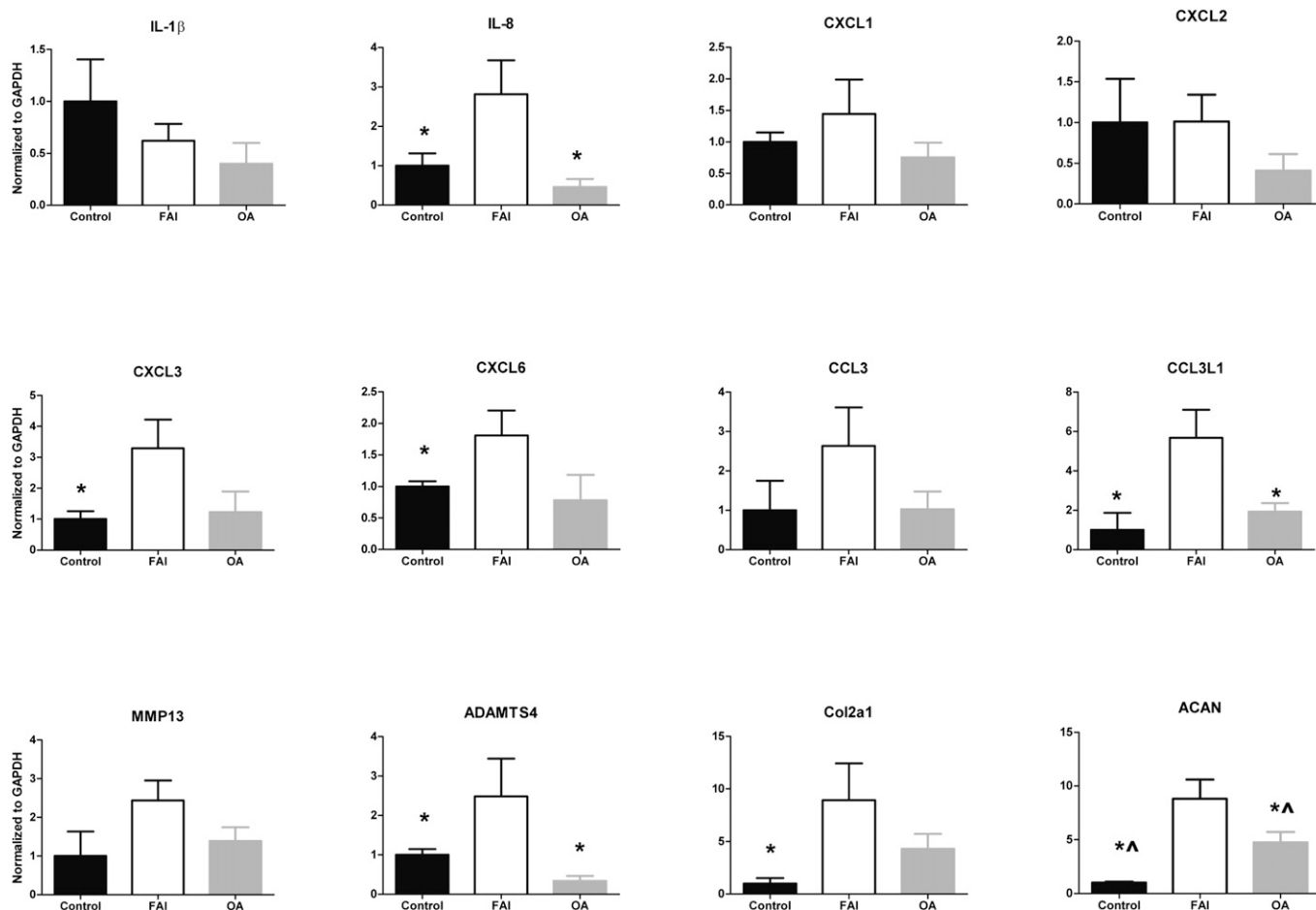


Fig. 1

Normalized mRNA expression of selected cytokine and chemokine, matrix-degrading, and structural matrix genes (defined in Table I) in articular cartilage samples obtained from hips with femoroacetabular impingement (FAI) and end-stage osteoarthritis (OA) compared with controls. Except for IL-1 β and CXCL2, the expression of all genes was higher in hips with FAI compared with controls and hips with OA. Significant differences between two or more categories were observed for IL-8, CXCL3, CXCL6, CCL3L1, ADAMTS-4, COL2A1, and ACAN, indicating that the cartilage in hips with FAI was metabolically more active than the cartilage in hips with OA and controls. The data are expressed as the mean and the standard error of the mean relative to the mean expression of the control specimens. * $P \leq 0.05$ compared with hips with FAI. $\Delta P \leq 0.05$ between controls and hips with OA.

with use of the system of Beck et al.³ This system includes criteria to evaluate the macroscopic appearance of the articular cartilage, integrity of the cartilage surface, and fixation of the cartilage to the underlying subchondral bone (see Appendix). This system was used by the senior surgeon (J.C.C.) to classify all samples into one of five categories: normal, chondromalacia, debonding, cleavage and/or thinning, or defect. The most severe area of disease in each specimen was used for the final grading. After the cartilage was harvested from the anterolateral impingement zone of the femoral head-neck junction, RNA was extracted from the sample and quantitative RT-PCR (real-time polymerase chain reaction) was performed to evaluate gene expression in the articular cartilage. The genes selected for evaluation included genes for cytokines, chemokines, degradative enzymes, and extracellular matrix proteins thought to play a role in osteoarthritis or joint degradation (Table I).

Isolation of RNA and Quantitative RT-PCR

The cartilage tissues were immersed promptly in TRIzol reagent (Invitrogen, Carlsbad, California) on reception to avoid potential RNA degradation. In addition, all RNA preparation was carried out under RNase-free conditions.

Isolation of total RNA and quantitative RT-PCR were carried out as described previously, with slight modifications^{29,30}. Briefly, total RNA was first extracted from the cartilage with TRIzol reagent according to the protocol recommended by the manufacturer. After the RNA extraction, RNA clean-up was performed with use of an RNeasy Mini Kit (Qiagen, Valencia, California). Total RNA was reverse-transcribed with SuperScript II reverse transcriptase (Invitrogen) to synthesize first-strand complementary DNA (cDNA). Using this cDNA, quantitative RT-PCR was performed with 20 μ L of reaction mixture containing SYBR Green PCR Master Mix (Applied Biosystems, Foster City, California) and primers on a 7500 Fast Real-Time PCR system (Applied Biosystems). Primers^{29,30} for quantitative RT-PCR were selected for each gene (Table I), and the dissociation curve was determined. The primer design parameters included a primer size of 18 to 21 bp, a product size of 80 to 150 bp, a primer annealing temperature of 59° to 61°C, and a primer GC content of 45% to 55%. Results were normalized to the glyceraldehyde-3-phosphate dehydrogenase (GAPDH) level. The three control articular cartilage samples and seven end-stage osteoarthritis samples were analyzed for comparison. The comparative C_t (threshold cycles) method was used to evaluate the expression level of each

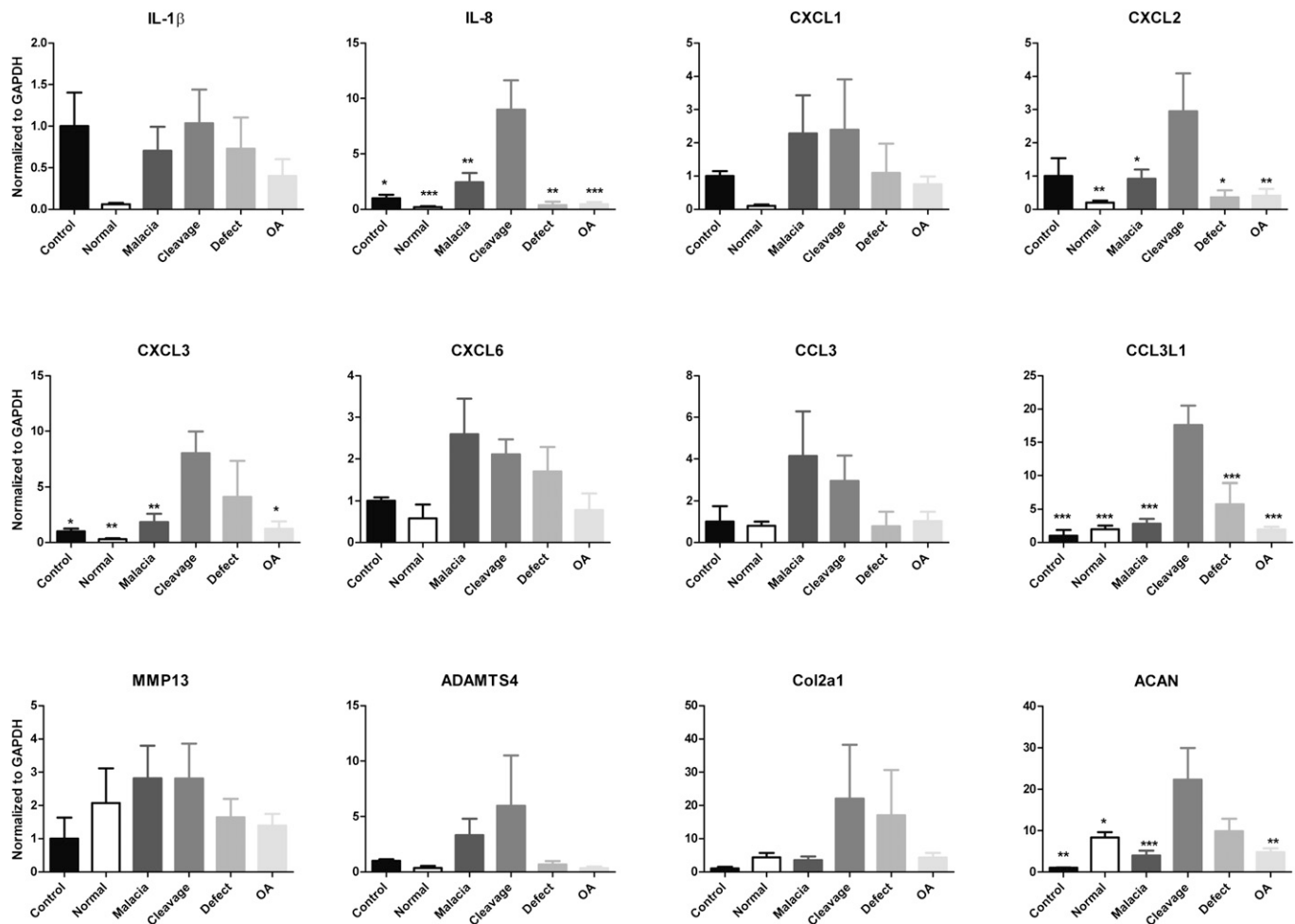


Fig. 2
Normalized mRNA expression of selected cytokine and chemokine, matrix-degrading, and structural matrix genes (defined in Table I) in articular cartilage samples obtained from hips with femoroacetabular impingement (FAI) classified intraoperatively according to the Beck criteria (normal, chondromalacia, cleavage/thinning, and defect) and hips with end-stage osteoarthritis (OA) compared with controls. The mRNA expression in the FAI cleavage/thinning category was higher than those in the other FAI categories, OA, and normal control cartilage except in the cases of CXCL1, CXCL6, and MMP-13, for which the expression in the FAI cleavage/thinning category remained relatively similar to that in the chondromalacia category. The mRNA expression levels of IL-8, CXCL2, CXCL3, CCL3L1, and ACAN were significantly higher in the FAI cleavage/thinning category than in the other categories indicated by asterisks, indicating that cartilage at the cleavage/thinning stage expressed more inflammatory and catabolic mediators. None of the other groups differed significantly. The data are expressed as the mean and the standard error of the mean relative to the mean expression of the control specimens. A p value of ≤ 0.05 was considered significant. * $P \leq 0.05$. ** $P < 0.01$. *** $P < 0.001$.

target gene relative to the level in the controls. All graphs depict the expression level in each non-control patient group divided by that in the controls.

Statistical Analysis

Data are expressed as the mean and the standard error of the mean unless otherwise indicated. The nonparametric Mann-Whitney U test was used for comparisons of normally distributed data among the groups. Analysis of variance (ANOVA) followed by the Tukey honestly significant difference post hoc test were used for multiple comparisons. Differences in gene expression were considered significant at a p value of ≤ 0.05 .

Source of Funding

The study was funded by NIH (National Institutes of Health) grants R0136994, R01AR050847, R02AR058978, and P30AR057235. M.F.R. is supported by

a Ruth L. Kirschstein National Research Service Award Fellowship (T32-AR060719) from the NIH.

Results

Expression of cytokine, chemokine, degradative enzyme, and matrix genes was evaluated in three distinct groups of articular cartilage specimens. The genes analyzed are shown in Table I and the characteristics of the tissue sources are summarized in Table II. Gene expression in the twenty-five hips with a clinical diagnosis of femoroacetabular impingement was compared with gene expression in the three control samples of cartilage from hips without osteoarthritis as well as the seven samples obtained from hips with end-stage osteoarthritis

at the time of total hip arthroplasty or hip resurfacing (Fig. 1). Expression of all inflammatory cytokines and chemokines except IL-1 β and CXCL2 was elevated in the samples from the hips with femoroacetabular impingement compared with the control samples. The difference was significant ($p \leq 0.05$) for IL-8, CXCL3, CXCL6, and CCL3L1, and significant differences were also observed for ADAMTS-4, COL2A1, and ACAN. Expression of certain of these chemokine (IL-8 and CCL3L1), matrix-degrading (ADAMTS-4), and extracellular matrix (ACAN) genes was also higher in cartilage from hips with femoroacetabular impingement compared with end-stage osteoarthritis. In addition, the gene expression differences between the control cartilage and the cartilage from hips with end-stage osteoarthritis were variable and not significant except in the case of ACAN, which was significantly upregulated in the osteoarthritis group.

Articular cartilage damage observed intraoperatively in hips with femoroacetabular impingement and osteoarthritis was graded in order to compare expression of cytokine, chemokine, degradative enzyme, and matrix genes in articular cartilage from different stages of the osteoarthritic cascade. According to the Beck criteria, three (12%) of the hips with femoroacetabular impingement were classified as showing a normal appearance; thirteen (52%), chondromalacia; zero (0%), debonding; five (20%), cleavage/thinning; and four (16%), a full-thickness defect (see Appendix). The radiographic osteoarthritis scoring was grade 0 (no evidence of osteoarthritis) in twelve (48%) of these hips, grade 1 (sclerosis only) in nine (36%), and grade 2 (moderate joint space narrowing) in four (16%). All samples from hips with end-stage osteoarthritis were classified as showing a full-thickness defect, and the radiographic scoring was grade 3 (severe joint space narrowing) in all of these hips. Analysis of gene expression according to the intraoperative classification of articular cartilage damage (Fig. 2) revealed that the expression of certain chemokine (IL-8, CXCL2, CXCL3, and CCL3L1) and extracellular matrix (ACAN) genes was significantly higher in the cleavage/thinning stage.

Gene expression was generally lower in the control cartilage than in the other groups except in the case of IL-1 β , which was expressed at a relatively similar level in the control cartilage and cartilage at the cleavage/thinning stage.

Discussion

Femoroacetabular impingement is a common cause of hip pain in adolescents and young adults³¹, and it has been implicated as an important etiologic factor in secondary hip osteoarthritis. In recent years, a better understanding of the clinical presentation and structural characteristics of this condition has led to increased utilization of surgical procedures designed to preserve the hip joint with the aim of relieving symptoms, enhancing function, and improving the mechanical environment of the hip joint. Although an increasing body of literature suggests that femoroacetabular impingement plays a role in the development of secondary osteoarthritis^{3,4,31}, there remains substantial controversy regarding

this topic^{6,32}. Additionally, the impact of femoroacetabular impingement on articular cartilage and joint biology at the cellular and molecular level is poorly understood. In order to better understand the biological link between femoroacetabular impingement and osteoarthritis, we compared the expression of cytokine, chemokine, degradative enzyme, and cartilage matrix genes in articular cartilage from hips with femoroacetabular impingement, normal hips, and hips with osteoarthritis. Furthermore, we compared gene expression in the articular cartilage from hips in various stages of the osteoarthritic cascade (as determined by intraoperative morphologic grading).

To our knowledge, this is the first report of metabolic activity levels in the articular cartilage of human subjects with femoroacetabular impingement. Articular cartilage obtained from the impingement zone (anterolateral head-neck junction) of hips with femoroacetabular impingement expressed markedly elevated levels of most chemokines and degradative enzymes, but not of the proinflammatory cytokine IL-1 β , compared with normal articular cartilage (Fig. 1). Cartilage specimens from hips with femoroacetabular impingement also expressed significantly higher levels of certain chemokines and other markers (IL-8, CCL3L1, ADAMTS-4, and ACAN) compared with articular cartilage from hips with end-stage osteoarthritis. In the comparison among different stages of articular cartilage degradation, the cleavage/thinning stage was the most metabolically active as indicated by our panel of target genes. Importantly, there was a trend toward decreased expression of matrix protein genes (COL2A1 and ACAN) in end-stage osteoarthritis compared with femoroacetabular impingement, although this decrease was significant only for ACAN.

The early pathophysiology of osteoarthritis is poorly understood, and very limited information exists regarding the biologic cascade that mediates osteoarthritis in the human hip. Nevertheless, previous work suggests that early changes after injury to articular cartilage include hypertrophy, collagen deformation, proteoglycan depletion, and mild inflammation³³⁻³⁵. These events are reversible, as chondrocytes can degrade damaged molecules and increase matrix production³⁶. Thus, both anabolism and catabolism are increased in early osteoarthritis, with the balance moving toward catabolism with disease progression³³. These previous observations are consistent with the data from the hips with femoroacetabular impingement and osteoarthritis in the present study (Fig. 1). The samples from hips with femoroacetabular impingement demonstrated higher metabolic activity involving inflammatory chemokine (IL-8 and CCL3L1), matrix-degrading (ADAMTS-4), and extracellular matrix (ACAN) genes compared with hips with end-stage osteoarthritis. The decrease in matrix protein gene expression in hips with end-stage osteoarthritis may indicate a loss of anabolic activity and an imbalance favoring catabolism.

Conventional diagnosis and treatment of pre-arthritic, early arthritic, and advanced arthritic conditions is highly dependent on patient symptoms, physical examination, and radiographic evaluation²⁰. It is important to note that the


majority (84%) of the hips with femoroacetabular impingement in the present study had no or only early radiographic signs of osteoarthritis (Tönnis grade 0 or 1), yet the alterations in articular cartilage metabolic activity were profound. This finding underscores the concept that the biology of the osteoarthritic cascade far precedes radiographic evidence of disease. Consequently, alternative methods of diagnosis and disease staging are being investigated. Biologic markers from blood, urine, and synovial fluid are considered potential candidates for future diagnostic and disease staging strategies^{37,38}. In the present study, articular cartilage from hips with femoroacetabular impingement demonstrated a “molecular signature” compared with normal cartilage. Several of the chemokines that were highly expressed in cartilage from hips with femoroacetabular impingement were most markedly elevated when the stage of articular cartilage degeneration was classified as chondromalacia or cleavage/thinning. These morphologic stages of articular cartilage degeneration commonly precede radiographic osteoarthritic changes, suggesting that specific cytokine and chemokine gene expression levels may have potential in characterizing the early (pre-arthritis) molecular changes that are occurring in articular cartilage. These new findings provide a basis for pursuing distinct chemokines as candidate biomarkers for the diagnosis and staging of pre-osteoarthritic and early osteoarthritic disorders³⁹.

Another important aspect of this study was the availability of control hip cartilage samples from age-matched subjects without osteoarthritis who were undergoing hip surgery. These samples provided baseline data for comparison with tissue from hips with femoroacetabular impingement and osteoarthritis. Nevertheless, the study has limitations. First, although we identified local alterations in articular cartilage gene expression in femoroacetabular impingement that may mediate the osteoarthritic cascade, we have not identified the specific molecular and/or mechanistic role of each factor in the pathophysiology of femoroacetabular impingement, as such studies were beyond the scope of this report. Future investigations will focus on the mechanisms of the osteoarthritic cascade. Second, we measured gene expression in only one specific area of articular cartilage (the anterolateral femoral head-neck junction); the expression and molecular characteristics of articular cartilage in other areas of the hip were not determined. This limitation could not be overcome because the surgical goal

of preserving the joint in patients with femoroacetabular impingement excluded the possibility of harvesting tissues from other regions. Therefore, the impact of femoroacetabular impingement pathomechanics on articular cartilage away from the impingement zone remains unclear.

In conclusion, these findings provide novel information regarding the pathophysiology of femoroacetabular impingement and the molecular basis of human hip osteoarthritis. Specifically, we demonstrated the feasibility of analyzing gene expression in articular cartilage samples obtained from the impingement zone at the time of joint preservation surgery. Analysis of these tissues suggests that the mechanical disease of femoroacetabular impingement causes localized articular cartilage alterations that are consistent with early osteoarthritic degeneration. Specifically, articular cartilage in the femoroacetabular impingement zone had high metabolic activity, both catabolic and anabolic, that commonly preceded radiographic evidence of osteoarthritis.

Appendix

 A table showing the Beck criteria for intraoperative grading of articular cartilage lesions is available with the online version of this article as a data supplement at jbj.org. ■

Shingo Hashimoto, MD, PhD
Muhammad Farooq Rai, PhD
Corey S. Gill, MD
Zhiqi Zhang, MD
Linda J. Sandell, PhD
John C. Clohisy, MD
Department of Orthopaedic Surgery,
Washington University School of Medicine at Barnes-Jewish Hospital,
660 South Euclid Avenue, Box 8233,
St. Louis, MO 63110.
E-mail address for S. Hashimoto: hashimotos@wudosis.wustl.edu.
E-mail address for M.F. Rai: raim@wustl.edu.
E-mail address for C.S. Gill: gillc@wudosis.wustl.edu.
E-mail address for Z. Zhang: zhzhi@mail2.sysu.edu.cn.
E-mail address for L.J. Sandell: sandell@wudosis.wustl.edu.
E-mail address for J.C. Clohisy: clohisyj@wudosis.wustl.edu

References

- Clohisy JC, Dobson MA, Robison JF, Warth LC, Zheng J, Liu SS, Yehyawi TM, Callaghan JJ. Radiographic structural abnormalities associated with premature, natural hip-joint failure. *J Bone Joint Surg Am.* 2011 May;93(Suppl 2):3-9.
- Murphy SB, Ganz R, Müller ME. The prognosis in untreated dysplasia of the hip. A study of radiographic factors that predict the outcome. *J Bone Joint Surg Am.* 1995 Jul;77(7):985-9.
- Beck M, Kalhor M, Leunig M, Ganz R. Hip morphology influences the pattern of damage to the acetabular cartilage: femoroacetabular impingement as a cause of early osteoarthritis of the hip. *J Bone Joint Surg Br.* 2005 Jul;87(7):1012-8.
- Ganz R, Leunig M, Leunig-Ganz K, Harris WH. The etiology of osteoarthritis of the hip: an integrated mechanical concept. *Clin Orthop Relat Res.* 2008 Feb;466(2):264-72.
- Siebenrock KA, Wahab KH, Werlen S, Kalhor M, Leunig M, Ganz R. Abnormal extension of the femoral head epiphysis as a cause of cam impingement. *Clin Orthop Relat Res.* 2004 Jan;(418):54-60.
- Hartofilakidis G, Bardakos NV, Babis GC, Georgiades G. An examination of the association between different morphotypes of femoroacetabular impingement in asymptomatic subjects and the development of osteoarthritis of the hip. *J Bone Joint Surg Br.* 2011 May;93(5):580-6.
- Sandell LJ, Aigner T. Articular cartilage and changes in arthritis. An introduction: cell biology of osteoarthritis. *Arthritis Res.* 2001;3(2):107-13.
- Goldring MB. The role of cytokines as inflammatory mediators in osteoarthritis: lessons from animal models. *Connect Tissue Res.* 1999;40(1):1-11.
- Mitchell PG, Magna HA, Reeves LM, Lopresti-Morrow LL, Yocum SA, Rosner PJ, Geoghegan KF, Hambor JE. Cloning, expression, and type II collagenolytic activity of matrix metalloproteinase-13 from human osteoarthritic cartilage. *J Clin Invest.* 1996 Feb 1;97(3):761-8.
- Amer EC, Pratta MA, Trzaskos JM, Decicco CP, Tortorella MD. Generation and characterization of aggrecanase. A soluble, cartilage-derived aggrecan-degrading activity. *J Biol Chem.* 1999 Mar 5;274(10):6594-601.

- 11.** Tsuzaki M, Guyton G, Garrett W, Archambault JM, Herzog W, Almekinders L, Bynum D, Yang X, Banes AJ. IL-1 beta induces COX2, MMP-1, -3 and -13, ADAMTS-4, IL-1 beta and IL-6 in human tendon cells. *J Orthop Res.* 2003 Mar;21(2):256-64.
- 12.** Endo H, Akahoshi T, Nishimura A, Tonegawa M, Takagishi K, Kashiwazaki S, Matsushima K, Kondo H. Experimental arthritis induced by continuous infusion of IL-8 into rabbit knee joints. *Clin Exp Immunol.* 1994 Apr;96(1):31-5.
- 13.** Borzi RM, Mazzetti I, Macor S, Silvestri T, Bassi A, Cattini L, Facchini A. Flow cytometric analysis of intracellular chemokines in chondrocytes in vivo: constitutive expression and enhancement in osteoarthritis and rheumatoid arthritis. *FEBS Lett.* 1999 Jul 23;455(3):238-42.
- 14.** McKinney C, Merriman ME, Chapman PT, Gow PJ, Harrison AA, Highton J, Jones PB, McLean L, O'Donnell JL, Pokorny V, Spellerberg M, Stamp LK, Willis J, Steer S, Merriman TR. Evidence for an influence of chemokine ligand 3-like 1 (CCL3L1) gene copy number on susceptibility to rheumatoid arthritis. *Ann Rheum Dis.* 2008 Mar;67(3):409-13.
- 15.** Pharoah DS, Varsani H, Tatham RW, Newton KR, de Jager W, Prakken BJ, Klein N, Wedderburn LR. Expression of the inflammatory chemokines CCL5, CCL3 and CXCL10 in juvenile idiopathic arthritis, and demonstration of CCL5 production by an atypical subset of CD8+ T cells. *Arthritis Res Ther.* 2006;8(2):R50.
- 16.** Borzi RM, Mazzetti I, Marcu KB, Facchini A. Chemokines in cartilage degradation. *Clin Orthop Relat Res.* 2004 Oct;427(Suppl):S53-61.
- 17.** Vergunst CE, van de Sande MG, Lebre MC, Tak PP. The role of chemokines in rheumatoid arthritis and osteoarthritis. *Scand J Rheumatol.* 2005 Nov-Dec;34(6):415-25.
- 18.** Borzi RM, Mazzetti I, Magagnoli G, Paoletti S, Ugucioni M, Gatti R, Orlandini G, Cattini L, Facchini A. Growth-related oncogene alpha induction of apoptosis in osteoarthritis chondrocytes. *Arthritis Rheum.* 2002 Dec;46(12):3201-11.
- 19.** Sandell LJ, Xing X, Franz C, Davies S, Chang LW, Patra D. Exuberant expression of chemokine genes by adult human articular chondrocytes in response to IL-1beta. *Osteoarthritis Cartilage.* 2008 Dec;16(12):1560-71.
- 20.** Clohisy JC, Beaulé PE, O'Malley A, Safran MR, Schoenecker P. AOA symposium. Hip disease in the young adult: current concepts of etiology and surgical treatment. *J Bone Joint Surg Am.* 2008 Oct;90(10):2267-81.
- 21.** Murphy S, Tannast M, Kim YJ, Buly R, Millis MB. Debridement of the adult hip for femoroacetabular impingement: indications and preliminary clinical results. *Clin Orthop Relat Res.* 2004 Dec;429:178-81.
- 22.** Beaulé PE, Le Duff MJ, Zaragoza E. Quality of life following femoral head-neck osteochondroplasty for femoroacetabular impingement. *J Bone Joint Surg Am.* 2007 Apr;89(4):773-9.
- 23.** Beck M, Leunig M, Parvizi J, Boutier V, Wyss D, Ganz R. Anterior femoroacetabular impingement: part II. Midterm results of surgical treatment. *Clin Orthop Relat Res.* 2004 Jan;(418):67-73.
- 24.** Clohisy JC, Zebala LP, Nepple JJ, Pashos G. Combined hip arthroscopy and limited open osteochondroplasty for anterior femoroacetabular impingement. *J Bone Joint Surg Am.* 2010 Jul 21;92(8):1697-706.
- 25.** Peters CL, Erickson JA. Treatment of femoro-acetabular impingement with surgical dislocation and débridement in young adults. *J Bone Joint Surg Am.* 2006 Aug;88(8):1735-41.
- 26.** Nassif NA, Schoenecker PL, Thorsness R, Clohisy JC. Periacetabular osteotomy and combined femoral head-neck junction osteochondroplasty: a minimum two-year follow-up cohort study. *J Bone Joint Surg Am.* 2012 Nov 7;94(21):1959-66.
- 27.** Clohisy JC, Carlisle JC, Beaulé PE, Kim YJ, Trousdale RT, Sierra RJ, Leunig M, Schoenecker PL, Millis MB. A systematic approach to the plain radiographic evaluation of the young adult hip. *J Bone Joint Surg Am.* 2008 Nov;90(Suppl 4):47-66.
- 28.** Tönnis D. Congenital dysplasia and dislocation of the hip in children and adults. Heidelberg: Springer; 1987.
- 29.** Zhang Z, Bryan JL, DeLassus E, Chang LW, Liao W, Sandell LJ. CCAAT/enhancer-binding protein β and NF- κ B mediate high level expression of chemokine genes CCL3 and CCL4 by human chondrocytes in response to IL-1 β . *J Biol Chem.* 2010 Oct 22;285(43):33092-103.
- 30.** Brophy RH, Rai MF, Zhang Z, Torgomyan A, Sandell LJ. Molecular analysis of age and sex-related gene expression in meniscal tears with and without a concomitant anterior cruciate ligament tear. *J Bone Joint Surg Am.* 2012 Mar 7;94(5):385-93.
- 31.** Clohisy JC, Knaus ER, Hunt DM, Leshner JM, Harris-Hayes M, Prather H. Clinical presentation of patients with symptomatic anterior hip impingement. *Clin Orthop Relat Res.* 2009 Mar;467(3):638-44.
- 32.** Brand RA. Femoroacetabular impingement: current status of diagnosis and treatment: Marius Nygaard Smith-Petersen, 1886-1953. *Clin Orthop Relat Res.* 2009 Mar;467(3):605-7.
- 33.** Buckwalter JA, Mankin HJ, Grodzinsky AJ. Articular cartilage and osteoarthritis. *Instr Course Lect.* 2005;54:465-80.
- 34.** Sandell LJ. Modern molecular analysis of a traditional disease: progression in osteoarthritis. *Arthritis Rheum.* 2007 Aug;56(8):2474-7.
- 35.** Dijkgraaf LC, de Bont LG, Boering G, Liem RS. The structure, biochemistry, and metabolism of osteoarthritic cartilage: a review of the literature. *J Oral Maxillofac Surg.* 1995 Oct;53(10):1182-92.
- 36.** Pollard TC, Gwilym SE, Carr AJ. The assessment of early osteoarthritis. *J Bone Joint Surg Br.* 2008 Apr;90(4):411-21.
- 37.** Gamero P, Delmas PD. Biomarkers in osteoarthritis. *Curr Opin Rheumatol.* 2003 Sep;15(5):641-6.
- 38.** Gamero P, Rousseau JC, Delmas PD. Molecular basis and clinical use of biochemical markers of bone, cartilage, and synovium in joint diseases. *Arthritis Rheum.* 2000 May;43(5):953-68.
- 39.** Patra D, Sandell LJ. Recent advances in biomarkers in osteoarthritis. *Curr Opin Rheumatol.* 2011 Sep;23(5):465-70.