

## Washington University School of Medicine Digital Commons@Becker

---

### Open Access Publications

---

11-7-2012

# Periacetabular osteotomy and combined femoral head-neck junction osteochondroplasty: A minimum two-year follow-up cohort study

Nader A. Nassif

*Washington University School of Medicine in St. Louis*

Perry L. Schoenecker

*Washington University School of Medicine in St. Louis*

Robert Thorsness

*Washington University School of Medicine in St. Louis*

John C. Clohisy

*Washington University School of Medicine in St. Louis*

Follow this and additional works at: [http://digitalcommons.wustl.edu/open\\_access\\_pubs](http://digitalcommons.wustl.edu/open_access_pubs)

---

### Recommended Citation

Nassif, Nader A.; Schoenecker, Perry L.; Thorsness, Robert; and Clohisy, John C., "Periacetabular osteotomy and combined femoral head-neck junction osteochondroplasty: A minimum two-year follow-up cohort study." *The Journal of Bone and Joint Surgery*.94,21. 1959-1966. (2012).

[http://digitalcommons.wustl.edu/open\\_access\\_pubs/1230](http://digitalcommons.wustl.edu/open_access_pubs/1230)

This Open Access Publication is brought to you for free and open access by Digital Commons@Becker. It has been accepted for inclusion in Open Access Publications by an authorized administrator of Digital Commons@Becker. For more information, please contact [engeszer@wustl.edu](mailto:engeszer@wustl.edu).

# Periacetabular Osteotomy and Combined Femoral Head-Neck Junction Osteochondroplasty

## A Minimum Two-Year Follow-up Cohort Study

Nader A. Nassif, MD, Perry L. Schoenecker, MD, Robert Thorsness, MD, and John C. Clohisy, MD

*Investigation performed at the Department of Orthopedic Surgery, Washington University School of Medicine, St. Louis, Missouri*

**Background:** Proximal femoral deformities and overcorrection of the acetabulum both can result in secondary femoroacetabular impingement and suboptimal clinical results after periacetabular osteotomy. The purpose of the present study was to determine the rate of complications, the need for reoperations, radiographic correction, and hip function among patients who underwent periacetabular osteotomy and combined femoral head-neck osteochondroplasty as compared with those who underwent periacetabular osteotomy alone.

**Methods:** Patients who underwent periacetabular osteotomy with or without osteochondroplasty of the femoral head-neck junction were evaluated retrospectively after a minimum duration of follow-up of two years. We compared the two groups with regard to the modified Harris hip score, radiographic correction, complications, and reoperations.

**Results:** Forty patients (forty hips) who underwent periacetabular osteotomy in conjunction with a femoral head-neck osteochondroplasty were compared with forty-eight patients (forty-eight hips) who underwent an isolated periacetabular osteotomy. Patients were evaluated after a mean duration of follow-up of 3.4 years (range, 2.0 to 9.7 years). Preoperatively, the modified Harris hip score (and standard deviation) was  $64.3 \pm 13.2$  for the study group and  $63.2 \pm 13.4$  for the comparison group. At the time of the latest follow-up, the modified Harris hip score was not significantly different between the study group and the comparison group ( $p = 0.17$ ). Patients demonstrated equivalent preoperative deformities and postoperative acetabular radiographic parameters. There was a significant decrease in the alpha angle and improvement in head-neck offset in the study group. There was one reoperation for secondary impingement and/or labral pathology in the study group, compared with four reoperations in the comparison group. There were no adhesions requiring surgery, femoral neck fractures, instances of osteonecrosis, or increases in heterotopic ossification in the study group.

**Conclusions:** Femoral head-neck junction osteochondroplasty performed concurrently with a periacetabular osteotomy for the treatment of symptomatic acetabular dysplasia and associated femoral head-neck junction deformities is not associated with an increased complication rate. This combined procedure provides effective correction of associated femoral head-neck deformities and produces similar early functional outcomes when compared with isolated periacetabular osteotomy.

**Level of Evidence:** Therapeutic Level III. See Instructions for Authors for a complete description of levels of evidence.

The Bernese periacetabular osteotomy is a well-established procedure that involves reorientation of the acetabulum for the treatment of acetabular dysplasia<sup>1-5</sup>. Intermediate to long-term follow-up studies have demonstrated good outcomes for most patients, with a survivorship rate of 76% at an average of nine years<sup>6</sup> and 60% at twenty years<sup>7</sup>. Despite these encouraging results in the majority of patients, all series have

demonstrated clinical failures in subgroups of patients<sup>2</sup>. One of the major causes of clinical failure is the development of secondary femoral acetabular impingement after acetabular reorientation<sup>8,9</sup>.

With periacetabular osteotomy, impingement can occur from two causes. First, asphericity of the femoral head or femoral head-neck malformations can cause “cam” impingement

**Disclosure:** None of the authors received payments or services, either directly or indirectly (i.e., via his or her institution), from a third party in support of any aspect of this work. One or more of the authors, or his or her institution, has had a financial relationship, in the thirty-six months prior to submission of this work, with an entity in the biomedical arena that could be perceived to influence or have the potential to influence what is written in this work. No author has had any other relationships, or has engaged in any other activities, that could be perceived to influence or have the potential to influence what is written in this work. The complete **Disclosures of Potential Conflicts of Interest** submitted by authors are always provided with the online version of the article.

after acetabular reorientation. Second, iatrogenic “pincer” impingement can be produced by overcorrection or retroversion of the acetabulum producing excessive anterolateral femoral head coverage. For these reasons, some surgeons have expanded the periacetabular osteotomy surgical technique to include arthrotomy with direct inspection of the femoral-head neck junction and osteochondroplasty, if needed, to minimize the risk of secondary femoroacetabular impingement and to improve clinical results. This added component of the procedure is controversial and could be a source of increased complications and inferior clinical results due to intra-articular adhesions, capsular scarring, femoral neck fracture, osteonecrosis, and/or heterotopic ossification resulting from the osteochondroplasty of the femoral head-neck region. An increased risk of heterotopic ossification was a concern when we adopted this procedure because of an observed increased risk associated with the treatment of femoral head fractures through the anterior approach<sup>10</sup> and because of the potential for the release of osteochondral debris into the surrounding soft tissues. Therefore, there was a need to investigate the safety and clinical impact of head-neck junction osteochondroplasty in conjunction with periacetabular osteotomy.

The purpose of the present study was to determine the rate of complications, the need for reoperations, radiographic correction, and hip function among patients who underwent periacetabular osteotomy and combined femoral head-neck osteochondroplasty as compared with those who underwent periacetabular osteotomy alone. We anticipated that osteochondroplasty for hips with aspherical heads, reduced head-neck offset, and/or intraoperative impingement would yield similar clinical outcomes and improved radiographic femoral correction without an increased risk of complications or reoperations at the time of short-term follow-up.

## Materials and Methods

After institutional review board approval was obtained, a retrospective comparison study was initiated from our prospective young adult hip database. Patients who underwent periacetabular osteotomy between 2000 and 2007 at one of three hospitals in our system were reviewed (Fig. 1). All procedures were performed by the senior authors (J.C.C., P.L.S.). A total of 148 hips in 132 patients were available for analysis. The inclusion criteria included a minimum of two years of follow-up, a diagnosis of symptomatic acetabular dysplasia, and treatment with primary periacetabular osteotomy with or without capsulotomy and osteochondroplasty of the femoral head-neck junction. The exclusion criteria included major femoral head deformities (i.e., Perthes-like abnormalities with an elliptical or aspheric femoral head)<sup>11</sup> (two hips), concurrent proximal femoral osteotomy (eight hips)<sup>11,12</sup>, and previous pelvic osteotomy (fourteen hips). In the cases of sixteen patients who underwent a bilateral procedure and met all inclusion criteria, only the first surgical procedure was included to avoid bias. Twenty patients with twenty hips (representing 13.5% of the initial 148 hips) could not be located for the minimum two-year follow-up evaluation. After applying the inclusion and exclusion criteria, eighty-eight patients (eighty-eight hips) were identified; all forty patients in the study group had a combined periacetabular osteotomy, arthrotomy, and osteochondroplasty, and the forty-eight patients in the comparison group underwent a periacetabular osteotomy without an osteochondroplasty. In the study group, six labral procedures (15%) were performed, including four reattachments and two partial resections. Thirty-four (85%) of the forty hips in the study group had no labral procedure. Eleven (23%) of the forty-eight hips in the comparison group had an ar-

throtoomy without osteochondroplasty. In the comparison group, five labral procedures (10%) were performed, including two repairs and three partial resections. Six hips in the comparison group had an exploratory arthrotomy without labral procedure or osteochondroplasty. In general, the patients who were managed exclusively with a periacetabular osteotomy had surgery earlier in the series. We subsequently introduced adjunctive osteochondroplasty for patients with aspherical femoral heads or head-neck offset deformities (see Surgical Technique section). Demographic data that were obtained included sex, age at the time of surgery, and body mass index.

Clinical outcomes were evaluated with use of the modified Harris hip score. Preoperative Harris hip scores as well as minimum two-year clinical follow-up scores were collected prospectively. Patients who were not able to return to the office were interviewed by telephone to obtain a modified Harris hip score<sup>13</sup>. Sixty-nine patients (78.4%) were seen at the time of follow-up and completed self-administered questionnaires, whereas the other nineteen patients (21.6%) were interviewed by a research assistant over the telephone in order to obtain the modified Harris hip score and information on complications and reoperations. Complications associated with the procedure and reoperations were also assessed by means of a retrospective review of outpatient and inpatient records. The clinical record review was performed by one of the authors (N.A.N.) who was not involved in treatment of the patients.

## Radiographic Assessment

Preoperative and postoperative radiographs of each hip were evaluated by a single observer with use of previously established radiographic parameters<sup>14-16</sup>. This observer (N.A.N.) was not involved in the treatment of the patients. All measured radiographic parameters were then blindly reviewed and approved by the senior author (J.C.C.). Supine anteroposterior pelvic and frog-leg-lateral radiographs of the involved hip were available preoperatively and postoperatively for thirty-nine of the forty patients who underwent periacetabular osteotomy with osteochondroplasty and for forty-four of the forty-eight patients who underwent periacetabular osteotomy exclusively. Five patients (five hips) who were missing preoperative frog-leg-lateral radiographs were not included in the radiographic analysis but remained in the cohort for the evaluation of clinical outcomes. False-profile radiographs were available for sixty-one (73.5%) of the remaining eighty-three patients and were used to measure the anterior center-edge angle both preoperatively and postoperatively.

Femoral measurements were made on preoperative and postoperative radiographs for patients who underwent periacetabular osteotomy and osteochondroplasty. There was no postoperative assessment of femoral correction for patients who underwent periacetabular osteotomy only as no intervention was performed on the femoral head-neck junction. Head-neck offset and alpha angles were evaluated on the frog-leg-lateral hip radiograph (see Appendix). This projection was standardized as previously described<sup>17</sup> by placing the heel of the affected leg against the medial aspect of the contralateral knee. The femoral head-neck offset was measured on the frog-leg lateral radiograph according to the method described by Eijer et al.<sup>17-19</sup>. The alpha angle was measured according to the method described by Nötzli et al.<sup>20</sup>.

Acetabular measurements were made on anteroposterior pelvic and false-profile radiographs (see Appendix). The Tönnis angle<sup>21</sup>, the lateral center-edge angle<sup>22</sup>, and the horizontal position of the hip center were evaluated on the anteroposterior pelvic radiograph<sup>17</sup>. The anterior center-edge angle<sup>23</sup> was evaluated on the false-profile radiograph. The horizontal position of the hip center was the distance from the medial aspect of the femoral head to the ilioischial line. Joint degeneration was classified with the method described by Tönnis et al.<sup>24</sup>. The degree of heterotopic ossification was evaluated on postoperative radiographs and was classified with the method described by Brooker et al.<sup>25</sup>.

Magnetic resonance arthrograms were made selectively for patients with mechanical symptoms of locking and/or catching. In the study group, five of six magnetic resonance arthrogram studies showed a labral tear and two of these tears were repaired surgically. In the comparison group, ten of ten magnetic resonance arthrogram studies showed a labral tear; two of these ten tears were repaired, and two were treated with partial resection. Labral tears were not repaired if they measured  $\leq 10$  mm and were stable to probing.

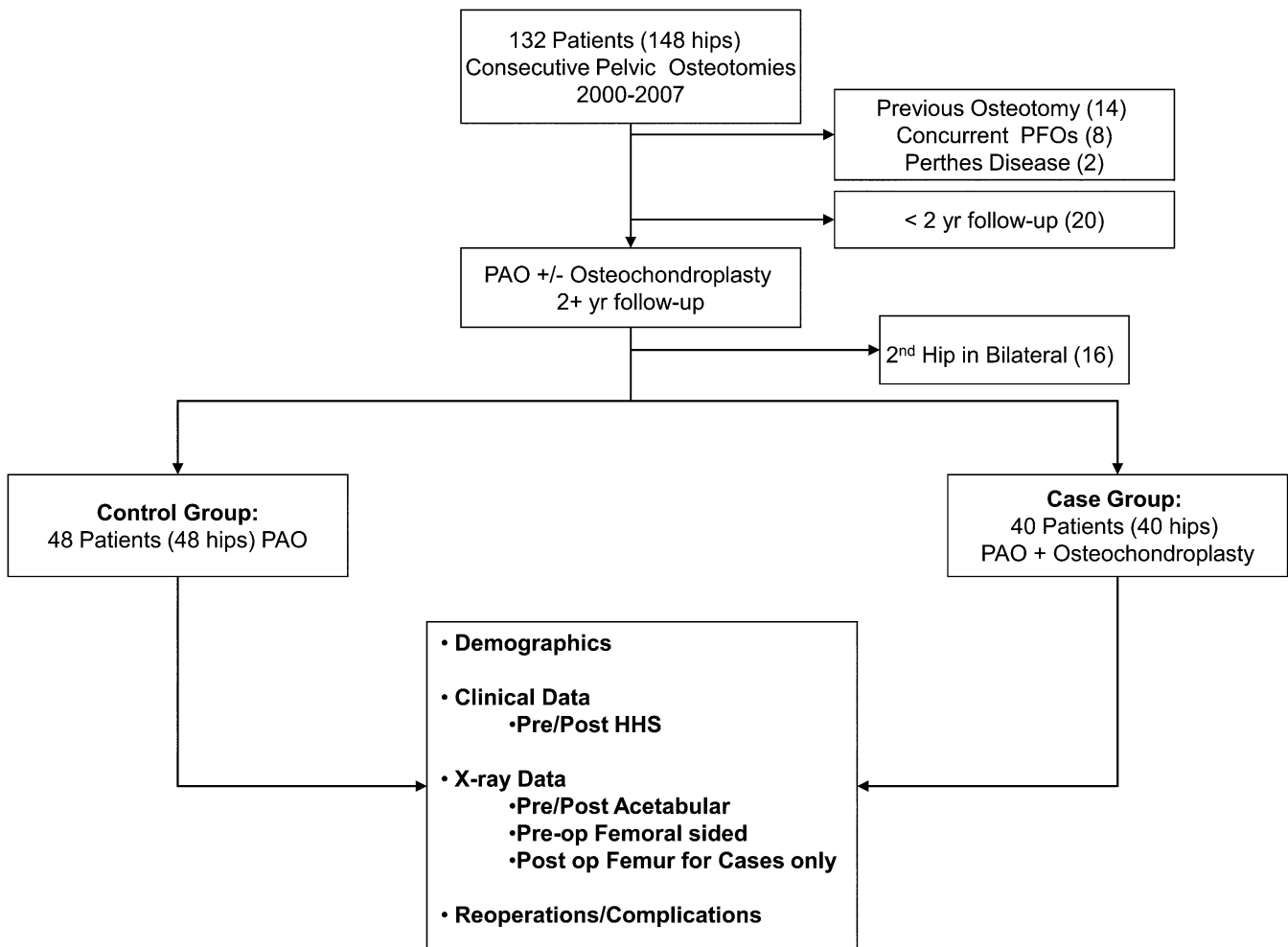


Fig. 1

Schematic diagram of the study design. PAO = periacetabular osteotomy, PFO = proximal femoral osteotomy, and HHS = Harris hip score.

### Surgical Technique

The periacetabular osteotomy was performed as previously described<sup>3</sup> and modified<sup>1,26</sup>. The surgical approach included rectus femoris tendon transection and subsequent repair with nonabsorbable suture. After the osteotomy cuts were completed and the reorientation of the acetabulum had been secured, an arthrotomy was performed if a labral tear and/or femoro-acetabular impingement were suspected. All hips in the study group had an arthrotomy. Ten of the forty-four hips in the comparison group had an arthrotomy to assess for labral tear and/or femoral head-neck junction deformity. Small stable labral tears were not treated. Tears larger than 10 mm with displacement on probing were repaired. Complex tears with degenerative changes were treated with partial resection. Hip motion was assessed with specific attention to flexion and combined flexion and internal rotation. An osteochondroplasty was performed if there was a visible femoral deformity, restricted internal rotation of the hip ( $<20^\circ$  at  $90^\circ$  of flexion), and/or palpable impingement at  $90^\circ$  of hip flexion with combined internal rotation ( $0^\circ$  to  $20^\circ$ ) (Figs. 2-A through 2-D). Adequacy of the head-neck junction osteochondroplasty was determined with direct visualization, dynamic examination, and fluoroscopy.

All patients in both groups were managed with 325 mg of aspirin twice a day for prophylaxis against thromboembolic disease. No prophylaxis was given for heterotopic ossification. All patients in both groups received the same rehabilitation program, featuring six weeks of 30-lb partial weight-bearing and

progressive weight-bearing and strengthening after six weeks. Patients were released to full activity as tolerated four months after surgery.

### Statistical Analysis

The least squares means standard errors from the mixed-model analysis demonstrated that the minimum detectable change in the modified Harris hip score was 8.4 points for a power of 0.80 with use of a two-tailed unpaired t test at the 0.05 level of significance. To our knowledge, there is no currently accepted value for the minimum clinically important difference of the modified Harris hip score; nevertheless, others have reported a 10-point difference as clinically meaningful<sup>27,28</sup>.

Demographic data were compared between the groups with use of the unpaired t test for continuous variables and the chi-square test for categorical variables. The Wilcoxon test was used to compare the duration of follow-up. The Fisher exact test was used to compare reoperation events. The modified Harris hip score data were analyzed with use of mixed-model repeated measures analysis of variance (ANOVA) that included the duration of follow-up as a covariate. Scores were rank-transformed prior to analysis. Preoperative and postoperative radiographic variables were compared between groups with use of the unpaired t test and within groups with use of the paired t test.

### Source of Funding

Funding for personnel support and statistical analysis was received from the Curing Hip Disease Fund.

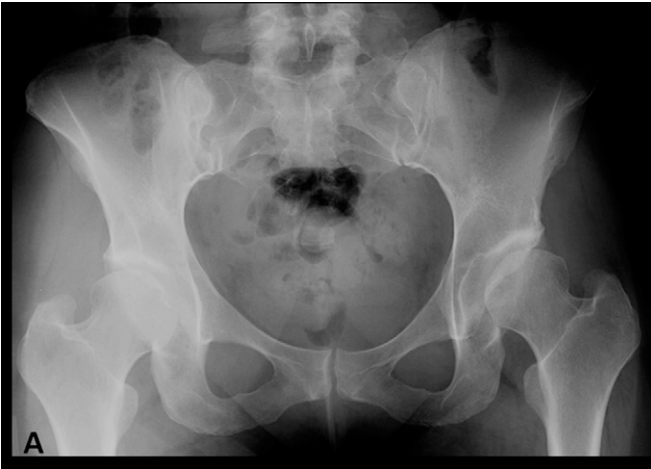

Fig. 2-A

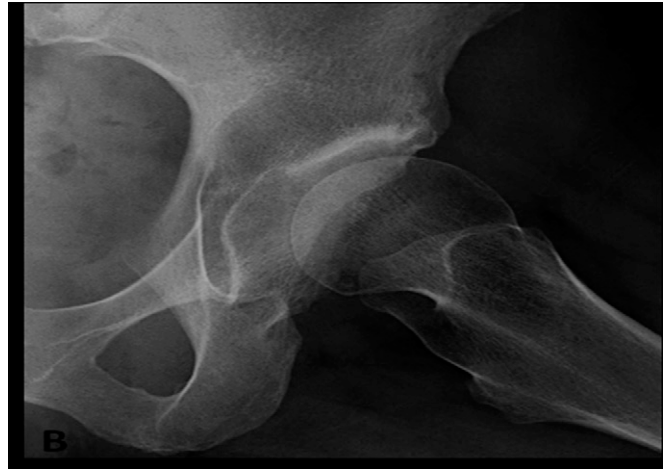

Fig. 2-B

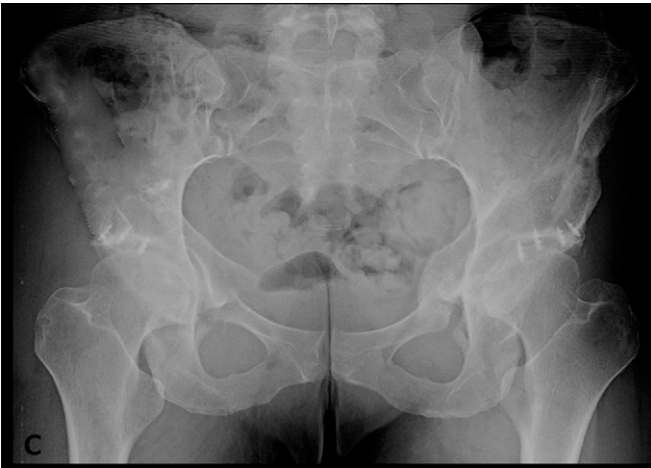

Fig. 2-C

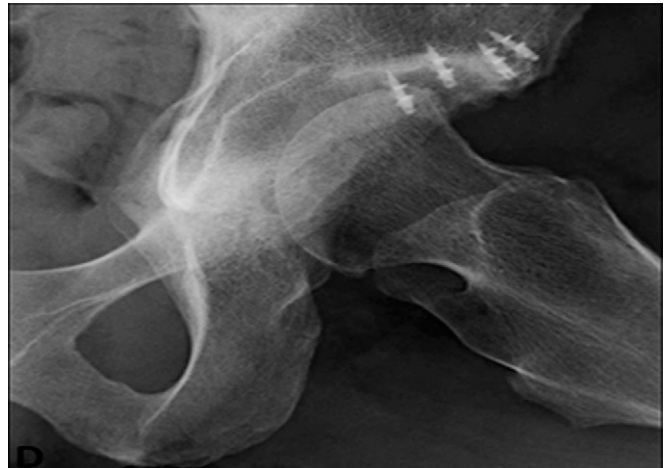


Fig. 2-D

**Figs. 2-A through 2-D** A forty-year-old woman with bilateral symptomatic acetabular dysplasia and femoral head-neck junction deformity underwent a left periacetabular osteotomy in conjunction with an osteochondroplasty and open labral repair. **Figs. 2-A and 2-B** Preoperative radiographs showing acetabular dysplasia with femoral head asphericity and a prominent head-neck junction of the left hip. **Figs. 2-C and 2-D** Postoperative radiographs, made two years after surgery, demonstrating acetabular correction and recontouring of the femoral head-neck junction to prevent secondary femoroacetabular impingement. The patient had the same treatment on the right hip. Both procedures were associated with excellent clinical results.

## Results

Eighty-eight patients (104 hips) with a mean duration of follow-up of 3.4 years were available for the present study (see Appendix). Sixteen patients underwent a bilateral procedure, with only the first procedure being included in the study. The study group included forty patients (forty hips) who had undergone a combined procedure of periacetabular osteotomy and osteochondroplasty between September 2003 and July 2007, whereas the comparison group included forty-eight patients (forty-eight hips) who had undergone periacetabular osteotomy alone between January 2000 and September 2006. There were no significant differences between the groups in terms of sex, age at the time of surgery, or body mass index (see Appendix). The duration of follow-up was significantly different between the study group (mean, 2.8 years; range, 2.0 to 4.6) and the comparison group (mean, 4.1 years; range 2.0 to 9.7 years) ( $p < 0.0001$ ).

## Clinical Outcomes

The mean preoperative modified Harris hip score (and standard deviation) was  $64.3 \pm 13.2$  for the study group and  $63.2 \pm 13.4$  for the comparison group. At the time of the latest follow-up, the mean score in the study group had improved to  $87.4 \pm 14.2$  ( $p < 0.0001$ ) and the mean score in the comparison group had improved to  $87.4 \pm 15.5$  ( $p < 0.0001$ ). There was no significant difference between the groups preoperatively ( $p = 0.71$ ) or at the time of the latest follow-up ( $p = 0.17$ ). There were no conversions to a total hip arthroplasty in any patient in this cohort.

## Radiographic Data

Femoral-side measurements were similar preoperatively in the two groups (Table I). The preoperative head-neck offset was not significantly different between the study group and the comparison group (mean,  $6.03 \pm 3$  compared with  $7.1 \pm$

TABLE I Radiographic Data on the Study and Comparison Groups\*

Variable	Study Group (N = 39)	Comparison Group (N = 44)	P Value (Between Groups)
<b>Head-neck offset (mm)</b>			
Preop.	6.03 ± 3	7.1 ± 3	0.10
Postop.	10.36 ± 2	NA	
Change	4.33 ± 3	NA	NA
P value (within group)	<0.0001	—	
<b>Alpha angle (deg)</b>			
Preop.	56.1 ± 17	56.2 ± 18	0.99
Postop.	39.2 ± 6	NA	
Change	-16.9 ± 16	NA	NA
P value (within group)	<0.0001	—	
<b>Tönnis angle (deg)</b>			
Preop.	23.2 ± 8	23.5 ± 7	0.84
Postop.	8.6 ± 3	8.1 ± 4	
Change	-14.6 ± 7	-15.4 ± 7	0.61
P value (within group)	<0.0001	<0.0001	
<b>Lateral center-edge angle (deg)</b>			
Preop.	8.5 ± 8	6.2 ± 9	0.39
Postop.	23.1 ± 6	25.2 ± 8	
Change	14.6 ± 8	19.0 ± 10	0.04
P value (within group)	<0.0001	<0.0001	
<b>Anterior center-edge angle (deg)</b>			
Preop.	10.0 ± 10 (n = 33)	11.4 ± 16 (n = 28)	0.68
Postop.	26.1 ± 9	30.4 ± 9	
Change	16.1 ± 10	19.0 ± 19	0.45
P value (within group)	<0.0001	<0.0001	
<b>Horizontal position of hip center (mm)</b>			
Preop.	15.7 ± 5	15.5 ± 6	0.86
Postop.	9.1 ± 7	8.2 ± 8	
Change	-6.6 ± 5	-7.3 ± 6	0.58
P value (within group)	<0.0001	<0.0001	

\*NA = not applicable.

3 mm;  $p = 0.10$ ). The alpha angle also was not significantly different between the groups (mean,  $56.1^\circ \pm 17^\circ$  compared with  $56.2^\circ \pm 18^\circ$ ;  $p = 0.99$ ). Postoperatively, the study group had an average improvement of  $4.33 \pm 3$  mm in the head-neck offset ( $p < 0.0001$ ) and an average decrease of  $16.9^\circ \pm 16^\circ$  in the alpha angle ( $p < 0.0001$ ).

Preoperative acetabular deformities were similar between the study and comparison groups, with a mean Tönnis angle of  $23.2^\circ \pm 8^\circ$  and  $23.5^\circ \pm 7^\circ$ , respectively; a decreased mean lateral center-edge angle of  $8.5^\circ \pm 8^\circ$  and  $6.2^\circ \pm 9^\circ$ , respectively; and a decreased mean anterior center-edge angle of  $10.0^\circ \pm 10^\circ$  and  $11.4^\circ \pm 16^\circ$ , respectively ( $p > 0.05$  for all). Surgical correction achieved similar results in terms of the correction of acetabular coverage as determined on the basis of the Tönnis angle ( $p = 0.61$ ) and the anterior center-edge angle ( $p = 0.45$ ). The change in the lateral center-edge angle after surgery was slightly greater in the comparison group than

in the study group ( $19.0^\circ$  compared with  $14.6^\circ$ ;  $p = 0.04$ ). Nevertheless, the final average lateral center-edge angles in the two groups were not significantly different ( $23.1^\circ$  and  $25.2^\circ$ , respectively).

The preoperative Tönnis osteoarthritis grade was also similar in both groups ( $p = 0.71$ ), with the majority of hips demonstrating Tönnis Grade-0 or 1 changes. In the study group, twenty-three hips (59%) were categorized as Grade 0, eleven hips (28.2%) were Grade 1, three hips (7.7%) were Grade 2, and two hips (5.1%) were Grade 3. In the comparison group, twenty-four hips (54.5%) were Grade 0, thirteen hips (29.5%) were Grade 1, and seven hips (15.9%) were Grade 2.

Heterotopic ossification was present in thirty-five of eighty-three patients. Grade-1 or 2 heterotopic ossification was noted in fifteen (38.5%) of thirty-nine hips in the study group (with eight hips having Grade 1 and seven having Grade

2) and in nineteen (43.2%) of forty-four hips in the comparison group (with eight hips having Grade 1 and eleven having Grade 2). One hip in the comparison group had Grade-3 heterotopic ossification but was asymptomatic and required no intervention. No patient in either group required treatment for heterotopic ossification. There was no difference between the groups in terms of heterotopic ossification ( $p = 0.35$ ).

#### *Complications and Reoperations*

There were six complications in the entire cohort, all of which were in the comparison group. One patient had an early deep wound infection that resolved after multiple debridements and a course of antibiotic therapy. One patient had residual lateral femoral cutaneous nerve dysesthesia. Three additional patients underwent a second surgical intervention after the periacetabular osteotomy. One noncompliant patient had loss of reduction and required a revision open reduction and fixation of the acetabulum two months after the index procedure; the symptoms resolved, and the patient was asymptomatic two years after surgery. Another patient had a delayed union of the periacetabular osteotomy site and required revision with bone-grafting one year postoperatively, with healing and resolution of pain. The third patient had screws that appeared to be too close to the joint and underwent a screw exchange at six weeks. The patient had slight occasional pain at the time of the two-year follow-up and was satisfied with the result. One additional patient had development of psoas irritation and required a psoas lengthening; four years following the index procedure, the patient was asymptomatic and had no limitations.

Five additional procedures were performed because of continued hip pain and suspected impingement and labral pathology at an average of 2.8 years (range, 0.6 to 5.2 years) after the index procedure. Four of these procedures were in the comparison group (representing an 8.3% rate of reoperation), and one was in the study group (representing a 2.5% rate of reoperation). Four patients in the comparison group had development of symptoms consistent with labral tears and underwent hip arthroscopy for labral repair. Two of these four patients also underwent reshaping of the head-neck junction. All four patients had resolution of the symptoms. Only one of these four patients had had a capsulotomy at the time of the index procedure, and no labral procedure was performed. The other three had not had an arthrotomy at the time of the index procedure. Only one patient in the study group had development of recurrent hip pain and symptoms of labral tear four years after the index procedure. The patient underwent hip arthroscopy and debridement of a degenerative labral tear. The etiology of this tear was unclear; we speculate that this tear had been present but had not been treated at the time of the index procedure. Hip pain continued to decrease over the first year following arthroscopy. No fractures of the femoral neck or osteonecrosis of the femoral head were noted in this cohort. There were no reoperations for the treatment of symptomatic adhesions or capsular scarring. The difference between the

groups with regard to reoperations for labral tears or impingement was not significant ( $p = 0.37$ ).

#### **Discussion**

The present observational study of eighty-eight hips in eighty-eight patients was intended to assess safety, associated complications and reoperations, and the clinical impact of femoral head-neck junction osteochondroplasty when compared with isolated periacetabular osteotomy. There was no difference between the two groups in terms of hip function. Reoperations were more common in the comparison group, but the difference was not significant with the numbers available. The complication rate was not increased in the study group.

Periacetabular osteotomy provides reliable intermediate and long-term results for patients with symptomatic acetabular dysplasia; however, there is increasing evidence that secondary femoroacetabular impingement may be a cause of ongoing clinical symptoms. Matheny et al.<sup>6</sup> reported an 11% prevalence of continued pain and labral pathology after a mean duration of follow-up of 6.8 years in spite of normal intraoperative findings at the time of the index procedure. All of the patients who had persistent symptoms were managed with arthroscopy. The data in that report are similar to those for our comparison group, in which 8.3% of the patients required a second procedure for the treatment of labral abnormalities and/or femoroacetabular impingement. Troelsen et al.<sup>29</sup> reported an 81.6% survivorship rate at a mean of 9.2 years after periacetabular osteotomy, with 14% of hips requiring total hip replacement at a mean 6.8 years. None of the hips had been treated with osteochondroplasty at the time of the index periacetabular osteotomy. Of the surviving hips, 34% had groin pain, 25% had clicking or locking, and 18% had a positive impingement test. Despite overall good results, these symptoms raise the issue of residual femoroacetabular impingement as a potential contributing factor. In a twenty-year follow-up study on periacetabular osteotomy, Steppacher et al.<sup>7</sup> reported a survival rate of 60.5% and identified six predictors of poor outcomes following the procedure: age, Merle d'Aubigné and Postel score, postoperative impingement sign, preoperative limp, more severe preoperative osteoarthritis, and lower postoperative extrusion index. Of those six factors, a positive postoperative impingement sign carried the highest hazard ratio. Recently, Ziebarth et al.<sup>30</sup> showed that male patients are prone to femoroacetabular impingement after periacetabular osteotomy, with a 47.8% prevalence of a positive impingement sign postoperatively. The authors hypothesized that developmental variances in males may lead to increased risk of femoroacetabular impingement after periacetabular osteotomy. In addition, our group showed that the prevalence of proximal femoral deformity was 92.6% in symptomatic dysplastic hips, with a 73.1% prevalence of decreased head-neck offset<sup>8</sup>. Those studies suggest that periacetabular osteotomy in the setting of femoral head deformities has the potential to provoke secondary femoroacetabular impingement, with resultant labral damage and/or progressive joint degeneration. Over longer periods of follow-up, femoroacetabular impingement could be a source of periacetabular

osteotomy failures<sup>7</sup>. Because of these observations, some surgeons have advocated arthrotomy and femoral head-neck osteochondroplasty for hips that are at risk for secondary femoroacetabular impingement<sup>8,9</sup>. Nevertheless, the addition of this surgical component to the operative procedure is controversial and has not been rigorously investigated. The theoretical clinical benefit of correcting secondary femoroacetabular impingement needs to be balanced with the potential for additional complications of adhesion formation, capsular scarring, heterotopic ossification, femoral neck fracture, and osteonecrosis.

Our study examined two relatively homogeneous patient groups with the diagnosis of symptomatic acetabular dysplasia. Our results demonstrated that, at the time of early follow-up, there was no negative impact of osteochondroplasty of the femoral head-neck junction on hip function, the risk of complications, or the reoperation rate. Osteochondroplasty reliably corrected femoral head-neck malformations. Importantly, we did not observe superior clinical results in the osteochondroplasty group at this duration of follow-up.

The present study does have limitations. Only 73.5% of the hips had false-profile radiographs, resulting in an incomplete data set for anterior center-edge angle values. The discrepancy in the duration of follow-up may result in some bias. Because of the historical nature of this retrospective review, the patients who exclusively underwent periacetabular osteotomy with osteochondroplasty (study group) had a significantly shorter duration of follow-up. The mean duration of follow-up was 2.8 years for the study group and 4.0 years for the comparison group. It is our contention that patients had fully recovered by two years after surgery and that the two to four-year interval represents early follow-up for all patients. Therefore, we do not think that the 1.3-year difference in follow-up duration is clinically important in terms of our reported outcomes. Nevertheless, the complication rates associated with the procedures may be impacted by the longitudinal nature of the study. While there is temporal overlap between these two cohorts, the procedures in the comparison group tended to be performed earlier in the series. The procedures in the study group were performed later, after additional surgeon experience with the procedure. We acknowledge that the higher number of complications observed in the comparison group may be related to this increased surgeon experience over time. Despite this potential difference in surgeon experience, the data indicate that the study group did not have an increased rate of associated complications. It should be emphasized that combined periacetabular osteotomy and osteochondroplasty is associated with a low complication rate in the hands of experienced surgeons. Another limitation of the study is that the analysis of reoperation and complication rates may be underpowered because of the infrequent occurrence of the events and the relatively small size of the patient groups. Nevertheless, our data indicate that the study group had fewer reoperations and complications. Therefore, our conclusions seem appropriate in that the risk of complications was not increased in the study group. We acknowledge that the procedures in the study group were performed after the surgeons

had obtained additional experience with the performance of the periacetabular osteotomy. This issue does not detract from our conclusions regarding the safety and efficacy of performing a concurrent femoral osteochondroplasty<sup>7,29,30</sup>. Finally, although the patient groups had similar demographic characteristics and radiographic structural anatomy, there may be bias toward the study group having more profound head-neck offset deformities that could impact the final clinical results. Nevertheless, our radiographic data did not suggest that this was the case.

On the basis of the present study, performing an osteochondroplasty of the femoral head-neck junction in combination with a periacetabular osteotomy provides equivalent short-term pain relief and functional outcomes without an increase in complications. In addition, intraoperative evaluation and treatment of potential secondary femoroacetabular impingement may decrease the need for reoperation and improve the long-term outcomes of periacetabular osteotomies. Nevertheless, after short-term follow-up, we have not demonstrated superior clinical results in association with an adjunctive femoral osteochondroplasty. Given these data, routine osteochondroplasty is not recommended for all patients undergoing a periacetabular osteotomy. Rather, we recommend consideration of the osteochondroplasty if a femoral head-neck malformation is present and/or if testing suggests a risk for secondary femoroacetabular impingement. The exact indications for femoral osteochondroplasty need to be determined in future investigations. Along these lines, continued follow-up of this cohort is necessary to assess the impact of osteochondroplasty on hip survivorship after periacetabular osteotomy. Studies with larger patient cohorts and more comprehensive clinical outcome data are also needed to determine the role of routine arthrotomy in combination with periacetabular osteotomy and to delineate the specific intra-articular pathologies that should be addressed to avoid late femoroacetabular impingement and/or labral tears.

### Appendix

**eA** Figures showing frog-leg-lateral, anteroposterior pelvic, and false-profile radiographs and a table showing demographic characteristics of the study group and the comparison group are available with the electronic version of this article as a data supplement at [jbjs.org](http://jbjs.org). ■

Note: The authors would like to acknowledge the work of Gail Pashos for her efforts with data collection and patient tracking.

Nader A. Nassif, MD  
Perry L. Schoenecker, MD  
Robert Thorsness, MD  
John C. Clohisy, MD  
Department of Orthopedic Surgery,  
Washington University School of Medicine,  
One Barnes-Jewish Hospital Plaza,  
Suite 11300 West Pavilion,  
St. Louis, MO 63110.  
E-mail address for J.C. Clohisy: [jclohisy@wustl.edu](mailto:jclohisy@wustl.edu)



## References

1. Clohisy JC, Barrett SE, Gordon JE, Delgado ED, Schoenecker PL. Periacetabular osteotomy for the treatment of severe acetabular dysplasia. *J Bone Joint Surg Am.* 2005 Feb;87(2):254-9.
2. Clohisy JC, Schutz AL, St John L, Schoenecker PL, Wright RW. Periacetabular osteotomy: a systematic literature review. *Clin Orthop Relat Res.* 2009 Aug;467(8):2041-52. Epub 2009 Apr 21.
3. Ganz R, Klaue K, Vinh TS, Mast JW. A new periacetabular osteotomy for the treatment of hip dysplasias. Technique and preliminary results. *Clin Orthop Relat Res.* 1988 Jul;(232):26-36.
4. Millis MB, Murphy SB, Poss R. Osteotomies about the hip for the prevention and treatment of osteoarthritis. *Instr Course Lect.* 1996;45:209-26.
5. Trousdale RT. Acetabular osteotomy: indications and results. *Clin Orthop Relat Res.* 2004 Dec;(429):182-7.
6. Matheney T, Kim YJ, Zurakowski D, Matero C, Millis M. Intermediate to long-term results following the Bernese periacetabular osteotomy and predictors of clinical outcome. *J Bone Joint Surg Am.* 2009 Sep;91(9):2113-23.
7. Steppacher SD, Tannast M, Ganz R, Siebenrock KA. Mean 20-year followup of Bernese periacetabular osteotomy. *Clin Orthop Relat Res.* 2008 Jul;466(7):1633-44. Epub 2008 May 1.
8. Clohisy JC, Nunley RM, Carlisle JC, Schoenecker PL. Incidence and characteristics of femoral deformities in the dysplastic hip. *Clin Orthop Relat Res.* 2009 Jan;467(1):128-34. Epub 2008 Nov 26.
9. Myers SR, Eijer H, Ganz R. Anterior femoroacetabular impingement after periacetabular osteotomy. *Clin Orthop Relat Res.* 1999 Jun;(363):93-9.
10. Swiontkowski MF, Thorpe M, Seiler JG, Hansen ST. Operative management of displaced femoral head fractures: case-matched comparison of anterior versus posterior approaches for Pipkin I and Pipkin II fractures. *J Orthop Trauma.* 1992;6(4):437-42.
11. Clohisy JC, Nunley RM, Curry MC, Schoenecker PL. Periacetabular osteotomy for the treatment of acetabular dysplasia associated with major aspherical femoral head deformities. *J Bone Joint Surg Am.* 2007 Jul;89(7):1417-23.
12. Beck M, Kalhor M, Leunig M, Ganz R. Hip morphology influences the pattern of damage to the acetabular cartilage: femoroacetabular impingement as a cause of early osteoarthritis of the hip. *J Bone Joint Surg Br.* 2005 Jul;87(7):1012-8.
13. McGrory BJ, Shinar AA, Freiberg AA, Harris WH. Enhancement of the value of hip questionnaires by telephone follow-up evaluation. *J Arthroplasty.* 1997 Apr;12(3):340-3.
14. Jamali AA, Mladenov K, Meyer DC, Martinez A, Beck M, Ganz R, Leunig M. Anteroposterior pelvic radiographs to assess acetabular retroversion: high validity of the "cross-over-sign". *J Orthop Res.* 2007 Jun;25(6):758-65.
15. Mast NH, Impellizzeri F, Keller S, Leunig M. Reliability and agreement of measures used in radiographic evaluation of the adult hip. *Clin Orthop Relat Res.* 2011 Jan;469(1):188-99. Epub 2010 Jul 2.
16. Nassif NA, Pekmezci M, Pashos G, Schoenecker PL, Clohisy JC. Osseous remodeling after femoral head-neck junction osteochondroplasty. *Clin Orthop Relat Res.* 2010 Feb;468(2):511-8. Epub 2009 Sep 18.
17. Clohisy JC, Carlisle JC, Beaulé PE, Kim YJ, Trousdale RT, Sierra RJ, Leunig M, Schoenecker PL, Millis MB. A systematic approach to the plain radiographic evaluation of the young adult hip. *J Bone Joint Surg Am.* 2008 Nov;90 Suppl 4:47-66.
18. Clohisy JC, Nunley RM, Otto RJ, Schoenecker PL. The frog-leg lateral radiograph accurately visualized hip cam impingement abnormalities. *Clin Orthop Relat Res.* 2007 Sep;462:115-21.
19. Eijer H, Leunig M, Mahomed N, Ganz R. Cross-table lateral radiographs for screening of anterior femoral head-neck offset in patients with femoroacetabular impingement. *Hip Int.* 2001;11:37-41.
20. Nötzli HP, Wyss TF, Stoecklin CH, Schmid MR, Treiber K, Hodler J. The contour of the femoral head-neck junction as a predictor for the risk of anterior impingement. *J Bone Joint Surg Br.* 2002 May;84(4):556-60.
21. Tönnis D, Heinecke A. Acetabular and femoral anteversion: relationship with osteoarthritis of the hip. *J Bone Joint Surg Am.* 1999 Dec;81(12):1747-70.
22. Wiberg G. Studies on dysplastic acetabula and congenital subluxation of the hip joint. With specific reference to the complication of osteoarthritis. *Acta Chir Scand.* 1939;83:28-38.
23. Lequesne M, de Seze . [False profile of the pelvis. A new radiographic incidence for the study of the hip. Its use in dysplasias and different coxopathies]. *Rev Rhum Mal Osteoartic.* 1961 Dec;8:643-52. French.
24. Tönnis D, Legal H, Graf R, editors. *Congenital dysplasia and dislocation of the hip in children and adults.* Berlin: Springer; 1987.
25. Brooker AF, Bowerman JW, Robinson RA, Riley LH Jr. Ectopic ossification following total hip replacement. Incidence and a method of classification. *J Bone Joint Surg Am.* 1973 Dec;55(8):1629-32.
26. Clohisy JC, Barrett SE, Gordon JE, Delgado ED, Schoenecker PL. Periacetabular osteotomy in the treatment of severe acetabular dysplasia. Surgical technique. *J Bone Joint Surg Am.* 2006 Mar;88 Suppl 1 Pt 1:65-83.
27. Byrd JW, Jones KS. Hip arthroscopy in the presence of dysplasia. *Arthroscopy.* 2003 Dec;19(10):1055-60.
28. Nepple JJ, Zebala LP, Clohisy JC. Labral disease associated with femoroacetabular impingement: do we need to correct the structural deformity? *J Arthroplasty.* 2009 Sep;24(6 Suppl):114-9.
29. Troelsen A, Elmengaard B, Søballe K. Medium-term outcome of periacetabular osteotomy and predictors of conversion to total hip replacement. *J Bone Joint Surg Am.* 2009 Sep;91(9):2169-79.
30. Ziebarth K, Balakumar J, Domayer S, Kim YJ, Millis MB. Bernese periacetabular osteotomy in males: is there an increased risk of femoroacetabular impingement (FAI) after Bernese periacetabular osteotomy? *Clin Orthop Relat Res.* 2011 Feb;469(2):447-53.