

10-1-2004

The association of radial deficiency with thumb hypoplasia

Michelle A. James

Shriners Hospitals for Children, Northern California

Hillary D. Green

Shriners Hospitals for Children, Northern California

H. Relton McCarroll Jr.

Shriners Hospitals for Children, Northern California

Paul R. Manske

Washington University School of Medicine in St. Louis

Follow this and additional works at: http://digitalcommons.wustl.edu/open_access_pubs



Part of the [Medicine and Health Sciences Commons](#)

Recommended Citation

James, Michelle A.; Green, Hillary D.; McCarroll, H. Relton Jr.; and Manske, Paul R., "The association of radial deficiency with thumb hypoplasia." *The Journal of Bone and Joint Surgery*.86,10. 2196-2205. (2004).
http://digitalcommons.wustl.edu/open_access_pubs/1089

THE ASSOCIATION OF RADIAL DEFICIENCY WITH THUMB HYPOPLASIA

BY MICHELLE A. JAMES, MD, HILLARY D. GREEN, MD, H. RELTON MCCARROLL JR., MD, AND PAUL R. MANSKE, MD

Investigation performed at Shriners Hospitals for Children, Northern California, Sacramento, California

Background: Congenital longitudinal deficiencies of the radius and thumb are known to be associated with one another; however, the details of their relationship are unknown. The purpose of this study was to determine whether increased severity of radial deficiencies is associated with increased severity of thumb deficiencies and to review the relationship between radial deficiency and reconstructibility of a hypoplastic thumb.

Methods: Radiographs and charts of 227 affected upper extremities of 139 patients with radial longitudinal deficiency were reviewed. The associated thumb deficiency was classified according to a modification of the Blauth and Schneider-Sickert scheme and the radial deficiency was classified according to a modification of the Bayne and Klug criteria for 191 extremities of 119 patients.

Results: The severity of the thumb deficiency was directly proportional to the severity of the radial deficiency ($p < 0.0001$). Half of the extremities had either a thumb deficiency or thumb and carpal deficiencies without radial deficiency. Two-thirds (sixty-three) of the ninety-five limbs with a normal radius had a thumb that could be surgically reconstructed. Seventy-one (91%) of seventy-eight extremities with a thumb amenable to surgical reconstruction had a radius that did not require surgical reconstruction. All extremities with a radial and/or carpal deficiency had a thumb deficiency. Forty-eight (94%) of fifty-one extremities with complete absence of the radius had a thumb that was not reconstructible.

Conclusions: This study supports the growing body of evidence that the components of radial longitudinal deficiency represent a progressive spectrum of upper extremity abnormalities, and a distal progression of severity, with distal structures likely to be more involved than proximal structures.

Level of Evidence: Prognostic study, Level II-1 (retrospective study). See Instructions to Authors for a complete description of levels of evidence.

Longitudinal deficiency of the radius and thumb hypoplasia are complex congenital disorders that may require surgical treatment to maximize hand function. Although the two abnormalities are known to be associated, few studies of large populations of children with these unusual conditions have been published^{1,2}. The prevalence of deficiency of the radial aspect of the forearm and hand is between 1:30,000 and 1:100,000 live births², and the male:female ratio is 3:2^{1,3-5}. The prevalence of bilateral involvement is between 64% (sixty-four of 101)⁶ and 72% (forty-nine of sixty-eight)⁴, and radial deficiency is commonly linked with several syndromes including Holt-Oram syndrome, thrombocytopenia absent radius (TAR) syndrome, Fanconi syndrome, and the VACTERL (vertebral anomalies, anal atresia, cardiac anomalies, tracheoesophageal fistula, renal anomalies, radial anomalies, lung anomalies) association¹⁻¹⁰.

We previously studied a large population of patients with

thumb deficiency to describe associated anomalies and to determine the prevalence of various types of hypoplastic thumbs according to our modification¹⁰ of the Blauth and Schneider-Sickert classification¹¹ (Table I and Figs. 1-A through 1-G). This scheme allows the surgeon to classify thumb hypoplasia on the basis of clinical and radiographic findings in order to determine whether the thumb can be reconstructed or whether thumb ablation and index finger pollicization would be the preferred treatment.

In a subsequent study of this same population¹², we determined that radial deficiency could be classified with a modification of the Bayne and Klug system⁶, which recognizes the spectrum of pathological entities involved in this condition, including radial deficiency, carpal anomalies, and hypoplasia of the thumb. Carpal anomalies are an integral component of radial deficiency and link thumb hypoplasia with radial deficiency. Isolated thumb hypoplasia represents radial deficiency

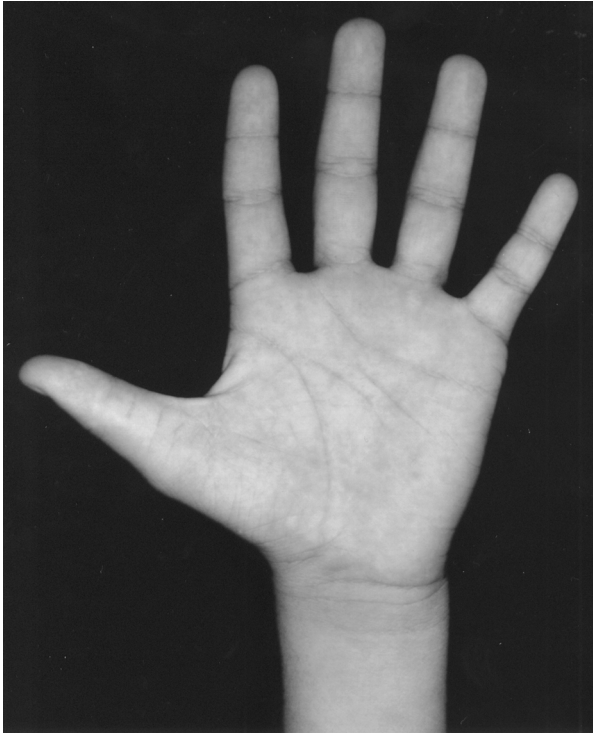


Fig. 1-A

Figs. 1-A through 1-G Types of thumb deficiency. (See Table I and, also, Figs. 2-B and 2-D.) **Fig. 1-A** Type 1. The chief characteristic of Type 1 is hypoplastic thenar muscles, as manifested by flattening of the thenar eminence.

in its mildest form, thumb hypoplasia and carpal anomalies represent an intermediate form, and absence or abnormality of all of the radial structures (thumb, radial carpus, and radius) is at the extreme end of the spectrum^{4,11}. This modified classification system is presented in Table II and illustrated in Figures 2-A through 2-D. Use of this classification also assists in treatment decisions; the type-1 radius usually requires no surgical intervention, whereas the type-2 radius may be amenable to lengthening, and the severely deficient radius (type 3 or 4) may benefit from surgical treatment, including centralization (surgical reduction of the carpus onto the distal end of the ulna).

Both of our previous studies suggested an association between the severity of radial deficiency and the severity of thumb hypoplasia^{10,12}. The purpose of the current study was to determine if increased severity of radial deficiency is associated with increased severity of thumb deficiency. We hypothesized that the degree of radial deficiency would correlate directly with the degree of thumb hypoplasia. Because the degree of thumb hypoplasia determines the reconstructibility of the thumb, we also hypothesized that this relationship could be used to predict the reconstructibility of a hypoplastic thumb.

Materials and Methods

The charts and radiographs of all subjects with a diagnosis of deficiency of the radius or thumb seen at Shriners Hospitals for Children, Northern California, between 1923 and 2002 (124 patients) or seen at the private office of one of the authors (H.R.McC. Jr.) between 1978 and 2000 (fifteen

Fig. 1-B

Bilateral, asymmetric thumb deficiency. The left hand has type-2 thumb deficiency, characterized by a diminutive thumb, thenar muscle hypoplasia, and laxity of the metacarpophalangeal ulnar collateral ligament (not shown). The right hand has type-5 thumb deficiency (an absent thumb).

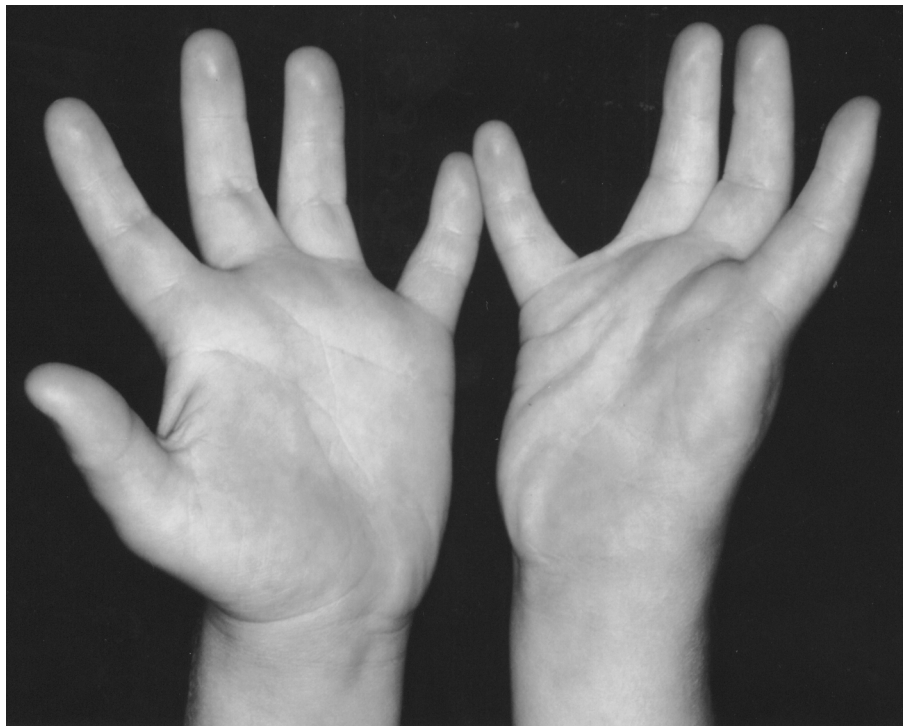


TABLE I Modification ¹⁰ of Blauth and Schneider-Sickert ¹¹ Classification (Key Features Shaded)*			
	Type 1	Type 2	Type 3A
Thumb size	Normal or small	Normal or small	Small
First web	Normal size and location	Distal and tight	Distal and tight
Intrinsic muscles	APB and OP hypoplastic	APB and OP hypoplastic or absent	APB and OP absent or severely hypoplastic
Extrinsic muscles	Normal	Normal or nearly normal	Abnormal: FPL and/or EPL absent or FPL-EPL connection or pollex abductus
Ligaments	Normal	MP UCL lax	MP UCL and possibly RCL lax
Bones and joints	All bones present, maybe hypoplastic	All bones present and hypoplastic	All bones present and hypoplastic

*APB = abductor pollicis brevis, OP = opponens pollicis, FPB = flexor pollicis brevis, FPL = flexor pollicis longus, EPL = extensor pollicis longus, MP UCL = metacarpophalangeal ulnar collateral ligament, and RCL = radial collateral ligament.

patients) were reviewed. Our institutional review board approved the retrospective chart and radiograph review. The findings on physical examination, radiographs, and opera-

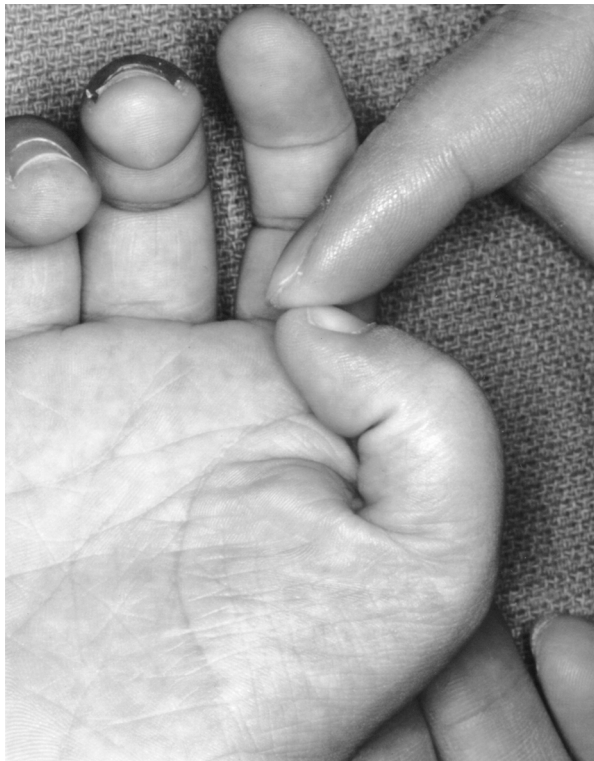

Fig. 1-C

Type 3A, which has all of the characteristics of type 2 with the addition of abnormal extrinsic muscles, resulting in limited motion of the interphalangeal joint, as shown here, or other abnormalities such as pollex abductus.

tive findings for these 139 patients with 227 affected upper extremities were studied to determine if adequate clinical, radiographic, and operative information was available to clas-

sify the radius and thumb malformations according to the modified Bayne and Klug^{6,12} and Blauth and Schneider-Sickert^{10,11} systems and to determine if there were associated malformations that called into question the diagnosis of radial longitudinal deficiency. Subjects were excluded from the

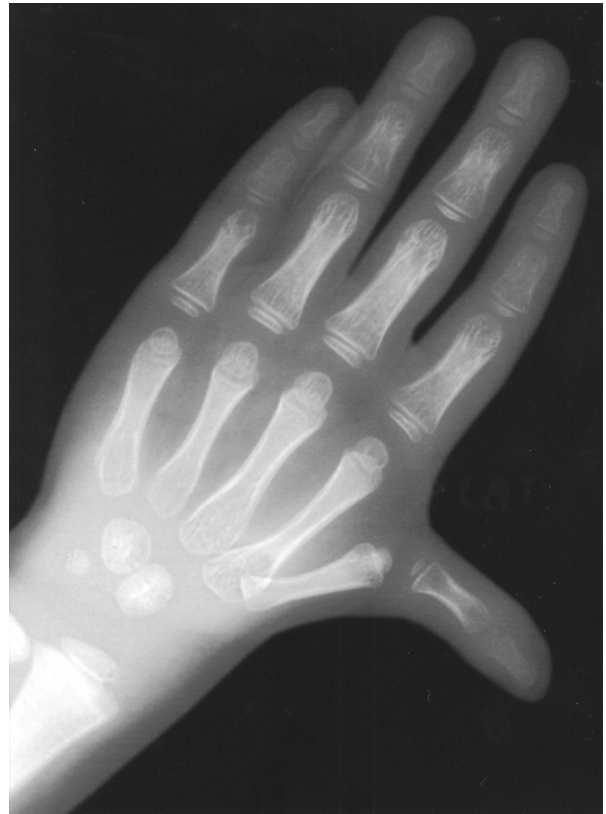

Fig. 1-D

Radiograph of a type-3A thumb deficiency (in a different patient from the one seen in Fig. 1-C). The base of the first metacarpal is small but present, another key feature of type-3A thumbs. This hand also has pollex abductus.

TABLE I (continued)		
Type 3B	Type 4	Type 5
Small	Very small	Absent
Distal and tight		Absent
APB and OP absent or severely hypoplastic	APB, OP, FPB, and adductor absent	APB, OP, FPB, and adductor absent
Abnormal: FPL and/or EPL absent or FPL-EPL connection or pollex abductus	Absent	Absent
MP UCL and possibly RCL lax	Absent	Absent
Proximal metacarpal absent	Metacarpal, trapezium, and scaphoid absent	Phalanges, metacarpal, trapezium, and scaphoid absent

study if inadequate information was available for classification of either the thumb or the radius or if they had an ipsilateral triphalangeal thumb, delta phalanx in the thumb, duplicated thumb, ulnar hypoplasia, aphalangia of fingers, or symbrachydactyly. Six patients (twelve affected extremities) with TAR syndrome were also excluded because the

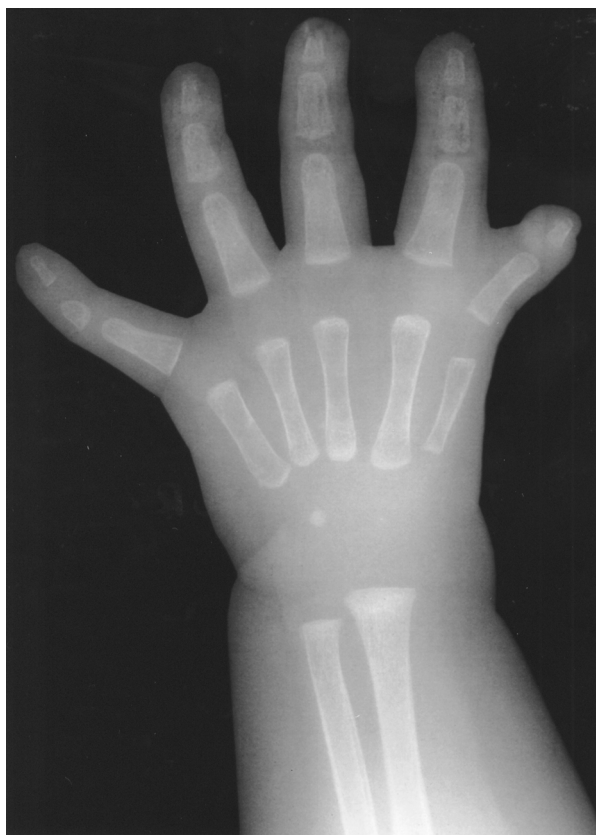

Fig. 1-E
Type 3B. The base of the first metacarpal is absent, which is the key feature of type 3B. Otherwise, type-3B thumbs have the same characteristics as type-3A thumbs.

thumb deficiency could not be classified with use of the modified Blauth and Schneider-Sickert criteria, although all of them had an absent radius and a functioning but abnormal thumb. One hundred and nineteen patients with 191 af-

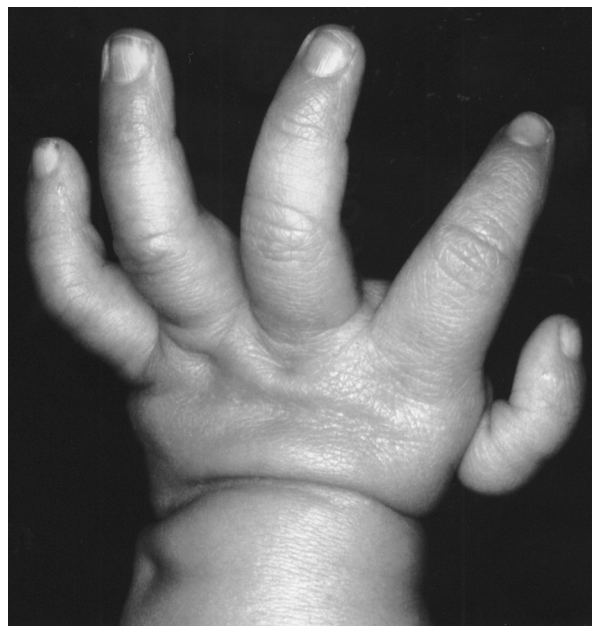

Fig. 1-F
Type 4. Type-4 thumbs are attached by soft tissue only.

ected limbs fit the inclusion criteria for this study. One hundred and four of these patients had been included in the previous study of the classification of radial deficiency¹², and ninety-eight had been included in the previous study of thumb deficiency¹⁰.

Seventy-two patients (61%) were male, and forty-seven (39%) were female. Seventy-two patients (61%) had bilateral involvement, and thirty-three (70%) of the forty-seven patients who had unilateral deficiency were affected on the right.

TABLE II Modification¹² of Bayne and Klug⁶ Classification of Radial Longitudinal Deficiency

Type	Thumb	Carpus	Distal Part of Radius	Proximal Part of Radius
N	Hypoplastic or absent	Normal	Normal	Normal
0	Hypoplastic or absent	Absence, hypoplasia, or coalition	Normal	Normal, radioulnar synostosis, or congenital dislocation of radial head
1	Hypoplastic or absent	Absence, hypoplasia, or coalition	>2 mm shorter than ulna	Normal, radioulnar synostosis, or congenital dislocation of radial head
2	Hypoplastic or absent	Absence, hypoplasia, or coalition	Hypoplasia	Hypoplasia
3	Hypoplastic or absent	Absence, hypoplasia, or coalition	Physis absent	Variable hypoplasia
4	Hypoplastic or absent	Absence, hypoplasia, or coalition	Absent	Absent

Forty-eight (67%) of the seventy-two children with bilateral radial deficiency had asymmetric severity.

Twelve associated syndromes were diagnosed in fifty-

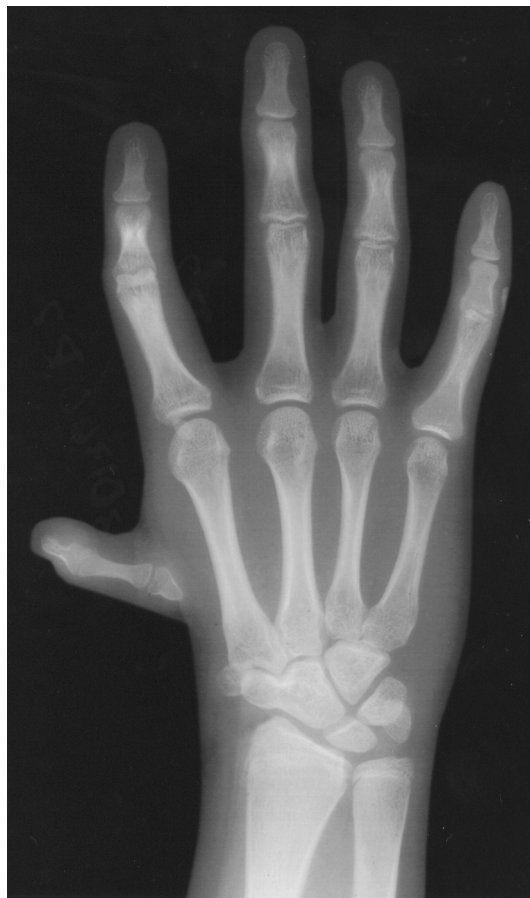

Fig. 1-G

Radiograph of type-4 thumb deficiency (in a different patient from the one seen in Fig. 1-F). This limb also has a type-0 radial deficiency (scaphoid-trapezoid-capitate coalition with a radius of normal length).

five patients (46%) (Table III). Bilateral involvement was more common in children with a syndrome; 78% had bilateral deficiency, and 22% had a unilateral anomaly (Table IV). Children with bilateral deficiency were more likely to have a syndrome: 60% had a syndrome compared with 26% of the children with unilateral deficiency (Table IV). The true prevalence of syndromes in this population is probably higher than we detected, as genetic consultation was not available at our institution before 1978. Twenty patients in this series were born before 1960 and thus were ineligible for care at Shriners Hospital by 1978.

Thumb deficiency was classified according to a modification of the scheme described by Blauth and Schneider-Sickert^{10,11}. Classification with this system requires detailed clinical examination and adequate radiographs (Table I and Figs. 1-A through 1-G). Important structures for classification include the size of the first web space, the presence and function of the intrinsic and extrinsic muscles of the thumb, the presence and function of the collateral ligaments of the metacarpophalangeal joint, and the presence and size of the bones of the first ray. Types 1, 2, and 3A thumbs can be reconstructed surgically (although type 1 does not usually require reconstruction). Types 3B, 4, and 5 are treated with ablation of the thumb, if present, and pollicization of the index finger. For six patients, sufficient information was available to determine

TABLE III Associated Syndromes

Syndrome	No. of Patients
VACTERL	22
Holt-Oram	21
Nager	2
Juberg-Hayward	2 (identical twins)
Fanconi anemia	1
Other	7
Total	55

TABLE IV Bilateral and Unilateral Deficiency According to Whether the Patient Had a Syndrome

	Deficiency (no. of patients)		
	Bilateral	Unilateral	Total
Syndrome	43	12	55
No known syndrome	29	35	64
Total	72	47	119

that they had either a type-2 or type-3A thumb, but there was not enough information to determine between these two types. Thus, for the purposes of statistical analysis, types 2 and 3A were combined (Table V).

Radial longitudinal deficiency was classified according to our modification of the Bayne and Klug criteria^{6,12}. This system is based on radiographic evaluation of both the radius and the carpus (Table II and Figs. 2-A through 2-D). Several carpal anomalies are seen in association with radial and thumb deficiency, including hypoplasia and absence of the scaphoid, trapezium, and lunate as well as carpal coalitions. Normal radiographic ossification of the scaphoid begins by the age of eight years^{13,14}, and therefore only children eight years of age and older at the time of the most recent radiographic examination were classified as having an absent scaphoid (type 0). Children who were seven years of age or younger were classified as having a type-N or 0 deficiency. Since the classification of type-N radii in children who are less than eight years old may change as the children grow older, types N and 0 were combined into one category for the statistical analysis (Table V).

Statistical Analysis

The correlation between thumb deficiency and radial deficiency was analyzed with use of Spearman rho and Kendall tau with significance determined by $p < 0.01$.

Results

Radial deficiency was highly correlated with thumb deficiency; all extremities with radial or carpal deficiency had thumb deficiency (Table V). Ninety-five (50%) of the 191 extremities had thumb deficiency with no radial deficiency (type N) or thumb and carpal deficiency with no radial deficiency (type 0). Forty-eight (94%) of the fifty-one limbs with complete absence of the radius (type-4 radial deficiency) had a non-reconstructible thumb (type-4 or 5 thumb deficiency), whereas sixty-three (66%) of the ninety-five limbs with a normal radius had a reconstructible thumb (type-1, 2, or 3A thumb deficiency).

In addition, seventy-one (91%) of the seventy-eight extremities with a reconstructible thumb (type 1, 2, or 3A) had a radius that was either of normal length or did not require surgical reconstruction (type N, 0, or 1). Of the 113 extremities with a non-reconstructible thumb (type 3B, 4, or 5), fifty-eight (51%) had a type-2, 3, or 4 radius.

Spearman rho and Kendall tau calculations both showed a highly significant and positive association between the severity of radial deficiency and the severity of thumb deficiency as classified with the modified Blauth and Schneider-Sickert and Bayne and Klug systems, with a p value of <0.0001 for both. The Spearman correlation was 0.6007, and the Kendall correlation was 0.5260.

Discussion

The underlying cause of thumb and radial deficiencies and their true relationship with each other remain unknown. In this clinical series of patients with thumb and radial deficiencies, proximal deficiency (i.e., of the radius) was always associated with distal deficiency, but distal deficiency often occurred in isolation. Several authors have reported the association of thumb deficiency with radial deficiency^{1-6,15-17}. Previous descriptions have focused on the association between thumb deficiency and carpal anomalies¹⁸⁻²⁰ as well as the association between radial deficiency and carpal anomalies^{5,16}. Published case reports

TABLE V Occurrence of Radial and Thumb Types*

Thumb Type†	Radial Type‡					Total
	N or 0	1	2	3	4	
1	6					6
2 or 3A	57	8	3§	1§	3§	72
3B	7	4	1			12
4	15	7	1	3	14	40
5	10	12		5	34	61
Total	95	31	5	9	51	191

*Blue = thumb deficiency with no radial deficiency, red = non-reconstructible thumb and absent radius, light blue = reconstructible thumb and normal radius, green = reconstructible thumb and radius that is deficient but does not require reconstruction, and yellow = non-reconstructible thumb and very deficient radius. †Thumb types 2, 3A, and "2 or 3A" have been combined. ‡Radial types N, 0, and "N or 0" have been combined. §Five of these seven extremities belonged to three patients, two with VACTERL association and one with Goldenhar syndrome.

of carpal deficiency have usually described either thumb and/or radial deficiency coexisting with carpal abnormality^{16,19,21-26}; isolated carpal absence is extremely rare²⁶⁻²⁹ and did not occur in our series. Patients with TAR syndrome were excluded from our series because the thumb deficiency could not be classified with use of the modified Blauth and Schneider-Sickert classification. These patients all have type-4 radial deficiency and do not appear to have distal progression of severity.

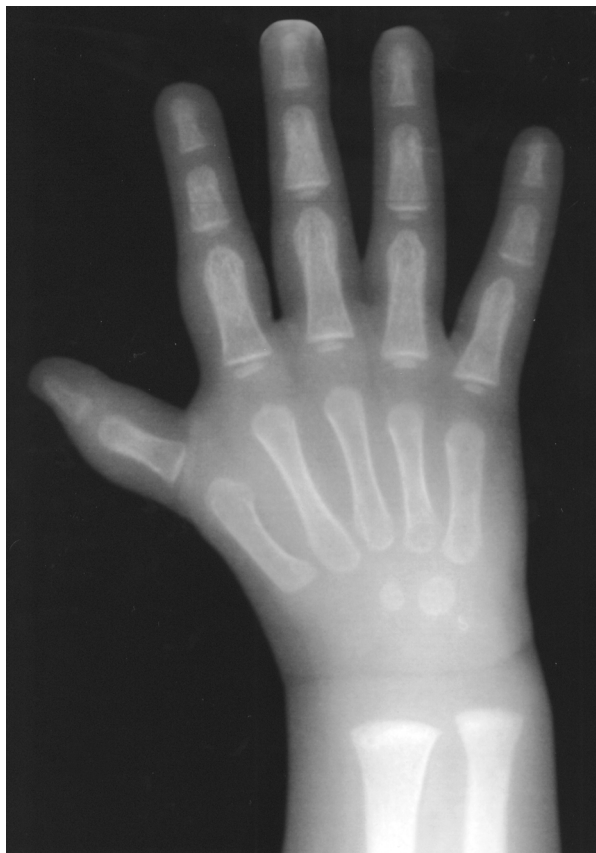

Fig. 2-A

Although the etiology of radial deficiency is unknown, it is certainly multifactorial. Specific genes are known to be associated with limb development³⁰, and some cases of radial deficiency are clearly genetic. Associations with multiple congenital anomaly syndromes suggest that radial deficiency may occur with the deletion of chromosome 22q11³¹. Holt-Oram syndrome appears to be heterogeneous, with linkage to gene map locus 12q24.1 in some cohorts and TBX5 gene mutations in others³²⁻³⁴. Fanconi anemia has been mapped to gene locus 16q24.3³⁵, and diagnosis with chromosomal breakage analysis has made it possible to treat this previously fatal aplastic anemia with bone marrow transplantation³⁶⁻³⁸. TAR syndrome has not yet been mapped³⁹.

Thus, thumb deficiency is associated with many syndromes mapped to numerous loci throughout the genome. Other heritable thumb malformations, such as triphalangeal thumb and thumb polydactyly, have been mapped to chromosome 7q36⁴⁰.

Fetal exposure to toxins such as thalidomide can cause radial deficiency. It is possible that some cases of radial deficiency are caused by unknown environmental toxins that interrupt longitudinal development of the upper limb when the fetus is exposed to them at a critical phase of development. Unique features of individual digits are known to develop in utero in response to the zone of polarizing activity, a specialized area of the posterior apical epidermal ridge⁴¹. In the vertebrate limb bud, signals from the zone of polarizing activity are known to control the pattern of cellular differentiation in a radioulnar direction⁴¹⁻⁴³. The zone of polarizing activity, through mechanisms currently under investigation, has some regulatory power over the apical epidermal ridge⁴¹. Digit formation is also under the control of the zone of polarizing activity, which seems to be responsible for ordering digit type and number⁴⁴ and is therefore potentially responsible for forming the unique features of the thumb. As early as 1977, Lamb suggested a localized absence of the apical epidermal ridge as a cause for radial deficiencies⁴. More recently, sonic hedgehog protein (Shh) has been shown to mediate the activity of the

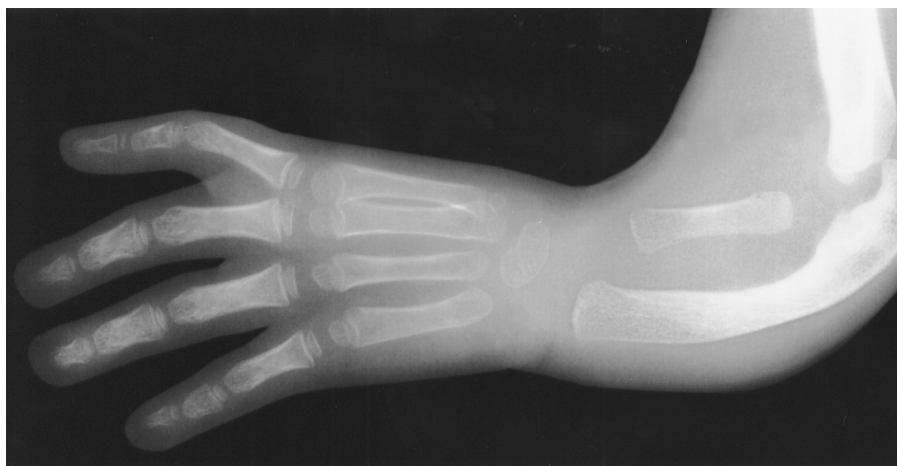

Fig. 2-B

Figs. 2-A through 2-D Types of radial deficiency. (See Table II and, also, Fig. 1-G.) **Fig. 2-A** Type 1. **Fig. 2-B** Type 2, with type-5 thumb deficiency.

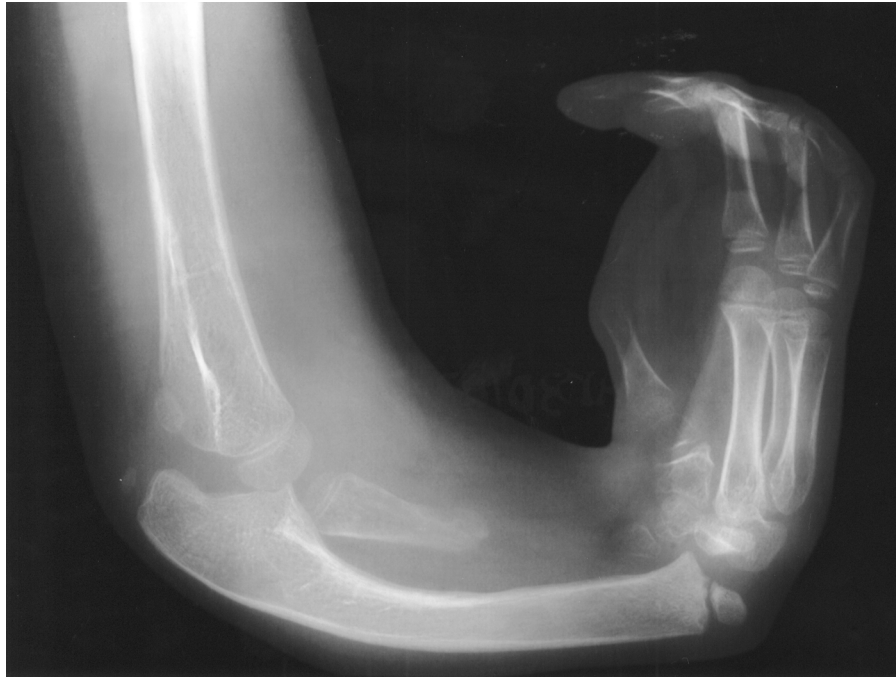

Fig. 2-C
Type 3, with a pollicized index finger.

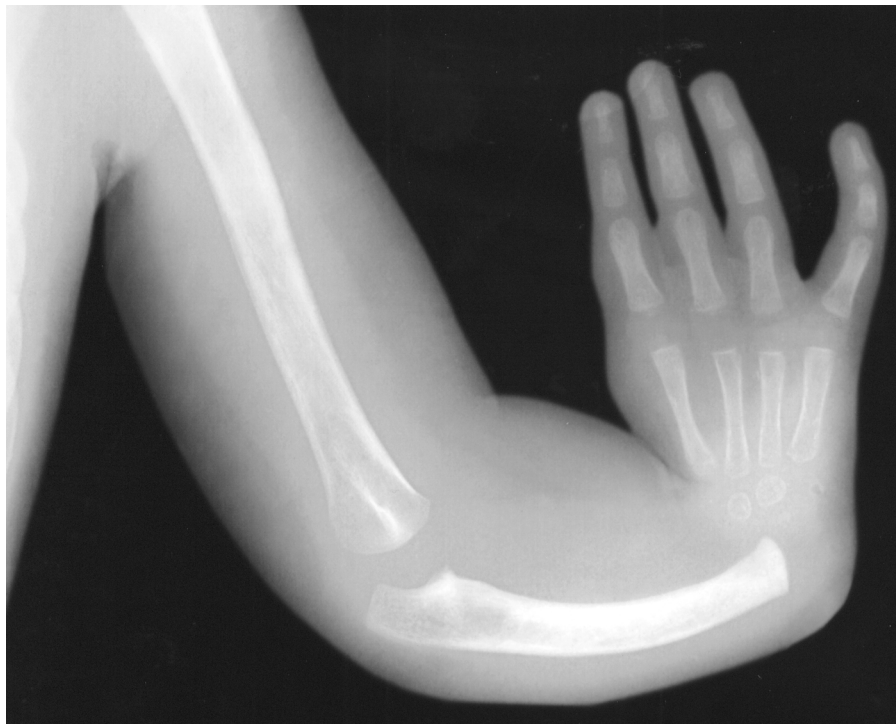

Fig. 2-D
Type 4, with a type-5 thumb deficiency.

zone of polarizing activity⁴⁵, and, in mice, disruption of the Shh pathway has been associated with a spectrum of developmental anomalies very similar to VACTERL⁴⁶.

The interaction of the apical epidermal ridge with the underlying undifferentiated mesoderm is responsible for limb outgrowth in a proximal-to-distal direction, with proximal

structures being formed first⁴⁴. The known precedence of proximal development supports our clinical finding that radial deficiency is always associated with thumb deficiency, but thumb deficiency can occur in isolation. However, proximal-to-distal development is extremely complex and not yet completely understood; it would be an oversimplification to conclude that the development of distal structures depends solely on the antecedent development of proximal structures. TAR syndrome, in which a type-4 radius is consistently associated with a relatively well-developed thumb, refutes this conclusion.

The impetus for this study was an observation in previous investigations that the majority of patients with radial deficiency had thumb deficiency¹². The specific aim was to determine if radial deficiency correlated with thumb hypoplasia and to thereby determine if the degree of radial deficiency was associated with the reconstructibility of the thumb. We found that radial deficiency always occurred in the presence of thumb deficiency and, when classified according to well-established systems that can be used to predict prognosis and guide treatment, the severity of thumb deficiency was proportional to the severity of radial deficiency ($p < 0.0001$). Furthermore, extremities with type-4 radial deficiency nearly always had a non-reconstructible thumb.

This study adds to a growing body of evidence that thumb hypoplasia and radial longitudinal deficiency are part

of a spectrum of abnormal upper-extremity development rather than independent processes. The severity of these malformations progresses distally and thus the presence of a severe radial deficiency signals the presence of a severely deficient or absent thumb. ■

NOTE: The authors acknowledge Kent Yinger, MD, for his assistance with the chart and radiographic review.

Michelle A. James, MD
Hillary D. Green, MD
H. Relton McCarroll Jr., MD
Department of Orthopaedic Surgery, Shriners Hospitals for Children,
Northern California, 2425 Stockton Boulevard, Sacramento, CA 95817.
E-mail address for M.A. James: mjames@shrinenet.org

Paul R. Manske, MD
Department of Orthopaedic Surgery, Washington University School
of Medicine, 660 South Euclid Avenue, Campus Box 8233, St. Louis,
MO 63110

The authors did not receive grants or outside funding in support of their research or preparation of this manuscript. They did not receive payments or other benefits or a commitment or agreement to provide such benefits from a commercial entity. No commercial entity paid or directed, or agreed to pay or direct, any benefits to any research fund, foundation, educational institution, or other charitable or nonprofit organization with which the authors are affiliated or associated.

References

1. **Heikel HV.** Aplasia and hypoplasia of the radius: studies on 64 cases and on epiphyseal transplantation in rabbits with the imitated defect. *Acta Orthop Scand.* 1959;Suppl 39:1-155.
2. **Flatt AE.** *The care of congenital hand anomalies.* 2nd ed. St. Louis: Quality Medical Publishing; 1993. Radial clubhand; p 366-410.
3. **Flatt AE.** *The care of congenital hand anomalies.* 2nd ed. St. Louis: Quality Medical Publishing; 1993. The absent thumb; p 96-119.
4. **Lamb DW.** Radial club hand. A continuing study of sixty-eight patients with one hundred and seventeen club hands. *J Bone Joint Surg Am.* 1977;59:1-13.
5. **Riordan DC.** Congenital absence of the radius. *J Bone Joint Surg Am.* 1955;37:1129-40.
6. **Bayne LG, Klug MS.** Long-term review of the surgical treatment of radial deficiencies. *J Hand Surg [Am].* 1987;12:169-79.
7. **McKusick VA.** VATER association. In: *Online Mendelian inheritance in man, OMIM (TM).* Johns Hopkins University. www.ncbi.nlm.nih.gov/entrez/dispomim.cgi?id=192350.
8. **Lamb DW, Scott H, Lam WL, Gillespie WJ, Hooper G.** Operative correction of radial club hand. A long-term follow-up of centralization of the hand on the ulna. *J Hand Surg [Br].* 1997;22:533-6.
9. **Manske PR, McCarroll HR Jr, James M.** Type III-A hypoplastic thumb. *J Hand Surg [Am].* 1995;20:246-53.
10. **James MA, McCarroll HR Jr, Manske PR.** Characteristics of patients with hypoplastic thumbs. *J Hand Surg [Am].* 1996;21:104-13.
11. **Blauth W, Schneider-Sickert F.** *Congenital deformities of the hand: an atlas on their surgical treatment.* New York: Springer; 1981. Numerical variations; p 120-1.
12. **James MA, McCarroll HR Jr, Manske PR.** The spectrum of radial longitudinal deficiency: a modified classification. *J Hand Surg [Am].* 1999;24:1145-55.
13. **Greulich WW, Pyle SI.** *Radiographic atlas of skeletal development of the hand and wrist.* Stanford, CA: Stanford University Press; 1959.
14. **Hensinger RN.** *Standards in pediatric orthopedics: tables, charts, and graphs illustrating growth.* New York: Raven Press; 1986. Upper extremity; p 136-49.
15. **O'Rahilly R.** Morphological patterns in limb deficiencies and duplications. *Am J Anat.* 1951;89:135-93.
16. **Skerik SK, Flatt AE.** The anatomy of congenital radial dysplasia. Its surgical and functional implications. *Clin Orthop.* 1969;66:125-43.
17. **Kato K.** Congenital absence of the radius. With review of literature and report of three cases. *J Bone Joint Surg Am.* 1924;6:589-626.
18. **O'Rahilly R.** Radial hemimelia and the functional anatomy of the carpus. *J Anat.* 1946;80:179-83.
19. **Imamura T, Miura T.** The carpal bones in congenital hand anomalies: a radiographic study in patients older than ten years. *J Hand Surg [Am].* 1988;13:650-6.
20. **Tsuyuguchi Y, Yukioka M, Kawabata H, Kawai H, Ono K.** Radial ray deficiency. *J Pediatr Orthop.* 1987;7:699-704.
21. **Bonatz E, Masear VR, Meyer RD, Cohen S.** Degenerative arthritis of the carpus associated with congenital hypoplastic thumb. *J Hand Surg [Am].* 1989;14:734-6.
22. **Davison EP.** Congenital hypoplasia of the carpal scaphoid bone. *J Bone Joint Surg Br.* 1962;44:816-27.
23. **Hall RF Jr, Keuhn D Jr, Prieto J.** Congenital hypoplasia of the thumb ray with absent carpal navicular and hypertrophic styloid process of the radius: a case report. *J Hand Surg [Am].* 1986;11:32-5.
24. **Hanley T, Conlon PC.** Congenital deformity of the carpus associated with maldevelopment of certain thenar muscles. *J Bone Joint Surg Br.* 1957;39:458-62.
25. **Hodgson AR.** Congenital retardation in development of the carpal navicular, first metacarpal, and styloid process of the radius. *Br J Surg.* 1943;31:95-6.
26. **O'Rahilly R.** A survey of carpal and tarsal anomalies. *J Bone Joint Surg Am.* 1953;35:626-42.
27. **Kuz JE, Smith JM.** Congenital absence of the scaphoid without other congenital abnormality: a case report. *J Hand Surg [Am].* 1997;22:489-91.
28. **Patankar H.** Bilateral congenital aplasia of the scaphoid. *J Hand Surg [Br].* 1998;23:817-9.
29. **Srivastava KK, Kochhar VL.** Congenital absence of the carpal scaphoid. A case report. *J Bone Joint Surg Am.* 1972;54:1782.

30. **Upholt WB.** Homeobox genes and limb development. In: Buckwalter JA, Ehrlich MG, Sandell LF, Trippel SB, editors. *Skeletal growth and development: clinical issues and basic science advances*. 1st ed. Rosemont, IL: American Academy of Orthopaedic Surgeons; 1998. p 71-86.
31. **Digilio MC, Giannotti A, Marino B, Guadagni AM, Orzalesi M, Dallapiccola B.** Radial aplasia and chromosome 22q11 deletion. *J Med Genet.* 1997;34:942-4.
32. **Basson CT, Bachinsky DR, Lin RC, Levi T, Elkins JA, Soultis J, Grayzel D, Kroumpouzou E, Traill TA, Leblanc-Straceski J, Renault B, Kucherlapati R, Seidman JG, Seidman CE.** Mutations in human TBX5 [corrected] cause limb and cardiac malformation in Holt-Oram syndrome. *Nat Genet.* 1997;15:30-5. Erratum in: *Nat Genet.* 1997;15:411.
33. **Basson CT, Cowley GS, Solomon SD, Weissman B, Poznanski AK, Traill TA, Seidman JG, Seidman CE.** The clinical and genetic spectrum of the Holt-Oram syndrome (heart-hand syndrome). *N Engl J Med.* 1994;330:885-91. Erratum in: *N Engl J Med.* 1994;330:1627.
34. **Basson CT, Huang T, Lin RC, Bachinsky DR, Weremowicz S, Vaglio A, Bruzone R, Quadrelli R, Lerone M, Romeo G, Silengo M, Pereira A, Krieger J, Mesquita SF, Kamisago M, Morton CC, Pierpont ME, Muller CW, Seidman JG, Seidman CE.** Different TBX5 interactions in heart and limb defined by Holt-Oram syndrome mutations. *Proc Natl Acad Sci U S A.* 1999;96:2919-24.
35. **McKusick VA.** Fanconi anemia; FA. In: *Online Mendelian inheritance in man, OMIM (TM)*. Johns Hopkins University. www.ncbi.nlm.nih.gov/entrez/dispomim.cgi?id=227650.
36. **Gluckman E.** Allogeneic bone marrow transplantation in Fanconi anemia. *Bone Marrow Transplant.* 1996;18 Suppl 2:140-4.
37. **Verlinsky Y, Rechitsky S, Schoolcraft W, Strom C, Kuliev A.** Preimplantation diagnosis for Fanconi anemia combined with HLA matching. *JAMA.* 2001;285:3130-3.
38. **Josefson D.** Couple select healthy embryo to provide stem cells for sister. *BMJ.* 2000;321:917.
39. **McKusick VA.** Thrombocytopenia—absent radius syndrome. In: *Online Mendelian inheritance in man, OMIM (TM)*. Johns Hopkins University. www.ncbi.nlm.nih.gov/entrez/dispomim.cgi?id=274000.
40. **Hing AV, Helms C, Slauch R, Burgess A, Wang JC, Herman T, Downton SB, Donis-Keller H.** Linkage of preaxial polydactyly type 2 to 7q36. *Am J Med Genet.* 1995;58:128-35.
41. **Carlson BM.** *Human embryology and developmental biology*. 2nd ed. St. Louis: Mosby; 1999. Limb development; p 184-207.
42. **Tickle C.** Experimental embryology as applied to the upper limb. *J Hand Surg [Br]*. 1987;12:294-300.
43. **Niswander L, Jeffrey S, Martin GR, Tickle C.** A positive feedback loop coordinates growth and patterning in the vertebrate limb. *Nature.* 1994;371:609-12.
44. **Zaleske DJ.** Overview of musculoskeletal development. In: Buckwalter JA, Ehrlich MG, Sandell LF, Trippel SB, editors. *Skeletal growth and development: clinical issues and basic science advances*. 1st ed. Rosemont, IL: American Academy of Orthopaedic Surgeons; 1998. p 5-16.
45. **Riddle RD, Johnson RL, Laufer E, Tabin C.** Sonic hedgehog mediates the polarizing activity of the ZPA. *Cell.* 1993;75:1401-16.
46. **Kim J, Kim P, Hui CC.** The VACTERL association: lessons from the Sonic hedgehog pathway. *Clin Genet.* 2001;59:306-15.