

## Washington University School of Medicine Digital Commons@Becker

---

Open Access Publications

---

8-1-2005

# Arthrodesis techniques in the management of stage-II and III acquired adult flatfoot deformity

Jeffrey E. Johnson

*Washington University School of Medicine in St. Louis*

James R. Yu

*Washington University School of Medicine in St. Louis*

Follow this and additional works at: [http://digitalcommons.wustl.edu/open\\_access\\_pubs](http://digitalcommons.wustl.edu/open_access_pubs)

 Part of the [Medicine and Health Sciences Commons](#)

---

### Recommended Citation

Johnson, Jeffrey E. and Yu, James R., "Arthrodesis techniques in the management of stage-II and III acquired adult flatfoot deformity." *The Journal of Bone and Joint Surgery*.87,8. 1865-1876. (2005).  
[http://digitalcommons.wustl.edu/open\\_access\\_pubs/831](http://digitalcommons.wustl.edu/open_access_pubs/831)

This Open Access Publication is brought to you for free and open access by Digital Commons@Becker. It has been accepted for inclusion in Open Access Publications by an authorized administrator of Digital Commons@Becker. For more information, please contact [engeszer@wustl.edu](mailto:engeszer@wustl.edu).



SELECTED  
**INSTRUCTIONAL  
COURSE  
LECTURES**

**THE AMERICAN ACADEMY OF ORTHOPAEDIC SURGEONS**

*Printed with permission of the American Academy of Orthopaedic Surgeons. This article, as well as other lectures presented at the Academy's Annual Meeting, will be available in February 2006 in Instructional Course Lectures, Volume 55. The complete volume can be ordered online at [www.aaos.org](http://www.aaos.org), or by calling 800-626-6726 (8 A.M.-5 P.M., Central time).*

**TERRY R. LIGHT**  
EDITOR, VOL. 55

**COMMITTEE**

**TERRY R. LIGHT**  
CHAIRMAN

**PAUL J. DUWELIUS**  
**DAVID L. HELFET**  
**J. LAWRENCE MARSH**  
**VINCENT D. PELLEGRINI JR.**

**EX-OFFICIO**

**DEMPSEY S. SPRINGFIELD**  
DEPUTY EDITOR OF THE JOURNAL OF BONE AND JOINT SURGERY  
FOR INSTRUCTIONAL COURSE LECTURES

**JAMES D. HECKMAN**  
EDITOR-IN-CHIEF,  
THE JOURNAL OF BONE AND JOINT SURGERY



# ARTHRODESIS TECHNIQUES IN THE MANAGEMENT OF STAGE-II AND III ACQUIRED ADULT FLATFOOT DEFORMITY

BY JEFFREY E. JOHNSON, MD, AND JAMES R. YU, MD

*An Instructional Course Lecture, American Academy of Orthopaedic Surgeons*

Arthrodesis is indicated for the management of an acquired adult flatfoot disorder with a fixed deformity or degenerative joint disease. In general, limited fusions of the hindfoot and midfoot preserve more motion than do extensive fusion procedures such as triple arthrodesis. However, full correction of the deformity is important for a durable outcome, and this may require a more extensive fusion procedure or the inclusion of adjunctive procedures.

Triple arthrodesis provides the most reliable and predictable correction of a fixed deformity. Careful preoperative and intraoperative physical examination and radiographic evaluation are critical to developing an operative plan that will address all of the components of this complex deformity and to minimizing the chance of its recurrence.

Posterior tibial tendon dysfunction is the most common etiology of

adult acquired flatfoot deformity. The pathological process by which this dysfunction occurs varies and may be inflammatory, degenerative, or traumatic in nature. Acquired adult flatfoot deformity can occur in younger patients (thirty to forty years old) with inflammatory arthropathy, but it is more common in older women (fifty to sixty years old) with degenerative tears<sup>1</sup>. Posterior tibial tendon dysfunction with loss of the dynamic stabilizer of the medial aspect of the hindfoot can lead to a progressive valgus deformity of the hindfoot. Once the posterior tibial tendon ruptures or becomes elongated, the dynamic forces of weight-bearing contribute to attritional rupture or laxity of the static hindfoot stabilizers and collapse of the medial longitudinal arch. There is sagging of the medial column of the foot with eversion and external rotation of the calcaneus in relation to the

talus. With longer-standing deformity, compensatory forefoot varus often develops (Figs. 1-A and 1-B).

Johnson and Strom<sup>2</sup> described three clinical stages of posterior tibial tendon dysfunction (Stages I, II, and III). This staging system was subsequently modified to include Stage IV, or the so-called tilted-ankle deformity, which indicates valgus tilt of the talus in the ankle mortise<sup>1</sup>.

Surgical intervention is indicated following failure of nonoperative treatment. The surgical management of a flexible flatfoot without degenerative changes has been reviewed in detail elsewhere<sup>1,3-6</sup>. Every attempt should be made to fully correct the deformity with hindfoot osteotomies, midfoot osteotomies, soft-tissue balancing, and tendon transfers in order to fuse as few joints as possible; however, full correction of the deformity may necessitate fusion of one or more joints. Although there is controversy about whether full correction of the deformity is absolutely necessary for a good outcome<sup>7</sup>, residual hindfoot valgus deformity following hindfoot fusion with only partial correction will lead to substantially increased valgus stresses at the ankle and may result in late valgus deformity of the tibiotalar

**Look for this and other related articles in *Instructional Course Lectures*, Volume 55, which will be published by the American Academy of Orthopaedic Surgeons in February 2006:**

- “Treatment of a Recurrent Clubfoot After Correction with the Ponseti Technique,” by Frederick Dietz, MD

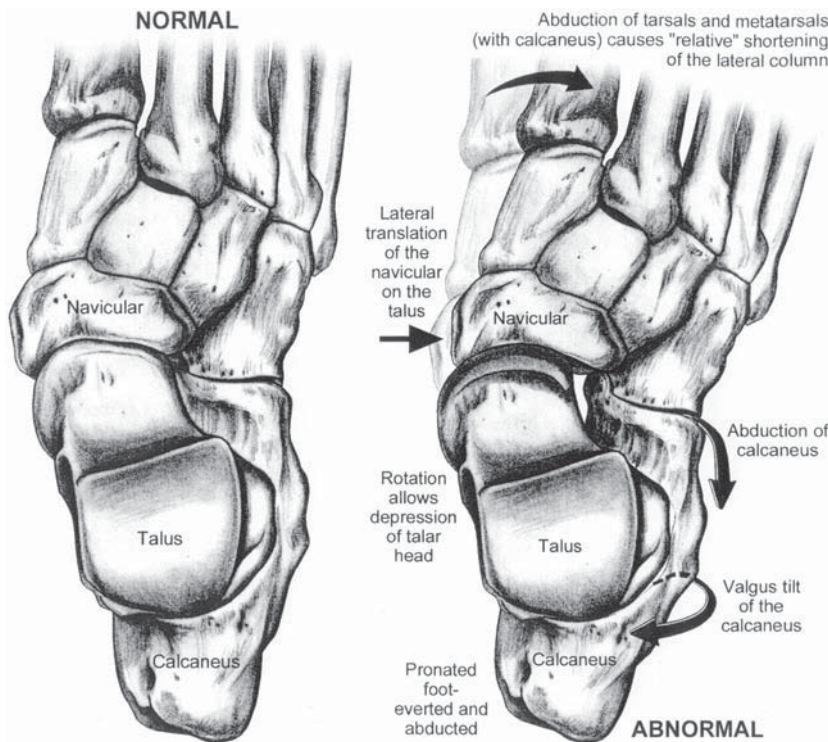


Fig. 1-A

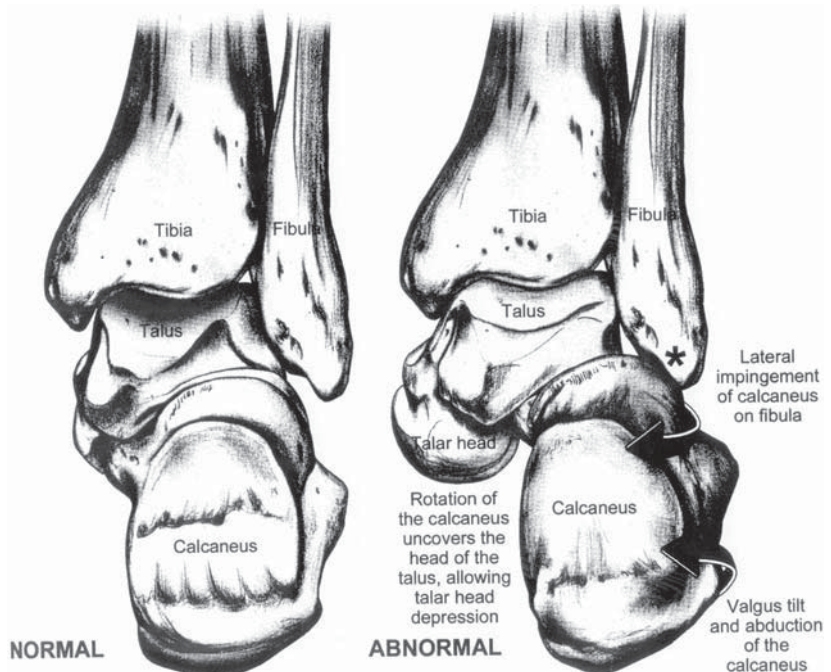
**Figs. 1-A and 1-B** A typical flatfoot deformity. (Reproduced, with modification, from: Romash MM. Triple arthrodesis for treatment of painful flatfoot, grade III posterior tibial tendon dysfunction. *Tech Foot Ankle Surg.* 2003;2:109. Reprinted with permission.) **Fig. 1-A** Dorsoplantar view. Note the lateral translation of the navicular on the talus, relative shortening of the lateral column causing forefoot abduction, and valgus (and abduction) of the calcaneus.

adult flatfoot deformity include subtalar, double, triple, tibiotalar, and pantalar procedures. Limited arthrodesis, involving the talonavicular and calcaneocuboid joints, or isolated subtalar fusion allows more residual motion than does triple arthrodesis<sup>8</sup>.

Severe, fixed deformities of the hindfoot and forefoot (Stage III) require triple arthrodesis. Occasionally, triple arthrodesis alone may not fully correct the deformity; adjunctive procedures may be necessary to correct residual forefoot varus, forefoot abduction, or hindfoot valgus deformities after the repositional triple arthrodesis. Adjunctive procedures include medial displacement calcaneal osteotomy to address residual hindfoot valgus; medial column procedures such as a plantar flexion osteotomy of the medial cuneiform, fusion of the first tarsometatarsal joint, or naviculocuneiform fusion to address residual forefoot varus deformity; and lateral column lengthening to address forefoot abduction. These procedures are best performed simultaneously with the triple arthrodesis, but they may be utilized later to correct a malunited or incompletely corrected planovalgus foot.

joint. Stage-II disease with degenerative changes, Stage-III disease, and Stage-IV disease generally require an arthrodesis of some type. The management of a Stage-IV foot deformity is similar to that of a Stage-II or III deformity, depending on the degree of arthritis and the flexibility of the hindfoot. The valgus ankle component of a Stage-IV disorder has been managed with a variety of techniques, including reconstruction of the deltoid ligament, ankle fusion, total ankle replacement, and bracing. Management of this component is not the focus of this paper.

Painful joints with modest-to-severe degenerative changes must be treated with arthrodesis in order to minimize residual postoperative pain. Arthrodesis can be avoided when painful joints have minimal degenerative changes since such joints often become painless after repositional osteotomies and tendon transfers alone. Arthrodeses for acquired

Fig. 1-B  
Posteroanterior view.

### Arthrodesis Procedures for Acquired Adult Flatfoot Deformity

In general, the proper selection of surgical procedures depends on the severity and flexibility of the deformity as well as the presence and location of degenerative changes about the foot and ankle. Activity level, age, body habitus, and medical comorbidities need to be considered as well. Surgical goals include relief of pain, establishment of a stable plantigrade foot without the need for bracing, and maintenance of the integrity of adjacent unfused joints, especially the ankle joint. This review will focus on the indications, surgical techniques, and complications of the various arthrodesis procedures used for the management of Stage-II disease with degenerative changes and Stage-III disease.

In Stage-II disease, the deformity is flexible, and hindfoot osteotomies are usually performed because they spare the important hindfoot joints and are a powerful means with which to correct a wide range of deformities. Limited arthrodesis may be indicated, especially when there is a moderate deformity that cannot be fully corrected with reconstruction of the posterior tibial tendon and joint-sparing osteotomy alone. Limited fusions are especially useful when the deformity is flexible and there is evidence of arthrosis in the hindfoot. According to Mann and Beaman, talonavicular arthrodesis is indicated for management of an unstable talonavicular joint associated with a flexible subtalar joint in patients who are older than fifty years of age, whereas double arthrodesis is preferred for an unstable talonavicular joint associated with a flexible subtalar joint in a younger patient<sup>9</sup>. Isolated arthrodesis of the subtalar joint is indicated for a fixed deformity of the subtalar joint associated with a flexible forefoot as well as for a flexible hindfoot deformity in the presence of degenerative changes in the subtalar joint. Subtalar fusion is also indicated for salvage of a failed reconstruction of a foot with acquired adult flatfoot deformity when there is residual subluxation, degenerative changes, or pain at the subtalar joint. The addition of a flexor digitorum

longus tendon transfer to the navicular or the first cuneiform has been advocated to improve function and stabilize the talonavicular joint even when an isolated subtalar joint fusion is being performed<sup>10</sup>.

Patients with Stage-III disease require a more extensive repositioning arthrodesis in order to fully correct the fixed deformity. Triple arthrodesis is indicated for a rigid subtalar joint and a fixed varus deformity of the forefoot. It may be necessary to include adjunctive procedures to fully correct all components of the deformity. The decision to utilize these adjunctive procedures is highly dependent on the degree of deformity and the intraoperative assessment of the correction obtained with the initial realignment. After reducing the subtalar, calcaneocuboid, and talonavicular joints, the surgeon should determine whether the foot will be plantigrade. The heel should be evaluated for excessive residual hindfoot valgus, which, if present, may require additional correction with a medial displacement calcaneal osteotomy. The position of the forefoot relative to the hindfoot should be

evaluated as well. Additional surgery, such as a lateral column lengthening with a bone block placed in the calcaneocuboid joint, may be indicated to fully correct the abducted forefoot to a neutral position. Any residual varus deformity of the forefoot needs to be corrected (Figs. 2-A and 2-B). This may require an osteotomy of the medial column, such as a plantar flexion osteotomy of the medial cuneiform, or an extended arthrodesis of the medial column.

At our institution, most of these procedures are performed with the patient under general anesthesia and with preemptive ankle block regional anesthesia. Antibiotic prophylaxis, a pneumatic tourniquet, and fluoroscopy are used routinely. Patients are initially cared for in the hospital and then are discharged on the day following the surgery. Splints and sutures are removed and a cast is applied in the clinic at approximately two weeks postoperatively.

#### Medial Column Arthrodesis

Loss of the medial longitudinal arch may be due to pathological changes in

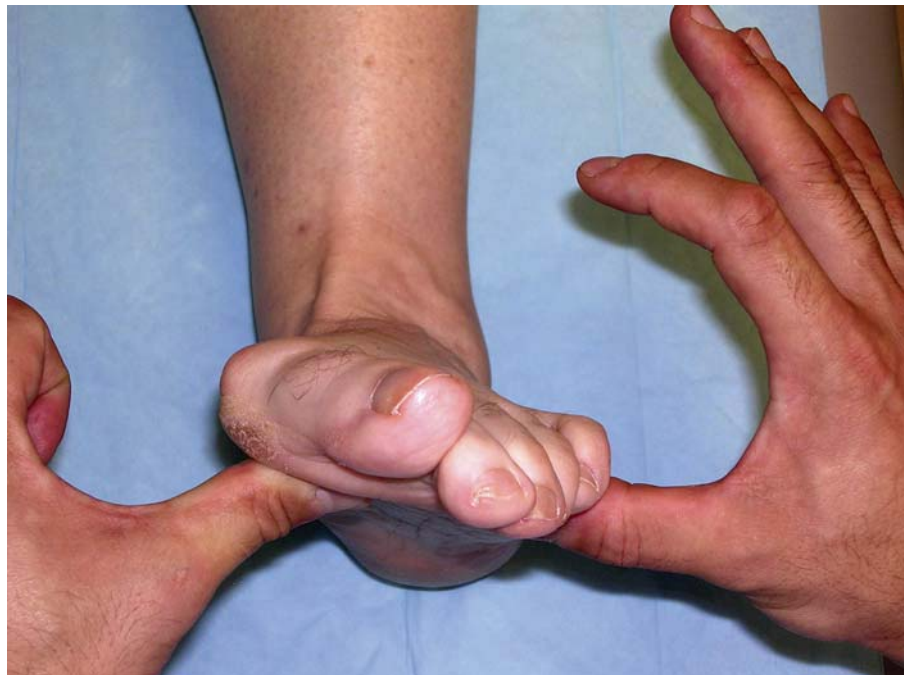

Fig. 2-A

**Figs. 2-A and 2-B** Evaluation for varus forefoot deformity. **Fig. 2-A** Forefoot varus with the subtalar joint corrected to neutral.

the talonavicular, naviculocuneiform, and/or metatarsocuneiform joints. Instability or hypermobility, degenerative changes, or residual forefoot varus at these joints are the primary indications for medial column fusion<sup>11</sup>. Isolated arthrodesis of the talonavicular joint essentially eliminates motion in the rest of the hindfoot<sup>8</sup>. A patient with a flexible hindfoot deformity who has no arthrosis in adjacent joints may be a candidate for isolated talonavicular arthrodesis; however, the specific indications remain controversial, and nonunion rates are higher than those following other hindfoot fusions<sup>12</sup>. Patients with residual hindfoot valgus, instability at multiple midfoot joints, or ankle arthrosis may require additional procedures such as a calcaneal osteotomy, midfoot fusions, ankle fusion, or ankle arthroplasty<sup>13</sup>. Arthrodesis of the naviculocuneiform joint is usually performed in conjunction with other procedures to correct hindfoot deformity and is done when there is residual forefoot varus secondary to severe instability or arthritis at this joint.

#### Surgical Technique for Talonavicular Arthrodesis

A dorsomedial longitudinal incision is made over the talonavicular joint, along the lateral edge of the anterior tibial tendon to the tibialis anterior tendon. The talonavicular joint capsule is identified and is incised longitudinally. Subperiosteal dissection exposes the remainder of the talonavicular joint. A small lamina spreader can help distract and expose the joint. The talonavicular articular surfaces are then débrided. The forefoot is then reduced to the talus by adducting, plantar flexing, and pronating it. Lateral counter pressure is applied to the medial aspect of the talar head. Provisional fixation can be obtained with use of Kirschner wires or the guide pins for the cannulated screw system. The hindfoot should be in 5° to 10° of valgus. It is imperative that the hindfoot not be fused in varus and that the forefoot not be left in varus relative to the hindfoot. The reduction should be confirmed fluoroscopically as well as clinically. Once the reduction is deemed to be satisfactory, two 4.5-mm cannu-

lated screws are placed across the talonavicular joint in a retrograde fashion. Occasionally, a third cannulated screw can be placed percutaneously from the lateral aspect of the navicular into the talus or a staple may be placed across the dorsal joint line. In severely sclerotic bone, a tricortical iliac bone allograft or autograft can be placed as a slot graft across the joint to augment the fusion. A saw is used to cut a rectangular trough perpendicular to the joint line. The slot graft is then impacted into the trough, spanning the joint line. The wound is closed in the usual manner. It is important to assess the foot for excessive heel valgus, forefoot varus, or heel-cord contracture preoperatively. The presence of these problems signifies the need for additional or different surgery to address them.

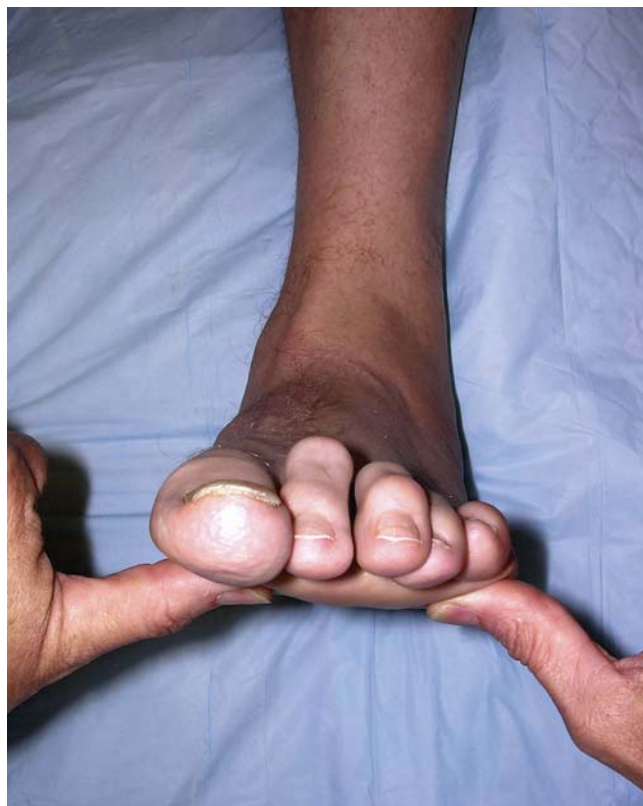Postoperatively, a bulky compressive Robert Jones dressing and splint are applied. Sutures are removed at two weeks. A short leg non-weight-bearing cast is applied and worn for four weeks. The patient then wears a short leg weight-bearing cast for another four to six weeks.

#### Outcomes and Complications

The outcomes of isolated talonavicular arthrodeses have varied in studies reported in the literature. Harper reported that twenty-four of twenty-seven patients treated with talonavicular arthrodesis to correct acquired adult flatfoot deformity had a good or excellent result with no pain or pain only with strenuous activity<sup>14</sup>. The correction was maintained in all patients at an average of twenty-seven months postoperatively. Progressive arthrosis was noted in one ankle, one calcaneocuboid joint, and three naviculocuneiform joints. In four of these joints, the arthrosis had been present preoperatively and had progressed after the talonavicular arthrodesis. There was one nonunion requiring revision and one major wound problem.

Below and McCluskey reported the outcomes for fifteen of twenty-one patients who had undergone isolated talonavicular arthrodesis for the treatment of acquired adult flatfoot deform-

Fig. 2-B  
Neutral forefoot alignment.



ity<sup>15</sup>. Twelve patients had Stage-II posterior tibial tendon dysfunction, and nine patients had Stage-III disease with talonavicular degenerative joint disease. Most of the patients experienced daily pain postoperatively. Radiographic evidence of subtalar arthrosis developed in eight patients, and twelve patients had pain at the subtalar joint on examination. Six patients had a nonunion.

Complications of talonavicular arthrodesis include residual lateral midfoot pain, malunion, nonunion, and the development of arthrosis at adjacent joints. For these reasons, talonavicular fusion alone is not commonly performed for Stage-II acquired adult flatfoot deformity.

#### **Lateral Column Lengthening**

Calcaneocuboid distraction arthrodesis or lateral column lengthening arthrodesis has been advocated for the treatment of Stage-II posterior tibial tendon dysfunction with dorsolateral peritalar subluxation<sup>16</sup>. Lengthening of the lateral column has been shown to restore the medial arch and correct hindfoot valgus and forefoot abduction<sup>17,18</sup>. The decision whether to perform a lengthening osteotomy through the distal part of the calcaneus or with distraction arthrodesis of the calcaneocuboid joint is controversial<sup>17,19</sup>. Proponents of distraction arthrodesis of the calcaneocuboid joint cite the potential for the development of degenerative changes at the calcaneocuboid joint following osteotomy of the calcaneus as a result of increased contact pressures at the calcaneocuboid joint<sup>4,16-21</sup>; however, the nonunion rate following distraction arthrodesis of the calcaneocuboid joint is approximately 20%. Typically, if lateral column lengthening is required as a component of the correction of a flexible Stage-II acquired adult flatfoot deformity, a lengthening osteotomy of the calcaneal neck with interposition of bone graft is performed. When lateral column lengthening is needed for a Stage-III acquired adult flatfoot deformity, distraction arthrodesis of the calcaneocuboid joint is performed with interposition of bone graft as part of a triple arthrodesis.

#### **Surgical Technique**

A lateral longitudinal incision is made over the anterolateral aspect of the calcaneus from just anterior to the tip of the fibula toward the base of the fourth metatarsal. Dissection through the soft tissues is performed to expose the extensor digitorum brevis, with care taken to avoid injury to the anterior branch of the sural nerve. Other cutaneous nerves, such as the intermediate branch of the superficial peroneal nerve, can occasionally enter the surgical field, and they need to be protected. The peroneal tendons and sural nerve are retracted inferiorly. The extensor digitorum brevis is retracted superiorly; the extensor digitorum brevis origin and the plantar aspect of the muscle may be elevated to facilitate exposure of the calcaneocuboid joint.

The articular surfaces of the calcaneocuboid joint are then débrided. A lamina spreader without teeth is used to distract the joint.

Care must be taken to avoid overcorrecting the heel into varus or pushing the forefoot into varus. A tricortical iliac crest bone allograft or autograft is then fashioned to fit into the distracted calcaneocuboid joint. This graft usually measures between 8 and 12 mm in width<sup>16</sup>. Fixation is obtained with a 4.0 or 4.5-mm cannulated screw inserted in a retrograde direction. However, an isolated distraction arthrodesis of the calcaneocuboid joint usually requires additional fixation to help prevent a nonunion, and a lateral plate is often added. The extensor digitorum brevis is reapproximated, and the skin is closed in the usual manner. Postoperative care is similar to that described above.

#### **Outcomes and Complications**

Complications of calcaneocuboid arthrodesis include cutaneous neuroma of the sural or superficial peroneal nerve, residual lateral midfoot pain, malunion, nonunion, and the development of arthrosis at adjacent joints. Symptomatic nonunion is treated with bone-grafting and plate, screw, or staple fixation. Chi et al. reported that eight of forty-one attempted distraction arthrodeses of the calcaneocuboid joint

in thirty-six patients did not result in healing<sup>18</sup>. Distraction arthrodesis of the calcaneocuboid joint causes some loss of motion in the foot, but less than is seen after subtalar or talonavicular arthrodesis<sup>21</sup>.

#### **Isolated Subtalar Arthrodesis with Flexor Digitorum Longus Transfer**

There is support in the literature for the use of isolated subtalar arthrodesis to treat acquired adult flatfoot deformity when the patient has a fixed deformity of the subtalar joint and a flexible forefoot<sup>22,23</sup>. Mann et al. stated that 10° to 15° of forefoot varus or joint hypermobility is a contraindication to isolated subtalar fusion<sup>10</sup>. In such a situation, isolated subtalar joint arthrodesis will overload the lateral border during gait as a result of the fixed forefoot varus. Other indications for isolated subtalar joint arthrodesis include degenerative changes in the subtalar joint and salvage of a failed hindfoot reconstruction. The procedure allows residual motion at the talonavicular and calcaneocuboid joints (26% and 56% residual motion, respectively<sup>8</sup>). This may have a protective effect on the development of ankle arthritis when compared with triple arthrodesis<sup>23</sup>. However, the authors of an in vitro biomechanical study concluded that isolated subtalar or calcaneocuboid fusion cannot achieve full correction of a moderate flatfoot deformity with substantial transverse tarsal joint laxity; in contrast, a talonavicular, double, or triple arthrodesis completely corrected the deformity<sup>24</sup>. We believe that, when an isolated subtalar fusion is performed to treat acquired adult flatfoot deformity, the addition of a flexor digitorum longus transfer helps to support the talonavicular joint and balances the pull of the peroneus brevis<sup>22</sup>.

#### **Surgical Technique**

An oblique longitudinal skin incision is made from the tip of the lateral malleolus toward the base of the fourth metatarsal, centered over the sinus tarsi. Alternatively, an oblique Ollier-type incision can be used, but this may limit the placement of a calcaneal osteotomy

incision if one is needed during the procedure. Care is taken to preserve full-thickness skin flaps as well as the sural nerve at the inferior and distal aspect of the incision.

The origin of the extensor digitorum brevis muscle and the peroneal tendon sheath are identified. The origin of the extensor digitorum brevis is split in line with the muscle fibers and is retracted superiorly. The fat in the sinus tarsi is either excised or reflected to improve exposure. The calcaneocuboid joint capsule is not violated. The peroneal tendons are retracted posteriorly to expose the posterior facet of the subtalar joint. A small lamina spreader can be inserted into the sinus tarsi to distract the subtalar joint and improve visualization. Any obvious osteophytes should be resected, and any removed bone should be morcellized for bone graft. The talocalcaneal interosseous ligament is resected to allow greater distraction of the joint. The medial aspect of the subtalar joint capsule may be excised carefully with a rongeur if necessary to improve hindfoot mobility in order to allow reduction.

The articular surfaces of the subtalar joint are débrided. Care should be taken to preserve the subchondral contour of the joint surfaces in order to maximize the surface area of bone contact. The calcaneocuboid articulation, talonavicular articulation, and tibiotalar capsules should be preserved.

The posterior tibial tendon is then exposed through a medial incision and is débrided as needed. The flexor digitorum longus tendon is dissected distal to the knot of Henry and is divided just proximal to its decussation with the flexor hallucis longus tendon. A 4.5-mm drill hole is placed in the navicular tuberosity, and the flexor digitorum longus tendon is pulled up from plantar to dorsal through the drill hole with use of a grasping suture placed in the end of the tendon. Tensioning of the flexor digitorum longus is delayed until the subtalar joint is fused.

The subtalar joint is then reduced; this usually requires internal rotation and inversion of the calcaneus

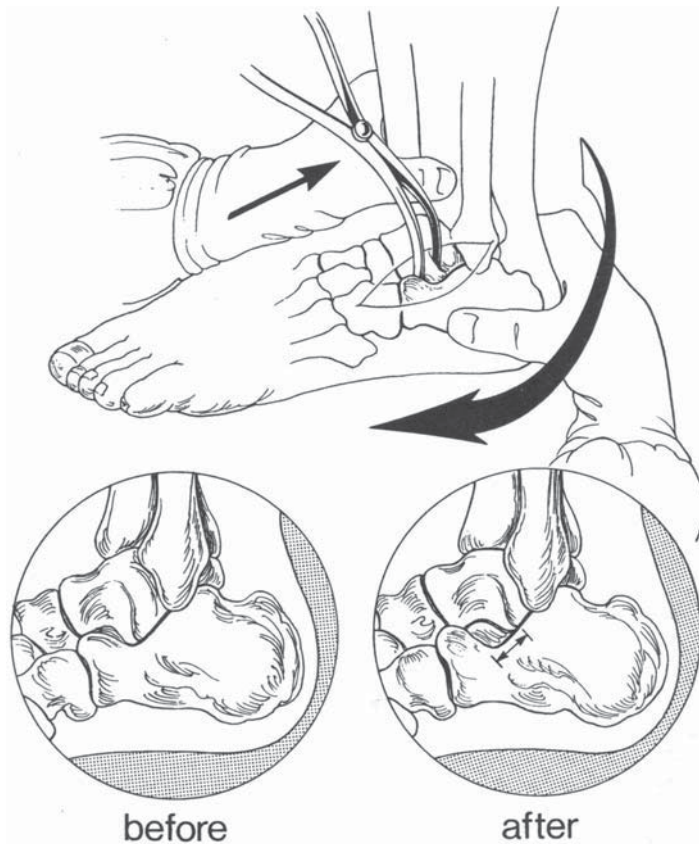


Fig. 3 Manual reduction of the subtalar joint is accomplished by internally derotating the calcaneus underneath the talus. (Reprinted, with permission, from: Schon LC. Derotational triple arthrodesis for severe pes plano valgus correction. *Tech Orthop.* 1996;11:294-5.)

back under the talus (Fig. 3) as well as elevation of the lateral column and depression of the medial column of the forefoot. The reduction can be aided by placing a lamina spreader between the lateral process of the talus and the anterior process of the calcaneus as described by Hansen<sup>25</sup> (Figs. 4 and 5). After reduction, the heel should be in no more than 5° to 10° of valgus. Bone apposition is confirmed, and the need for bone graft is assessed.

A small stab wound is made in the heel. Guide wires for one or two 6.5-mm cannulated screws are introduced through the stab wound and then advanced through the calcaneus and into the talar body under fluoroscopic control. Proper pin placement must be confirmed on all three intraoperative views—i.e., the lateral and anteroposterior views of the ankle and the axial view of the heel. The cannulated screws

are then inserted in the usual manner. Stability of the construct is verified, and bone graft, if needed, is placed after thorough irrigation of the wound with saline solution. The addition of a flexor digitorum longus tendon transfer to the navicular or the first cuneiform has been advocated to improve function and stabilize the talonavicular joint even when an isolated subtalar joint fusion is being performed<sup>10</sup>. The flexor digitorum longus tendon is pulled up through the hole in the navicular under moderate tension and is secured back on itself or to the surrounding periosteum with nonabsorbable sutures. Any tears in the spring ligament complex are also repaired.

Prior to wound closure, the extensor digitorum brevis is reapproximated with 2-0 Vicryl sutures. Postoperative care is as described above.



### Outcomes and Complications

Outcomes of subtalar joint arthrodesis for the treatment of acquired adult flat-foot deformity have been described in the literature. Johnson et al. reported on seventeen feet treated with subtalar joint arthrodesis, reconstruction of the flexor digitorum longus, and repair of the spring ligament<sup>22</sup>. At two years post-operatively, the results compared favorably with those of medial displacement calcaneal osteotomy and lateral column lengthening. Kitaoka and Patzer reported sixteen good or excellent results at three years following subtalar joint realignment and arthrodesis in twenty-one feet<sup>23</sup>. Complications included symptomatic arthrosis of adjacent joints, malunion, and nonunion. Others have recommended the addition of a flexor digitorum longus transfer to the navicular in order to help stabilize the talonavicular joint when isolated subtalar arthrodesis is performed for Stage-II disease<sup>22</sup>. The addition of the flexor digitorum longus transfer in the treatment of Stage-II disease may also help to prevent the progressive development of valgus tilt of the ankle after triple arthrodesis, but it has not been widely utilized in that setting.

### Double Arthrodesis (Calcaneocuboid and Talonavicular Joints)

A double arthrodesis involves fusion of the calcaneocuboid and talonavicular joints. It is indicated for a flexible moderate hindfoot deformity with a forefoot varus deformity. It has been stated that a double arthrodesis is indicated for a younger patient with a flexible hindfoot deformity and excessive forefoot varus, whereas an isolated talonavicular fusion is indicated for an older patient with that condition<sup>26</sup>. Given that the range of motion of the subtalar joint is essentially eliminated following double arthrodesis, a triple arthrodesis should be performed if there is tenderness or degenerative changes in the subtalar joint<sup>8</sup>.

### Surgical Technique

The approach to the talonavicular joint is performed as described above. The calcaneocuboid joint is approached in a

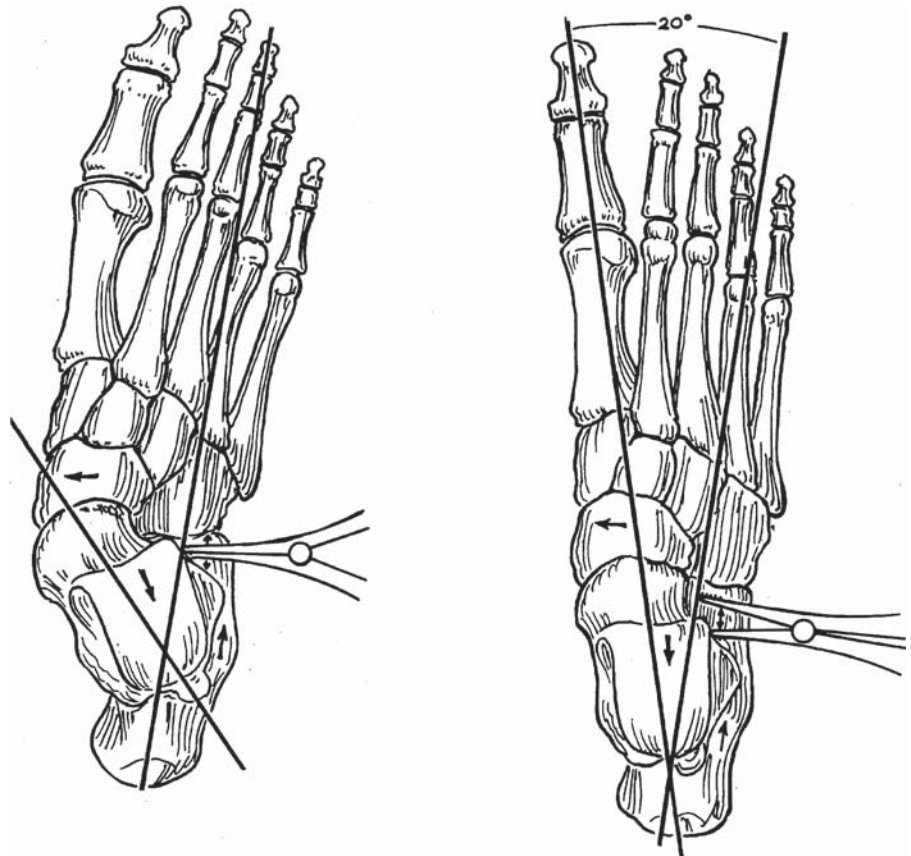


Fig. 4  
Anteroposterior view of a reduction of a flatfoot deformity and forefoot abduction with use of a lamina spreader placed between the anterior aspect of the dorsal part of the calcaneus and the lateral shoulder of the talus. (Reprinted, with permission, from: Hansen ST Jr. Functional reconstruction of the foot and ankle. Philadelphia: Lippincott Williams and Wilkins; 2000. p 302-3.)

fashion similar to that described for a calcaneocuboid distraction arthrodesis. In order to correct a major forefoot varus deformity, care must be taken to débride enough of the talonavicular and calcaneocuboid joints to allow derotation of the forefoot and correction of forefoot varus. Because the talonavicular joint is at the apex of the deformity, most surgeons reduce and stabilize it first. Guide pins for the 4.5-mm cannulated screws can be used for provisional fixation. It is then verified that the talonavicular joint and the calcaneocuboid joint have been reduced simultaneously, and these joints are provisionally stabilized with either Steinmann pins or guide pins for the cannulated screws. The alignment of the foot and the position of the hardware are confirmed both clinically and fluoroscopically. The talonavicular joint

is then fixed with two 4.5-mm cannulated screws; the calcaneocuboid joint is also fixed internally, either with a screw or staples. The skin is closed in the usual manner. Postoperative care is similar to that described above.

### Outcomes and Complications

Clain and Baxter reported four excellent, eight good, and four fair results at an average of eighty-three months after double arthrodeses performed on sixteen feet with a variety of hindfoot disorders<sup>24</sup>. There was one nonunion of the talonavicular joint, which remained asymptomatic. Progressive degenerative changes developed in the ankle of six patients and in the naviculocuneiform joints of seven. The authors concluded that double arthrodesis was better than isolated talonavicular fusion and a viable alternative to triple arthrodesis.

Mann and Beaman reported the outcomes of twenty-four double arthrodeses at an average of fifty-six months<sup>9</sup>. Sixteen of the double arthrodeses were performed for acquired adult flatfoot deformity due to posterior tibial tendon insufficiency, and eight were done for other diagnoses. Similar outcomes were observed in the two groups of patients, with eighteen patients having a good or excellent result overall. Complications were more frequent in the patients who had flatfoot deformity. Talonavicular nonunion was the most frequent complication, occurring in four patients, three of whom required revision arthrodesis. The development of arthrosis in the surrounding joints was common but asymptomatic. For this reason, triple arthrodesis may be preferred for most patients.

#### Triple Arthrodesis

Triple arthrodesis is indicated for the treatment of acquired adult flatfoot de-

formity when the subtalar joint or transverse tarsal joint is not passively correctable, when there are degenerative changes at the subtalar joint or transverse tarsal joint, and for the salvage of a failed hindfoot reconstruction. The radiographic criteria for triple arthrodesis are controversial and are of limited value<sup>27</sup>. Myerson recommended triple arthrodesis for a fixed hindfoot deformity with subfibular impingement<sup>1</sup>. Others have stated that medial foot pain associated with dorsal peritalar subluxation should be corrected with triple arthrodesis<sup>28</sup>. The goal of triple arthrodesis is to fuse the subtalar, talonavicular, and calcaneocuboid joints with the hindfoot in 5° of valgus and to correct midfoot and forefoot deformities to neutral through repositioning arthrodesis. A single extensile lateral or extensile medial incision could be used if needed for access to the joint in a triple arthrodesis, but a two-incision technique provides better ex-

posure and allows easier correction of the deformity.

#### Surgical Technique

Two incisions are utilized for this procedure. The lateral incision is made obliquely from the tip of the distal part of the fibula to the base of the fourth metatarsal. Occasionally, branches of the intermediate branch of the superficial peroneal nerve may cross the surgical field near the anterior aspect of the calcaneus. If they do, these branches are identified and are retracted cephalad. The subcutaneous exposure involves creation of full-thickness flaps with meticulous soft-tissue handling. Care should be taken to identify and protect the sural nerve and any branches of the superficial peroneal nerve.

The peroneal tendons are identified and retracted. The extensor digitorum brevis is incised along its muscle fibers and is sharply raised from the calcaneal insertion. The subtalar joint is exposed as described above. The lateral talonavicular, calcaneocuboid, and naviculocuboid articulations are identified. A useful landmark for localizing the talonavicular joint is the insertion of the bifurcate ligament (ligament of Chopart). The bifurcate ligament consists of the lateral calcaneonavicular and medial calcaneocuboid ligaments and inserts into the calcaneonaviculocuboid region. The lateral aspect of the calcaneus is followed distally to the calcaneocuboid joint. The calcaneocuboid joint capsule is incised sharply both laterally and dorsally. The lateral aspect of the talonavicular joint may then be partially exposed and débrided through the lateral incision. The naviculocuboid articulation is débrided in a similar manner. Exposure of the calcaneocuboid joint can be facilitated by use of a small lamina spreader. The articular surfaces of the calcaneocuboid joint are then débrided. The articular surfaces of the subtalar joint are prepared as described above.

The dorsomedial approach, as described above, is used to expose the remainder of the talonavicular joint and allow complete débridement of the talonavicular joint. The foot is placed into

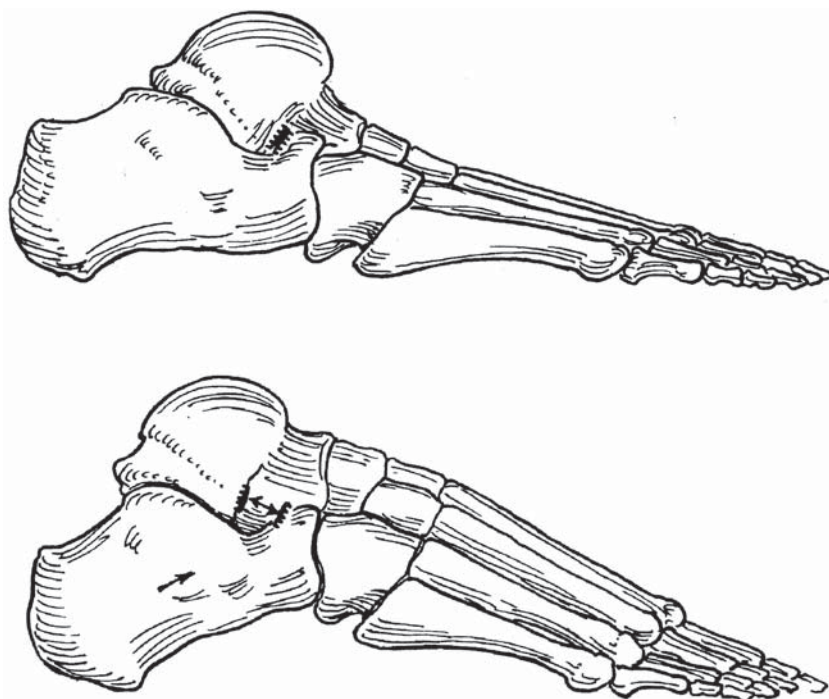


Fig. 5

Lateral view showing flatfoot deformity and forefoot abduction deformity (top) and reduction of those deformities (bottom) with a lamina spreader placed between the anterior aspect of the calcaneus and the lateral shoulder of the talus. Cross-hatched locations on the talus and the calcaneus demonstrate proper placement of the lamina spreader. (Reprinted, with permission, from: Hansen ST Jr. Functional reconstruction of the foot and ankle. Philadelphia: Lippincott Williams and Wilkins; 2000. p 302-3.)

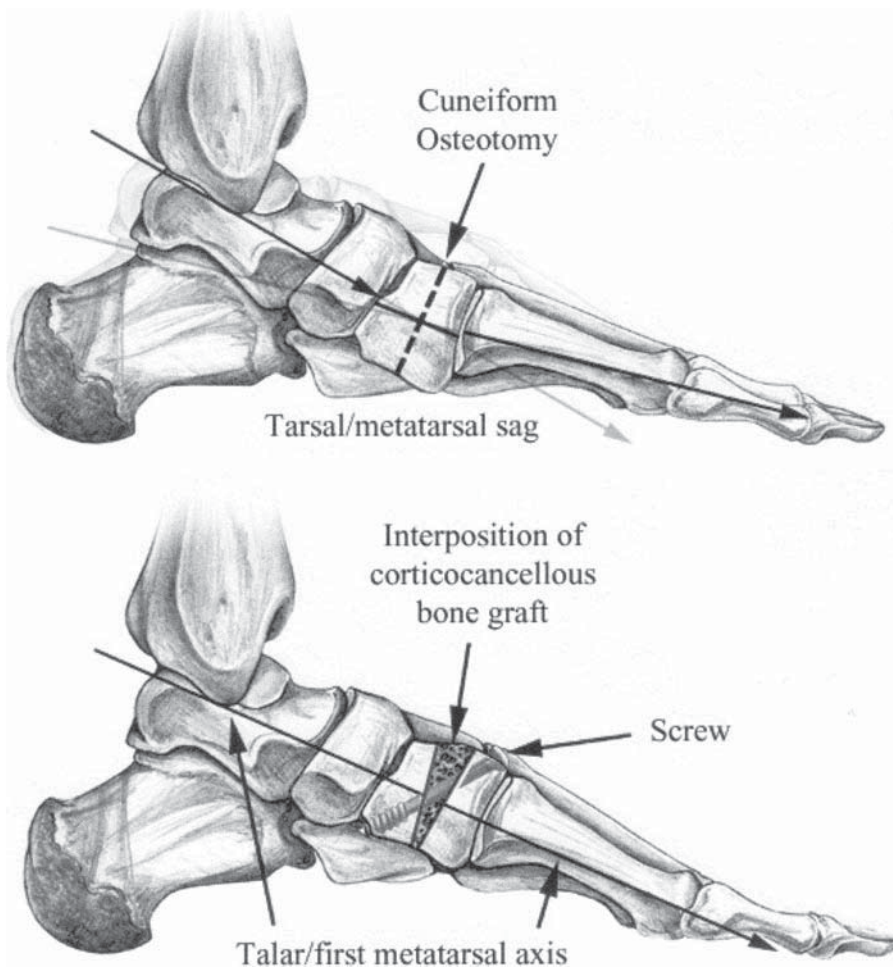


Fig. 6  
Schematic drawing of a completed plantar flexion osteotomy of the medial cuneiform with use of a corticocancellous bone graft and internal fixation. Note that the lateral talo-first metatarsal angle has been restored to normal. (Reprinted, with permission, from: Johnson JE. Plantar flexion opening wedge cuneiform-1 osteotomy for correction of fixed forefoot varus. *Tech Foot Ankle Surg.* 2004;3:6.)

a plantigrade position. After the hindfoot is corrected to the “anatomic neutral” position, the necessity for adjunctive procedures should be assessed. A tendo Achillis lengthening is almost always required and is usually performed at the outset of the procedure before the surgeon tries to reposition the foot. If there is residual heel valgus of  $>5^\circ$  to  $10^\circ$  after subtalar joint alignment has been re-established, a medial displacement calcaneal osteotomy may be needed. Next, the position of the forefoot relative to the hindfoot needs to be considered since residual forefoot varus promotes a valgus thrust on the hindfoot with gait and may con-

tribute to a poor outcome and late valgus deformity at the ankle secondary to insufficiency of the deltoid ligament. If the forefoot is abducted, distraction arthrodesis of the calcaneocuboid joint may be required. The medial column is evaluated for instability or any residual supination deformity that might require fusion of the first tarsometatarsal joint, plantar flexion cuneiform osteotomy, or naviculocuneiform fusion.

Intraoperatively, the decision to begin with reduction of the subtalar joint or the talonavicular joint is controversial<sup>7</sup>. Proponents of primary subtalar joint fusion cite the ability and importance of placing the hindfoot in

slight valgus with subsequent reduction of the forefoot by lateral column lengthening or medial column arthrodesis<sup>25</sup>. Primary fixation of the talonavicular joint is favored by those who believe a multiplanar correction of the talonavicular joint will reduce the rest of the deformity<sup>24</sup>. We prefer correcting the deformity in a proximal-to-distal progression, beginning with the subtalar joint. Once the heel is in neutral, the midfoot is reduced at the talonavicular and calcaneocuboid joints.

After the subtalar joint is reduced in a position of  $5^\circ$  to  $10^\circ$  of valgus, inspection should confirm that the heel was not placed in varus. Several maneuvers to assist reduction have been described. A lamina spreader placed in the sinus tarsi between the calcaneus and the lateral talar process, or neck, can be used to push the forefoot out of abduction and effectively lengthen the lateral column, rather than distract the subtalar joint<sup>25</sup> (Figs. 4 and 5). Alternatively, primary talonavicular reduction can be achieved by pushing the head of the talus laterally while adducting and pronating the forefoot<sup>29</sup>. Kirschner-wire joysticks placed transversely across the midfoot may be helpful for elevating the lateral aspect of the forefoot and depressing the medial aspect of the forefoot during reduction of forefoot varus.

The reduction is confirmed fluoroscopically. Internal fixation with screws is utilized routinely at the subtalar, talonavicular, and calcaneocuboid joints. The guide pins for the cannulated screws can be used to provide provisional fixation. Staple fixation with or without a screw is commonly utilized at the calcaneocuboid joint.

A 6.5-mm cannulated screw can be inserted in either a retrograde fashion (as described above) or an antegrade fashion (from the dorsal aspect of the talar neck into the calcaneus) across the subtalar joint. This screw is countersunk and is usually placed from the calcaneus to the talus in order to avoid the neurovascular bundle. The talonavicular joint is internally fixed with two cannulated 4.5-mm screws, approximately 40 to 50 mm long, from the navicular tuberosity into the head and neck of the talus. Tech-

nically, it is important to countersink the head of the screw in the navicular to minimize hardware prominence. The calcaneocuboid articulation is internally fixed with two 30 to 40-mm-long 4.5-mm cannulated screws or a staple device.

Postoperative care is similar to that following any arthrodesis of the hindfoot. Initially, a bulky compressive Robert Jones dressing and splint are applied. At two weeks, the foot is placed in a cast, which is worn for an additional four weeks. Protected weight-bearing in a cast is begun at six weeks. At ten weeks, a removable walker boot is applied, and the patient gradually resumes shoe wear at twelve to fourteen weeks.

#### Outcomes and Complications

Outcomes after triple arthrodesis have been well described<sup>27,29-36</sup>. Graves et al. reported on a series of eighteen feet in seventeen patients who had undergone triple arthrodesis<sup>30</sup>. At an average of 3.5 years, pain was decreased in all patients, although eleven feet were the source of residual discomfort. A substantial prevalence of degenerative changes in the ankle and foot was noted. The authors concluded that triple arthrodesis is a satisfactory salvage operation but is technically difficult and is associated with a relatively high complication rate. Fortin and Walling<sup>29</sup> and Haddad et al.<sup>36</sup> both noted effective pain relief and improved function at four to six years following triple arthrodesis for deformity correction. Both concluded that triple arthrodesis was an acceptable treatment for late-stage disease and noted a propensity for secondary degenerative changes to develop at the ankle joint. Similarly, in a report on the results twenty-five and forty-four years after triple arthrodesis, Saltzman et al. reported that sixty-four of sixty-seven feet had a satisfactory result<sup>37</sup>. Twenty feet had degenerative changes at the ankle at twenty-five years, and all had degenerative changes at forty-four years. Interestingly, the radiographic appearance of the ankle did not correlate with symptoms.

#### Adjunctive Procedures

Adjunctive procedures may be necessary to fully correct a severe fixed flat-

foot deformity. The need to perform these procedures is determined by careful preoperative and intraoperative assessment of the hindfoot alignment and the degree of fixed varus deformity of the forefoot. Tendo Achillis lengthening or gastrocnemius-soleus lengthening is almost always necessary to correct the equinus contracture seen with acquired adult flatfoot deformity. These procedures are indicated when the patient lacks 10° of ankle dorsiflexion with the knee extended. Tendo Achillis lengthening can be performed percutaneously or with an open technique, and gastrocnemius-soleus lengthening is performed in the midcalf through a small medial or midline incision. We prefer an open Z-lengthening of both the gastrocnemius and the soleus muscle at the myotendinous junction, as this allows a more controlled release of the gastrocnemius muscle either alone or in combination with the soleus, depending on which is tight. However, excellent results can be obtained with either method.

Medial displacement calcaneal osteotomy is useful for correcting residual hindfoot valgus after initial realignment of the heel. Medial displacement calcaneal osteotomy helps to remove the deforming force of the Achilles tendon on the valgus heel by displacing its insertion medially. It may be used in conjunction with a lateral column lengthening by means of calcaneocuboid distraction arthrodesis if there is excessive residual hindfoot valgus along with excessive forefoot abduction. The need for a medial displacement calcaneal osteotomy can be assessed intraoperatively after provisional reduction and fixation of the calcaneus under the talus. The surgeon can then assess the hindfoot for any residual valgus deformity. If excessive hindfoot valgus is noted, either repeat repositioning of the subtalar joint can be performed if full correction was not obtained or a medial displacement calcaneal osteotomy can be utilized to correct the residual valgus.

A plantar flexion osteotomy through the medial cuneiform is useful for reducing residual varus forefoot de-

formity and restoring the weight-bearing tripod of the foot. The osteotomy is oriented in the coronal plane through the midportion of the medial cuneiform at the level of the second tarsometatarsal joint (Fig. 6). The first ray is then plantar flexed through this osteotomy site by gently levering the site open with a small osteotome. The resulting gap in the cuneiform is measured once the first ray is plantar flexed to a neutral position. A wedge-shaped tricortical allograft bone block is then cut to this width. It is usually between 4 and 7 mm thick. The graft is impacted into the osteotomy site. The osteotomy site is secured with internal fixation with a 4.0-mm screw or a percutaneous 0.062-inch (1.575-mm) Kirschner wire. If the forefoot varus is secondary to instability, subluxation, or degenerative arthritis at the first tarsometatarsal joint, reduction and fusion of this joint is performed.

#### Overview

The proper management of acquired adult flatfoot deformity requires careful history-taking and physical examination of the foot, ankle, and lower extremity. Accurate assessment of foot flexibility and localization of pain will aid in decision-making. Nonoperative management is the recommended initial treatment, but it may not be successful for the treatment of advanced disease, particularly when there are degenerative changes. Surgical management of advanced acquired adult flatfoot deformity (Stages III and IV) is indicated if nonoperative management has failed. Adjunctive procedures, such as tendo Achillis lengthening, medial displacement calcaneal osteotomy, lateral column lengthening, stabilization of the first tarsometatarsal joint, and plantar flexion osteotomy of the medial column of the foot are useful for correcting residual deformities after hindfoot realignment intraoperatively.

Jeffrey E. Johnson, MD  
James R. Yu, MD  
Department of Orthopaedic Surgery, Washington University School of Medicine, 660 South

Euclid Avenue, Box 8233, St. Louis, MO 63110. E-mail address for J.E. Johnson: foot@msnotes.wustl.edu

The authors did not receive grants or outside funding in support of their research or preparation of this manuscript. They did not receive payments or other benefits or a

commitment or agreement to provide such benefits from a commercial entity. No commercial entity paid or directed, or agreed to pay or direct, any benefits to any research fund, foundation, educational institution, or other charitable or nonprofit organization with which the authors are affiliated or associated.

Printed with permission of the American Academy of Orthopaedic Surgeons. This article, as well as other lectures presented at the Academy's Annual Meeting, will be available in February 2006 in *Instructional Course Lectures*, Volume 55. The complete volume can be ordered online at [www.aaos.org](http://www.aaos.org), or by calling 800-626-6726 (8 A.M.-5 P.M., Central time).

### References

1. Myerson MS. Adult acquired flatfoot deformity: treatment of dysfunction of the posterior tibial tendon. *Instr Course Lect.* 1997;46:393-405.
2. Johnson KA, Strom DE. Tibialis posterior tendon dysfunction. *Clin Orthop Relat Res.* 1989; 239:196-206.
3. Myerson MS, Corrigan J, Thompson F, Schon LC. Tendon transfer combined with calcaneal osteotomy for treatment of posterior tibial tendon insufficiency: a radiological investigation. *Foot Ankle Int.* 1995;16:712-8.
4. Mosier-LaClair S, Pomeroy G, Manoli A 2nd. Operative treatment of the difficult stage 2 adult acquired flatfoot deformity. *Foot Ankle Clin.* 2001; 6:95-119.
5. Alvarez RG, Marini AL. Posterior tibialis tendon dysfunction nonoperative management. Read at the Annual Summer Meeting of the American Orthopaedic Foot and Ankle Society; 1998 July 24-26; Boston, MA.
6. Mann RA. Rupture of the tibialis posterior tendon. *Instr Course Lect.* 1984;33:302-9.
7. Pinney SJ, Van Bergeyck A. Controversies in surgical reconstruction of acquired adult flat foot deformity. *Foot Ankle Clin.* 2003;8:595-604.
8. Astion DJ, Deland JT, Otis JC, Kenneally S. Motion of the hindfoot after simulated arthrodesis. *J Bone Joint Surg Am.* 1997;79:241-6.
9. Mann RA, Beaman DN. Double arthrodesis in the adult. *Clin Orthop Relat Res.* 1999;365:74-80.
10. Mann RA, Beaman DN, Horton GA. Isolated subtalar arthrodesis. *Foot Ankle Int.* 1998;19:511-9.
11. Coetzee JC, Hansen ST. Surgical management of severe deformity resulting from posterior tibial tendon dysfunction. *Foot Ankle Int.* 2001;22:944-9.
12. Mann RA. Talonavicular arthrodesis for the painful adult acquired flatfoot. *Foot Ankle Int.* 1997; 18:375-6.
13. Fortin PT. Posterior tibial tendon insufficiency. Isolated fusion of the talonavicular joint. *Foot Ankle Clin.* 2001;6:137-51, vii-viii.
14. Harper MC. Talonavicular arthrodesis for the acquired flatfoot in the adult. *Clin Orthop Relat Res.* 1999;365:65-8.
15. Below SK, McCluskey LC. Isolated talonavicular arthrodesis for posterior tibial tendon dysfunction and degenerative joint disease of the talonavicular joint. Read at the Annual Summer Meeting of the American Orthopaedic Foot and Ankle Society; 2002 July 12-14; Traverse City, MI.
16. Gallina J, Sands AK. Lateral-sided bony procedures. *Foot Ankle Clin.* 2003;8:563-7, ix-x.
17. Toolan BC, Sangeorzan BJ, Hansen ST Jr. Complex reconstruction for the treatment of dorsolateral peritalar subluxation of the foot. Early results after distraction arthrodesis of the calcaneocuboid joint in conjunction with stabilization of, and transfer of the flexor digitorum longus tendon to, the midfoot to treat acquired pes planovalgus in adults. *J Bone Joint Surg Am.* 1999;81:1545-60.
18. Chi TD, Toolan BC, Sangeorzan BJ, Hansen ST Jr. The lateral column lengthening and medial column stabilization procedures. *Clin Orthop Relat Res.* 1999;365:81-90.
19. Cooper PS, Nowak MD, Shaer J. Calcaneocuboid joint pressures with lateral column lengthening (Evans) procedure. *Foot Ankle Int.* 1997;18:199-205.
20. Raines RA Jr, Brage ME. Evans osteotomy in the adult foot: an anatomic study of structures at risk. *Foot Ankle Int.* 1998;19:743-7.
21. Neufeld SK, Myerson MS. Complications of surgical treatments for adult flatfoot deformities. *Foot Ankle Clin.* 2001;6:179-91.
22. Johnson JE, Cohen BE, DiGiovanni BF, Lamdan R. Subtalar arthrodesis with flexor digitorum longus transfer and spring ligament repair for treatment of posterior tibial tendon insufficiency. *Foot Ankle Int.* 2000;21:722-9.
23. Kitaoka HB, Patzer GL. Subtalar arthrodesis for posterior tibial tendon dysfunction and pes planus. *Clin Orthop Relat Res.* 1997;345:187-94.
24. Clain MR, Baxter DE. Simultaneous calcaneocuboid and talonavicular fusion. Long-term follow-up study. *J Bone Joint Surg Br.* 1994;76:133-6.
25. Hansen ST Jr. Functional reconstruction of the foot and ankle. Philadelphia: Lippincott Williams and Wilkins; 2000.
26. Coughlin MJ, Mann RA, editors. *Surgery of the foot and ankle.* 7th ed. St. Louis: Mosby; 1999.
27. Bednarz PA, Monroe MT, Manoli A 2nd. Triple arthrodesis in adults using rigid internal fixation: an assessment of outcome. *Foot Ankle Int.* 1999; 20:356-63.
28. Maenpaa H, Lehto MU, Belt EA. What went wrong in triple arthrodesis? An analysis of failures in 21 patients. *Clin Orthop Relat Res.* 2001;391: 218-23.
29. Fortin PT, Walling AK. Triple arthrodesis. *Clin Orthop Relat Res.* 1999;365:91-9.
30. Graves SC, Mann RA, Graves KO. Triple arthrodesis in older adults. Results after long-term follow-up. *J Bone Joint Surg Am.* 1993;75:355-62.
31. Jayakumar S, Cowell HR. Rigid flatfoot. *Clin Orthop Relat Res.* 1977;122:77-84.
32. Kadakia AR, Haddad SL. Hindfoot arthrodesis for the adult acquired flat foot. *Foot Ankle Clin.* 2003;8:569-94, x.
33. Acosta R, Ushiba J, Cracchiolo A 3rd. The results of a primary and staged pantalar arthrodesis and tibiotalar calcaneal arthrodesis in adult patients. *Foot Ankle Int.* 2000;21:182-94.
34. Kelly IP, Easley ME. Treatment of stage 3 adult acquired flatfoot. *Foot Ankle Clin.* 2001;6:153-66.
35. Laughlin TJ, Payette CR. Triple arthrodesis and subtalar joint arthrodesis. For the treatment of end-stage posterior tibial tendon dysfunction. *Clin Podiatr Med Surg.* 1999;16:527-55.
36. Haddad SL, Myerson MS, Pell RF 4th, Schon LC. Clinical and radiographic outcome of revision surgery for failed triple arthrodesis. *Foot Ankle Int.* 1997;18:489-99.
37. Saltzman CL, Fehrle MJ, Cooper RR, Spencer EC, Ponseti IV. Triple arthrodesis: twenty-five and forty-four-year average follow-up of the same patients. *J Bone Joint Surg Am.* 1999;81: 1391-402.