

2-1-2005

# Periacetabular osteotomy for the treatment of severe acetabular dysplasia

John C. Clohisy

*Washington University School of Medicine in St. Louis*

Susan E. Barrett

*Mulroy Orthopedic Surgery and Sports Medicine*

J. Eric Gordon

*St. Louis Shriners Hospital for Children*

Eliana D. Delgado

Perry L. Schoenecker

*St. Louis Shriners Hospital for Children*

Follow this and additional works at: [http://digitalcommons.wustl.edu/open\\_access\\_pubs](http://digitalcommons.wustl.edu/open_access_pubs)



Part of the [Medicine and Health Sciences Commons](#)

---

## Recommended Citation

Clohisy, John C.; Barrett, Susan E.; Gordon, J. Eric; Delgado, Eliana D.; and Schoenecker, Perry L., "Periacetabular osteotomy for the treatment of severe acetabular dysplasia." *The Journal of Bone and Joint Surgery*.87,2. 254-259. (2005).  
[http://digitalcommons.wustl.edu/open\\_access\\_pubs/1065](http://digitalcommons.wustl.edu/open_access_pubs/1065)

# PERIACETABULAR OSTEOTOMY FOR THE TREATMENT OF SEVERE ACETABULAR DYSPLASIA

BY JOHN C. CLOHISY, MD, SUSAN E. BARRETT, MD, J. ERIC GORDON, MD,  
ELIANA D. DELGADO, MD, AND PERRY L. SCHOENECKER, MD

*Investigation performed at St. Louis Shriners Hospital for Children and  
Barnes-Jewish Hospital at Washington University School of Medicine, St. Louis, Missouri*

**Background:** The optimal treatment of severe acetabular dysplasia with subluxation of the femoral head or the presence of a secondary acetabulum remains controversial. The purpose of this study was to analyze the extent of surgical correction and the early clinical results obtained with the Bernese periacetabular osteotomy for the treatment of severely dysplastic hips in adolescent and young adult patients.

**Methods:** Sixteen hips in thirteen patients with an average age of 17.6 years (range, 13.0 to 31.8 years) were classified as having severe acetabular dysplasia (Group IV or V according to the Severin classification). Eight hips were classified as subluxated, and eight had a secondary acetabulum. Preoperatively, all patients had hip pain and sufficient hip joint congruency on radiographs to be considered candidates for the osteotomy. All sixteen hips underwent a Bernese periacetabular osteotomy, and six of them underwent a concomitant proximal femoral osteotomy. Postoperatively, the hips were assessed radiographically to evaluate correction of deformity, healing of the osteotomy site, and progression of osteoarthritis. Clinical results and hip function were measured with the Harris hip score at an average of 4.2 years postoperatively.

**Results:** Comparison of preoperative and follow-up radiographs demonstrated an average improvement of 44.6° (from -20.5° to 24.1°) in the lateral center-edge angle of Wiberg, an average improvement of 51.0° (from -25.4° to 25.6°) in the anterior center-edge angle of Lequesne and de Seze, and an average improvement of 25.9° (from 37.3° to 11.4°) in acetabular roof obliquity. The hip center was translated medially an average of 10 mm (range, 0 to 31 mm). All iliac osteotomy sites healed. The average Harris hip score improved from 73.4 points preoperatively to 91.3 points at the time of the latest follow-up. Eleven of the thirteen patients (fourteen of the sixteen hips) were satisfied with the result of the surgery, and fourteen hips had a good or excellent clinical result. Major complications included loss of acetabular fixation, which required an additional surgical procedure, in one patient and overcorrection of the acetabulum and an associated ischial nonunion in another patient. Both patients had a good clinical result at the time of the latest follow-up. There were no major neurovascular injuries or intra-articular fractures.

**Conclusions:** The periacetabular osteotomy is an effective technique for surgical correction of a severely dysplastic acetabulum in adolescents and young adults. In this series, the early clinical results were very good at an average of 4.2 years postoperatively; the two major complications did not compromise the good clinical results.

**Level of Evidence:** Therapeutic Level IV. See Instructions to Authors for a complete description of levels of evidence.

A variety of pelvic osteotomies have been proposed for the treatment of residual hip dysplasia in adolescents and young adults<sup>1-8</sup>. These osteotomies can be classified as either reconstructive or salvage procedures. The goals of a reconstructive osteotomy are to reposition a congruent,

pre-arthritis acetabulum or femoral head to maximize femoral head coverage with hyaline articular cartilage, decrease high articular cartilage loading, and delay or prevent the onset of secondary osteoarthritis<sup>9,10</sup>. Options for pelvic reconstruction include single, double, and triple innominate osteotomies as well as periacetabular osteotomies. In contrast, salvage osteotomies are performed for patients with established osteoarthritis and/or those with an incongruent hip joint that is less amenable to reorientation of the acetabulum. The Chiari



A commentary is available with the electronic versions of this article, on our web site ([www.jbjs.org](http://www.jbjs.org)) and on our quarterly CD-ROM (call our subscription department, at 781-449-9780, to order the CD-ROM).

TABLE I Radiographic Correction

	Preop.	Postop.	Change
Lateral center-edge angle (deg)	-20.5 (range, -14 to -29)	24.1 (range, 10 to 50)	44.6 (range, 30 to 79)
Anterior center-edge angle (deg)	-25.4 (range, -14 to -45)	25.6 (range, 7 to 35)	51.0 (range, 27 to 73)
Acetabular roof obliquity (deg)	37.3 (range, 23 to 48)	11.4 (range, -5 to 28)	25.9 (range, -11 to 44)

osteotomy and shelf procedures are the most commonly utilized salvage techniques<sup>11</sup>. The goals of salvage osteotomies of the acetabulum are to improve femoral head coverage, albeit with metaplastic fibrocartilage, and to provide additional years of hip function prior to definitive arthroplasty. Despite the availability of these reconstructive and salvage osteotomies, the optimal surgical strategy for treating a severely dysplastic acetabulum remains controversial. Severely dysplastic hips with subluxation of the femoral head or the presence of a false acetabulum (Group IV or V according to the Severin classification<sup>12,13</sup>) pose a particularly challenging problem.

The Bernese periacetabular osteotomy was initially described by Ganz et al.<sup>2</sup> and has subsequently been established as an effective reconstructive osteotomy to treat acetabular dysplasia<sup>11,14-18</sup>. We have performed the periacetabular osteotomy for reconstruction of symptomatic dysplastic hips in adolescents and young adults<sup>19</sup>, and after our initial satisfactory experience with this technique we extended its indications to the treatment of dysplastic hips with severe acetabular deformity. To our knowledge, the efficacy of this osteotomy for the correction of severely dysplastic hips has not been reported. Thus, the purpose of this study was to analyze the magnitude of surgical correction and the early clinical results of the periacetabular osteotomy for treatment of severely dysplastic hips with subluxation or a false acetabulum.

### Materials and Methods

Seventy-six consecutive periacetabular osteotomies were performed in sixty-nine patients with symptomatic acetabular dysplasia between July 1994 and July 2001 by the senior authors (J.C.C. and P.L.S.). On retrospective review of the findings in all seventy-six hips, sixteen in thirteen patients were classified as having Group-IV or V dysplasia according to Severin's system<sup>12,13</sup>; eight of the hips had subluxation and eight, a false acetabulum. There were eleven female patients (twelve hips) and two male patients (four hips) at the time of surgery. The average age at the time of surgery was 17.6 years (range, 13.0 to 31.8 years), and all patients were skeletally mature. No hip had advanced degenerative changes. Three hips had had a previous osteotomy. One of them had been treated with a varus proximal femoral osteotomy without complications. One had had an attempted open reduction in childhood and a subsequent varus proximal femoral osteotomy complicated by deep infection and femoral malunion. The third hip had had a shelf procedure with abductor muscle origin release, a varus proximal femoral osteotomy, and a subsequent valgus proximal femoral osteotomy.

On preoperative evaluation, all patients had  $\geq 110^\circ$  of

hip flexion. Congruency of the hip was determined on functional flexion-abduction radiographs and/or fluoroscopic examination, as previously described<sup>20</sup>. Fluoroscopic evaluation of the hip was performed with both the anteroposterior and the lateral (false-profile) view. With abduction of the hip, the anteroposterior view was used to assess congruency and the lateral coverage that potentially could be achieved with acetabular reorientation. The false-profile view of Lequesne and de Seze<sup>21</sup> was used to assess hip joint congruency in the sagittal plane and the extent of anterior coverage to be achieved with repositioning of the acetabulum. We believe that the functional views and fluoroscopic examination of a patient being considered for periacetabular osteotomy should demonstrate reduction of the femoral head with maintenance or improvement of the joint space and a concentric hip joint articulation. Importantly, localized joint-space narrowing on the functional views indicates lack of concentricity and is a contraindication to acetabular reorientation in our practice.

### Surgical Technique

All sixteen hips underwent periacetabular osteotomy. Six hips in four patients had a concomitant proximal femoral osteotomy to optimize the hip reconstruction. Three of those osteotomies were valgus-producing and three were varus-producing. Two of the hips also had an adductor tenotomy and one had removal of hardware at the time of the index procedure. All acetabular procedures were performed through a modified anterior<sup>11</sup> or modified Smith-Petersen<sup>2</sup> approach. The periacetabular osteotomy was performed as initially described by Ganz et al.<sup>29</sup>. Definitive fixation was achieved with three, four, or five 4.5-mm cortical screws. Supplemental plate fixation was used in three hips, when the screw fixation was deemed to be inadequate. Periacetabular cuts, acetabular fragment reduction, and screw fixation were monitored with intraoperative fluoroscopy. Arthrotomy of the hip was not performed. The Cell Saver (Haemonetics, Braintree, Massachusetts) was utilized for intraoperative blood collection and reinfusion, and electromyographic peripheral nerve monitoring was employed for all patients.

### Clinical and Radiographic Analysis

One senior-level orthopaedic resident and two attending surgeons reviewed the preoperative and follow-up radiographs of all sixteen hips. Clinical hip function was determined preoperatively and at the time of the most recent follow-up with the Harris hip score<sup>22</sup>. The patient's overall satisfaction with the result of the surgery was also recorded. No patient was lost to follow-up. The average duration of clinical follow-up was fifty-

one months (range, twenty-three to ninety-seven months). The most recent clinical data were obtained during an office visit for ten patients and with a telephone interview<sup>23</sup> for six. All patients were followed for at least two years postoperatively. The duration of radiographic follow-up, which consisted of comparisons of preoperative, postoperative, and final follow-up anteroposterior pelvic and false-profile radiographs, averaged thirty-six months (range, twenty-four to sixty-nine months). The anterior center-edge angle of Lequesne and de Seze<sup>21</sup>, lateral center-edge angle of Wiberg<sup>24</sup>, horizontal position of the hip joint center<sup>25</sup>, acetabular roof obliquity<sup>25,26</sup>, integrity of the Shenton line, grade of osteoarthritis, and healing of the osteotomy site were recorded. The osteoarthritis grade was determined with a modification of the Tönnis classification as previously reported<sup>27,28</sup>. A normal joint space was graded as 0; slight narrowing, as 1; moderate narrowing (<50%), as 2; and severe narrowing (>50%), as 3. The presence of periacetabular cysts was also noted.

#### Statistical Analysis

The differences between the preoperative and follow-up hip scores and radiographic parameters were analyzed with a paired t test. Significance was determined to be  $p < 0.05$ .

#### Results (see Appendix)

Eleven of the thirteen patients (fourteen of the sixteen hips) were satisfied with the result of the surgery and were con-

sidered to have a good or excellent clinical result. All eight Severin Group-IV hips and six of the eight Severin Group-V hips had a good or excellent result, with the average Harris hip score improving from 73.4 points (range, 37 to 91 points) preoperatively to 91.3 points (range, 55 to 100 points) at the time of follow-up ( $p = 0.002$ ), at a mean of 4.2 years. Of these eleven patients (fourteen hips), eight (ten hips) had no hip pain and three (four hips) had slight, occasional pain. Nine patients (twelve hips) had no limp; one patient (one hip) had a slight, occasional limp; and one patient (one hip) had a moderate limp. Twelve patients (thirteen hips) required no support for walking, and one patient (one hip) used a walker. The patient with a moderate limp who used a walker had spastic diplegia, which limited overall function and restricted her ability to walk independently. Importantly, this patient had complete resolution of the preoperative hip pain after the osteotomy and was therefore considered to have a good result.

Two patients (two hips, both classified as Severin Group V with a false acetabulum) were dissatisfied with the result of the surgery at the time of the latest follow-up. One of those patients had had a shelf procedure with an abductor muscle origin release, two proximal femoral osteotomies, and mild radiographic signs of osteoarthritis prior to the index periacetabular osteotomy. She had a decrease in symptoms at one year postoperatively but then experienced progressive hip pain and limitation of activity. At the time of the most recent follow-up (at thirty-six months), she was working full time as a waitress;

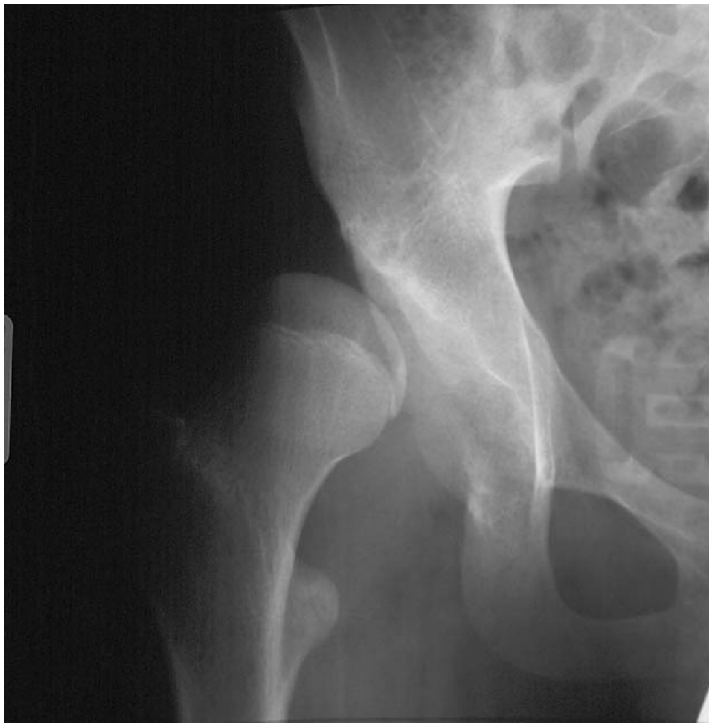

Fig. 1-A

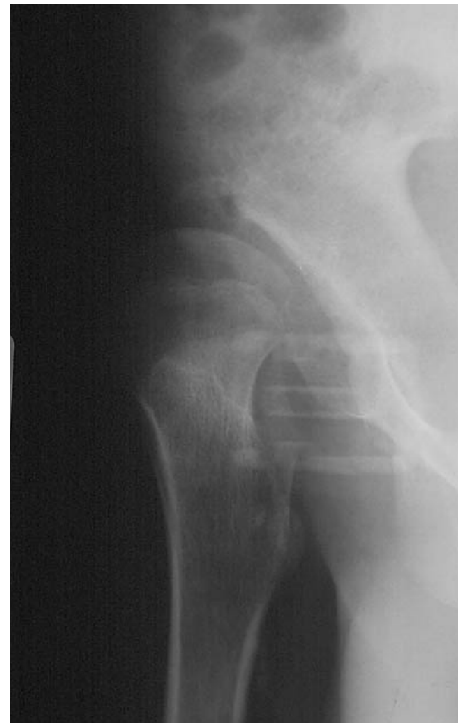

Fig. 1-B

**Figs. 1-A and 1-B** Case 6, a sixteen-year-old boy with severe acetabular dysplasia, as demonstrated on the anteroposterior (Fig. 1-A) and false-profile (Fig. 1-B) radiographs. The patient was treated with a combined periacetabular osteotomy and proximal femoral varus osteotomy.

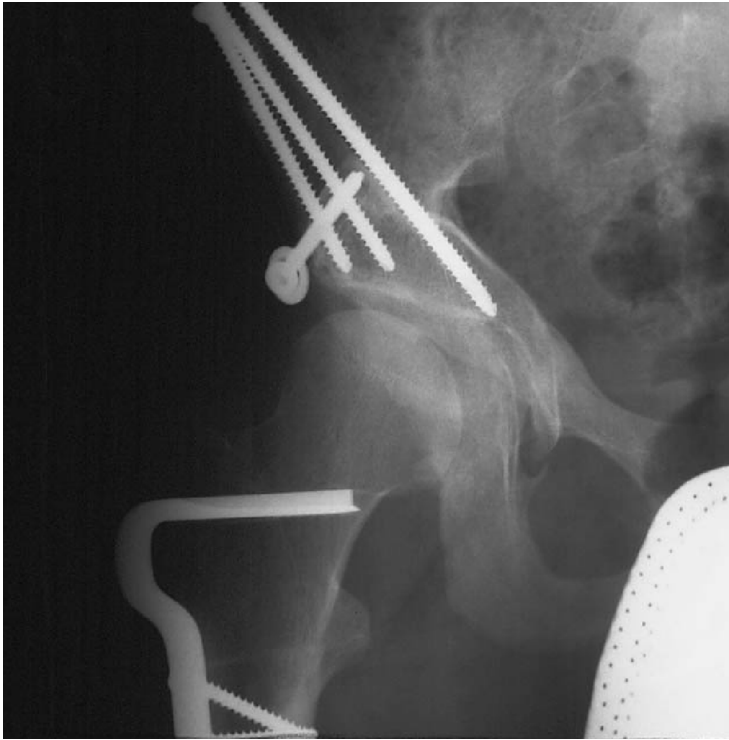

Fig. 1-C

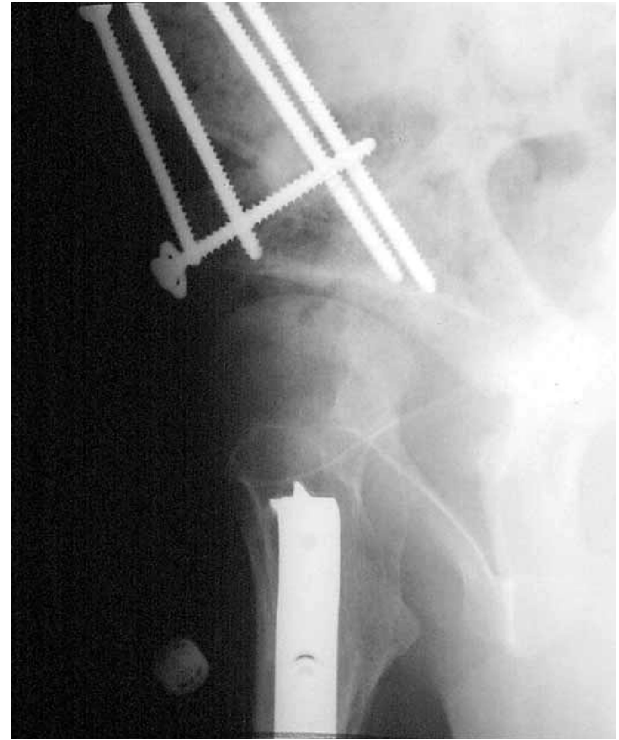

Fig. 1-D

**Figs. 1-C and 1-D** Twenty-three months postoperatively, the patient had an excellent clinical result.

she had marked hip pain and a moderate limp. Radiographs revealed advanced osteoarthritis of the hip. The second dissatisfied patient had had a good clinical result at two years but noted recurrent moderate hip pain at three years. At the time of the most recent follow-up, this patient had a healed osteotomy site with minimal secondary osteoarthritis.

The results of the radiographic analysis of the magnitude of the multiplanar correction are shown in Table I. The lateral center-edge angle improved an average  $44.6^\circ$  (from  $-20.5^\circ$  to  $24.1^\circ$ ;  $p < 0.0001$ ). The anterior center-edge angle improved an average  $51.0^\circ$  (from  $-25.4^\circ$  to  $25.6^\circ$ ;  $p < 0.0001$ ). The acetabular roof obliquity improved an average  $25.9^\circ$  (from  $37.3^\circ$  to  $11.4^\circ$ ;  $p < 0.0001$ ). On the average, the hip joint center was translated medially 10 mm (range, 0 to 31 mm). The continuity of the Shenton line was restored in nine of the sixteen hips. The osteoarthritis grade did not progress in eleven hips. Preoperatively, ten of these eleven hips had grade-0 osteoarthritis, and one had grade 1. The other five hips showed radiographic signs of progression of osteoarthritis, from grade 0 to grade 1 in three and from grade 1 to grade 3 in two. Acetabular cysts were present in four hips preoperatively, and they persisted in three of those hips. A new acetabular cyst developed in one hip and was detected at the time of the last follow-up. All of the sixteen iliac osteotomy sites healed. Two hips had an asymptomatic superior nonunion of the pubic ramus.

#### Complications

Major complications included excessive medial translation of the acetabulum and an associated asymptomatic ischial non-

union in one patient. This patient had a good result and a Harris hip score of 91 points at the time of follow-up, at 3.9 years. The second major complication was early loss of fixation of the acetabulum requiring repeat open reduction and internal fixation. This patient was a twenty-three-year-old woman who returned to smoking two packs of cigarettes per day in the immediate postoperative period despite preoperative counseling and an agreement to terminate smoking in both the preoperative and postoperative periods. This patient also progressed to full weight-bearing immediately after the surgery contrary to our protocol, which dictates partial weight-bearing for the first eight weeks. Subsequently, the osteotomy site healed in this patient. At the time of the latest follow-up, 2.7 years after the second procedure, she had an excellent clinical result with a Harris hip score of 100 points.

There were no major neurovascular problems, no intra-articular fractures, and no evidence of osteonecrosis of the acetabulum in this series.

#### Discussion

Joint-preserving surgical management of a severely dysplastic acetabulum in adolescents and young adults presents a major challenge for the reconstructive hip surgeon. Initial patient evaluation is extremely important when acetabular reorientation with a periacetabular osteotomy is being considered. The evaluation should establish that the hip joint has sufficient congruency and an adequate range of motion. Congruency of the hip is often difficult to ascertain on routine radiographic examination because of the relatively small acetabular articular

surface area. In these instances, we have found functional radiographs and fluoroscopic examination of the hip to be helpful in demonstrating improved articulation of the femoral head and acetabulum in both the coronal and the sagittal plane. Functional radiographs that show impingement due to a lack of femoral head reduction, “levering out” of the femoral head due to a lack of concentricity, or localized joint-space narrowing are indicative of incongruity and, in our view, constitute contraindications to a reorientation periacetabular osteotomy. A candidate for periacetabular osteotomy must have, in addition to congruency of the joint, an adequate range of motion of the hip that will tolerate a major reorientation of the acetabulum. In general, at least 105° of hip flexion and 30° of abduction should be present on physical examination. Finally, radiographic analysis must demonstrate minimal or no secondary osteoarthritis, as moderate or advanced secondary disease may compromise the clinical result<sup>17</sup>. Previous surgery about the hip should be noted because residual scar tissue, osseous deformity, retained hardware, and compromise of the abductor muscles may complicate the procedure and affect the final clinical result.

Others have reported that rotational acetabular osteotomy is an effective surgical option for the management of a severely dysplastic hip<sup>3,29</sup>. With this technique, the acetabulum is fashioned into a hemispherical shape with an osteotomy, starting at the external region of the joint capsule, and the acetabulum is rotated en bloc anterolaterally. Ninomiya reported the results of this osteotomy in forty-one severely dysplastic hips (Severin group IV or V)<sup>3</sup>. Radiographic evidence of correction was excellent in most patients and, on the average, the lateral center-edge angle improved from -21.1° preoperatively to 25.6° postoperatively and the acetabular roof obliquity improved from 39.6° to 10.9°. Clinical assessment with the modification of the Severin grading system proposed by Gibson and Benson<sup>30</sup> showed a good or excellent clinical result in thirty-one (76%) of the hips at a mean of seven years postoperatively. Major complications included osteonecrosis of the acetabulum that resulted in a delayed union in one patient.

Shindo et al.<sup>29</sup> reviewed the results of rotational acetabular osteotomy in nineteen hips in seventeen patients with severe dysplasia (Severin group V) followed for an average of ten years. Eleven hips had a concomitant proximal femoral osteotomy. The mean lateral center-edge angle improved from -16.8° to 28.5°, and the mean acetabular roof obliquity improved from 43.5° to 12.8°. Fifteen hips had a very good or good clinical result according to the Merle d’Aubigné hip score.

Despite the encouraging results in the above two studies, we think that rotational acetabular osteotomy has certain disadvantages. We consider it to be more difficult to perform because the hemispherical osteotomy is closer to the acetabulum and it produces a smaller acetabular fragment that may be more susceptible to osteonecrosis. Matsui et al.<sup>25</sup> reviewed the results of rotational acetabular osteotomy in nineteen hips (eighteen patients) and reported a 40% prevalence of chondrolysis and collapse of the transferred acetabulum. Additionally, the ability to provide medial translation of the hip joint center is limited with the rotational acetabular osteotomy, whereas it is con-

sistently achieved with the periacetabular osteotomy<sup>31</sup>.


When considering surgical options for reorientation of a severely dysplastic acetabulum, the surgeon should be aware that the Bernese periacetabular osteotomy has potential advantages<sup>9</sup>. The procedure is performed through one surgical approach, and it includes a series of straight periacetabular osteotomies that maintain the integrity of the posterior column and preserve the blood supply to the acetabular fragment. The osteotomy fragment can be mobilized to obtain multiplanar corrections, and the intact posterior column enables early mobilization and facilitates rehabilitation. In the present study, radiographic examination after this osteotomy showed excellent improvement in lateral femoral head coverage, anterior femoral head coverage, acetabular inclination, and the horizontal position of the hip joint (Figs. 1-A through 1-D). Osteotomy site healing was predictable, and fourteen of the sixteen hips had a good or excellent clinical result at an average of 4.2 years postoperatively. It is noteworthy that the two hips that failed clinically were both in Severin Group V, with a false acetabulum. This suggests that the prognosis for hips with a false acetabulum may be less predictable than that for Severin Group-IV subluxated hips. This finding was not unexpected given that the articular surface of a false acetabulum is fibrocartilage rather than hyaline articular cartilage. Nevertheless, given our favorable clinical experience and the positive results reported with rotational acetabular osteotomies in Severin Group-V hips<sup>3,29</sup>, we believe that acetabular reorientation is feasible in selected patients with a false acetabulum. It should be emphasized that the relatively young age of our patients (average, 17.6 years) and our selection criteria may have favorably affected the results achieved in Severin Group-V hips.

The two major complications in our study occurred during our “learning curve” with this osteotomy. It has been reported that the complication rates associated with this procedure diminish over time as the surgeon becomes more experienced<sup>14</sup>. Thus, we are confident that, even in this population of patients with severely dysplastic hips, our complication rate will not increase as our experience is broadened. Additionally, refinement of the osteotomy technique may optimize future results. For example, as our experience has increased, the ability to optimize the acetabular reduction has improved. Our surgical technique has also evolved to include a routine arthrotomy after acetabular reorientation to assess labral pathology and femoroacetabular impingement. We now recognize that severely dysplastic hips may have an associated aspherical femoral head with reduced head-neck offset, which can result in anterior femoroacetabular impingement after acetabular reorientation<sup>32</sup>. Therefore, we now assess hip flexion and combined flexion and internal rotation at the time of the arthrotomy. If anterior impingement is present, we establish a head-neck offset with a resection osteoplasty<sup>32</sup> to optimize hip flexion and minimize the potential for clinical symptoms related to anterior femoroacetabular impingement.

In conclusion, at a mean of 4.2 years, the results of Bernese periacetabular osteotomies performed for surgical correction of severely dysplastic hips in adolescent and young

adult patients were encouraging. We prefer this osteotomy because we can predictably obtain major reorientation of the acetabulum in all planes, reliable osseous healing, and good clinical results in the early follow-up period. Clearly, longer-term follow-up of these patients is essential to define the durability of the results of this osteotomy when performed in patients with severe acetabular dysplasia.

### Appendix

 A table presenting detailed information on each patient is available with the electronic versions of this article, on our web site at [jbjs.org](http://jbjs.org) (go to the article citation and click on "Supplementary Material") and on our quarterly CD-ROM (call our subscription department, at 781-449-9780, to order the CD-ROM). ■

John C. Clohisy, MD  
Washington University School of Medicine, 660 South Euclid, Campus Box 8233, St. Louis, MO 63110. E-mail address: [jclohisy@msnotes.wustl.edu](mailto:jclohisy@msnotes.wustl.edu)

Susan E. Barrett, MD  
Mulroy Orthopedic Surgery and Sports Medicine, 321 Fortune Building, 1st Floor, Milford, MA 01757

J. Eric Gordon, MD  
Perry L. Schoenecker, MD  
St. Louis Shriners Hospital for Children, 2001 South Lindbergh Boulevard, Saint Louis, MO 63131

Eliana D. Delgado, MD  
400 Parnassus Avenue, Suite A311, San Francisco, CA 94117

The authors did not receive grants or outside funding in support of their research or preparation of this manuscript. They did not receive payments or other benefits or a commitment or agreement to provide such benefits from a commercial entity. No commercial entity paid or directed, or agreed to pay or direct, any benefits to any research fund, foundation, educational institution, or other charitable or nonprofit organization with which the authors are affiliated or associated.

doi:10.2106/JBJS.D.02093

### References

- Chiarì K. Medial displacement osteotomy of the pelvis. *Clin Orthop*. 1974;98:55-71.
- Ganz R, Klaue K, Vinh TS, Mast JW. A new periacetabular osteotomy for the treatment of hip dysplasias. Technique and preliminary results. *Clin Orthop*. 1988;232:26-36.
- Ninomiya S. Rotational acetabular osteotomy for the severely dysplastic hip in the adolescent and adult. *Clin Orthop*. 1989;247:127-37.
- Salter RB, Hansson G, Thompson GH. Innominate osteotomy in the management of residual congenital subluxation of the hip in young adults. *Clin Orthop*. 1984;182:53-68.
- Steele HH. Triple osteotomy of the innominate bone. *J Bone Joint Surg Am*. 1973;55:343-50.
- Sutherland DH, Greenfield R. Double innominate osteotomy. *J Bone Joint Surg Am*. 1977;59:1082-91.
- Sutherland DH, Moore M. Clinical and radiographic outcome of patients treated with double innominate osteotomy for congenital hip dysplasia. *J Pediatr Orthop*. 1991;11:143-8.
- Wagner H. Experiences with spherical acetabular osteotomy for the correction of the dysplastic acetabulum. *Progr Orthop Surg*. 1978;2:131-45.
- Leunig M, Siebenrock KA, Ganz R. Rationale of periacetabular osteotomy and background work. *Instr Course Lect*. 2001;50:229-38.
- Millis MB, Murphy SB, Poss R. Osteotomies about the hip for the prevention and treatment of osteoarthritis. *J Bone Joint Surg Am*. 1995;77:626-47.
- Murphy SB, Millis MB. Periacetabular osteotomy without abductor dissection using direct anterior exposure. *Clin Orthop*. 1999;364:92-8.
- Severin E. Contribution to the knowledge of congenital dislocation of the hip joint. Late results of closed reduction and arthrographic studies of recent cases. *Acta Chir Scand*. 1941;84(Suppl 63):37.
- Zionts LE, MacEwen GD. Treatment of congenital dislocation of the hip in children between the ages of one and three years. *J Bone Joint Surg Am*. 1986;68:829-46.
- Davey JP, Santore RF. Complications of periacetabular osteotomy. *Clin Orthop*. 1999;363:33-7.
- Matta JM, Stover MD, Siebenrock K. Periacetabular osteotomy through the Smith-Petersen approach. *Clin Orthop*. 1999;363:21-32.
- Siebenrock KA, Scholl E, Lottenbach M, Ganz R. Bernese periacetabular osteotomy. *Clin Orthop*. 1999;363:9-20.
- Trousdale RT, Ekkernkamp A, Ganz R, Wallrichs SL. Periacetabular and intertrochanteric osteotomy for the treatment of osteoarthritis in dysplastic hips. *J Bone Joint Surg Am*. 1995;77:73-85.
- Trumble SJ, Mayo KA, Mast JW. The periacetabular osteotomy. Minimum 2 year follow-up in more than 100 hips. *Clin Orthop*. 1999;363:54-63.
- Clohisy J, Barrett SE, Gordon JE, Delgado ED, Schoenecker PL. Early results of the Bernese periacetabular osteotomy in the treatment of residual hip dysplasia in adolescent patients. Read at the Annual Meeting of the American Academy of Orthopaedic Surgeons; 2003 Feb 5-9; New Orleans, LA.
- Murphy S, Deshmukh R. Periacetabular osteotomy: preoperative radiographic predictors of outcome. *Clin Orthop*. 2002;405:168-74.
- Lequesne M, de Seze. [False profile of the pelvis. A new radiographic incidence for the study of the hip. Its use in dysplasias and different coxopathies]. *Rev Rhum Mal Osteoartic*. 1961;28:643-52. French.
- Harris WH. Traumatic arthritis of the hip after dislocation and acetabular fractures: treatment by mold arthroplasty. An end-result study using a new method of result evaluation. *J Bone Joint Surg Am*. 1969;51:737-55.
- McGrory BJ, Shinar AA, Freiberg AA, Harris WH. Enhancement of the value of hip questionnaires by telephone follow-up evaluation. *J Arthroplasty*. 1997;12:340-3.
- Wiberg G. Studies on dysplastic acetabular and congenital subluxation of the hip joint. With special reference to the complication of osteoarthritis. Parts HV. *Acta Chir Scand Suppl*. 1939;58:7-38.
- Matsui M, Masuhara K, Nakata K, Nishii T, Sugano N, Ochi T. Early deterioration after modified rotational acetabular osteotomy for the dysplastic hip. *J Bone Joint Surg Br*. 1997;79:220-4.
- Massie WK, Howarth MB. Congenital dislocation of the hip. Part I. Methods of grading results. *J Bone Joint Surg Am*. 1950;32:519-31.
- Mayo KA, Trumble SJ, Mast JW. Results of periacetabular osteotomy in patients with previous surgery for hip dysplasia. *Clin Orthop*. 1999;363:73-80.
- Tönnis D. Congenital dysplasia and dislocation of the hip in children and adults. Berlin; New York: Springer; 1987.
- Shindo H, Igarashi H, Taneda H, Azuma H. Rotational acetabular osteotomy for severe dysplasia of the hip with a false acetabulum. *J Bone Joint Surg Br*. 1996;78:871-7.
- Gibson PH, Benson MK. Congenital dislocation of the hip. Review at maturity of 147 hips treated by excision of the limbus and derotation osteotomy. *J Bone Joint Surg Br*. 1982;64:169-75.
- Clohisy JC, Barrett SE, Gordon JE, Delgado ED, Schoenecker PL. Medial translation of the hip joint center associated with the Bernese periacetabular osteotomy. *Iowa Orthop J*. 2004;24:43-8.
- Myers SR, Eijer H, Ganz R. Anterior femoroacetabular impingement after periacetabular osteotomy. *Clin Orthop*. 1999;363:93-9.