

From the DEPARTMENT OF CLINICAL SCIENCE AND
EDUCATION, SÖDERSJUKHUSET
Karolinska Institutet, Stockholm, Sweden

DISPLACED FEMORAL NECK FRACTURES IN THE ELDERLY: TREATMENT WITH ARTHROPLASTIES

Christian Inngul



**Karolinska
Institutet**

Stockholm, 2015

All previously published papers were reproduced with the permission of the publishers:
Wolters Kluwer Health Inc. & Springer Science and Business Media
Published by Karolinska Institutet
Printed by Åtta45 Tryckeri AB
© Christian Inngul, 2015
ISBN 978-91-7549-982-6

Displaced femoral neck fractures in the elderly – Treatment with arthroplasties

THESIS FOR DOCTORAL DEGREE (Ph.D.)

By

Christian Inngul

Principal Supervisor:

Anders Enocson, Associate Professor
Karolinska Institutet
Department of Clinical Science and Education,
Södersjukhuset

Opponent:

Lars Weidenhielm, Professor
Karolinska Institutet
Department of Molecular Medicine and Surgery

Co-supervisor(s):

Richard Blomfeldt, PhD
Karolinska Institutet
Department of Clinical Science and Education,
Södersjukhuset

Examination Board:

Olof Sköldenberg, Associate Professor
Karolinska Institutet
Department of Clinical Sciences,
Danderyds Hospital

Sari Ponzer, Professor
Karolinska Institutet
Department of Clinical Science and Education,
Södersjukhuset

Suzanne Werner, Professor
Karolinska Institutet
Department of Molecule Medicine and Surgery

Hans Mallmin, Professor
Uppsala University
Institute of Surgical Sciences,
Uppsala University Hospital

To Maria, Ebba, Maja and...

Table of Contents

Abstract	6
List of papers	7
List of abbreviations	8
Introduction	9
Treatment of femoral neck fractures	9
Bipolar arthroplasty	13
Periprosthetic fractures in hip fracture patients	14
Uncemented arthroplasties	15
Patients and Methods	17
Ethics	17
Age and gender	17
Study I	17
Study II	18
Study III	18
Study IV	19
Randomisation	19
Fracture classification	20
Anaesthesiological assessment and ASA classification	22
Cognitive function	22
EQ-5D	22
Charnley Score	23
Harris Hip Score	23
SMFA	24
Radiological assessment	25
Statistical methods	25
Results	26
Study I	26
Study II	31
Study III	38
Study IV	42
General Discussion	49
Conclusions	61
Implications for clinical practice and future research	62
Abstract in Swedish	64
Acknowledgements	65
References	67
Original papers I–IV	76

Abstract

Treatment of displaced femoral neck fractures in the elderly with arthroplasties has become standard practice during the last decade and results in good and predictable outcomes regarding hip function and health-related quality of life (HRQoL). There is, however, a lack of evidence concerning certain types of arthroplasties and different subgroups of patients. Patients with severe cognitive dysfunction have a very limited life expectancy after a hip fracture and low functional demands, as well a low HRQoL before the injury. Many surgeons have concerns regarding arthroplasties in these patients. The bipolar hemiarthroplasty (HA) is designed to reduce stress and erosion on the patient's natural acetabulum and should, in theory, render a better functional outcome and HRQoL than the unipolar HA. Patients with arthroplasties after displaced femoral neck fractures are at higher risk of sustaining a late periprosthetic fracture (PPF) compared to patients treated due to degenerative joint disease. In addition, some prosthetic designs have been pointed out as being a risk factor for PPF. Uncemented arthroplasties are widely used for various indications and show excellent clinical results. In addition, there are concerns about cementing in older frail patients with multiple comorbidities. All patients in Studies I to IV have been treated with arthroplasties because of a displaced femoral neck fracture.

Study I is a randomised controlled trial (RCT) comparing treatment with internal fixation (IF) and treatment with HA in patients with severe cognitive dysfunction. Compared to treatment with IF, HAs appear to result in a better HRQoL and fewer reoperations.

Study II is an RCT with a 48-month follow-up comparing bipolar and unipolar HAs. Treatment with a bipolar HA resulted in a better HRQoL after four years.

In Study III a cohort of 2757 patients with primary or secondary arthroplasties after femoral neck fractures were investigated. A single cemented femoral implant was used. The incidence of PPFs was high (2.3%) in the cohort, but the surgical outcome after reoperation for a PPF was better compared to previous reports.

Study IV is an RCT with a 12-month follow-up comparing uncemented arthroplasties with cemented arthroplasties. The uncemented arthroplasties showed inferior results regarding functional outcome and HRQoL.

The main conclusions of this thesis are: Treatment of displaced femoral neck fractures with arthroplasties is safe, even for patients with severe cognitive dysfunction; the use of uncemented arthroplasties should be avoided and there are still controversies regarding the use of bipolar Has.

List of papers

This thesis is based on the four following papers, which are indicated in the text by their roman numerals (Studies I to IV)

- I. Internal fixation versus cemented hemiarthroplasty for displaced femoral neck fractures in patients with severe cognitive dysfunction: a randomized controlled trial.
Hedbeck CJ, Inngul C, Blomfeldt R, Ponzer S, Törnkvist H, Enocson A.
J Orthop Trauma. 2013 Dec;27(12):690-5.

- II. Unipolar hemiarthroplasty versus bipolar hemiarthroplasty in patients with displaced femoral neck fractures: a four-year follow-up of a randomised controlled trial.
Inngul C, Hedbeck CJ, Blomfeldt R, Lapidus G, Ponzer S, Enocson A.
Int Orthop. 2013 Dec;37(12):2457-64.

- III. Postoperative periprosthetic fractures in patients with an Exeter stem due to a femoral neck fracture: cumulative incidence and surgical outcome.
Inngul C, Enocson A.
Int Orthop. 2014 Oct 24. [Epub ahead of print]

- IV. Cemented versus uncemented arthroplasty in patients with displaced femoral neck fractures: a randomised controlled trial.
Inngul C, Blomfeldt R, Ponzer S, Enocson A.
Manuscript submitted.

List of abbreviations

ASA	American Society of Anesthesiologists
EQ-5D	5-dimension scale of the EuroQol
EQ-5D index score	Quality of life score generated from the EQ-5D questionnaire
HA	Hemiarthroplasty
HHS	Harris Hip Score
HRQoL	Health-related quality of life
IF	Internal fixation
ITT	Intention to treat
PPF	Periprosthetic fracture
SPMSQ	Short portable mental status questionnaire
RCT	Randomised controlled trial
THA	Total hip arthroplasty

Introduction

Patients with hip fractures are a very common sight at orthopaedic departments throughout the world and one of the great challenges for today's health care.

A hip fracture is associated with high mortality and morbidity among the elderly. Recent studies from both the U.S. and Europe show that the economic burden of osteoporosis-related fractures outweighs the burden of myocardial infarction, stroke or breast cancer (Lippuner, Grifone et al. 2012, Singer, Exuzides et al. 2015).

In Sweden, we treat approximately 18,000 patients with hip fractures every year (Rikshöft 2013). There have been reports from several parts of the world that the age-adjusted incidence of hip fractures is decreasing. Speculations on underlying causes have involved better medical management of osteoporosis, better general health among the elderly, better and faster treatment options and better medical follow-up after treatment (Rogmark, Sernbo et al. 1999, Jaglal, Weller et al. 2005, Kannus, Niemi et al. 2006). More recent studies have, however, shown that the incidence curve is tending to shift to the right and we will be dealing with a higher percentage of older patients. An aging and growing population will result in approximately 30,000 annual hip fractures in 2050 in Sweden, as predicted by Rosengren et al. (Rosengren and Karlsson 2014).

Treatment of femoral neck fractures

The treatment of femoral neck fractures has been the cause of debate throughout the orthopaedic community for many years. The intracapsular fracture of the femoral neck (occurring proximal to the attachment of the hip joint capsule to the femur) is the cause of substantial mortality and morbidity as patients suffering from such a fracture are at great risk of facing impaired walking ability, persistent pain and loss of independent living conditions. Healing complications after IF of displaced fractures are frequent due to impairment of the blood supply to the femoral head caused by the fracture. Stable fracture reduction and fixation are therefore crucial for healing. The fracture classification mostly used to assess fractures of the femoral neck is the Garden classification (Garden 1961) from 1961. This classification is widely accepted as it makes possible the distinction between undisplaced (Garden 1 and 2) and displaced fractures (Garden 3 and 4). This distinction has been proven to highly correlate with

predictions of outcome after femoral neck fractures (Thomsen, Jensen et al. 1996, Blundell, Parker et al. 1998).

The most common healing complications after internal fixation (IF) of a displaced femoral neck fracture are non-union and avascular necrosis. Despite disruption of the blood supply to the femoral head, union of the fracture can still occur and the structural integrity of the femoral head can be preserved for a long time (Bachiller, Caballer et al. 2002). Most of the healing complications will, however, occur within the first two years after the IF procedure, but avascular necrosis can become symptomatic as late as four years after IF (Blomfeldt, Törnkvist et al. 2005). Figure 1.

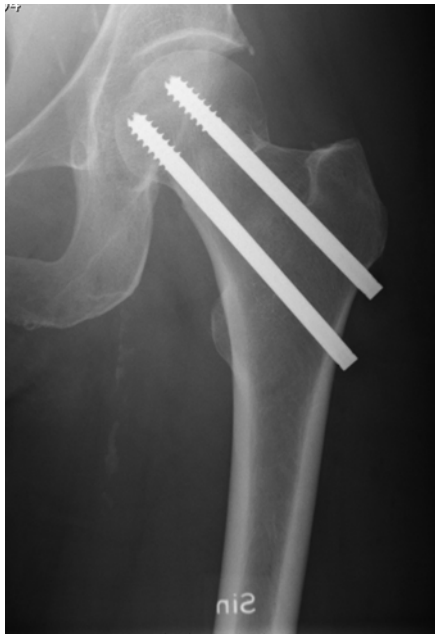

Figure 1 Fracture fixation with two cannulated screws

Traditionally, IF has been the treatment of choice in Sweden for both undisplaced and displaced fractures of the femoral neck. For undisplaced fractures, IF is still the treatment of choice as it has been shown to yield good results regarding complication rates and HRQoL (Tidermark, Zethraeus et al. 2003). However, Rogmark et al. recently published a retrospective study on elderly patients (median age 81) with undisplaced femoral neck fractures treated with IF indicating that as many as 40% of the included patients had some kind of residual pain in the operated hip while walking and 25% had pain at rest (Rogmark, Flensburg et al. 2009). Undisplaced femoral neck fractures are, however, not within the scope of this thesis.

For displaced fractures of the femoral neck, IF has mostly been abandoned since it results in healing complications leading to reoperations in 35% to 42% of the patients (Bhandari, Devereaux et al. 2003). The inferiority of IF, compared to treatment with arthroplasties, regarding reoperation rates, function and HRQoL has been confirmed in a meta-analysis (Bhandari, Devereaux et al. 2003) and a Cochrane report (Masson, Parker et al. 2003), as well as in multiple RCTs (Rogmark, Carlsson et al. 2002, Tidermark, Ponzer et al. 2003, Blomfeldt, Törnkvist et al. 2005, Keating, Grant et al. 2006).

The spectrum of patients suffering from a displaced fracture of the femoral neck ranges from young patients after high-energy trauma to elderly, bedridden patients with multiple comorbidities sustaining a low-energy fall. Therefore, every surgeon must have a variety of treatment options in his toolbox. Most of them will advocate IF for younger patients, even those with displaced femoral neck fractures. Preserving the natural femoral head in a younger patient with high functional demands is the main objective when treating this group of patients (Bhandari, Devereaux et al. 2005). Another group of patients with displaced fractures of the femoral neck regularly treated with IF is those who are considered to be medically too frail to undergo surgery with an arthroplasty.

Arthroplasties have become the standard treatment for such diseases as osteoarthritis and rheumatoid arthritis and yield excellent results regarding function, HRQoL and long-term implant survivorship for these indications. The total hip arthroplasty has therefore been titled the ‘operation of the century’ (Learmonth, Young et al. 2007).

Treatment of displaced femoral neck fractures with arthroplasties has a long history within the orthopaedic community. Today’s version of the classical Austin Moore prosthesis was invented by Dr Austin Moore (1899–1963) and has been used since the early 1950’s (Moore 1952). Although not used in Sweden anymore, in 2010 the British National Hip Fracture Database reported the use of uncemented, uncoated unipolar hemiarthroplasties in 19.2% of the patients (Currie C 2011). Even though the database does not report on implant specifics, one can assume that many of these prostheses are Austin Moore prostheses.

Total hip arthroplasties have been shown to result in excellent functional outcome after a displaced fracture of the femoral neck (Tidermark, Ponzer et al. 2003, Blomfeldt, Törnkvist et al. 2005, Heetveld, Rogmark et al. 2009, Parker, Gurusamy et al. 2010). Despite the good results, there are concerns regarding the magnitude of the surgical trauma that these patients are confronted with and the risk for postoperative complications, such as dislocations, surgical site

infections and increased mortality. Most current treatment guidelines will therefore limit the use of THAs for displaced fractures of the femoral neck to younger patients (although within the cohort of patients with fragility fractures) with higher functional demands and a longer expected survivorship (Florschutz, Langford et al. 2015, Roberts, Brox et al. 2015).

HA is a good alternative to THA in the oldest patients as the procedure in these patients results in good pain relief, good HRQoL, acceptable functional results and often leads to a return to the patient's preinjury living conditions. Many surgeons have HA as their preferred choice for displaced fractures of the femoral neck in the elderly and in patients with multiple medical comorbidities (Bhandari, Devereaux et al. 2005) (Figure 2 a-b).

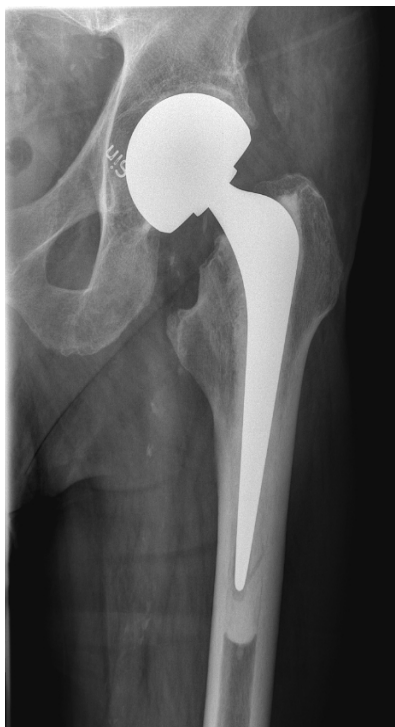
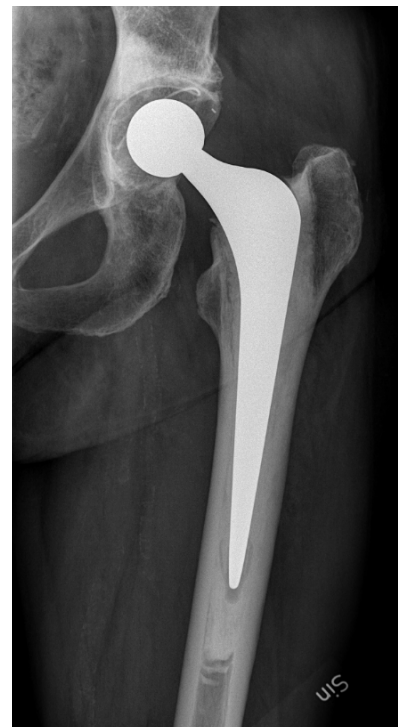
Figure 2a Unipolar hemiarthroplasty;



2b Total hip arthroplasty

Despite all the evidence supporting the use of arthroplasties, IF is superior to any kind of arthroplasty regarding blood loss, operating time and postoperative infection rates (Bhandari, Devereaux et al. 2003, Heetveld, Rogmark et al. 2009). There is, however, no evidence that this would result in lower mortality rates for the IF patients. Mortality seems to be more influenced by age, medical comorbidities and cognitive status rather than the severity of the surgical procedure (Heetveld, Rogmark et al. 2009). Despite the evidence in favour of treatment with arthroplasties, patients with severe cognitive impairment are often treated with IF. There are doubts about operating with arthroplasties in a group of patients that is prone to dislocations,

surgical site infections and new traumas due to their failure to understand postoperative instructions. IF is even considered to be a more 'merciful' operation in this group of patients with a considerable one-year mortality after hip fracture (48%) (Söderqvist, Miedel et al. 2006).

Bipolar arthroplasty

When using an HA there are two types of articulations of the prosthesis and the patient's acetabulum: unipolar and bipolar. While the unipolar head has a single articulation between the prosthesis and the acetabulum, the bipolar head offers a second articulation between an inner smaller head and the polyethylene liner of the larger outer head (Figure 3). In theory, this reduces stress on the acetabular surface and thereby acetabular erosion. Acetabular erosion is believed to cause pain and impaired hip function. Since the bipolar articulation allows for a greater range of motion due to the extra articulation, the bipolar concept has been suggested to result in better hip function and fewer dislocations. The use of bipolar HAs has, however, been on the decrease in Sweden since a report from the Swedish Hip Arthroplasty Register (SHAR) which shows a higher risk for reoperation for bipolar HAs than for unipolar HAs. This includes a higher risk for reoperations due to dislocation (Leonardsson, Kärrholm et al. 2012). The results from the SHAR are in contrast to multiple clinical trials in which the authors could not demonstrate superiority of either the unipolar or the bipolar articulation concerning surgical or functional outcome (Enocson, Hedbeck et al. 2012, Liu, Tao et al. 2014). There is, however, promising evidence from a recent meta-analysis that bipolar HAs lead to less acetabular erosion at 12 months follow-up (Jia, Ding et al. 2015). The clinical relevance of this finding has yet to be proven though.

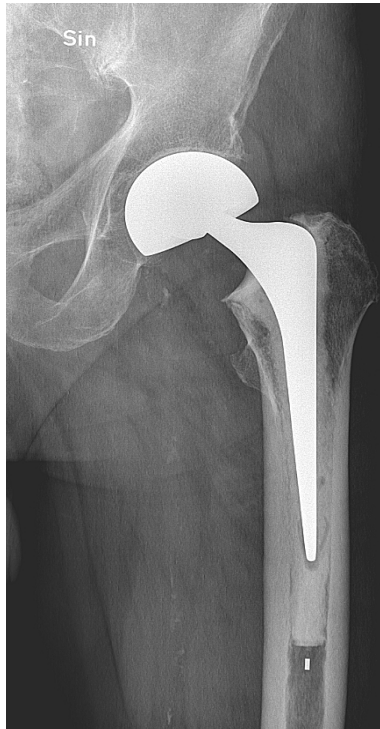

Figure 3 Bipolar arthroplasty

Periprosthetic fractures in hip fracture patients

A periprosthetic fracture of the femur is a rare, but devastating, complication after hip arthroplasty surgery. The main goal when treating a PPF is to obtain a stable prosthesis and fixation of the fracture, thus allowing early rehabilitation and thereby avoiding complications associated with immobilisation. The surgical treatment of a PPF can be challenging and must often combine the skills of a trauma surgeon and a hip revision surgeon. Cases with a well-fixed stem can be treated with open reduction and internal fixation (ORIF). If the stem is unstable, it has to be revised and the femur stabilised around the new stem. Incidence rates of PPFs vary in the literature from 0.4% (Lindahl, Malchau et al. 2005) to 1.4% (Berry 1999), but these figures often comprise a mixture of indications, implants and patients. Patients receiving any kind of arthroplasty due to a hip fracture are at higher risk of sustaining a PPF (Lindahl, Garellick et al. 2006a). This increase in risk is related to advanced age, impaired walking ability, medical comorbidities and osteoporosis. Another risk factor for PPFs seems to be certain implant designs. There is evidence from the SHAR that polished stem designs are a risk factor for sustaining a PPF (Register 2013). Very few studies have investigated a specific patient subgroup and a specific stem design regarding the surgical outcome after treatment of PPFs.

Uncemented arthroplasties

Besides THA and HA with either unipolar or bipolar articulation, one can distinguish arthroplasties by the fixation method. In cemented arthroplasties, the prosthesis is fixed to the bone by using bone cement (polymethyl methacrylate [PMMA]) to create an interface between the prosthesis and the bone. This method gained wide acceptance after Sir John Charnley's report on his 'low friction arthroplasty' (Charnley 1970). The use of PMMA in arthroplasties dates back to the late 1940s (D'Aubigne and Postel 1954). D'Aubigne used PMMA to mould an arthroplasty rather than using it for fixation of an arthroplasty made of other material.

The use of uncemented arthroplasties has an even longer tradition. Moore and Bohman fabricated an uncemented arthroplasty for the treatment of a patient with a giant cell tumour in the hip in 1939 (Hernigou, Quiennec et al. 2014). In uncemented arthroplasties, the prosthesis is inserted in close contact with the natural bone and fixated primarily by screws or by press-fit. Modern uncemented designs have a coating on the surface (e.g., titanium and/or hydroxyapatite) that facilitates bone on- or ingrowth. Both cemented and uncemented designs display excellent results and long-term survivorship in several national arthroplasty registers (Register 2010, Register 2013, Register 2014) (Figure 4a-b).

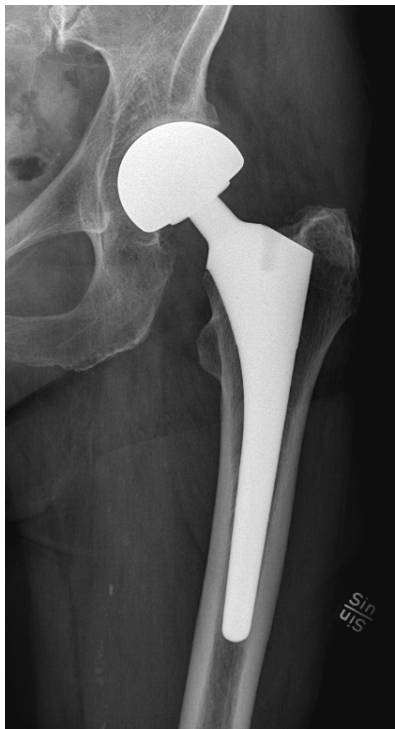
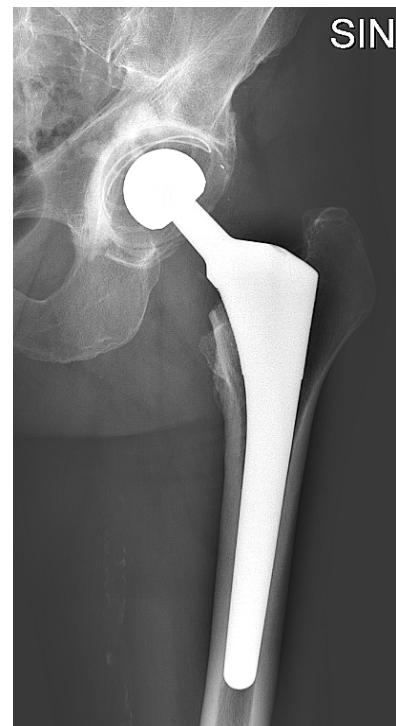
Figure 4a Uncemented unipolar HA



4b Reverse hybrid THA

Advocates of uncemented arthroplasties often cite the bone cement implantation syndrome as a rare but devastating complication to cementation with the possibility of death during surgery as the worst possible outcome (Olsen, Kotyra et al. 2014). The aetiology is not totally clear, but most authors agree that pressurisation of the femoral canal under the cementation procedure forces fat and bone marrow content into the venous circulation and this is then the possible cause of pulmonary embolism. Hip fracture patients are generally more frail and older than other arthroplasty patients and are therefore at greater risk for cardiopulmonary complications such as pulmonary embolism. The use of uncemented prostheses is considered to be a possible way to avoid the bone cement implantation syndrome. On the other hand, a femoral neck fracture in an elderly patient is typically associated with osteoporosis, which makes the bone on- and ingrowth more difficult. Recent reports show, however, good survivorship of uncemented prostheses in osteoporotic bone (Kelly, Robbins et al. 2007, Meding, Galley et al. 2010). Uncemented arthroplasties have also been reported to be at higher risk of sustaining both intra- and postoperative PPFs (Lindahl, Garellick et al. 2006a, Leonardsson, Kärrholm et al. 2012). In the 2010 Cochrane Review, *Arthroplasties (With and Without Bone Cement) for Proximal Femoral Fractures in Adults*, the authors concluded that cemented fixation leads to less pain and better mobility one year after surgery, but no differences in complications or mortality were detected (Parker, Gurusamy et al. 2010). However, the authors also concluded that mainly old prosthesis designs (both uncemented and cemented) were investigated, and the need for further studies including modern prostheses was pointed out.

Differences concerning pain and functional outcomes when using modern, uncemented prosthetic designs still have to be proven.

Patients and Methods

Ethics

All four studies were conducted in conformity with the Helsinki Declaration and the Ethics Committee of Karolinska Institutet approved each protocol. In Studies II and IV, all the patients gave their informed consent to participate. In Study I, the family or legal guardian provided informed consent.

Age and gender

The mean age of the patients in Study I was 84.6 years and 83% were females. In Study II, the mean age was 86.4 years and 76% of all patients were females. In Study III, the median age of all included patients was 82 years and 73% were of female gender. In Study IV, the mean age of all patients was 81.3 years and 70% were females.

Study I

Between June 2005 and May 2012, we included 60 patients with an acute displaced fracture of the femoral neck (Garden 3 and 4) (OTA/AO type 31-B). Inclusion criteria were severe cognitive dysfunction (defined as a score of 2 or less on the Short Portable Mental Status Questionnaire (SPMSQ)), age 70 years or older and independent walking ability with or without walking aids. Exclusion criteria were pathological fractures, previous osteoarthritis or other ipsilateral hip disorders and fractures older than 24 hours on admission. Before inclusion in the study, the family or guardian gave their informed consent. Family and/or caregivers were then interviewed as proxies for all patient-related outcome measures.

Patients were followed up at 4, 12 and 24 months postoperatively. If the patients declined to come to the outpatient clinic, a visit to the patient's residence was offered. Radiographs were taken pre- and postoperatively and again at the 4, 12 and 24-month follow-ups.

Study II

Between August 2005 and October 2008, we included 120 patients with an acute displaced fracture of the femoral neck (Garden 3 and 4). Inclusion criteria were age 80 or older, absence of severe cognitive dysfunction (≥ 3 correct answers on the SPMSQ) and independent walking and living conditions. Exclusion criteria were pathological fractures, previous osteoarthritis or other ipsilateral hip disorders and fractures older than 48 hours on admission. Patients with a history of mental illness, alcohol or drug abuse were also excluded. All patients gave their informed consent.

Patients were followed up clinically and radiologically at 4, 12, 24 and 48 months postoperatively. If the patients declined to come to the outpatient clinic, a visit to the patient's residence was offered. The results of the 4 and 12-month follow-ups have been published previously (Hedbeck, Blomfeldt et al. 2011).

Study III

A consecutive series including all patients who had undergone a primary or secondary arthroplasty due to a non-pathological femoral neck fracture between 1 January 1998 and 31 December 2010 was identified and included in this study. In addition to audit data, all individual patient records were searched up to 31 December 2012 or death in order to obtain information about all reoperations due to periprosthetic fractures. Finally, the Swedish personal identification number was used to perform a search in the National Board of Health and Welfare's nationwide register to find any patients who had been reoperated elsewhere in Sweden. Two such cases were found. Mortality records were obtained from the Swedish National Cause of Death Register. The median follow-up time was 39 months.

For patients with a PPF the preoperative radiographs were analysed separately according to the Vancouver classification by the two investigators. The investigators disagreed about two cases in the Vancouver B group. After a discussion which resulted in a consensus, both cases were included in the subgroup B2. Patients with Vancouver A fractures were not included.

Study IV

Between October 2009 and April 2013, 964 patients with a non-pathological, acute, displaced (Garden 3 or 4) fracture of the femoral neck after a low-energy trauma presented at our institution. Of these patients, 141 were included in this study. Inclusion criteria were age 65 or older, absence of severe cognitive dysfunction (≥ 3 correct answers on the SPMSQ), independent living status and walking ability (with or without walking aids). Exclusion criteria were pathological fractures, osteoarthritis or other ipsilateral hip disorders and fractures older than 48 hours on admission. Patients with a history of mental illness or alcohol or drug abuse were also excluded. All patients gave their informed consent.

Patients were randomised to either a cemented or an uncemented femoral stem. Patients aged between 65 and 79 were allocated to treatment with either a cemented THA or a reverse hybrid THA. Patients aged 80 years or older were allocated to treatment with either a cemented or an uncemented unipolar HA. The study was originally designed as two independent studies examining HAs and THAs separately, but, owing to a slow inclusion rate, a decision was taken in November 2012 to pool the two original studies.

Patients were followed up clinically and radiologically at 4 and 12 months postoperatively. If the patients declined to come to the outpatient clinic, a visit to the patient's residence was offered.

Randomisation

The randomisation procedures in Studies I, II and IV were performed with independently prepared, numbered, opaque and sealed envelopes.

Fracture classification

The fracture classification used to determine eligibility for inclusion in Studies I, II and IV was the widely used Garden classification (Garden 1961). In addition to the Garden classification, all fractures in Study I were classified according to the OTA/AO classification (Marsh, Slongo et al. 2007). The Garden classification is based on the anteroposterior radiograph alone.

Undisplaced fractures are Garden type 1 (valgus impacted fracture) and Garden type 2 (undisplaced fracture). Displaced fractures are Garden type 3 (partially displaced fracture) and Garden type 4 (fully displaced fracture) (Figure 5).

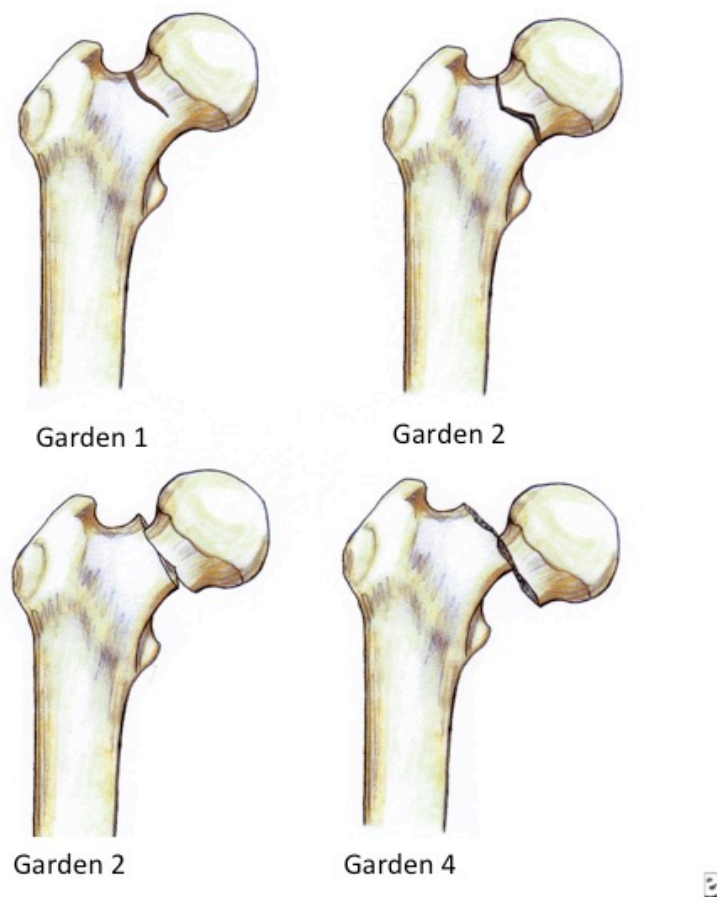


Figure 5 Schematics of the Garden classification

Apart from making it possible to compare results, the purpose of a fracture classification is to facilitate clinical decision-making and to provide information on the prognosis. The division into displaced and undisplaced fractures is the only classification that is reproducible and

related to healing complications after IF treatment (Thomsen, Jensen et al. 1996, Blundell, Parker et al. 1998).

In Study III, all PPFs were classified according to the Vancouver classification (Duncan and Masri 1995). The Vancouver classification is a combination of an anatomical and a surgical classification system. It takes the anatomical location of the fracture (e.g., greater or lesser trochanter) into account, as well as making predictions of treatment options (e.g., a well-fixed or loose stem) and the quality of the bone. The Vancouver classification is a universal system that applies to all joints and all kinds of arthroplasties, but it was developed for periprosthetic femoral fractures after hip replacement surgery. Fractures of the greater and lesser trochanter do not compromise the stability of the implant and are labelled AG and AL.

Fractures around the stem are labelled B. A B1 fracture is situated around the stem, and the stem is well fixed. A B2 fracture is situated around the stem, and the stem is loose. In a B3 fracture, the fracture is situated around the stem, the stem is loose and there is radiological evidence of severe bone loss.

Finally, the C fracture is situated below a well-fixed stem (Figure 6).

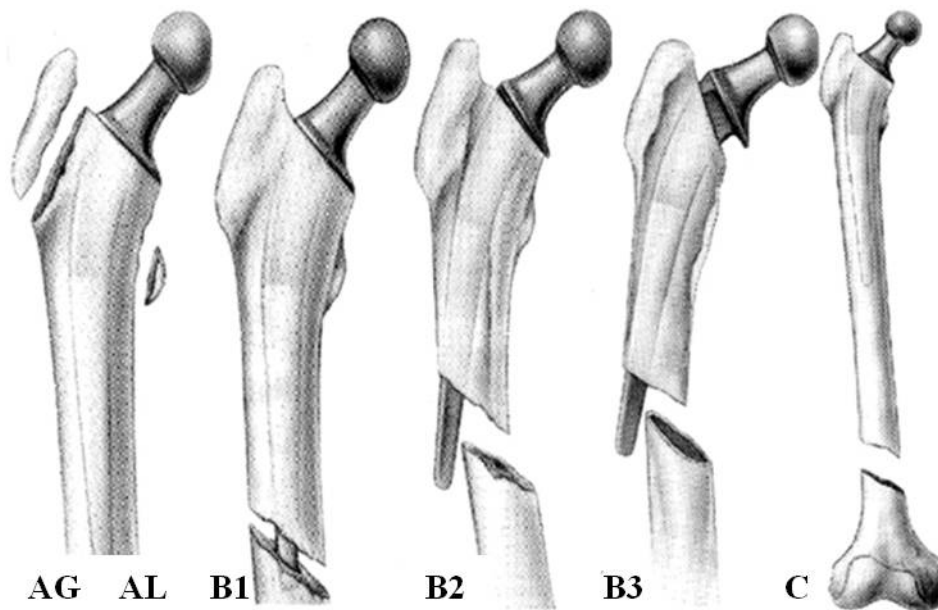


Figure 6 Schematics of the Vancouver classification

Anaesthesiological assesment and ASA classification

All patients in Studies I, II and IV were, prior to inclusion, assessed by an anaesthetist and cleared for surgery with an arthroplasty. The ASA (American Society of Anesthesiologists) classification (Owens, Felts et al. 1978) was used to assess physical health prior to surgery. The ASA classification has been proven to be a good predictor of mortality in hip fracture patients (Söderqvist, Ekström et al. 2009). ASA grade 1 indicates a normal healthy patient; ASA grade 2 indicates a patient with mild systemic disease; ASA 3 indicates a patient with severe systemic disease; ASA grade 4 indicates a patient with severe systemic disease that is a constant threat to life; ASA grade 5 indicates a moribund patient who is not expected to survive without the operation.

Cognitive function

Cognitive function is a strong predictor of outcome after hip fracture surgery (Givens, Sanft et al. 2008, Söderqvist, Ekström et al. 2009). The instrument that was used to assess cognitive dysfunction in Studies I, II and IV was the Short Portable Mental Status Questionnaire (SPMSQ) (Pfeiffer 1975). The SPMSQ consists of 10 questions where every correct answer generates 1 point. A result of 2 points or less on the SPMSQ is strongly correlated with increased mortality after hip fracture surgery (Söderqvist, Miedel et al. 2006). Patients with 3 points or more were excluded from Study I. Patients with 2 points or less were excluded from Studies II and IV.

EQ-5D

HRQoL is a broad multidimensional concept that often includes self-reported measures of physical and mental health. The EQ-5D (Brooks 1996) is, in particular, a standardised instrument for use as a measure of health outcome. The EQ-5D questionnaire is widely used throughout the orthopaedic community and is the standard HRQoL outcome measure used at our institution. It is very concise and easy to use, especially for the elderly population (Brazier, Walters et al. 1996). It has been validated in hip fracture patients (Coast, Peters et al. 1998) and shows good responsiveness (Tidermark, Bergström et al. 2003, Tidermark and Bergström 2007).

The EQ-5D consists of the following 5 dimensions: Mobility, Self-care, Usual activities, Pain/Discomfort and Anxiety/Depression. Each dimension has three levels: No problems, Some problems, Extreme problems. The original EQ-5D also includes a visual analogue scale for the patients to rate their perceived health status. This instrument was not used in any of the studies. Each dimension with three different alternatives produces a 5-digit code with different weights assigned to every digit. The preference scores used to weight the raw results of the EQ-5D were taken from a large population study in the United Kingdom (Dolan, Gudex et al. 1996). The worst possible health state is represented by 0 and the best possible by 1. The EQ-5D index score can then be displayed as a central tendency and measures of dispersion.

Preinjury EQ-5D index scores were obtained using the recall principle. The patients were asked to recall their health status one week prior to injury. This method has been proven by others to work as a valid measure (Marsh, Bryant et al. 2009).

Charnley score

The hip function in Study I was rated using the Charnley score (Charnley 1972), which consists of three parts: Pain, Movement and Walking ability. Each part is graded from 1 to 6, where 1 equals total disability and 6 normal status, giving a maximum and best score of 18. A central tendency can then be calculated for comparisons of each part.

Harris Hip Score

Hip function in Studies II and IV was reported using the Harris Hip Score (HHS) (Harris 1969). HHS consists of four dimensions. Each dimension has a specific number of points attached to it. The total sum of all the points generates a maximum score of 100: Pain (0–44 points); Function (0–47 points); Absence of deformity (0–4 points) and Range of motion (0–5). A higher score means better hip function. Except for the range of motion dimension, the HHS is self-reported by the patient. The HHS has good responsiveness in hip fracture patients (Frihagen, Grotle et al. 2008), even though it has been criticised for its ceiling effect (Wamper, Sierevelt et al. 2010).

SMFA

The Short Musculoskeletal Function Assessment (SMFA) (Swiontkowski, Engelberg et al. 1999) was used in Study IV to evaluate functional status before and after hip fracture surgery.

The SMFA is designed to detect differences in the functional status of patients who have a broad range of musculoskeletal disorders. It also allows patients to evaluate how bothered they are by functional problems. The SMFA has good overall responsiveness for hip fracture patients (Hedbeck, Tidermark et al. 2011).

The SMFA contains two parts: the Dysfunction index and the Bother index. The Dysfunction index has 34 items, which are divided into four categories: Daily activities, Emotional status, Function of arm and hand and Mobility. Each item has five different response alternatives. The Dysfunction index is intended to interpret the patient's perception of difficulties and actual difficulties they encounter in performing certain functions. The Bother index has 12 items, each of which has five different response alternatives. The Bother index is intended to interpret how much the patient is bothered by problems they encounter in different areas of daily life.

The raw index is recalculated into a sum score using the formula:

$$(\text{actual raw score} - \text{lowest possible raw score}) / (\text{possible range of raw score}) \times 100$$

This generates a score from 0 to 100. A higher score indicates poorer function. In Study IV the patients recalled their functional status one week prior to surgery.

Radiological assessment

All postoperative radiographs in Studies I, II and IV were assessed for presence of acetabular erosion. The grading system used was a 4-grade scale ranging from 0 to 3 (Baker, Squires et al. 2006). Grade 0 represents no evidence of acetabular erosion; Grade 1 represents joint space narrowing; Grade 2 represents acetabular bone erosion; Grade 3 represents protusio acetabuli.

In Study I the quality of IF was graded by the method described by Lindeqvist et al. in 1995 (Lindeqvist and Törnkvist 1995). The reduction of the fracture was categorised as good (displacement < 2 mm, Garden angle 160° to 175°, posterior angulation < 10°), fair (displacement < 5 mm, Garden angle 160° to 175°, posterior angulation < 20°) or poor (displacement > 5 mm, Garden angle < 160° or > 175°, posterior angulation < 20°).

The position of the screws was categorised as good if the screw tips were less than 5 mm from the subchondral bone and the screws were parallel (< 10° angle).

In Study IV all femurs were classified preoperatively as type A, B or C using the Dorr classification (Dorr, Faugere et al. 1993). Type A has a funnel shaped proximal femur with thick cortices. Type B has thinned proximal cortices and the femoral canal is widened. Type C has a very wide and pipe shaped femoral canal as well as very thin cortices.

Statistical methods

The statistical software used in Studies I and II was IBM SPSS, version 20, for Windows. In Studies III and IV, the updated version 22 of the IBM SPSS software was used. All power analyses were performed with IBM Sample Power 2.0 for Windows.

In Studies I to IV, the Mann-Whitney U test was used to compare scale and ordinal variables in independent groups. Nominal variables were tested by Fisher's exact test. In Study II, the Chi-square test was used in addition to Fisher's exact test to compare nominal variables. In Study IV, Wilcoxon's signed-rank test was used to compare data at the 4 and 12-month follow-ups. All tests were two-sided. The results were considered significant at $p < 0.05$.

In Study III, a Kaplan-Meier survival analysis was calculated with a PPF, death or end-of-study as endpoints.

Results

Study I

A flowchart of all included patients is shown in Figure 7. One patient randomised to HA was excluded due to a wrong diagnosis (subtrochanteric fracture) discovered intraoperatively. Another patient randomised to IF was operated on with an HA due to an irreducible fracture. All analyses were performed according to the intention-to-treat (ITT) principle.

The overall mortality was 32% (19 out of 59) at 4 months, 44% (26 out of 59) at 12 months and 63% (37 out of 59) at 24 months. No significant differences in mortality were seen between the groups. One patient refused the 4-month follow-up and one patient refused the 24-month follow-up.

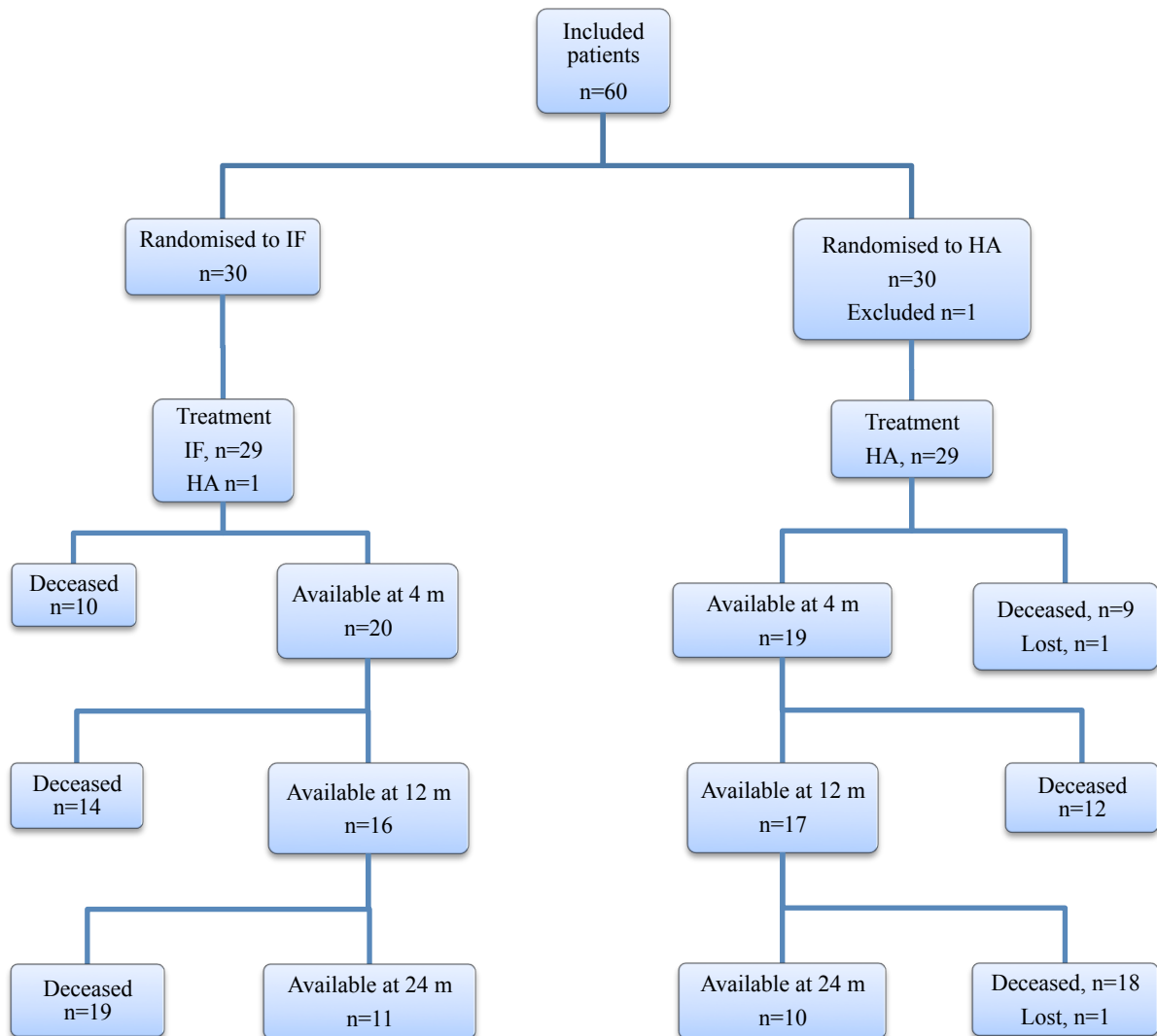


Figure 7. Flowchart of all included patients

Health-related quality of life and hip function

HRQoL was the main outcome measure of this study. The EQ-5D index score at all follow-ups was generally lower in the IF group than in the HA group (Figure 8). At 12 months, the difference was significant ($p = 0.03$), but not at the 24-month follow-up.

No difference in hip function according to the Charnley score was found between the groups at any of the follow-ups.

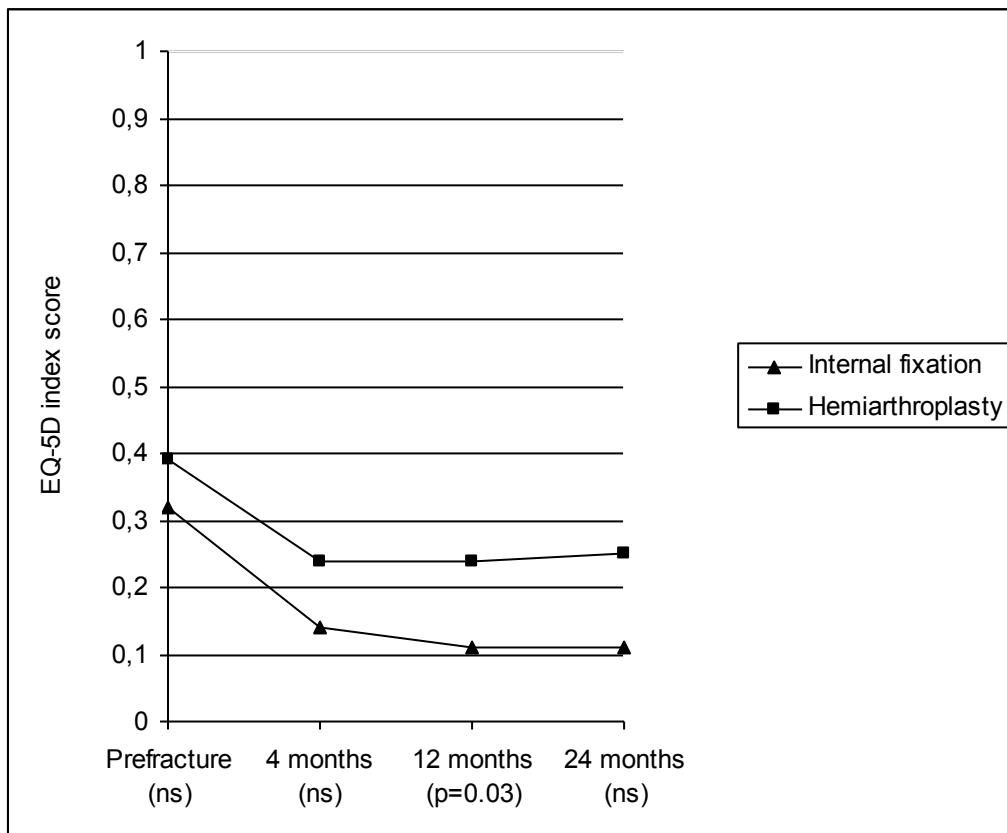


Figure 8. Mean EQ-5D index score prefracture at 4 months, 12 months and 24 months in relation to the operation; ns = no significant difference between groups

Surgical outcome

Eight out of 59 patients were reoperated upon, giving a total reoperation rate of 14%. In the IF group, 23% (7 out of 30) were reoperated upon, compared to 3% (1 out of 29) in the HA group ($p = 0.05$). The most usual reason for reoperation was non-union of the fracture after IF ($n = 4$), followed by a trochanteric fracture in the same hip after IF ($n = 2$), dislocation of the HA ($n = 1$) or lateral pain from screw ends after IF ($n = 1$) (Table 1). In one of the IF patients suffering from a non-union (no. 5, Table 1), the fracture was not adequately reduced (a ventral displacement of 4 mm). In addition, the position of both screw tips was in the superior half of the femoral head. In both IF patients who sustained a trochanteric fracture in the same hip after a new fall, the lateral entry point of the screws was not adequate since the inferior screw was inserted at the lower level of, and 5 mm below, the lesser trochanter.

The mean operating time was significantly longer in the HA group (67 [36–110] min) than in the IF group (30 [13–115] min) ($p < 0.001$). Also, the mean intraoperative bleeding was more extensive in the HA group (236 [100–400] ml) than in the IF group (127 [20–500]) ml ($p = 0.003$).

Table 1. All reoperations (n = 8)

Patient no.	Age	Gender	Primary operation	Reason for reoperation	Time to reoperation	Reoperation	History
1	89	Male	IF	Non-union	3.5 months	Girdlestone	No further operations
5	96	Female	IF	Non-union	2.5 months	Unipolar HA	Plate osteosynthesis due to a periprosthetic fracture 1.5 months after HA operation
9	80	Female	IF	Trochanteric fracture, same hip	18 months	Intramedullary nail	No further operations
11	84	Female	IF	Lateral pain from screw ends	15 months	Extraction of screws	No further operations
13	92	Female	IF	Non-union	3 months	Unipolar HA	No further operations
31	87	Female	HA	Dislocation	2 weeks	Open reduction	No further operations
32	86	Female	IF	Trochanteric fracture, same hip	1 month	Unipolar HA	3 weeks after HA; 3 times dislocation of prosthesis and subsequent prosthesis extraction
59	80	Female	IF	Non-union	1 month	Unipolar HA	Patient died during HA operation

Radiological results

In 14 of the 29 IF patients, the reduction and screw position was classified as good. In four of the 29 IF patients, the reduction was classified as fair. In one patient, the reduction was classified as poor and, in another patient, the reduction was classified as fair and the screw position as poor. This patient (no. 5, Table 1) was subsequently reoperated upon with an HA due to non-union of the fracture.

Postoperatively, all HA patients had a good position of the prosthesis on radiographs. At the 4-month follow-up, there were two patients with a grade 1 acetabular erosion and one patient with a grade 2. At the next follow-up after 12 months, there were three patients with a grade 1 erosion and one patient with grade 2. Finally, at the 24-month follow-up, five patients had a grade 1 and two patients a grade 2 acetabular erosion. All patients alive at the 24-month follow-up had available radiographs.

General complications

General complications at four months in the HA group were: one patient with a superficial wound infection, one patient with a pressure ulcer and one patient with a deep venous thrombosis. In the IF group, there were no general complications.

Study II

A flowchart of all included and followed patients is displayed in Figure 9.

The overall mortality was 4.2% (5 out of 120) at 4 months, 16% (19 out of 120) at 12 months, 22% (26 out of 120) at 24 months and 45% (54 out of 120) at 48 months. There were no differences in mortality between unipolar and bipolar patients at any time.

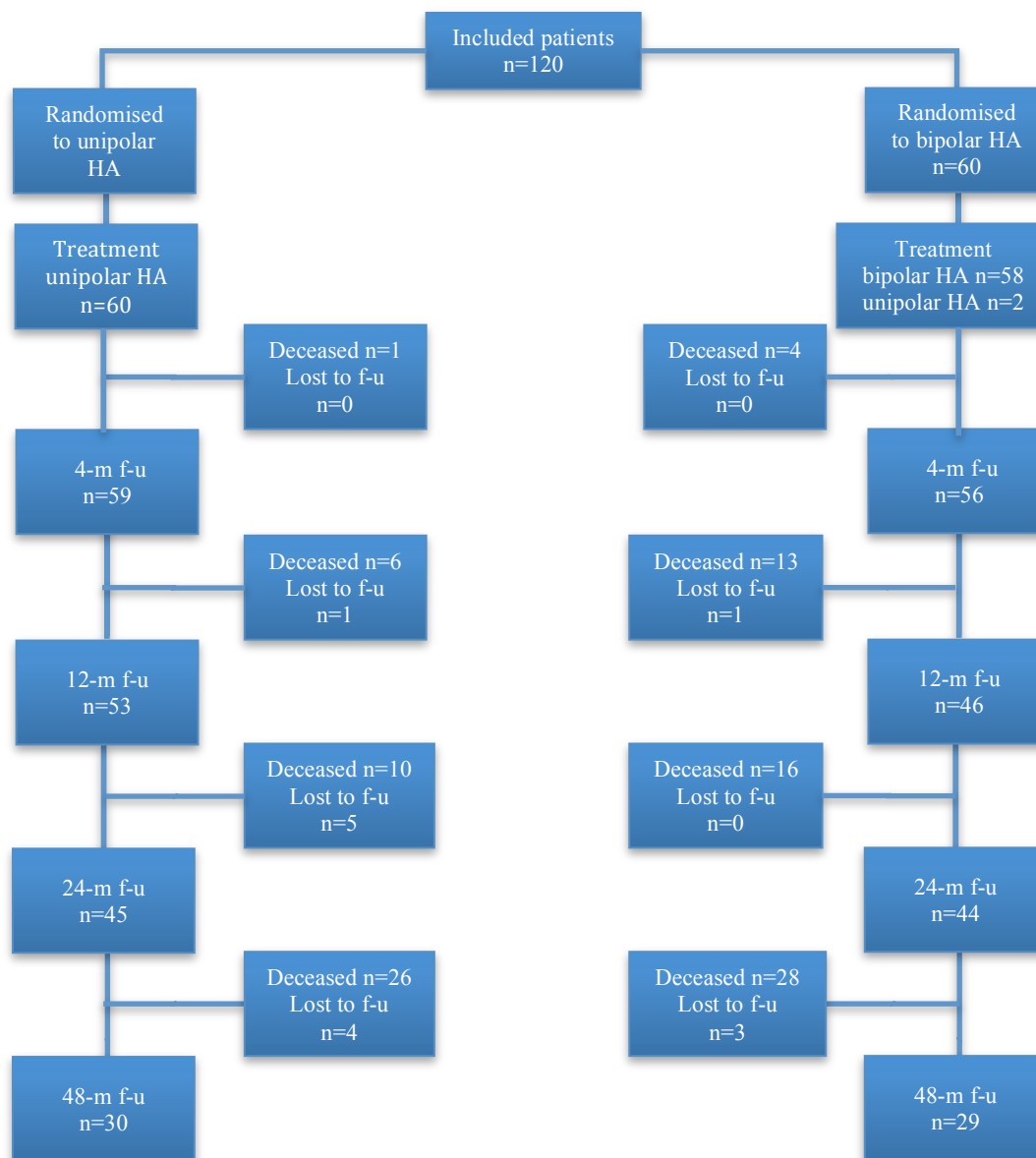

Figure 9. Flowchart of all included patients; m = month, f-u = follow-up.

Hip function and Health-related Quality of Life

The main outcome of this study was hip function measured by the Harris Hip Score. The secondary outcome was HRQoL, measured by the EQ-5D index score.

The HHS showed no differences between the groups, neither in the total score nor in the subscores at any of the follow-ups (Table 2).

Table 2 Mean (range) Harris Hip Score for available patients

	Unipolar HA (n=60)	Bipolar HA (n=60)	p-value
4 months, n = 114			
Total score	73.8 (44–98)	75.5 (24–95)	0.2
Pain score	39.5 (20–44)	40.3 (10–44)	0.2
12 months, n = 99			
Total score	78.2 (34–100)	77.7 (33–100)	1.0
Pain score	41.3 (20–44)	40.5 (20–44)	0.9
24 months, n = 89			
Total score	76.6 (28–98)	77.8 (50–100)	1.0
Pain score	40.9 (20–44)	42.0 (30–44)	0.6
48 months, n = 59			
Total score	75.8 (38–100)	77.6 (46–100)	0.9
Pain score	41.5 (20–44)	41.9 (20–44)	0.5

HA= hemiarthroplasty; p-values are given for differences between groups.

Missing values due to patients declining: at 4 months, n = 1; at 12 months, n = 2; at 24 months, n = 5; at 48 months, n = 7

HRQoL measured by the EQ-5D index score was generally lower in the unipolar HA group. This was consistent throughout the whole follow-up time. As expected, there was no difference in the preinjury score. The score deteriorated postoperatively to a much lower level in both groups, but the difference between the groups was not statistically significant before the 48-month follow-up (Figure 10).

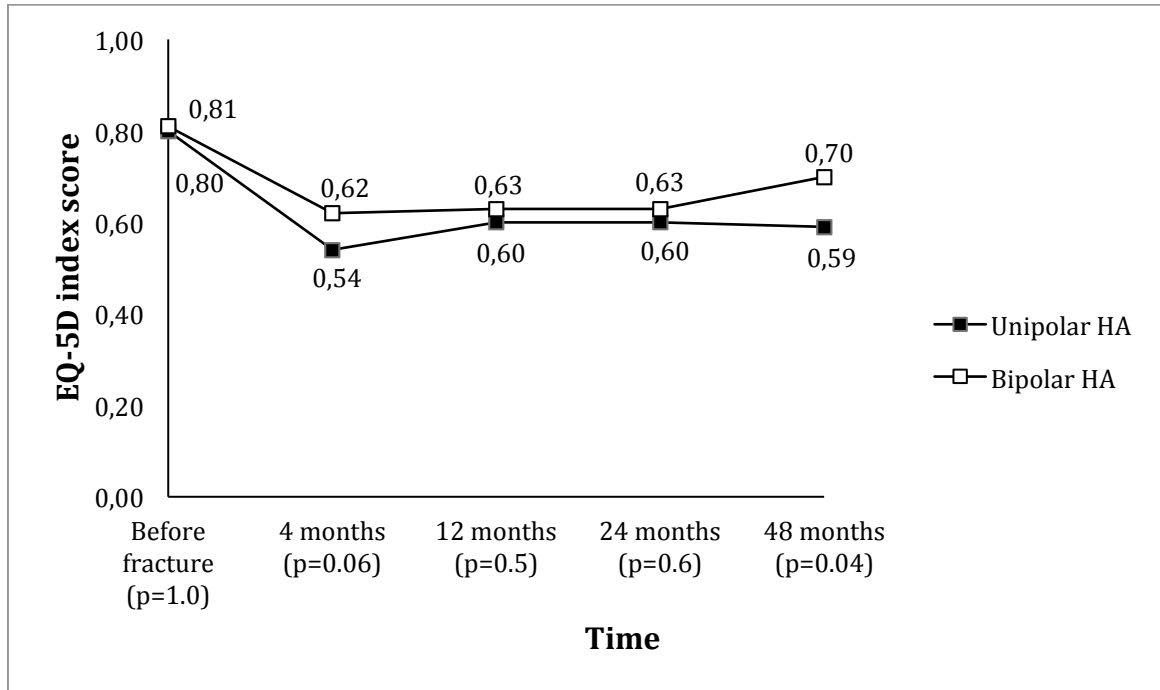


Figure 10. Health-related quality of life (mean EQ-5D index score) before fracture and at follow-ups. Missing values due to patients declining: at 4 months, n = 3; at 12 months, n = 2; at 24 months, n = 5; at 48 months, n = 9. p-values are given for differences between groups.

Surgical outcome

The cumulative reoperation rate over the study period was 9.2% (11 out of 120 patients). There were more reoperations in the bipolar group (13% [8 out of 60]) than in the unipolar group (5% [3 out of 69]), but the difference was not statistically significant. Ten of the 11 complications leading to reoperations occurred within the first two months after the index operation. One patient in the bipolar group suffered a periprosthetic fracture 15 months after the index operation. All four patients reoperated on due to a suspected deep infection were treated with antibiotics plus open debridements (1 to 7 times) and tissues were collected for bacterial cultures, from which bacterial growth could be verified in three patients. Three of the patients with a suspected deep infection healed uneventfully, but in one patient the infection was persistent and the prosthesis was therefore extracted. Out of the four patients sustaining a periprosthetic fracture, three were reoperated upon with revision of the stem to a long, cemented

Exeter stem and one patient was reoperated upon with revision of the stem to a distally fixed uncemented Link MP stem. All three patients who sustained a prosthetic dislocation were treated with closed reductions (1 to 3 times) and were stable afterwards. All reoperations are shown in Table 3.

There was no difference in the mean duration of the surgery: 72 min (range 37–109) for the unipolar group and 69 min (range 39–126) for the bipolar group ($p = 0.1$). Nor were there any differences in the mean intraoperative blood loss between the unipolar patients (290 ml [range 50–1200]) and the bipolar patients (240 ml [range 50–600]) ($p = 0.3$).

Table 3. Data on the 11 patients undergoing reoperations

Patient no.	Gender	Group	Indication for reoperation	Reoperation	Time to reoperation
7	Male	Bipolar	Periprosthetic fracture	Stem revision to cemented long Exeter stem	15 months
18	Female	Unipolar	Prosthetic dislocation	Closed reduction x 3	19 days
20	Female	Bipolar	Deep infection	Wound revision x 3	25 days
34	Female	Unipolar	Prosthetic dislocation	Closed reduction x 2	13 days
40	Male	Bipolar	Deep infection	Wound revision x 7	2 months
41	Male	Bipolar	Periprosthetic fracture	Stem revision to Cemented, long Exeter stem	1 month
68	Male	Bipolar	Periprosthetic fracture	Stem revision to uncemented Lubinus MP stem	1.5 months
69	Male	Bipolar	Periprosthetic fracture	Stem revision to cemented long Exeter stem	2 months
82	Female	Unipolar	Deep infection	Wound revision x 5, finally extraction of prosthesis	24 days
86	Female	Bipolar	Deep infection	Wound revision x 1, negative culture	18 days
106	Female	Bipolar	Prosthetic dislocation	Closed reduction x 1	15 days

Acetabular erosion

In general, the unipolar group displayed more acetabular erosion at all follow-ups (Table 4). The difference was statistically significant at the 12-month follow-up. Initially, the bipolar group displayed only limited acetabular erosion compared to the unipolar group, but the incidence in the bipolar group increased over time and the difference disappeared at the 24- and 48-month follow-ups. One patient in the unipolar group showed grade 3 erosion at the 24-month follow-up. All other patients were graded with erosion grade 1 or 2.

Table 4. Number of patients with available radiographs and acetabular erosion grade ≥ 1 at the follow-ups

	Unipolar HA	Bipolar HA	p-value
4 months	9/57 (16%)	3/55 (5.5%)	0.1
12 months	10/49 (20%)	2/44 (4.5%)	0.03
24 months	10/41 (24%)	5/37 (14%)	0.3
48 months	5/26 (19%)	3/21 (14%)	0.7

HA = hemiarthroplasty; p-values are given for differences between groups.

General complications

There was no statistical difference in the number of general complications between unipolar and bipolar patients. In the unipolar group, the general complications included: pneumonia (n = 2), pressure ulcer (n = 2), myocardial infarction (n = 1) and pulmonary embolism (n = 1). In the bipolar group, the general complications included: pneumonia (n = 1), pulmonary embolism (n = 1) and deep venous thrombosis (n = 1).

Study III

A total of 2757 consecutive patients (THA, n = 913, and HA, n = 1844) with a median follow-up period of 39 months (range 0–178) were identified and included in this study. The median age was 82 years (range 45–102) and there were 2019 females (73%). Of these patients, 63 (2.3%) sustained a postoperative periprosthetic femoral fracture that was treated surgically. The median time between the index operation and the PPF operation was 339 days (range 6 days–9.0 years). There was no significant difference in the incidence of PPFs between THA (24 of 913, 2.6%) and HA (39 out of 1844, 2.1%) patients ($p = 0.4$). The median age of the 2694 patients who did not sustain a PPF was 82 years (range 45–102) and the median age of the 63 PPF patients was 83 years (range 63–97) ($p = 0.4$). There were 1985 females (74%) among the patients who did not sustain a PPF, and 34 females (54%) ($p = 0.001$) in the PPF group.

The majority of the PPFs were classified as B2 (n = 25) or B1 (n = 23) according to the Vancouver classification, followed by 14 cases classified as C fractures. Only one case was classified as a B3 fracture (Table 5).

Forty-four of the PPF patients were treated with ORIF, and 19 underwent a revision of the stem. The majority of the B1 fractures (n = 21 out of 23) and all the C fractures (n = 14 out of 14) were treated using ORIF, whereas most of the B2 fractures (n = 16 out of 25) and the only B3 fracture were treated with stem revision (Table 5). All ORIF procedures were performed using a single lateral plate with either screws only (n = 25) or screws in combination with cerclage wires (n = 19). The majority of the stem revisions were performed with a longer, cemented stem (n = 10) and a complementary lateral plate (n = 2). In seven cases a distally fixed uncemented revision stem was used. No cortical strut grafts or double plate constructs were used.

Table 5. Treatment by the Vancouver classification

Vancouver class	All n (%)	ORIF n (%)	Stem revision n (%)
B1	23 (36%)	21 (91%)	2 (9%)
B2	25 (40%)	9 (36%)	16 (64%)
B3	1 (1%)	0	1 (100%)
C	14 (14%)	14 (100%)	0

A total of six of the PPF patients (5 out of 44 ORIF and 1 out of 19 revision) were reoperated upon, giving an overall reoperation rate of 9.5%. The median time between the PPF operation and the reoperation was 71 days (range 14 days–29 months). Three of the reoperations (4.8% of all patients) were performed due to deep infection: all ORIF patients with B1 (n = 2) or C (n = 1) fractures. The other three reoperations (4.8% of all patients) were fracture-related complications, all in patients with B2 fractures. Two of the three patients had a refracture (one ORIF and one revision patient) (Figure 11a-d) and one patient treated with ORIF was reoperated upon due to a non-union. The poorest outcome of all was displayed by the patients with B2 fractures treated with ORIF, two out of nine (22%) of which underwent reoperation.

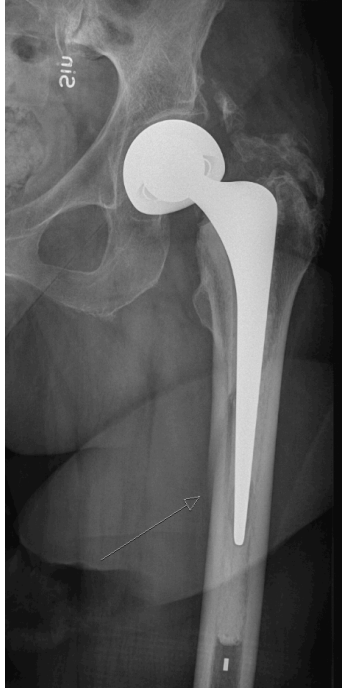

Figure 11a. A patient with an Exeter bipolar hemiarthroplasty who sustained a Vancouver B2 periprosthetic fracture (arrow).

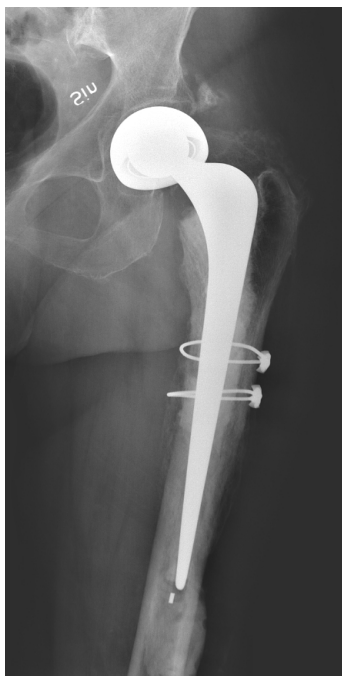

Figure 11b. The same patient after reoperation with a longer cemented stem and cerclage wires. Leakage of cement indicates that the new stem did not fully bridge the periprosthetic fracture.

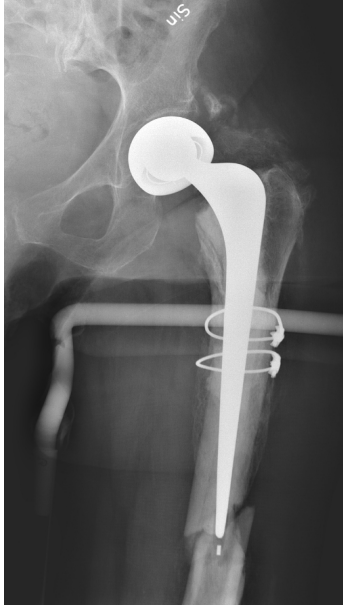

Figure 11c. One month after the operation for the periprosthetic fracture (Figure 11b), the patient suffered a new fracture.

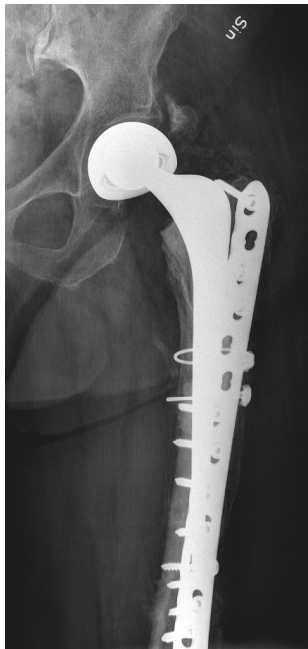

Figure 11d. The patient was finally reoperated upon with a long plate bridging the new fracture.

Study IV

A flowchart of all patients included in this study is presented in Figure 12. The mean (range) age was 81.3 (65–96) years, and 99 (70.2%) of the patients were females. One HA patient randomised to the cemented group suffered acute pulmonary oedema immediately before the operation and the decision was therefore taken to operate with closed reduction and two cannulated screws. According to the ITT principle, the patient was analysed in the cemented group.

The overall mortality was 3.5% (5 out of 141) at four months and 7.8% (11 out of 141) at 12 months. There was no difference in mortality at four months between the cemented (4 out of 67) and the uncemented group (1 out of 74) ($p = 0.2$). Nor was there any difference in the 12-month mortality between the cemented (7 out of 67) and the uncemented group (4 out of 74) ($p = 0.4$). One patient in the cemented HA group suffered sudden severe hypotension during cementing of the stem and died within two hours after the operation due to cardiac failure. No other deaths occurred within 48 hours after the operation.

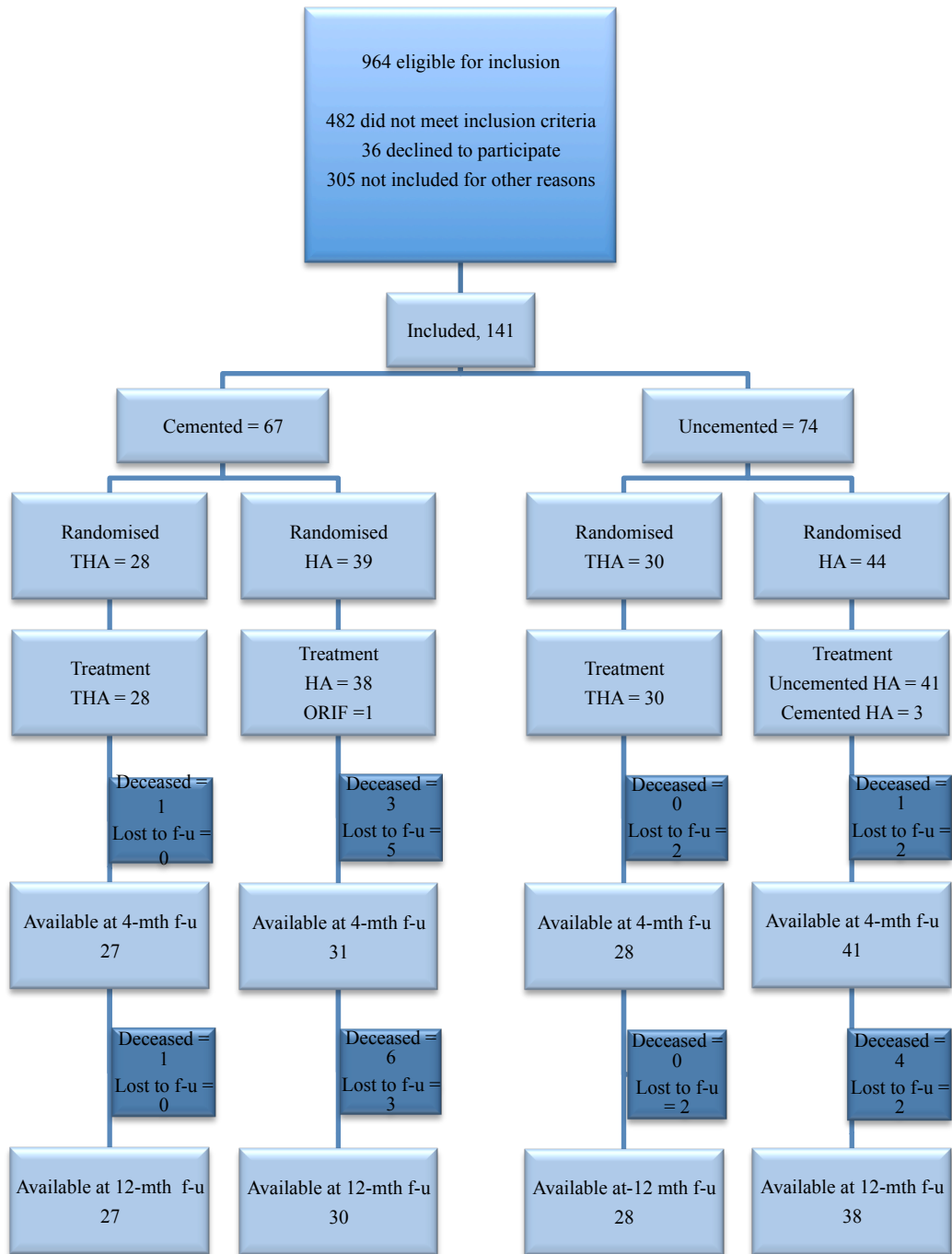

Figure 12. Flowchart of all included patients; mth = month; f-u = follow-up.

Harris Hip Score

The main outcome of this study was hip function measured by the HHS. At 4 months, the mean total HHS was significantly better in the cemented group than in the uncemented one ($p = 0.004$). No statistical difference was demonstrated at the 12-month follow-up. No differences were seen in the HHS pain subscore at any of the follow-ups (Table 6).

SMFA

The SMFA showed results in favour of the cemented group with a significantly better Dysfunction score at 4 months ($p = 0.007$) and 12 months ($p = 0.001$) and a significantly better Bother score at 12 months ($p = 0.007$) (Table 6).

Table 6. Functional outcome according to the HHS and the SMFA

	Cemented group	Uncemented group	p-value
HHS total, 4 mths, n = 127	78 (14)	70.7 (14.6)	0.004
HHS total, 12 mths, n = 123	82.3 (13.1)	78.6 (17.1)	0,093
HHS pain subscore, 4 mths, n = 127	39.6 (8.2)	37.2 (9.1)	0.065
HHS pain subscore, 12 mths, n = 123	40.7 (8.8)	38.9 (9)	0.101
SMFA Dysfunction score preop, n = 138	17.9 (13.8)	21.2 (14.3)	0.142
SMFA Bother score preop, n = 133	12.7 (14)	12,5 (11.3)	0.546
SMFA Dysfunction score, 4 mths, n = 125	29.8 (17.5)	39,2 (19.6)	0.007
SMFA Bother score, 4 mths, n = 117	26.9 (19.4)	32,2 (19.9)	0.113
SMFA Dysfunction score, 12 mths, n = 118	22.3 (16.3)	34,9 (22.2)	0.001
SMFA Bother score, 12 mths, n = 116	18.6 (16.8)	29 (21.1)	0.007

HHS = Harris Hip Score

SMFA = Short Musculoskeletal Function Assessment

() = standard deviation

mths = months

EQ-5D

The mean EQ-5D index score for all patients was consistently in favour of the cemented group at the follow-ups, with significant differences at 4 and 12 months (Figure 13a). On analysing HA and THA patients separately, a difference was found in favour of the cemented patients with significant results at 4 and 12 months for the HA patients and at 12 months for the THA patients (Figures 13b-c).

There was no difference in the baseline mean (\pm SD) EQ-5D index score between the cemented, 0.81 (0.21), and the uncemented groups, 0.84 (0.19) ($p = 0.54$).

At four months, the mean (\pm SD) EQ-5D index score was 0.68 (0.23) for all the cemented patients and 0.53 (0.28) for all the uncemented ones ($p = 0.001$). At 12 months, the mean (\pm SD) EQ-5D index score was 0.75 (0.25) for all the cemented and 0.58 (0.26) for all the uncemented patients ($p < 0.001$).

At four months, the mean (\pm SD) EQ-5D index score was 0.64 (0.22) for the cemented HA patients and 0.49 (0.27) for the uncemented ones ($p = 0.004$). At 12 months, it was 0.73 (0.19) for the cemented HA patients and 0.56 (0.26) for the uncemented ones ($p < 0.001$).

For the THA patients, the 4-month mean (\pm SD) EQ-5D index score was 0.7 (0.24) for the cemented and 0.58 (0.3) for the uncemented patients ($p = 0.09$). At 12 months, it was 0.77 (0.31) for the cemented and 0.6 (0.26) for the uncemented THA patients ($p = 0.01$).

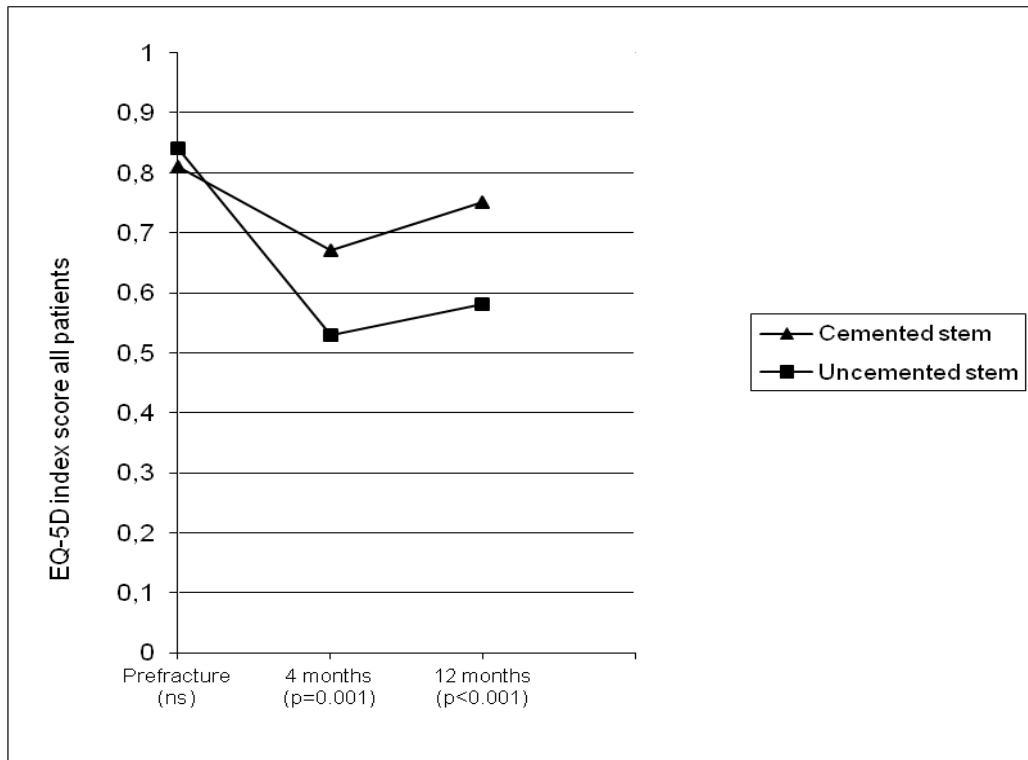


Figure 13a. Mean EQ-5D index score for all patients

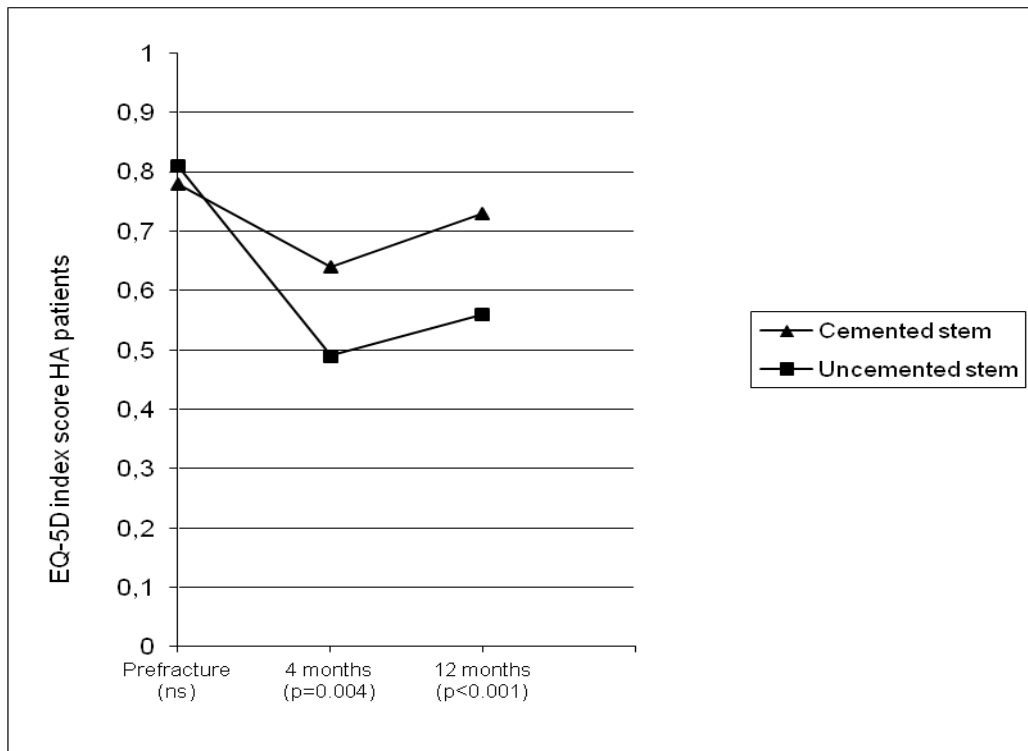


Figure 13b. Mean EQ-5D index score for HA patients

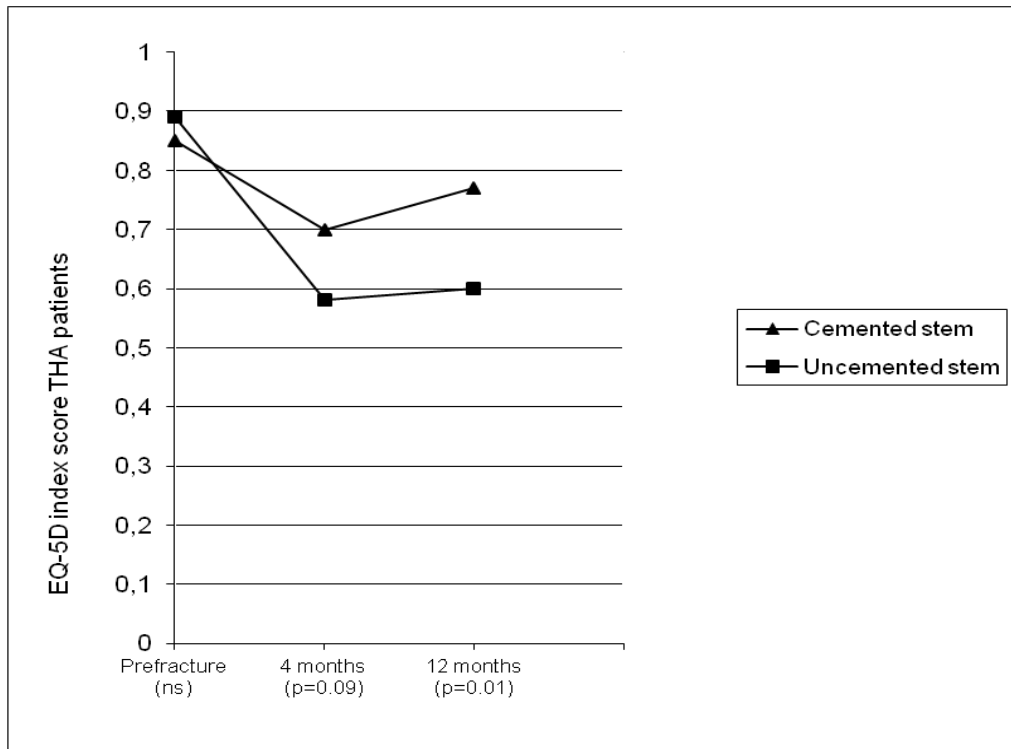


Figure 13c. Mean EQ-5D index score for THA patients

Surgical outcome

Eight patients in the uncemented group suffered an intraoperative periprosthetic femoral fracture. After fixation with cerclage wires, five of these patients showed sufficient stability to proceed with the operation as planned, whereas three were converted to cemented stems. These three patients were analysed in the uncemented group according to the ITT principle. In addition, one THA patient in the uncemented group suffered an intraoperative periprosthetic fracture that was not discovered before the four-month follow-up. On re-evaluating the postoperative radiographs, the fracture was classified as a Vancouver AL and treated conservatively. Four patients in the uncemented and four in the cemented group suffered an intraoperative fracture of the tip of the greater trochanter. None of these fractures required further treatment.

One THA patient in the uncemented group was reoperated upon with open debridments at five and seven days after the primary operation due to a suspected deep infection. All cultures were negative and the patient recovered without further complications. One HA patient in the cemented group dislocated the prosthesis 20 days after the index operation. After three closed reductions, the prosthesis was revised to a dual mobility cup 27 days after the index operation.

The mean estimated intraoperative blood loss (\pm SD) in ml was 297 (202) in the cemented and 341 (259) in the uncemented group ($p = 0.5$). The mean operating time (\pm SD) in minutes was 82 (27) for the cemented and 80 (18) for the uncemented patients ($p = 0.8$).

Radiological outcome

At the 4-month follow-up, 123 patients had radiographs available for evaluation and at the 12-month follow-up the number was 115.

Type of femur

On the preoperative radiographs, 4 out of 74 patients in the uncemented group were classified as having a Dorr type A femur, 52 out of 74, a type B, and 18 out of 74, a type C. Nobody in the cemented group was classified as having a Dorr type A femur, 26 out of 67, a type B, and 41 out of 67, a type C.

Acetabular erosion

At four months, 4 out of 39 of the uncemented HAs and 4 out of 28 of the cemented HAs displayed a grade 1 acetabular erosion. At the 12-month follow-up, 8 out of 35 of the uncemented HAs and 5 out of 26 of the cemented HAs displayed a grade 1 acetabular erosion.

General complications

Nine patients, five in the cemented group, were treated for a postoperative superficial wound infection that healed with antibiotic treatment alone. Nine patients in the uncemented and seven in the cemented group were treated for an immediate postoperative urinary tract infection. Two patients in the uncemented and one in the cemented group were treated for pneumonia. In the uncemented group, one patient suffered an acute myocardial infarction, one had acute cardiac failure and one developed acute renal failure. All three recovered. No statistically significant differences in general complications were found between the cemented and the uncemented groups.

General Discussion

The overall purpose of this thesis was to investigate the clinical outcome by means of functional and surgical outcomes and HRQoL after treatment of displaced femoral neck fractures with arthroplasties. Special attention was paid to PPFs, which is a complication after treatment with arthroplasties. In Study I, the aim was to compare the functional outcome and HRQoL after treatment of a displaced fracture of the femoral neck in an elderly population with severe cognitive dysfunction. The main purpose of Studies II and IV was to compare the clinical outcome of treatment of displaced femoral neck fractures when different kinds of arthroplasties were used. In Study III, the main outcome was the incidence and reoperation rate after PPFs in a patient population operated upon due to a displaced fracture of the femoral neck using a single implant.

Displaced femoral neck fractures in patients with severe cognitive impairment

The treatment displaced femoral neck fractures has been the cause of debate and numerous investigations for decades. It has become more and more evident that in an elderly population, in which femoral neck fractures occur after low-energy trauma and are strongly correlated with osteoporosis, the treatment of choice is an arthroplasty (Parker, Gurusamy et al. 2010). Cognitive dysfunction is common among hip fracture patients. Up to 55% of these patients suffer from some kind of cognitive dysfunction (Samuelsson, Hedstrom et al. 2009). The 2006 Cochrane Review concludes that arthroplasty is superior to IF in terms of residual pain, function and return to preinjury living conditions. There is no clear difference in mortality one year after surgery between patients treated with IF and those treated with arthroplasties (Parker and Gurusamy 2006). Mortality is, however, a great concern for patients with cognitive dysfunction (Söderqvist, Ekström et al. 2009). Since IF is a minor surgical intervention with less trauma and less blood loss, many consider it a more merciful option for these patients. The only two previous clinical trials on patients with severe cognitive dysfunction (van Dortmont, Douw et al. 2000, Blomfeldt, Törnkvist et al. 2005) report a lower HRQoL in the HA group, compared to IF, but more reoperations. The HA used in both these studies is the now out-dated Austin Moore prosthesis. This prosthesis is an uncemented, monobloc prosthesis, and its inferiority regarding functional and surgical outcome has been demonstrated previously (Parker and

Gurusamy 2006, Rogmark, Leonardsson et al. 2012). Even compared to earlier cemented designs, such as the Thomson monobloc prosthesis, the Austin Moore prosthesis has been proven to be inferior with regard to residual pain, earlier mobilisation and length of hospital stay (Parker, Pryor et al. 2010).

In a previous RCT from our institution (Blomfeldt, Törnkvist et al. 2005) including 60 patients, the IF group had a higher EQ-5D index score than the HA group at the 24-month follow-up. Van Dortmont et al. reported fewer reoperations in the Austin Moore group, compared to the IF group (van Dortmont, Douw et al. 2000). Both studies conclude that IF is preferable compared to treatment with HA. Our interpretation of these results is however that treatment with Austin Moore prostheses results in even worse outcome than treatment with IF.

Why should the cognitive impaired patients respond any different to a treatment than lucid patients, especially when a modern modular cemented HA is used?

In Study I, we found HRQoL (EQ-5D index score) to be generally better in the HA group, with a significant difference in favour of the HA group at 12 months. This is in contrast to a recent six-year follow-up of an RCT in which patients both with and without cognitive impairment were included (Stoen, Lofthus et al. 2014). The HA used was of a cemented, modular design similar to the prosthesis used in Study I. The authors could not detect any difference regarding HHS and EQ-5D after 6 years. One can, however, assume that many patients with severe comorbidities, such as severe cognitive dysfunction, had died under the follow-up period, as the mortality rate in this patient group is exceptionally high.

We found no difference in hip function according to the Charnley score. This corresponds quite well with the two previous RCTs (van Dortmont, Douw et al. 2000, Blomfeldt, Törnkvist et al. 2005).

In Study I, there were more reoperations in the IF group (7 out of 30) than in the HA group (1 out of 29). This is in conformity with the study by Blomfeldt et al., where there was a trend towards a higher rate of reoperation after IF (10 out of 30), compared to HA (4 out of 30) (Blomfeldt, Törnkvist et al. 2005) and in the study by van Dortmont et al., who reported fracture-related reoperations in 4 out of 31 IF patients, but in none of the HA patients (van Dortmont, Douw et al. 2000). Stoen et al. reported a reoperation rate of 43% (48 out of 112) in the IF group, compared to 10% (11 out of 110) in the HA group. All reoperations, besides two

cases in the IF group, occurred within the first two years of follow-up. No reoperations occurred in the HA group after two years.

Although the reoperation rate for the IF group in Study I was not high compared to other studies on patients with displaced femoral neck fractures treated with IF (Lu-Yao, Keller et al. 1994), one of the patients with a non-union clearly had to undergo an avoidable reoperation due to the fact that there was suboptimal reduction of the fracture and positioning of the screws. Furthermore, in both patients who sustained subsequent trochanteric fractures after new falls, the lateral entry point for the screws was a bit low, which can predispose to a new fracture. Only one patient in the HA group suffered a prosthetic dislocation, giving a dislocation rate of 3.3%. All patients were operated upon using an anterolateral surgical approach. The dislocation rate is similar to that in a large previous study from our institution comprising 739 HAs, where the dislocation rate was 3.0% after anterolateral and 12% after posterolateral surgical approaches (Enocson, Tidermark et al. 2008). As a comparison, Johansson et al. had a dislocation rate of 32% in their dementia subcohort after a total hip arthroplasty (Johansson, Jacobsson et al. 2000). Their high incidence is, however, most likely due to the fact that a posterolateral surgical approach was used, rather than the cognitive dysfunction of the patients (Enocson, Tidermark et al. 2008). No dislocations were reported in the RCTs by Blomfeldt et al. or Dortmund et al., in which anterolateral approaches were used.

Patients with severe cognitive dysfunction have a considerable risk of falling (Hayakawa, Hashimoto et al. 2014). One can therefore assume that these patients are at especially high risk of sustaining a PFF. There were, however, no PFFs in our cohort, which is in line with Parker et al. (Parker, Pryor et al. 2010), who reported no PFFs among their 200 patients with a cemented Thomson prosthesis and 17 (8.5%) PFFs (14 intraoperative and 3 postoperative) among their 200 patients with an uncemented Austin Moore prosthesis.

Acetabular erosion is suspected to be a problem after operation with HAs. Baker et al. (Baker, Squires et al. 2006) reported that, after 3 years, 20 out of 32 HA patients (63%) showed radiological signs of acetabular erosion. Another report from our own institution (Inngul, Hedbeck et al. 2013) showed that, after 4 years, 10 out of 41 patients (24%) with a unipolar HA displayed acetabular erosion of some degree. The SHAR states that, among hip fracture patients, approximately 5% of all reoperations are done because of acetabular erosion (Register 2013). In a recent study from our institution including 830 Exeter HAs with a minimum follow-up of 3 years, only four patients (0.5%) were reoperated upon due to acetabular erosion

(Enocson, Hedbeck et al. 2012). In our study, five patients presented with a Grade 1 and two patients with a Grade 2 acetabular erosion at the 24-month follow-up. None of the patients with erosion had sufficient clinical symptoms to justify a reoperation. Although the threshold for reoperation might be higher in a population of frail patients, compared to a more lucid population, acetabular erosion does not seem to be a major problem in the hip fracture population, regardless of the cognitive status.

There is a high mortality in the hip fracture population (Valizadeh, Mazloomzadeh et al. 2012) and patients with a hip fracture and an SPMSQ < 7 have a doubled risk of dying within the first two years after the fracture (Samuelsson, Hedstrom et al. 2009). Study I is no exception, with a one-year mortality of 44% and a two-year mortality of 63%. There were no differences in mortality or general complications between the groups. The mortality in this study is in accordance with the 57% mortality rate reported by van Dortmont et al. (van Dortmont, Douw et al. 2000) after one year and the 54% mortality rate reported by Söderqvist et al. (Söderqvist, Ekström et al. 2009) after two years.

Treatment of displaced femoral neck fractures in patients with severe cognitive dysfunction is a challenge. Treatment with HA seems to result in a better HRQoL and fewer reoperations in a population of patients with severe cognitive dysfunction, compared to IF. IF is a shorter and less traumatic operation compared to HA, but this fact does not justify IF as a treatment alternative to HA. The treatment goal in this frail group of patients must be the restoration of HRQoL, walking ability and freedom of pain during their remaining short life span.

Bipolar hemiarthroplasty in patients with displaced femoral neck fractures

Both unipolar and bipolar HAs are widely used for the treatment of displaced fractures of the femoral neck in the elderly (Bhandari, Devereaux et al. 2005, Lieberman, Romano et al. 2006). Many surgeons prefer the bipolar articulation as it, in theory, allows for a greater range of motion and thereby decreases the risk of prosthetic dislocation. Furthermore, the bipolar articulation is supposed to slow down the development of acetabular erosion since most of the motion is assumed to take place within the bipolar head. Residual pain and the functional deficit are supposed to be less than with a unipolar HA. On the other hand, data from the SHAR suggests that the risk for reoperation due to infection, dislocation and PPF are higher for bipolar HAs than for unipolar HAs (Leonardsson, Kärrholm et al. 2012).

HRQoL and hip function were the main outcome measures in Study II. The EQ-5D index score was generally higher throughout the follow-up period in the bipolar group. The difference first reached statistical significance at the 48-month follow-up. The EQ-5D index score in both patient groups deteriorated from 0.8/0.81 (unipolar/bipolar) before the injury to 0.54/0.62 at four months. At the 12- and 24-month follow-ups, the scores were stable at 0.60/0.63. The raw scores correspond very well with a previous 48-month follow-up from our institution in which patients were randomised to either treatment with a bipolar HA or a THA (Hedbeck, Enocson et al. 2011). The EQ-5D index score for the bipolar group increased to 0.7 at the 48-month follow-up. There is, to the best of our knowledge, only one previous RCT (Raia, Chapman et al. 2003) using a validated instrument for measuring HRQoL (SF-36). In that study, 115 patients were followed for 12 months and no difference in the SF-36 could be detected.

The bipolar articulation is meant to increase the range of motion and minimise the erosion of the acetabular cartilage, and thus enhance the functional outcome, compared to a unipolar articulation. However, we did not find any significant differences in the HHS total score or in the HHS subscores for pain, function, absence of deformity or range of motion between the groups at any time. The HHS results are in line with those of Davison et al., who performed a three-armed RCT (Davison, Calder et al. 2001) with similar inclusion criteria. Patients with a displaced femoral neck fracture were operated upon with either IF, unipolar HA or bipolar HA. The implants used were the now out-dated cemented monobloc Thompson and Monk prostheses. The patients were reviewed annually for five years and the total amount of patients lost to follow-up after 5 years was 58%. They reported no difference in HHS between the groups. Their total HHS scores were generally lower at every follow-up compared to our patients, which might be explained by the use of now out-dated prosthetic designs. Calder et al. randomised patients with a displaced femoral neck fracture to treatment with a Monk or Thompson prosthesis (Calder, Anderson et al. 1996). Their follow-up time was 24 months. At the final follow-up, they found no difference between the groups in the HHS, but the article gives no actual score values for comparison. Furthermore, Raia et al. followed their patients with a self-reported musculoskeletal functional assessment instrument (MFA) but could not identify any significant difference at the one-year follow-up (Raia, Chapman et al. 2003). Two more recent RCTs, comparing bipolar and unipolar HAs in patients with displaced femoral neck fractures, could not show any difference in functional outcome (Jeffcote, Li et al. 2010, Stoffel, Nivbrant et al. 2013). Finally, Cornell et al. reported no difference in functional outcome after a six-month follow-up of their patients (Cornell, Levine et al. 1998).

Recent data from the Swedish Hip Arthroplasty Register published by Leonardsson et al. including 23,509 HA operations between 2005 and 2010 showed a substantially lower risk for revision due to acetabular erosion in favour of bipolar HAs, compared to unipolar HAs (Leonardsson, Kärrholm et al. 2012). Comparisons in the 2010 Cochrane Report on arthroplasties for the treatment of displaced femoral neck fractures show a decreased risk ratio for acetabular erosion in favour of bipolar HAs, compared to unipolar HAs (Parker, Gurusamy et al. 2010). Furthermore, after a mean follow-up time of nine years, Avery et al. reported a rate of acetabular erosion of 100% in the unipolar HA group, although only 13 of the original 41 patients were available for follow-up (Avery, Baker et al. 2011). Three of their 13 patients (23%) had sufficient symptoms of acetabular erosion to justify revision surgery. In our study, the unipolar HA group displayed an initially high rate of acetabular erosion, i.e., 16% after four months, but there was no further deterioration over time. In the bipolar group, the acetabular erosion was significantly less at 12 months, but the rate then increased and, at the later follow-ups, there were no differences between the groups. This could be explained by previous reports indicating that the bipolar articulation ceases to work after some time and thereby turns the bipolar prosthesis into a unipolar one (Verberne 1983, Phillips 1987, Chen, Badrinath et al. 1989, Eiskjaer, Boll et al. 1989). However, Bochner et al. demonstrated a small amount of radiographic motion at the bipolar interface with weight bearing at an average follow-up of 3 years (Bochner, Pellicci et al. 1988). Even if the HRQoL was better in the bipolar group at the last follow-up, we found no correlation between presence of acetabular erosion and impairment in the EQ-5D index score or HHS pain score at any of the follow-ups. None of our patients with acetabular erosion had sufficient symptoms to justify a reoperation, which is in accordance with other authors (Wachtl, Jakob et al. 2003). In summary, the bipolar articulation might decrease the risk for acetabular erosion, but we believe it plays a minor role in the outcome after HA due to the low functional demands in this elderly and frail patient population. None of our patients underwent a reoperation due to acetabular erosion or pain.

We found no difference in reoperation rates between the unipolar and bipolar groups. This is in line with a previous study from our institution on 830 Exeter HA patients with a median follow-up time of three years, in which no difference in the reoperation rate between unipolar and bipolar HAs could be found (Enocson, Hedbeck et al. 2012). In contrast, Leonardsson et al. reported a significantly higher risk of reoperation for bipolar HAs, compared to unipolar HAs, in patients from the Swedish Hip Arthroplasty Register, including all HAs performed in Sweden between 2005 and 2010 (Leonardsson, Kärrholm et al. 2012). However, there have been

indications in earlier annual reports from the SHAR that the risk for reoperation differs between different stem designs and other bipolar heads than the head used in this study (Stryker UHR) might be the cause of the difference in the reoperation rate between unipolar and bipolar HAs in the SHAR. In accordance with our findings, Leonardsson et al. found that dislocations, periprosthetic fractures and infections were the most usual reasons for reoperations (Leonardsson, Kärrholm et al. 2012).

Deciding between either a unipolar or a bipolar HA for the treatment of displaced femoral neck fractures in the elderly is not easy. We did not find any differences in functional outcome, reoperation rates or mortality in our material, which is in accordance with a recent meta-analysis (Liu, Tao et al. 2014). There is evidence in the literature that bipolar HAs reduces the risk for acetabular erosion, but this seems to play a minor clinical role. Our findings of a better HRQoL after 48 months could mean that, in the long term, the bipolar articulation actually has advantages over the unipolar articulation. Since this study was originally designed to show differences at the 12-month follow-up, the difference at the 48-month follow-up could actually be a statistical type I error due to multiple analyses.

Periprosthetic fractures in hip fracture patients

The number of patients treated with hip arthroplasties is steadily increasing and a considerable share of these patients are treated due to a displaced fracture of the femoral neck.

In Study III, a cohort of 2757 consecutive patients treated for a femoral neck fracture (primary and secondary arthroplasties) with a single femoral implant (Stryker Exeter stem) were investigated. The cumulative incidence of PPFs was 2.3%. This is a substantially higher incidence compared to two of the most cited articles on the epidemiology of PPFs (Berry 1999, Lindahl, Malchau et al. 2005). Berry reported an incidence of PPFs after primary THAs of 1.1% in a cohort of mixed indications from the Mayo Clinic Joint Arthroplasty Register (Berry 1999). Lindahl et al. reported a cumulative incidence of 0.4% for all THAs in the SHAR, but the authors suspected a systematic bias, as many institutions do not report ORIF procedures to the SHAR (Lindahl, Malchau et al. 2005). Our reported incidence is almost six times higher than the incidence reported by Lindahl et al. and more than double the incidence reported by Berry.

This indicates that patients treated with arthroplasties because of a hip fracture have a higher risk of sustaining a PPF than patients treated because of other indications (osteoarthritis, rheumatoid arthritis). This is in accordance with the findings of Lindahl et al., where the investigation of 321 PPFs showed that patients treated due to a hip fracture had a higher risk of sustaining a PPF than patients operated on for osteoarthritis (Lindahl, Garellick et al. 2006a).

There are previous reports on the incidence of PPFs in patients operated on with a HA due to a femoral neck fracture. Philips et al. reported an incidence of 1.7% PPFs among 8354 HAs due to hip fractures (Phillips, Moran et al. 2013). The prostheses used were either the uncemented Austin Moore stem or one of two cemented designs (the modular Exeter stem and the monobloc Exeter trauma stem). The incidence of PPFs in the group of patients with Austin Moore prostheses was 2.3%, and 0.5% in the other group. Furthermore, McGraw et al. reported similar figures for their 546 HAs performed on patients with displaced fractures of the femoral neck (McGraw, Spence et al. 2013). The patients were treated with either an uncemented Austin Moore prosthesis or a cemented monobloc Exeter trauma stem. The mean age of the group treated with an Austin Moore prosthesis was 85 years, and the mean age of the group treated with an Exeter trauma stem was 80 years. The incidence of PPFs was 4% for Austin Moore patients, whereas no PPFs occurred in the Exeter trauma stem group. Thus, both of the later studies reported a lower incidence of PPFs in the Exeter stem groups, compared to our results, it can be assumed that the cemented stems were used for the slightly more lucid and less frail patients.

There was no difference in the incidence of PPFs between the THA (2.6%) and the HA groups (2.1%) in our material. Hedbeck et al. reported one PPF (1.7%) in a four-year follow-up of 60 patients randomised to THA after a femoral neck fracture (Hedbeck, Enocson et al. 2011). Johansson et al. reported a 15-year follow-up of a randomised controlled trial comparing internal fixation with THA for the treatment of displaced femoral neck fractures (Johansson 2014). There was no PPF among the 68 patients allocated to THA, but one PPF in the internal fixation group 14 years after a secondary THA performed 3 months after failed internal fixation. However, the small numbers of patients in these clinical trials make the incidence rates difficult to compare.

The Vancouver classification has been proven to be reliable, reproducible and correlated with outcome (Vioreanu, Parry et al. 2014). Treatment of PPFs according to the Vancouver classification is widely debated in the literature and many treatment algorithms and review

articles have been published (Berry 2002, Tsiridis, Haddad et al. 2003, Tsiridis, Pavlou et al. 2009, Holzapfel, Prodinger et al. 2010).

A comparison of the results of treatment alternatives is difficult since many authors report on specific treatment options rather than on specific patient subgroups (Sen, Prasad et al. 2007, Bryant, Morshed et al. 2009, Munro, Garbuz et al. 2014). Current concepts for the treatment for PPFs agree that Vancouver B1 fractures, which have a well-fixed stem, are best treated with ORIF with at least one lateral plate. The distinction between a B1 and a B2 fracture preoperatively can be difficult to make (Lindahl, Garellick et al. 2006a). In our series, two of the 23 B1 fractures were treated with a stem revision because, intraoperatively, the surgeons had concerns about the stability of the stem.

Lindahl et al. reported that the use of a single lateral plate was associated with a poor outcome (Lindahl, Malchau et al. 2006b). In another report on patients with B1 fractures treated with a single locking compression plate, 43% (6 out of 14) failed to heal and were reoperated upon within the first year (Buttaro, Farfalli et al. 2007). This is in contrast to our findings where only 9.5% (2 out of 21) of the B1 patients treated with ORIF were reoperated, all due to deep infections and none were reoperated upon for a fracture-related complication. An additional strut on-lay graft or a second anterior plate has been suggested to increase the mechanical stability when ORIF is used (Masri, Meek et al. 2004). None of the patients in this study were fitted with strut grafts or additional plates. The reoperation rate for a fracture-related complication in patients treated with ORIF (B1 and B2) was 4.5% (2 out of 44). One possible explanation for our positive results after ORIF using single plating could be the design of the Exeter stem. The wedge-formed shape in the frontal plane and the slim profile in the lateral plane allow for stable bicortical screw fixation on both sides of the stem through the cement mantle.

In B2 and B3 fractures, a revision of the stem is generally recommended in the literature (Tsiridis, Haddad et al. 2003, Masri, Meek et al. 2004, Tsiridis, Pavlou et al. 2009). Pavlou et al. reviewed 202 type B fractures and found that B2 fractures undergoing stem revision were more likely to unite, compared to ORIF (Pavlou, Panteliadis et al. 2011). Although the B2 fractures only comprise a small number of fractures in our series of patients, Pavlou's results correspond quite well with our finding, where 22% (2 out of 9) of the B2 fractures treated with ORIF underwent reoperation due to fracture-related complications.

The ideal treatment option for Vancouver C fractures is ORIF, as the stem is stable and, by definition, the fracture does not affect the stem (Duncan and Masri 1995). One important consideration in these cases is implant length so as to avoid stress risers between the old and new implants.

On comparing the gender distribution between patients who suffered from a PPF and those who did not, we found an increased number of males among the PPF patients. This is in contrast to a recent report from Sheth et al., who reported female gender to be a risk factor in a large series of THA patients (Sheth, Brown et al. 2013). Their patients were, however, mainly operated on for osteoarthritis. In a recently published review, Schwarzkopf et al. stated that gender has not been convincingly demonstrated as a risk factor (Schwarzkopf, Oni et al. 2013), and we believe that no final conclusion regarding the gender issue can be drawn from our study either.

Uncemented arthroplasties

Uncemented arthroplasties for the treatment of displaced femoral neck fractures have been in use for decades. The theoretical advantages of an uncemented prosthesis are, however, overshadowed by inferior functional and surgical outcomes of the earlier uncemented designs (Moore 1952). In Study IV, we therefore used a modern cementing technique and a modern hydroxyapatite-coated uncemented stem to compare the functional, surgical and radiological outcomes in patients treated for a displaced femoral neck fracture. The major findings were an increased rate of intraoperative complications and inferior functional results associated with the use of an uncemented stem.

Similar results were reported in an RCT with a two-year follow-up by Taylor et al. (Taylor, Wright et al. 2012). They found better results in the Oxford Hip Score for the cemented implant, but could only demonstrate a statistically significant difference at the six-week follow-up. Furthermore, they found more intraoperative fractures in the uncemented group than in the cemented one (6 out of 80 versus 0 out of 80). This matches quite well our findings and highlights the risk associated with introducing a press-fit stem into osteoporotic bone.

In contrast to our results, DeAngelis et al. (Deangelis, Ademi et al. 2012) reported, in a one-year follow-up of an RCT including 130 HA patients, no difference in stem-specific or general

complications. Nor did they find any difference in their main outcome measure, an ADL-based score, or in intraoperative blood loss or operating time.

Late postoperative periprosthetic fractures and revision due to failure of osseointegration are risk factors for the survival of uncemented stems in this patient population (Lindahl, Malchau et al. 2005). There is now some evidence that coating of titanium stems with hydroxyapatite enhances bone ongrowth, even in the osteoporotic bone. Sköldenberg et al. were able to demonstrate good fixation after three months in patients with femoral neck fractures with a stem design similar to the one used in this study (Sköldenberg, Sjöo et al. 2014). In addition, Schewelov et al. reported promising RSA results in a series of 38 fracture patients using a hydroxyapatite-coated stem (Schewelov, Ahlborg et al. 2012). After an initial subsidence, the stem seems to stabilise within three months, but the clinical relevance of this initial subsidence is questioned.

In 2009 Figved et al. (Figved, Opland et al. 2009) published 12-month results from an RCT comparing cemented HAs and uncemented hydroxyapatite-coated HAs. They found no difference between the groups in the HHS or EQ-5D index score at four or 12 months and no difference in intraoperative fractures, but, in contrast to our findings, the operating time and the intraoperative blood loss differed significantly in favour of the uncemented group.

Regarding the late periprosthetic fractures, there is evidence from different national joint registers (Leonardsson, Kärrholm et al. 2012, Rogmark, Fenstad et al. 2014) and one mid-term follow-up (five years) of an RCT (Langslet, Frihagen et al. 2014) that uncemented stems constitute a risk factor for sustaining such a complication. Parker et al. (Parker, Gurusamy et al. 2010) published in 2010 an RCT with high methodological quality in which a cemented Thomson prosthesis was compared with an uncemented Austin Moore prosthesis. During their follow-up period of two to five years, there was no significant difference between the groups regarding revision due to periprosthetic fractures. In our material, there is no revision due to a late periprosthetic fracture or loose implant, but one year of follow-up time may not be sufficient to detect the late fractures caused by poor osseointegration.

One method used to increase the statistical power is to pool several studies in a systematic review, and there are a number of such reviews comparing cemented and uncemented stems as the treatment for patients with femoral neck fractures. In the 2011 systematic review of relevant RCTs by Azegami et al. (Azegami, Gurusamy et al. 2011), the authors concluded that the cemented implants were superior regarding mobility scores and pain relief. However, this systematic review included only one study using a modern hydroxyapatite-coated stem (Figved,

Opland et al. 2009). In 2014 Ning et al. (Ning, Li et al. 2014) published a systematic review, but they could not demonstrate a significant difference regarding residual pain and complications. Their review included four studies (Figved, Opland et al. 2009, Moroni A 2009, Deangelis, Ademi et al. 2012, Talsnes, Hjelmstedt et al. 2013) comparing modern hydroxyapatite-coated uncemented implants with cemented implants.

One of the theoretical advantages of using an uncemented implant in fracture patients is to avoid immediate fatal complications related to cement insertion, known as the cement implantation syndrome (Olsen, Kotyra et al. 2014). This theory is supported by findings from the Australian National Joint Replacement Registry (Costain, Whitehouse et al. 2011), where the authors found an increased mortality on the first postoperative day for cemented implants. These findings were changed in favour of the cemented implants at one week, one month and one year after surgery. Interestingly, the authors were not able to show a significant difference in mortality rates throughout the follow-up period when only modular uncemented and cemented implants were compared. Even though the implants are not specified in their study, a modular implant is most likely of modern design. A major weakness of register data is a selection bias as the choice of treatment is influenced by age, gender and comorbidities of the patient and therefore one can expect that, traditionally, the uncemented implants could have been chosen for the elderly, more frail patient in order to avoid the cement implantation syndrome. In our study, we had one death related to the bone cement implantation syndrome on the first postoperative day, with no further differences in mortality rates. None of the above-mentioned RCTs have been able to demonstrate a difference in mortality, but an RCT is not the right method to compare mortality rates owing to the limited number of patients included.

Acetabular erosion is restricted to HAs only. We found no differences between the groups in the formation of heterotopic bone or the development of acetabular erosion. Acetabular erosion appears to play a minor role in the short- and mid-term functional outcomes, as previous studies from our institution have indicated (Hedbeck, Blomfeldt et al. 2011, Inngul, Hedbeck et al. 2013).

Conclusions

Study I

Treatment with cemented HAs in patients with displaced femoral neck fractures and severe cognitive dysfunction seems to result in a better HRQoL and fewer reoperations, compared to treatment with IF. The results imply that patients with severe cognitive dysfunction should not be treated in a different way from patients with intact cognitive function.

Study II

Treatment with cemented bipolar HAs in elderly patients with displaced femoral neck fractures appears to result in a better HRQoL 48 months after injury, compared to cemented unipolar HAs. However, taking reports from other authors and the possibility of type I statistical errors into account, the use of a bipolar HA cannot be advocated without considerable doubts.

Study III

The incidence of postoperative femoral periprosthetic fractures was high among patients with Exeter stems operated on for a femoral neck fracture. The reoperation rate due to fracture-related complications was highest among patients with B2 fractures. The Exeter stem was found to yield reliable results after ORIF using a single lateral plate.

Study IV

Treatment with an uncemented, hydroxyapatite-coated femoral stem in patients with displaced femoral neck fractures results in inferior results regarding HRQoL, functional outcome and intraoperative complications, compared to a cemented, modular femoral stem. Our results strongly imply that an uncemented, hydroxyapatite-coated stem should not be used in these patients.

Implications for clinical practise and future research

The results of Study I showed that HA can be used in this subgroup with good results regarding HRQoL and complication rates. The results correspond quite well to those for elderly patients without cognitive dysfunction. The use of HA for all displaced femoral neck fracture, regardless of the patient's cognitive status, should therefore be considered. Because of the obvious difficulties that clinical trials encounter when studying patients with severe cognitive dysfunction a large cohort study may contribute to answering the question concerning treatment alternatives for this subgroup of patients.

The results of Study II imply that treatment with bipolar HA leads to a better HRQoL at the 48-month follow-up, compared to treatment with unipolar HA. Multiple studies in the literature have failed to demonstrate any difference in HRQoL or functional outcome on comparing bipolar with unipolar HA. However, Study II has one of the longest follow-up periods, compared to the other clinical trials in the literature. It is possible that our results may imply that bipolar HA is a better treatment alternative for the patients with the longest life expectancy among those treated with HAs. Studies with a follow-up period as long as 10 years should be conducted to evaluate the potential long term benefits of bipolar HAs.

A PPF as a complication to treatment with arthroplasties is rare, but patients treated for a displaced femoral neck fracture display a very high cumulative incidence. Data from the SHAR show a higher risk for revision due to PPF if a polished stem (such as the Exeter stem) is used, but the SHAR suffers from underreporting of treatment for Vancouver B1 and C fractures. There is a need for a matched cohort study investigating the risk for reoperation due to PPF in hip fracture patients with comparisons of different implant types. Patient satisfaction is important when comparing outcomes after different treatment alternatives. This is why the HRQoL should be included in such an analysis.

Cementing a prosthesis into the femoral canal can cause serious cardiopulmonary complications, especially in an elderly and frail population, such as patients with displaced femoral neck fractures. An uncemented prosthesis could prevent such complications. The results of Study IV showed very clearly that treatment of displaced femoral neck fractures with an uncemented arthroplasty results in an inferior outcome regarding function, HRQoL and intraoperative complications, compared to a cemented arthroplasty. The general use of a modern hydroxyapatite-coated arthroplasty cannot be recommended for patients with displaced

femoral neck fractures. There is, however, a need to further individualise the treatment of displaced femoral neck fractures and future research should aim to investigate possible benefits of modern uncemented prosthesis in patients with severe cardiopulmonary comorbidities.

Abstract in Swedish

Behandling av felställda lårbenshalsbrott bland äldre patienter utgörs idag till stor del av konstgjorda ledimplantat (höftproteser). Istället för att reparera lårbenshalsen ersätts höftleden med olika typer av höftproteser. Resultaten avseende hälsorelaterad livskvalitet (HRQoL) och höftfunktion är mycket goda. En grupp patienter som kräver speciell uppmärksamhet är patienterna med svår demens. Vanligtvis opereras äldre patienter med en särskild halvprotes (HA), där enbart höftkulan byts ut. En bipolär HA är utvecklat för att reducera slitage på patientens ledpanna och borde därför leda till bättre HRQoL och höftfunktion jämförd med en vanlig HA (unipolär HA). En allvarlig komplikation efter operation med en höftprotes är ett benbrott som engagerar själva höftprotesen (PPF). Frekvensen av PPF är ett viktigt mått för att kunna jämföra olika behandlingar. I Sverige används vanligtvis bencement för att fästa höftprotesen i lårbenets mörghåla. Att låta protesen växa fast är dock en metod som används i mycket stor utsträckning utomlands och även i Sverige används denna metod mer och mer. Resultaten av denna metod är mycket goda för t.ex. artrospatienter. Alla patienter som ingår i studierna I till IV är behandlade p.g.a. ett felställt brott genom lårbenshalsen.

Studie I är en jämförande studie mellan behandling med höftprotes eller reparation av lårbenshalsen med två skruvar. Alla behandlade patienter led av svår demens. Resultaten pekar på att behandlingen med en höftprotes resulterar i bättre HRQoL och mindre följdoperationer jämförd med skruvbehandlingen.

Studie II är en jämförande studie mellan behandling med unipolär och bipolär HA. Resultaten pekar på bättre HRQoL 4 år efter operationen för patienter med en bipolär HA jämförd med en unipolär HA.

Studie III undersöker hur frekvent en PPF förekommer bland patienter som opererades p.g.a. ett lårbenshalsbrott med en speciell protestyp. Frekvensen var 2,3%, vilket får anses vara hög. Komplikationsfrekvensen efter behandling av PPF var dock relativt låg.

Studie IV jämför behandlingen med höftprotes med och utan cement. Patienterna som behandlades med en höftprotes utan cement hade lägre HRQoL, sämre funktion och mer komplikationer.

Det viktigaste slutsatserna av denna avhandling är: Behandlingen med höftproteser är säker och leder till goda resultat, även för patienter med svår demens; Användningen av ocementerade höftproteser rekommenderas ej för patienter med felställt brott genom lårbenshalsen; Fördelarna med en bipolär jämförd med en unipolär HA är marginella och behöver undersökas mer.

Acknowledgements

First of all, I would like to thank all participating patients in the clinical trials. Thank you for your contribution!

Special thoughts go out to the patient on the cover: one of the first to participate in Study IV, and one of my greatest failures. You remind me of the importance of being humble and working hard to achieve the best for every patient.

My gratitude and appreciation also goes out to everybody who has been involved and has contributed to this work. In particular, I would like to thank:

Anders Enocson, my main supervisor. Thank you for all the help and patience throughout the years. You are a great surgeon and a great teacher. Everything looks easy in your hands.

Sari Ponzer, my co-supervisor and ‘big boss.’ Thank you for your time, patience and support. You always see the best in all of us.

Richard Blomfeldt, my co-supervisor. Thank you for all your help and support and all the big and small expressions of encouragement in research and everyday clinical work. It means a lot to me.

Hans Törnkvist, my co-supervisor until 2013. Thank you for hiring me and getting me started in research.

Gerhard Wimmer-Greinecker, my first surgical role model. Thank you for inspiring me to a life in surgery.

Raggarfiket: Jenny, Eric och Cecilia. SÖS would be a colder and darker place without you.

Björn Barenius, my ‘little boss’ and friend. I don’t know where to start – so just thank you!

Tina Levander and **Elisabeth Skogman**, the best research nurses ever. Couldn’t have done it without you.

Annelie Andersson and **Monica Linder**, angels of the 4th floor. You never complain; you always laugh; you always help.

Hans Järnbert Pettersson, my favourite statistician. Thank you for all the on-the-go statistical advice! You told me to find the statistician in me – I’m still looking...

Isaac Austin, for fantastic linguistic consultation. Sorry for making you work under pressure.

All my colleagues from the Department of Orthopaedics at Södersjukhuset. Thank you for making SÖS such a great place to work.

Delirium Dan, Hotlips and Simply B. Sharpen your ski edges. I will not let you down next year.

My big brother, **Nils**, for your love, friendship and for always believing in me.

My late parents, **Christa** and **Georg**, for all your love and support and letting me become the person I am today.

Mia, my wonderful wife and best friend – the love of my life. My fantastic girls **Ebba** and **Maja**, the joy of my life.

References

- Avery, P. P., R. P. Baker, M. J. Walton, J. C. Rooker, B. Squires, M. F. Gargan and G. C. Bannister (2011). "Total hip replacement and hemiarthroplasty in mobile, independent patients with a displaced intracapsular fracture of the femoral neck: a seven- to ten-year follow-up report of a prospective randomised controlled trial." J Bone Joint Surg Br **93**(8): 1045-1048.
- Azegami, S., K. S. Gurusamy and M. J. Parker (2011). "Cemented versus uncemented hemiarthroplasty for hip fractures: a systematic review of randomised controlled trials." Hip Int **21**(5): 509-517.
- Bachiller, F. G., A. P. Caballer and L. F. Portal (2002). "Avascular necrosis of the femoral head after femoral neck fracture." Clin Orthop Relat Res(399): 87-109.
- Baker, R. P., B. Squires, M. F. Gargan and G. C. Bannister (2006). "Total hip arthroplasty and hemiarthroplasty in mobile, independent patients with a displaced intracapsular fracture of the femoral neck. A randomized, controlled trial." J Bone Joint Surg Am **88**(12): 2583-2589.
- Berry, D. J. (1999). "Epidemiology: hip and knee." Orthop Clin North Am **30**(2): 183-190.
- Berry, D. J. (2002). "Management of periprosthetic fractures: the hip." J Arthroplasty **17**(4 Suppl 1): 11-13.
- Bhandari, M., P. J. Devereaux, M. F. Swiontkowski, P. Tornetta, 3rd, W. Obremskey, K. J. Koval, S. Nork, S. Sprague, E. H. Schemitsch and G. H. Guyatt (2003). "Internal fixation compared with arthroplasty for displaced fractures of the femoral neck. A meta-analysis." J Bone Joint Surg Am **85-a**(9): 1673-1681.
- Bhandari, M., P. J. Devereaux, P. Tornetta, 3rd, M. F. Swiontkowski, D. J. Berry, G. Haidukewych, E. H. Schemitsch, B. P. Hanson, K. Koval, D. Dirschl, P. Leece, M. Keel, B. Petrisor, M. Heetveld and G. H. Guyatt (2005). "Operative management of displaced femoral neck fractures in elderly patients. An international survey." J Bone Joint Surg Am **87**(9): 2122-2130.
- Blomfeldt, R., H. Törnkvist, S. Ponzer, A. Söderqvist and J. Tidermark (2005). "Comparison of internal fixation with total hip replacement for displaced femoral neck fractures. Randomized, controlled trial performed at four years." J Bone Joint Surg Am **87**(8): 1680-1688.
- Blomfeldt, R., H. Törnkvist, S. Ponzer, A. Söderqvist and J. Tidermark (2005). "Internal fixation versus hemiarthroplasty for displaced fractures of the femoral neck in elderly patients with severe cognitive impairment." J Bone Joint Surg Br **87**(4): 523-529.
- Blundell, C. M., M. J. Parker, G. A. Pryor, J. Hopkinson-Woolley and S. S. Bhonsle (1998). "Assessment of the AO classification of intracapsular fractures of the proximal femur." J Bone Joint Surg Br **80**(4): 679-683.
- Bochner, R. M., P. M. Pellicci and J. P. Lyden (1988). "Bipolar hemiarthroplasty for fracture of the femoral neck. Clinical review with special emphasis on prosthetic motion." J Bone Joint Surg Am **70**(7): 1001-1010.
- Brazier, J. E., S. J. Walters, J. P. Nicholl and B. Kohler (1996). "Using the SF-36 and Euroqol on an elderly population." Qual Life Res **5**(2): 195-204.
- Brooks, R. (1996). "EuroQol: the current state of play." Health Policy **37**(1): 53-72.

- Bryant, G. K., S. Morshed, J. Agel, M. B. Henley, D. P. Barei, L. A. Taitzman and S. E. Nork (2009). "Isolated locked compression plating for Vancouver Type B1 periprosthetic femoral fractures." Injury **40**(11): 1180-1186.
- Buttaro, M. A., G. Farfalli, M. Paredes Nunez, F. Comba and F. Piccaluga (2007). "Locking compression plate fixation of Vancouver type-B1 periprosthetic femoral fractures." J Bone Joint Surg Am **89**(9): 1964-1969.
- Calder, S. J., G. H. Anderson, C. Jagger, W. M. Harper and P. J. Gregg (1996). "Unipolar or bipolar prosthesis for displaced intracapsular hip fracture in octogenarians: a randomised prospective study." J Bone Joint Surg Br **78**(3): 391-394.
- Charnley, J. (1970). "Total hip replacement by low-friction arthroplasty." Clin Orthop Relat Res **72**: 7-21.
- Charnley, J. (1972). "The long-term results of low-friction arthroplasty of the hip performed as a primary intervention." J Bone Joint Surg Br **54**(1): 61-76.
- Chen, S. C., K. Badrinath, L. H. Pell and K. Mitchell (1989). "The movements of the components of the Hastings bipolar prosthesis. A radiographic study in 65 patients." J Bone Joint Surg Br **71**(2): 186-188.
- Coast, J., T. J. Peters, S. H. Richards and D. J. Gunnell (1998). "Use of the EuroQoL among elderly acute care patients." Qual Life Res **7**(1): 1-10.
- Cornell, C. N., D. Levine, J. O'Doherty and J. Lyden (1998). "Unipolar versus bipolar hemiarthroplasty for the treatment of femoral neck fractures in the elderly." Clin Orthop Relat Res(348): 67-71.
- Costain, D. J., S. L. Whitehouse, N. L. Pratt, S. E. Graves, P. Ryan and R. W. Crawford (2011). "Perioperative mortality after hemiarthroplasty related to fixation method." Acta Orthop **82**(3): 275-281.
- Currie C, P. M., Plant F, Roberts J, Wakeman R, Williams A. (2011). The national hip fracture database annual report 2011. <http://www.nhfd.co.uk>.
- D'Aubigne, R. M. and M. Postel (1954). "Functional results of hip arthroplasty with acrylic prosthesis." J Bone Joint Surg Am **36-a**(3): 451-475.
- Davison, J. N., S. J. Calder, G. H. Anderson, G. Ward, C. Jagger, W. M. Harper and P. J. Gregg (2001). "Treatment for displaced intracapsular fracture of the proximal femur. A prospective, randomised trial in patients aged 65 to 79 years." J Bone Joint Surg Br **83**(2): 206-212.
- Deangelis, J. P., A. Ademi, I. Staff and C. G. Lewis (2012). "Cemented versus uncemented hemiarthroplasty for displaced femoral neck fractures: a prospective randomized trial with early follow-up." J Orthop Trauma **26**(3): 135-140.
- Dolan, P., C. Gudex, P. Kind and A. Williams (1996). "The time trade-off method: results from a general population study." Health Econ **5**(2): 141-154.
- Dorr, L. D., M. C. Faugere, A. M. Mackel, T. A. Gruen, B. Bognar and H. H. Malluche (1993). "Structural and cellular assessment of bone quality of proximal femur." Bone **14**(3): 231-242.
- Duncan, C. P. and B. A. Masri (1995). "Fractures of the femur after hip replacement." Instr Course Lect **44**: 293-304.

- Eiskjaer, S., K. Boll and J. Gelineck (1989). "Component motion in bipolar cemented hemiarthroplasty." *J Orthop Trauma* **3**(4): 313-316.
- Enocson, A., C. J. Hedbeck, H. Törnkvist, J. Tidermark and L. J. Lapidus (2012). "Unipolar versus bipolar Exeter hip hemiarthroplasty: a prospective cohort study on 830 consecutive hips in patients with femoral neck fractures." *Int Orthop* **36**(4): 711-717.
- Enocson, A., J. Tidermark, H. Törnkvist and L. J. Lapidus (2008). "Dislocation of hemiarthroplasty after femoral neck fracture: better outcome after the anterolateral approach in a prospective cohort study on 739 consecutive hips." *Acta Orthop* **79**(2): 211-217.
- Figved, W., V. Opland, F. Frihagen, T. Jervidal, J. E. Madsen and L. Nordsletten (2009). "Cemented versus uncemented hemiarthroplasty for displaced femoral neck fractures." *Clin Orthop Relat Res* **467**(9): 2426-2435.
- Florschütz, A. V., J. R. Langford, G. J. Haidukewych and K. J. Koval (2015). "Femoral neck fractures: current management." *J Orthop Trauma* **29**(3): 121-129.
- Frihagen, F., M. Grotle, J. E. Madsen, T. B. Wyller, P. Mowinckel and L. Nordsletten (2008). "Outcome after femoral neck fractures: a comparison of Harris Hip Score, Eq-5d and Barthel Index." *Injury* **39**(10): 1147-1156.
- Garden, R. (1961). "Low-angle fixation in fractures of the femoral neck." *J Bone Joint Surg Br* **43-B**(4): 647-663
- Givens, J. L., T. B. Sanft and E. R. Marcantonio (2008). "Functional recovery after hip fracture: the combined effects of depressive symptoms, cognitive impairment, and delirium." *J Am Geriatr Soc* **56**(6): 1075-1079.
- Harris, W. H. (1969). "Traumatic arthritis of the hip after dislocation and acetabular fractures: treatment by mold arthroplasty. An end-result study using a new method of result evaluation." *J Bone Joint Surg Am* **51**(4): 737-755.
- Hayakawa, T., S. Hashimoto, H. Kanda, N. Hirano, Y. Kurihara, T. Kawashima and T. Fukushima (2014). "Risk factors of falls in inpatients and their practical use in identifying high-risk persons at admission: Fukushima Medical University Hospital cohort study." *BMJ Open* **4**(8): e005385.
- Hedbeck, C. J., R. Blomfeldt, G. Lapidus, H. Törnkvist, S. Ponzer and J. Tidermark (2011). "Unipolar hemiarthroplasty versus bipolar hemiarthroplasty in the most elderly patients with displaced femoral neck fractures: a randomised, controlled trial." *Int Orthop* **35**(11): 1703-1711.
- Hedbeck, C. J., A. Enocson, G. Lapidus, R. Blomfeldt, H. Törnkvist, S. Ponzer and J. Tidermark (2011). "Comparison of bipolar hemiarthroplasty with total hip arthroplasty for displaced femoral neck fractures: a concise four-year follow-up of a randomized trial." *J Bone Joint Surg Am* **93**(5): 445-450.
- Hedbeck, C. J., J. Tidermark, S. Ponzer, R. Blomfeldt and G. Bergström (2011). "Responsiveness of the Short Musculoskeletal Function Assessment (SMFA) in patients with femoral neck fractures." *Qual Life Res* **20**(4): 513-521.
- Heetveld, M. J., C. Rogmark, F. Frihagen and J. Keating (2009). "Internal fixation versus arthroplasty for displaced femoral neck fractures: what is the evidence?" *J Orthop Trauma* **23**(6): 395-402.

- Hernigou, P., S. Quiennec and I. Guissou (2014). "Hip hemiarthroplasty: from Venable and Bohlman to Moore and Thompson." *Int Orthop* **38**(3): 655-661.
- Holzappel, B. M., P. M. Prodinger, M. Hoberg, R. Meffert, M. Rudert and R. Gradinger (2010). "[Periprosthetic fractures after total hip arthroplasty : classification, diagnosis and therapy strategies]." *Orthopade* **39**(5): 519-535.
- Inngul, C., C. J. Hedbeck, R. Blomfeldt, G. Lapidus, S. Ponzer and A. Enocson (2013). "Unipolar hemiarthroplasty versus bipolar hemiarthroplasty in patients with displaced femoral neck fractures: a four-year follow-up of a randomised controlled trial." *Int Orthop* **37**(12): 2457-2464.
- Jaglal, S. B., I. Weller, M. Mamdani, G. Hawker, H. Kreder, L. Jaakkimainen and J. D. Adachi (2005). "Population trends in BMD testing, treatment, and hip and wrist fracture rates: are the hip fracture projections wrong?" *J Bone Miner Res* **20**(6): 898-905.
- Jeffcote, B., M. G. Li, A. Barnet-Moorcroft, D. Wood and B. Nivbrant (2010). "Roentgen stereophotogrammetric analysis and clinical assessment of unipolar versus bipolar hemiarthroplasty for subcapital femur fracture: a randomized prospective study." *ANZ J Surg* **80**(4): 242-246.
- Jia, Z., F. Ding, Y. Wu, W. Li, H. Li, D. Wang, Q. He and D. Ruan (2015). "Unipolar versus bipolar hemiarthroplasty for displaced femoral neck fractures: a systematic review and meta-analysis of randomized controlled trials." *J Orthop Surg Res* **10**(1): 8.
- Johansson, T. (2014). "Internal fixation compared with total hip replacement for displaced femoral neck fractures: a minimum fifteen-year follow-up study of a previously reported randomized trial." *J Bone Joint Surg Am* **96**(6): e46.
- Johansson, T., S. A. Jacobsson, I. Ivarsson, A. Knutsson and O. Wahlstrom (2000). "Internal fixation versus total hip arthroplasty in the treatment of displaced femoral neck fractures: a prospective randomized study of 100 hips." *Acta Orthop Scand* **71**(6): 597-602.
- Kannus, P., S. Niemi, J. Parkkari, M. Palvanen, I. Vuori and M. Jarvinen (2006). "Nationwide decline in incidence of hip fracture." *J Bone Miner Res* **21**(12): 1836-1838.
- Keating, J. F., A. Grant, M. Masson, N. W. Scott and J. F. Forbes (2006). "Randomized comparison of reduction and fixation, bipolar hemiarthroplasty, and total hip arthroplasty. Treatment of displaced intracapsular hip fractures in healthy older patients." *J Bone Joint Surg Am* **88**(2): 249-260.
- Kelly, S. J., C. E. Robbins, B. E. Bierbaum, J. V. Bono and D. M. Ward (2007). "Use of a hydroxyapatite-coated stem in patients with Dorr Type C femoral bone." *Clin Orthop Relat Res* **465**: 112-116.
- Langslet, E., F. Frihagen, V. Opland, J. E. Madsen, L. Nordsletten and W. Figved (2014). "Cemented versus uncemented hemiarthroplasty for displaced femoral neck fractures: 5-year followup of a randomized trial." *Clin Orthop Relat Res* **472**(4): 1291-1299.
- Learmonth, I. D., C. Young and C. Rorabeck (2007). "The operation of the century: total hip replacement." *Lancet* **370**(9597): 1508-1519.
- Leonardsson, O., J. Kärrholm, K. Akesson, G. Garellick and C. Rogmark (2012). "Higher risk of reoperation for bipolar and uncemented hemiarthroplasty." *Acta Orthop* **83**(5): 459-466.

- Lieberman, J. R., P. S. Romano, G. Mahendra, J. Keyzer and M. Chilcott (2006). "The treatment of hip fractures: variations in care." Clin Orthop Relat Res **442**: 239-244.
- Lindahl, H., G. Garellick, H. Regner, P. Herberts and H. Malchau (2006a). "Three hundred and twenty-one periprosthetic femoral fractures." J Bone Joint Surg Am **88**(6): 1215-1222.
- Lindahl, H., H. Malchau, P. Herberts and G. Garellick (2005). "Periprosthetic femoral fractures classification and demographics of 1049 periprosthetic femoral fractures from the Swedish National Hip Arthroplasty Register." J Arthroplasty **20**(7): 857-865.
- Lindahl, H., H. Malchau, A. Oden and G. Garellick (2006b). "Risk factors for failure after treatment of a periprosthetic fracture of the femur." J Bone Joint Surg Br **88**(1): 26-30.
- Lindequist, S. and H. Törnkvist (1995). "Quality of reduction and cortical screw support in femoral neck fractures. An analysis of 72 fractures with a new computerized measuring method." J Orthop Trauma **9**(3): 215-221.
- Lippuner, K., S. Grifone, M. Schwenkglenks, P. Schwab, A. W. Popp, C. Senn and R. Perrelet (2012). "Comparative trends in hospitalizations for osteoporotic fractures and other frequent diseases between 2000 and 2008." Osteoporos Int **23**(3): 829-839.
- Liu, Y., X. Tao, P. Wang, Z. Zhang, W. Zhang and Q. Qi (2014). "Meta-analysis of randomised controlled trials comparing unipolar with bipolar hemiarthroplasty for displaced femoral-neck fractures." Int Orthop **38**(8): 1691-1696.
- Lu-Yao, G. L., R. B. Keller, B. Littenberg and J. E. Wennberg (1994). "Outcomes after displaced fractures of the femoral neck. A meta-analysis of one hundred and six published reports." J Bone Joint Surg Am **76**(1): 15-25.
- Marsh, J., D. Bryant and S. J. MacDonald (2009). "Older patients can accurately recall their preoperative health status six weeks following total hip arthroplasty." J Bone Joint Surg Am **91**(12): 2827-2837.
- Marsh, J. L., T. F. Slongo, J. Agel, J. S. Broderick, W. Creevey, T. A. DeCoster, L. Prokuski, M. S. Sirkin, B. Ziran, B. Henley and L. Audige (2007). "Fracture and dislocation classification compendium - 2007: Orthopaedic Trauma Association classification, database and outcomes committee." J Orthop Trauma **21**(10 Suppl): S1-133.
- Masri, B. A., R. M. Meek and C. P. Duncan (2004). "Periprosthetic fractures evaluation and treatment." Clin Orthop Relat Res(420): 80-95.
- Masson, M., M. J. Parker and S. Fleischer (2003). "Internal fixation versus arthroplasty for intracapsular proximal femoral fractures in adults." Cochrane Database Syst Rev(2): Cd001708.
- McGraw, I. W., S. C. Spence, E. J. Baird, S. M. Eckhardt and G. E. Ayana (2013). "Incidence of periprosthetic fractures after hip hemiarthroplasty: Are uncemented prostheses unsafe?" Injury **44**(12): 1945-1948.
- Meding, J. B., M. R. Galley and M. A. Ritter (2010). "High survival of uncemented proximally porous-coated titanium alloy femoral stems in osteoporotic bone." Clin Orthop Relat Res **468**(2): 441-447.
- Moore, A. T. (1952). "Metal hip joint; a new self-locking vitallium prosthesis." South Med J **45**(11): 1015-1019.

- Moroni A, P. F., Romagnoli M, Hoang-Kim A, Tesei F, Giannini S (2009). "Results in osteoporotic femoral neck fractures treated with cemented versus uncemented hip arthroplasty." J Bone Joint Surg Br **91_B**(Supp I).
- Munro, J. T., D. S. Garbuz, B. A. Masri and C. P. Duncan (2014). "Tapered fluted titanium stems in the management of Vancouver B2 and B3 periprosthetic femoral fractures." Clin Orthop Relat Res **472**(2): 590-598.
- Ning, G. Z., Y. L. Li, Q. Wu, S. Q. Feng, Y. Li and Q. L. Wu (2014). "Cemented versus uncemented hemiarthroplasty for displaced femoral neck fractures: an updated meta-analysis." Eur J Orthop Surg Traumatol **24**(1): 7-14.
- Olsen, F., M. Kotyra, E. Houltz and S. E. Ricksten (2014). "Bone cement implantation syndrome in cemented hemiarthroplasty for femoral neck fracture: incidence, risk factors, and effect on outcome." Br J Anaesth **113**(5): 800-806.
- Owens, W. D., J. A. Felts and E. L. Spitznagel, Jr. (1978). "ASA physical status classifications: a study of consistency of ratings." Anesthesiology **49**(4): 239-243.
- Parker, M. I., G. Pryor and K. Gurusamy (2010). "Cemented versus uncemented hemiarthroplasty for intracapsular hip fractures: A randomised controlled trial in 400 patients." J Bone Joint Surg Br **92**(1): 116-122.
- Parker, M. J. and K. Gurusamy (2006). "Internal fixation versus arthroplasty for intracapsular proximal femoral fractures in adults." Cochrane Database Syst Rev(4): Cd001708.
- Parker, M. J., K. S. Gurusamy and S. Azegami (2010). "Arthroplasties (with and without bone cement) for proximal femoral fractures in adults." Cochrane Database Syst Rev(6): Cd001706.
- Pavlou, G., P. Panteliadis, D. Macdonald, J. A. Timperley, G. Gie, G. Bancroft and E. Tsiridis (2011). "A review of 202 periprosthetic fractures--stem revision and allograft improves outcome for type B fractures." Hip Int **21**(1): 21-29.
- Pfeiffer, E. (1975). "A short portable mental status questionnaire for the assessment of organic brain deficit in elderly patients." J Am Geriatr Soc **23**(10): 433-441.
- Phillips, J. R., C. G. Moran and A. R. Manktelow (2013). "Periprosthetic fractures around hip hemiarthroplasty performed for hip fracture." Injury **44**(6): 757-762.
- Phillips, T. W. (1987). "The Bateman bipolar femoral head replacement. A fluoroscopic study of movement over a four-year period." J Bone Joint Surg Br **69**(5): 761-764.
- Raia, F. J., C. B. Chapman, M. F. Herrera, M. W. Schweppe, C. B. Michelsen and M. P. Rosenwasser (2003). "Unipolar or bipolar hemiarthroplasty for femoral neck fractures in the elderly?" Clin Orthop Relat Res(414): 259-265.
- Register, Norwegian Arthroplasty Register. (2010). "Annual report 2010." <http://nrlweb.ihelse.net/>.
- Register, Swedish Hip Arthroplasty Register. (2013). "Annual report 2013." <http://www.shpr.se>.
- Register, National Joint Arthroplasty Registry. (2014). "Annual report 2014." <http://www.njrcentre.org.uk>.
- Rikshöft, Natioanl Swedish Hip Fracture Register. (2013). "Annual report 2013." <http://www.rikshoft.se>.

- Roberts, K. C., W. T. Brox, D. S. Jevsevar and K. Sevarino (2015). "Management of hip fractures in the elderly." J Am Acad Orthop Surg **23**(2): 131-137.
- Rogmark, C., A. Carlsson, O. Johnell and I. Sernbo (2002). "A prospective randomised trial of internal fixation versus arthroplasty for displaced fractures of the neck of the femur. Functional outcome for 450 patients at two years." J Bone Joint Surg Br **84**(2): 183-188.
- Rogmark, C., A. M. Fenstad, O. Leonardsson, L. B. Engesaeter, J. Kärrholm, O. Furnes, G. Garellick and J. E. Gjertsen (2014). "Posterior approach and uncemented stems increases the risk of reoperation after hemiarthroplasties in elderly hip fracture patients." Acta Orthop **85**(1): 18-25.
- Rogmark, C., L. Flensburg and H. Fredin (2009). "Undisplaced femoral neck fractures--no problems? A consecutive study of 224 patients treated with internal fixation." Injury **40**(3): 274-276.
- Rogmark, C., O. Leonardsson, G. Garellick and J. Kärrholm (2012). "Monoblock hemiarthroplasties for femoral neck fractures--a part of orthopaedic history? Analysis of national registration of hemiarthroplasties 2005-2009." Injury **43**(6): 946-949.
- Rogmark, C., I. Sernbo, O. Johnell and J. A. Nilsson (1999). "Incidence of hip fractures in Malmo, Sweden, 1992-1995. A trend-break." Acta Orthop Scand **70**(1): 19-22.
- Rosengren, B. E. and M. K. Karlsson (2014). "The annual number of hip fractures in Sweden will double from year 2002 to 2050: projections based on local and nationwide data." Acta Orthop **85**(3): 234-237.
- Samuelsson, B., M. I. Hedstrom, S. Ponzer, A. Söderqvist, E. Samnegard, K. G. Thorngren, T. Cederholm, M. Saaf and N. Dalen (2009). "Gender differences and cognitive aspects on functional outcome after hip fracture--a 2 years' follow-up of 2,134 patients." Age Ageing **38**(6): 686-692.
- Schewelov, T., H. Ahlberg, L. Sanzen, J. Besjakov and A. Carlsson (2012). "Fixation of the fully hydroxyapatite-coated Corail stem implanted due to femoral neck fracture: 38 patients followed for 2 years with RSA and DEXA." Acta Orthop **83**(2): 153-158.
- Schwarzkopf, R., J. K. Oni and S. E. Marwin (2013). "Total hip arthroplasty periprosthetic femoral fractures: a review of classification and current treatment." Bull Hosp Jt Dis (2013) **71**(1): 68-78.
- Sen, R., P. Prasad, S. Kumar and O. Nagi (2007). "Periprosthetic femoral fractures around well fixed implants: a simple method of fixation using LC-DCP with trochanteric purchase." Acta Orthop Belg **73**(2): 200-206.
- Sheth, N. P., N. M. Brown, M. Moric, R. A. Berger and C. J. Della Valle (2013). "Operative treatment of early peri-prosthetic femur fractures following primary total hip arthroplasty." J Arthroplasty **28**(2): 286-291.
- Singer, A., A. Exuzides, L. Spangler, C. O'Malley, C. Colby, K. Johnston, I. Agodoa, J. Baker and R. Kagan (2015). "Burden of illness for osteoporotic fractures compared with other serious diseases among postmenopausal women in the United States." Mayo Clin Proc **90**(1): 53-62.
- Sköldenberg, O. G., H. Sjöö, P. Kelly-Pettersson, H. Boden, T. Eisler, A. Stark and O. Muren (2014). "Good stability but high periprosthetic bone mineral loss and late-occurring periprosthetic fractures with use of uncemented tapered femoral stems in patients with a femoral neck fracture." Acta Orthop **85**(4): 396-402.

- Söderqvist, A., W. Ekström, S. Ponzer, H. Pettersson, T. Cederholm, N. Dalen, M. Hedstrom, J. Tidermark and G. Stockholm Hip Fracture (2009). "Prediction of mortality in elderly patients with hip fractures: a two-year prospective study of 1,944 patients." *Gerontology* **55**(5): 496-504.
- Söderqvist, A., R. Miedel, S. Ponzer and J. Tidermark (2006). "The influence of cognitive function on outcome after a hip fracture." *J Bone Joint Surg Am* **88**(10): 2115-2123.
- Stoen, R. O., C. M. Lofthus, L. Nordsletten, J. E. Madsen and F. Frihagen (2014). "Randomized trial of hemiarthroplasty versus internal fixation for femoral neck fractures: no differences at 6 years." *Clin Orthop Relat Res* **472**(1): 360-367.
- Stoffel, K. K., B. Nivbrant, J. Headford, R. L. Nicholls and P. J. Yates (2013). "Does a bipolar hemiprosthesis offer advantages for elderly patients with neck of femur fracture? A clinical trial with 261 patients." *ANZ J Surg* **83**(4): 249-254.
- Swiontkowski, M. F., R. Engelberg, D. P. Martin and J. Agel (1999). "Short musculoskeletal function assessment questionnaire: validity, reliability, and responsiveness." *J Bone Joint Surg Am* **81**(9): 1245-1260.
- Talsnes, O., F. Hjelmstedt, A. H. Pripp, O. Reikeras and O. E. Dahl (2013). "No difference in mortality between cemented and uncemented hemiprosthesis for elderly patients with cervical hip fracture. A prospective randomized study on 334 patients over 75 years." *Arch Orthop Trauma Surg* **133**(6): 805-809.
- Taylor, F., M. Wright and M. Zhu (2012). "Hemiarthroplasty of the hip with and without cement: a randomized clinical trial." *J Bone Joint Surg Am* **94**(7): 577-583.
- Thomsen, N. O., C. M. Jensen, N. Skovgaard, M. S. Pedersen, P. Pallesen, N. H. Soe-Nielsen and A. Rosenklint (1996). "Observer variation in the radiographic classification of fractures of the neck of the femur using Garden's system." *Int Orthop* **20**(5): 326-329.
- Tidermark, J. and G. Bergström (2007). "Responsiveness of the EuroQol (EQ-5D) and the Nottingham Health Profile (NHP) in elderly patients with femoral neck fractures." *Qual Life Res* **16**(2): 321-330.
- Tidermark, J., G. Bergström, O. Svensson, H. Törnkvist and S. Ponzer (2003). "Responsiveness of the EuroQol (EQ 5-D) and the SF-36 in elderly patients with displaced femoral neck fractures." *Qual Life Res* **12**(8): 1069-1079.
- Tidermark, J., S. Ponzer, O. Svensson, A. Söderqvist and H. Törnkvist (2003). "Internal fixation compared with total hip replacement for displaced femoral neck fractures in the elderly. A randomised, controlled trial." *J Bone Joint Surg Br* **85**(3): 380-388.
- Tidermark, J., N. Zethraeus, O. Svensson, H. Törnkvist and S. Ponzer (2003). "Quality of life related to fracture displacement among elderly patients with femoral neck fractures treated with internal fixation. 2002." *J Orthop Trauma* **17**(8 Suppl): S17-21.
- Tsiridis, E., F. S. Haddad and G. A. Gie (2003). "The management of periprosthetic femoral fractures around hip replacements." *Injury* **34**(2): 95-105.
- Tsiridis, E., G. Pavlou, R. Venkatesh, P. Bobak and G. Gie (2009). "Periprosthetic femoral fractures around hip arthroplasty: current concepts in their management." *Hip Int* **19**(2): 75-86.
- Valizadeh, M., S. Mazloomzadeh, S. Golmohammadi and B. Larijani (2012). "Mortality after low trauma hip fracture: a prospective cohort study." *BMC Musculoskelet Disord* **13**: 143.

- van Dortmont, L. M., C. M. Douw, A. M. van Breukelen, D. R. Laurens, P. G. Mulder, J. C. Wereldsma and A. B. van Vugt (2000). "Cannulated screws versus hemiarthroplasty for displaced intracapsular femoral neck fractures in demented patients." Ann Chir Gynaecol **89**(2): 132-137.
- Verberne, G. H. (1983). "A femoral head prosthesis with a built-in joint. A radiological study of the movements of the two components." J Bone Joint Surg Br **65**(5): 544-547.
- Vioreanu, M. H., M. C. Parry, F. S. Haddad and C. P. Duncan (2014). "Field testing the Unified Classification System for peri-prosthetic fractures of the pelvis and femur around a total hip replacement : an international collaboration." Bone Joint J **96-b**(11): 1472-1477.
- Wachtl, S. W., R. P. Jakob and E. Gautier (2003). "Ten-year patient and prosthesis survival after unipolar hip hemiarthroplasty in female patients over 70 years old." J Arthroplasty **18**(5): 587-591.
- Wamper, K. E., I. N. Sierevelt, R. W. Poolman, M. Bhandari and D. Haverkamp (2010). "The Harris hip score: Do ceiling effects limit its usefulness in orthopedics?" Acta Orthop **81**(6): 703-707.