

From THE DEPARTMENT OF CLINICAL NEUROSCIENCE,
SECTION OF OPHTHALMOLOGY AND VISION,
ST. ERIK EYE HOSPITAL
Karolinska Institutet, Stockholm, Sweden

CONGENITAL ECTOPIA LENTIS
- DIAGNOSIS AND TREATMENT

Tiina Rysä Konradsen

Stockholm 2012

All previously published papers were reproduced with permission from the publisher.

Published by Karolinska Institutet. Printed by Larserics Digital Print AB.

© Tiina Rysä Konradsen, 2012

ISBN 978-91-7457-883-6

ABSTRACT

Congenital ectopia lentis (EL) is an ocular condition, which typically causes a high grade of refractive errors, mainly myopia and astigmatism. These might be difficult to compensate for, especially in children, who might develop ametropic amblyopia. Surgery on ectopic lenses has previously been controversial, due to the risk of sight-threatening complications.

In **paper I** we studied retrospectively visual outcomes and complications in children, who were operated for congenital EL, and who had an scleral-fixated capsular tension ring (CTR) and an intra-ocular lens (IOL) implanted at the primary surgery. Thirty-seven eyes of 22 children were included. Visual acuity (VA) improved in all eyes, and only few had persistent amblyopia at the end of the follow-up. A great majority of the eyes had postoperative visual axis opacification (VAO), which was expected, since the posterior capsule was left intact at the primary surgery. Two eyes required secondary suturing for IOL decentration. No eye had any serious complications such as retinal detachment, glaucoma or endophthalmitis.

Congenital ectopia lentis is often an indicator of a systemic connective tissue disorder, and Marfan syndrome (MFS) is diagnosed in 70% of the cases. This genetic disorder affects basically all organ systems in the body, EL and dilatation of the ascending aorta being the cardinal signs. MFS is associated with markedly decreased life expectancy due to the cardiovascular complications. Therefore, an early and accurate diagnosis is of importance.

In **paper II** we measured the accommodative power, lens thickness, anterior chamber depth (ACD), and pupil size in these eyes, using an optical coherence tomography (OCT). Thirty-one eyes of 31 cases of MFS were included, and these were compared to non-affected controls. We found that the lens was significantly thicker in MFS at all stages. The pupil size was significantly smaller in MFS at baseline, decreased less in accommodation and dilated more during dilatation. No significant difference was seen in the accommodative power or ACD. No difference was seen in any parameter between the MFS eyes with, and without EL. We conclude, that even though the lens and the pupil seem to be affected in MFS, these eyes seem to have the same ability to accommodate as normal subjects. The observed changes seem to be associated to MFS independently of EL.

In **paper III** we studied the corneal curvature, thickness and endothelial cell density (ECD) in 39 MFS eyes and compared those to non-affected controls. We found significantly lower keratometric (K) values and corneal thickness in MFS, but no difference in the ECD. No significant difference was found in these parameters between MFS eyes with and without EL. We also reported on generally increased corneal astigmatism in MFS, especially in eyes with EL.

In **paper IV** we described the ocular characteristics in 102 eyes of 56 cases of MFS. We found increased axial length, but mostly only moderate myopia, which seemed to be compensated by the flat cornea. The majority of the eyes had EL, or were pseudophakic due to EL. Other associated diagnosis included amblyopia, glaucoma, retinal detachment and strabismus.

In conclusion, we found that surgery for EL in children, including CTR and IOL gives good visual development and no serious complications. Also, most of the ocular changes in MFS seem to be connected to MFS itself, rather than EL.

LIST OF PUBLICATIONS

- I. Konradsen T, Kugelberg M, Zetterström C.
Visual outcomes and complications in surgery for ectopia lentis in children.
Journal of Cataract and Refractive Surgery 2007 May;33(5):819-24.
- II. Konradsen TR, Koivula A, Kugelberg M, Zetterström C.
Accommodation measured with optical coherence tomography in patients with Marfan's syndrome.
Ophthalmology 2009 Jul;116(7):1343-8.
- III. Konradsen TR, Koivula A, Kugelberg M, Zetterström C.
Corneal curvature, pachymetry, and endothelial cell density in Marfan syndrome.
Acta Ophthalmologica Scandinavica 2012 Jun;90(4):375-9.
- IV. Konradsen TR, Zetterström C.
A descriptive study of ocular characteristics in Marfan syndrome.
Submitted.

TABLE OF CONTENTS

1	Ectopia lentis – introduction	1
1.1	Definition.....	1
1.2	The optical function of the lens	1
1.3	Epidemiology	2
1.4	Pathophysiology.....	4
1.5	Consequences and complications	5
1.5.1	Myopia and astigmatism.....	5
1.5.2	Glaucoma	5
1.5.3	Retina	6
1.6	Surgical treatment of ectopia lentis.....	6
1.6.1	Introduction.....	6
1.6.2	Endocapsular devices.....	7
1.6.3	Indications.....	9
1.7	Refractive correction of ectopia lentis	9
2	Marfan syndrome	10
2.1	Introduction	10
2.2	Molecular genetics and pathophysiology	10
2.3	Clinical signs and diagnostic criteria	11
2.4	Ocular signs.....	13
2.4.1	Ocular diagnostic criteria.....	13
2.4.2	Lens	14
2.4.3	Refraction.....	14
2.4.4	Cornea	14
2.4.5	Iris.....	15
2.5	Medical therapy.....	15
2.6	Mortality	16
2.7	Neonatal MFS	16
3	General aims	17
4	Material and methods.....	18
4.1	Paper I.....	18
4.1.1	Patients and methods	18
4.2	Paper II	18
4.2.1	Study design.....	18
4.2.2	Inclusion/exclusion criteria.....	18
4.2.3	Method	18
4.2.4	Optical coherence tomography.....	19
4.2.5	Statistical Analysis.....	20
4.3	Paper III.....	20
4.3.1	Study design.....	20
4.3.2	Inclusion/exclusion criteria.....	20
4.3.3	Method	20
4.3.4	Orbscan II Segment Analyzer.....	20
4.3.5	Statistical Analysis.....	21
4.4	Paper IV.....	21
4.4.1	Study design.....	21

4.4.2	Inclusion/exclusion criteria	21
4.4.3	Method.....	21
4.4.4	Statistical Analysis	21
5	Results and discussion.....	22
5.1	Paper I.....	22
5.1.1	Patient data	22
5.1.2	Visual outcomes	22
5.1.3	Complications.....	23
5.2	Paper II.....	24
5.2.1	Baseline data.....	24
5.2.2	The lens and anterior chamber depth	24
5.2.3	The pupil.....	25
5.3	Paper III	26
5.3.1	Baseline data.....	26
5.3.2	Corneal assessments	26
5.4	Paper IV	28
5.4.1	Ocular characteristics	28
5.4.2	Phakic eyes	28
5.4.3	Aphakic eyes	30
5.4.4	Pseudophakic eyes.....	30
6	Main conclusions.....	32
7	Future perspectives.....	33
8	Sammanfattning på svenska	34
9	Acknowledgements	36
10	References	39

LIST OF ABBREVIATIONS

AL	Axial length
ACD	Anterior chamber depth
ACIOL	Anterior chamber intraocular lens
BCVA	Best corrected visual acuity
BSCVA	Best spectacle-corrected visual acuity
CTR	Capsular tension ring
CTS	Capsular tension segment
D	Diopters
ECCE	Extracapsular cataract extraction
ECD	Endothelial cell density
EL	Ectopia lentis
FBN1	Fibrillin 1
ICCE	Intracapsular cataract extraction
IOL	Intraocular lens
IOP	Intraocular pressure
K value	Keratometric value
K _{max}	Maximum keratometric value
K _{med}	Mean of the maximum and minimum keratometric value
K _{min}	Minimum keratometric value
LH	Lea Hyvärinen
logMAR	Logarithm of the minimum angle of resolution
M-CTR	Modified capsular tension ring
MASS	Myopia, mitral valve prolapse, borderline ($Z < 2$) aortic root dilatation, striae, skeletal findings
MFS	Marfan syndrome
MMP	Matrix metalloproteinase
MVPS	Mitral valve prolaps syndrome
nMFS	Neonatal Marfan syndrome
OCT	Optical coherence tomography
OR	Odds ratio
PCIOL	Posterior chamber intraocular lens
PMMA	Polymethylmethacrylate

POAG	Primary open-angle glaucoma
RD	Retinal detachment
TAA	Thoracic aortic aneurysm
TGF- β	Transforming growth factor beta
TGFBR2	Transforming growth factor, beta receptor II
UV-B	Ultraviolet light B
VA	Visual acuity
VAO	Visual axis opacification

1 ECTOPIA LENTIS – INTRODUCTION

1.1 DEFINITION

Ectopia lentis is defined as a displacement of the crystalline lens of the eye from its normal location. The lens is normally positioned posterior of the pupillary aperture, centered in the middle of the pupil with its thickest part along with the optical axis (Figure 1). If the lens is partly displaced, it is referred to as subluxated, and if totally displaced, it is referred to as luxated. Lens ectopia can be divided into congenital and non-congenital type. In this thesis only congenital lens ectopia will be discussed.

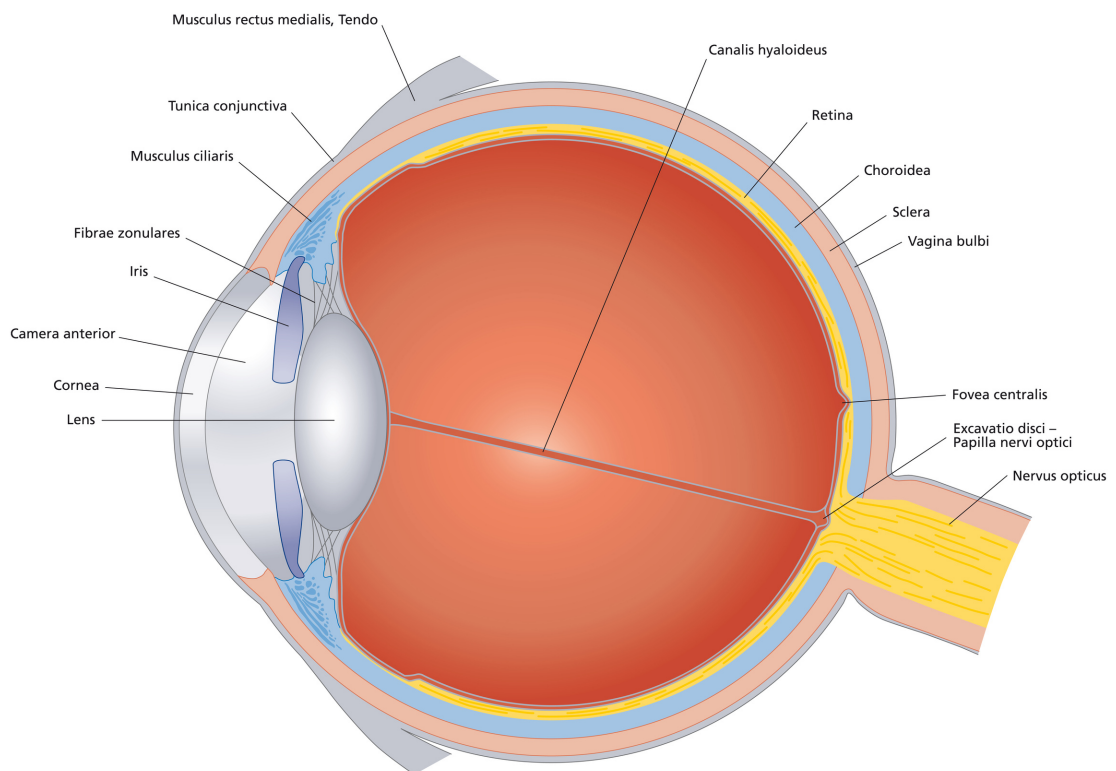


Figure 1. The anatomy of a human eye.

1.2 THE OPTICAL FUNCTION OF THE LENS

The crystalline lens plays an important role in the optical system of the eye. It gathers the rays of light entering the eye in a single spot, fovea centralis, on the retina, in the posterior pole of the eye. The total refractive power of a relaxed eye is approximately 60 diopters (D). The light rays entering the eye are first converged in the cornea, which is a convex, light-permeable structure on the anterior part of the eye, and has a refractive power of approximately 40 D. The light rays are then further converged as they pass through the lens, with a power of approximately 20 D. Also aqueous and

vitreous humors contribute to convergence, but account for a minor part of the total refractive power.

The crystalline lens embodies a unique ability to adapt its light-refractive power, depending on the distance to the object, which the eye is focused on. This focusing ability, accommodation, is possible due to the elastic structure of the lens, and the thin threads (zonulae) that are attached radially from its outermost edge (equator) to the ciliary muscle around it. When looking at distance, the ciliary muscle is relaxed, the zonulae are stretched, and the lens is flat. Changing the focus on a closer target, however, makes the ciliary muscle to contract, allowing the lens to get thicker. This will increase the refractive power of the lens. The degree of accommodation, the accommodative amplitude, is about 20 D at the age of 10 years, and is gradually decreased with age. By the age of about 60 years, the accommodative amplitude is practically non-existent. This loss of accommodative ability is called presbyopia.

The exact mechanism of accommodation and causes of presbyopia have been discussed. According to the ruling theory on accommodation, described by Helmholtz (Von Helmholtz 1855), the contraction of the ciliary muscle allows all the zonulae to relax, thereby allowing the elastic lens capsule to contract, causing a decrease in the equatorial diameter, a decrease in the radii of curvature of the anterior and posterior lens surfaces, and an increase in axial lens thickness (Schachar et al. 1996). According to this hypothesis, presbyopia is caused by loss of elasticity of the lens capsule and/or sclerosis of the lens nucleus, with decreased ability to change its shape.

Lately, electronmicroscopic studies on the structures around the lens, zonules, and ciliary body have revealed that the anterior and posterior lens zonules originate from the surface of pars plicata, while the equatorial zonules originate from anterior valleys between the ciliary processes (Stachs et al. 2006). It has also been shown that the equator of the lens moves peripherally towards the sclera during accommodation (Schachar et al. 1996). It has therefore been proposed by Schachar that accommodation is a product of increased tension in the equatorial zonules, which causes flattening and increased diameter of the lens equator; and decreased tension in the anterior and posterior zonules, causing steepening of the anterior and posterior lens surface (Schachar et al. 1996; Schachar 2004; Schachar 2006). Since the lens is of ectodermal origin, and continues to grow throughout life (ca. 0.02 mm/year), while the sclera does not change significantly after childhood, it is postulated that the effective force that the ciliary body can apply to the lens equator decreases with age. According to this theory, presbyopia results from normal lens growth, rather than structural changes in the lens (Schachar 2006).

1.3 EPIDEMIOLOGY

In a large Danish retrospective study on epidemiology and characterisation of conditions associated to ectopia lentis, 396 cases of ectopia lentis were studied and classified (Fuchs & Rosenberg 1998). In this study the reported prevalence rate of ectopia lentis at birth was 0.83/10,000 live born, and 6.4 /100,000 in general population.

In their study, the nosological classification was possible in only 70% of these cases, but the authors found that the great majority of the cases (68%) also had Marfan syndrome (MFS) (Figure 2). Other diagnoses included:

- Ectopia lentis et pupillae	21%
- Simple dominant ectopia lentis	8.0%
- Homocysteinuria	1.1%
- Sulfite oxidase deficiency	0.7%
- Weill-Marchesani syndrome	0.7%

It seems apparent that ectopia lentis is often a part of a systemic condition, and in a majority of the cases Marfan syndrome. Therefore, the work-up of ectopia lentis should always include a general medical examination. Marfan syndrome will be described in detail in chapter 2.

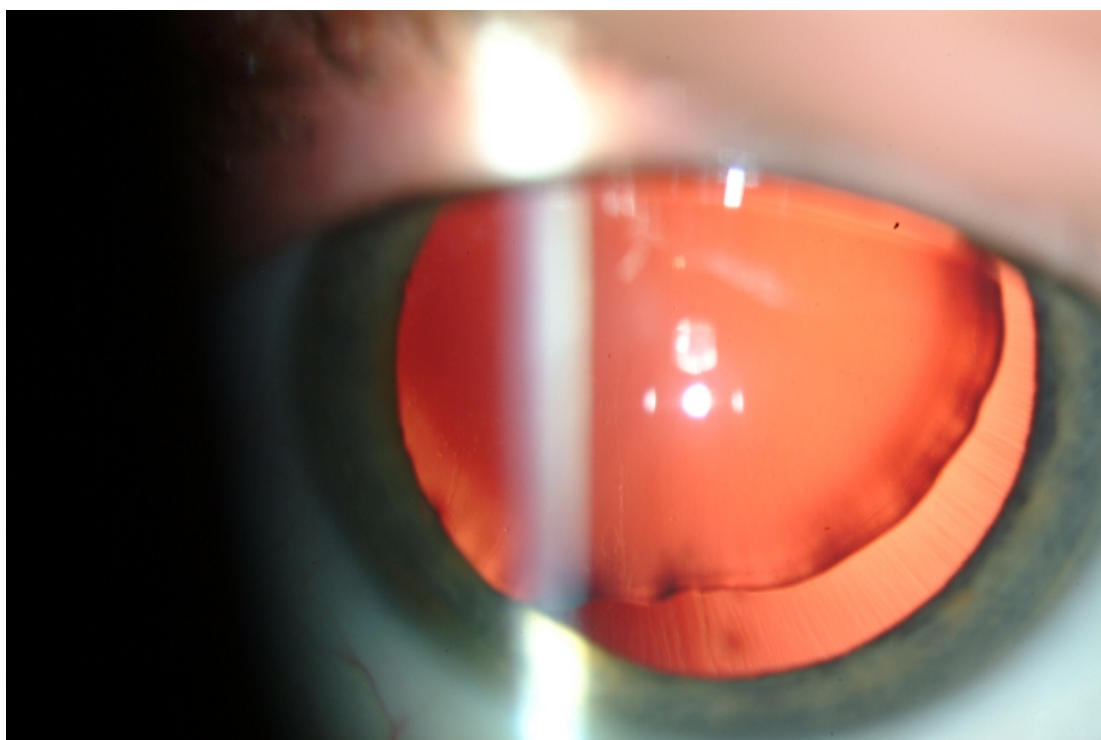


Figure 2. A superiotemporal subluxation of the lens in Marfan syndrome.

Ectopia lentis et pupillae is a rare condition, in which remnants of the pupillary membrane are present, often bilaterally. The pupil is oval or slit-shaped and dislocated in opposite directions than the lens. Other features include iris transillumination in the iris periphery, high myopia and poor vision. It is autosomal recessive condition, which lacks the systemic signs of MFS (Cruysberg & Pinckers 1995).

'Simple dominant ectopia lentis', or familial ectopia lentis, is a condition with some skeletal features of MFS and a mutation in the same gene as in MFS, the FBN1 gene. They lack, however, the risk of aortic risk found in MFS. Since aortic dilatation and aneurysm may arise later in life, even patients with familial ectopia lentis should be followed up with cardiovascular imaging throughout the life.

Homocysteinuria is a condition, which in addition to ectopia lentis, is associated to mental retardation and thrombosis. The diagnosis is based on an analysis on urine amino acids in the absence of pyridoxine supplementation. The lens

is typically dislocated downward, due to total loss of zonular support (Pyeritz & McKusick 1979).

Sulfite oxidase deficiency is a rare, but fatal disease, causing neurological disorders, mental retardation, degradation of the brain, and death. In some cases ectopia lentis have been seen (Lee 2011).

Weill-Marchesani syndrome is associated with microspherophakia (small, thick and round lens), and shallow anterior chamber. The affected cases are short, have brachydactyly (short and stubby hands and feet) and joint stiffness. The ocular features include high myopia (due to dislocated lens), cataract and glaucoma. Both autosomal dominant and recessive inheritance occur (Faivre et al. 2003). In the dominant cases, FBN1 mutations are found.

1.4 PATHOPHYSIOLOGY

In 1986, fibrillin 1 was identified as a major component of the extracellular matrix microfibril (Sakai et al. 1986), which is present in skin, lung, kidney, vasculature cartilage, tendon, muscle, cornea and ciliary zonules (Kielty et al. 2005). Thus, it is found in practically all tissues with clinical manifestations of MFS. Fibrillins are large glycoproteins that are polymerized in to bead-like microfibrils, including epidermal growth factor-like domains, as well as TGF- β binding protein-like domains (Ramirez & Sakai 2010). These microfibrils can occur independently in the extracellular matrix, or associate with elastin in elastic fibers.

The ciliary zonules anchor the crystalline lens radially from the equator of the lens to the surrounding ciliary body. These zonular fibers are composed of elastic core, covered with microfibrils containing fibrillin 1. Fibrillin 1 is mainly secreted by the cells of non-pigmented epithelium of the ciliary body (Hanssen et al. 2001). Although the secretion of new fibrillin decreases with age, the amount of fibrillin present in zonules is the same, probably due to remodelling of the microfibrils. This gives the zonular microfibrils a shorter and increasingly disorganized appearance, which may reflect an increased cross-linking of the microfibrils during ageing (Hanssen et al. 1998).

Besides in the zonules, fibrillin has been seen in various structures of the human eye (Wheatley et al. 1995). In the anterior segment, fibrillin has been seen the lens capsule; connective tissues of the iris, ciliary body, ciliary processes and conjunctiva; the basement membrane of the corneal epithelium (mainly in the periphery) and endothelium of Schlemm's canal. In the posterior segment fibrillin has been localized in the lamina cribrosa, sclera, choroid, around the retinal vessels and retinal pigment epithelium.

The exact mechanism causing zonular stretching in ectopia lentis is still unknown, but it seems that pathologic fibrillin 1 found in systemic conditions associated with ectopia lentis could be more susceptible to proteolysis (Reinhardt et al. 2000). When the fibrillin polymers are proteolyzed into monomers, the amount of free fibrillin increases in the extracellular matrix. The free fibrillin 1 fragments are then believed to cause upregulation of extracellular matrix proteins and antiproteases, including matrix metalloproteinases (MMPs), which in turn leads to degradation of microfibrils (Booms et al. 2005). On the other hand, it is not known whether there

could be structural changes in the zonules in the direction of ectopia, causing traction on the lens and secondary stretching in the zonules at the opposite side of the lens.

On the lens capsule, three distinct zones containing fibrillin may be seen in the equatorial and periequatorial regions of a normal lens capsule. These regions are platforms for zonular attachment on the surface on the lens. Fibrillins in these areas show significant quantitative and qualitative defects in MFS, and show abnormal and disrupted appearance when imaged (Mir et al. 1998; Traboulsi et al. 2000). The zonules in MFS are thin, stretched and irregular in diameter. Substantial differences in the quality of fibrillin 1 have also been shown in conjunctiva of MFS patients with ectopia lentis, compared to unaffected controls (Ganesh et al. 2006). These changes lay ground for a causative relationship between abnormalities in the quality and quantity of fibrillin-containing microfibrils in the lens capsule and lens ectopia in MFS.

1.5 CONSEQUENCES AND COMPLICATIONS

1.5.1 Myopia and astigmatism

Myopia and astigmatism are the most common consequences of lens ectopia. Dagi and Walton (Dagi & Walton 2006) have outlined the two types of mechanisms leading to progressive myopia in ectopia lentis: firstly, the anterior displacement of the lens and the iris, moving the focal point of the eye forward, and secondly, the relaxation of the zonulae, giving rise to more spherical shape of the lens, and thereby increasing its refractive power. Progressive ectopia lentis also causes irregular astigmatism, which may result in blurred vision and monocular diplopia.

1.5.2 Glaucoma

Glaucoma is seen more frequently in MFS than in general population (Izquierdo et al. 1992). Primary open-angle glaucoma (POAG) is seen most often, but it may arise via several mechanisms (Nemet et al. 2006):

- 1) POAG. Without any obvious anatomical or mechanical reason, but sometimes displacement of Schlemm's canal or unusual prominence of the canal and aqueous veins are seen (Allen et al. 1967).
- 2) Secondary angle-closure glaucoma. In ectopia lentis, the lens may move forward, displacing the iris forward, thereby narrowing the angle. This may be enhanced by vitreous dislocation into the anterior segment (Ritch et al. 2003; Barkana et al. 2006) (Figure 3).
- 3) Pupillary block glaucoma, in which the lens is subluxated anteriorly, blocking the aqueous humor circulation. The lens may be pressed against the pupillary borders, incarcerated in the pupillary aperture, or dislocated into the anterior chamber. Treatment of increased intra-ocular pressure (IOP) with pilocarpine at this state is contraindicated. The situation should instead be managed with pupil dilating topical medication, supine positioning of the patient in order to replace the lens, peripheral iridotomy, and lens extraction.
- 4) Pigment dispersion glaucoma, caused by contact of the mobile crystalline lens with the iris (Doyle et al. 2005).

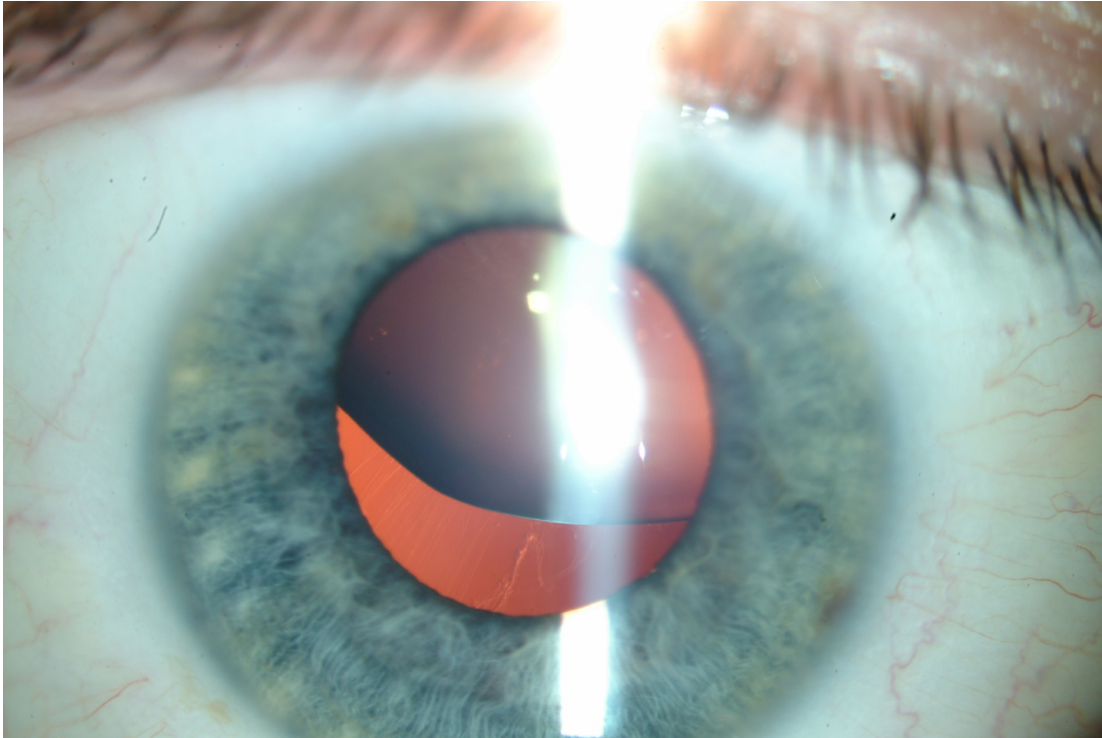


Figure 3. Ectopia lentis is associated with an increased risk of glaucoma and retinal detachment through several possible mechanisms.

1.5.3 Retina

Ectopia lentis and aphakia are associated with an increased risk of retinal detachment. In addition, MFS increases this risk, ranging from 5-25% in different case series (Nemet et al. 2006). This is mainly due to increased axial length (Maumenee 1981) and is often seen bilaterally in MFS (Dotrelova 1998). Also, the ectopic lens may cause vitreous traction. Fibrillin is found in the walls of retinal vessels, which could contribute to formation of retinal breaks and detachment in MFS (Wheatley et al. 1995). Further, the retinal ruptures or early detachments may be easily missed in MFS due to a small, poorly dilating pupil and lens abnormalities (Remulla & Tolentino 2001).

1.6 SURGICAL TREATMENT OF ECTOPIA LENTIS

1.6.1 Introduction

The modern techniques of lens surgery have developed due to the need for effective and safe methods for treatment of cataract. Although cataract at early age is a common feature in ectopia lentis, many cases of ectopia lentis are operated mainly on refractive indications. This is true especially in children, who may now gain from the development of these techniques, and be operated at early age.

The golden standard of cataract surgery today is phacoemulsification with posterior-chamber intraocular lens (PCIOL). However, in case of poor zonular support, there is an increased risk of capsular tears, vitreous loss, retained lens material and

intraocular lens (IOL) decentration/dislocation. Before the development of the current techniques, these cases required extracapsular cataract extraction (ECCE), intracapsular cataract extraction (ICCE), or pars plana lensectomy.

The alternatives for surgical correction of aphakia, when the posterior capsule is extracted, are the anterior-chamber IOL (ACIOL) and scleral-fixated PCIOL. The ACIOL is found in mainly two types: one fixated in the angle, and the other one is iris claw lens, which is today, in some cases, fixated retropupillary. However, the risk of vitreous loss and retinal detachment are decreased, if the lens capsule is left intact. Therefore, an IOL implanted in the bag seems like a safer alternative in cases of lens ectopia.

1.6.2 Endocapsular devices

The introduction of capsular support devices – capsular tension rings (CTRs), modified CTRs (M-CTR), capsular tension segments (CTSs), and iris/capsule support hooks – have improved the safety of lens surgery in cases of poor zonular support, and they have come as welcomed instruments for lens surgeons, who face these challenging situations (Figure 4). They all contribute to preservation and stabilisation of the capsular bag so that PCIOL may be safely implanted and the PCIOL remains stable post-operatively.




Figure 4. An illustration of some endocapsular devices. From the top left, clockwise: capsular tension ring (CTR), modified CTR with one eyelet, capsular tension segment, and modified CTR with two eyelets. (MORCHER® GmbH, Germany)

1.6.2.1 Capsular tension ring

A CTR is an open, compressible, polymethylmethacrylate (PMMA) ring with a rounded eyelet at each end of the ring. Since its diameter is slightly greater than the capsular bag, it exerts a centrifugal force at the equator, expands the capsular bag and redistributes tension from the weakened zonules to stronger, intact zonules (Blecher & Kirk 2008). The first CTR was introduced by Hara et al. in 1991 (Hara et al. 1991). This was a redesign of a previous endocapsular device introduced in Japan in the late 1980s, which was designed for preventing migration of epithelial cells and posterior capsule opacification (Hasanee & Ahmed 2006). The ‘equator ring’ created by Hara et al. had a closed-ring structure, which limited its use in capsular bags of varying sizes. Also in 1991, Nagamoto and Bissen-Miyajuma presented an open PMMA ring developed for capsular support (Nagamoto & Bissen-Miyajima 1994). These rings were popularized and further developed by Legler and BM Witschel.

1.6.2.2 Modified capsular tension ring

Before the introduction of M-CTR, the cases of profound zonular support required more invasive and complicated surgery, since the standard CTR does not offer sufficient support in those cases. Sometimes, suturing of the CTS through the capsular bag, and fixating it to sclera was done (Lam et al. 2000). This procedure, however, increases the risk of capsular tears markedly, and disrupts the integrity of the capsular bag as a barrier between anterior and posterior segment, thus increasing the risk of peri- and postoperative complications. To address these issues, Cionni developed a M-CTR in 1998. It is a development of the traditional CTR, with the addition of one (model 1-L or 1-R) or two (model 2-L) fixation eyelets attached to the central ring, allowing fixation to sclera (Ahmed & Crandall 2001; Kohnen et al. 2003). This device allows small-incision intraocular surgery and PCIOL implantation (Cionni et al. 2003; Moreno-Montanes et al. 2003) (Figure 5).

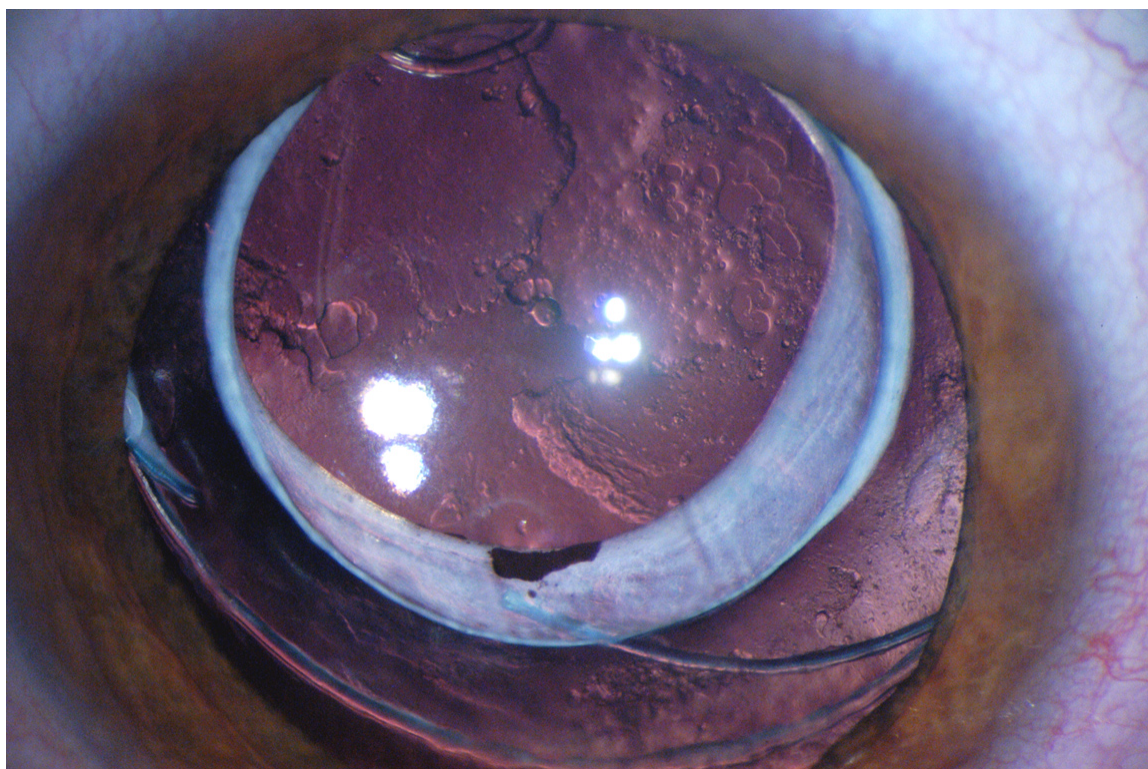


Figure 5. A Cionni modified capsular tension ring (note the fixation eyelet superiorly), and a 3-piece IOL implanted in the bag. Visual axis opacification is seen in the posterior lens capsule.

1.6.2.3 *Capsular tension segment*

Capsular tension segment was designed by Ahmed in 2002 (Hasanee & Ahmed 2006). It is a partial PMMA ring segment, with 120 degrees width and a radius of 5 mm. Like M-CTR, CTS also possesses an anteriorly positioned fixation eyelet, which is used when fixating the segment to sclera.

1.6.3 Indications

The CTRs are useful and indicated in cases of mild zonular weakness (<4 clock hours), and possibly in cases of generalized zonular weakness in eyes with pseudoexfoliation (Gimbel et al. 1997; Jacob et al. 2003; Ahmed et al. 2005). In cases of moderate or advanced zonular dialysis, a CTR is considered to be insufficient. In these cases a M-CTR or a CTS, which both provide fixation into sclera, is required. In case of anterior capsule tear, posterior capsule rent, incomplete rhexis, or in need for recentering a severely subluxated capsular bag, the use of CTR and M-CTR is contraindicated (Lang et al. 2001; Bopp & Lucke 2003; Bhattacharjee et al. 2004).

Due to the fact that CTS is smaller than a CTR or a M-CTR, it is easier to insert in the capsular bag, even before phacoemulsification. It is designed to glide in to the bag atraumatically, and thus transmits much less force on the weakened zonules than a CTR or a M-CTR does. Therefore, a CTS is a good option in cases of profound zonular dialysis. The advantage of the CTS is that it may be used even in cases of discontinuous capsulorrhexis, anterior capsule tear, or a posterior capsule rent. Several segments may be used, in cases of general zonular weakness.

1.7 REFRACTIVE CORRECTION OF ECTOPIA LENTIS

In mild cases of ectopia lentis, with a stable refraction, spectacles may be used for correction of ametropia. In children, however, this requires frequent follow-up of the visual acuity and possible changes in refraction, in order to avoid amblyopia. It has been shown that conservative treatment in ectopia lentis, despite of careful refraction, gives poor visual development, with ametropic functional amblyopia in 50% of the patients (Romano et al. 2002).

Before the surgical management of ectopia lentis was developed to the standard that is seen today, aphakic contact lenses were recommended as the safest option for postoperative optical correction in pediatric lens ectopia (Neely & Plager 2001). However, the management of contact lenses is challenging in children, and requires much attention from the parents, as well as close follow-up by ophthalmological specialists. It has been reported that contact lens wearing in MFS is associated with complications, such as neovascularisation, giant papillary conjunctivitis, and punctate staining, in 70% of the cases (Yeung & Weissman 1997). Considering these facts, it seems reasonable to aim for surgical management of lens ectopia, including primary IOL implantation in the capsular bag, in pediatric cases of ectopia lentis.

2 MARFAN SYNDROME

2.1 INTRODUCTION

Marfan syndrome (MFS) is an autosomal dominant genetic condition, which affects both sexes equally, and has no ethnic predilection. The estimated incidence of MFS is 1 per 5,000 (Pyeritz & McKusick 1979), and about 20% of the cases are de novo mutations, without affected parents. MFS affects mainly the musculoskeletal, ocular and the cardiovascular organ systems. Also skin and integuments, lungs and dura are affected. The syndrome shows high genetic penetrance, but great inter- and intrafamilial variability of symptoms. Since the diagnosis is to a great extent based on clinical findings, the clinical variability makes the diagnostics of MFS challenging. Other major problems are that the typical manifestations become more apparent with age, high degree of de novo mutations, and clinical overlap with several other conditions.

Professor A. Marfan was a French paediatrician, who lived in the late 19th century, was the first to describe skeletal abnormalities associated with ‘arachnodactyly’ (spider-like fingers) in a 5-year old girl. Since then, other specific manifestations related to the skeletal changes have been found, mainly ocular (ectopia lentis) and cardiac changes with aortic root dilatation and rupture, as well as mitral valve prolaps.

MFS may be diagnosed at all ages. The four most important reasons for referral to rule out MFS are family history of MFS, ectopia lentis and a variety of cardiac and skeletal manifestations associated with MFS (Hamod et al. 2003). The median age at diagnosis in children (0-18 years) is 6.5 years (Faivre et al. 2009).

2.2 MOLECULAR GENETICS AND PATHOPHYSIOLOGY

In 1991, mutations in fibrillin 1 (FBN1) gene, located in chromosome 15, were demonstrated as a cause for MFS (Dietz et al. 1991). This was a breakthrough in MFS diagnostics, since for the first time a specific location for genetic mutations could be associated to MFS. At the beginning, FBN1 mutations were demonstrated only in a minority of patients. It was subsequently shown that the frequency of finding FBN1 was significantly higher in classic MFS (73%), but low in patients referred for analysis when having possible MFS (14%) (Stheneur et al. 2009). These results implicate the importance of using the clinical (Ghent) criteria as a tool for determining, which patients should be genetically analyzed for FBN1 mutations. Faivre et al., who studied a group of probands with a known FBN1 mutation, further analyzed this. They showed that when the clinical signs were used as a base for the diagnosis, also the number of patients with mutations in FBN1 gene increased (Faivre et al. 2008). When only clinical signs for MFS were used, 79% of the adults were diagnosed with MFS, but when the FBN1 mutation was included in the criteria, 90% fulfilled the international criteria. The corresponding figures for children were 56% and 85%, with increasing figures in the older groups, indicating the progressive nature of the clinical signs (Faivre et al. 2009).

By now, over 500 different mutations in FBN1 gene have been found and almost all of them are unique for the affected individual or family. This may partly explain the great variation in the clinical signs (Boileau et al. 2005). Even mutations in the transforming growth factor receptor 2 (TGFBR2) gene have been shown in some cases of MFS (Mizuguchi et al. 2004; Attias et al. 2009). The molecular biology methods have improved through the years, and they have become less expensive. Therefore, now more patients can be tested with these methods.

Interestingly, it seems that there is a great inter- and intrafamilial variability in the spectrum of clinical signs, including risk for aortic complications, even within families with the same mutation. This could be explained by the two main hypotheses on how the FBN1 mutations disturb the normal function of fibrillin-1:

- **Dominant-negative effect**, which is considered the most likely. According to this hypothesis, the mutate proteins perturb the function of the polymerized fibrillin-1. This is supported by the observation that the amount of fibrillin-1 in MFS is lower than expected if only one allele was functioning normally (Hollister et al. 1990).

- **Haploinsufficiency**, according to which the abnormal protein is not produced, or is rapidly degraded. If this hypothesis is shown most likely, it could open for a new therapeutic method by boosting the fibrillin-1 production (Judge et al. 2004).

In addition, some studies show that fibrillin-1 could, besides the structural effect on extracellular matrix, also affect the TGF- β signalling pathway (Neptune et al. 2003; Ng et al. 2004). This assumption seems logic, since fibrillin-1 contains TGF- β binding protein-like domains. TGF- β is a growth factor, which is bound in a latent form in the microfibrils. TGF- β has been shown present in excessive amounts in aneurysms of ascending aorta (Borges et al. 2010). When released from microfibrils by, for example, tissue injury, TGF- β is activated, stimulating the release of extracellular matrix proteins and antiproteases, including matrix metalloproteinases (MMPs), and it thereby activates tissue repair. The abundance and activity of MMPs have been shown to be associated to thoracic aortic aneurysms (TAA) in a number of studies (Barbour et al. 2007). This could be the pathomechanism behind aortic complications in MFS. The pathology of aortic aneurysm is caused by degradation of extracellular matrix in the aortic wall, which leads to decreased resistance against the blood pressure. These changes are similar in MFS and in other genetic, as well as non-genetic aetiologies, but occur at younger age in MFS, often around 40 years.

2.3 CLINICAL SIGNS AND DIAGNOSTIC CRITERIA

The view on MFS has evolved since it was first described. Great efforts have been made by groups of experts, in order to systematize the diagnostic criteria for MFS (Beighton et al. 1988; De Paepe et al. 1996; Loeys et al. 2010) The first consensus of the clinical criteria (Berlin criteria) (Beighton et al. 1988) was felt needed to facilitate communication about MFS between clinicians, patients and researchers.

However, since the recognition of the mutation in FBN1 gene as a cause for MFS (Dietz et al. 1991), it became obvious that the Berlin nosology allowed falsely the diagnosis for MFS in individuals with family history of MFS, with unspecific connective tissue manifestations, but no genetic changes found in family members more affected by MFS. Therefore, the diagnostic criteria were up-dated, now including the mutations in FBN1 gene as part of the criteria (Ghent nosology) (De Paepe et al.

1996). The Ghent nosology served as a better tool for over-diagnosing of MFS and made it easier to differentiate MFS from other Marfan-like disorders, such as the myopia, mitral valve prolaps, borderline and non-progressive aortic root enlargement, skeletal findings and striae syndrome (MASS), and mitral valve prolaps syndrome (MVPS).

The Ghent criteria used a combination of major and minor clinical criteria in basically all organ systems: skeletal, ocular, cardiovascular and pulmonary, as well as in dura, skin and integument (De Paepe et al. 1996). The major criteria include ectopia lentis, aortic root dilatation/dissection, dural ectasia and at least 4 of the skeletal manifestations. In an index case, without family history of MFS, two major criteria and at least one minor criterion are needed for diagnosis. In case of typical FBN1 mutation, or a family member fulfilling the clinical criteria according to Ghent criteria, only one major and one minor criterion are required. The Ghent criteria served as a clinical tool for MFS diagnostics for many years. It has been shown that FBN1 mutations can be found in up to 91% of the cases of MFS fulfilling the Ghent criteria from 1996, which is an indication of high specificity in diagnosing MFS (Loeys et al. 2001; Loeys et al. 2004). This specificity is, however, associated to adult populations, and does not take into account the natural age-dependent variation of some clinical findings. It is therefore not fully applicable in children (Faivre et al. 2009). The practical use of the criteria has also shown that the clinical criteria were not entirely validated with threshold values for the required signs, or necessitated expensive and specialized investigations.

Therefore, the criteria were recently up-dated, with an emphasis on the two cardinal signs for MFS: aortic root aneurysm and ectopia lentis (Loeys et al. 2010). These new criteria are based on large patient cohorts, including clinical and molecular biological investigations on individuals with MFS and other fibrillinopathies (Loeys et al. 2001; Loeys et al. 2004; Faivre et al. 2007; Faivre et al. 2008). They now underline the importance of genetic testing of FBN1 and other relevant genes causing Marfan-like phenotype. Further, some clinical signs with less specificity for MFS were removed or made less influential in the total diagnostic evaluation.

The main diagnostic criteria for MFS are, in the absence of family history: aortic root dilatation/dissection, in combination with EL, FBN 1 mutation or systemic score (≥ 7 points). In the presence of family history, the presence of either EL, systemic score (≥ 7 points), or aortic root dilatation/dissection, gives the diagnosis. For the systemic scoring, see Table 1.

Wrist AND thumb sign – 3 (wrist OR thumb sign – 1)
 Pectus carinatum deformity – 2 (pectus excavatum or chest asymmetry – 1)
 Hindfoot deformity – 2 (plain pes planus – 1)
 Pneumothorax – 2
 Dural ectasia – 2
 Protrusio acetabuli – 2
 Reduced US/LS AND increased arm/height AND no severe scoliosis – 1
 Scoliosis or thoracolumbar kyphosis – 1
 Reduced elbow extension – 1
 Facial features (3/5) – 1 (dolichocephaly, enophthalmos, downslanting palpebral fissures, malar hypoplasia, retrognathia)
 Skin striae – 1
 Myopia > 3 diopters - 1
 Mitral valve prolapse (all types) – 1

Maximum total: 20 points; score ≥ 7 indicates systemic involvement; US/LS, upper segment/lower segment ratio.

Table 1. Scoring of systemic features (Reproduced from Loeys et al: Revised Ghent criteria (Loeys et al. 2010))

2.4 OCULAR SIGNS

2.4.1 Ocular diagnostic criteria

The importance of ectopia lentis in diagnosing MFS has been undisputable ever since MFS was described. However, other ocular criteria in MFS have evolved together with the systemic criteria. In the Berlin nosology from 1988 (Beighton et al. 1988), ectopia lentis is described as a major feature, whereas flat cornea, elongated globe, retinal detachment and myopia are mentioned as minor features.

In the Ghent criteria from 1996 (De Paepe et al. 1996), the clinical criteria are defined as major and minor and ectopia lentis is solely defined as a major ocular criterion for MFS. The minor ocular criteria include

- abnormally flat cornea (as measured by keratometry)
- increased axial length (as measured by ultrasound)
- hypoplastic iris or hypoplastic ciliary muscle causing decreased miosis

Since the clinical practice showed subsequently that these criteria were inadequately defined, and no threshold values were included in the criteria, they were difficult to use. Therefore, in the revised criteria from 2010, an extra emphasis is given for ectopia lentis in the diagnosis, in line with FBN1 mutation and aortic root enlargement/dissection.

Besides ectopia lentis, high myopia is regarded as the most prominent ocular feature in MFS. It also shows early onset, high severity and rapid progression. Therefore, myopia >3D is now included in the systemic features in MFS. Corneal flattening and increased axial length are now considered having unclear specificity and not being routinely measured by ophthalmologists. These features have therefore been removed from the ocular criteria.

2.4.2 Lens

The crystalline lens is typically subluxated upwards and temporally in MFS, but other directions may occur (Maumenee 1981). It is usually bilateral and symmetric, and seen in approximately 60% of the patients (Maumenee 1981; Sultan et al. 2002). In order to detect ectopia lentis, the eyes should be examined in the slit lamp after maximal dilatation. The main patient complaints in ectopia lentis are blurred vision and monocular diplopia caused by progressive lens subluxation and following astigmatism. Clinical findings include irido-phakodonesis and irregular astigmatism.

The reasons for the typical superotemporal subluxation, and the progressive subluxation with age, are not clear. An interesting theory has been proposed by Sachdev et al., who showed zonule-associated staining of MMPs in Marfan syndrome (Sachdev et al. 2002). Since defect fibrillin in MFS is believed to be more susceptible for proteolysis, MMPs are believed to be involved in the degradation of zonules. It has also been proposed that the UV-B light is mainly focused on the inferonasal portion of the cornea (Coroneo 1993; Narayanan et al. 1996), which could lead to increased UV-B light exposure also in the inferonasal zonules. In the skin, UV-B has been shown to decrease fibrillin messenger RNA exposure (Werth et al. 1997). Considering these facts together, it seems plausible to assume that the inferonasal zonules, which are more exposed to UV-B light throughout life, would have decreased production of fibrillin, and the defect fibrillin would be the first to break.

Due to ectopia lentis, cataract is seen at a younger age in MFS than in the general population. These cataracts are often posterior capsular opacities, or localized cortical opacities (Nemet et al. 2006).

2.4.3 Refraction

High myopia and astigmatism in MFS are caused by the same factors as described for ectopia lentis in general (1.5.1). Furthermore, in Marfan syndrome (MFS), the axial length is increased, contributing to additional myopia (Maumenee 1981; Setala et al. 1988). The increased axial length could be explained by the abnormal microfibrils in the connective tissue of sclera and cornea (Wheatley et al. 1995).

2.4.4 Cornea

Abnormally flat cornea in MFS has been reported for many years (Maumenee 1981; Sultan et al. 2002; Heur et al. 2008). This feature was previously included as a minor criteria for MFS, but has now been removed (Beighton et al. 1988; De Paepe et al. 1996). Interestingly, in these flat corneas, also high corneal astigmatism is common. Furthermore, both cornea and sclera are thinned in MFS (Heur et al. 2008). Unlike the traditional conception of the connection between MFS and keratoconus, no studies have shown a connection between these two conditions (Maumenee 1981; Heur et al. 2008).

The reasons for corneal flattening are unknown. One hypothesis is that both corneal flattening and thinning are secondary to general enlargement of the globe in MFS. It could also be a primary corneal pathology, due to weakness in the corneal fibrillin. This hypothesis is supported by the fact that in immunohistochemical staining,

fibrillin is detected in the basement membrane region of the corneal epithelium, where a dense band of fibrillin is seen between the corneal epithelium and Bowman's membrane (Wheatley et al. 1995). Fibrillin is seen mostly in the periphery of the cornea, and only scarcely in the central areas. Only minor fibrillin staining has been seen in the stroma, and it was localized to the spaces between the collagen lamellae. No fibrillin staining has been detected in the Descemet's membrane or the corneal endothelium. Since microfibrils might be a part of the anchoring system at the epithelial-mesenchymal basement membrane interface, the defects in the microfibrils could have a negative effect on the support of the corneal structure (Sultan et al. 2002).

Significant endothelial guttata-formation, cell pleomorphism, central black spots and in some cases abnormal endothelial cells have been seen in the cornea of MFS patients (Setala et al. 1988; Iordanidou et al. 2007). These features were most prominent in MFS eyes with ectopia lentis. No abnormal endothelial cell density has, however, been shown in MFS (Setala et al. 1988).

Megalocornea is a nonprogressive enlargement of the cornea to 13 mm or greater. The enlarged ciliary ring causes zonular stretching leading to phakodonesis, ectopia lentis, iridodonesis, iris stromal hypoplasia and transillumination defects (Nemet et al. 2006). In the context of MFS megalocornea is mainly associated to the neonatal form of MFS.

2.4.5 Iris

The iris sphincter and dilator muscles in MFS are typically poorly developed, which have been reported to cause eccentric and poorly dilated pupils, when pharmacological pupil dilating drops were used (Maumenee 1981). The crypts of the anterior iris surface are also frequently absent (Nemet et al. 2006).

2.5 MEDICAL THERAPY

The demonstration of the connection between the TGF- β signalling pathway and MFS has changed the view on MFS from a structural disease towards a functional one. This opens for new therapeutic strategies, which could have life-saving effects on MFS patients. While β -adrenergic receptor blockers are the standard medical treatment today for MFS patients in need for prevention and delaying aortic aneurysm, it now seems that losartan could be the drug of choice in the future. Losartan is mainly used for its hemodynamic effects in treatment of hypertension, as it lowers the arterial pressure. It has been shown in mouse models of MFS that losartan prevented aortic-root enlargement and improved aortic wall structure by remodelling it (Habashi et al. 2006). Losartan has also shown effects outside the vascular system, in preventing emphysema and myopathy associated to MFS. Human studies have already been started (Lacro et al. 2007; Radonic et al. 2010). If it is shown that losartan also works in regulating TGF- β activity in humans, this could be a welcomed improvement in the medical treatment of MFS. Also TGF- β antibodies have shown effect in mouse models, but their effect in humans remains unknown until further studied.

2.6 MORTALITY

The mortality rates previously connected to MFS have been related mainly to the cardiovascular complications. The primary life-threatening complication in MFS is rupture of an aortic aneurysm. Besides being an important diagnostic factor, the aortic root diameter is one of the most important predicting factors for aortic dissection and rupture. Aortic root diameter > 50 mm is associated with a markedly increased risk of aortic rupture, and this diameter is considered an indication for surgical repair (Roman et al. 1993; Legget et al. 1996).

In a study done in the early 1970's, before the development of aortic surgery, the life expectancy of MFS patients was significantly shortened (Murdoch et al. 1972). In that study, the median (50%) cumulative probability of survival in MFS was 48 years, and the mean age at death was 32 years. The cardiovascular complications were the cause of death in > 90% of the cases, with aortic rupture accounting for 80% of the deaths.

About 30 years later, the median (50%) cumulative probability of survival was reported considerably better, 72 years, and the mean age at death was 41 years (Silverman et al. 1995). Also the life expectancy after aortic root surgery was reported higher, 61 years, than the total life expectancy in 1972 (Finkbohner et al. 1995). The improvement of life expectancy could be explained by several factors: overall improvement in population life expectancy, developments in cardiovascular surgery, greater proportion of milder cases due to improved diagnostics, and medical treatment including β -blockers.

2.7 NEONATAL MFS

Neonatal MFS (nMFS) is a special form of MFS, which represents the most serious type of clinical manifestations of MFS. The mutations are typically clustered in a specific part of the FBN1 gene (exons 23-32), and basically all reported cases are de novo mutations (Putnam et al. 1996). Neonatal MFS carries the same clinical characteristics as classic MFS, with the addition of congenital flexion contractures, characteristic 'aged-appearance' of the face, megalocornea, ectopia lentis and crumpled ears (Morse et al. 1990; Booms et al. 1999). This form of MFS is associated with high mortality, often within the first months of life. This is due to serious cardiovascular complications, including ascending aorta dilatation, cardiac valve prolaps and following congestive heart failure at young age being the rule (Morse et al. 1990; Booms et al. 1999; Faivre et al. 2009).

3 GENERAL AIMS

1. To study the visual outcomes in children who had had surgery for ectopia lentis including scleral fixated capsular tension ring (CTR) and implantation of an intraocular lens (IOL) in the primary surgery, and to study complications associated to this type of surgery (paper I).
2. To compare the changes in the anterior segment during accommodation and cycloplegia in eyes predisposed to ectopia lentis (Marfan syndrome) and controls measured with optical coherence tomography (OCT) (paper II).
3. To compare the corneal curvature, thickness and endothelial cell density in eyes predisposed to ectopia lentis (Marfan syndrome) and controls (paper III).
4. To describe the ocular characteristics of eyes predisposed to ectopia lentis (Marfan syndrome) (paper IV).

4 MATERIAL AND METHODS

4.1 PAPER I

4.1.1 Patients and methods

Patients in paper I were recruited by a search in the patient charts at St. Erik Eye Hospital, Stockholm, Sweden. Children, who had had surgery with a scleral fixated capsular tension ring (CTR) and primary intraocular lens (IOL) implantation for congenital ectopia lentis at St. Erik Eye Hospital, Stockholm, Sweden, between the years 2000 and 2005, were included.

The patients were in many cases from outside Stockholm. The first postoperative follow-up was done by the surgeon on the first postoperative day. Thereafter the patients were followed up at their home clinics. The records of the visits until February 2006 were sent from the home clinics. The pre- and postoperatively best best-corrected visual acuity (BCVA) and complications were recorded.

4.2 PAPER II

4.2.1 Study design

The participants with Marfan syndrome in paper II were recruited in cooperation with the departments of Cardiology, and Clinical Genetics, at the Karolinska University Hospital, Stockholm, Sweden. One hundred letters were sent to possible study candidates with MFS. Affected family members were also invited to participate. The study candidates were asked to contact the study group, if interested in participating in the study. Fifty-six candidates contacted us. The MFS group was compared to unaffected controls matched for age and refractive sphere. They were recruited among the hospital staff at St. Erik Eye Hospital, and their families.

The parent or guardian of each child provided a signed informed consent form agreeing to participate in the study. Approval for this study was obtained from the local ethics committee.

4.2.2 Inclusion/exclusion criteria

The inclusion criteria were diagnosis of MFS based on the Ghent criteria, and age 12 years or older to avoid participants without fully developed visual acuity (VA). A best-corrected logarithm of the minimum angle of resolution (logMAR) visual acuity of 0.3 or better was required, in order to ensure good focusing on the fixation point in the Visante OCT. The most myopic eye of each participant was included. Cases with suspected, but unverified diagnosis with MFS, or previous corneal/intraocular surgery were excluded.

4.2.3 Method

Prior to the examination with OCT, best spectacle-corrected visual acuity (BSCVA) and manifest refraction were measured. The eyes were also examined in slit-lamp,

before administering cycloplegic eye drops, and in full dilatation/cycloplegia. The eyes were scanned with OCT at baseline, during accommodation and dilatation. The anterior chamber depth (ACD), pupil size and lens thickness were then measured in millimeters. The MFS eyes were compared to the controls. Subsequently, the MFS eyes with subluxation were compared to those without subluxation.

4.2.4 Optical coherence tomography

Optical coherence tomography (OCT), with 820-nm wavelength, is a well-known device for imaging the posterior segment of the eye (Huang et al. 1991). OCT for imaging of the anterior segment of the eye was introduced in 2001 (Radhakrishnan et al. 2001). It is a real-time imaging device using 1310-nm wavelength light, which does not include any contact with the surface of the eye (Figure 6). It suits well for imaging of the cornea, sclera, iris stroma and pigment epithelium, anterior chamber angle, and anterior surface of the lens, even through an opaque cornea. Since the light waves are blocked by pigment epithelium in the iris, the ciliary body and the equator of the lens are not visible when using OCT. However, as we show in paper II, even the posterior surface of the lens is visible with OCT.

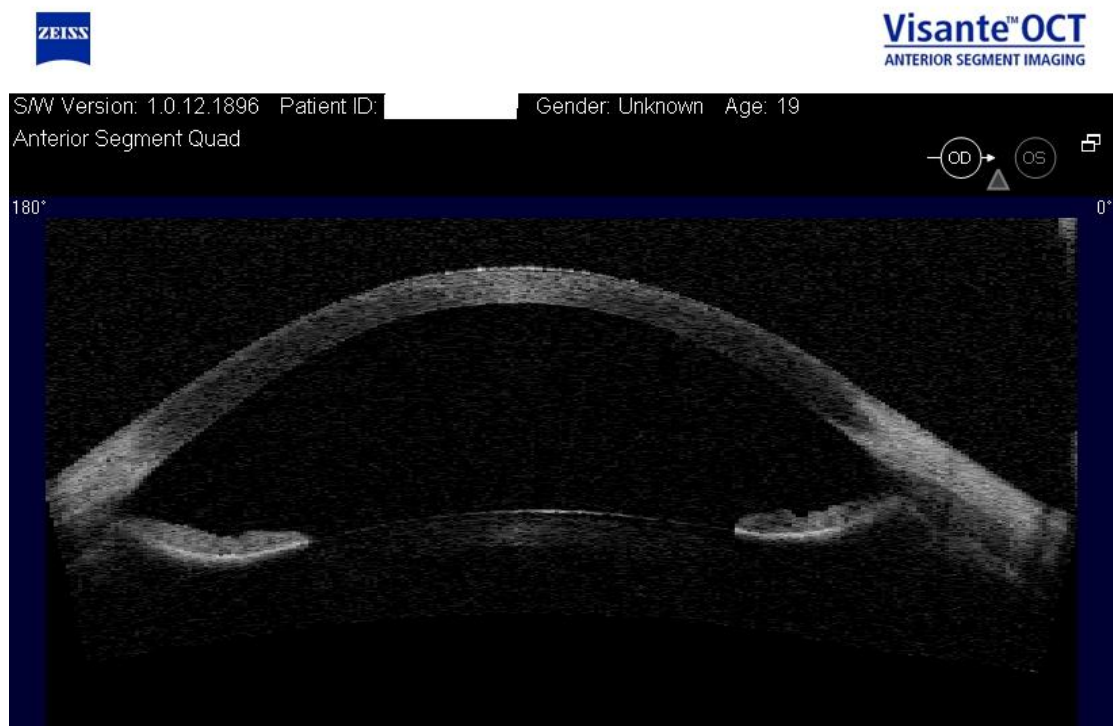

Figure 6. The anterior segment of a 19-year old male with Marfan syndrome, imaged with OCT.

The fixation target in OCT can be focused with adding positive or negative lenses with a simple press of a button, to correct for any spherical ametropia the subject may have, and to produce imaging of the unaccommodated eye. The target may also be defocused adding negative lens power, in order to stimulate accommodation. As the eye accommodates, the pupil size is decreased, the anterior surface of the lens is pushed forward and the anterior chamber depth is decreased. These changes during accommodation may be observed and imaged in real time with OCT.

Anterior segment OCT has shown to be a user-friendly instrument, with good repeatability and reproducibility (Muscat et al. 2002; Baikoff et al. 2004; Fine et al. 2007). It has been used in various diagnosis of the anterior segment, for instance in diagnostics of glaucoma (Ursea & Silverman 2010) and in refractive surgery (Baikoff et al. 2005; Lai et al. 2006; Koivula & Kugelberg 2007). In our study on accommodation, Visante OCT (*Carl Zeiss, Jena, Germany*) was used.

4.2.5 Statistical Analysis

Statistical analyses were performed using the Student's t-test. A *P* value of less than 0.05 was considered statistically significant.

4.3 PAPER III

4.3.1 Study design

The same as for paper II.

4.3.2 Inclusion/exclusion criteria

The same as for paper II, but without limitation on VA.

4.3.3 Method

Prior to the corneal examination, best spectacle-corrected visual acuity (BSCVA) and manifest refraction were measured. The eyes were then scanned with Orbscan II Segment Analyzer. The corneal curvature and thickness at the thinnest point were measured in micrometers (μm). The endothelial cell layer was imaged using Topcon IMAGENet-640, and the ECD in cells per mm^2 was assessed using a semi-automated method. The eyes were also examined in slit-lamp, before administrating cycloplegic eye drops, and in full dilatation/cycloplegia. The MFS eyes were compared to the controls. Subsequently, the MFS eyes with subluxation were compared to those without subluxation.

4.3.4 Orbscan II Segment Analyzer

The first Orbscan (Bausch & Lomb Inc., Rochester, NY, USA) corneal topography using slitscanning technique was introduced in 1995. This device was later enhanced to Orbscan II Segment Analyzer, which is a corneal topography system using a combination of slitscanning and placido technique (Swartz et al. 2007). It analyzes the anterior and posterior edge of the light slits, and creates a three-dimensional map of the cornea using the two-dimensional images. The maps present elevation and curvature of both anterior and posterior surfaces the cornea, as well as corneal thickness. Orbscan II has shown good accuracy of measurement (Cairns et al. 2002; Gonzalez Perez et al. 2004), and is widely used in healthy populations (Wei et al. 2006), diagnostics of

corneal diseases (e.g. keratoconus) (Lim et al. 2007), and is today an essential part of planning for refractive surgery.

4.3.5 Statistical Analysis

Statistical analyses were performed using the Student's t-test for most parameters. The Mann Whitney U test was applied for sphere since the data were not normally distributed. For cross tabulations, the chi-square test or the two-tailed Fisher's exact test was used. A *P* value of less than 0.05 was considered statistically significant. Odds Ratio (OR) for some suggested diagnostic values in corneal changes and their association with MFS were also calculated.

4.4 PAPER IV

4.4.1 Study design

The same as for paper II. However, since this was a descriptive study, no control group was used.

4.4.2 Inclusion/exclusion criteria

The same as for paper II. However, both eyes of each participant were included, and there was no limitation on VA.

4.4.3 Method

At first, the best spectacle-corrected visual acuity (BSCVA) and manifest refraction were measured. The eyes were then scanned with IOLMaster, and the axial bulb length was noted. The eyes were also examined in slit-lamp, before administrating cycloplegic eye drops, and in full dilatation/cycloplegia. Full ophthalmologic history, including previous ocular surgery, was obtained from the participants.

4.4.4 Statistical Analysis

Since study IV was an investigative observational analysis, no comparative analyses were performed. However, a descriptive statistical analysis was performed.

5 RESULTS AND DISCUSSION

5.1 PAPER I

5.1.1 Patient data

In this retrospective study, 37 eyes of 22 children with a median age of 52 months (range, 17 to 131 months) at the time of primary surgery were included. The median follow-up time was 27 months (range, 1 to 59 months). Six patients were diagnosed with Marfan syndrome. Other etiologies included familial lens dislocation (2 patients), spherophakia (2), and idiopathic lens dislocation (12).

5.1.2 Visual outcomes

The visual acuity was measured with several different charts, depending on the maturity of the patient and the local traditions in each clinic. BCVA could be measured preoperatively with a Lea Hyvärinen (LH) chart and letter charts in 22 eyes. The mean BCVA for those eyes was 0.26 decimal (range, 0.015 to 0.65), including one patient tested binocularly (one eye included) (Figure 7).

All patients could be tested for BCVA with LH or letter chart postoperatively. The mean BCVA after (primary or secondary) surgery of 36 eyes was 0.59 (range 0.2 to 1.0), including one patient tested binocularly. All non-amblyopic eyes had a postoperative minimum BCVA of 0.4 (range, 0.4 to 1.0), and three patients with persistent amblyopia had a postoperative BCVA 0.2 to 0.4 at the end of the follow-up.

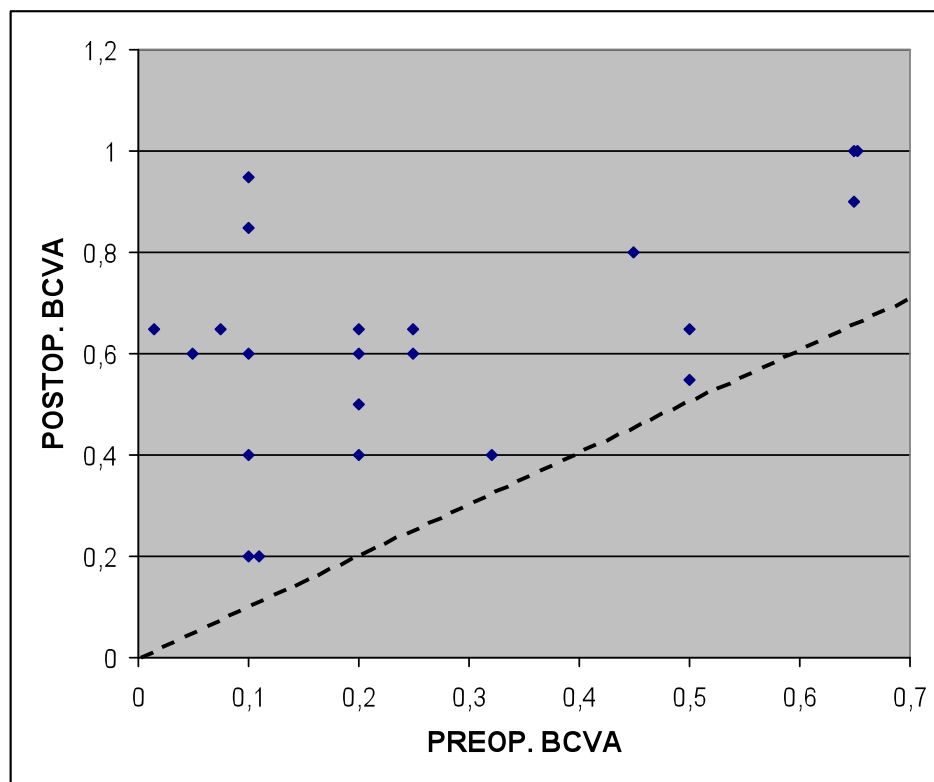


Figure 7. Diagram showing decimal pre- and postoperative best-corrected visual acuity (BCVA) in 21 eyes. The dotted line indicates no change. All squares are above the line indicating improvement in BCVA in all eyes.

Despite the postoperative improvement of visual acuity in nearly all patients, many eyes in this study did not reach full visual acuity. This could be explained by many factors: most importantly, the age by the time of the primary surgery affects the postoperative visual acuity. Early surgery seems to be associated with better visual rehabilitation. Many patients in this series had been treated conservatively for many years, and had already developed amblyopia. Further, the youngest patients were still very young at the end of the follow-up, and the visual acuity could therefore be expected to improve. The follow-up was also in some cases relatively short, and did not show the fully developed post-operative visual acuity in those cases. Finally, some eyes had mild visual axis opacification (VAO), which was not treated during the follow-up time. After treatment for VAO, a better VA could be expected also in those eyes.

Conservative management of ectopia lentis has shown to give poor visual development (Romano et al. 2002). Aphakia, surgical or spontaneous, on the other hand, gives better visual development (Behki et al. 1990; Speedwell & Russell-Eggitt 1995; Shortt et al. 2004), but leaves the patient with a need of great refractive correction, either with spectacles or contact lenses. Considering the high grade of refractive correction needed in the spectacles, and that contact lens related complications are common, primary IOL implantation seems like a good alternative in management of ectopia lentis. This, however, requires good control of the capsular bag during the surgery. Some type of capsular tension device is therefore needed in these cases, preferably a scleral-fixated (Cionni) ring, which does not compromise the integrity of the posterior lens capsule (Ahmed & Crandall 2001). In this paper we show that this intraocular device gives a good visual development in children with congenital EL.

5.1.3 Complications

Thirty-one of the total 37 eyes had VAO. Other complications requiring secondary surgery included resuturing in two eyes, conjunctival discomfort related to the sutures in two eyes, and anterior synechiae in one eye. Six eyes had no reported complications. None of the patients had any serious complication, such as retinal detachment, endophthalmitis, or glaucoma during the follow-up.

The high incidence of VAO in this paper was expected. The lens epithelial cells in children are very lively, and it has been reported that VAO could be highly expected in pediatric eyes operated for cataract, when the surgery is performed without posterior capsulorrhexis (Kugelberg & Zetterstrom 2002). However, posterior capsulorrhexis is difficult to perform in cases of EL, and could risk the stability of the capsular bag. In this paper we found VAO in 84% of the eyes, and a higher number could be expected with a longer follow-up time.

Re-suturing was needed in two cases. The stability of the 10-0 Prolene suture, also used in this paper, has sometimes been questioned. Late IOL dislocations (after 7-14 years) have been reported, and microscopic analysis of the sutures has shown degradation and cracking of the suture material (Price et al. 2005). As few studies on surgery for EL have such a long follow-up time, this complication is rarely reported. Also the cases in this paper could be expected to show a higher number of IOL dislocation with a longer follow-up. Still, both VAO and the suture-related complications are surgically treatable, and give no permanently sight-threatening

consequences. No endophthalmitis, secondary glaucoma or retinal detachment, which have been associated with surgery for EL, was seen in these eyes.

In conclusion, these results show that surgery for congenital EL in children, including a scleral-sutured CTR and primary IOL implantation gives good visual development, and has no serious complications.

5.2 PAPER II

5.2.1 Baseline data

Thirty-one eyes of 31 individuals with Marfan syndrome were included and 31 eyes of 31 unaffected individuals served as the control group. These two groups had a mean age 35.4 years (range, 12.7 - 63.8 years) vs. 34.1 years (11.9 - 61.6 years) ($P=0.74$), and spherical refraction, -3.3 D (-17.5 to +1.5 D) vs. -2.3 D (-10.3 to +2.5 D) ($P=0.30$).

5.2.2 The lens and anterior chamber depth

The accommodative power was defined as the change in the refractive power (spherical equivalent) from baseline to maximal accommodation. In the MFS eyes, the spherical power changed from -3.5 ± 4.0 D (mean \pm standard deviation) at baseline to -10.1 ± 5.0 D in full accommodation, adding to an accommodative power of -6.6 ± 2.2 D. In the control eyes the same results were -2.6 ± 3.2 D, -9.4 ± 4.0 D, and -6.8 ± 2.3 D. None of these differences were statistically significant. Further, no statistically significant difference was found in anterior chamber depth (ACD) at the different stages ($P=0.17-0.21$). In the eyes with MFS, the lens was significantly thicker at baseline, accommodation and dilatation (Table 2).

Lens Thickness (mm)	MFS	Control	Difference (CI 95%)	P Value
Baseline	4.27 \pm 0.56	3.97 \pm 0.38	0.30 (0.06 to 0.54)	0.017*
Accommodation	4.39 \pm 0.49	4.18 \pm 0.30	0.21 (0.007 to 0.42)	0.043*
Dilatation	4.19 \pm 0.58	3.94 \pm 0.38	0.25 (0.004 to 0.50)	0.046*

Table 2. The lens thickness in MFS eyes and controls at baseline, in accommodation and in dilatation, expressed as mean \pm standard deviation.

95% CI= 95% confidence interval of the difference.

* indicates a statistically significant difference.

Even though EL is a well-known feature of MFS, little is known about the accommodation in MFS. To the best of our knowledge, this is the first report on accommodation studied with OCT in MFS. A previous study on accommodation in a normal population showed the same forward movement of the anterior lens surface, and the pupil contraction, as we did in this paper (Baikoff et al. 2004). Histopathologic studies have shown both qualitative and quantitative abnormalities in the fibrillin-

containing structures on the lens surface in MFS eyes (Mir et al. 1998; Traboulsi et al. 2000). A study with ultrasound biomicroscopy has also shown increased lenticular sphericity in areas of zonular abnormalities (Pavlin et al. 1998). In this paper we show significant differences in the lens thickness in MFS compared to controls. This might be explained by decreased tension in the zonular fibers, leading to a more spherical form of the lens in MFS. The increased lens thickness might therefore indicate a partially accommodated state in MFS eyes at baseline, adding lenticular myopia to the axial myopia in MFS.

Schachars theory on accommodation has been previously discussed in this thesis (chapter 1.2). According to this theory, the lens equator becomes flattened and the anterior and posterior lens surfaces steepen during accommodation (Schachar et al. 1996; Schachar 2004; Schachar 2006). This mechanism might even apply for MFS eyes, if the zonules are equally abnormal anterior and posterior of the equator, such as previous histopathologic studies have implied (Mir et al. 1998; Traboulsi et al. 2000). This is, nevertheless, difficult to confirm with OCT, since the light waves to the lens equator are blocked by iris, and does not allow imaging of the outmost part of the lens.

5.2.3 The pupil

The pupil size in the eyes with MFS at baseline was significantly smaller. In the eyes with MFS, the pupil size decreased less during accommodation and increased more during dilatation compared to controls (Table 3).

Pupil Diameter (mm)	MFS	Control	Difference (CI 95%)	P Value
Baseline	4.53±1.30	5.27±0.99	-0.74 (-1.32 to -0.15)	0.01*
Accommodation	3.70±1.17	3.93±0.92	-0.22 (-0.76 to 0.31)	0.40
Dilatation	7.12±0.96	6.90±0.84	0.23 (-0.23 to 0.69)	0.33
Difference from baseline accommodation	-0.83±0.65	-1.34±1.02	0.51 (0.08 to 0.95)	0.02*
Difference from baseline dilatation	2.59±1.04	1.63±0.80	0.96 (0.49 to 1.44)	0.0001*

Table 3. The pupil diameter in MFS eyes and controls at baseline, accommodation and in dilatation, as well as the different between the different stages, expressed as mean ± standard deviation.

CI 95% = 95% confidence interval of the difference.

* indicates a statistically significant difference.

The diagnostic criteria for MFS at the time of this paper (De Paepe et al. 1996) included iris hypoplasia, causing decreased miosis, as a minor ocular criteria for MFS.

Although our results show less change in the pupil size in MFS eyes, the decreased ability for miosis is difficult to confirm only referring to this difference, since the pupils were significantly smaller in MFS eyes at the baseline. This difference at the baseline might also contribute to the increased difference in pupil size from baseline to accommodation, even though it does not seem to explain the whole difference. The iris in MFS could also be more susceptible to pharmacological agents than normal eyes.

Interestingly, we found no significant difference in the accommodative power, ACD, lens thickness or pupil size, between MFS eyes with and without EL. This might implicate that there are subclinical changes in the zonules and iris even before EL becomes visible in a slit lamp examination, and is probably explained by the progressive nature of the connective tissue abnormalities previously shown in MFS. Nevertheless, measured with OCT, there is no difference in the ability of the MFS eyes to accommodate compared to control eyes, which is an indication that the remaining zonules in MFS seem to function in a similar manner than in normal eyes.

5.3 PAPER III

5.3.1 Baseline data

Thirty-nine eyes of 39 individuals with MFS were included. Forty eyes of 40 unaffected individuals served as the control group. The mean age in these groups were 35.9 ± 15.5 years (mean \pm standard deviation (SD)) vs. 36.6 ± 14.5 years ($P=0.83$). The mean spherical refraction was -1.75 D (-17.5 to $+1.5$ D) vs. -1.25 D (-10.3 to $+2.5$ D) ($P=0.18$).

5.3.2 Corneal assessments

The mean keratometric value (K_{med} value) in the MFS eyes was significantly lower than in the control eyes (Table 4). Also, 15 MFS eyes (38%) had a K_{med} value below 41.5 D compared to three (8%) controls, which was significantly different ($P=0.0012$). However, we found no significant difference in the mean K_{med} value between the MFS eyes with and without lens subluxation ($P=0.87$) (Table 5).

	MFS	Controls	<i>P</i> Value (95% CI)
K_{med} (D)	42.2 ± 1.9	43.4 ± 1.4	0.02 (-2.0 to -0.5)*
$K_{max}-K_{min}$ (D)	1.1 ± 0.9	0.8 ± 0.4	0.035 (0.02 to 0.67)*
Corneal thickness (μ m)	485 ± 54.5	514 ± 37.3	0.007 (-49.7 to -8.0)*

Table 4. The K_{med} , corneal astigmatism and corneal thickness in MFS eyes compared to controls, expressed as the mean \pm standard deviation.

95% CI= 95% confidence interval of the difference.

* indicates a statistically significant difference.

	MFS with EL	MFS without EL	<i>P</i> Value (95% CI)
K_{med} (D)	42.2 ± 2.0	42.3 ± 1.8	0.87 (-1.3 to 1.1)
$K_{max}-K_{min}$ (D)	1.6 ± 1.1	0.6 ± 0.3	0.0002 (0.51 to 1.53)*
Corneal thickness (μm)	475 ± 54.8	494 ± 54.1	0.29 (-54.3 to 16.6)

Table 5. The K_{med} , corneal astigmatism and corneal thickness in MFS eyes with and without ectopia lentis (EL), expressed as the mean ± standard deviation.

95% CI= 95% confidence interval of the difference.

* indicates a statistically significant difference.

Abnormally flat cornea was included in the clinical diagnostic criteria for MFS at the time of this paper, even though the threshold value was never well defined. Several previous studies have confirmed this well-known feature, and K values below 41.5 D are commonly seen (Maumenee 1981; Sultan et al. 2002; Heur et al. 2008). This was the case also in this paper. Despite the fact that the corneal curvature no longer is included in the diagnostic criteria for MFS (Loeys et al. 2010), other signs of MFS should be looked for in eyes with very low K values.

MFS eyes had more corneal astigmatism compared to control eyes ($P=0.035$) (Table 4). Further, nine MFS eyes (23%) but only two control eyes (5%) had corneal astigmatism exceeding 1.5 D ($P=0.025$). Interestingly, the same nine MFS eyes also had a subluxated lens. In general, MFS eyes with a subluxated lens had significantly more corneal astigmatism than those without a subluxated lens ($P=0.0002$) (Table 5). The possible connection between corneal astigmatism and EL is unclear. It has been suggested that oblique viewing could cause false measurements of corneal astigmatism, and that an ectopic lens could be comparable to oblique viewing. However, a previous study on refractive changes measured due to oblique viewing, showed insignificant changes on the total refraction, as well as astigmatism or higher grade of aberrations (Radhakrishnan & Charman 2007). We therefore hypothesized that the eyes with EL also have structural defects in the cornea, causing corneal astigmatism.

Keratoconus has sometimes been connected to MFS, but to the best of our knowledge, this has never been reported in a clinical study. In this paper, all the Orbscan images were analyzed carefully, and no MFS or control eyes had keratoconus, despite of high corneal astigmatism.

The mean corneal thickness at the thinnest point was significantly decreased in MFS eyes compared to control eyes (Table 4). The number of MFS eyes with very thin corneas (with corneal thickness below 500 μm) was significantly higher than in the control eyes, 24 MFS eyes (62%) vs. 10 control eyes (25%) ($P=0.01$). However, the difference in the mean corneal thickness between the MFS eyes with and without a subluxated lens was not statistically significant (Table 5). Thirteen MFS eyes with a subluxated lens (72%) and 11 MFS eyes without a subluxated lens (52%) had corneal thickness below 500 μm at the thinnest point ($P=0.32$). All eyes with thin corneas in this paper had generally thin corneas, and no local thinning, as is the case in keratoconus. Some previous studies on corneal changes in MFS did not show corneal

thinning (Maumenee 1981; Setala et al. 1988), whereas the more recent ones report the same corneal thinning as we did (Sultan et al. 2002; Heur et al. 2008). This could be due to more accurate instruments used today.

No significant difference in ECD was found between the MFS eyes and control eyes ($P=0.66$). In addition, there was no significant difference in the ECD between MFS eyes with and without a subluxated lens ($P=0.22$). This is equal to a previous report by Setala et al. (Setala et al. 1988). Even though MFS does not seem to affect the ECD, alterations in the endothelial morphology have been reported in MFS eyes (Setala et al. 1988; Iordanidou et al. 2007).

We found no statistically significant difference in K_{med} or in corneal thickness between MFS eyes with and without EL. This indicates that these changes are typical of MFS in general, and not specifically associated to EL.

5.4 PAPER IV

5.4.1 Ocular characteristics

One hundred and two eyes of 51 individuals were included (23 males, 28 females). The mean age among the participants was 39.0 years (range, 12.7-71.6 years).

Thirty-one eyes (30%) of 16 participants had EL, and 12 eyes (12%) of eight participants had signs of cataract at the time of the study. Nine eyes (9%) of nine participants had a history of strabismus, two of whom underwent surgery in one eye. Three eyes (3%) of three participants had amblyopia, all of whom had EL and two of who also had strabismus. Four eyes (4%) of three participants underwent surgery for a retinal detachment (RD); two of these eyes were blind and had a history of both a surgically dislocated lens and RD. Five eyes (5%) of three participants received medical treatment for glaucoma. One eye (1%) had optic nerve atrophy of unclear genesis, with a VA of counting fingers. Twenty-two eyes (22%) of 12 participants did not have any ocular complications. Two eyes were amaurotic and were not studied further.

5.4.2 Phakic eyes

Seventy-seven eyes were phakic. The mean age among these participants was 36.2 years (range, 12.7-71.6 years). The mean BSCVA in the phakic eyes was -0.024 logMAR (range, 0.5 to -0.2 logMAR).

The phakic eyes had a mean spherical refraction of -2.78 D (range, -17.50 to +2.00 D) (Figure 8), -1.36 D of cylinder (range, -5.5 to ± 0 D), and a spherical equivalent of -3.46 D (range, -17.75 to +1.75 D). Four eyes were excluded from computation of this mean value: two eyes in which the subjective refraction could not be determined because of BSCVA less than 1 logMAR, and two eyes which had a spherical refraction +0.5 and +0.75 D due to previous corneal refractive surgery.

The mean AL among the phakic eyes was 24.73 mm (range, 21.59 - 32.75), including 39 eyes (51%) with an elongated AL (≥ 24.5 mm) (Figure 9). The mean K_{med} was 42.2 D (range, 38.7 - 46.9 D). Two eyes were excluded from the computation of the K_{med} due to previous corneal refractive surgery.

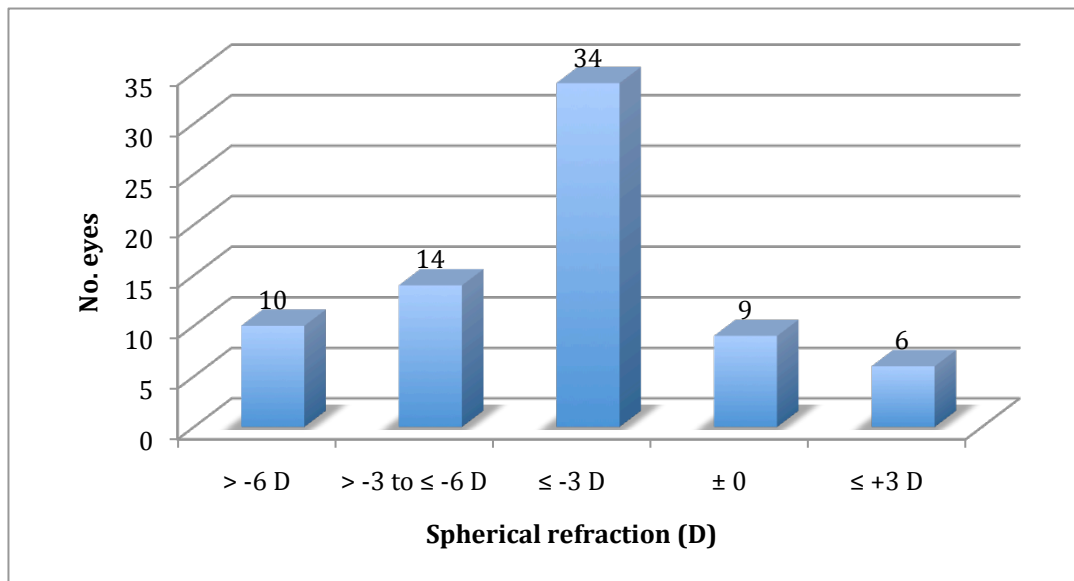


Figure 8. The distribution of the spherical refraction in diopters (D) in phakic eyes with Marfan syndrome.

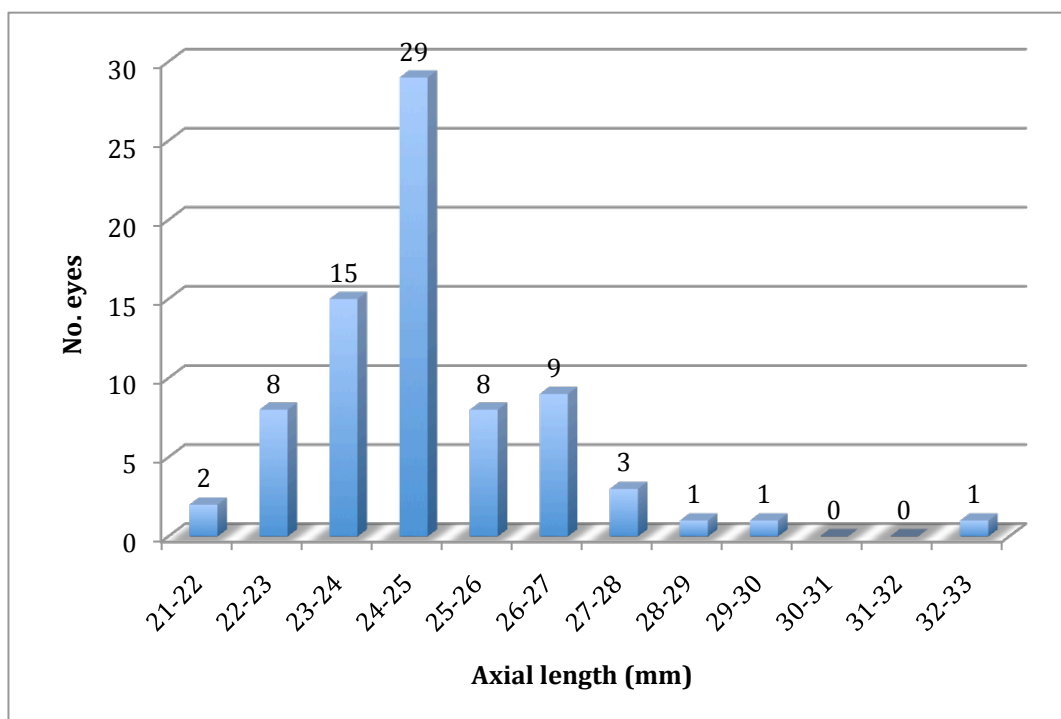


Figure 9. The distribution of the axial length in mm in phakic Marfan eyes.

Of the 77 phakic eyes, 31 eyes (40%) had EL. Twenty-seven of those eyes were myopic (87%). Twelve eyes with EL (39%) had myopia exceeding -3 D. Of the 46 phakic eyes without EL, 33 eyes were myopic (71%). Twelve eyes (26%) had myopia exceeding -3 D.

In eyes with and without EL, no statistically significant difference was seen in the mean spherical refraction ($P=0.44$), spherical equivalent ($P=0.07$), AL

($P=0.76$), K_{\max} ($P=0.67$), K_{\min} ($P=0.11$), or K_{med} ($P=0.56$). An abnormally high AL (≥ 24.5 mm) was seen in 39 of all the 77 phakic eyes (51%); in 17 eyes (55%) with EL, and in 22 eyes (48%) without EL.

However, fifteen eyes (48%) with EL had lens-related astigmatism, defined as a difference by at least 1.0 D in subjective astigmatism compared to corneal astigmatism. In comparison, only four eyes (12%) without visible EL had lens-related astigmatism. Two of those four eyes had ectopia pupillae.

These results confirm the well-known fact that increased axial length is a common feature in MFS. However, only a minor part (36%) of the eyes show high myopia, which would be expected in eyes with high axial length. This could be explained by the flat cornea, which seems to compensate for the total subjective refraction. Further, only 26% of the phakic eyes without EL showed myopia exceeding 3.0 D. This means that only about one fourth of the MFS eyes without EL fill the current ocular diagnostic criteria for MFS. This increases the risk of misdiagnosing patients with MFS in suspected cases. Therefore, we suggest that also corneal curvature and AL should be measured and evaluated in the cases of suspected MFS without visible signs of EL.

5.4.3 Aphakic eyes

Five eyes were aphakic. The mean age among the participants with aphakic eyes was 57.3 years (range, 50.9 - 63.2 years). Four of these lenses were surgically dislocated into the vitreous during the 1950's when two of the patients were children. Two of these lenses were later extracted, one due to vitritis and the other one due to RD. In one of the five aphakic eyes, the lens was primarily extracted during the 1970's. Three of these eyes had a BSCVA of 0.1 logMAR, and two were amaurotic. Both of the amaurotic eyes had had surgical dislocation of the lenses, and one of the lenses was later extracted. Both eyes also had a history of a RD.

5.4.4 Pseudophakic eyes

Twenty eyes were pseudophakic. The mean age among the pseudophakic participants was 48.0 years (range, 17.0 - 71.6 years). Seventeen of those underwent surgery primarily because of EL, two eyes because of a combination of EL and cataract, and one eye because of cataract. Twelve eyes had a sutured posterior chamber intraocular lens (IOL). Six eyes had an IOL implanted in the capsular bag. Two eyes had an anterior chamber IOL. One eye had undergone surgery for a RD years after the lens surgery. The pseudophakic eyes had in general good visual acuity: the mean BSCVA was 0.15 logMAR (range, 0.8 to -0.1 logMAR).

Our results showed current EL or history of EL in 55 of 102 eyes (54%). The frequency of EL in previous reports varies from 60% (Maumenee 1981) to 89% (Sultan et al. 2002). The ectopic lens causes a great deal of lenticular astigmatism, which could be explained by either tilting of the lens or displacement of the center of the lens from the optical axis. Also, as we have shown in paper II, the lens is thicker in MFS compared to controls in a non-accommodated state, which could indicate a partly accommodated state at baseline. This is probably explained by decreased zonular tension, which could further contribute to myopia.

The mean age in the pseudophakic eyes in this paper was 48 years. This could be compared to a mean age of 75 years in patients who had cataract surgery in a normal population (Behndig et al. 2011). Most of the participants in this paper had had lens surgery mainly due to EL, but cataract is over-represented in eyes with EL, and could be expected at a younger age than in normal population.

The age difference between the subgroups (phakic, pseudophakic and aphakic) eyes is partly an indication of the progressive nature of EL. The younger participants were still phakic, though many showed signs of EL. At the same time, it is an indicator of the evolution in the surgical techniques in managing EL. The aphakic participants were middle-aged and had had their lenses surgically extracted or dislocated during childhood, but no IOL was implanted in the primary surgery. This had led to a poor visual development in some cases. On the other hand, the participants that had had surgery in the recent years had all received an IOL.

The risk of retinal detachment (RD) has previously kept the ocular surgeons away from the eyes with EL as long as possible. The incidence of RD reported in this paper was 4%. This could be compared to an incidence of 10% reported previously (Maumenee 1981). The risk of RD in MFS could be due to increased AL, previous intraocular surgery, EL causing vitreous traction, or a combination of these factors. However, it seems that RD in MFS eyes is managed better today, independently of whether the eyes is phakic or aphakic (Loewenstein et al. 2000). All pseudophakic eyes in this paper underwent surgery before 2000, and only one of them had a history of RD postoperatively. This could indicate that the techniques of lens surgery have improved, and that the risk of RD is therefore not significantly increased in eyes operated for EL.

In the updated diagnostic criteria for MFS, EL is included as one of the main criteria for MFS. When EL is not present, a myopia exceeding 3.0 D is used as a diagnostic factor. Our results show that only a minor part of the MFS eyes without EL have a total refraction exceeding this value, and it seems that both increased bulb length and flattened cornea affect the subjective refraction, though in opposite directions. We suggest that these factors should be taken into account when examining cases with suspected MFS.

6 MAIN CONCLUSIONS

1. Surgery for congenital ectopia lentis in children, which includes scleral-fixated capsular tension ring and primary implantation of an intraocular lens in the bag, gives good visual outcomes, and has no serious complications.
2. Even though the pupil and crystalline lens are affected in MFS, these lenses seem to accommodate normally. The observed changes in the pupil and lens seem to be connected to MFS itself rather than ectopia lentis.
3. Cornea in MFS is flattened and thinned. High corneal astigmatism is over-represented in MFS, especially in eyes with ectopia lentis. Keratoconus does not seem to be associated to MFS.
4. In addition to ectopia lentis, increased axial length and flattened cornea are typical ocular characteristics in MFS. The flattened cornea may compensate for high myopia, which would otherwise be expected in eyes with ectopic lens and increased axial length.

7 FUTURE PERSPECTIVES

Still today many children with EL are managed conservatively, due to fear of surgical complication. Or, when surgery is performed, lensectomy is performed, with aphakia as a result. As we show in paper I, a scleral-fixated CTR and an IOL implanted in the bag gives good visual rehabilitation in children. This method could be used more widely for correction for EL, allowing more children to get early surgery, and decreasing the risk of amblyopia. In the cohort studied in paper I, the follow-up was not especially long in some cases. Also, many of the patients still were very young, and their visual acuity was not yet fully developed. Therefore, the long-term visual development would be interesting to follow up, as well as the possible long-term complications.

The demonstration of the connection between the TGF- β signalling pathway and MFS has changed the view on MFS from a structural disease towards a functional one. This opens for new therapeutic strategies, which could have life-saving effects on MFS patients. The ongoing treatment studies with losartan on humans seem therefore very interesting, and the future will show, whether this medication, or other treatments for modifying the TGF- β signalling pathway, could have an effect on some of the systemic features in MFS. Could it possibly decrease the risk of aortic root dilatation and dissection, and in the ophthalmological spectrum, stop the development of lens ectopia?

8 SAMMANFATTNING PÅ SVENSKA

Delarbete I

Två av de viktigaste delarna i ögats optiska system är hornhinnan och linsen som samlar inkommande ljusstrålar så att en klar bild skapas på näthinnan. En viktig förutsättning för att en klar bild skapas är att linsen ligger på sin naturliga plats, strax bakom pupillöppningen. Om linsen är snedställd i förhållande till pupillöppningen, påverkas synen negativt. Snedställdhet av linsen orsakar i första hand kraftig närsynthet och astigmatism. Det kan också störa cirkulationen av kammarvätskan inuti ögat och därmed orsaka förhöjt ögontryck med synnervsskada (glaukom). Vidare ger snedställdhet ökad risk för näthinneavlossning. Alla dessa komplikationer är potentiellt synhotande, framför allt hos barn som kan få bestående svagsynthet om inte snedställdhet och dess komplikationer upptäcks och åtgärdas effektivt i tid. Den medicinska term som används för snedställdhet av ögats lins är *ectopia lentis*.

Behandling av snedställda linser har varit omdiskuterat. Kirurgi av snedställda linser har ansetts svårt eftersom linsen sitter mer eller mindre lös. Därför har kirurgi ofta förknippats med allvarliga komplikationer. Samtidigt har flera studier visat att enbart glasögonkorrektur inte ger bra synutveckling hos barn med snedställda linser. De senaste årtiondena har operationsmetoderna förbättrats och komplikationsrisken minskat, framför allt efter introduktion av implantat (s.k. kapselringar) som stabiliserar linsäcken vid ögonkirurgi. Dessa kapselringar läggs in i linsäcken efter att linsens innehåll tömts, varefter en konstgjord lins kan läggas in. De första kapselringarna kom i början av 1990-talet när man introducerade den första typen av kapselring som läggs in i linskapseln för att spänna ut den. Denna typ av kapselring kan användas vid lättare snedställdhet. En nyare typ av kapselring kan sys fast genom ögats vägg för att stabilisera linsäcken vid mera uttalad snedställdhet.

I **delarbete I** studerades synutveckling och komplikationer hos barn som opererats för snedställd lins med en fästsydd kapselring och insättning av en konstgjord lins. Studien omfattade 37 ögon hos 22 barn och visade att alla barn fick bättre synskärpa efter operationen. Den vanligaste komplikationen efter operationen var efterstarr som påvisades i 31 ögon. Av dessa hade 26 blivit behandlade för efterstarr vid studiens slut. Efterstarr efter linskirurgi är förväntat hos barn eftersom linscellerna är mycket livliga hos dem. Inget barn hade dock några allvarliga komplikationer under eller efter den första operationen. Dessa resultat tyder på att denna operationsmetod är trygg för barn och ger bra synutveckling utan svåra komplikationer.

Delarbete II-IV

Medfödd snedställdhet av ögats lins är oftast en del av en ärftlig bindvävssjukdom. Marfans syndrom (MFS) är den vanligaste av dessa. Cirka 70 % av alla med snedställd lins har också MFS. Omkring en av 5000 människor drabbas av MFS statistiskt sett och syndromet är lika vanligt hos män som hos kvinnor bland alla etniska grupper i världen. De huvudsakliga diagnostiska kriterierna är snedställdhet i ögats lins, vidgning av kroppspulsådern och typiska genetiska förändringar. Typiska synliga förändringar vid

MFS är lång och smal kroppsbyggnad med långa (spindellika) fingrar och tår, felställningar i ryggraden eller bröstkorgen och överrörliga leder. Trots att de genetiska diagnostiska metoderna förbättrats genom åren baseras MFS-diagnosen fortfarande mycket på symptomen och fynden i olika organ.

Bindväv finns i många delar av ögat och MFS kan därför drabba ögat på flera olika sätt. Man har i tidigare studier bl.a. konstaterat att hornhinnan är plattare och att ögat är längre än normalt. Linsen är upphängd med tunna elastiska bindvävstrådar, s.k. zonulatrådar, som fäster i en omgivande ringmuskel. Zonulatrådarna fungerar som fjädrarna i en studsatta och ger linsen dess spänst. När ögat fokuserar på nära håll (ackommoderar) drar ringmuskeln ihop sig, trådarna slappnar av och linsen får en rundare form. Därmed förstärks linsens ljusbrytande styrka. När ögat sedan fokuserar på långt håll slappnar ringmuskeln av, zonulatrådarna spänns ut och linsen plattas till. Vid MFS är zonulatrådarna försvagade eller brutna vilket leder till snedställdhet av linsen.

I **delarbete II** studerades hur ackommodation fungerar i ögon med snedställda linser. Studien omfattade 31 ögon hos 31 personer med MFS samt 31 ögon hos 31 friska individer (kontroller). Graden av ackommodation och förändringar i ögats främre delar studerades vid full ackommodation och efter att pupillvidgande ämnen droppats. Vi kunde konstatera att MFS ögon hade lika bra ackommodationsförmåga som friska kontroller samt att linsen vid MFS är tjockare än hos kontrollerna. Man ser alltså påverkan på linsen vid MFS men trots det verkar dessa linser ha bra ackommodationsförmåga. Vi kunde inte påvisa någon skillnad mellan MFS ögon med och utan snedställd lins vilket talar för att dessa förändringar är typiska för MFS och är inte beroende av endast att linsen är lös. Det kan därför antas att även MFS ögon utan påvisad snedställd lins har begynnande svagheter i sina zonulatrådar trots att detta inte kunnat ses vid vanlig ögonundersökning.

I **delarbete III** studerades hornhinnan vid MFS. I studien ingick 39 ögon hos 39 personer med MFS och 40 ögon hos 40 friska kontroller. Vi mätte bl.a. hornhinnans kurvatur och tjocklek och kunde se att hornhinnan är inte bara plattare men också tunnare i MFS ögon än hos kontroller. Det förelåg ingen skillnad mellan MFS ögon med och utan sned lins vilket talar för att också dessa förändringar är typiska för själva MFS, oberoende av snedställd lins. Detta tyder på att avvikande tjocklek och platthet i hornhinnan skulle kunna användas som stöd i diagnostiken av MFS.

I **delarbete IV** beskriver vi ögonförändringarna hos 56 personer med MFS. De flesta av dessa hade snedställd lins vid undersökning eller hade blivit tidigare opererade för det. Andra ögonförändringar vi noterade var glaukom, skelning, näthinneavlossning, synsvaghet och blindhet. Vi kunde också se att ögat var ovanligt långt hos många, vilket hade medfört närsynthet, dock inte i den grad som man skulle kunna förvänta sig. Hornhinnans platthet tycktes kompensera för det i många fall. I de uppdaterade diagnostiska kriterierna för MFS är hög närsynthet ett diagnostiskt kriterium hos dem som inte har snedställd lins. Eftersom många personer med MFS endast visar lätt närsynthet finns också en risk att dessa personer inte blir diagnostiserade för MFS om man vid diagnostiken inte samtidigt tar hänsyn till de andra typiska ögonförändringarna, dvs. platt och tunn hornhinna samt onormalt långt öga.

9 ACKNOWLEDGEMENTS

A number of people contributed to this thesis in many ways, inspiring, helping and encouraging me to accomplish it. I would like to express my sincerest gratitude to all of them. I especially want to thank:

Professor **Charlotta Zetterström**, my supervisor, for giving me the chance to do this thesis, for believing in me, for supporting and encouraging me all the way, for sharing your immense experience in ophthalmic surgery in a local, as well as global, perspective. Working with you has been truly inspiring.

Associate professor **Maria Kugelberg**, my co-supervisor, whose thesis gave me the inspiration to start this project, for your invaluable hands-on support from the very beginning of my PhD studies, for help with the statistics, and for sharing your positive energy and drive in research.

Annemari Koivula, my co-author, for your friendship, for sharing your vast experience in refractive surgery, and for great lunches together, with uplifting discussions on being an ophthalmologist, and inspiring reflections on the everlasting challenge of combining clinical work, research and family-life.

All the patients and participants who took their precious time and volunteered in the studies. Without you, this thesis would not exist.

Mikaela Taube, ophthalmic research nurse, for your preciseness and dedication in the Marfan studies, and for your optimistic and no-problem attitude.

Eva Mattsson at the Department of Cardiology, and professor **Elisabeth Blennow** at the Department of Clinical Genetics at the Karolinska University Hospital, for much appreciated help and collaboration in finding the candidates for the studies on Marfan syndrome.

Corresponding colleagues at the local hospitals around the country, who made a great effort in gathering the patient charts in paper I.

Associate professor **Ulla Kugelberg**, head of the Department of Pediatric ophthalmology and strabismus, and a member of our research team, for sharing your wide knowledge and experience in pediatric ophthalmology and research, and for valuable reflections on this thesis. Also, for creating such an inspiring and positive atmosphere at the clinic.

Pia Agervi, a member of our research team, and a former colleague at the Department of Pediatric ophthalmology and strabismus, for your kindness, for showing great interest in my work, giving much appreciated comments on this thesis, and for unforgettable dinners with the research team in your beautiful garden.

My colleagues and members of our research team **Margrethe Rönbeck** and **Anthony Chang**, for great discussions.

My clinical and research mentor **Tomas Wijk**, for encouraging me to apply for the residency at St. Erik Eye Hospital, when we first worked together in Åland islands for 10 years ago. You have patiently guided me through the field of clinical ophthalmology and provided memorable peptalks when needed. Your mentorship has been truly ‘non plus ultra’.

Carl-Gustav Laurell, head of the Anterior segment department at the time of these studies, and all the colleagues at the department, for fantastic co-operation and enabling these studies to be made.

Professor **Jan Ygge**, head of the Division of Ophthalmology and Vision, Department of Clinical neuroscience, for your help and support.

Ingrid Ludwigs, IT expert, for your help in finding the patients in paper I.

Ulla-Britt Schützler-Peterson and **Mia Pettersson**, administrators at the Division of Ophthalmology, for always giving prompt and accurate help in all matters concerning my thesis.

Associate professor **Agneta Rydberg**, for great help in interpretation of the visual acuity testing in children.

My colleagues **Agneta Wallin** and **Gunnar Lindgårde** at the Department of Pediatric ophthalmology and strabismus at Danderyd hospital, and all the wonderful staff there, for making every working day a joyful one and making me feel part of the team from day one.

All the other fantastic colleagues at the Department of Pediatric ophthalmology and strabismus, for your kindness and encouragement.

My colleagues **Eva Dafgård Kopp**, **Sven Sahlin**, **Anna Nilsson**, **Rikard Linderöth** and **Elin Bohman** at the Unit of Oculoplastic surgery, and all the fantastic staff there, for your flexible attitude towards me when finishing this thesis. I am lucky to have such fantastic colleagues and co-workers.

Tuija Leimu, **Salla Suves**, **Miska Suves** and **Camilla Röhl**, **Line Trondsen** and **Oscar Hedin**, **Kalle Pakarinen** and **Elin Öman**, for being my friends, for sharing the ups and downs in life, for fun and laughter.

Anu Tolonen, for running together, for talking together (for hours and hours), for having such a good and wise heart, and for being a true friend; and her fiancé **Peter Albrecht**, for your instant editing help with the thesis.

My parents-in-law **Jorunn** and **Roald Konradsen**, for your support and kind thoughts.

My dear grandparents **Kerttu** and **Kai† Karstila**, for your kindness, for caring for me and giving me your unconditional love.

My sister **Piia**.

My brother **Timo**, and his children **Helmi** and **Väinö**.

My brother **Jussi**, and his wife **Anna**.

My sister **Anna**, and her husband **Vesa**.

- I am blessed for having you all around me.

My dear parents **Ritva** and **Pekka**, for your encouragement and interest in my work, and for your love and support to me and my family.

Finally, my dearest and most beloved ones - **Jon**, for skiing with me, for being with me, and for giving me so much love; and **Olga**, **Arthur** and our smallest one kicking inside me, my twinkly little stars, for lighting up my sky and filling my heart with joy.

10 REFERENCES

- Ahmed, II, SH Chen, C Kranemann & DT Wong (2005): Surgical repositioning of dislocated capsular tension rings. *Ophthalmology* **112**: 1725-1733.
- Ahmed, II & AS Crandall (2001): Ab externo scleral fixation of the Cionni modified capsular tension ring. *Journal of cataract and refractive surgery* **27**: 977-981.
- Allen RA, BR Straatsma, L Apt & MO Hall (1967): Ocular manifestations of the Marfan syndrome. *Transactions - American Academy of Ophthalmology and Otolaryngology. American Academy of Ophthalmology and Otolaryngology* **71**: 18-38.
- Attias D, C Stheneur, C Roy, G Collod-Beroud, D Detaint, L Faivre, MA Delrue, L Cohen, C Francannet, C Beroud, M Claustres, F Iserin, P Khau Van Kien, D Lacombe, M Le Merrer, S Lyonnet, S Odent, H Plauchu, M Rio, A Rossi, D Sidi, PG Steg, P Ravaut, C Boileau & G Jondeau (2009): Comparison of clinical presentations and outcomes between patients with TGFBR2 and FBN1 mutations in Marfan syndrome and related disorders. *Circulation* **120**: 2541-2549.
- Baikoff G, G Bourgeon, HJ Jodai, A Fontaine, FV Lellis & L Trinquet (2005): Pigment dispersion and Artisan phakic intraocular lenses: crystalline lens rise as a safety criterion. *Journal of cataract and refractive surgery* **31**: 674-680.
- Baikoff G, E Lutun, C Ferraz & J Wei (2004): Static and dynamic analysis of the anterior segment with optical coherence tomography. *Journal of cataract and refractive surgery* **30**: 1843-1850.
- Barbour JR, FG Spinale & JS Ikonomidis (2007): Proteinase systems and thoracic aortic aneurysm progression. *The Journal of surgical research* **139**: 292-307.
- Barkana Y, W Shihadeh, C Oliveira, C Tello, JM Liebmann & R Ritch (2006): Angle closure in highly myopic eyes. *Ophthalmology* **113**: 247-254.
- Behki R, LP Noel & WN Clarke (1990): Limbal lensectomy in the management of ectopia lentis in children. *Archives of ophthalmology* **108**: 809-811.
- Behndig A, P Montan, U Stenevi, M Kugelberg & M Lundstrom (2011): One million cataract surgeries: Swedish National Cataract Register 1992-2009. *Journal of cataract and refractive surgery* **37**: 1539-1545.
- Beighton P, A de Paepe, D Danks, G Finidori, T Gedde-Dahl, R Goodman, JG Hall, DW Hollister, W Horton, VA McKusick & et al. (1988): *International Nosology of Heritable Disorders of Connective Tissue*, Berlin, 1986. *American journal of medical genetics* **29**: 581-594.
- Bhattacharjee H, K Bhattacharjee, D Das, PK Jain, D Chakraborty & S Deka (2004): Management of a posteriorly dislocated endocapsular tension ring and a foldable acrylic intraocular lens. *Journal of cataract and refractive surgery* **30**: 243-246.
- Blecher MH & MR Kirk (2008): Surgical strategies for the management of zonular compromise. *Current opinion in ophthalmology* **19**: 31-35.
- Boileau C, G Jondeau, T Mizuguchi & N Matsumoto (2005): Molecular genetics of Marfan syndrome. *Current opinion in cardiology* **20**: 194-200.
- Booms P, J Cisler, KR Mathews, M Godfrey, F Tiecke, UC Kaufmann, U Vetter, C Hagemeyer & PN Robinson (1999): Novel exon skipping mutation in the fibrillin-1 gene: two 'hot spots' for the neonatal Marfan syndrome. *Clinical genetics* **55**: 110-117.

- Booms P, R Pregla, A Ney, F Barthel, DP Reinhardt, A Pletschacher, S Mundlos & PN Robinson (2005): RGD-containing fibrillin-1 fragments upregulate matrix metalloproteinase expression in cell culture: a potential factor in the pathogenesis of the Marfan syndrome. *Human genetics* **116**: 51-61.
- Bopp S & K Lucke (2003): Chronic cystoid macular edema in an eye with a capsule defect and posteriorly dislocated capsular tension ring. *Journal of cataract and refractive surgery* **29**: 603-608.
- Borges LF, D Gomez, M Quintana, Z Touat, G Jondeau, A Leclercq, O Meilhac, M Jandrot-Perrus, PS Gutierrez, E Freymuller, R Vranckx & JB Michel (2010): Fibrinolytic activity is associated with presence of cystic medial degeneration in aneurysms of the ascending aorta. *Histopathology* **57**: 917-932.
- Cairns G, CN McGhee, MJ Collins, H Owens & GD Gamble (2002): Accuracy of Orbscan II slit-scanning elevation topography. *J Cataract Refract Surg* **28**: 2181-2187.
- Cionni RJ, RH Osher, DM Marques, FF Marques, ME Snyder & S Shapiro (2003): Modified capsular tension ring for patients with congenital loss of zonular support. *Journal of cataract and refractive surgery* **29**: 1668-1673.
- Coroneo MT (1993): Pterygium as an early indicator of ultraviolet insolation: a hypothesis. *The British journal of ophthalmology* **77**: 734-739.
- Cruysberg JR & A Pinckers (1995): Ectopia lentis et pupillae syndrome in three generations. *The British journal of ophthalmology* **79**: 135-138.
- Dagi LR & DS Walton (2006): Anterior axial lens subluxation, progressive myopia, and angle-closure glaucoma: recognition and treatment of atypical presentation of ectopia lentis. *Journal of AAPOS : the official publication of the American Association for Pediatric Ophthalmology and Strabismus / American Association for Pediatric Ophthalmology and Strabismus* **10**: 345-350.
- De Paepe A, RB Devereux, HC Dietz, RC Hennekam & RE Pyeritz (1996): Revised diagnostic criteria for the Marfan syndrome. *American journal of medical genetics* **62**: 417-426.
- Dietz HC, GR Cutting, RE Pyeritz, CL Maslen, LY Sakai, GM Corson, EG Puffenberger, A Hamosh, EJ Nanthakumar, SM Curristin & et al. (1991): Marfan syndrome caused by a recurrent de novo missense mutation in the fibrillin gene. *Nature* **352**: 337-339.
- Dotrelova D (1998): Bilateral retinal detachment in Marfan's syndrome. *European journal of ophthalmology* **8**: 102-105.
- Doyle A, P Hamard, M Puech & Y Lachkar (2005): Asymmetric pigmentary glaucoma in a patient with Marfan's syndrome. *Graefe's archive for clinical and experimental ophthalmology = Albrecht von Graefes Archiv fur klinische und experimentelle Ophthalmologie* **243**: 955-957.
- Faivre L, G Collod-Beroud, A Child, B Callewaert, BL Loeys, C Binquet, E Gautier, E Arbustini, K Mayer, M Arslan-Kirchner, C Stheneur, A Kiotsekoglou, P Comeglio, N Marziliano, D Halliday, C Beroud, C Bonithon-Kopp, M Claustres, H Plauchu, PN Robinson, L Ades, J De Backer, P Coucke, U Francke, A De Paepe, C Boileau & G Jondeau (2008): Contribution of molecular analyses in diagnosing Marfan syndrome and type I fibrillinopathies: an international study of 1009 probands. *Journal of medical genetics* **45**: 384-390.
- Faivre L, G Collod-Beroud, BL Loeys, A Child, C Binquet, E Gautier, B Callewaert, E Arbustini, K Mayer, M Arslan-Kirchner, A Kiotsekoglou, P Comeglio, N Marziliano, HC Dietz, D Halliday, C Beroud, C Bonithon-Kopp, M Claustres, C Muti, H Plauchu, PN Robinson, LC Ades, A Biggin, B Benetts, M Brett, KJ Holman, J De Backer, P Coucke, U Francke, A De Paepe, G Jondeau & C

- Boileau (2007): Effect of mutation type and location on clinical outcome in 1,013 probands with Marfan syndrome or related phenotypes and FBN1 mutations: an international study. *American journal of human genetics* **81**: 454-466.
- Faivre L, H Dollfus, S Lyonnet, Y Alembik, A Megarbane, J Samples, RJ Gorlin, A Alswaid, J Feingold, M Le Merrer, A Munnich & V Cormier-Daire (2003): Clinical homogeneity and genetic heterogeneity in Weill-Marchesani syndrome. *American journal of medical genetics. Part A* **123A**: 204-207.
- Faivre L, A Masurel-Paulet, G Collod-Beroud, BL Callewaert, AH Child, C Stheneur, C Binquet, E Gautier, B Chevallier, F Huet, BL Loeys, E Arbustini, K Mayer, M Arslan-Kirchner, A Kiotsekoglou, P Comeglio, M Grasso, DJ Halliday, C Beroud, C Bonithon-Kopp, M Claustres, PN Robinson, L Ades, J De Backer, P Coucke, U Francke, A De Paepe, C Boileau & G Jondeau (2009): Clinical and molecular study of 320 children with Marfan syndrome and related type I fibrillinopathies in a series of 1009 probands with pathogenic FBN1 mutations. *Pediatrics* **123**: 391-398.
- Fine IH, RS Hoffman & M Packer (2007): Profile of clear corneal cataract incisions demonstrated by ocular coherence tomography. *J Cataract Refract Surg* **33**: 94-97.
- Finkbohner R, D Johnston, ES Crawford, J Coselli & DM Milewicz (1995): Marfan syndrome. Long-term survival and complications after aortic aneurysm repair. *Circulation* **91**: 728-733.
- Fuchs J & T Rosenberg (1998): Congenital ectopia lentis. A Danish national survey. *Acta ophthalmologica Scandinavica* **76**: 20-26.
- Ganesh A, C Smith, W Chan, S Unger, N Quercia, M Godfrey, S Kraft, R Buncic & A Levin (2006): Immunohistochemical evaluation of conjunctival fibrillin-1 in Marfan syndrome. *Archives of ophthalmology* **124**: 205-209.
- Gimbel HV, R Sun & JP Heston (1997): Management of zonular dialysis in phacoemulsification and IOL implantation using the capsular tension ring. *Ophthalmic surgery and lasers* **28**: 273-281.
- Gonzalez Perez J, A Cervino, MJ Giraldez, M Parafita & E Yebra-Pimentel (2004): Accuracy and precision of EyeSys and Orbscan systems on calibrated spherical test surfaces. *Eye Contact Lens* **30**: 74-78.
- Habashi JP, DP Judge, TM Holm, RD Cohn, BL Loeys, TK Cooper, L Myers, EC Klein, G Liu, C Calvi, M Podowski, ER Neptune, MK Halushka, D Bedja, K Gabrielson, DB Rifkin, L Carta, F Ramirez, DL Huso & HC Dietz (2006): Losartan, an AT1 antagonist, prevents aortic aneurysm in a mouse model of Marfan syndrome. *Science* **312**: 117-121.
- Hamod A, D Moodie, B Clark & EI Traboulsi (2003): Presenting signs and clinical diagnosis in individuals referred to rule out Marfan syndrome. *Ophthalmic genetics* **24**: 35-39.
- Hanssen E, S Franc & R Garrone (1998): Fibrillin-rich microfibrils: structural modifications during ageing in normal human zonule. *Journal of submicroscopic cytology and pathology* **30**: 365-369.
- Hanssen E, S Franc & R Garrone (2001): Synthesis and structural organization of zonular fibers during development and aging. *Matrix biology : journal of the International Society for Matrix Biology* **20**: 77-85.
- Hara T, T Hara & Y Yamada (1991): "Equator ring" for maintenance of the completely circular contour of the capsular bag equator after cataract removal. *Ophthalmic surgery* **22**: 358-359.
- Hasanee K & Ahmed, II (2006): Capsular tension rings: update on endocapsular support devices. *Ophthalmology clinics of North America* **19**: 507-519.

- Heur M, B Costin, S Crowe, RA Grimm, R Moran, LG Svensson & EI Traboulsi (2008): The value of keratometry and central corneal thickness measurements in the clinical diagnosis of Marfan syndrome. *American journal of ophthalmology* **145**: 997-1001.
- Hollister DW, M Godfrey, LY Sakai & RE Pyeritz (1990): Immunohistologic abnormalities of the microfibrillar-fiber system in the Marfan syndrome. *The New England journal of medicine* **323**: 152-159.
- Huang D, EA Swanson, CP Lin, JS Schuman, WG Stinson, W Chang, MR Hee, T Flotte, K Gregory, CA Puliafito & et al. (1991): Optical coherence tomography. *Science* **254**: 1178-1181.
- Iordanidou V, G Sultan, C Boileau, M Raphael & C Baudouin (2007): In vivo corneal confocal microscopy in marfan syndrome. *Cornea* **26**: 787-792.
- Izquierdo NJ, EI Traboulsi, C Enger & IH Maumenee (1992): Glaucoma in the Marfan syndrome. *Transactions of the American Ophthalmological Society* **90**: 111-117; discussion 118-122.
- Jacob S, A Agarwal, A Agarwal, S Agarwal, N Patel & V Lal (2003): Efficacy of a capsular tension ring for phacoemulsification in eyes with zonular dialysis. *Journal of cataract and refractive surgery* **29**: 315-321.
- Judge DP, NJ Biery, DR Keene, J Geubtner, L Myers, DL Huso, LY Sakai & HC Dietz (2004): Evidence for a critical contribution of haploinsufficiency in the complex pathogenesis of Marfan syndrome. *The Journal of clinical investigation* **114**: 172-181.
- Kielty CM, MJ Sherratt, A Marson & C Baldock (2005): Fibrillin microfibrils. *Advances in protein chemistry* **70**: 405-436.
- Kohnen T, M Baumeister & J Bühren (2003): Scheimpflug imaging of bilateral foldable in-the-bag intraocular lens implantation assisted by a scleral-sutured capsular tension ring in Marfan's syndrome. *Journal of cataract and refractive surgery* **29**: 598-602.
- Koivula A & M Kugelberg (2007): Optical coherence tomography of the anterior segment in eyes with phakic refractive lenses. *Ophthalmology* **114**: 2031-2037.
- Kugelberg M & C Zetterstrom (2002): Pediatric cataract surgery with or without anterior vitrectomy. *Journal of cataract and refractive surgery* **28**: 1770-1773.
- Lacro RV, HC Dietz, LM Wruck, TJ Bradley, SD Colan, RB Devereux, GL Klein, JS Li, LL Minich, SM Paridon, GD Pearson, BF Printz, RE Pyeritz, E Radojewski, MJ Roman, JP Saul, MP Stylianou & L Mahony (2007): Rationale and design of a randomized clinical trial of beta-blocker therapy (atenolol) versus angiotensin II receptor blocker therapy (losartan) in individuals with Marfan syndrome. *American heart journal* **154**: 624-631.
- Lai MM, M Tang, EM Andrade, Y Li, RN Khurana, JC Song & D Huang (2006): Optical coherence tomography to assess intrastromal corneal ring segment depth in keratoconic eyes. *Journal of cataract and refractive surgery* **32**: 1860-1865.
- Lam DS, AL Young, AT Leung, SK Rao, DS Fan & JS Ng (2000): Scleral fixation of a capsular tension ring for severe ectopia lentis. *Journal of cataract and refractive surgery* **26**: 609-612.
- Lang Y, E Fineberg & HJ Garzozzi (2001): Vitrectomy to remove a posteriorly dislocated endocapsular tension ring. *Journal of cataract and refractive surgery* **27**: 474-476.
- Lee WT (2011): Disorders of amino acid metabolism associated with epilepsy. *Brain & development* **33**: 745-752.

- Legget ME, TA Unger, CK O'Sullivan, TR Zwink, RL Bennett, PH Byers & CM Otto (1996): Aortic root complications in Marfan's syndrome: identification of a lower risk group. *Heart* **75**: 389-395.
- Lim L, RH Wei, WK Chan & DT Tan (2007): Evaluation of keratoconus in Asians: role of Orbscan II and Tomey TMS-2 corneal topography. *American journal of ophthalmology* **143**: 390-400.
- Loewenstein A, IS Barequet, E De Juan, Jr. & IH Maumenee (2000): Retinal detachment in Marfan syndrome. *Retina* **20**: 358-363.
- Loeys B, J De Backer, P Van Acker, K Wettinck, G Pals, L Nuytinck, P Coucke & A De Paepe (2004): Comprehensive molecular screening of the FBN1 gene favors locus homogeneity of classical Marfan syndrome. *Human mutation* **24**: 140-146.
- Loeys B, L Nuytinck, I Delvaux, S De Bie & A De Paepe (2001): Genotype and phenotype analysis of 171 patients referred for molecular study of the fibrillin-1 gene FBN1 because of suspected Marfan syndrome. *Archives of internal medicine* **161**: 2447-2454.
- Loeys BL, HC Dietz, AC Braverman, BL Callewaert, J De Backer, RB Devereux, Y Hilhorst-Hofstee, G Jondeau, L Faivre, DM Milewicz, RE Pyeritz, PD Sponseller, P Wordsworth & AM De Paepe (2010): The revised Ghent nosology for the Marfan syndrome. *Journal of medical genetics* **47**: 476-485.
- Maumenee IH (1981): The eye in the Marfan syndrome. *Transactions of the American Ophthalmological Society* **79**: 684-733.
- Mir S, HM Wheatley, IE Hussels, JA Whittum-Hudson & EI Traboulsi (1998): A comparative histologic study of the fibrillin microfibrillar system in the lens capsule of normal subjects and subjects with Marfan syndrome. *Investigative ophthalmology & visual science* **39**: 84-93.
- Mizuguchi T, G Collod-Beroud, T Akiyama, M Abifadel, N Harada, T Morisaki, D Allard, M Varret, M Claustres, H Morisaki, M Ihara, A Kinoshita, K Yoshiura, C Junien, T Kajii, G Jondeau, T Ohta, T Kishino, Y Furukawa, Y Nakamura, N Niikawa, C Boileau & N Matsumoto (2004): Heterozygous TGFBR2 mutations in Marfan syndrome. *Nature genetics* **36**: 855-860.
- Moreno-Montanes J, C Sainz & MJ Maldonado (2003): Intraoperative and postoperative complications of Cionni endocapsular ring implantation. *Journal of cataract and refractive surgery* **29**: 492-497.
- Morse RP, S Rockenmacher, RE Pyeritz, SP Sanders, FR Bieber, A Lin, P MacLeod, B Hall & JM Graham, Jr. (1990): Diagnosis and management of infantile marfan syndrome. *Pediatrics* **86**: 888-895.
- Murdoch JL, BA Walker, BL Halpern, JW Kuzma & VA McKusick (1972): Life expectancy and causes of death in the Marfan syndrome. *The New England journal of medicine* **286**: 804-808.
- Muscat S, N McKay, S Parks, E Kemp & D Keating (2002): Repeatability and reproducibility of corneal thickness measurements by optical coherence tomography. *Invest Ophthalmol Vis Sci* **43**: 1791-1795.
- Nagamoto T & H Bissen-Miyajima (1994): A ring to support the capsular bag after continuous curvilinear capsulorhexis. *Journal of cataract and refractive surgery* **20**: 417-420.
- Narayanan P, JC Merriam, ME Vazquez & J Dillon (1996): Experimental model of light focusing of the peripheral cornea. *Investigative ophthalmology & visual science* **37**: 37-41.
- Neely DE & DA Plager (2001): Management of ectopia lentis in children. *Ophthalmology clinics of North America* **14**: 493-499.

- Nemet AY, EI Assia, DJ Apple & IS Barequet (2006): Current concepts of ocular manifestations in Marfan syndrome. *Survey of ophthalmology* **51**: 561-575.
- Neptune ER, PA Frischmeyer, DE Arking, L Myers, TE Bunton, B Gayraud, F Ramirez, LY Sakai & HC Dietz (2003): Dysregulation of TGF-beta activation contributes to pathogenesis in Marfan syndrome. *Nature genetics* **33**: 407-411.
- Ng CM, A Cheng, LA Myers, F Martinez-Murillo, C Jie, D Bedja, KL Gabrielson, JM Hausladen, RP Mecham, DP Judge & HC Dietz (2004): TGF-beta-dependent pathogenesis of mitral valve prolapse in a mouse model of Marfan syndrome. *The Journal of clinical investigation* **114**: 1586-1592.
- Pavlin CJ, YM Buys & T Pathmanathan (1998): Imaging zonular abnormalities using ultrasound biomicroscopy. *Archives of ophthalmology* **116**: 854-857.
- Price MO, FW Price, Jr., L Werner, C Berlie & N Mamalis (2005): Late dislocation of scleral-sutured posterior chamber intraocular lenses. *Journal of cataract and refractive surgery* **31**: 1320-1326.
- Putnam EA, M Cho, AB Zinn, JA Towbin, PH Byers & DM Milewicz (1996): Delineation of the Marfan phenotype associated with mutations in exons 23-32 of the FBN1 gene. *American journal of medical genetics* **62**: 233-242.
- Pyeritz RE & VA McKusick (1979): The Marfan syndrome: diagnosis and management. *The New England journal of medicine* **300**: 772-777.
- Radhakrishnan H & WN Charman (2007): Refractive changes associated with oblique viewing and reading in myopes and emmetropes. *Journal of vision* **7**: 5.
- Radhakrishnan S, AM Rollins, JE Roth, S Yazdanfar, V Westphal, DS Bardenstein & JA Izatt (2001): Real-time optical coherence tomography of the anterior segment at 1310 nm. *Archives of ophthalmology* **119**: 1179-1185.
- Radonic T, P de Witte, MJ Baars, AH Zwinderman, BJ Mulder & M Groenink (2010): Losartan therapy in adults with Marfan syndrome: study protocol of the multi-center randomized controlled COMPARE trial. *Trials* **11**: 3.
- Ramirez F & LY Sakai (2010): Biogenesis and function of fibrillin assemblies. *Cell and tissue research* **339**: 71-82.
- Reinhardt DP, RN Ono, H Notbohm, PK Muller, HP Bachinger & LY Sakai (2000): Mutations in calcium-binding epidermal growth factor modules render fibrillin-1 susceptible to proteolysis. A potential disease-causing mechanism in Marfan syndrome. *The Journal of biological chemistry* **275**: 12339-12345.
- Remulla JF & FI Tolentino (2001): Retinal detachment in Marfan's syndrome. *International ophthalmology clinics* **41**: 235-240.
- Ritch R, BM Chang & JM Liebmann (2003): Angle closure in younger patients. *Ophthalmology* **110**: 1880-1889.
- Roman MJ, SE Rosen, R Kramer-Fox & RB Devereux (1993): Prognostic significance of the pattern of aortic root dilation in the Marfan syndrome. *Journal of the American College of Cardiology* **22**: 1470-1476.
- Romano PE, NC Kerr & GM Hope (2002): Bilateral ametropic functional amblyopia in genetic ectopia lentis: its relation to the amount of subluxation, an indicator for early surgical management. *Binocular vision & strabismus quarterly* **17**: 235-241.
- Sachdev NH, N Di Girolamo, PJ McCluskey, AV Jennings, R McGuinness, D Wakefield & MT Coroneo (2002): Lens dislocation in Marfan syndrome: potential role of matrix metalloproteinases in fibrillin degradation. *Archives of ophthalmology* **120**: 833-835.
- Sakai LY, DR Keene & E Engvall (1986): Fibrillin, a new 350-kD glycoprotein, is a component of extracellular microfibrils. *The Journal of cell biology* **103**: 2499-2509.

- Schachar RA (2004): Qualitative effect of zonular tension on freshly extracted intact human crystalline lenses: implications for the mechanism of accommodation. *Investigative ophthalmology & visual science* **45**: 2691-2695.
- Schachar RA (2006): The mechanism of accommodation and presbyopia. *International ophthalmology clinics* **46**: 39-61.
- Schachar RA, C Tello, DP Cudmore, JM Liebmann, TD Black & R Ritch (1996): In vivo increase of the human lens equatorial diameter during accommodation. *The American journal of physiology* **271**: R670-676.
- Setala K, P Ruusuvaara & K Karjalainen (1988): Corneal endothelium in Marfan syndrome. A clinical and specular microscopic study. *Acta Ophthalmol (Copenh)* **66**: 334-340.
- Shortt AJ, B Lanigan & M O'Keefe (2004): Pars plana lensectomy for the management of ectopia lentis in children. *Journal of pediatric ophthalmology and strabismus* **41**: 289-294.
- Silverman DI, KJ Burton, J Gray, MS Bosner, NT Kouchoukos, MJ Roman, M Boxer, RB Devereux & P Tsipouras (1995): Life expectancy in the Marfan syndrome. *The American journal of cardiology* **75**: 157-160.
- Speedwell L & I Russell-Eggitt (1995): Improvement in visual acuity in children with ectopia lentis. *Journal of pediatric ophthalmology and strabismus* **32**: 94-97.
- Stachs O, H Martin, D Behrend, KP Schmitz & R Guthoff (2006): Three-dimensional ultrasound biomicroscopy, environmental and conventional scanning electron microscopy investigations of the human zonula ciliaris for numerical modelling of accommodation. *Graefe's archive for clinical and experimental ophthalmology = Albrecht von Graefes Archiv fur klinische und experimentelle Ophthalmologie* **244**: 836-844.
- Stheneur C, G Collod-Beroud, L Faivre, JF Buyck, L Gouya, JM Le Parc, B Moura, C Muti, B Grandchamp, G Sultan, M Claustres, P Aegerter, B Chevallier, G Jondeau & C Boileau (2009): Identification of the minimal combination of clinical features in probands for efficient mutation detection in the FBN1 gene. *European journal of human genetics : EJHG* **17**: 1121-1128.
- Sultan G, C Baudouin, O Auzerie, M De Saint Jean, M Goldschild & PJ Pisella (2002): Cornea in Marfan disease: Orbscan and in vivo confocal microscopy analysis. *Investigative ophthalmology & visual science* **43**: 1757-1764.
- Swartz T, L Marten & M Wang (2007): Measuring the cornea: the latest developments in corneal topography. *Current opinion in ophthalmology* **18**: 325-333.
- Traboulsi EI, JA Whittum-Hudson, SH Mir & IH Maumenee (2000): Microfibril abnormalities of the lens capsule in patients with Marfan syndrome and ectopia lentis. *Ophthalmic genetics* **21**: 9-15.
- Ursea R & RH Silverman (2010): Anterior-segment imaging for assessment of glaucoma. *Expert review of ophthalmology* **5**: 59-74.
- Von Helmholtz H (1855): Über die Akkommodation des Auges. . *Albrecht Von Graefes Arch. Ophthalmol.*: 1-89.
- Wei RH, L Lim, WK Chan & DT Tan (2006): Evaluation of Orbscan II corneal topography in individuals with myopia. *Ophthalmology* **113**: 177-183.
- Werth VP, KJ Williams, EA Fisher, M Bashir, J Rosenbloom & X Shi (1997): UVB irradiation alters cellular responses to cytokines: role in extracellular matrix gene expression. *The Journal of investigative dermatology* **108**: 290-294.
- Wheatley HM, EI Traboulsi, BE Flowers, IH Maumenee, D Azar, RE Pyeritz & JA Whittum-Hudson (1995): Immunohistochemical localization of fibrillin in human ocular tissues. Relevance to the Marfan syndrome. *Archives of ophthalmology* **113**: 103-109.

Yeung KK & BA Weissman (1997): Contact lens correction of patients with Marfan syndrome. *Journal of the American Optometric Association* **68**: 367-372.