

## A TRANSPETROSAL APPROACH FOR EXTENSIVE EPIDERMOID CYST IN THE CEREBELLOPONTINE ANGLE IN A YOUNG ADULT

HIROYUKI NAKASE

*The 2nd Department of Surgery, Nara Medical University*

HIDEYUKI OHNISHI, HAJIME TOUHO, JUN KARASAWA and KIYOSHI SHIMIZU\*

*Department of Neurosurgery and Neurophysiology Section of the Department of Clinical Laboratory\*,  
Osaka Neurological Institute*

Received April 5, 1994

*Abstract* : A 26-year-old male with a large epidermoid cyst in the cerebellopontine angle (CPA) undergoing successful total removal via the transpetrosal approach is described. He was referred to our clinic with a history of left facial pain for five years and left hearing disturbance for three years. Computed tomography and magnetic resonance imaging revealed a low-density mass located at the left side of the brainstem, which extended from the ventral side of the medullae to the left parasellar region and medial temporal fossa without abnormal enhancement. Operation was performed via the transpetrosal approach under facial nerve electromyographic, somatosensory evoked potential and auditory brainstem response monitoring. Two-staged operation through the pre- and retrosigmoid route was performed and resulted in successful total removal.

In such extensive epidermoid cysts as the present case, a wide operative field is required for total removal, so the transpetrosal approach is very useful.

### Index Terms

epidermoid cyst, cerebellopontine angle, transpetrosal approach

### INTRODUCTION

Epidermoid cysts are cholesterol-rich material filled benign tumors whose capsule consists of epidermis. These tumors grow very slowly and tend to spread flexibly and extensively, and are characterized by extensive size despite relatively minimal neurologic symptoms. The extensiveness of these tumors and the resulting difficulties of operative removal account for their relatively high lethality in comparison with other slow-developing tumors.<sup>1)</sup> The CPA is the most common site of occurrence of intracranial epidermoids, with epidermoids representing from 4.6% to 6.3% of all tumors at this site.<sup>2)</sup> Hamel et al<sup>1)</sup> reviewed 221 epidermoids and dermoids (his own 38 cases and those reported in the literature) and reported that they occur in decreasing order of frequency in the CPA (23%), in the suprasellar region (19%), in the cerebellum (18%), and in the temporal region (14%). Tumors in the CPA often extend into the middle fossa and parasellar space over the tentorial hiatus. Total removal of CPA epidermoids is difficult and risky due to adherence to surrounding structures: brainstem, cranial nerves, and

---

Author's present address: Hiroyuki Nakase, Department of Neurosurgery, Nara Medical University, 840 Shijo-cho, Kashihara-shi, Nara, Japan

blood vessels. However, recurrence is inevitable with incomplete removal of the capsule, especially in young patients.<sup>3)</sup> Also, leakage of the tumor contents has occasionally led to irritation of adjacent tissue, resulting in inflammation and granulation.

We describe a young adult with a large epidermoid cyst in the cerebellopontine angle (CPA) who underwent total removal successfully via the transpetrosal approach. Also, the results of surgical treatment of CPA epidermoid in the literature and the surgical technique, including intraoperative monitoring, are discussed.

### CASE REPORT

A 26-year-old man with a history of left facial pain for five years and left hearing disturbance for three years was admitted to Osaka Neurological Institute. His general physical condition was normal. Neurological examination revealed hypesthesia in the territory of the second and third divisions of the left trigeminal nerve, and left deafness. Computed tomography (CT) revealed a low-density mass located at the left side of the brainstem. The mass extended from the ventral side of the medullae to the left parasellar region and medial temporal fossa with no abnormal enhancement. Magnetic resonance imaging (MRI) demonstrated tumor extension from the ventral portion of the medullae into the parasellar region. The tumor was slightly hypointense on T1-weighted images (Figs. 1, 2) and hyperintense on T2-weighted images. Cerebral angiography demonstrated that the basilar artery was displaced backwards by an avascular mass.

Operation was performed via the transpetrosal approach. Facial nerve electromyographic, somatosensory evoked potential (SEP), and auditory brainstem response (ABR) monitoring and lumbar drain were established. The patient was placed in the left lateral position with the head elevated 30 degrees and turned parallel to the floor. A periauricular incision was made. The muscle and pericranium were reflected with the scalp. Bone was removed to expose the inferior temporal bone, sigmoid sinus and sufficient posterior fossa dura to the foramen magnum. A complete mastoidectomy was performed using a high speed drill. The petrous bone was removed to a depth of about 1.5 cm from the medial edge of sigmoid sinus. The dura could

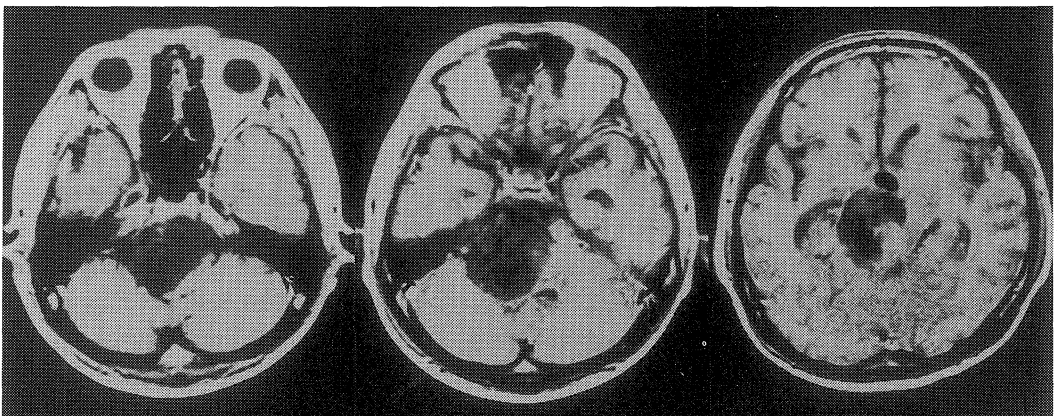


Fig. 1. Magnetic resonance imaging (MRI) revealing a hypointensity mass in T1-weighted image located at the left side of the brainstem. The mass extended from the ventral side of the medullae to the left parasellar region and the medial temporal fossa.

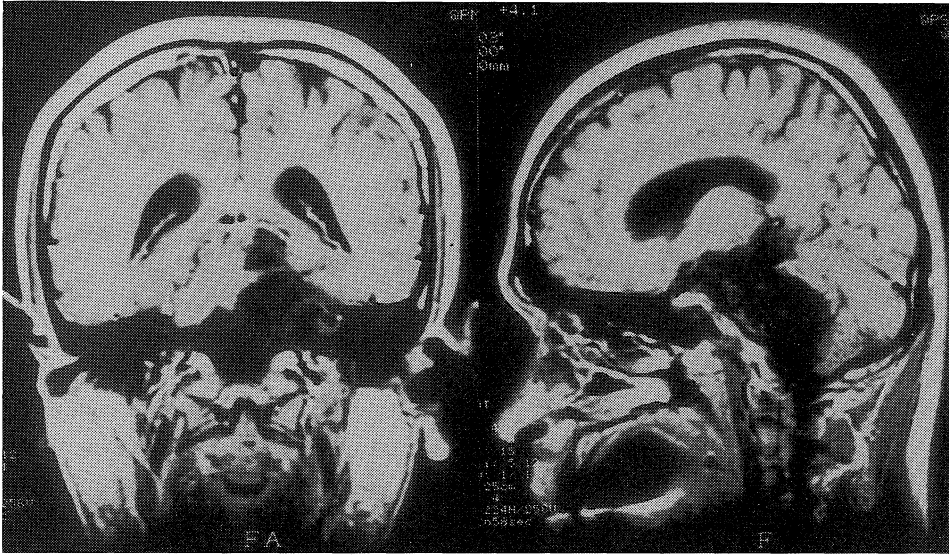


Fig. 2. Coronal and sagittal image of MRI demonstrating extension of the tumor from the ventral side of the medullae into the parasellar region.

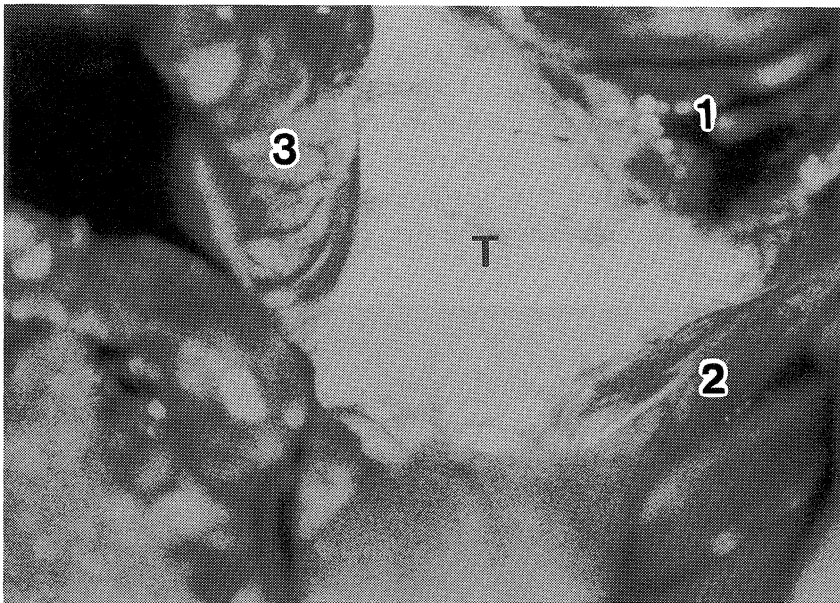


Fig. 3. Intraoperative photograph showing tumor with a white, smooth, and irregular nodular surface.

1 : Trautmann's, 2 : Temporal lobe, 3 : Cerebellum, T : Tumor

be incised anterior to the sigmoid sinus and along the inferior surface of the temporal lobe, and the superior petrosal sinus was ligated and cut. Care was taken to protect the vein of Labbe.<sup>4)</sup> Division of the tentorium to the incisura was performed, preserving the trochlear nerve. The tumor was observed with a white, smooth, and irregular nodular surface (Fig. 3) and was removed in a piecemeal fashion. Extreme care was taken to avoid damaging the surrounding

neurovascular structures, cranial nerves, vasculatures, pons and medullae under intraoperative ABR and SEP monitoring. The tumor, which was located at the left side of the brainstem, the left parasellar region, and the medial temporal fossa, was removed. The first operation was interrupted because of an excessively long operative time and an increase (1.2 msec) in interwave (III-V) latency of ABR. A portion of the tumor located at the left side of the lower part of the brainstem and the ventral side of medullae remained. The cranial nerves were preserved anatomically, and facial nerve was also preserved functionally as judged by a facial nerve electromyographic monitoring. After sufficient irrigation to prevent irritation to the adjacent tissue, dural closure using autologous fascia lata was made, and fibrin glue and autologous fat taken from the abdomen were placed in the epidural space.

Postoperatively, he was observed in the intensive care unit and showed mild left facial weakness which improved after a month. The left facial pain disappeared. Two months after the first operation, a second operation (mainly via the retrosigmoid route) was performed. Total removal of the tumor, located at the lower CPA and ventral side of the medullae, was accomplished. The postoperative course was good, and the patient was discharged a month after the second operation. Postoperative CT and MRI revealed total removal (Fig. 4). He remains tumor-free one year after discharge with left deafness.

#### DISCUSSION

Lunardi *et al*<sup>2)</sup> reported the long-term surgical results of a series of 17 epidermoids of the CPA (total removal in 6 cases and subtotal removal in 11 cases) which were operated through retromastoid suboccipital craniotomy, and found 2 (18%) recurrences among the 11 cases 15 and 21 years after the first operation respectively. However, two of five patients undergoing total removal of the capsule died in the postoperative period, whereas no operative mortality occurred among the 11 patients undergoing subtotal removal. The authors concluded that

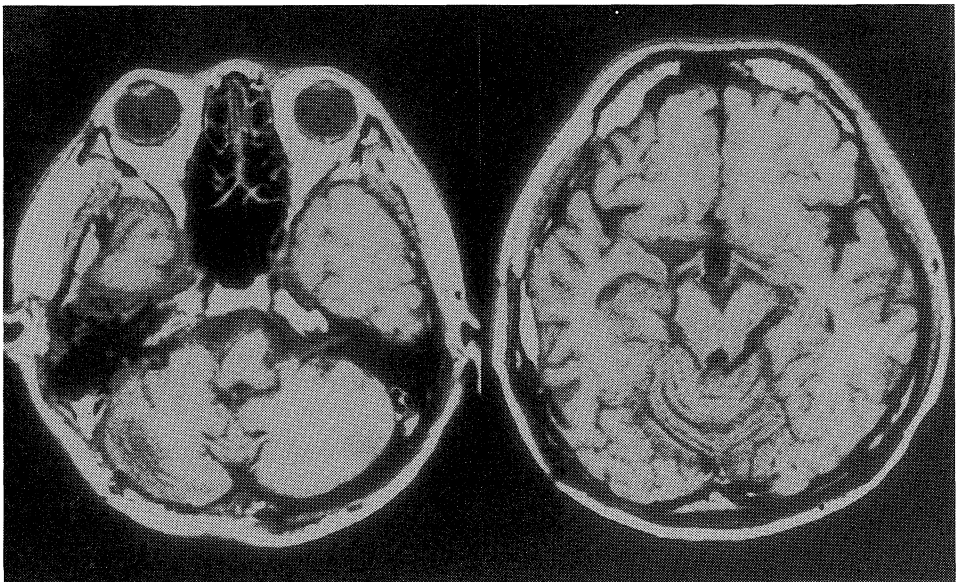


Fig. 4. Postoperative MRI demonstrating total removal and improvement of midline shift.

subtotal removal is justified when tight capsular adhesions are present. Zhou<sup>5)</sup> reported 102 intracranial epidermoids (39 of which were located in the CPA), with the likelihood of complete removal of tumor increasing, rising from 29.3% (before 1981) to 72.7 % (after 1981) in his series with the aid of microsurgical technique. Among 24 patients with incomplete removal, 4 had recurrence. Yasargil<sup>6)</sup> reported his results in 25 patients with subtentorial epidermoid and concluded that an epidermoid can be removed completely thanks partly to microneurosurgery and partly to the fact that the tumour does not extend much past the midline since it does not tend to invade the contralateral subarachnoid space. King et al<sup>7)</sup> reported the petrosal approach with hearing preservation in 26 patients with petroclival lesions including three CPA epidermoids. Two of these three cases underwent reoperation after subtotal removal by a suboccipital approach, and complete removal was obtained in all cases. We believe that better results by the transpetrosal approach for CPA epidermoid will be reported in the future; however, recovery of cranial nerve function is not likely to be satisfactory if hearing or facial nerve disturbance is severe or long-standing.

The transpetrosal approach<sup>7-12)</sup> is appreciated as being the best approach to gain access to the petroclival region, and has the following advantages: (a) a wide operative field extending from the middle fossa to the foramen magnum; (b) minimal retraction of temporal lobe and cerebellum; (c) short operative distance to the clivus; (d) preservation of cranial nerves and major sinuses; (e) early interception of blood supply to the tumor. Spetzler et al<sup>13)</sup> reported this approach divided into three variations based upon the amount of petrous bone removed: retrolabyrinthine technique, translabyrinthine technique, and transcochlear technique. An adequate view to the level of the midpons and trigeminal nerve can be obtained by this approach; however, inferior exposure of the clivus through a presigmoid route is limited by the jugular tubercle. More inferior parts can be accessed through a lateral suboccipital approach or transcondylar approach. Diraz et al<sup>3)</sup> reported a transpetrosal extreme lateral suboccipital approach for an extensive CPA epidermoid case.

Concerning intraoperative monitoring, ABR and SEP are useful in the approach to sensitive areas like the brain stem, and ABR and facial nerve monitoring provide information about hearing and facial nerve function intraoperatively. We routinely perform these monitorings in the transpetrosal approach. Especially in a reoperation, it is difficult to grasp the anatomy due to postoperative adhesions, and such monitoring is very useful.<sup>12)</sup> The critical fluctuation of intraoperative ABR in the latency is 1.5 msec according to Raudzens.<sup>14)</sup> This monitoring may justify subtotal removal and stage-operation. We advocate the stage-operation method for large tumors according to these monitorings.

## REFERENCES

- 1) Hamel, E., Frowein, R. A. and Karimi-Nejad, A. : Intracranial intradural epidermoids and dermoids. *Neurosurg. Rev.* 3 : 215-219, 1980.
- 2) Lunardi, P., Missori, P., Innocenzi, G., Gagliardi, F. M. and Fortuna, A. : Long-term results of surgical treatment of cerebello-pontine angle epidermoids. *Acta Neurochir.(Wien)* 103 : 105-108, 1990.
- 3) Diraz, A., Kobayashi, S., Kyoshima, K., Nagasaki, C. and Hokama, M. : Transpetrosal extreme lateral suboccipital approach for extensive posterior fossa epidermoid cyst. *Neurol. Med. Chir.(Tokyo)* 32 : 589-592, 1992.

- 4) **Ohnishi, H., Nakase, H., Touho, H., Hashimoto, K., Watabe, Y., Itoh, T., Yamada, K., Sato, N. and Karasawa, J.** : Preservation of the vein of Labbe in the approach of skull base lesions. *Surgery for Cerebral Stroke* **21**(4) : 305-310, 1993.
- 5) **Zhou, L. F.** : Intracranial epidermoid tumours; thirty-seven years of diagnosis and treatment. *Brit. J. Neurosurg.* **4** : 211-216, 1990.
- 6) **Yasargil, M. G., Abernathey, C. D. and Sarioglu, A. C.** : Microneurosurgical treatment of intracranial dermoid and epidermoid tumors. *Neurosurgery* **24** : 561-567, 1989.
- 7) **King, W. A., Black, K. L., Martin, N. A., Canalis, R. F. and Becker, D. P.** : The petrosal approach with hearing preservation. *J. Neurosurg.* **79** : 508-514, 1993.
- 8) **Al-mefty, O., Schenk, M. P. and Smith, R. R.** : Petroclival meningiomas. *in* *Neurosurgical operative atlas* (Rengachary, S. S. and Wilkins, R. H. eds.). vol. 1, Chicago, Illinois, AANS Publication committee, p339-350, 1991.
- 9) **Hakuba, A., Nishimura, S., Tanaka, A., Kishi, W. and Nakamura, T.** : Clivus meningiomas; six cases of total removal. *Neurol. Med. Chir.(Tokyo)* **17** : 63-77, 1977.
- 10) **Kawase, T., Shiobara, R. and Toya, S.** : Anterior transpetrosal-transtentorial approach for sphenopetroclival meningiomas; Surgical method and results in 10 patients. *Neurosurgery* **28** : 869-876, 1991.
- 11) **Morrison, A. W. and King, T. T.** : Experience with a translabyrinthine-transtentorial approach to the cerebellopontine angle. *J. Neurosurg.* **38** : 382-390, 1973.
- 12) **Nakase, H., Ohnishi, H., Touho, H., Watabe, Y., Yamada, K. and Karasawa, J.** : A combined supra- and infratentorial transpetrosal approach for surgical treatment of tumors extending from the cerebellopontine angle into the cavernous sinus. *Jap. J. Neurosurg.* **2**(4) : 321-325, 1993.
- 13) **Spetzler, R. F., Dasplit, C. P. and Pappas, C. T.** : The combined supra- and infratentorial approach for lesions of the petrous and clival regions: experience with 46 cases. *J. Neurosurg.* **76** : 588-599, 1992.
- 14) **Raudzens, P. A. and Shetter, A. G.** : Intraoperative monitoring of brain-stem auditory evoked potentials. *J. Neurosurg.* **57** : 341-348, 1982.