

Contents lists available at [ScienceDirect](http://www.sciencedirect.com)

International Journal of Pediatric Otorhinolaryngology

journal homepage: www.elsevier.com/locate/ijporl

Case Report

Grisel syndrome, acute otitis media, and temporo-mandibular reactive arthritis: A rare association

J. Martins^{a,*}, S. Almeida^b, P. Nunes^a, F. Prata^c, M.L. Lobo^d, J.G. Marques^c^a Pediatric Department, Hospital Prof. Doutor Fernando Fonseca E.P.E., Amadora, Portugal^b Pediatric Department, Hospital de Santa Maria; Centro Hospitalar de Lisboa Norte E.P.E., Lisboa, Portugal^c Pediatric Infectious Diseases Unit, Hospital de Santa Maria; Centro Hospitalar de Lisboa Norte E.P.E., Lisboa, Portugal^d Radiology Department, Hospital de Santa Maria, Centro Hospitalar de Lisboa Norte E.P.E., Lisboa, Portugal

ARTICLE INFO

Article history:

Received 28 April 2015

Received in revised form 16 May 2015

Accepted 20 May 2015

Available online 29 May 2015

Keywords:

Grisel syndrome

Acute otitis

Reactive arthritis

Torticollis

ABSTRACT

We present a case report of a four-year-old boy with torticollis and trismus after acute otitis media. Grisel Syndrome diagnosis in association with temporo-mandibular reactive arthritis was admitted, leading to early conservative treatment. GS should be suspected in a child presenting with torticollis after an upper respiratory tract infection or an ENT surgical procedure. The association with temporo-mandibular reactive findings is somehow rarer but not impossible, due to the close vascular communication between retropharyngeal and pterigoid spaces.

© 2015 Elsevier Ireland Ltd. All rights reserved.

1. Background

By definition, Grisel's syndrome (GS) is a rare, nontraumatic subluxation of C1-C2 joint. Its name is due to the description by Pierre Grisel of three patients with pharyngitis and torticollis due to C1-C2 joint dislocation [1,2].

Although its pathogenesis remains elusive, it is plausible that those with baseline hyperlaxidity are at higher risk. That would explain why GS primarily affects children under the age of 12 years and patients with Down syndrome.

Karkos et al. [3] reported 96 cases with non-traumatic atlanto-axial rotary subluxation. Forty-eight percent occurred following infections and 40% after Ear Nose and Throat (ENT) surgery (adenotonsillectomy in 78%). Within the infectious etiology, the main responsible is upper respiratory tract viral infection (83%), followed by retropharyngeal abscess (11%), otitis media (4%) and mumps (2%).

The correct diagnosis is challenging and requires a high index of clinical suspicion and appropriate radiographic imaging. Computerized tomography and/or magnetic resonance imaging

of the head and neck are considered the gold standard for GS diagnosis.

The length of time until reduction has been directly related to the failure of medical treatment and to an increased risk of recurrence or permanent neck deformity [4]. Up to 15% of the untreated GS patients develop severe neurological complications: nerve damage, paralysis and even death. Early recognition is of utmost importance to avoid complications.

2. Case presentation

A previously healthy four-year-old boy was admitted to our hospital having neck pain and stiffness, with a rotational misalignment of the mental region to the right side of the neck for six days. There was no history of trauma, but the patient had rhinopharyngitis and acute otitis media diagnosed in the day prior to the beginning of the cervical complaints. He received antibiotic treatment and had remained afebrile.

The physical examination showed: torticollis, associated with spasm and tenderness over right sternocleidomastoid muscle and limited cervical range of motion (Fig. 1); trismus; right temporo-mandibular joint (TMJ) tumefaction; bilateral tympanic hyperemia; there were no asymmetry or inflammation within the tonsillar area. No neurological, ophthalmological or other osteoarticular signs were found.

* Corresponding author at: Hospital Prof. Doutor Fernando Fonseca E.P.E., IC-19, Ventoura, 2720-276 Amadora, Portugal. Tel.: +351 21 434 8200.

E-mail address: Joana.jm@gmail.com (J. Martins).

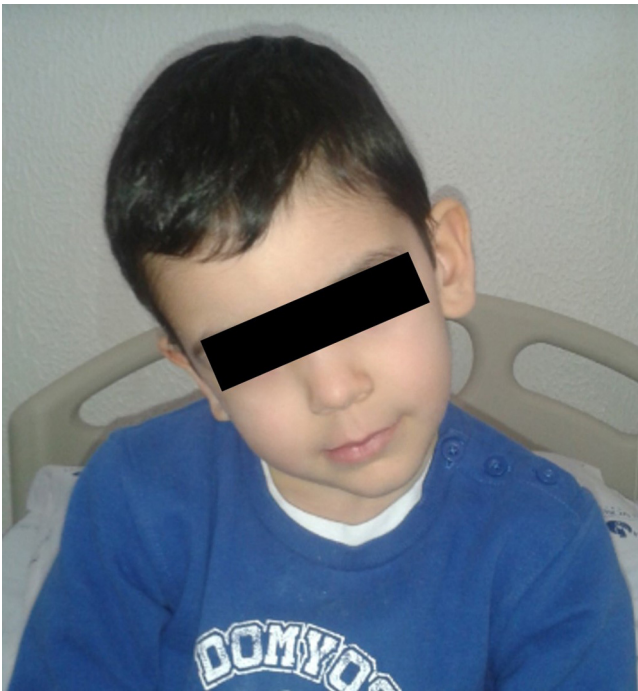

Fig. 1. Clinical presentation: right torticollis.

3. Investigation

The C-reactive protein was 2.6 mg/dL and the white blood cell count was not altered. Ultrasound examination of the neck revealed multiple enlarged lymph nodes, the biggest one measuring 22 mm × 11 mm in size and was located in the anterior jugular chain.

Contrast-enhanced CT-scan of the cervical region, showed multiple lymphadenopathies in the anterior-lateral cervical region, with no abscess detection (Fig. 2). There was a significant asymmetry of the tissues surrounding the right TMJ due to joint effusion with peripheral halo of contrast intake, suggesting of inflammatory/infectious process (Fig. 3).

4. Treatment and follow-up

First diagnostic impression lead us to assume that this was the case of a secondary torcicollis due to cervical lymphadenopathies' inflammatory process. However, initial treatment with diazepam (muscle relaxant), ibuprofen (non-steroid anti-inflammatory) and intravenous (IV) antibiotic (amoxicillin-clavulanate) lead to no further improvement.

This lead to the review of previous CT-scan images. After obtaining adequate multiplanar reconstructions for the cervical spine, additional signs of rotational dislocation of the atlantoaxial joint (Figs. 4 and 5) were identified.

After confirmation of atlantoaxial rotatory subluxation (AARS) – Type 2 dislocation according to Fielding and Hawkins classification [5], neurosurgery consulting was obtained.

In the presence of an AARS with no prior cervical trauma and only acute otitis media as the trigger factor, lead us to establish Grisel Syndrome diagnosis (Deichmueller and Welkoborsky diagnostic algorithm [6] – Table 1).

Being a type 2 AARS with less than 2 weeks of evolution, conservative management was chosen. The patient was submitted to manual subluxation closed reduction under conscious sedation by the neurosurgery team and cervical mobilization restraint was adopted using a Philadelphia collar.

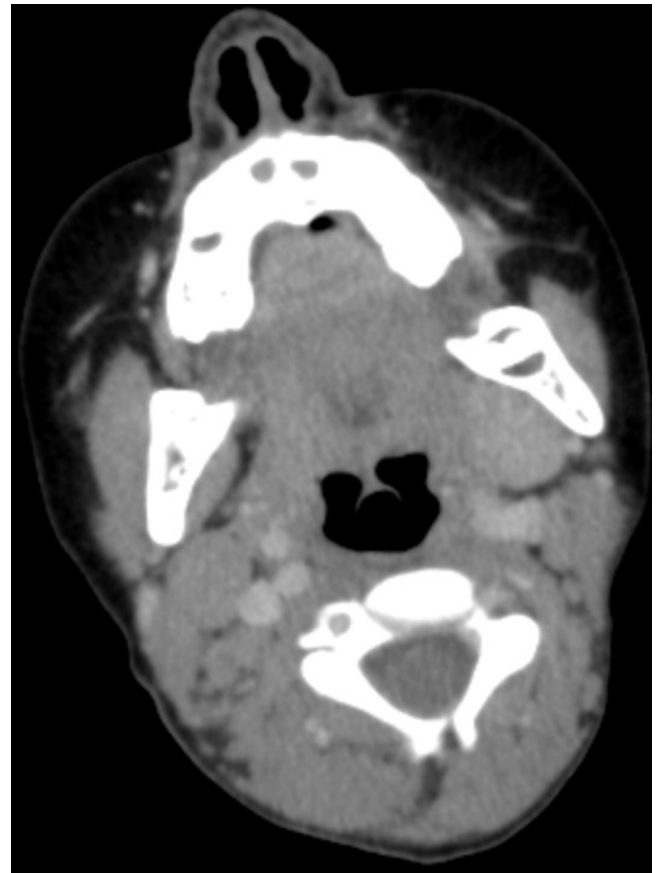


Fig. 2. Contrast-enhanced axial CT image showing multiple lymphadenopathies in the anterior-lateral cervical region, with no abscess detection.

The patient was kept on treatment with ibuprofen and IV amoxicillin-clavulanate for 11 days.

Follow-up contrast enhanced CT-scan performed after 2 weeks, and before hospital release, showed normal alignment of C1-C2, with mild edema of the atlantodental ligament (Figs. 6 and 7). No

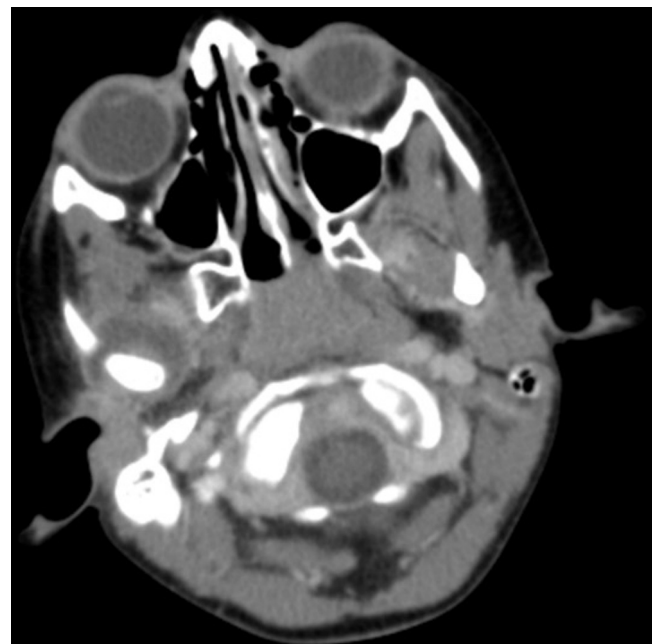


Fig. 3. Contrast-enhanced axial CT image showing right TMJ effusion.

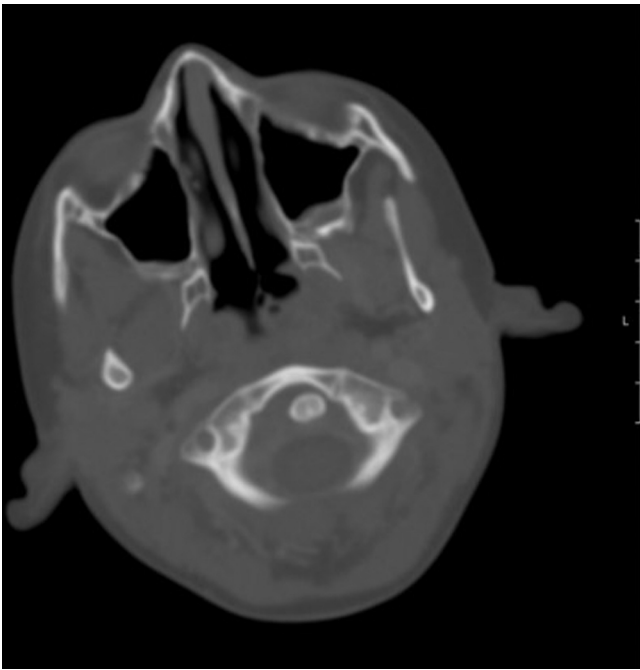


Fig. 4. Axial CT image showing C1-C2 subluxation.

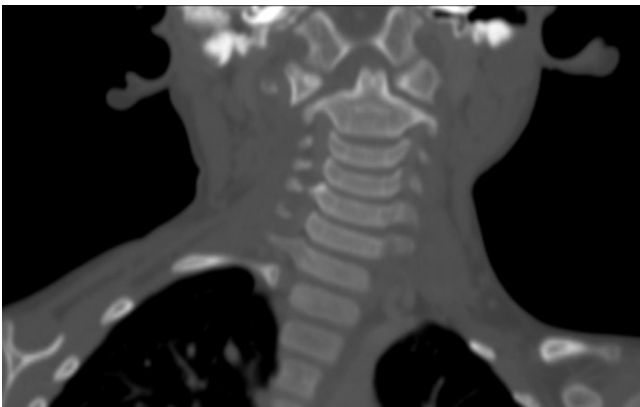


Fig. 5. Coronal reformat CT image showing C1-C2 subluxation.

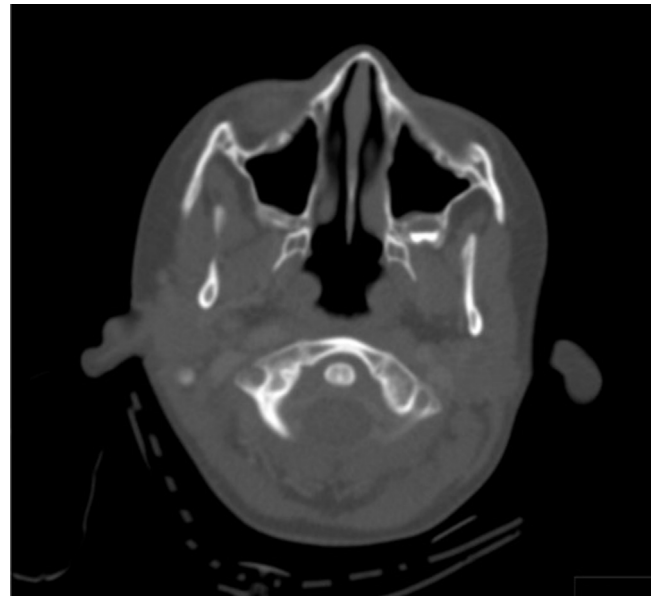


Fig. 6. Contrast-enhanced CT, following 2 weeks of treatment. Axial CT image showing normal alignment of C1-C2 and a mild edema of the atlantodental ligament.

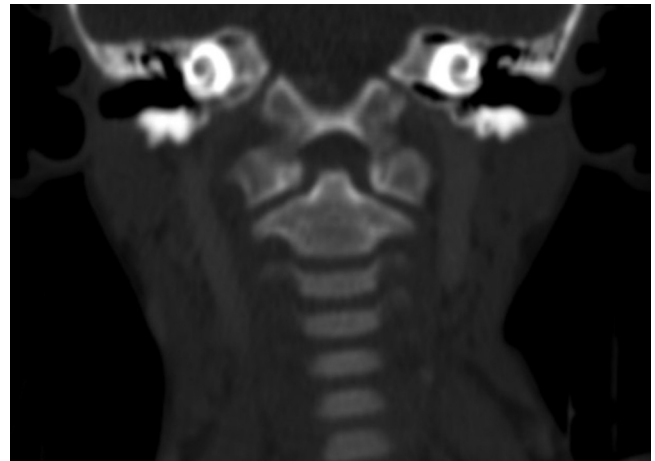


Fig. 7. Reformat CT image showing normal alignment of C1-C2 and a mild edema of the atlantodental ligament.

Table 1
Diagnostic algorithm for Grisel syndrome [6].

- History of ENT Surgery or ENT infection
- Torticollis some days after onset of infection/operation
- Rotation and slight flexion of the head with chin rotated contralaterally
- Painful active and passive rotation of the head
- In the first days of torticollis, elevated CPR and leucocytes, and later normalization of these parameters and usually no fever
- Radiograph of the cervical spine: space between atlas and dens axis > 5 mm.
- CT scan: atlantoaxial subluxation and rotation

joint effusion was detected in the right TMJ. The patient was then discharged, and neurosurgeru follow-up was provided. He kept the cervical collar for 6 weeks, after which there was no recurrence of the AARS.

5. Discussion

As proposed by Welinder at al [7], GS starts as a typical torticollis from the spasm of irritated neck muscles, however, in the prevalence of preexisting lax C1-C2 ligaments, this spasm leads

to subluxation of the atlas and axis. This theory can in fact explain the prevalence of GS in children and Down syndrome patients. Additionally, children have wider atlantodental intervals than the general population.

Battiata et al. [8] advanced the two-hit hypothesis to the GS development: the first hit would be the existing of this baseline laxity and a wider anatomical atlantodental space. Followed by the second hit which would be the induction of spasm caused by the inflammatory mediators carried to the cervical muscles by pharyngovertebral venous plexus. The final phase would be the C1-C2 luxation establishment, with secondary inflammatory changes in the transversal ligament and eventually the reabsorptive decalcification of C1 and C2 seen in cases with greater disease length.

In this case, the simultaneous reactive joint involvement, with a rare development of TMJ effusion, shows that the hematogenous spread of inflammatory mediators through pharyngovertebral venous plexus may in fact reach the pterygoid space, linking the

ear, C1-C2 region and TMJ. That would explain trismus and facial asymmetry in the absence of peritonsillar findings in some late detected cases described in literature.

After the AARS diagnosis is established, conservative treatment can be ideally applied if the disease length is shorter than 2 weeks [9]. Conservative or medical treatment consists of C1-C2 subluxation reduction, treatment of the inflammatory and/or infectious process (antibiotics, muscle relaxants and anti-inflammatory therapy) and cervical mobilization restraint using a Sternal-Occipital-Mandibular immobilizer (SOMI) as the first choice of orthosis or simply the Philadelphia collar as a substitute [10].

The majority of GS patients, as our child, do well if diagnosed early [3]. Intractable cases, with a disease length greater than 2 weeks, can be managed with manual repositioning under general anesthesia followed by Minerva orthosis or halo fixation.

Learning points

- Although rare, GS should be suspected in a child presenting with torticollis after an upper respiratory tract infection or an ENT surgical procedure.
- Prompt diagnosis and treatment usually avoid serious complications.
- Previous ligament hyperlaxity may predispose for the development of GS. Muscular spasm induction through the

haematogenous spread of inflammatory mediators must be an important trigger for the subluxation.

References

- [1] C. Bell, C. McKay, *The Nervous System of the Human Body Embracing Papers Delivered to the Royal Society on the Subject of the Nerves*, Longman, Rees and Orme, London, 1830.
- [2] P. Grisel, *Enucleation de L'atlas et torticollis nasopharyngien*, *Presse Med.* 38 (1930) 50–53.
- [3] P.D. Karkos, J. Benton, S.C. Leong, E. Mushi, N. Sivaji, D.A. Assimakopoulos, *Grisel's syndrome in otolaryngology: a systematic review*, *Int. J. Pediatr. Otorhinolaryngol.* 71 (2007) 1823–1827.
- [4] A. Dagtekin, E. Kara, Y. Vayisoglu, *The importance of early diagnosis and appropriate treatment in Grisel's Syndrome: report of two cases*, *Turk. Neurosurg.* 21 (N4) (2011) 680–684.
- [5] J.W. Fielding, R.J. Hawkins, *Atlanto-axial rotatory fixation*, *J. Bone Joint Surg. Am.* 59 (1) (1977) 37–44.
- [6] C. Deichmueller, H.J. Welkoborsky, *Grisel's syndrome – a rare complication following "small" operations and infections in the ENT region*, *Eur. Arch. Otorhinolaryngol.* 267 (2010) 1467–1473.
- [7] N. Welinder, P. Hoffmann, S. Hakansson, *Pathogenesis of non-traumatic atlanto-axial subluxation (Grisel's syndrome)*, *Eur. Arch. Otorhinolaryngol.* 254 (1997) 251–254.
- [8] A.P. Battiata, G. Pazos, *Grisel's syndrome: the two-hit hypothesis—a case report and literature review*, *Ear Nose Throat J.* 83 (2004) 553–555.
- [9] A. Viscone, C. Brembilla, G. Gotti, *The importance and effectiveness of conservative treatment in Grisel's syndrome*, *J. Pediatr. Neurosci.* 9 (2) (2014) 200–201.
- [10] A. Akbay, B. Bilginer, N. Akalan, *Closed manual reduction maneuver of atlantoaxial rotatory dislocation in pediatric age*, *Childs Nerv. Syst.* 30 (2014) 1083–1089.