

## Unusual association of diseases/symptoms

## Leprosy and rheumatoid arthritis: consequence or association?

Celia Coelho Henriques,<sup>1</sup> Begoña Lopéz,<sup>1</sup> Tiago Mestre,<sup>2</sup> Bruno Grima,<sup>3</sup> António Panarra,<sup>1</sup> Nuno Riso<sup>1</sup><sup>1</sup>Internal Medicine Department 2, Curry Cabral Hospital, Lisbon, Portugal;<sup>2</sup>Dermatology Department, Hospital Curry Cabral, Lisbon, Portugal;<sup>3</sup>Internal Medicine 4 Department, Fernando da Fonseca Hospital, Amadora, Portugal**Correspondence to** Dr Celia Coelho Henriques, [celia.c.henriques@gmail.com](mailto:celia.c.henriques@gmail.com)**Summary**

Leprosy or Hansen's disease is a chronic granulomatous infectious disease caused by *Mycobacterium leprae* with a high prevalence in some developing countries however, it is rarely seen in non-endemic regions. Arthritis has been described in all types of Hansen's disease. Chronic arthritis is known to exist even in paucibacillary forms, resolved or treated disease and in patients without reaction, suggesting a perpetuated inflammatory process. In these cases leprosy can mimic some autoimmune diseases such as rheumatoid arthritis. When a patient with a history of leprosy presents with a symmetric, distal, polyarthritis the diagnosis may not be linear. Possibly it is a rheumatoid-like leprosy arthritis with *M leprae* acting as the trigger element for the chronic process or it is an overlap condition, with a concomitant rheumatoid arthritis? A case report of a patient with a chronic inflammatory arthritis with 10 years of evolution is presented. The differential diagnosis between leprosy and rheumatoid arthritis is discussed.

**BACKGROUND**

Leprosy is a chronic granulomatous infectious disease caused by *Mycobacterium leprae*. The clinical range from tuberculoid to lepromatous leprosy is a result of variation in the cellular immune response to the *Mycobacterium*.<sup>1</sup> Proposed by Ridley and Jopling, disease classification is defined within two poles with transition between the clinical forms.<sup>2</sup> Clinical, histopathological and immunological criteria identify five forms of leprosy: tuberculoid polar form, borderline tuberculoid, mid-borderline, borderline lepromatous and lepromatous polar leprosy.<sup>3</sup>

Data taken by the WHO reveal that the prevalence of *M leprae* infection has been reduced to less than one case per 10 000 in 90% of the endemic countries where leprosy is considered to be a public health problem. However, new case detection rates are still high. Globally 228 474 new cases were detected during 2010 in 130 countries and the prevalence at the beginning of 2010 was still 192 246 cases. Leprosy remains a major problem in some of the emerging economies of Asia, Africa and South America.<sup>4</sup>

Leprosy's clinical manifestations are primarily confined to skin and peripheral nerves. However, musculoskeletal involvement including inflammatory arthritis, though underreported, is quite common. Joint involvement occurs in about 75% of cases of leprosy and at times, is the only presenting manifestation.<sup>5</sup>

Chronic arthritis has been described in Hansen's disease but not associated with the presence of bacilli within the joint. In the majority of patients, the arthritis follows a chronic pattern and is not associated with leprosy reactions.

The role of *Mycobacteria* in the pathogenesis of rheumatoid arthritis (RA) and other types of chronic inflammation has been suggested previously. In particular, mycobacterial heat-shock proteins have been considered important targets of the cellular immune response in patients showing

symptoms of juvenile arthritis, RA and of antibody production in patients with RA.<sup>6</sup>

Recent studies have demonstrated the presence of anti-cyclic citrullinated peptide (anti-CCP) antibodies, known to have a high specificity to RA diagnosis, in various infectious diseases such as tuberculosis, leishmaniasis, Hansen's disease and hepatitis. Anti-CCP antibodies were predominantly observed in patients with tuberculosis, however with a great variability and frequently not related with articular manifestations.<sup>7</sup>

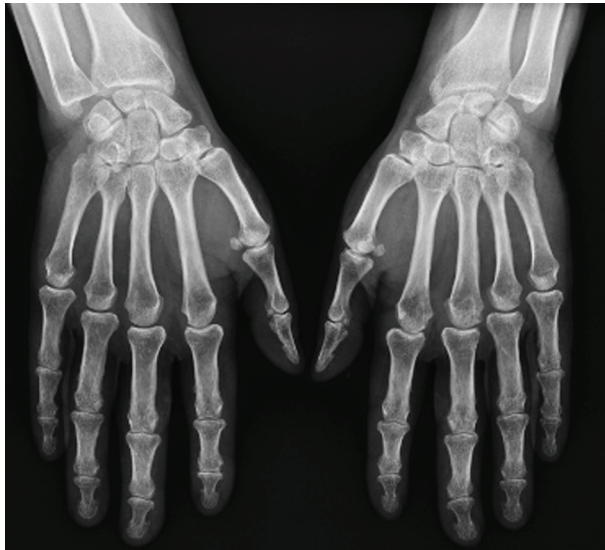**CASE PRESENTATION**

A 47-year-old female patient presented with articular complaints for about 10 years, characterised by symmetric polyarthralgia and polyarthritis of the metacarpophalangeal (MCP) joints, wrists, knees and tibio-tarsal joints. She also had morning stiffness lasting approximately 2 h. Concurrent with the onset of joint complaints, she had large maculo-papular skin lesions (approximately with 5 cm in diameter) hypopigmented, with a roughly symmetric distribution, scattered throughout the back, arms and face, with central hypoaesthesia. She had no painful or thickened nerve routes.

At the time, a borderline Hansen's disease was diagnosed by isolation of *M leprae* on skin lesions. In this context, she started treatment with dapsone, rifampicin and clofazimine with gradual improvement of skin lesions, but persistence of articular complaints. According to the patient, treatment was completed without complications.

She was a heavy smoker since adolescence, of approximately 30 cigarettes a day. She had no other co-existing medical conditions and no chronic medication. No family history of autoimmune diseases has been recorded.

Over the 10 years of joint symptoms she was treated with non-steroidal anti-inflammatory drugs and glucocorticoids in varying doses, with no symptomatic relief.



**Figure 1** Radiography of hands revealed no erosive lesions, only juxta-articular osteopaenia.

On physical examination, she had arthritis of both wrists and symmetrical polyarthralgia of multiple MCF joints. Remaining physical examination was unremarkable, without any skin changes.

#### INVESTIGATIONS

Blood tests showed elevated inflammatory parameters (erythrocyte sedimentation rate 67 mm/h and C reactive protein 2.1 mg/dl), positive rheumatoid factor (RF) of 311 and a highly positive anticitrullinated protein antibody 251 U/ml.

Hands radiography revealed no erosive lesions, only juxta-articular osteopaenia (figure 1A,B).

In this context, according to American College of Rheumatology/European League Against Rheumatism 2010 criteria, the diagnosis of RA was admitted.

At this point, screening for Mycobacterial infection or latent disease was not performed.

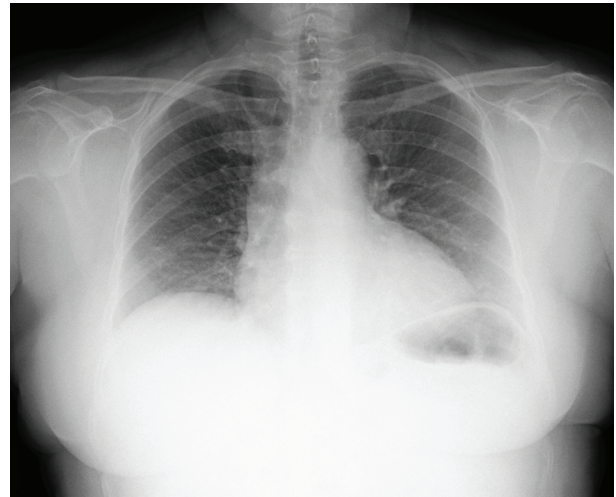
#### TREATMENT

The patient was treated with disease-modifying antirheumatic drugs (DMARD), initially with methotrexate (MTX) and a low dose of prednisolone. The dose of MTX was increased progressively to 20 mg/week. Over 1 year, two more DMARDs were associated – sulfasalazine and hydroxychloroquine at maximum tolerable doses. There was no significant clinical improvement, maintaining polyarthrits and polyarthralgia associated with marked limitation of daily activities.

Before starting biological therapy with antitumour necrosis factor- $\alpha$ , a delayed hypersensitivity skin test reaction using a purified protein derivative test was performed which proved to be highly positive (25 mm). A chest radiography was normal (figure 2).

Considering that epidemiological information was irrelevant, interferon  $\gamma$  release assay for *M tuberculosis* was conducted and was negative.

Given the previous history of Hansen's disease, the patient's medical history was investigated and which suggested that she had interrupted triple therapy for leprosy



**Figure 2** Normal thorax radiography.

(served for 5 months only). The therapy was stopped on its own initiative following an episode of optic neuritis, probably resulting from dapsone.

At this time the diagnosis of RA was questioned. Was it RA or leprous arthritis?

#### OUTCOME AND FOLLOW-UP

Currently, the patient is treated with two DMARDs, MTX 20 mg/week and sulfasalazine 2 g/day, keeping flare-ups of joint inflammation. These episodic flares are controlled with anti-inflammatory medication and alternate with periods of almost remission of articular symptoms.

#### DISCUSSION

Leprosy can present a great variety of signs and symptoms including arthralgia and arthritis similar to that seen in some rheumatic diseases. The articular involvement in leprosy is considered to be the third most frequent manifestation, after dermatological and neurological involvement.<sup>8</sup>

Leprosy typically affects the skin (macules, plaques, papules or nodules, which are hypopigmented and anaesthetic) and the peripheral nervous system (mononeuropathy, mononeuritis multiplex or peripheral neuropathy).<sup>5</sup>

Involvement of the musculoskeletal is a commonly known manifestation, however it's often underdiagnosed.

To date, there has been no formal classification of arthritis in leprosy. However, taking into account the existing bibliographic data, arthritis in leprosy can be divided into two main groups:

1. Acute arthritis of lepra reaction
2. Chronic arthritis

Acute arthritis in leprosy usually occurs as part of lepra reactions – typically, type I reactions, in patients with borderline or paucibacillary disease or type II reactions in patients with lepromatous leprosy.<sup>9</sup> Also a chronic, relapsing, symmetrical, inflammatory, peripheral polyarthrits affecting primarily the wrists, metacarpal and proximal interphalangeal joints of the hands with a RA – like distribution associated with leprosy has been described.<sup>10 11</sup>

Because of similarities in the presentation of arthritis and the joints involved, leprous arthritis frequently simulates RA. The absence of nodules or extra-articular

manifestations, males being more commonly affected than females and response to antileprosy treatment are considered some of the clinical distinguishing features between these two entities.<sup>12</sup>

Radiological abnormalities in patients of arthritis due to leprosy can range from normal joints to joint subluxations and complete destruction.<sup>5</sup>

In leprosy, the presence of autoantibodies associated with systemic manifestations similar to those found in rheumatic diseases can lead to misdiagnosis of these diseases. Besides the large variability in prevalence of different autoantibodies in patients with leprosy reported in the literature, there are few studies correlating the presence of autoantibodies to the articular manifestations in this disease.<sup>13</sup> RF is reported as positive in 70–80% of patients with RA; however, its specificity is limited since RF is also detected in sera from healthy older individuals and patients with various other autoimmune and infectious diseases, including leprosy.<sup>8</sup> Anti-CCP antibodies are considered to be highly specific for the diagnosis of RA.

*Makrygiannakis et al* found that citrullinisation is a common process in inflammation, suggesting that this process is inflammation dependent rather than disease dependent. In this study, biopsy specimens were obtained from patients with inflammatory conditions such as RA, polymyositis (PM), inflammatory bowel disease (IBD) and recurrent tonsillitis were studied. Citrullinated proteins were found in 100% of the cases of RA, PM and chronic tonsillitis and in 70% of the active IBD lesions.<sup>14</sup>

Recent published studies searched anti-CCP antibodies by ELISA in infectious diseases, and the finding of positivity, ranging from 0% to 37%, was higher in Mycobacterial pulmonary tuberculosis, putting in doubt the specificity of this test for the diagnosis of RA. Besides tuberculosis, anti-CCP antibodies were found in a low percentage in numerous infectious diseases (hepatitis C, hepatitis B, Hansen disease, untreated visceral leishmaniasis, Lyme disease, Chagas disease, HIV patients, HTLV-I positive patients, mononucleosis and *Yersinia* infection); however, there is a great variability in its frequency in different studies, probably due to methodological variations.<sup>7</sup>

The symptoms the patient exhibits would allude to a diagnosis of either a leprosy or a RA.

Some points favouring the diagnosis of RA are the fact that is a female patient, the presence of high levels of autoantibodies specific for RA (anti-CCP and RF) and the absence of neuro-cutaneous manifestations suggesting leprosy.

Multiple studies have been suggested an association between smoking and RA. Hutchinson *et al* propose the hypothesis that prolonged heavy cigarette smoking, but not smoking itself, results in increased RF production, explaining in part the relation of increasing pack years smoked and the association with RA.<sup>15</sup> Lundstrom *et al* described a positive association between smoking and the development of anti-CCP positive RA.<sup>16</sup> The described patient was a heavy smoker of about 45 pack years. This is a positive fact favouring the diagnosis of a seropositive RA.

However, after 10 years of evolution of the arthritis it remains non-erosive and there was no improvement with the introduction of targeted therapy for RA, with multiple DMARDs and corticosteroids.

The fact that the onset of joint complaints coincide with the appearance of skin lesions and the diagnosis of Hansen's disease, favours the eventual diagnosis of leprosy arthritis.

A positive response causing reaction to tuberculin test has been occasionally described in patients with lepromatous leprosy. Although the mechanism is not clearly understood, it is suggested that a coincidence of delayed hypersensitivity to tuberculin and a less delayed phenomenon of excessive local edema to systemic features may be responsible for exaggerated changes.<sup>17</sup>

The role of Mycobacteria as a trigger factor in the pathogenesis of RA has been suggested. Holoshitz *et al* described that peripheral blood and synovial fluid T-lymphocytes from patients with RA showed increased reactivity to a mycobacterial fraction that cross-reacted with articular cartilage constituents, especially in patients with 1–10 years of disease duration. The response was considered specific since there was no reactivity to other mitogens or streptococcal antigens, suggesting a direct relationship between the Mycobacterial antigens and the pathogenesis of RA.<sup>18</sup>

Regardless of whether the diagnosis is RA, leprosy arthritis or an overlap of these two entities, the therapeutic approach is necessarily more complicated, taking into account the adverse effects associated with both specific therapy.

Recently, some cases of leprosy have been reported among patients born and resident in countries without leprosy, after treatment with anti-TNF  $\alpha$  agents – infliximab and adalimumab.<sup>9 19</sup>

In conclusion, in order to avoid devastating consequences associated with therapeutic interventions, this case highlights the importance of awareness of leprosy and its various presentations even in the geographical regions where this disease is not endemic.

### Learning points

- ▶ Arthritis in leprosy is common but usually under-recognised, being the third most common symptom.
- ▶ Arthritis can be present in all types of Hansen's disease and in patients without reactions.
- ▶ *M leprae* may trigger chronic immunological responses in genetically predisposed individuals, conditioning a chronic, perpetuated arthritis.
- ▶ Articular manifestations of leprosy can mimic RA and other autoimmune diseases.

**Competing interests** None.

**Patient consent** Obtained.

### REFERENCES

1. Britton WJ, Lockwood DN. Leprosy. *Lancet* 2004;**363**:1209–19.
2. Ridley DS, Jopling WH. Classification of leprosy according to immunity. A five-group system. *Int J Lepr Other Mycobact Dis* 1966;**34**:255–73.
3. Pinheiro RO, de Souza Salles J, Sarno EN, *et al*. Mycobacterium leprae-host-cell interactions and genetic determinants in leprosy: an overview. *Future Microbiol* 2011;**6**:217–30.
4. WHO. Leprosy update; weekly epidemiological record 2011;**86**:389–400. <http://www.who.int/wer> (accessed Feb 2012).

5. **Sandeep C**, Wakhlu A, Agarwa V. Arthritis in leprosy. *Rheumatology* 2010;**49**:2237–42.
6. **Cossermelli-Messina W**, Cossermelli W. Possible mechanisms of chronic leprosy-related arthritis. *Sao Paulo Med J* 1997;**115**:1406–9.
7. **Lima I**, Santiago M. Antibodies against cyclic citrullinated peptides in infectious diseases—a systematic review. *Clin Rheumatol* 2010;**29**:1345–51.
8. **Ribeiro SL**, Pereira HL, Silva NP, *et al*. Anti-cyclic citrullinated peptide antibodies and rheumatoid factor in leprosy patients with articular involvement. *Braz J Med Biol Res* 2008;**41**:1005–10.
9. **Oberstein EM**, Kromo O, Tozmat EC. Type I reaction of Hansen's disease with exposure to adalimumab: a case report. *Arthritis Rheum* 2008;**59**:1040–3.
10. **Cossermelli-Messina W**, Festa Neto C, Cossermelli W. Articular inflammatory manifestations in patients with different forms of leprosy. *J Rheumatol* 1998;**25**:111–9.
11. **Atkin SL**, Welbury RR, Stanfield E, *et al*. Clinical and laboratory studies of inflammatory polyarthritis in patients with leprosy in Papua New Guinea. *Ann Rheum Dis* 1987;**46**:688–90.
12. **Vengadakrishnan K**, Saraswat PK, Mathur PC. A study of rheumatological manifestations of leprosy. *Indian J Dermatol Venereol Leprol* 2004;**70**:76–8.
13. **Ribeiro SLE**, Pereira HLA, Silva NP, *et al*. Autoanticorpos em pacientes com hanseníase, com e sem comprometimento articular, no Estado do Amazonas. *Rev Bras Reumatol* 2009;**49**:547–61.
14. **Makrygiannakis D**, af Klint E, Lundberg IE, *et al*. Citrullination is an inflammation-dependent process. *Ann Rheum Dis* 2006;**65**:1219–22.
15. **Hutchinson D**, Shepstone L, Moots R, *et al*. Heavy cigarette smoking is strongly associated with rheumatoid arthritis (RA), particularly in patients without a family history of RA. *Ann Rheum Dis* 2001;**60**:223–7.
16. **Lundström E**, Källberg H, Alfredsson L, *et al*. Gene-environment interaction between the DRB1 shared epitope and smoking in the risk of anti-citrullinated protein antibody-positive rheumatoid arthritis: all alleles are important. *Arthritis Rheum* 2009;**60**:1597–603.
17. **Waters MF**, Stanford JL. Giant reactions to tuberculin in lepromatous leprosy patients. *Int J Lepr Other Mycobact Dis* 1985;**53**:546–53.
18. **Holoshitz J**, Klajman A, Drucker I, *et al*. T lymphocytes of rheumatoid arthritis patients show augmented reactivity to a fraction of mycobacteria cross-reactive with cartilage. *Lancet* 1986;**2**:305–9.
19. **Scollard DM**, Joyce MP, Gillis TP. Development of leprosy and type 1 leprosy reactions after treatment with infliximab: a report of 2 cases. *Clin Infect Dis* 2006;**43**:e19–22.

This pdf has been created automatically from the final edited text and images.

Copyright 2012 BMJ Publishing Group. All rights reserved. For permission to reuse any of this content visit <http://group.bmj.com/group/rights-licensing/permissions>.  
BMJ Case Report Fellows may re-use this article for personal use and teaching without any further permission.

Please cite this article as follows (you will need to access the article online to obtain the date of publication).

Henriques CC, Lopéz B, Mestre T, Grima B, Panarra A, Riso N. Leprosy and rheumatoid arthritis: consequence or association?. *BMJ Case Reports* 2012;10.1136/bcr.12.2011.5346, Published XXX

Become a Fellow of BMJ Case Reports today and you can:

- ▶ Submit as many cases as you like
- ▶ Enjoy fast sympathetic peer review and rapid publication of accepted articles
- ▶ Access all the published articles
- ▶ Re-use any of the published material for personal use and teaching without further permission

For information on Institutional Fellowships contact [consortiasales@bmjgroup.com](mailto:consortiasales@bmjgroup.com)

Visit [casereports.bmj.com](http://casereports.bmj.com) for more articles like this and to become a Fellow

Keep up to date with all published cases by signing up for an alert (all we need is your email address) <http://casereports.bmj.com/cgi/alerts/etoc>