

Artigos Originais

Torção aguda do cordão espermático: Factor de risco para anticorpos anti-espermatozóides?

Bruno Graça*, Manuel Ferreira Coelho**, Margarida Franco***

* Interno do Internato Complementar de Urologia

** Assistente Hospitalar de Urologia

*** Assistente Hospitalar Graduada de Patologia Clínica

Resumo

Introdução: A torção aguda do cordão espermático é uma urgência urológica dada a isquémia testicular acompanhante, podendo mesmo levar à necrose testicular se não resolvida atempadamente. A correcção cirúrgica passa pela destorção do cordão espermático atingido e orquidopexia bilateral ou, na presença de torção com isquémia testicular irreversível, pela orquidectomia e orquidopexia contralateral. As eventuais sequelas desta entidade clínica independentemente da cirurgia efectuada, passam por alterações quantitativas e/ou qualitativas do espermograma com repercussão ainda mal esclarecida em termos de fertilidade masculina.

Materiais e Métodos: Caracterizámos os valores de testosterona total, espermograma e a presença sérica de anticorpos anti-espermatozóides (AAE) em 9 doentes com torção aguda unilateral do cordão espermático de modo a caracterizar a sua prevalência nesta amostra comparando os resultados com grupo controlo de 15 indivíduos.

Resultados: Todos os doentes obtiveram valores normais de testosterona total sérica. Cinco doentes não apresentaram AAE, representando 55,6% da amostra e quatro doentes apresentaram AAE, representando 44,4% da amostra. O tempo médio entre a cirurgia e a pesquisa de anticorpos foi de 23,75 meses (6-66) para doentes com AAE positivos e 37,2 meses (10-48) para doentes com AAE negativos. O espermograma revelou-se normal em todos os parâmetros avaliados em apenas três doentes (um com AAE e dois sem AAE) e anormal em seis doentes (três com AAE e três sem AAE). Os dois doentes com concentrações mais baixas de espermatozóides apresentavam AAE. Os 15 indivíduos do grupo de controlo não apresentaram AAE.

Conclusões: O nosso estudo aponta a torção do cordão espermático como factor de risco para a presença de AAE e para alterações do espermograma, independentemente da presença de AAE e da correcção cirúrgica efectuada.

Abstract

Introduction and Objectives: Acute testicular torsion is a urological emergency due to the accompanying testicular ischemia, which may even lead to testicular necrosis if not promptly treated. Surgical correction consists of detorsion of the affected spermatic

cord and bilateral orchidopexy or, if there has been irreversible testicular ischemia, orchidectomy and contralateral orchidopexy. The primary objective of this study was to evaluate the presence of antisperm antibody levels after testicular torsion and secondly late total testosterone profile and seminal parameters.

Materials and Methods: Total testosterone levels, semen analysis values and the presence of antisperm antibodies (ASA) were examined in 9 patients with a history of unilateral testicular torsion in order to determine prevalence in this sample compared with the results of a control group of 15 proven fertile individuals. We used Indirect Immunofluorescence Assay (IFA) to evaluate ASA presence.

Results: Five patients were negative for ASA, and four were positive. The mean time between surgery and the antibody studies was 23.75 months (range 6-66) for ASA-positive patients and 37.2 months (range 10-48) for ASA-negative patients. None of the 15 individuals in the control group tested positive for ASA. Total serum testosterone levels were normal in all the patients. The semen analysis was found to be normal on all parameters in only three patients (one with ASA and two without ASA) and was abnormal in six patients (three with ASA and three without ASA). The two patients with the lowest sperm counts were positive for ASA.

Conclusion: Our study suggests that testicular torsion is a risk factor for the development of ASA and for abnormal semen analysis values, regardless of whether ASA are present and what type of corrective surgery was done. Further studies may clarify if and what ASA are clinically important and their major role in the pathogenesis and diagnostics of male infertility.

Keywords: Testicular torsion, Antisperm antibodies

Introduction

Acute testicular torsion occurs more frequently in adolescence, with an estimated incidence of 1:4000 in men under 25 years of age. The majority of follow-up studies show decreased testicular exocrine function even in the unaffected testicle, with the severity of the changes appearing to be directly related to the duration of the torsion (ischemic time).

The existence of a blood-testis barrier (BTB) in the testicles and male genital tract prevents the immune system from entering in contact with the antigenic surface of the spermatozoa. Spermatogenesis that occurs in adolescence is accompanied by the development of intercellular junctions in the Sertoli cells of the seminiferous tubules forming a critical component of the BTB.

Risk factors for the appearance of antisperm antibodies (ASA) include conditions that can damage the BTB, with ductal obstruction being clearly associated with the development of ASA. After vasectomy, approximately 60% of men develop ASA, while only about 30% of men with congenital bilateral absence of the vas deferens develop them.

Clinical evidence is conflicting regarding other predisposing conditions. Apparently testicular torsion is not an important risk factor for the development of ASA, and the role of varicocele, cryptorchidism, genital infection and testicular biopsy as predisposing factors is unclear.

Immunoglobulins (Ig) can enter the genital tract through the seminiferous tubules, epididymis or prostate. IgA and IgG can enter passively and IgA can also be actively secreted. ASA can affect sperm function in different ways, namely in terms of motility, ability to penetrate the cervical mucous, capacitation, acrosome reaction, binding and penetration of the zona pellucida, among others.

Sperm with sluggish motility are suggestive for the presence of ASA. Infertile couples in which the cause of the infertility is unclear, as well as those in which there are changes in motility or agglutination of the sperm are clinical situations associated with increased incidence of ASA.

ASA are detected in approximately 10% of infertile men compared with 2% in the fertile male population and their impact on fertility is directly related to the levels of ASA found.

Objectives

The primary objective of this study is to describe a population of patients who have been undergone surgery for acute unilateral torsion of the spermatic cord with respect to the presence of ASA. The secondary objectives are to determine levels of total serum testosterone and semen analysis results in this population.

Material

A search was made of patients who had undergone surgery for acute testicular torsion at Hospital Fernando Fonseca from 2000 through June 2008.

A total of 45 patients were identified, 31 of whom underwent bilateral orchidopexy (BO) and 14 of whom underwent orchidectomy with contralateral orchidopexy (OCO).

The patients were contacted by telephone and 16 agreed to participate in the study. At the first visit, after the informed consent was obtained, a medical history was taken and a physical exam and scrotal exam was done (see Appendix 1). A scrotal ultrasound was done to obtain testicular dimensions. One patient who was found to have a grade II varicocele was excluded.

Methods

Lab tests were ordered to check for serum ASA and total morning serum testosterone levels, along with a semen analysis. Only 9 patients completed all the tests.

The serum samples for the ASA assays were frozen at -70°C to be tested later by indirect immunofluorescence assay using a positive and negative control. Serum samples from the patients and the control group were diluted to 1:10 in a

phosphate-saline buffer and then added to the sperm cell smears fixed to slides. Each slide had 3 wells where the human sperm cells were fixed.

If there are specific antibodies in the patient's serum, stable antigen-antibody complexes form which bind to a fluorescent labelled anti-human immunoglobulin (polyclonal anti-IgG, IgA and IgM). A positive reaction makes the tails of the sperm turn a fluorescent apple-green when they are viewed under a fluorescence microscope.

The results are interpreted by comparing the fluorescence of the positive and negative controls with our patient samples. The result is qualitative (expressed only as positive or negative), with a reaction deemed positive if the intensity of the fluorescence is 1+ or greater in comparison to the positive control.

A control group of 15 fertile males between 21 and 35 years of age (mean age 28.9), who met all the exclusion criteria and had no history of acute testicular torsion.

Total testosterone levels above 300 ng/dL were considered normal, and semen analysis values were considered normal or abnormal based on volume, concentration, motility and morphology. A change in only one of the values was sufficient for the semen analysis to be classified as abnormal (Table 1).

Results

Only one patient had tried to impregnate his partner after his surgery, and was successful. This patient's lab values were all normal.

One patient who was 10 months post-op OB was found on exam to have an atrophied detorsed testicle measuring <2 cm at its widest diameter, no ASA and abnormal semen analysis values. All the patients had normal total serum testosterone levels.

Table 1. Normal values for sperm analysis according to the 1999 WHO criteria

• Volume	≥ 2.0 mL
• pH	7.0-8.0
• Sperm concentration	≥ 20 million/mL
• Total no. of spermatozoa	≥ 40 million/ejaculate
• Motility	$\geq 50\%$ with progressive motility or 25% with rapid motility within 60 min after ejaculation
• Morphology	$\geq 14\%$ of normal shape and form*
• Viability	$> 50\%$ of spermatozoa
• Leukocytes	< 1 million/mL
• Immunobead test (IBT)	$< 50\%$ spermatozoa with adherent particles
• MAR test**	$< 50\%$ spermatozoa with adherent particles

* Assessment according to Kruger and Menckfeld criteria.
** MAR = Mixed antiglobulin reaction.

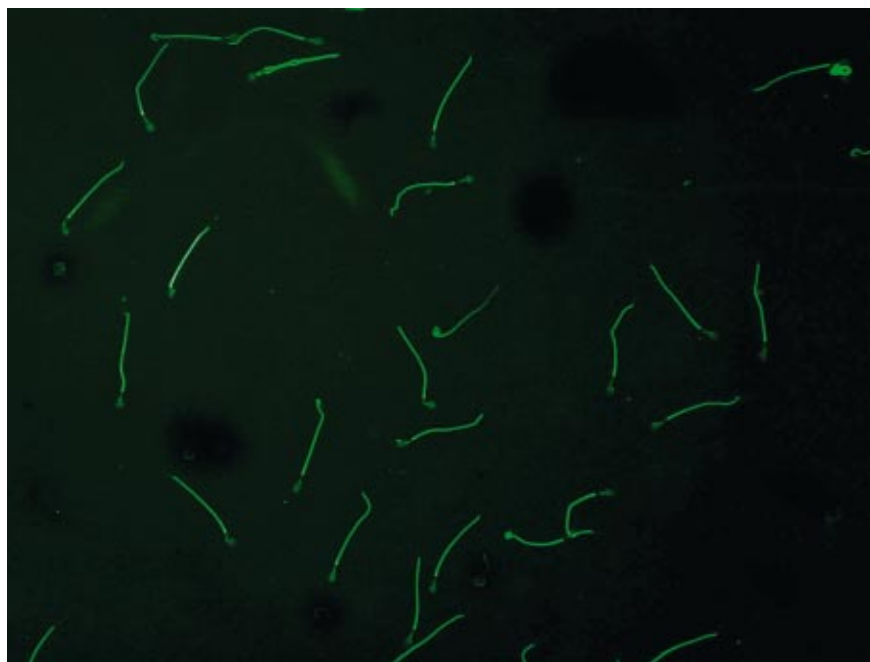


Figure 1. ASA-positive sperm tails image (IFA)

Five patients were ASA-negative and four patients were ASA-positive, of the latter group, 2 had undergone BO surgery and 2 had undergone OCO (Figure 1). Two out of three patients who underwent OCO had ASA, and two out of six patients who underwent BO had ASA. The mean time between the surgery and the antibody study was 23.75 months (range 6-66) for ASA-positive patients and 37.2 months (range 10-48) for ASA-negative patients.

ASA positivity was found in patients with both short and long post-operative follow-up (from 6 to 66 months).

Semen analysis was normal on all the parameters tested in only three patients (one with ASA and two without ASA) and abnormal in six patients (three with ASA and three without ASA). The two patients with the lowest sperm counts were ASA-positive.

The results are summarised in Table 2.

None of the 15 individuals in the control group was ASA-positive.

Discussion

Despite wide variations in daily total testosterone levels, all the patients had values within normal limits, thereby eliminating the need to repeat the tests to recheck below normal values as recommended in international guidelines¹.

The semen analysis likewise show a high degree of temporal intrapersonal variability, with this exam probably having less predictive value due to its being a one-time sample, the need to examine several parameters and the low number of semen analyses routinely done in our laboratory. Although the most common abnormality found was low volume, the patients were advised to abstain from ejaculating for three days prior to collecting the sample, and were instructed in how to collect and transport it. We were unable to demonstrate a tendency for abnormal semen analysis values according to the presence or absence of ASA, however, the results point to testicular torsion as a risk factor for quantitative and qualitative changes in sperm, since 6 out of 9 patients fell outside the normal criteria¹.

Direct tests for detecting ASA look for the presence of antibodies on the patient's sperm itself, while indirect testing methods look for their presence in the patient's serum, generally requiring sperm for a negative control. Since Ig may be present in the seminal plasma and not in the blood serum, direct detection methods are more sensitive. Likewise, the presence of antibodies in the serum does not necessarily mean they are present on the sperm, but the higher the titre found in the serum, the more likely it is that there are also antibodies bound to the sperm. As most authors believe that the only clinically important antio-

ID	Age	Date of Surgery	Surgical Procedure	Pos-op. (months)	ASA	Testosterone (ng/dl)	Semen Analysis	Volume (cc) / Sperm Concentration (millions/ml)	Progressive Motility (%)	Normal Morphology (%)	Notes
AL	29	Aug-04	BO	48	Negative	643,9	N	4 / 416,0	50	70	Pregnancy
JM	24	Sep-04	BO	47	Negative	785,37	Abnormal	0,7 / 91,0	8	X	
LC	17	Nov-04	BO	45	Negative	507,23	N	2 / 102,0	60	X	
IV	18	Aug-05	OCO	36	Negative	584,97	Abnormal	1 / 77,2	50	X	Incomplete liquefaction
RP	17	Oct-07	BO	10	Negative	564,43	Abnormal	1 / 25,6	30	60	Atrophied detorsed testicle
LB	19	Jan-03	BO	66	Positive	409,98	Abnormal	1,5 / 390,4	50	70	
CS	21	May-07	OCO	15	Positive	552,31	Abnormal	1 / 3,2	25	X	
VF	15	Dec-07	BO	8	Positive	902,56	Abnormal	0,5 / 19,2	40	70	
JL	19	Feb-08	OCO	6	Positive	561,61	N	4,5 / 76,8	50	80	

BO=Bilateral Orchiopexy, OC=Orchiectomy with contralateral orchiopexy, N=Normal, X=Not assessed

Table 2. Results of the clinical and laboratory evaluation

dies are those found on the sperm, direct tests are preferred².

Our results did not correspond with some findings in international literature, which do not suggest that testicular torsion is a risk factor for the development of ASA^{3,4,5}. Recently however Arap et al found a tendency for a higher prevalence of ASA, with hormone levels being preserved, in patients with a history of acute testicular torsion, regardless of the type of surgery done⁶. Fu et al corroborated this finding in their series of 10 patients⁷. Currently there is evidence that at least some of these antibodies may cause infertility, the clinical repercussions of ASA depending on which antigens are “blocked”^{8,9}. However, the majority of these antigens and their specific functions are as yet unknown, and as such we do not know which ASA are clinically important^{10, 11, 12}. We are therefore unable to claim

the existence of infertility by the simple presence of ASA.

In cases of immune infertility systemic treatment is not formally indicated, given the medically assisted reproduction techniques available that permit the collection of sperm, oftentimes before it comes in contact with the ASA, e.g. if antibodies are present in the seminal plasma (seminal vesicles and prostate) and the collection is testicular^{13, 14, 15}. The type of antibody is equally important, since while IgM does not easily cross the HTB, the presence of IgA suggests a strong immune response, usually associated with high serum levels of IgG, forming complexes on the sperm even before their principal “immunisation” with the seminal plasma¹⁶. Despite being the principal cause of immune infertility, ASA are only responsible for approximately 1-3% of the aetiology of male infertility (Table 3).

Table 3. Aetiology and distribution of male infertility

Aetiology	Distribution (%)
• Sexual factors	1.7
• Urogenital infection	6.6
• Congenital anomalies	2.1
• Acquired factors	2.6
• Varicocele	12.3
• Endocrine disturbances	0.6
• Immunological factors	3.1
• Other abnormalities	3.0
• Idiopathic abnormal semen (OAT* syndrome) or no demonstrable cause	75.1

* OAT = Oligo-astheno-teratozoospermia.

Conclusions

ASA remain a controversial topic with respect to their risk factors, the ideal method of detecting them, the complexes that are detected and their clinical significance. Their role in infertility of couples is poorly understood and testing for ASA is only recommended in specific circumstances.

Our study suggests that acute testicular torsion is a risk factor for the development of ASA and thus the question of its influence on the fertility of couples remains pertinent and lacks an answer.

References

1. Dohle GR, Jungwirth A, Colpi G, Giwercman A, Diemer T, Hargreave TB. EAU Guidelines on Male Infertility. 2008
2. Emin A, Konova E, Lichev D, Aivazova N, Popov I, Radev R. [The importance of the presence of anti-sperm antibodies in serum and ejaculate of men with infertility]. *Akush Ginekol (Sofia)*. 2008; 47 (2): 26-30
3. Heidenreich A, Bonfig R, Wilbert DM, Strohmaier WL, Engelmann UH. Risk factors for antisperm antibodies in infertile men. *Am J Reprod Immunol*. 1994 Mar-Apr; 31 (2-3): 69-76
4. Hagen P, Buchholz MM, Eigenmann J, Bandhauer K: Testicular dysplasia causing disturbance of spermiogenesis in patients with unilateral torsion of the testis. *Urol Int* 1992;49:154-157
5. Puri P, Barton D, O'Donnell B. Prepubertal testicular torsion: Subsequent fertility. *J Pediatr Surg* 1985; 20: 598-601
6. Arap MA, Vicentini FC, Cocuzza M, Hallak J, Athayde K, Lucon AM, Arap S, Srougi M. Late hormonal levels, semen parameters, and presence of antisperm antibodies in patients treated for testicular torsion. *AJ Androl*. 2007 Jul-Aug; 28 (4): 528-32
7. Fu GB, Qian LX, Cui YG, Xu ZY, Xuan HB, Zhu JG, Zhang W. [Antisperm antibodies induced by testicular torsion and its influence on testicular function]. *Zhonghua Nan Ke Xue*. 2006 Nov; 12 (11): 988-91
8. Chamley LW, Clarke GN. Antisperm antibodies and conception. *Semin Immunopathol*. 2007 Jun; 29 (2): 169-84
9. Francavilla F, Santucci R, Barbonetti A, Francavilla S. Naturally-occurring antisperm antibodies in men: interference with fertility and clinical implications. An update. *Front Biosci*. 2007 May 1; 12: 2890-911
10. Bohring C, Krause W. The role of antisperm antibodies during fertilization and for immunological infertility. *Chem Immunol Allergy*. 2005; 88: 15-26
11. Bohring C, Krause W. Immune infertility: towards a better understanding of sperm (auto)-immunity. The value of proteomic analysis. *Hum Reprod*. 2003 May; 18 (5): 915-24
12. Chiu WW, Chamley LW. Clinical associations and mechanisms of action of antisperm antibodies. *Fertil Steril*. 2004 Sep; 82 (3): 529-35
13. Bronson RA. Antisperm antibodies: a critical evaluation and clinical guidelines. *J Reprod Immunol*. 1999 Dec; 45 (2): 159-83
14. Mazumdar S, Levine AS. Antisperm antibodies: etiology, pathogenesis, diagnosis, and treatment. *Fertil Steril*. 1998 Nov; 70 (5): 799-810
15. Chavez-Badiola A, Drakeley AJ, Finney V, Sajjad Y, Lewis-Jones DI. Necrospermia, antisperm antibodies, and vasectomy. *Fertil Steril*. 2008 Mar; 89 (3): 723
16. Hjort T. Do autoantibodies to sperm reduce fecundity? A mini-review in historical perspective. *Am J Reprod Immunol*. 1998 Sep; 40 (3): 215-22