

Letters to the Editor

Rectal ulcer as a complication of Longo's haemorrhoidopexy

Key words: Stapled haemorrhoidopexy. Rectal bleeding. Post-operative complications.

Dear Editor,

Grade III or grade IV haemorrhoids are best treated with surgical treatment (1).

Clinical case

A 31 years-old man, with grade IV haemorrhoids and sporadic rectal bleeding in the previous year had been treated with stapled Longo haemorrhoidopexy, with no short-term complications.

Six days after the procedure he was admitted in the Emergency Department due to severe rectal bleeding and anal pain. The physical exam was normal and the haemoglobin was 12,7 g/dL.

He was submitted to a surgical reintervention and an area of necrosis with active bleeding was observed. A supplementary haemostatic suture was successfully performed and he was discharged the next day.

The patient returned 24 hours later with the same complains. In the physical exam he was pale, with hypotension and with anaemia (Hb 9,9 g/dL).

A second surgery was performed showing the same features and requiring another supplementary haemostatic suture that was ineffective. Haemoglobin decreased in the following hours to 6,8 g/dL, with the need of blood transfusion.

A flexible sigmoidoscopy revealed, near the suture, an ulcer occupying 2/3 of the wall with a clot in one of its extremities (Fig. 1). An endoscopic treatment with epinephrine's injection (2,5 cc) was done.

The patient was discharged 3 days later without any symptoms or anaemia (haemoglobin 11,4 g/dL).

The follow-up flexible sigmoidoscopy, 2 months later, showed a healed mucosa.

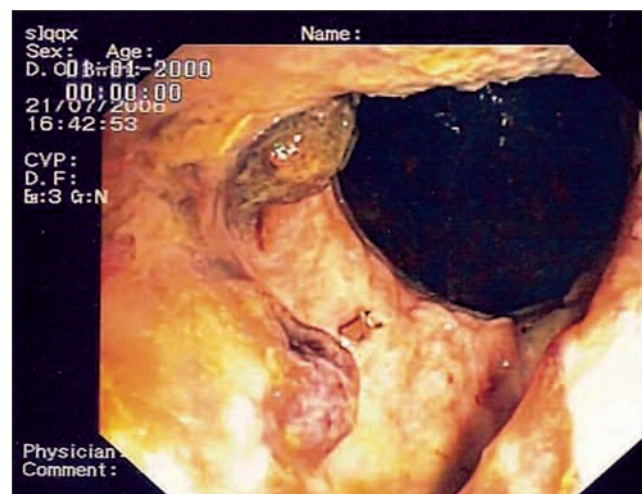


Fig. 1. Below the suture line there's an ulcer occupying 2/3 of the wall with a clot in one of its extremities.

Discussion

Conventional haemorrhoidectomy, like Milligan-Morgan technique, is the most effective treatment but with some post operative morbidity. After this surgery, patients complain about pain caused by the incisional wounds in the perianal skin and needing 2 or 3 days of hospitalization for an analgesic regimen and a recovery period longer than one month (1).

Stapled haemorrhoidopexy (HL) is the possible alternative technique (1,2). Developed by Longo in 1994, it maintains the anal canal's anatomy, creating an anastomosis 3 cm above the dentate line, in an area of low sensibility (3,4), which means less postoperative pain, shorter hospitalization and lower analgesics consumption (2).

Complication rates are similar for both techniques, being the postoperative bleeding the most common complication (1-25%), followed by faecal impactation, abscess or infection and more rarely sphincter's lesion, suture's dehiscence or stricture (2-4).

HL long-term studies as well as comparative trials between the 2 techniques are rare. In the few existing comparative studies, the level of satisfaction is also similar (3).

HL works in the vascular factor (with stapled circular interruption of mucosal and submucosal vascular branches that cause the haemorrhoids) and in the mechanical factor (excision of the excessive prolapsed mucosa, caused by the stretching of the ligaments of Parks and Trietz) (4).

Because this technique does not damage the perianal skin below the dentate line is less painful (3,4). The postoperative pain, specially associated to defecation, although less severe and shorter than the postoperative pain of conventional haemorrhoidectomy, is the most common patients' complain. The pain has several causes: thrombosis of the haemorrhoidary tissue, suture too near of the dentate line or small abscess or inflammation around the suture (5).

Intra- or postoperative bleeding can occur. Intraoperative bleeding rate is around 10%, being treated with haemostatic suture (3,5). Posoperative bleeding happens in 1-4% of the cases, mostly caused by the primary clot' fall among the 7th and 30th day (2,6); there's no preventive treatment, being necessary to perform another surgery with haemostatic suture (2,3).

In our case the bleeding didn't occur only due to the fall of the clot but also because of posoperative ischemia of distal rectum, causing mucosa and submucosa' ulceration with vessels' exposition, although we didn't find similar cases described in world literature. The ischemia would also explain the anal pain.

HL is an excellent procedure for haemorrhoids' treatment, with low morbidity and short hospitalization. However we need to be alert to possible complications that are not yet described, like our case, because this is a new technique.

S. Folgado Alberto, I. Oro¹, P. Sanchez¹, A. Godinho¹,
H. Garcia¹, A. Figueiredo and J. Ramos de Deus

*Services of Gastroenterology and ¹Surgery C.
Hospital Fernando Fonseca. Amadora, Portugal*

References

1. Rowsell M, Bello M, Hemingway DM. Circunferencial mucosectomy (stapled haemorrhoidectomy) versus conventional haemorrhoidectomy: randomised controlled trial. *The Lancet* 2000; 355(4): 779-81.
2. Ceci F, Picchio M, Palimento D, Cali B, Corelli S, Spaziani E. Long-term outcomes of stapled hemorrhoidopexy for grade III and grade IV hemorrhoids. *Dis Colon Rectum* 2008; 51(7): 1107-12.
3. Bikhchandani J, Agarwal PN, Kant R, Malik VK. Randomized controlled trial to compare the early and mid-term results of stapled versus open hemorrhoidectomy. *Am J Surg* 2005; 189(1): 56-60.
4. Gravié JF. Anpexie circulaire dans le traitement des hémorroïdes: technique de Longo. *Encycl Méd Chir* 2000; Techniques chirurgicales – Appareil digestif: Fa-40-685.
5. Ng KH, Ho KS, Ooi BS, Tang CL, Eu KW. Experience of 3711 stapled haemorrhoidectomy operations. *Br J Surg* 2006; 93(2): 226-30.
6. Raahave D, Jepsen L, Pedersen I. Primary and repeated stapled hemorrhoidopexy for prolapsing hemorrhoids: follow-up to five years. *Dis Colon Rectum* 2008; 51: 334-41.