

THE ROLE OF FNAC IN THE PREOPERATIVE DIAGNOSIS OF DERMATOFIBROSARCOMA PROTUBERANS, FIBROSARCOMATOUS VARIANT—a case report

Rita Theias Manso¹, M^a. Manuel Lemos², M^a. Carmo Martins³, M^a. Evelina Mendonça²

¹Surgical Pathology Department - Fernando Fonseca Hospital

²Cytology Laboratory – Portuguese Institute of Oncology (IPO) of Lisbon

³Center of Research and Molecular Pathology – IPO of Lisbon

Introduction:

Dermatofibrosarcoma protuberans (DFSP) is an uncommon low grade cutaneous sarcoma, with a slow progressive but destructive growth pattern, a propensity for local recurrence and which rarely metastasizes. The standard treatment of DFSP is excision with safety margins of 2 to 3cm. A molecular targeted therapy with imatinib is used in locally advanced DFSP with t(17;22), to diminish the tumour size before excision. An accurate cytological diagnosis is crucial in establishing the adequate therapeutic approach, avoiding mutilating surgery.

Case:

The authors report a case of a ten year old african boy, resident in Guiné Bissau, with a locally advanced, recurrent tumour (Fig.1). Fine needle aspiration (FNA) smears showed high cellularity with myxoid matrix in the background (Fig.2). Cells, lying singly and in storiform clusters, were spindle-shaped, with scant cytoplasm, ovoid nuclei with moderate variability in size, smooth nuclear membrane, fine chromatin and one to several small nucleoli (Figs.3 and 4). The cells expressed CD34 (Fig.5). A diagnosis of DFSP, high grade variant, was suggested. A biopsy was performed in order to get enough fresh material for cytogenetic study. Histological pattern correlated well with cytologic aspects, showing a high grade spindle-shaped cell tumor with myxoid features and positivity for CD34 (Figs.6, 7 and 8). Cytogenetic study revealed the translocation t(17;22) and a ring chromosome. The boy was treated with imatinib, before surgery. Clinical response was excellent.

Discussion:

In some series, the authors pointed out the difficulty in making a correct diagnosis from cytomorphology alone because DFSP shares some cytological features with a spectrum of benign and malignant spindle-cell lesions (1). In the present case, differential diagnosis is essentially established with cellular benign fibrous histiocytoma, infantile fibrosarcoma and solitary fibrous tumor for which entities, surgery is the treatment of choice. Others reports emphasize that “ancillary studies are necessary and should be standard in the FNA evaluation of this rare tumor”(2).

Conclusion

FNA with immunostaining emerge as a useful tool in establishing an accurate and reliable preoperative diagnosis, offering patients the advantage of preoperative neoadjuvant therapy and avoiding mutilating surgery in locally advanced cases of DFSP.

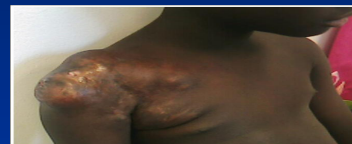

Fig.1: The african boy before treatment, with the locally advanced tumoral mass in the right scapular region with extension to the homolateral hemithorax.

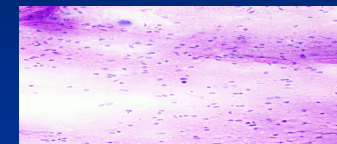


Fig.2 (Giemsa – 40x): FNA with high cellularity with myxoid matrix in the background

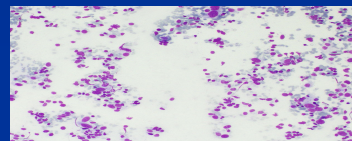


Fig.3 (Giemsa – 100x)

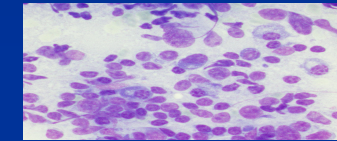


Fig.4 (Giemsa – 400x)



Fig.5 (CD34 – 400x)

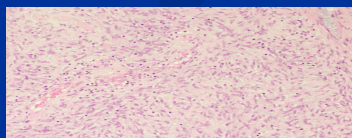


Fig.6 (HE – 40x): radial whorls of spindle cells producing the storiform pattern.

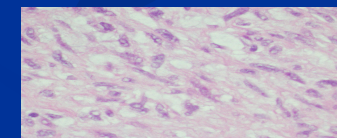


Fig.7 (HE – 400x): plumper spindle cells of myxoid appearance.

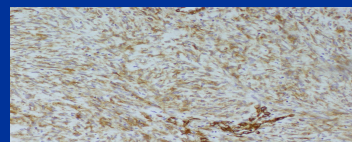


Fig.8 (CD34 – 100x)

References

1. Kljajnenko J., Caillaud J-M, Lagacé R. Fine-Needle Aspiration of Primary and Recurrent Dermatofibrosarcoma Protuberans. *Diagn. Cytopathol.* 2004;30:261-265.
2. Domanski H. A. FNA Diagnosis of Dermatofibrosarcoma Protuberans. *Diagn. Cytopathol.* 2005;32:299-302.

Acknowledgment

The authors acknowledge Caldas G., M.D., from Pediatric Department of IPO of Lisbon.