

# Oral Medicine Case Book 46: Squamous cell carcinoma of the tongue

SADJ February 2013, Vol 68 no 1 p32 - p34

S Stander<sup>1</sup>, A Jefftha<sup>2</sup>, WP Dreyer<sup>3</sup>, B Abdalrahman<sup>4</sup>, A Afrogheh<sup>5</sup>

## CASE REPORT

A 38-year-old-female presented at the Oral Medicine Clinic complaining of pain under her tongue that became worse during chewing, and radiated to her right ear. The pain started two months earlier and gradually increased in intensity. The patient reported that she smoked about twelve cigarettes per day, a habit that she maintained for the last twenty years. She also admitted that she consumed alcohol as a social habit, mainly over the weekends. Her medical history revealed no other abnormalities and she was not using any chronic medication.

The patient was febrile at the time of examination. Extra-oral examination revealed a raised skin lesion on the bridge of the nose and several similar, but smaller, lesions on her cheeks. The skin lesions were darker in colour than the surrounding normal skin and were suggestive of chronic sun damage. A right jugulo-digastric lymph node was found to be swollen and tender, but it was neither fixed nor hard in consistency. Intra-orally, a large crater-like ulcer with rolled and indurated margins was seen on the right lateral border of the tongue (Figure 1). A diffuse leukoplakic patch was present on the right antero-ventral surface of the tongue (Figure 2) and a similar lesion was seen on the contralateral surface of the tongue. In addition, a more pronounced and well-circumscribed leukoplakic plaque was discovered on the floor of the mouth, lingual to tooth 33 (Figure 3).

An incisional biopsy of the ulcer and an excisional biopsy of the leukoplakic patch on the floor of the mouth were performed under local anaesthesia. Both biopsies were sent for histopathological investigation and the patient was instructed to use 0.2% aqueous solution of chlorhexidine digluconate as an antibacterial mouthwash, twice daily. The patient

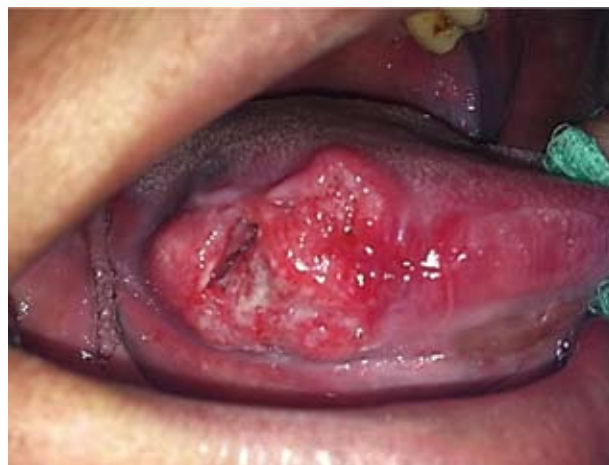## ACRONYMS

**MRI:** Magnetic Resonance Imaging  
**SCC:** Squamous Cell Carcinoma  
**OTSCC:** Oral Tongue Squamous Cell Carcinoma

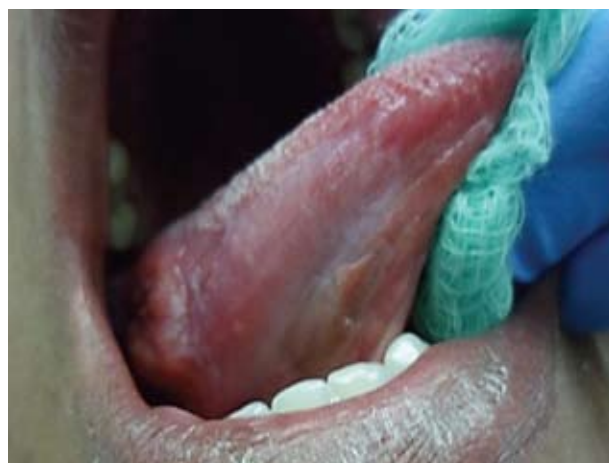was advised to refrain from smoking and requested to return a week later for suture removal and further consultation.

## DIAGNOSIS AND MANAGEMENT

The clinical appearance of the ulcer was suggestive of a squamous cell carcinoma, a traumatic eosinophilic ulcer or a syphilitic/tuberculous ulcer. Histopathological evaluation of the specimen taken from the margin of the ulcer showed



**Figure 1:** At the initial presentation an indurated ulcer with rolled margins was seen on the right lateral margin of the tongue.



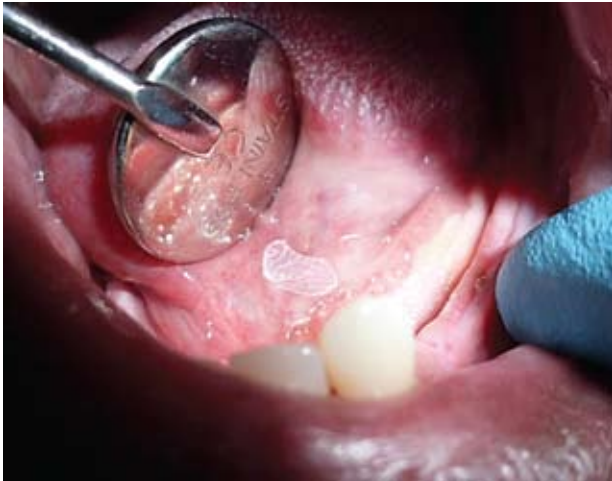**Figure 2:** A diffuse leukoplakic patch was present on the right antero-ventral surface of the tongue.

1. **S Stander:** *BChD, PDD*. Division of Oral Medicine and Periodontics, Faculty of Dentistry, University of the Western Cape.
2. **A Jefftha:** *BChD, MChD*. Division of Oral Medicine and Periodontics, Faculty of Dentistry, University of the Western Cape.
3. **WP Dreyer:** *BDS, HDipDent, PhD, FCD(SA)OMP*. Division of Oral Medicine and Periodontics, Faculty of Dentistry, University of the Western Cape; Professor Emeritus, Stellenbosch University.
4. **B Abdalrahman:** *BDS, MSc (Pharmacology)*, Division of Oral Medicine and Periodontics, Faculty of Dentistry, University of the Western Cape.
5. **A Afrogheh:** *BChD, MChD*. Division of Oral Pathology, Faculty of Dentistry, University of the Western Cape; National Health Laboratory Service, Tygerberg.

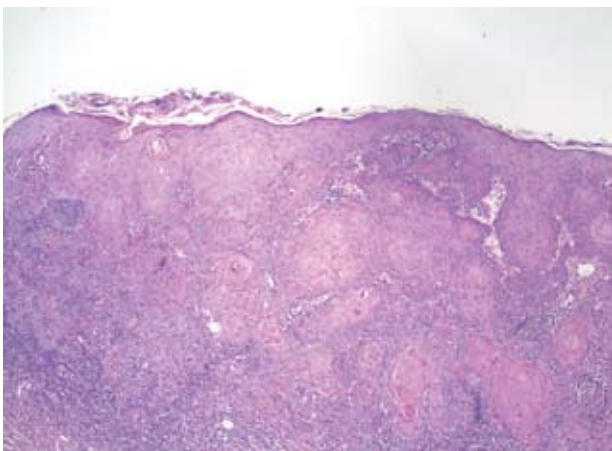
### Corresponding author

**WP Dreyer:**

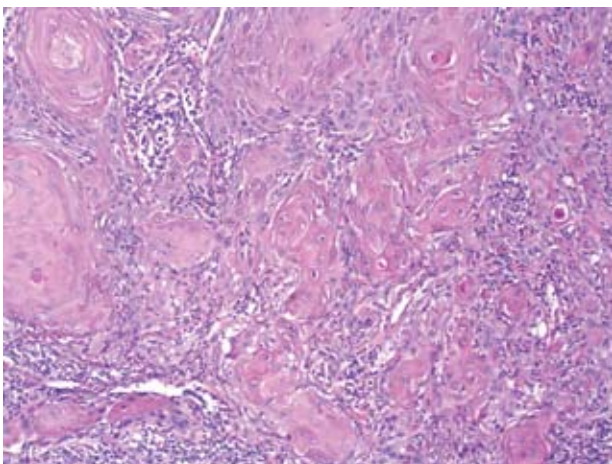
PO Box 1285, Sedgefield, 6573; E-mail [wpd@sun.ac.za](mailto:wpd@sun.ac.za)



**Figure 3:** A well-defined leukoplakic patch was present on left ventral surface of tongue, lingual to tooth 33, and extending onto the floor of the mouth.



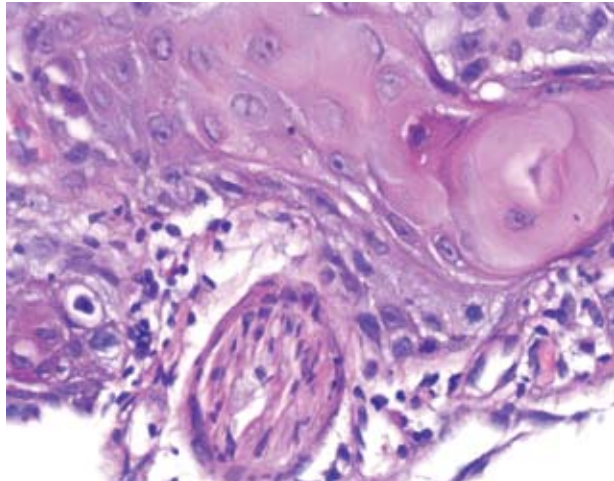
**Figure 4:** This photomicrograph shows a well-differentiated, infiltrating, keratinising squamous cell carcinoma arising from the overlying surface epithelium (H & E, x40).



**Figure 5:** This photomicrograph shows cohesive nests of squamous cell carcinoma associated with a dense lymphocytic host response (H & E, x200).

a well-differentiated, infiltrating, keratinising squamous cell carcinoma with perineural invasion (Figures 4, 5 and 6). Histological assessment of the leukoplakic patch, floor of the mouth, however, revealed hyperkeratosis and chronic inflammation with no evidence of malignancy.

At the scheduled follow-up visit, the histopathological findings were discussed with the patient and she was referred to the Department of Head and Neck Oncology for further evaluation and management. At a later visit the patient re-



**Figure 6:** This image shows perineural invasion at the edge of the biopsy: an island of squamous cell carcinoma is seen surrounding a minor nerve (H&E, x400).

ported that she was undergoing a seven weeks treatment regimen consisting of daily radiotherapy combined with weekly chemotherapy. She also mentioned improvement of her symptoms of pain and discomfort and was more comfortable eating solid foods. Nevertheless, she continued to smoke. Upon completion of her treatment, a further MRI will be done to evaluate the need for surgical removal of any residual disease. She was also referred to the dermatology clinic for evaluation of the skin lesions.

## DISCUSSION

The present case is not typical squamous cell carcinoma (SCC) of the tongue. Traditionally, SCC of the tongue occurs more often in men in their sixth to eighth decades of life, especially in individuals with a history of high tobacco usage and daily alcohol consumption. Most studies have reported smoking 20 cigarettes or more per day and consuming alcohol on a daily basis, at a rate of three to four drinks per day, as a significant combined risk factor for SCC of the tongue.<sup>1,2</sup> Although the present patient reported smoking cigarettes and consuming alcohol on a regular basis, her levels of consumption are somewhat lower than those used in the studies cited above. However, patients often under-report their consumption of tobacco and alcohol. Despite the patient's relatively young age, she also presented with leukoplakic patches which are generally considered to be potentially malignant and caused by smoking and probably also alcohol abuse. It is possible that the co-existence of these lesions could indicate a higher level of tobacco and alcohol use than the patient was willing to admit. Alternatively, the fact that the skin of her face showed advanced signs of sun-damage could indicate a genetic susceptibility to harmful agents.

The tongue is a complex organ which can be divided into two portions: the oral tongue and the base of the tongue. The former encompasses the anterior two-thirds and consists of dorsal, lateral and ventral surfaces, whilst the posterior, or base of the tongue, is that part of the tongue posterior to the circumvallate papillae, often considered to be part of the oropharynx.<sup>3,4</sup> It is reported that 50-70% of all tongue carcinomas occur on the lateral border of the tongue at the junction between the oral tongue (i.e. anterior two-thirds) and the base of the tongue (i.e. posterior one-third),<sup>1</sup> as seen in the present case. Another common site is the base of the

tongue and about one-third of all squamous cell carcinomas of the tongue arise in that site. This is a particularly difficult site to examine and, furthermore, the base of the tongue carcinomas are less inclined to be symptomatic.<sup>1</sup> Consequently these lesions are more advanced at the time of diagnosis, the reason why they carry an unfavourable prognosis. SCC rarely develops on the dorsum or tip of the tongue.

Tongue carcinoma is usually asymptomatic, with pain or dysphagia experienced only when deep invasion occurs. Squamous cell carcinoma of the tongue is the most common malignant intra-oral neoplasm and represents between 25% and 40% of all oral malignancies (with lip lesions being excluded). As outlined above, tobacco usage in any form (smoking, chewing, and snuff dipping), in conjunction with heavy daily alcohol consumption, is reported to be associated with up to 80% of all oral cancer cases in western countries.<sup>1,2,6</sup> Alcohol is thought to act as a synergistic agent, either as a co-carcinogen or as a solvent for carcinogenic chemicals released during smoking.<sup>1</sup> Although all forms of tobacco use are harmful to the health of the oral tissues, carcinoma of the tongue is mostly associated with cigarette smoking. With the rise in cigarette smoking in the younger segment of the population in many countries, it is not surprising that an increasing number of younger patients, worldwide, are diagnosed with oral carcinomas. In recent studies, up to 5.5% of all new cases are seen in persons younger than 40 years of age and in these persons the lesions often exhibit a particularly aggressive behaviour.<sup>3,7</sup> The proportion of women with oral squamous cell carcinoma, in the under-40 age group, is higher than seen in the traditional population at risk, probably due to an increasing tendency for younger women to smoke and consume alcohol on a daily basis. In addition, an increase in the incidence of oropharyngeal carcinoma associated with the human papilloma virus has been recorded in females, and also in males, both in smokers and non-smokers.<sup>3,7</sup> Other causal factors that may play a role include a genetic predisposition, infections with oncogenic viruses, environmental exposure to oncogenic agents, poor oral hygiene, diet and immune deficiencies.<sup>2,3,6</sup>

Metastatic spread of squamous cell carcinoma of the tongue is facilitated by the tongue's rich lymphatic network and the risk increases with the size of the primary tumour. Approximately 50% of tongue cancers present with lymph node involvement<sup>3</sup> and lesions of the base of the tongue are often advanced or have metastasised regionally by the time they are discovered, reflecting a significantly poorer prognosis for such lesions than those of the anterior two thirds of the tongue. The first nodes to become involved are the submandibular or jugulo-digastric nodes at the angle of the mandible. In exceptional cases, distant metastatic spread may be seen in the lung or the liver.<sup>5</sup>

Management of squamous cell carcinoma of the oral cavity is based on the location and stage of the primary tumour. Local surgery of the primary tumour, with a 1 to 1.5cm margin of clinically normal-appearing soft tissue at the periphery of the lesion, is the most commonly employed treatment modality. A partial glossectomy, or hemi-glossectomy, may be needed in cases where wide local excision is indicated in a specific case and a concomitant neck dissection is performed in cases with palpable cervical lymphadenopathy. Radiotherapy is employed in cases where primary surgery is impossible or contraindicated.<sup>5</sup> The prognosis of carcinoma of the tongue varies with site and stage of the primary lesion: it is poorer for base of tongue lesions and

in cases where the primary tumour extends into contiguous tissues and/or has spread to lymph nodes. The latter is most often seen in base of tongue lesions as compared with lesions of the oral tongue which usually have a better prognosis.<sup>1</sup> Once a patient displays lymphatic spread, the survival rate of squamous cell carcinoma of the tongue decreases substantially; in fact, it drops by 50%. According to data from population-based cancer registries, the overall five-year survival rate of carcinoma of the oral tongue cancer is around 53%, compared with 33-40% for the base of tongue lesions.<sup>4</sup>

## CONCLUSION

The present case is a reminder that carcinoma of the tongue, as opposed to earlier descriptions in the literature, can occur in younger females particularly in those individuals who smoke and consume alcohol on a regular basis. Many cases of squamous carcinomas in young females, however, are not associated with these risk factors and it is thought that genetic predisposition and/or aberrant immune factors may play a major role in such cases. The need for oral cancer screening in young females is thus emphasised. This must include a detailed history and a thorough examination of all oral tissues, including the base and ventral surface of the tongue. Despite the ready accessibility of the oral cavity to direct examination, oral malignancies are often not detected until at an advanced stage - with devastating consequences for the patient. Early detection of these lesions is thus essential to improve the prognosis of SSC of the tongue. This requires a dedicated educational effort directed at the population at large, and relevant health care professionals, to ensure that all parties remain informed on the serious nature of the disease and how it can be prevented.

**Declaration:** No conflict of interest declared.

## References and \*recommended reading

- \*Gorsky M, Epstein JB, Oakley C, Le ND, Hay J, Stevenson-Moore P. Carcinoma of the tongue: a case series analysis of clinical presentation, risk factors, staging, and outcome. *Oral Surg Oral Med Oral Pathol Oral Radiol Endodont* 2004; 98: 546-52.
- Bacher G, Hod R, Goldstein DP, Irish JC, Gullane PJ, Brown D *et al.* Outcome of oral tongue squamous cell carcinoma in patients with and without known risk factors. *Oral Oncol*, 2011; 47: 45-50.
- Patel SC, Carpenter WR, Tyree S, Couch ME, Weissler M, Hackman T *et al.* Increasing incidence of oral tongue squamous cell carcinoma in young white women, age 18 to 44 years. *J Clin Oncol* 2011; 29: 1488-94.
- \*Zhang L, Zhou X, Yao X, Wu Y, Zhang Q, Zhang L. Oral tongue cancer patients show a better overall survival than base of tongue cancer patients. *J Cancer Res Clin Oncol* 2012; 138: 341-6.
- Regezi JA, Sciubba JJ, Jordan RCK. *Oral Pathology: Clinical Pathologic Correlations*. 5th ed. Saint Louis: Saunders Elsevier: 2008: 48-54.
- Albuquerque R, López-López J, Marí-Roig A, Jané-Salas E, Roselló-Llabrés X, Santos JR. Oral tongue squamous cell carcinoma (OTSCC): alcohol and tobacco consumption versus non-consumption. A study in a Portuguese population. *Brazil Dent J*. 2011; 22: 517-21.
- Toner M and O'Regan EM. Head and neck squamous cell carcinoma in the young: a spectrum or a distinct group? Part 1. *Head Neck Pathol*. 2009; 3: 246-8.
- Gueiros LA, Coletta RD, Kowalski LP, Lopes MA. Clinicopathological features and proliferation markers in tongue squamous cell carcinoma. *Int J Oral Maxillofac Surg* 2011; 40: 510-5.