

A Comparison of Two Liner Materials for Use in the Ferric Sulfate Pulpotomy

SADJ July 2008, Vol 63 no 6 p338 - p342

Dr. N Mohamed: BChD, BSc (Hons), MSc (Paediatric dentistry). Lecturer/ Snr Dentist, Department of Paediatric Dentistry, University of the Western Cape, P. O. Box X1, Tygerberg, 7505, Cape Town, Tel: (021) 937 3073 (office), Cell: 083 270 5105, Fax: (021) 638 4503, E-mail: namohamed@uwc.ac.za.

SUMMARY

Objectives: The aim of this study is to compare the success rate obtained when applying either a calcium hydroxide (Dycal) base or a zinc oxide-eugenol (Kalzinol) base following the traditional ferric sulfate pulpotomy.

Methods: Patients were either treated in the chair or under general anaesthesia. All teeth had to have radiographic evidence of caries close to the pulp. After haemostasis was achieved with damp cotton pellets, ferric sulfate was applied to the pulpal stumps. Half of the cases then received a Dycal base followed by a cured layer of Vitrebond and a permanent amalgam restoration. The other half of the cases received a base of zinc oxide-eugenol (Kalzinol) followed by an amalgam restoration. The cases were followed up every 6 months for one year (ie. 2 follow-up visits). Radiographs were taken at each follow-up visit.

Results: Overall, teeth treated with Dycal demonstrated a higher failure rate when compared with those that received the Kalzinol base. Abscess formation and internal resorption were the most common causes of failure. Even though the Kalzinol base demonstrated greater success, there were still quite a few failures.

Conclusion: This study demonstrates that calcium hydroxide cannot be recommended as a medicament in primary tooth pulpotomies.

INTRODUCTION

Pulp therapy in the primary dentition has always been a source of much controversy. Different pulpotomy techniques and medicaments have been covered extensively in the literature, but due to the increasing awareness of the potential deleterious effects of some of these medicaments, a need has arisen in the dental profession to find safer, alternative pulpotomy agents. Ferric sulfate and calcium hydroxide have been suggested as possible, more biologically acceptable alternatives to formocresol, which is known for its toxic side effects^{1, 2, 20, 21}. Ferric sulfate is one of the most recent agents used in vital pulp therapy and has enjoyed reasonable success^{3, 4, 21}.

Unlike formocresol, ferric sulfate does not fix pulp tissue⁵. The base placed over the pulp could therefore play a significant

role in the outcome of the pulpotomy procedure. In the case of formocresol pulpotomies, the pulp tissue is fixed^{6, 7}, making it less susceptible to the effect of the base.

Ferric sulfate was proposed as a pulpotomy agent on the basis of its action^{8, 9}. Ferric sulfate reacts chemically with blood proteins, causing agglutination. A metal ion-protein complex is then formed at the surface of the pulpal stump. The membrane of this complex seals the cut blood vessels mechanically, producing haemostasis and preventing blood clot formation^{3, 9, 10, 20}. As the failure of calcium hydroxide pulpotomies has often been ascribed to the presence of a blood clot between the pulp tissue and the medicament^{11, 20}, it was thought that the use of ferric sulfate might increase the chance of success of calcium hydroxide pulpotomies.

Further controversy also exists in terms of the type of base which is placed over the amputated pulp. The choice of the base seems to determine the pulpal response. Two bases, calcium hydroxide (Dycal) and zinc oxide-eugenol (Kalzinol), have both been used in separate studies, but the pulpal responses that these bases elicit have never been compared.

The objective of this study was to compare the clinical and radiographic outcomes of the basic ferric sulfate (Astringedent) pulpotomy technique where a Dycal base placed over the amputated pulp is compared with a Kalzinol base. The aim of this study was to include approximately 20 to 30 children in each group.

MATERIALS AND METHODS

For a child to be included in the study, the following criteria had to be met:

- Absence of any medical condition that would be a contra-indication for pulp therapy.
- Absence of clinical signs of non-vitality such as an abscess, soft tissue swelling, mobility or tenderness to percussion. In other words, the tooth had to be vital.
- Absence of radiographic signs of pulpal necrosis such as apical or furcal radiolucencies, internal resorption or pulpal calcifications.
- There had to be radiographic evidence of caries close to the pulp or involving the pulp horns.
- No history of spontaneous pain

SUPER
COREGA

Let your patients Eat, Speak
and Smile with Confidence.

GREY 121861/SADJ



It's a sad fact of life: what we look like affects how we feel, and how we feel affects how we cope with our day-to-day life. For people with dentures, even normal social situations can become nerve racking, fearsome affairs, where they spend so much time worrying about how their teeth look, that they can't be themselves.

That's where Super Corega Denture Fixatives come in. By improving both a denture's fit and hold, Super Corega Denture Fixatives give users the freedom to engage with others when they go out. And by supplying up to 55% more bite force¹, they can enjoy all the foods they like – noticeably improving even well fitted dentures. But Super Corega Denture Fixatives aren't just about smiling. Its all day hold forms a seal that keeps food out, stopping small particles getting stuck and creating foul odours.

If you used to prescribe Poligrup to your patients, you'll be pleased to know that it isn't gone. It has just been taken into the unified Super Corega Denture Fixatives brand, along with Polident – which is now available as Super Corega Denture Cleansing Tablets.

So don't let your patients' lives be derailed by the daily problems encountered with dentures. Help them out, and recommend Super Corega Denture Fixatives to them. So they can eat, speak and smile with confidence.



Super Corega allows you to Eat, Speak and Smile with Confidence.

1. Stern PB, Aggour SM et al. Denture adhesive holds all day. Int Dent J 2003 53:347
GlaxoSmithKline, South Africa (Pty) Ltd, 57 Sloane Street, Bryanston, 2021 Consumer Care Line Tel: 0800 118 274. email: consumer.careline@gsk.com

This research was done under the auspices of the University of Stellenbosch (now the University of the Western Cape) in Cape Town. All children included in the study were routine patients at the university's School of Oral Health Sciences. Consent was obtained from the parents and the Research Committee of the University of Stellenbosch approved the protocol for this study.

Depending on the situation, treatment was either performed under general anaesthesia or using local anaesthetic. The standard ferric sulfate pulpotomy as described by Fuks *et al.*¹⁰ and Ibricevic *et al.*⁹ was used in this study. The clinical technique involved the following:

1. The cavity was prepared with a fast handpiece with continuous water cooling.
2. After the removal of all caries, the roof of the pulp chamber was removed.
3. The coronal pulp was then amputated using either a large, sterile caries bur in a slow handpiece or an excavator. Teeth had to be vital, in other words, normal, light red blood had to be evident upon exposure of the pulp.
4. Bleeding was brought under control with the aid of damp cotton pellets.
5. 15.5% Ferric sulfate (Astringedent, Ultradent Products) was applied with a cotton pellet for 15 seconds (with continuous friction). Haemorrhage control was assessed and ferric sulfate was re-applied if bleeding did not cease.
6. The tooth was gently rinsed to remove the ferric sulfate and any remaining debris.
7. Every alternate patient (i.e. one half of the cases) had a calcium hydroxide base placed over the amputated pulp. Dycal (Dentsply Caulk) was used in this instance. If haemorrhage occurred after the placement of the medicament, it was gently blotted with sterile cotton pellets. A glassionomer lining, Vitrebond (3M Dental Products), was mixed according to the manufacturer's instructions and then placed over the Dycal layer and cured for 20 seconds. This was followed by the placement of a permanent amalgam (Dispersalloy, Dentsply Caulk) restoration.
8. In the other half of the cases, a zinc oxide-eugenol base, Kalzinol (Dentsply De Trey) was mixed according to manufacturer's instructions until it could be rolled between the fingers without sticking. It was placed over the amputated pulp with the aid of a damp cotton pellet. This was then followed by the placement of a permanent amalgam restoration. In patients that required more than one pulpotomy procedure, both techniques were employed, but in different teeth.
9. Occlusion was checked and relieved where necessary.

With the follow-up examination, it was not known beforehand which pulpotomy agents were used. Conclusions were drawn without this prior knowledge, ensuring an unbiased view. Where possible, the cases were followed up every 6 months for 1 year (i.e. 2 follow-up visits) or until the teeth exfoliated. Radiographs were taken at each follow-up visit. The

patients were examined and the pulpotomized teeth were evaluated.

Clinical signs of failure included:

- presence of a draining sinus or swelling
- reports of pain
- mobility (not due to the exfoliation process)

Radiographic signs of failure included:

- recurrent caries
- evidence of pathology such as periapical and/ or furcal radiolucencies
- signs of internal and/ or external resorption
- If a pulpotomy failed, the tooth was either subjected to root canal treatment or it was extracted.

RESULTS

In this study, a total of 38 teeth were treated. Nearly 50% of the cases were performed under general anaesthesia and the rest were completed using local anaesthetic. The children ranged in age from 3 to 10 years with a mean age of 5.9 years.

A total of 22 teeth received a Kalzinol base and 16 received the Dycal and Vitrebond base. Twenty-one pulpotomies were performed on first primary molars and 17 were performed on second primary molars.

The statistical analysis involved the use of binary data and comparisons of the two groups at a given time of follow-up was carried out in terms of proportions of successes, Chi-squared and Fisher exact tests being of significance.

In teeth treated with the Kalzinol base, 5.26% of patients experienced pain after 6 months. Sinus formation was evident in 5.26% of cases. Patients who received the Dycal base ex-

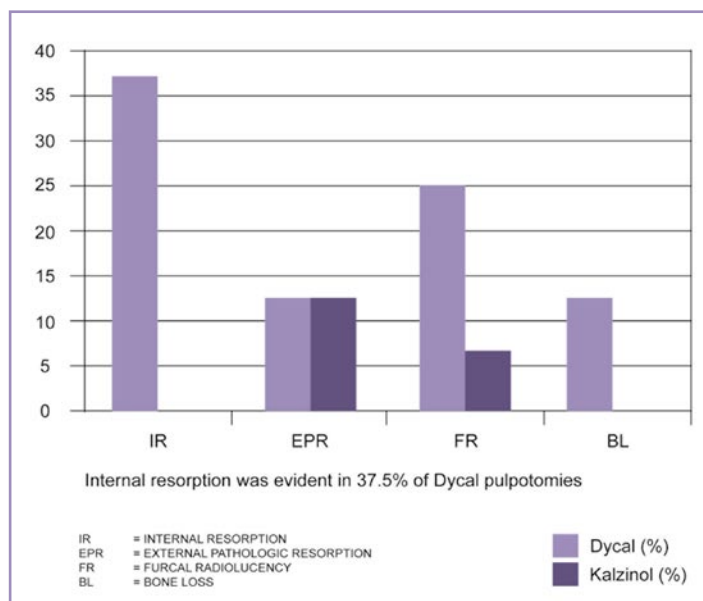


Figure 1: Radiographically demonstrable pathology at 6 months

perienced pain in 38.46% of cases with sinus formation evident in 46.15% of patients.

After 6 months, the Dycal pulpotomy had a clinical success rate of 53.85% while the Kalzinol pulpotomy was successful in 94.74% of cases. Radiographically, the success rate at 6 months was lower at 50% and 81.25% for the Dycal and Kalzinol pulpotomy procedures respectively.

At first glance, the results appear to indicate that there is a significant difference between the two materials. However, one should bear in mind that the small sample size could influence the results. This is especially relevant in the Dycal group. The reason for this is that it was not possible to take follow-up x-rays in many of the patients due to poor cooperation.

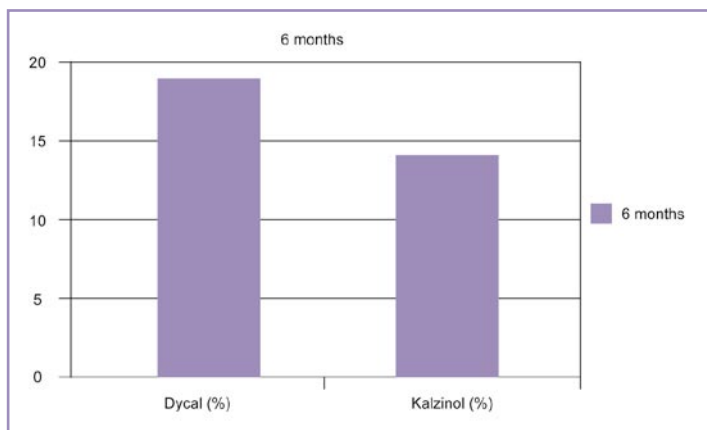


Figure 2 : Percentage of patients who failed to keep appointment

Figure 2 indicates the percentage of patients who failed to keep appointments. This was one of the problems encountered in this study.

DISCUSSION

Until recently, the standard pulpotomy treatment was the 5-minute formocresol devitalisation pulpotomy which partially mummified the pulp tissue. This technique replaced the initial multiple visit technique, which resulted in complete mummification of the pulp tissue. However, due to the proven toxicity of formocresol, the popularity of this technique has waned^{6, 10, 12, 13, 20}.

Ferric sulfate has been suggested as a less toxic pulpotomy agent and it is gaining popularity worldwide. A number of studies have confirmed the success of this method^{3, 6, 9, 10, 12}. Success rates of the ferric sulfate pulpotomy have been shown to be similar to those achieved with the formocresol pulpotomy^{6, 8, 12}.

In pulpotomy procedures, zinc oxide-eugenol cement is the most commonly used base material. It has, however, been shown to cause a moderate to severe inflammatory response with resulting chronic inflammation and necrosis^{3, 12, 14, 15}. Heilig *et al.*¹⁶ used a temporary filling material, Cavit, instead of a zinc oxide-eugenol base and achieved favourable results.

The choice of base is thought to influence the pulpal response. Calcium hydroxide and zinc oxide-eugenol have both been used in separate studies, but have never been compared. The purpose of the present study is to compare the success rate obtained when applying one or the other of these two bases following a ferric sulfate pulpotomy. Kalzinol is an example of a zinc oxide-eugenol cement which was used in this study and Dycal is the calcium hydroxide preparation which was used.

Instead of the usual zinc oxide-eugenol base, Vitrebond was used as a lining over the calcium hydroxide. The reason behind this was to eliminate the potential irritating effect of the zinc oxide-eugenol, making it possible to compare a Dycal base to a Kalzinol base. Vitrebond is a light-cured glassionomer base with good properties. It can be easily applied and could serve to seal the pulp, thereby preventing microleakage and stimulating reparative dentine formation.

OBSERVATIONS

The putty-like consistency of Kalzinol made it easy to manipulate and easy to place. It could be compressed gently into the pulp chamber with the aid of a damp cotton pellet. The technique was quick and this was an added advantage, especially in the treatment of difficult children. Thus, in children who displayed poor cooperation, this placement technique was favoured. It was also favoured in cases where access and visibility was limited.

The pulpotomy procedure in which Dycal was used, was more labour intensive and technique sensitive. Dycal adhered with difficulty to the exposed pulp and it was generally more difficult to place. The procedure took much longer because the Dycal did not stay where it was placed and often had to be re-applied. Bleeding often recurred, making another application of ferric sulfate necessary. This resulted in increased trauma to the pulpal tissue. The longer treatment time also meant that there was a greater chance of bacterial and/or saliva contamination.

Vitrebond was chosen over Vitremer (3M Dental Products) as the glassionomer lining because it is not as viscous as Vitremer and is easier to place. Vitremer has a thick, sticky consistency and is difficult to handle.

The Vitrebond layer which was placed over the Dycal took up a lot of space, often leaving little room for the amalgam. This was especially difficult in the smaller teeth. This could possibly make the amalgam restoration more susceptible to fracture.

On the whole, the calcium hydroxide pulpotomies were more demanding. This was also a finding in the literature⁶.

In this study, internal and external resorption as well as furcal radiolucencies were the most common radiographic findings indicative of pulp pathology in pulpotomies where the Dycal base was applied. This severe reaction could have been

due to the questionable prognosis of the pulp at the time of pulp amputation^{11, 16}. Pulp canal obliteration was seen in one case, but this has been regarded as a sign of success by many authors^{10, 17}.

Furcal radiolucencies and external resorption were the most common pathological changes observed on the radiographs in the Kalzinol pulpotomies. The radiographic success for the Kalzinol group was 81.25% after 6 months. This success rate is higher than for the Dycal group which demonstrated a radiographic success rate of 50% after 6 months. As was demonstrated in other studies^{11, 18}, the radiographic successes of the calcium hydroxide pulpotomy procedure seldom exceeded 60%.

More often than not, pulpotomies with the Dycal base failed within 6 months of the initial procedure. This is in agreement with Sawusch¹⁹ who noted that most calcium hydroxide pulpotomies failed within a 6 to 12-month follow-up period. A large number of patients presented with pain and sinus formation was very common. Sinus formation was evident in 46.15% of these patients at the 6-month follow-up visit and 38.46% presented with pain. These symptoms invariably meant that the pulpotomised tooth would be destined for either root canal treatment or extraction.

Besides the occasional gumboil, pulpotomies where Kalzinol was used as a base were generally more successful than pulpotomies in which a Dycal base was placed. The clinical success rate for the Kalzinol group was 94.74% at the first follow-up visit. At 6 months, the Kalzinol pulpotomy performed considerably better than the Dycal pulpotomy which demonstrated a 53.58% success rate. Clinical success does not necessarily indicate radiographic success.

In this study, patients were to be followed up every 6 months for a period of a year (ie. 2 follow-up visits) or until the treated teeth exfoliated. After 12 months, a large number of the teeth had exfoliated and many patients failed to return for their follow-up appointments. Cases that failed after 6 months were also excluded from the study. This meant that the sample that remained was not large enough to be subjected to a meaningful statistical analysis.

In cases where the pulpotomised teeth had exfoliated, no enamel defects were visible on the permanent successors. Of the patients who did return after 12 months, a greater number of successes were recorded in the Kalzinol group.

CONCLUSION

As was demonstrated in other studies, calcium hydroxide pulpotomies in general are not very successful, even when haemostatic agents like ferric sulfate are used to try and prevent clot formation. The suggestion that the passive barrier formed by the ferric sulfate could possibly protect the pulp from the irritating effect of the subbase placed over it was not supported by the results of this study.

Unlike formocresol, ferric sulfate does not have fixative properties and the base placed over the pulpal tissue seems to play an important role in the outcome of this type of pulpotomy procedure. Overall, success rates were higher in teeth that received a Kalzinol base as opposed to those in which Dycal was used.

The ferric sulfate pulpotomy technique described in this article using a Dycal base and Vitrebond lining cannot be recommended for the treatment of cariously exposed primary teeth. Even though the zinc oxide-eugenol base is also not ideal due to its irritating effect on pulpal tissue, it is still preferable to a Dycal base covered by a Vitrebond lining.

Ideally, materials should not interfere with the exfoliation of primary teeth nor should they adversely affect the eruption of the permanent successors. An effective pulpotomy medication must be physiologically compatible with both the pulp and the surrounding tissues and must result in clinical and radiographic success.

At present, it seems as though the ideal pulpotomy dressing material has still not been found and pulp therapy is likely to remain a contentious issue for many years to come.

ACKNOWLEDGEMENTS

In loving memory of Prof Ruth Peters, the supervisor of this study and the person who taught me everything I know.

Declaration: No conflict of interest was declared

REFERENCES

1. Ranly DM. Formocresol toxicity. Current knowledge. *Acta Odontologica Pediatrica* 1985; **5**: 93—98.
2. Ranly, DM. Assessment of the systemic distribution and toxicity of formaldehyde following pulpotomy treatment: part one. *ASDC Journal of Dentistry for Children* 1985; **52**: 431—434.
3. Smith NL, Seale NS, Nunn ME. Ferric sulfate pulpotomy in primary molars: A retrospective study. *Pediatric Dentistry* 2000; **22**: 192—199.
4. Primosh RE, Glomb TA, Jerrell RG. Primary tooth pulp therapy as taught in predoctoral pediatric dental programs in the United States. *Pediatric Dentistry* 1997; **19**: 118—122.
5. Landau MJ, Johnsen DC. Pulpal response to ferric sulfate in monkeys. *Journal of Dental Research* 1988; **67**: 215 (Abstract No. 822).
6. Ranly DM, Garcia-Godoy F. Current and potential pulp therapies for primary and young permanent teeth. *Journal of Dentistry* 2000; **28**: 153—161.
7. Chien M M-J, Setzer S, Cleaton-Jones P. How does zinc oxide-eugenol compare to ferric sulfate as a pulpotomy material? *South African Dental Journal* 2001; **56**: 130—134.
8. Fei A-L, Udin RD, Johnson R. A clinical study of ferric sulfate as a pulpotomy agent in primary teeth. *Pediatric Dentistry* 1991; **13**: 327—332.
9. Ibricevic H, Al-Jame Q. Ferric sulfate as pulpotomy agent in primary teeth: twenty month clinical follow-up. *Journal of Clinical Pediatric Dentistry* 2000; **24**: 269—272.
10. Fuks AB, Holan G, Davis JM, Eidelman E. Ferric sulfate vs dilute formocresol in pulpotomized primary molars: long term follow-up. *Pediatric Dentistry* 1997; **19**: 327—330.
11. Schröder U. A 2-year follow-up of primary molars, pulpotomized with a gentle technique and capped with calcium hydroxide. *Scandinavian Journal of Dental Research* 1978; **86**: 273—278.
12. Ranly DM. Pulpotomy therapy in primary teeth: new modalities for old

Additional references (12-21) are available on www.sadanet.co.za