



2002

Ultrastructure of the reproductive system of the black swamp snake (*Seminatrix pygaea*). Part III. The sexual segment of the male kidney.

David M. Sever

Follow this and additional works at: https://digitalcommons.butler.edu/facsch_papers



Part of the [Biology Commons](#)

Recommended Citation

Sever, D. M., R. Stevens, T. J. Ryan, and W. C. Hamlett. 2002. Ultrastructure of the reproductive system of the black swamp snake (*Seminatrix pygaea*). Part III. The sexual segment of the male kidney. *Journal of Morphology* 252:238-254. Available from: digitalcommons.butler.edu/facsch_papers/530/

This Article is brought to you for free and open access by the College of Liberal Arts & Sciences at Digital Commons @ Butler University. It has been accepted for inclusion in Scholarship and Professional Work - LAS by an authorized administrator of Digital Commons @ Butler University. For more information, please contact digitalscholarship@butler.edu.

Ultrastructure of the Reproductive System of the Black Swamp Snake (*Seminatrix pygaea*). III. Sexual Segment of the Male Kidney

David M. Sever,^{1*} Rebecca A. Stevens,¹ Travis J. Ryan,^{2,3} and William C. Hamlett⁴

¹Department of Biology, Saint Mary's College, Notre Dame, Indiana

²Savannah River Ecology Laboratory, Aiken, South Carolina

³Division of Biological Sciences, University of Missouri, Columbia, Missouri

⁴Indiana University School of Medicine, South Bend Center for Medical Education, Notre Dame, Indiana

ABSTRACT In mature male snakes and lizards, a distal portion of the nephron is hypertrophied in relation to its appearance in females and immature males. This sexual segment of the male kidney apparently provides seminal fluid that is mixed with sperm and released into the female cloaca during copulation. In this article, we provide the first study at the ultrastructural level of seasonal variation in the sexual segment of the kidney of a squamate, the natricine snake *Seminatrix pygaea*. Previous workers have indicated that the sexual segment is secretory only when the testes are spermatogenically active. The sexual segment of the kidney in *S. pygaea* does not go through an extended period of inactivity but does show a cycle of synthesis and secretion that can be related to the

spermatogenic cycle and mating activity. We show that synthesis of secretory product is initiated with the onset of spermatogenic activity in the spring and culminates with completion of spermiation in the fall. Secretion of the product, however, occurs in a pre-mating period in March when the testes are inactive. Secretion during this pre-mating period is probably necessary to provide time for the passage of the products down the ureter in order to mix with sperm during mating later in spring. *J. Morphol.* 252:238–254, 2002. © 2002 Wiley-Liss, Inc.

KEY WORDS: Reptilia; Squamata; Serpentes; *Seminatrix*; kidney; sexual segment; histology; ultrastructure; reproduction

The first histological description of a squamate nephron was made on the European natricine snake *Natrix natrix* by Gampert (1866). He noted that a portion of the distal segment (the "Harncanalchen") was especially thickened and he provided the first accurate illustration of a snake nephron (Fig. 1). Subsequent reports by Heidenhain (1874), also on *N. natrix*, and by Tribondeau (1902), on *Coluber viridiflavus*, described the enlarged distal segment of the nephron. Regaud and Policard (1903), however, were the first to note that this segment was sexually dimorphic, being hypertrophied only in males (but see Del Conte, 1972). They named this region the "segment sexuel."

Regaud and Policard (1903) also demonstrated that the sexual segment was present in a variety of male snakes and lizards but was absent in turtles. Later work concluded that the sexual segment is also absent in crocodylians (Fox, 1952) but is present in amphisbaenids (Bons and Saint Girons, 1963; Saint Girons, 1972); a portion of the nephron of *Sphenodon* (Rhynchocephalia) most likely differentiates seasonally into a sexual segment (Gabe and Saint Girons, 1964). The reptilian clade Lepidosauria is traditionally composed of the Squamata (snakes, lizards, and amphisbaenids) and Rhynchocephalia (cf., Pough et al., 1998). Thus, among

reptiles the presence of a sexual segment can be considered a synapomorphy at least for the Squamata and probably for the Lepidosauria.

Within squamates, however, some variation occurs in the extent of the sexual segment. In most snakes the sexual segment just involves the terminal portion of the distal convoluted tubule (called the pre-terminal segment by Fox, 1952). In many lizards and some snakes, the sexual segment may include the terminal segment, postterminal seg-

Contract grant sponsor: U.S. Department of Energy to the University of Georgia Research Foundation; Contract grant number: DE-FCO9-96SR18546.

Current address for T.J. Ryan: Department of Biology, Butler University, Indianapolis, IN.

*Correspondence to: David M. Sever, Department of Biology, Saint Mary's College, Notre Dame, IN 46556.
E-mail: dsever@saintmarys.edu

[†]This article is a US Government work and, as such, is in the public domain in the United States of America.

DOI: 10.1002/jmor.1102

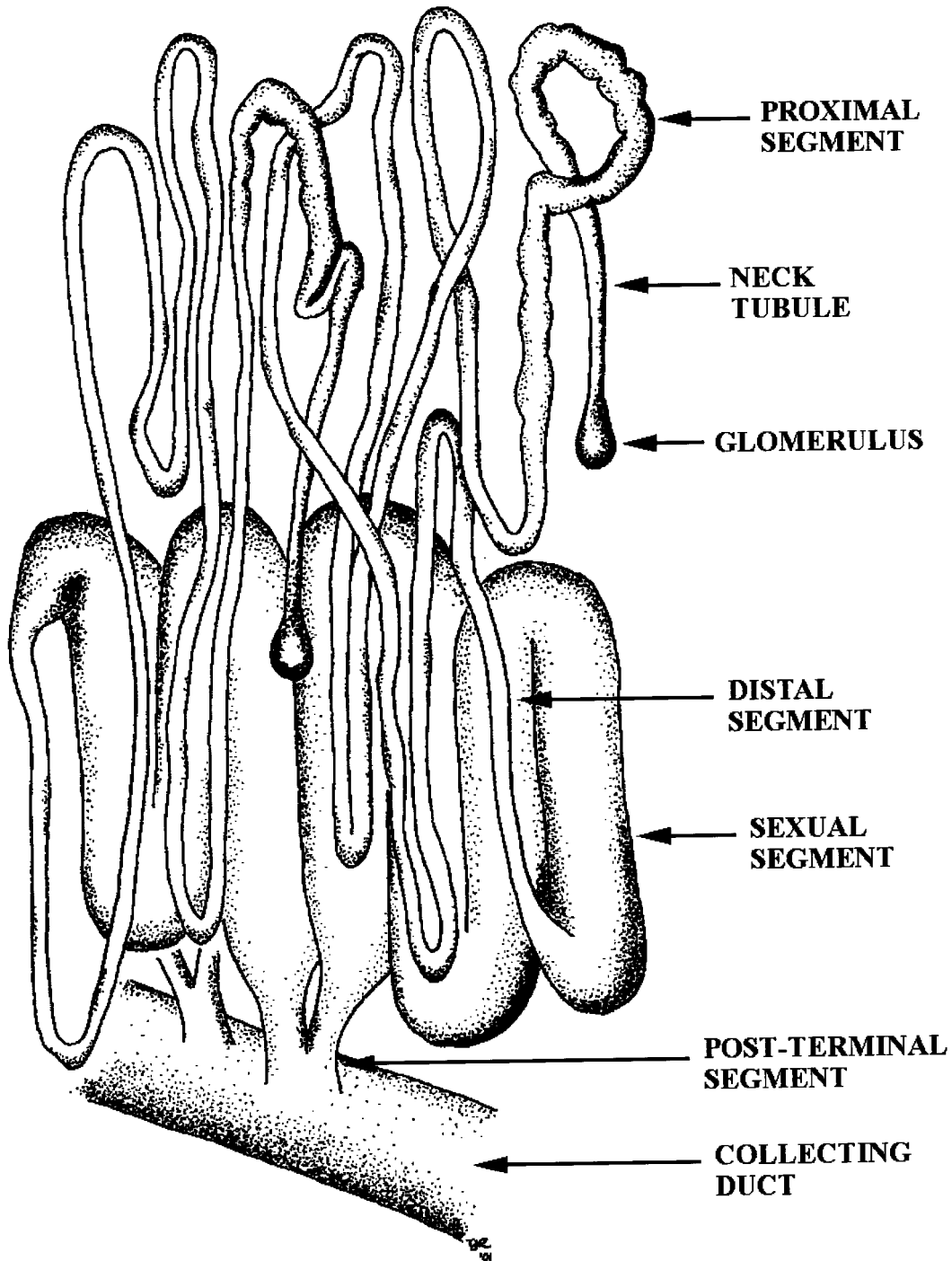


Fig. 1. Male snake nephrons as originally depicted by Gampert (1866), copied by Regaud and Policard (1903), and redrawn here by T.J. Ryan. Terminology follows Bishop (1959). The "intermediate segment," a short portion between proximal and distal segments that is difficult to distinguish externally, is not labeled.

ment, collecting ducts, and/or portions of the ureter (Fox, 1965; Saint Girons, 1972).

Fox (1977) provides a comprehensive review of the literature and no major morphological studies have been done since that time. The function of the sexual segment is still not clearly understood, but its secre-

tions may sustain and activate sperm (Bishop, 1959; Cuellar, 1966), provide courtship pheromones (Volsøe, 1944), form copulatory plugs (Devine, 1975), and/or have other purposes generally associated with seminal fluid (Prasad and Reddy, 1972). The only other source of seminal fluids in squamates is

the epididymis (Depeiges and Dufaure, 1980). Maximal development of the sexual segment is related to increased androgen levels (Bishop, 1959; Misra et al., 1965; Pandha and Thapliyal, 1964; Prasad and Sanyal, 1969; Krohmer, 1986). Thus, seasonal variation occurs, with the height of development generally associated with the mating season. Snakes, however, do not show as marked seasonal changes in the sexual segment as lizards (Fox, 1977).

To our knowledge, only three ultrastructural studies have previously been done on the sexual segment of squamates. Furieri and Lanzavecchia (1959) were concerned only with the effects of castration on the ergastoplasm of the sexual segment of the lacertid lizard, *Lacerta sicula*. Del Conte and Tamyo (1973) compared the sexual segment of males of the teiid lizard, *Cnemidophorus lemniscatus*, to a homologous area that undergoes some differentiation in females. They stated that this species has continuous sexual activity, but used only three specimens of each sex. In both *L. sicula* and *C. lemniscatus*, the sexual segment involves the collecting ducts. The only prior ultrastructural study on a snake is by Kuhnel and Krisch (1974) on *Natrix natrix*. All of Kuhnel and Krisch's specimens were sacrificed in one month (November), and they did not describe the reproductive condition of their specimens. In this article, we provide the first study at the ultrastructural level of seasonal variation in the sexual segment of the kidney of a snake and we relate this to our observations on the spermatogenic cycle.

MATERIALS AND METHODS

The squamate used for this study is the black swamp snake, *Seminatrix pygaea* (Cope). This small (20–40 cm snout–vent length as adults), highly aquatic snake is limited to the southern Atlantic coastal plain of the United States (Dorcas et al., 1998). This species is the subject of other studies concerning its reproductive cycle (Seigel et al., 1995) and the ultrastructure of the reproductive system (Sever and Ryan, 1999; Sever et al., 2000).

Seminatrix pygaea were collected at Ellenton Bay, located on the Department of Energy's Savannah River Site in Aiken County, South Carolina. This "Carolina bay" is freshwater, 10 ha, shallow (2 m maximum depth), and relatively permanent (Gibbons and Semlitsch, 1991). The population of *S. pygaea* at this locale is the largest known for the species (Gibbons and Semlitsch, 1991).

Collections were made during four periods in 1998 (10 May, 7 June, 22–24 July, and 29 September – 2 October), and one period in 1999 (17–22 March). Snakes were collected in unbaited minnow traps and from under coverboards alongside the bay. Specimens were sacrificed within a week of capture (Table 1).

Specimens were killed by a lethal injection (3–5 ml) of Nembutal (Abbott Laboratories, North Chi-

TABLE 1. Specimens utilized and diameters of 10 sexual segment tubules per individual

Date sacrificed	SVL ¹	Prep ²	Sexual segment		
			Range ³	Mean	SE
31 March	28.1	Par	0.15–0.21	0.17	0.005
	26.2	JB4	0.15–0.20	0.18	0.005
	23.2	TEM	0.13–0.18	0.15	0.005
16 May	26.1	Par	0.12–0.20	0.15	0.007
	27.9	JB4	0.15–0.18	0.17	0.004
	31.2	TEM	0.11–0.15	0.13	0.004
9 June	25.6	Par	0.12–0.15	0.13	0.003
	23.8	JB4	0.08–0.11	0.09	0.004
	26.8	TEM	0.11–0.12	0.11	0.002
30 July	28.0	Par	0.12–0.15	0.13	0.003
	23.8	JB4	0.08–0.11	0.09	0.004
	26.8	TEM	0.11–0.12	0.11	0.002
8 October	28.0	Par	0.13–0.17	0.14	0.004
	25.5	JB4	0.12–0.18	0.15	0.007
	29.0	TEM	0.12–0.16	0.14	0.007

¹SVL = snout–vent length in cm.

²Preparation in paraffin, JB–4 glycol methacrylate, or in epoxy resin for TEM.

³Sexual segment measurements are in mm.

ago, IL). This procedure was approved by the Animal Care and Use Committee of Saint Mary's College. After death, snout–vent length (SVL) was measured from the tip of the snout to the posterior end of the cloacal orifice. The reproductive tracts and kidneys were removed and prepared for light microscopy (LM) and transmission electron microscopy (TEM). Carcasses of all specimens were preserved in neutral buffered formalin (NBF) and are housed in the research collections at Saint Mary's College.

For LM examination, tissues were initially fixed in NBF, rinsed in water, dehydrated in ethanol, cleared in toluene, and embedded in paraffin or glycol methacrylate (JB-4 Plus; Electron Microscopy Sciences, Port Washington, PA) plastic resin. Paraffin sections (10 μ m) were cut with a rotary microtome and affixed to albuminized slides. Alternate paraffin slides from each specimen were stained with hematoxylin-eosin (general histology), brilliant indocyanine 6B (BB, for proteins), and Alcian blue 8GX at pH 2.5 (AB, for primarily carboxylated glycosaminoglycans) followed by the periodic acid-Schiff's procedure (PAS, for neutral carbohydrates and sialic acids). Sections (2 μ m) from tissues embedded in JB4 were stained with methylene blue and basic fuschin. Procedures followed Dawes (1979), Humason (1979), and Kiernan (1990).

Tissue for TEM was trimmed into 1-mm blocks and fixed in a 1:1 solution of 2.5% glutaraldehyde in Millonig's phosphate buffer and 3.7% formaldehyde buffered to pH 7.2 with monobasic and dibasic phosphate. After initial fixation, tissues were rinsed in distilled-deionized water, postfixed in 2% osmium tetroxide, dehydrated through a graded series of ethanol, cleared in propylene oxide, and polymerized in an epoxy resin (Embed 812; Electron Microscopy

TABLE 2. Tukey's HSD matrix of pairwise comparison possibilities among the monthly means for sexual segment of the kidney diameter in male *Seminatrix pygaea*

Date	31 March	16 May	9 June	30 July	8 October
31 March	1.000				
16 May	0.000	1.000			
9 June	0.000	0.000	1.000		
30 July	0.000	0.031	0.000	1.000	
8 October	0.000	0.978	0.000	0.141	1.000

The matrix consists of *P* values, with *P* ≤ 0.05 considered significant.

Sciences). Plastic sections were cut with an RMC MT7 ultramicrotome (Research and Manufacturing Co., Tucson, AZ) and Diatome (Biel, Switzerland) diamond knives. Semithin sections (0.5–1 mm) for LM were placed on microscope slides and stained with toluidine blue. Ultrathin sections (70 nm) for TEM were collected on uncoated copper grids and stained with solutions of uranyl acetate and lead citrate. Ultrathin sections were viewed with a Hitachi H-300 transmission electron microscope (Nissei Sangyo America, Mountain View, CA).

Using microscope slides of paraffin, glycol methacrylate, and epoxy-embedded tissues, diameters of 10 sexual segment tubules from each snake were measured to 0.01 mm with an ocular micrometer. Nested ANOVA was used to estimate variance components for both month and snake within month; these variance components were converted to percentages of the total (Sokal and Rohlf, 1995). To test for sea-

sonal variation, Tukey's HSD method was used for all pairwise comparisons of monthly mean sexual segment diameter (Table 2). Finally, the correlation coefficient (*r*) was calculated between SVL and mean sexual segment diameter. The *P* = 0.05 level was used to determine statistical significance. Statistics were calculated using SYSTAT v. 6.1 for Windows.

RESULTS

The following sections describe the spermatogenic cycle (Fig. 2), histology, and size variation in the sexual segment (Tables 1, 2; Figs. 3, 4) and ultrastructure of the sexual segment (Figs. 5–10). A summary of seasonal variation in the microscopic anatomy of the male reproductive system and the sexual segment of the kidney is given in Table 3.

Spermatogenic Cycle

The testes in specimens from the March sample are inactive, containing spermatogonia in a Sertoli syncytium, and the efferent ductules are devoid of sperm (Fig. 2A). The epididymis, however, like the entire vas deferens, is packed with sperm. Spermatogenesis is well under way in the specimens from May. Proliferation of primary spermatocytes is evident (Fig. 2B). The entire vas deferens, including the proximal portion, still contains sperm. Spermiation is evident in June and July samples; spermatids occur around the lumina of testicular lobules and

TABLE 3. Microscopic differences in the testes, reproductive ducts, and sexual segment among samples of *Seminatrix pygaea*

	March	May	June	July	October
Testes	Inactive spermatogonia	Primary spermatocytes	Many spermatids	Many spermatids	Few spermatids
Efferent ductules	Empty	Empty	A few sperm	A few sperm	Much sperm
Epididymis	Sperm	Empty	Empty	Empty	Sperm
Vas deferens	Sperm	Sperm	Sperm	Sperm	Sperm
Sexual segment					
PAS+, BB+	Entire cell and lumen	Luminal border and basally	Luminal border and basally	Luminal border and basally	Entire cell
Nuclei	Oval euchromatic	Irregular heterochromatic	Irregular heterochromatic	Irregular/oval heterochromatic	Irregular/oval euchromatic
Apocrine blebs	Numerous	Few	Scant	Few	Numerous
Granular luminal secretion	Abundant	Scant	Scant	Scant	Common
Colloidal luminal secretion	Present	Absent	Absent	Absent	Absent
Microvilli	Absent	Present	Present	Not conspicuous	Few
Intercellular canaliculi	Straight	Labyrinthine	Labyrinthine	Labyrinthine	Straight
Rough endoplasmic reticulum	Not apparent	Present	Present	Present	Present
Condensing vacuoles	Absent	Numerous apically	Numerous throughout	Numerous apically	Few
Mitochondria	Basal	Basal	Throughout some cells	Basal	Basal

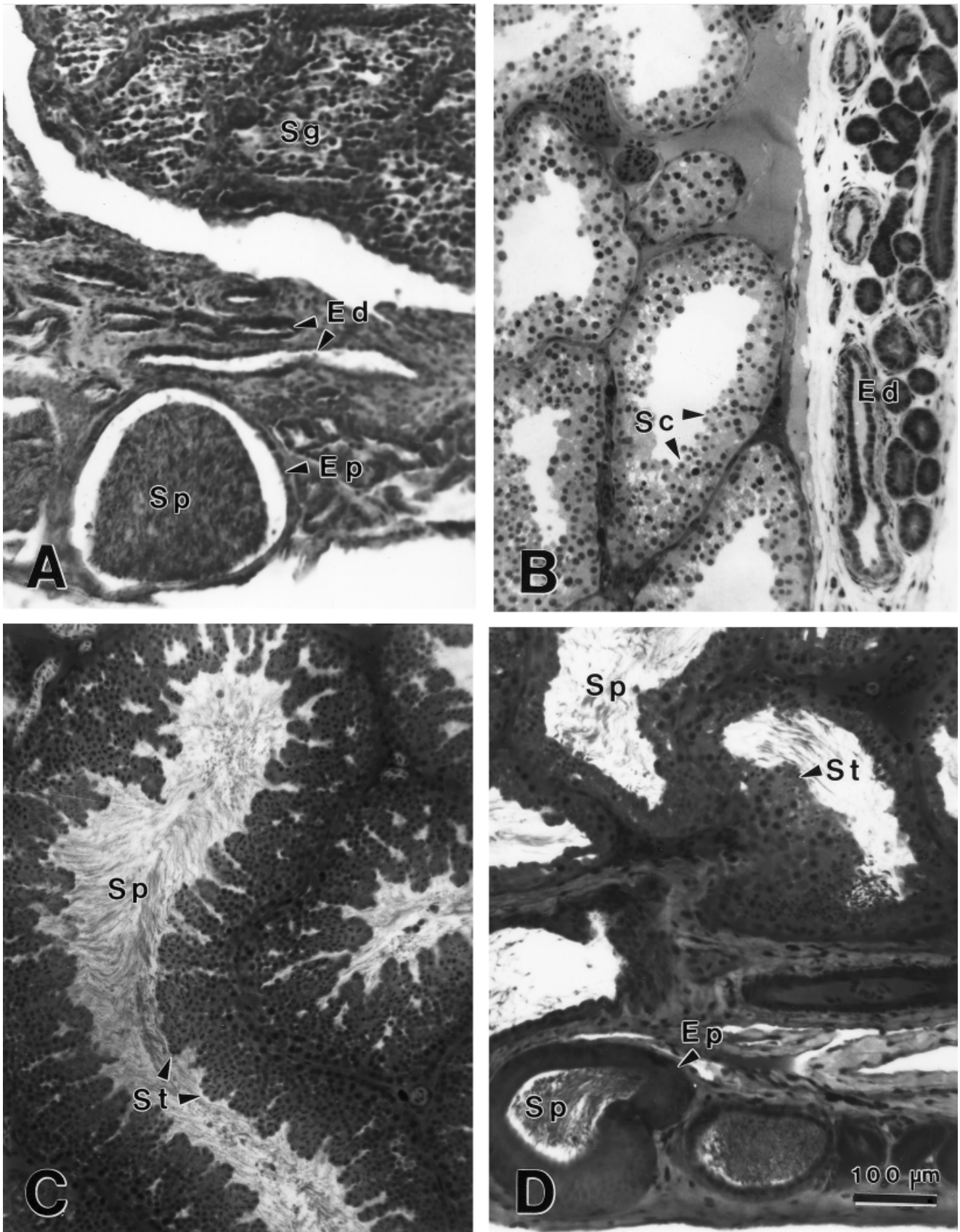


Fig. 2. Sections through the testes and vasa deferentia of *Seminatrix pygaea*. **A:** Paraffin section stained with hematoxylin-eosin. **B–D:** Glycol methacrylate sections stained with methylene blue and basic fuchsin. **A:** 28.1 cm SVL male sacrificed 31 March. **B:** 26.1 cm SVL male sacrificed 16 May. **C:** 28.0 cm SVL male sacrificed 30 July. **D:** 28.0 cm male sacrificed 8 October. Ed, efferent ductules; Ep, epididymis; Sc, spermatocytes; Sg, spermatogonia in the Sertoli syncytium; Sp, sperm; St, spermatids.

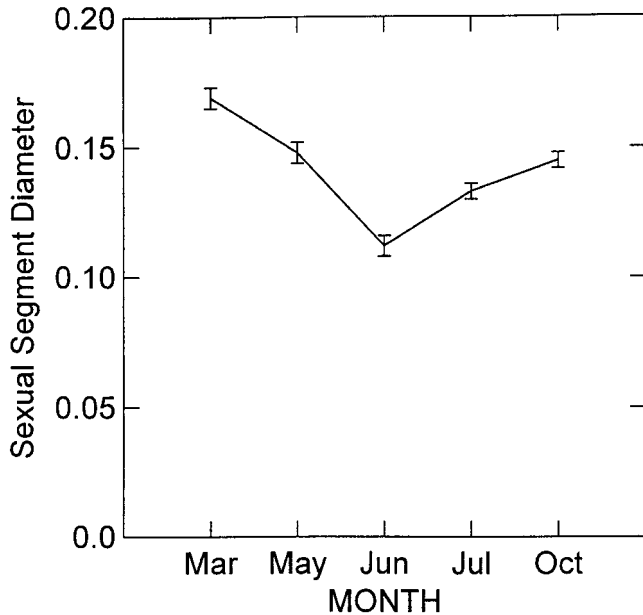


Fig. 3. Relationship between month and mean sexual segment diameter in *Seminatrix pygaea*. Vertical lines indicate one standard error, horizontal line indicates the mean.

lumina possess abundant sperm (Fig. 2C). The efferent ductules and proximal portions of the vas deferens contain little or no sperm, indicating that transfer of sperm newly formed in the testes has not yet occurred. In the October specimens, spermiation is nearly complete (Fig. 2D). The efferent ductules and epididymis contain much sperm. Testicular lobules, however, still possess some spermatids and lumina of the testes contain numerous sperm, but not as many as in July. The middle to distal portion of the vas deferens holds sperm the entire year. Ultrastructure of sperm storage in the vas deferens is the subject of another article (Sever et al., in prep.)

Light Microscopy

Seasonal variation is apparent at the light microscopy level in the size of the sexual segment tubules (Tables 1, 2, Fig. 3) and in some histological characteristics (Fig. 4). Correlation between SVL and sexual segment diameter is low ($r = 0.122$) and not significant ($r_{0.05} = 0.514$, probability that $r = 0.0$ is 66.4%). Nested ANOVA reveals that significant overall variation in tubule diameter (Table 1) occurs within months ($F = 15.665$) as well as among months ($F = 66.238$). However, variance among months (variance component = 41%) is greater than variation among snakes within months (variance component = 35%). Tukey's multiple comparison matrix (Table 2) shows that the group mean for March is significantly higher than all other months; the group mean for May is higher than all months except October; the group mean for June is signifi-

cantly lower than all other months; the group mean for July is significantly different from all other months except October; and the October group mean is significantly different from March and June. Overall, a pattern is evident in which sexual segment diameter is at its peak in March, declines gradually in the spring and early summer, and begins increasing once more in late summer and fall (Fig. 3).

At the light microscopy level, the sexual segment tubules in March are more hypertrophied than those from other samples (Fig. 4). Areas of the cytoplasm containing mature secretory granules stain intensely BB+ for proteins and PAS+ for carbohydrates; the granules are strongly eosinophilic with HE and stain intensely with methylene blue in glycol methacrylate. The product contained in the secretory granules, therefore, most likely contains a glycoprotein or mucoprotein. Nuclei appear central in the simple columnar epithelium composing the sexual segment. In March specimens, intensely staining granular areas occur throughout the basal cytoplasm and extend from the nuclei apically to the lumen (Fig. 4A). Lumina are relatively narrow and in most tubules contain a central translucent colloidal material with a collar of granules. The luminal material stains in the same manner as the secretory granules in the cytoplasm of the sexual segment tubules.

In the May sample, lumina are still relatively narrow, but they appear wider than in the March sample and the lumina are devoid of significant quantities of secretory products. The BB+ and PAS+ reactions, indicative of mature secretory granules, are limited to a light ring around luminal borders and basal to the nuclei (Fig. 4B). This condition continues in the June and July (Fig. 4C) samples. In October, more diffuse BB+ and PAS+ reactions are present, although these reactions are weakest around the luminal borders, and lumina still appear virtually empty (Fig. 4D).

In summary, a small amount of seasonal variation is apparent at the light microscopy level. The tubules in the March sample are the largest in diameter and show the most intense staining reactions throughout the cytoplasm. The March sample is the only one in which quantities of luminal material were observed that reacted histochemically in the same manner as the secretory granules. In the other samples, tubules were significantly smaller, histochemical reactions indicating mature secretory granules were most intense basally, and lumina appear devoid of secretory material.

Ultrastructure

March. The epithelium of the sexual segment consists of tall, slender, simple columnar cells with central nuclei (Fig. 5). In the March sample the nuclei are oval, regular in outline, and euchromatic.

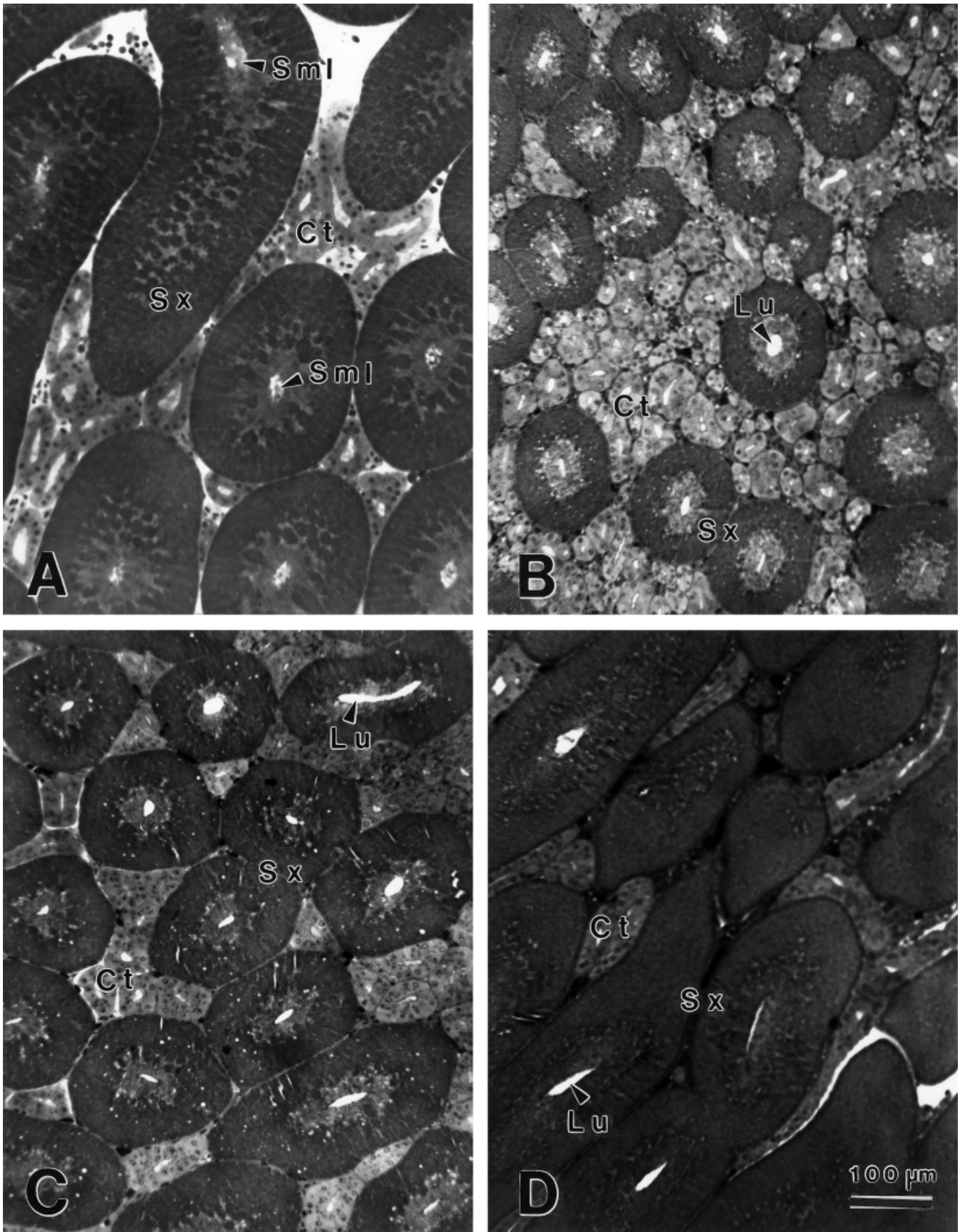


Fig. 4. Glycol methacrylate sections stained with methylene blue and basic fuchsin through the kidneys of male *Seminatrix pygaea*. Areas in the sexual segments (Sx) with mature secretory granules stain darkly. **A:** 26.2 cm SVL male sacrificed 31 March. **B:** 27.9 cm SVL male sacrificed 16 May. **C:** 23.8 cm SVL male sacrificed 30 July. **D:** 25.5 cm SVL male sacrificed 8 October. Ct, convoluted tubule; Lu, lumen; Sml, secretory material in the lumen; Sx, sexual segment.

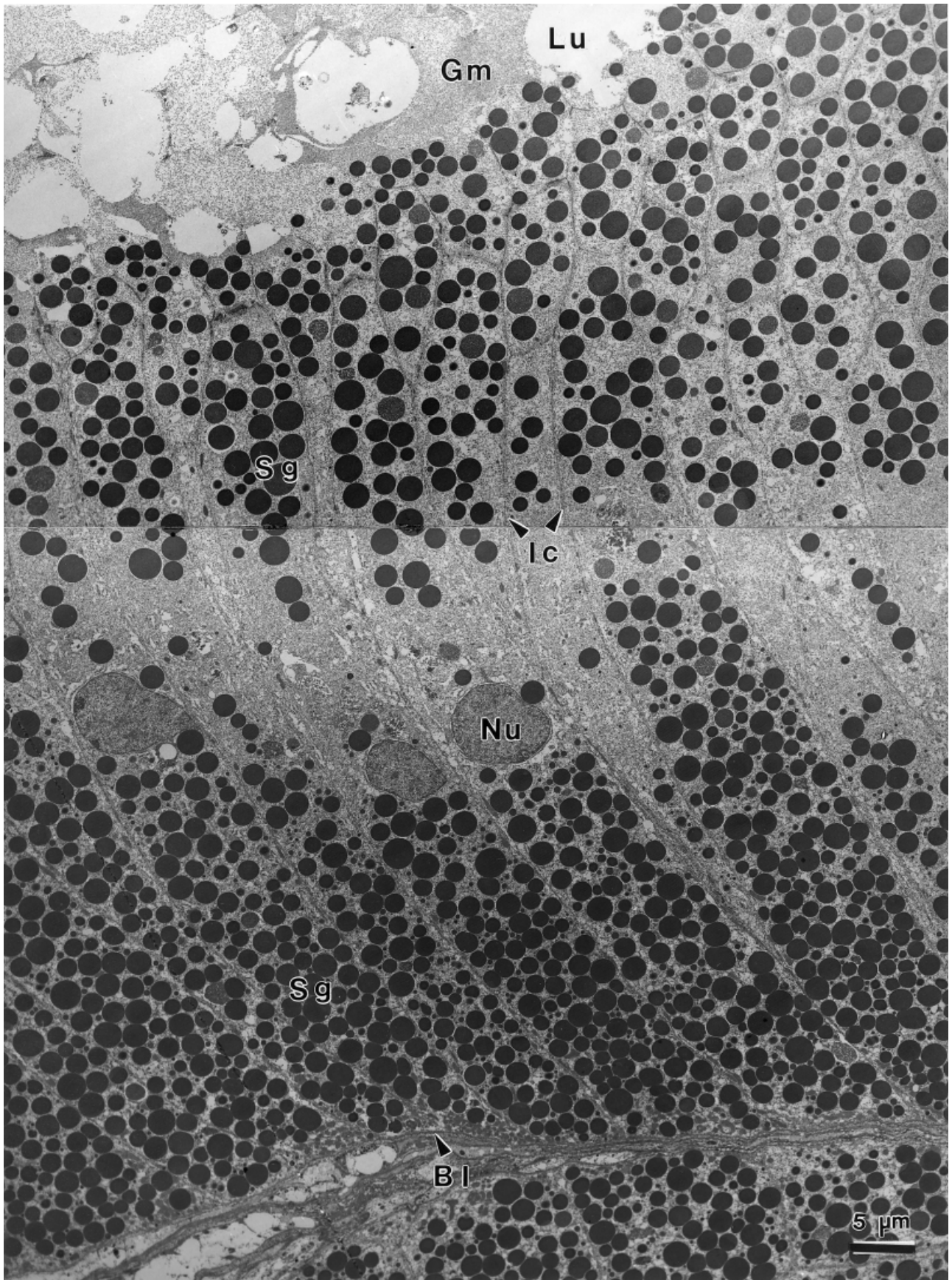


Fig. 5. Transmission electron micrograph of the sexual segment of the kidney in a 23.2 cm *Seminatrix pygaea* sacrificed 31 March. Bl, basal lamina; Gm, granular material; Ic, intercellular canaliculus; Lu, lumen; Nu, nucleus; Sg, secretory granules.

Intercellular canaliculi are narrow, relatively straight, and possess many junctional complexes. Secretory granules are round and almost uniformly electron-dense (Fig. 5). The largest granules (1.5–2 μm in diameter) are in the apical areas, but granules are most numerous and crowded basally (Fig. 5). Granules <1.5 μm are interspersed among the larger ones. However, if the granules are indeed spherical the variance in size may simply be due to the plane of section.

Along the apical border granules appear to be released into the lumen along with cytoplasm, i.e., an apocrine mode of secretion (Figs. 5, 6A). In the lumen, free secretory granules are observed in a granular matrix resulting from the disassociation of the apical cytoplasm (Figs. 5, 6A). A denser, colloidal material also is present in the lumen (Fig. 6A).

The supranuclear area contains few granules and many small vacuoles (Figs. 5, 6B,C). The perinuclear region also contains numerous vacuoles and lacks mitochondria and organelles generally associated with protein synthesis (Fig. 6C). Groups of small, densely staining, elongate mitochondria are numerous along the basal lamina (Figs. 5, 6D). Contractile elements are not in evidence around the tubules, but unmyelinated axons are numerous in the tunica propria (Figs. 5, 6D).

May. In the May sample nuclei are more irregular and heterochromatic (Fig. 7A). Secretory granules in the supranuclear area are still numerous, but much variation occurs in electron density (Fig. 7A). Condensing vacuoles in various degrees of maturity are numerous, whereas fully formed, uniformly electron-dense granules are less common. Lumina appear relatively empty and apocrine blebs along the borders are infrequent; instead, small microvilli occur on the luminal border of epithelial cells (Fig. 7B). In the perinuclear areas, rough endoplasmic reticulum (RER) is closely associated with condensing vacuoles (Fig. 7C), indicating a surge of product synthesis. The basal areas do not appear different from the March sample; round, uniformly electron-dense secretory granules are numerous (Fig. 7D).

June. In the June sample the relative decrease in height of the sexual segment tubules from the March and May sample noted with light microscopy (Fig. 3) also is apparent at the electron microscopy level (compare Figs. 5 and 7A with Fig. 8A). Some of the epithelial cells of the sexual segment contain few secretory granules and possess numerous mitochondria throughout the cytoplasm (Fig. 8A). Others contain numerous secretory granules that are often irregular in outline. Nuclei are heterochromatic and elongate with the long axis of the cells (Fig. 8A). Apocrine blebs are few and lumina appear empty except for some membranous debris (Fig. 8B). As in May, condensing vacuoles and granules in various stages of maturity are numerous apically (Fig. 8B) and in the perinuclear areas (Fig. 8C). In addition, the June specimen has condensing vacuoles scattered among mature granules basally (Fig. 8D). In-

tercellular canaliculi are narrow and labyrinthine (Fig. 8B–D). Multivesicular bodies that may represent secondary lysosomes are occasionally observed (Fig. 8D).

July. In the July sample elongation of the cells has once again occurred and the tubules resemble those of the March specimens, with some notable differences (compare Fig. 5 with Fig. 9A). First, the nuclei have become less irregular and more oval, but much heterochromatin still exists. Second, many of the supranuclear secretory granules are still immature (Fig. 9A,B). Finally, the presence of Golgi complexes, extensive RER profiles, and condensing vacuoles in various degrees of maturity in the perinuclear areas indicates extensive synthesis of new product (Fig. 9C).

The July specimen also differs in some other aspects from the May and June samples. Microvilli are no longer conspicuous on the luminal border of epithelial cells (Fig. 9B). Apocrine blebs are more numerous than in the June sample, but lumina still appear devoid of significant amounts of secretory material (Fig. 9B).

October. Although some nuclei are still irregular in outline, they have become more uniformly euchromatic (Fig. 10A). Condensing vacuoles are less numerous in the apical cytoplasm and mature granules with surrounding cytoplasm are being released by an apocrine process into the lumina (Fig. 10B). Secretion is not as abundant as in the March sample, however, and the colloidal matrix observed in the lumina of tubules from March is not present in the tubules from October. Significant synthetic activity is still apparent in the perinuclear area (Fig. 10C). Basally, the cytoplasm is crowded with uniformly electron-dense secretory granules (Fig. 10D).

DISCUSSION

In his comparative study of the histology of the sexual segment in 73 species representing 19 families of reptiles, Saint Girons (1972) found that in snakes and *Varanus* the segment corresponds to the medial region of the distal convoluted tubule. This condition characterizes *Seminatrix pygaea* as well. The sexual segment of the squamate kidney is a derivative of the mesonephric (Wolffian) duct and may be homologous to the seminal vesicle of mammals (Prasad and Reddy, 1972; Jones, 1998). The only sources of seminal fluid in squamates are the epididymis and the sexual segment (Depeiges and Dufaure, 1980). The epididymis of reptiles does not function in sperm maturation and sperm storage as in mammals. Instead, the vas deferens is the site of sperm storage in reptiles (Jones, 1968). During ejaculation, secretions of the sexual segment are mixed with sperm that have been stored in a matrix of epididymal secretions in the vas deferens (Prasad and Reddy, 1972). The manner in which these secre-

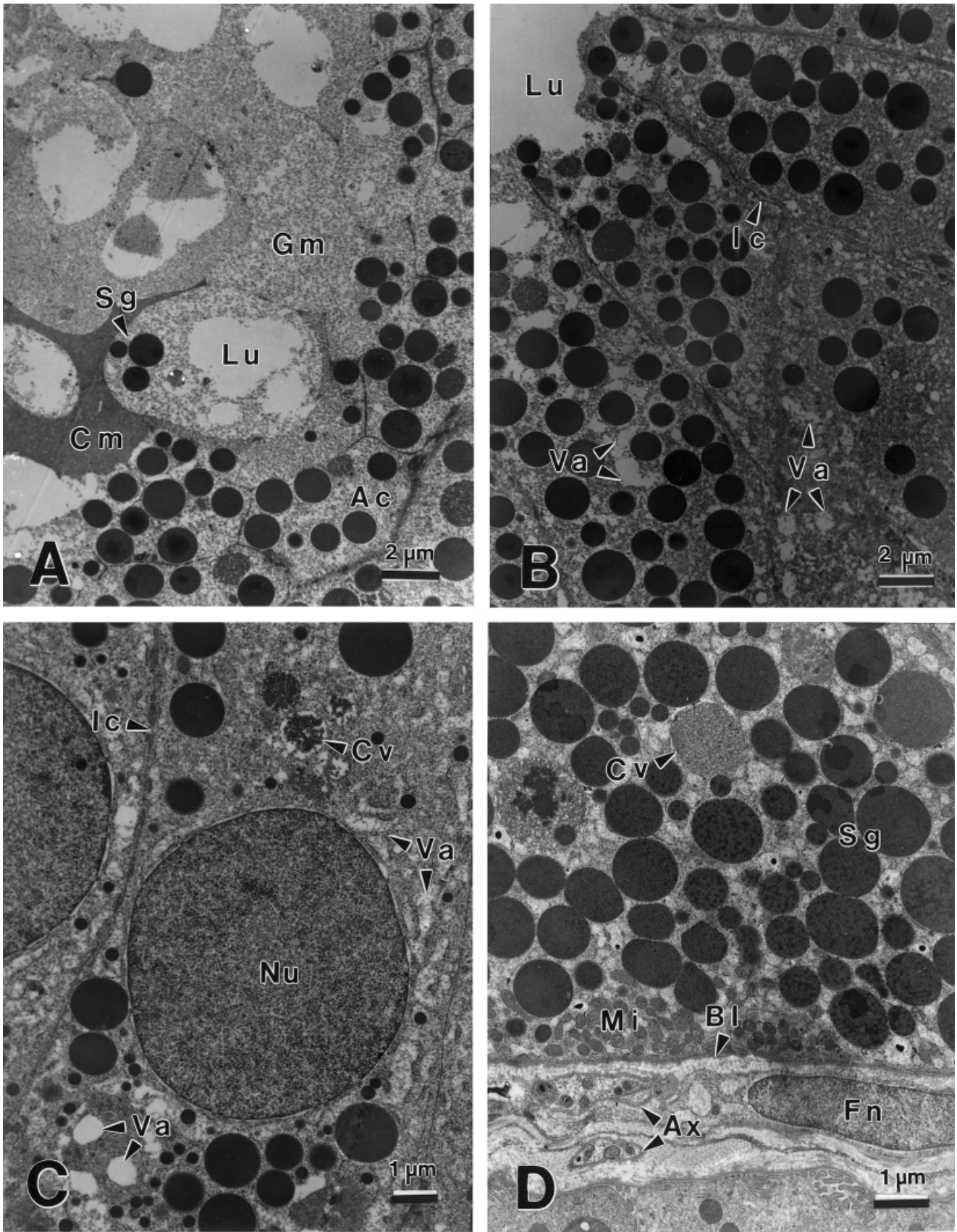


Fig. 6. Transmission electron micrographs of the sexual segment of the kidney in a 23.2 cm *Seminatrix pygaea* sacrificed 31 March. **A:** Secretory products in the lumen. **B:** Apical cytoplasm. **C:** Perinuclear region. **D:** Basal cytoplasm. Ac, apical cytoplasm; Ax, axons; Bl, basal lamina; Cm, colloidal material; Cv, condensing vacuole; Fn, fibroblast nucleus; Gm, granular material; Ic, intercellular canaliculus; Lu, lumen; Mi, mitochondria; Nu, nucleus; Sg, secretory granules; Va, vacuoles.

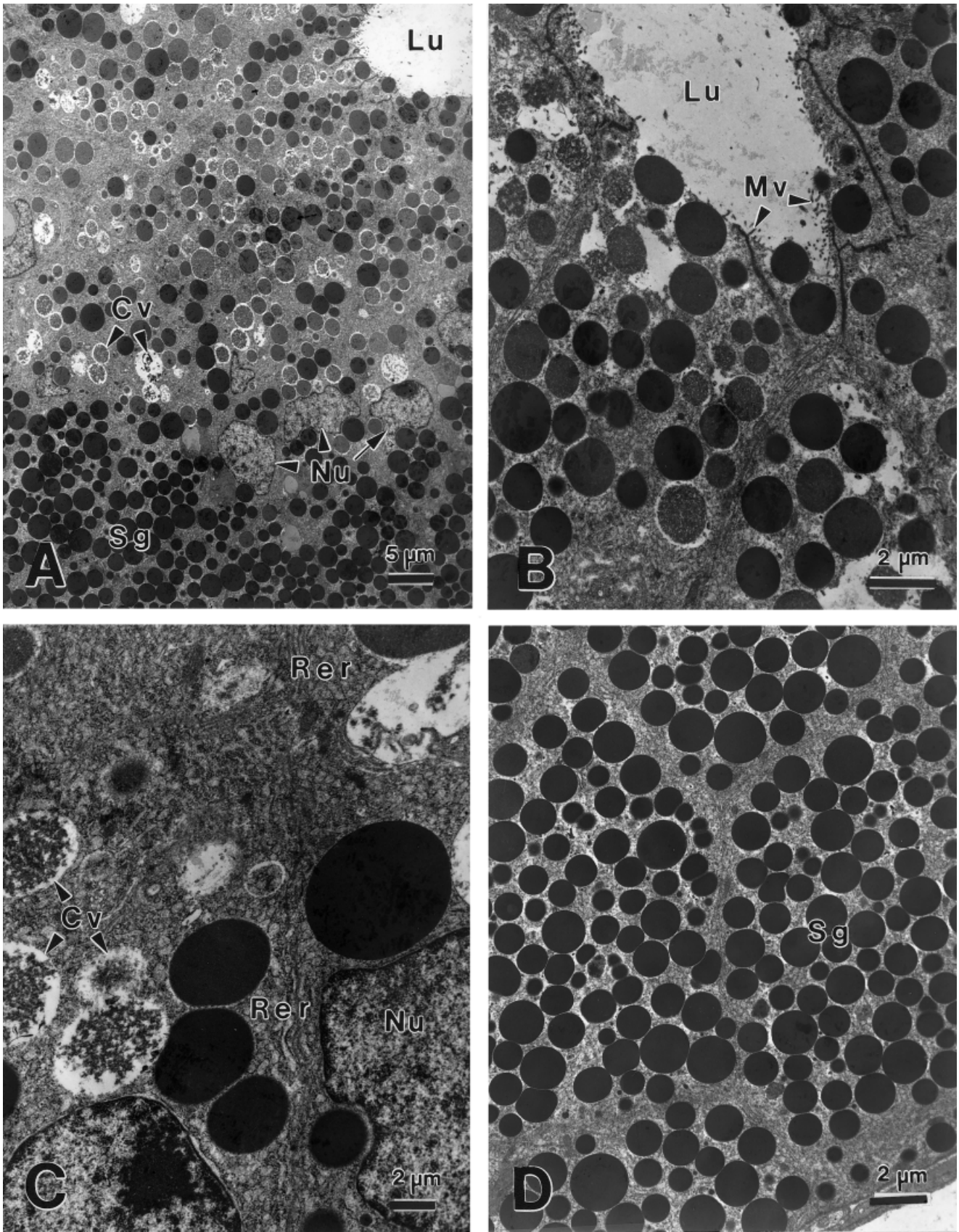


Fig. 7. Transmission electron micrographs of the sexual segment of the kidney in a 31.2 cm *Seminatrix pygaea* sacrificed 16 May. **A:** Overview. **B:** Apical cytoplasm. **C:** Nuclear region. **D:** Basal cytoplasm. Cv, condensing vacuole; Lu, lumen; Mv, microvilli; Nu, nucleus; Rer, rough endoplasmic reticulum; Sg, secretory granules.

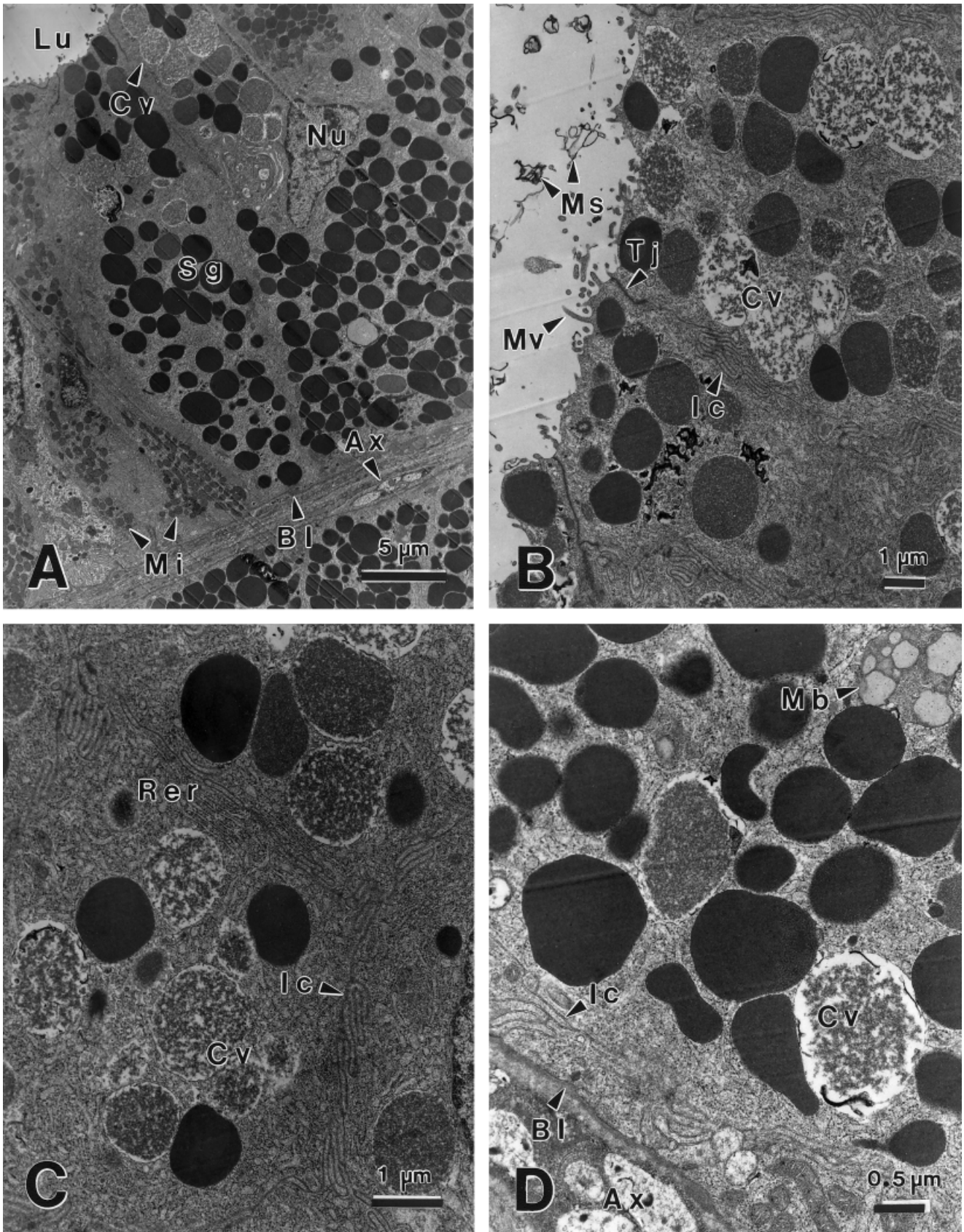


Fig. 8. Transmission electron micrographs of the sexual segment of the kidney in a 31.2 cm *Seminatrix pygaea* sacrificed 9 June. **A:** Overview. **B:** Apical cytoplasm. **C:** Nuclear region. **D:** Basal cytoplasm. Ax, axons; Bl, basal lamina; Cv, condensing vacuoles; Ic, intercellular canaliculus; Lu, lumen; Mb, multivesicular body; Mi, mitochondria; Ms, membranous structures; Mv, microvilli; Nu, nucleus; Rer, rough endoplasmic reticulum; Tj, tight junction; Sg, secretory granule.

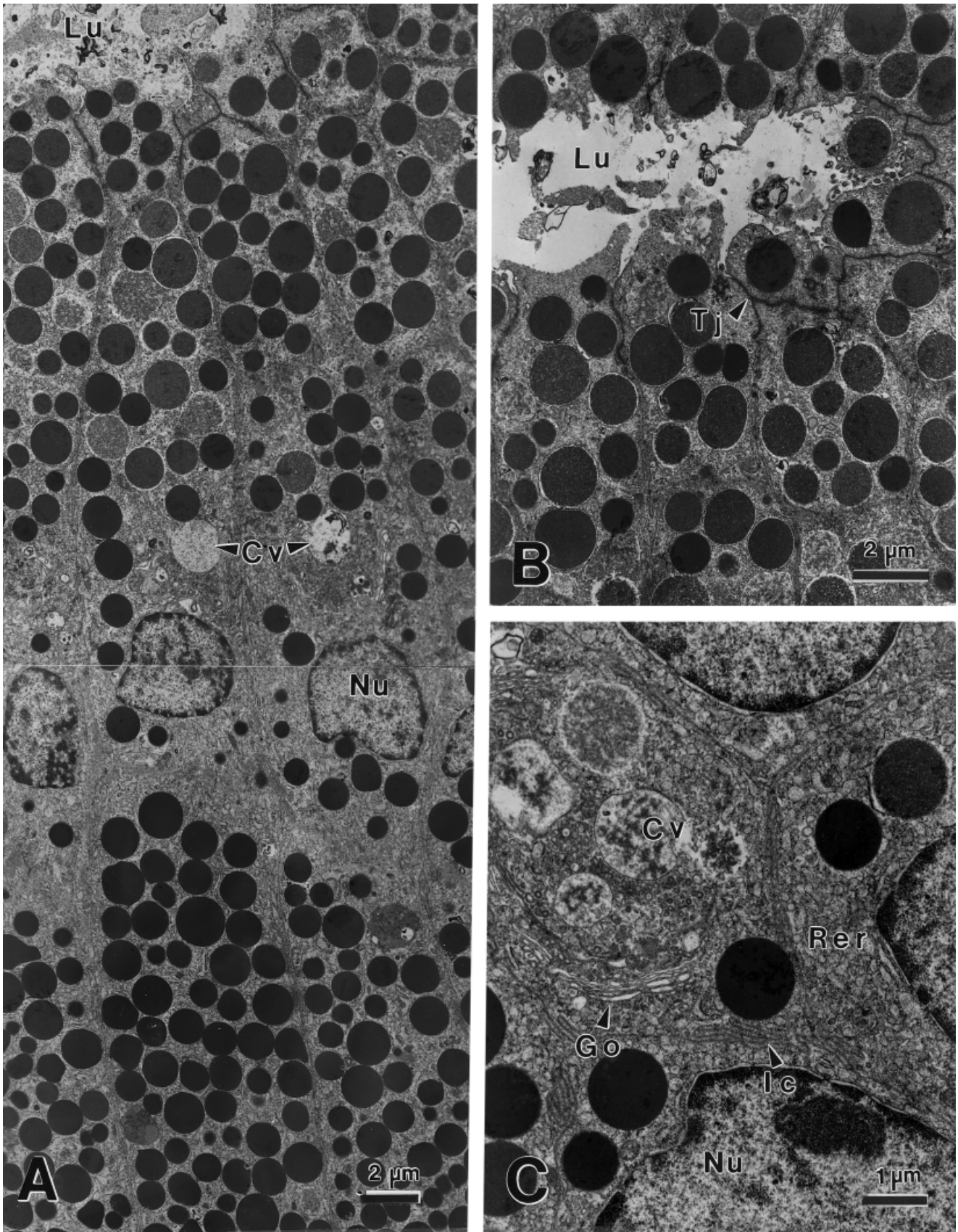


Fig. 9. Transmission electron micrographs of the sexual segment of the kidney in a 31.2 cm *Seminatrix pygaea* sacrificed 30 July. **A:** Overview. **B:** Apical cytoplasm. **C:** Nuclear region. Cv, condensing vacuoles; Go, Golgi complex; Ic, intercellular canaliculus; Lu, lumen; Nu, nucleus; Rer, rough endoplasmic reticulum; Tj, tight junction.

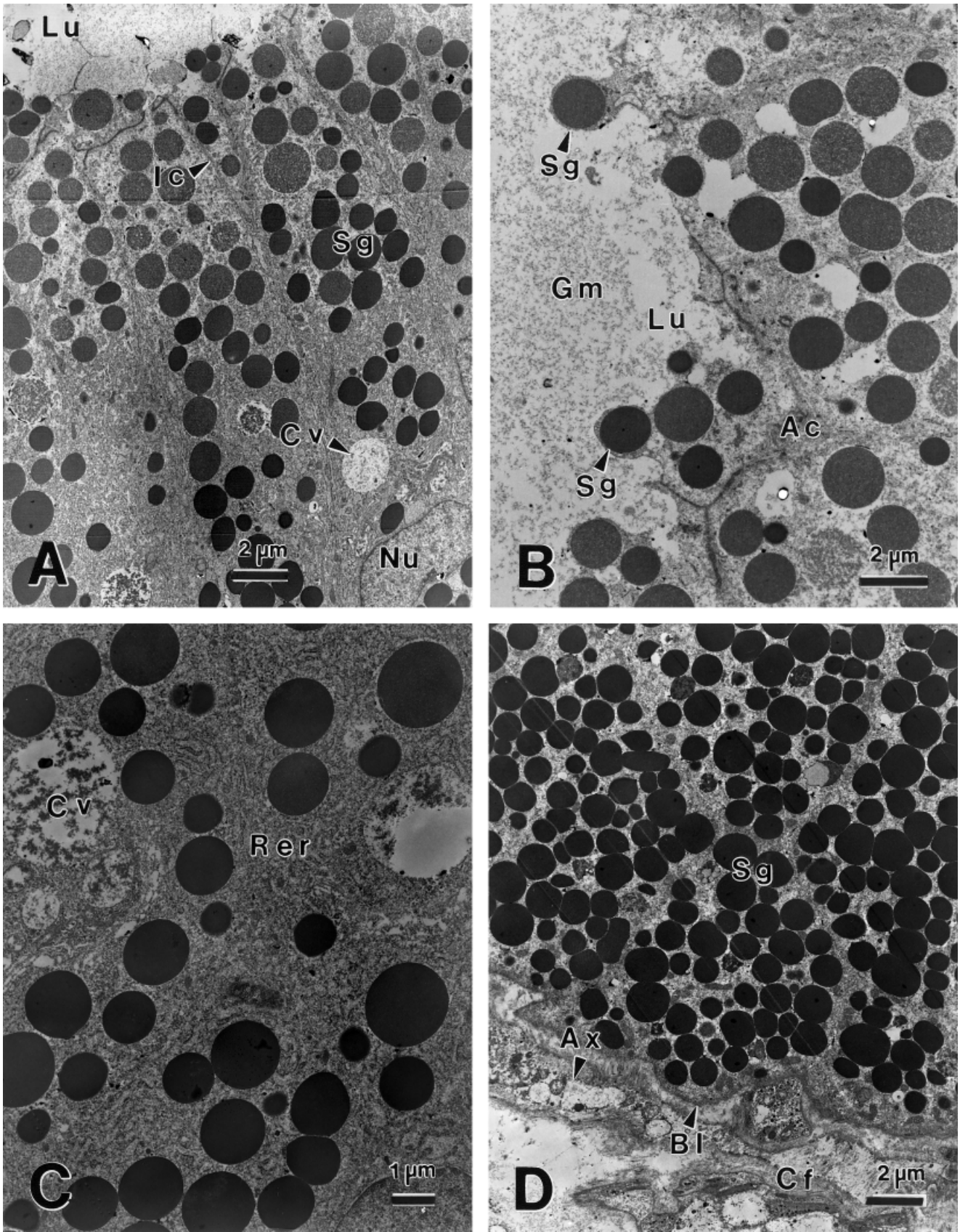


Fig. 10. Transmission electron micrographs of the sexual segment of the kidney in a 31.2 cm *Seminatrix pygaea* sacrificed 8 October. **A:** Overview of supranuclear region. **B:** Apical cytoplasm. **C:** Nuclear region. **D:** Basal cytoplasm. Ac, apical cytoplasm; Ax, axons; Bl, basal lamina; Cf, collagen fibers; Cv, condensing vacuoles; Gm, granular material; Ic, intercellular canaliculus; Lu, lumen; Nu, nucleus; Rer, rough endoplasmic reticulum; Sg, secretory granules.

tions are utilized by sperm in the female genital tract is unknown.

Ultrastructure

The only previous ultrastructural study on the sexual segment of a snake is by Kuhnel and Krisch (1974) on *Natrix natrix*. All of their specimens were collected in one month (November), and the reproductive condition of the specimens was not reported. The ultrastructure of the sexual segment of *N. natrix* in many respects resembles that of *Seminatrix pygaea* from late summer or fall. The columnar epithelial cells are filled with secretory granules, most of which are highly osmiophilic, whereas others, which we consider condensing vacuoles, contain a granular material or "vesicular or foamy inclusions." Mitochondria are concentrated in the basal regions, Rer is paranuclear, and Golgi complexes are supranuclear. Nerve fibers are frequently observed in the connective tissue surrounding the tubules.

One major difference is that Kuhnel and Krisch (1974) report that the sexual segment of *Natrix natrix*, unlike other portions of the kidney tubules, is surrounded by a sheet of elongate contractile cells. These cells give positive reactions for alkaline phosphatase, and the authors stated that these cells are similar to mammalian myoepithelial cells. We found no such sheath of cells around the sexual segment of *Seminatrix pygaea* and neither myoepithelium nor smooth muscle has been reported around kidney tubules in other squamates. Their illustrations do not convince us of the presence of any contractile elements, although collagen fibers are in evidence.

Kuhnel and Krisch (1974), however, clearly describe and illustrate the apocrine mode of product release in *Natrix natrix* that we found in *Seminatrix pygaea*. Sanyal and Prasad (1966), in the Indian house lizard (*Hemidactylus flaviviridis*), were the first to note that release of secretory granules in the sexual segment is apocrine.

The secretory granules of the sexual segment of *Lacerta sicula* (Furieri and Lanzavecchia, 1959) and the second region of the segment in *Cnemidophorus lemniscatus* (Del Conte and Tamyó, 1973) are different in appearance from those of *Natrix natrix* and *Seminatrix pygaea*. In the lizards, the mature secretory granules lack uniform density and contain a central dense core surrounded by a lighter material. In the snakes, the granules are uniformly electron-dense and superficially resemble the zymogen granules of pancreatic Paneth cells.

Other ultrastructural studies have not addressed seasonal variation of the sexual segment nor the relationship to the spermatogenic cycle. The exact timing of mating in *Seminatrix pygaea* is unknown. Because males possess sperm in distal portions of the vas deferens throughout the year, the possibility exists that mating could occur at any time. Sever and Ryan (1999), however, found sperm in sperm

storage tubules of a female sacrificed on 16 May and in the vagina and posterior uterus of a female sacrificed on 9 June, whereas sperm were absent in the oviducts of all females collected in July, October, and March. These findings, although limited, suggest that mating occurs in late spring.

The actual mating season, therefore, may extend into periods in which the sexual segment granules are no longer being released and a new wave of spermatogenesis has commenced (16 May) and proximal reproductive ducts are evacuated (9 June). Fetuses close to birth size are found in the oviducts of females sacrificed on 30 July (Sever et al., 2000) and parturition usually occurs in mid-August (Seigel et al., 1995).

The sexual segment of the kidney in *Seminatrix pygaea* does not go through an extended period of inactivity but does show a cycle of synthesis and secretion that can be related to the spermatogenic cycle and mating activity. Synthetic activity is initiated in May, at the beginning of a new spermatogenic cycle, and continues into October, when spermiation is near completion. In March, when the testes are inactive and the vasa deferentia are filled with sperm produced in the previous cycle, secretion of the products of the sexual segment is most intense. Secretion during this premating period could be necessary to provide time for the passage of the products down the ureter in order to mix with sperm during mating later in spring.

Histochemistry

Although he did not conduct specific tests for lipids, Saint Girons (1972) studied the carbohydrate and protein histochemistry of 38 species in 11 families of lizards, two species in two families of amphisbaenids, and 33 species in six families of snakes. He reported that the secretory product of the sexual segment is always rich in proteins and lacks acidic mucins, but that the PAS reaction is variable. In amphisbaenids and most lizards, the PAS reaction is weak or absent; in Anguillidae the reaction is highly positive; and in snakes the reaction varies interspecifically from positive to absent.

Like Saint Girons (1972), we did not conduct a thorough histochemical or biochemical analysis of the granules, but we performed some basic histochemical tests for proteins and carbohydrates. We obtained a BB+ reaction for proteins, as well as a PAS+ reaction and AB- reaction in all monthly samples. These results suggest a glycoprotein or mucoprotein in the secretory granules. Other, more detailed cytochemical analyses have further characterized the secretory product in several squamates.

Bishop (1959), in the garter snake (*Thamnophis sirtalis*), reported that "cap"-like areas of the granules show positive reactions with several lipid tests and with PAS and suggested that glycogen occurs in the sexual segment. We found no ultrastructural

evidence for glycogen in the sexual segment of *Seminatrix pygaea*. Bishop (1959) reported that the segment granules exhibit only a "faint flecking" when subjected to tests for proteins.

In contrast to the garter snake, Burtner et al. (1965) reported that the secretory granules of the rattlesnake, *Crotalus adamanteus*, are principally composed of some basic protein, probably containing tyrosine, lysine, cysteine, and tryptophan, as well as small amounts of other amino acids. Burtner et al. (1965) also reported the presence of some neutral muco- or glycoprotein (PAS+, AB-) and an unsaturated lipid moiety. The resemblance of the secretory granules to zymogen granules of pancreatic Paneth cell is superficial, as no enzymatic activity is discernable in the granules (Burtner et al., 1965).

Kuhnel and Krisch (1974) found no detectable carbohydrates in the secretory granules of *Natrix natrix* and a weak reaction for proteins. Instead, they reported that the granules were composed of lipids and phospholipids and that the cells of the sexual segment contain several hydrolases and oxyreductases which reflect enzyme activities of the glycolytic pathway, the citrate cycle, and related metabolic pathways.

In lizards, the cytochemistry of the sexual segment of the Indian house lizard, *Hemidactylus flaviviridis*, is the subject of articles by Misra et al. (1965), Sanyal and Prasad (1966), and Prasad and Reddy (1972). They reported that the secretions of the sexual segment are rich in phospholipids and contain acid phosphatase. The secretory granules also contain some protein but lack carbohydrates (Sanyal and Prasad, 1966). The association of acid phosphatase with phosphatides in the sexual segment, together with the presence of esterase in the oviduct could result in the liberation of fatty acids and glycerylphosphorycholine; these products may be used to sustain sperm (Sanyal and Prasad, 1966). Prasad and Reddy (1972) suggested that the sexual segment is homologous with the seminal vesicles of mammals.

In the lizard *Cnemidophorus lemniscatus*, however, Del Conte and Tamyo (1973) found little evidence for a lipid moiety in the secretory granules. Instead, they reported that granules in the first region of sexual segment contain a mucoprotein, whereas in the second region the granules contain a greater abundance of protein.

In summary, our observations on the glyco- or mucoprotein nature of the granules in the sexual segment of *Seminatrix pygaea* agrees most with Saint Girons (1972) on a variety of snakes, Burtner et al. (1965) on *Crotalus adamanteus*, and Del Conte and Tamyo on the lizard *Cnemidophorus lemniscatus*. However, none of these previous studies nor the present study conducted extensive tests for lipids, so whether phospholipids, etc., occur, as reported in *Natrix natrix* and *Hemidactylus flaviviridis*, requires further investigation. If interspecific differ-

ences do occur in chemistry of the sexual segment granules, such findings could have physiological implications concerning the transport, storage, and capacitation of sperm and these data also could have phylogenetic significance.

CONCLUSIONS

We propose that possession of a portion of the male nephron modified into a sexual segment can be traced back to the common ancestor of the squamate or even lepidosaurian clade. Thus, the character is a very ancient trait that appeared before differentiation of the 5,000+ species of extant squamates. These taxa have evolved a myriad of diverse morphological, ecological, physiological, behavioral, and reproductive characters. We should not be surprised, therefore, to find that interspecific differences occur in the location of the sexual segment (terminal segment, collecting duct, etc.), chemical nature of the secretory product, timing of secretory activity, etc., that reflect the diversity in other characters. We should expect homoplasy, as with other morphological and reproductive characters, to be commonplace. Because of these factors, the phylogenetic implications of some interspecific differences may be quite obscure beyond the level of species group or family. Thus, the challenge is to determine the functional significance of the morphology and physiology of the sexual segment in regard to the reproductive biology of a given species. Activity of the sexual segment is as essential to mating activity as spermatogenesis or testosterone production. Thus, one cannot truly understand the reproductive biology of any male squamate without consideration of the secretory cycle of the sexual segment.

ACKNOWLEDGMENTS

We thank R.J. Jensen for help with statistical tests; Mary Culley, Penelope Kistka, Allyson Treloar, and Christopher Hysell for help in the laboratory; and Daniel H. Gist for critically reading an earlier version of the manuscript.

LITERATURE CITED

- Bishop JE. 1959. A histological and histochemical study of the kidney tubules of the common garter snake, *Thamnophis sirtalis*, with special reference to the sexual segment in the male. *J Morphol* 104:307-357.
- Bons J, Saint Girons H. 1963. Ecologie et cycle sexual des amphisbaeniens du Maroc. *Bull Soc Sci Nat Maroc* 43:117-170.
- Burtner HJ, Floyd AD, Longley JB. 1965. Histochemistry of the "sexual segment" granules of the male rattlesnake kidney. *J Morphol* 116:189-193.
- Cuellar O. 1966. Oviducal anatomy and sperm storage structures in lizards. *J Morphol* 119:7-20.
- Dawes C. 1979. Biological techniques for transmission and scanning electron microscopy. Burlington, VT: Ladd Research Industries.

- Del Conte E. 1972. Granular secretion in the kidney sexual segments of female lizards, *Cnemidophorus l. lemniscatus* (Sauria, Teiidae). *J Morphol* 137:181–191.
- Del Conte E, Tamayo JG. 1973. Ultrastructure of the sexual segments of the kidneys in male and female lizards, *Cnemidophorus l. lemniscatus* (L.). *Z Zellforsch* 144:325–327.
- Depeiges A, Dufaure JP. 1980. Major proteins secreted by the epididymis of *Lacerta vivipara*. Isolation and characterization by electrophoresis of the central core. *Biochim Biophys Acta* 628:109–115.
- Devine MC. 1975. Copulatory plugs: enforced chastity. *Science* 187:844–845.
- Dorcas ME, Gibbons JW, Dowling HG. 1998. *Seminatrix*, *S. pygaea*. *Cat Am Amphib Rept* 679:1–5.
- Fox W. 1952. Seasonal variation in the male reproductive system of Pacific coast garter snakes. *J Morphol* 90:481–553.
- Fox W. 1965. A comparison of the male urogenital systems of blind snakes, Leptotyphlopidae and Typhlopidae. *Herpetologica* 21:241–256.
- Fox H. 1977. The urinogenital system of reptiles. In: Gans C, Parsons TS, editors. *Biology of the Reptilia*, vol. 6. Morphology E. New York: Academic Press. p 1–157.
- Furieri P, Lanzavecchia G. 1959. Le secrezione dell' epididimo e del rene sessuale nei rettili. Studio al microscopio elettronico. *Arch Ital Anat Embriol* 64:357–379.
- Gabe M, Saint Girons H. 1964. Contribution a l'histologie de *Sphenodon punctatus* Gray. Paris: Editions du Centre National de la Recherche Scientifique.
- Gampert O. 1866. Ueber die Niere von *Tropidonotus natrix* und der Cyprinoiden. *Zeit Wissen Zool* 16:369–373.
- Gibbons JW, Semlitsch RD. 1991. *Guide to the reptiles and amphibians of the Savannah River site*. Athens: University of Georgia Press.
- Heidenhain R. 1874. Mikroskopische Beitrage zur Anatomie und Physiologie der Nieren. *Arch Mikrosk Anat* 10:1–50.
- Humason GL. 1979. *Animal tissue techniques*, 4th ed. San Francisco: WH Freeman.
- Jones RC. 1998. Evolution of the vertebrate epididymis. *J Reprod Fert Suppl* 53:163–181.
- Kiernan JA. 1990. *Histological and histochemical methods: theory and practice*, 2nd ed. New York: Pergamon Press.
- Krohmer RW. 1986. Effects of mammalian gonadotropins (oFSH and oLH) on testicular development in the immature water snake, *Neroidea sipedon*. *Gen Comp Endocrin* 64:330–338.
- Kuhnel W, Krisch B. 1974. On the sexual segment of the kidney in the snake (*Natrix natrix*). *Cell Tiss Res* 148:412–429.
- Misra UK, Sanyal MK, Prasad MRN. 1965. Phospholipids of the sexual segment of the kidney of the Indian house lizard, *Hemidactylus flaviviridis* Ruppell. *Life Sci* 4:159–166.
- Pandha SK, Thapliyal JP. 1964. Effect of male hormone on the renal segment of castrated male of the lizard *Calotes versicolor*. *Copeia* 1964:579–581.
- Pough FH, Andrews RM, Cadle JE, Crump ML, Savitzky AH, Wells KD. 1998. *Herpetology*. Upper Saddle River, NJ: Prentice Hall.
- Prasad MRN, Reddy PRK. 1972. Physiology of the sexual segment of the kidney in reptiles. *Gen Comp Endocrin Suppl* 3:649–662.
- Prasad MRN, Sanyal MK. 1969. Effect of sex hormone on the sexual segment of kidney and other accessory reproductive organs of the Indian house lizard *Hemidactylus flaviviridis* Ruppell. *Gen Comp Endocrinol* 12:110–118.
- Regaud C, Policard A. 1903. Recherches sur la structure du rein de quelques ophidiens. *Arch Anat Microsc* 6:191–282.
- Saint Girons H. 1972. Morphologie comparee du segment sexuel du rein des squamates (Reptilia). *Archs Anat Micr Morph Exp* 61:243–266.
- Sanyal MK, Prasad MRN. 1966. Sexual segment of the kidney of the Indian house lizard, *Hemidactylus flaviviridis* Ruppell. *J Morphol* 118:511–528.
- Seigel RA, Loraine RK, Gibbons JW. 1995. Reproductive cycles and temporal variation in fecundity in the black swamp snake, *Seminatrix pygaea*. *Am Midl Nat* 134:371–377.
- Sever DM, Ryan TJ. 1999. Ultrastructure of the reproductive system of the black swamp Snake (*Seminatrix pygaea*). I. Evidence for oviducal sperm storage. *J Morphol* 241:1–18.
- Sever DM, Ryan, TJ, Morris T, Patton D, Swafford S. 2000. Ultrastructure of the reproductive system of the black swamp snake (*Seminatrix pygaea*). II. Annual oviducal cycle. *J Morphol* 245:146–160.
- Sokal RR, Rohlf FJ. 1995. *Biometry*, 3rd ed. New York: WH Freeman.
- Tribondeau, Bongrand. 1902. Localisation de la secretion du sulfo-indigotate de soude dans les tubes intermediaires du rein, chez le serpent. *Comp Rend Seances Soc Biol (Paris)* 55:102–104.
- Volsøe H. 1944. Structure and seasonal variation of the male reproductive organs of *Vipera berus* (L.). København: Spolia Zoologica Musei Hauniensis V. Skrifter, Universitetets Zoologiske Museum.