

## Transcranial magnetic stimulation (TMS) seeded tractography provides superior prediction of eloquence compared to anatomic seeded tractography

Matthew Muir, Sarah Prinsloo, Hayley Michener, Arya Shetty, Dhiego Chaves de Almeida Bastos, Jeffrey Traylor, Chibawanye Ene, Sudhakar Tummala, Vinodh A. Kumar, and Sujit S. Prabhu

*Department of Neurosurgery, The University of Texas M.D. Anderson Cancer Center, Houston, Texas, USA (M.M., S.P., H.M., A.S., C.E., S.S.P.); Department of Neurological Surgery, The University of Texas Southwestern Medical Center, Dallas, Texas, USA (J.T.); Department of Neuroradiology, The University of Texas M.D. Anderson Cancer Center, Houston, Texas, USA (V.A.K.); Department of Neurosurgery, Cleveland Clinic, Cleveland, Ohio, USA (D.C.A.B.); Department of Neuro-Oncology, The University of Texas M.D. Anderson Cancer Center, Houston, Texas, USA (S.T.)*

**Corresponding Author:** Sujit S. Prabhu, MD, 1515 Holcombe Boulevard, Room FC7.2000, Unit 442, Houston, TX 77030-4009, USA ([sprabhu@mdanderson.org](mailto:sprabhu@mdanderson.org)).

### Abstract

**Background.** For patients with brain tumors, maximizing the extent of resection while minimizing postoperative neurological morbidity requires accurate preoperative identification of eloquent structures. Recent studies have provided evidence that anatomy may not always predict eloquence. In this study, we directly compare transcranial magnetic stimulation (TMS) data combined with tractography to traditional anatomic grading criteria for predicting permanent deficits in patients with motor eloquent gliomas.

**Methods.** We selected a cohort of 42 glioma patients with peritumoral tumors who underwent preoperative TMS mapping with subsequent resection and intraoperative mapping. We collected clinical outcome data from their chart with the primary outcome being new or worsened motor deficit present at 3 month follow up, termed “permanent deficit”. We overlaid the postoperative resection cavity onto the preoperative MRI containing preoperative imaging features.

**Results.** Almost half of the patients showed TMS positive points significantly displaced from the precentral gyrus, indicating tumor induced neuroplasticity. In multivariate regression, resection of TMS points was significantly predictive of permanent deficits while the resection of the precentral gyrus was not. TMS tractography showed significantly greater predictive value for permanent deficits compared to anatomic tractography, regardless of the fractional anisotropic (FA) threshold. For the best performing FA threshold of each modality, TMS tractography provided both higher positive and negative predictive value for identifying true nonresectable, eloquent cortical and subcortical structures.

**Conclusion.** TMS has emerged as a preoperative mapping modality capable of capturing tumor induced plastic reorganization, challenging traditional presurgical imaging modalities.

### Key Points

- Anatomy does not always predict eloquence. The precentral gyrus can be safely resected in some patients.
- TMS tractography provides superior predictive value for eloquence compared to anatomic tractography.

## Importance of the Study

Despite widespread use of traditional anatomic grading criteria for brain tumor patient selection, preoperative risk stratification, and surgical planning, accumulating data has indicated that anatomy may not always predict surgical eloquence. Additionally, recent studies have shown significant utility for preoperative functional imaging modalities such as transcranial magnetic stimulation. However, little data exists directly comparing functional imaging with traditional structural imaging. In this study, we show that functional imaging can provide significantly better prediction of

eloquent cortical and subcortical structures than anatomical based imaging. We show that TMS tractography is significantly more predictive of eloquence than anatomic tractography, the current standard-of-care at our institution. We describe two case examples that illustrate how TMS tractography can be used to avoid permanent neurological deficits while significantly increasing extent of resection. This study challenges current practices and lays a foundation for large scale studies that provide more data-driven, patient-specific definitions of eloquence.

For patients with perielloquent tumors, surgeons must balance maximizing extent of resection with minimizing postoperative neurological morbidity. Sawaya et al found that anatomic tumor location predicted risk for neurological deficits. The authors defined three different groups: eloquent, near-eloquent, and non-eloquent with different anatomic criteria for each. They found that patients with eloquent or near-eloquent tumors had significantly higher risk for neurological morbidity.<sup>1</sup> These anatomic grading criteria have since widely been used for surgical indications and preoperative risk stratification.

However, recent accumulating data has shown that anatomic factors alone cannot predict eloquence.<sup>2</sup> Intraoperative mapping with direct cortical stimulation (DCS) has become the gold standard for functional delineation and preservation of eloquent cortical and subcortical structures.<sup>3</sup> However, optimal patient selection and surgical planning require functional data preoperatively. Transcranial magnetic stimulation (TMS) has recently emerged as a method of noninvasively mapping functional cortex. Many studies have found significant correlation between preoperative TMS data and intraoperative DCS data for motor eloquent tumors.<sup>4</sup> Additionally, previous work from our group has shown that resection of structures identified by TMS seeded DTI tractography leads to permanent deficits.<sup>5</sup>

Some studies have demonstrated the correlation between TMS imaging features and clinical outcomes, while another used clinician surveys to compare TMS and anatomic tractography.<sup>6-8</sup> Here we investigate the strength of TMS data for prediction of permanent deficits compared to traditional anatomic grading criteria. We aim to provide insight into the appropriate role of structural anatomic data versus functional mapping data with regards to choosing surgical candidates, evaluating risk, and planning for the surgery in patients with motor eloquent gliomas.

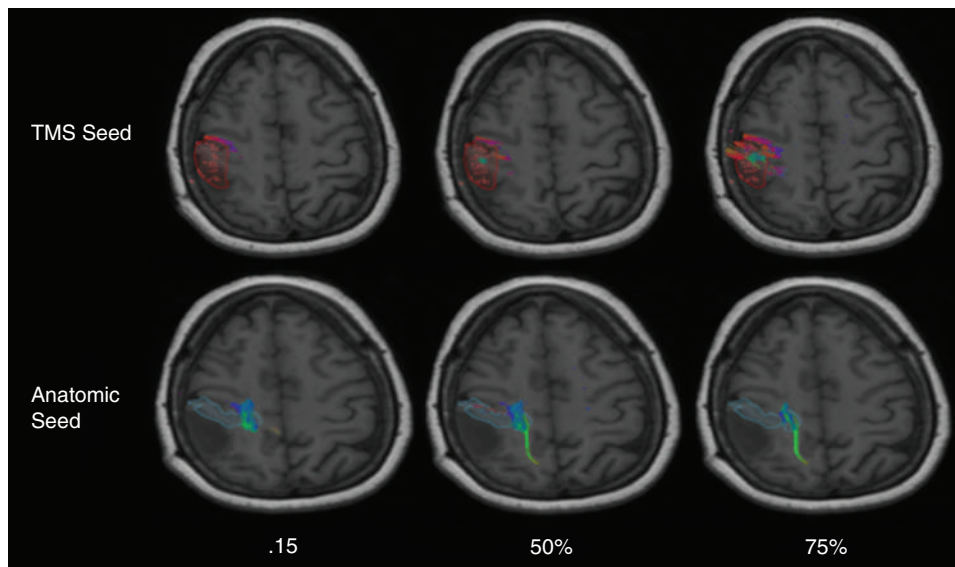
## Methods

Forty-two patients were included in this retrospective study with the following inclusion criteria: patients over

18 with motor eloquent gliomas as determined by preoperative MRI who also underwent presurgical TMS motor mapping. We used the following exclusion criteria: patients with postoperative acute infarctions, postoperative disease recurrence in eloquent cortex before 3 month follow up, and significant postoperative edema causing midline shift >10 mm present at 3 month follow up. We collected demographic data from the electronic medical record as well as clinical outcome data, with the primary outcome being new or worsened postoperative motor deficit present at 3 month follow up, termed "permanent deficit". A deficit was recorded if the neurological exam at 3 month follow up showed a weaker score in motor strength in any extremity compared to the preoperative examination. Informed consent was obtained from all patients. This study was approved by MD Anderson Institutional Review Board #2021-0856.

## Transcranial Magnetic Stimulation

A navigated TMS system was utilized in the present study (NBS System 3.2, Nexstim, Helsinki, Finland). The most likely location of the hand knob was identified anatomically. This area was then stimulated in a random pattern while systematically varying the rotation, tilt, and yaw of the magnetic field. The location of maximal motor evoked potential (MEP) was identified. Resting motor threshold (RMT) was identified using this position.<sup>9</sup> MEPs for generating the RMT were measured in the abductor digiti minimi. or in abductor pollicis brevis, whichever produced the most consistent response on a patient-by-patient basis. TMS stimulation was delivered over the primary motor cortex (MI) via a figure 8 head coil, at 110% intensity of resting motor threshold. The coil orientation was kept perpendicular to the central sulcus with a minimum of a 2 s interval between stimuli. For quantification of the TMS effect, MEPs were measured in the upper and lower extremity. For the upper extremity, surface electrodes were placed on the abductor pollicis brevis. For the lower extremity, surface electrodes were placed on the abductor digiti minimi. In both upper and lower extremity mappings and for areas close to the tumor location, density of the



**Figure 1** Axial preoperative DTI generated at 0.15, 50%, and 75% FA thresholds for both anatomic and TMS seeded paradigms. Top row, is the ROI for the TMS seed. Bottom row, is the ROI for the anatomic seed.

stimuli was increased and varying coil orientations were tested. Positive sites were marked in the 3D brain surface as white dots and this information was sent as a report to the surgeon. These sites were also exported in DICOM files as a “navigated brain scan” (NBS) to be uploaded in the Neuronavigation system (Elements, BrainLab, Munich, Germany).

### Diffusion Tensor Imaging

DTI, and structural MR imaging were performed using a 3T MRI scanner (GE Healthcare, Waukesha, Wisconsin) with an eight-channel head coil. DTI was performed using a diffusion-weighted spin-echo echo-planar imaging sequence (repetition time/echo time = 10 000/120 ms, matrix size = 128 × 128, field of view = 22 × 22 cm, slice thickness = 2.5 mm with no intersection gap, number of diffusion-weighting directions = 32,  $b$  value = 1000 s/mm<sup>2</sup>). In total, 44 slices were acquired, covering the medulla to the top of the brain. High-resolution 3D spoiled gradient-echo T1-weighted sequences were acquired for anatomic reference. DTI fiber tractography was generated using a deterministic method (Brainlab Elements) based on two regions of interest (ROIs) placed on the fractional anisotropy map. We used the TMS positive points as the cortical ROI point and the brainstem for the subcortical ROI. We used three different sets of DTI parameters for each modality. For one set, we used the standard parameters currently used at our institution: 0.15 fractional anisotropic (FA) threshold, 30 mm minimum fiber length, and 15 degree maximum angulation. We also used parameters described in our previous manuscript: 75% FA threshold, 110 minimum fiber length, and a 30 degree maximum angulation as well as 50% FA threshold, 110 minimum fiber length, and a 30 degree maximum angulation. Using the FA threshold percentage approach previously described,<sup>10</sup> for

each patient we increased the FA threshold until no fibers were generated. This was defined as 100% FA threshold for that patient. This contrasts with the current standard at our institution, which is a standard FA threshold of 0.15 across every patient. Each ROI variation (TMS points, and precentral gyrus) was analyzed with all three sets of parameters, for a total of 6 DTI combinations. **Figure 1** shows preoperative MRI of tractography generated with all 3 sets of parameters across both cortical ROIs, the precentral gyrus, and TMS points.

### Imaging Data Collection

We used Brainlab Elements (Brainlab Inc, Munich, Germany) to import and visualize the NBS DICOM output from the TMS system. We used automated anatomic segmentation algorithms to create anatomic objects of the precentral gyrus on the ipsilateral side to the lesion. We used the manual segmentation feature to make objects of the TMS points. We then analyzed the spatial relationship between TMS positive points and the precentral gyrus. We separated patients into anatomic groups, defining one group with patients having glioma infiltration of anatomically defined eloquent cortex (precentral gyrus) and the other group having no infiltration of precentral gyrus. We stratified patients using TMS points, with one group showing TMS points within the tumor and the other group showing TMS points outside of the tumor.

### Perioperative Overlays

We used Brainlab Elements (Brainlab Inc, Munich, Germany) to import and visualize the Navigated Brain Scan (NBS) DICOM output from the TMS system. Objects of the TMS points were created. We analyzed preoperative

imaging features, collecting patients with TMS points within the glioma as well as patients with glioma infiltrating the precentral gyrus. We then fused the NBS scan with the preoperative T1 MRI so that the TMS objects could be viewed on the T1 MRI. We then used a semi-elastic fusion approach (Brainlab Elements) to superimpose the postoperative MRI onto the preoperative MRI to view preoperative functional and anatomic imaging features in context of the resection cavity. The fusion was based on co-registrations using intra-axial markers determined by the Brainlab Elements algorithm.

### Statistical Analysis

Statistical analysis was done using SPSS (IBM Corp, Armonk, NY). We constructed a binary classifier system using TMS and anatomic variables to predict permanent deficits. We performed univariate binary logistic regression to find significant predictors of permanent deficits. We then used the significant variables in univariate logistic regression to perform multivariate logistic regression.

We calculated Receiver operator characteristics (ROC). A true positive was defined as the site (TMS point and/or white matter tracts [WMTs]) resected with a corresponding permanent deficit. A false positive was defined as the site resected with no corresponding permanent deficit. A true negative was defined as the site unresected with no permanent deficit. A false negative was defined as the site not resected with a permanent deficit. We calculated the positive predictive value (PPV) and negative predictive value (NPV) for resection of WMTs identified at various FA thresholds.

We constructed an ROC curve to model the predictive value of TMS and anatomic seeded tractography across the spectrum of FA thresholds and calculated the area under the curve (AUC) for each modality. We then selected the best performing TMS FA threshold compared to the current standard of care at our institution and modeled these with contingency tables. We aggregated true predictions (true positive/true negative) and false predictions (false positive/false negative) for both DTI parameters and performed a McNemar test to evaluate statistical significance between the groups at a significance level of  $P < .05$ .

## Results

**Table 1** shows perioperative patient data, TMS points relative to glioma and the precentral gyrus, and postoperative outcomes. Nineteen patients (45%) showed TMS captured neuroplasticity—TMS points significantly displaced from the precentral gyrus. The average displacement distance was 12.5 mm, while the median displacement distance was 11.5 mm. Twelve patients (29%) exhibited preoperative weakness. Nine patients (21%) had TMS positive points within the tumor, while 27 (64%) had glioma infiltration of the precentral gyrus. Eight patients (19%) had TMS positive points resected, while 18 patients (43%) underwent resection of the glioma infiltrated precentral gyrus. Seven patients (16%) had a new or worsened motor deficit persistent through 3 month follow up.

**Table 2** shows univariate binary logistic regression using permanent deficits as the dependent variable. The preoperative imaging features of TMS positive points within the tumor and tumorous infiltration of the precentral gyrus were not significantly predictive, while both the resection of TMS positive points as well as resection of the precentral gyrus were significantly predictive ( $P = .012$ ,  $P = .051$ ). Multivariate regression using these variables showed that TMS positive point resection was significantly predictive, while resection of the precentral gyrus approached but did not reach significance ( $P = .068$ ).

**Figure 2** shows the ROC curve comparing TMS versus anatomic seeded tractography. Each curve depicts the three different FA threshold parameters using the seed ROI of TMS (blue curve) and the precentral gyrus (orange curve). The AUC for the TMS curve was 0.90, while the AUC for the precentral gyrus curve was 0.72. **Table 3** shows the contingency tables for the best performing FA threshold for each seed ROI. We use the McNemar test to compare the difference between the ratio of true cases (true positive/true negatives) of false cases (false positives/false negatives) for TMS tractography versus anatomic tractography. The analysis revealed that TMS tractography shows significantly more cases of true positives/true negatives than anatomic tractography ( $P = .018$ ). **Figure 3** illustrates two case examples of the clinical impact of TMS versus anatomic tractography.

## Discussion

Spetzler et al first proposed an anatomic grading system for arteriovenous malformations (AVMs), assuming eloquent cortical regions occupy their normal anatomic location.<sup>10</sup> Sawaya et al extended this to oncology cohorts, estimating risk for postoperative neurological morbidity with similar measures.<sup>11</sup> Neurosurgeons have since commonly used these measures to optimize patient selection and preoperative risk stratification as well as to standardize cohort comparisons. However, recent studies have reported the resection of anatomically defined eloquent structures without adverse clinical sequela.<sup>11,12</sup> Pouratian et al reviewed multiple studies providing evidence that anatomic factors alone do not predict eloquence.<sup>2</sup>

Optimal patient selection, risk stratification, and surgical planning require accurate identification and prediction of eloquent cortical and subcortical structures. In our view, this requires studies that directly investigate the clinical consequences of resecting various structures, whether structural or functional. We have termed these types of neurosurgical investigations here as “knockout” studies, drawing a parallel term from other fields of biology. We aim to systematically correlate the surgical removal of various imaging features with meaningful functional outcomes. Studies from other groups have used similar methodology to study a variety of preoperative imaging techniques.<sup>13,14</sup> Previous work from our group has built on this work and established robust methodology for conducting “knockout” studies using sophisticated overlays, long-term functional outcomes, and appropriate exclusion criteria to mitigate confounding factors. In this study,

**Table 1** Patient Characteristics

Type	Number	%
Gender		
Male	27	64
Female	15	36
Age		
<60	13	31
>60	29	69
Tumor type		
Low grade glioma	23	55
High grade glioma	18	43
Preoperative weakness		
Yes	12	29
No	30	71
TMS captured neuroplasticity		
Yes	19	45
No	23	55
Resection of TMS points		
Yes	8	19
No	34	81
Resection of anatomical motor cortex		
Yes	19	45
No	23	55
New or worsened deficit immediately postoperatively		
Yes	12	29
No	30	71
New or worsened permanent deficit (3 months)		
Yes	7	17
No	35	83

we aimed to leverage this methodology to directly compare the strength of preoperative TMS functional imaging versus traditional structural MRI for predicting true eloquent, nonresectable tissue.

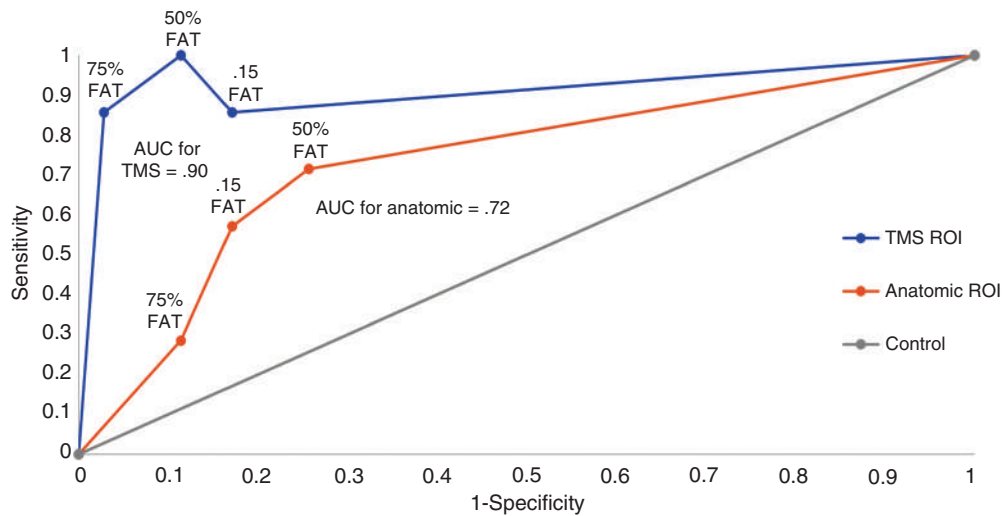
While manual segmentation of TMS points is a standardized process lacking interindividual variability, we wanted to ensure accurate and consistent anatomic segmentation for normalized comparisons. We used an automated segmentation algorithm based on 3D spatial MRI data to define the precentral gyrus, the same algorithm currently used at our institution for cortical anatomic DTI seeding. A previous multi-institutional study showed that automated segmentation algorithms from 3D MRI spatial data more accurately and completely identify the precentral gyrus compared to fMRI or 2D MRI analysis in the axial, coronal, and sagittal plane by an experienced neuroradiologist.<sup>15</sup> These results were independent of institution, MRI vendor, magnetic field strength, or image sequence parameters. The authors note that increased mass effect can render visual identification of anatomical landmarks difficult, lending an advantage to computer aided analysis for detecting the subtle structural contrast differences. Additionally, automated algorithms for anatomic segmentation allow for consistent comparisons across institutions and cohorts.

Initial analyses from this study revealed that almost half (46%) of patients showed TMS points significantly displaced from the precentral gyrus with an average distance of 12.5 mm, a phenomenon not observed in TMS studies on healthy patients.<sup>16</sup> These initial results necessitated defining a distinction between the functionally defined primary motor cortex (TMS points) and the anatomically defined primary motor cortex (precentral gyrus). The plasticity observed in this cohort supports previous studies using a variety of methods to demonstrate tumor induced neuroplasticity in glioma patients.<sup>17–19</sup>

Preoperative imaging features such as presence of TMS positive points within the tumor and tumor infiltration of

**Table 2** Univariate Binary Logistic Regression for Prediction of Permanent Deficit From Cortical Anatomic and TMS Perioperative Variables

	No. of Patients	Permanent Deficits, No. (%)	OR	95% CI	P value
TMS positive points within tumor					
Yes	9	3 (33%)	3.6	0.64–20.57	.15
No	33	4 (12%)			
Tumorous infiltration of precentral gyrus					
Yes	26	6 (23%)	4.5	0.49–41.47	.18
No	16	1 (6.2%)			
TMS positive points resection					
Yes	8	4 (50%)	10.3	1.67–64.00	.012
No	34	3 (8.8%)			
Resection of precentral gyrus					
Yes	19	6 (32%)	9.2	0.99–85.78	.051
No	23	1 (4.3%)			



**Figure 2** Receiver operating characteristic (ROC) curve for TMS versus anatomic tractography at various FA thresholds.

**Table 3** Predictive Models of Best Performing FAT for TMS Tractography versus Current Standard of Care FAT for Anatomic Tractography ( $P = .018$ )

Tractography at 75% FAT	Deficit	No Deficit	Anatomic at 0.15 FAT	Deficit	No Deficit
Resection	6	1	Resection	4	6
Preservation	1	34	Preservation	3	29

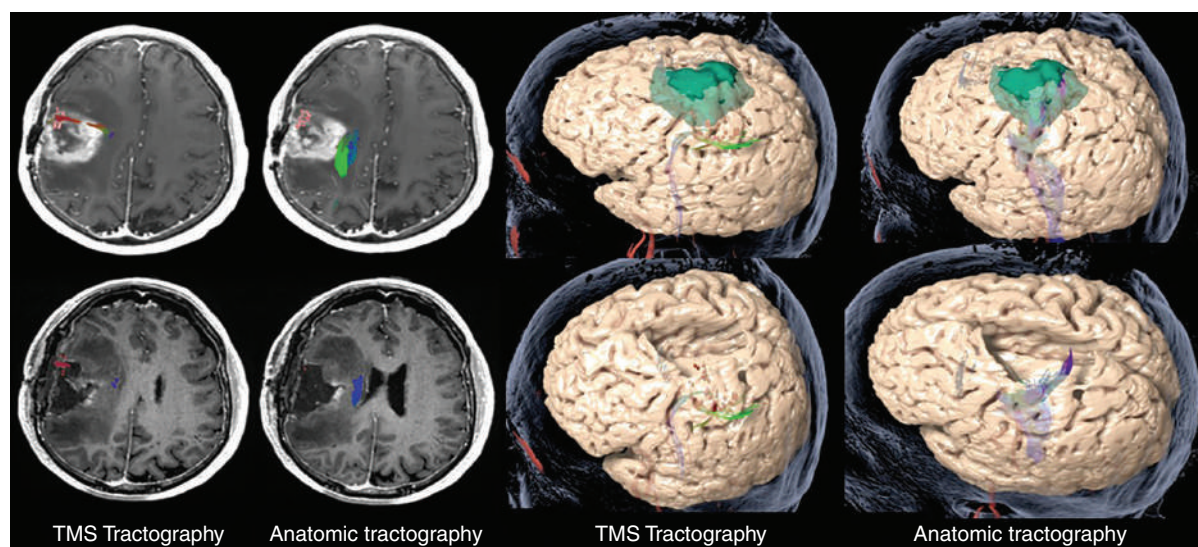
the precentral gyrus did not significantly predict permanent deficits. After generating overlays with postoperative scans showing the resection cavity, we found that both resection of TMS positive points as well as resection of the primary motor cortex defined anatomically (precentral gyrus) were significant predictors of permanent deficits. Further multivariate analysis revealed that resection of TMS positive points was a significant predictor of permanent deficits ( $P = .018$ ), while resection of the precentral gyrus approached but did not reach statistical significance ( $P = .068$ ). This analysis shows that resection of TMS points significantly predicts permanent deficits even when controlling for anatomic factors. These results support accumulating data showing that anatomy alone cannot predict eloquence.

We then generated ROC curves using the various FA thresholds for both anatomic and TMS tractography. The curve for TMS showed significantly increased AUC (0.90) compared to the curve for anatomy (0.72), indicating that TMS tractography provides superior diagnostic accuracy for eloquent tissue compared to anatomic tractography, regardless of FA threshold selection.<sup>20</sup> We selected the best performing FA thresholds for both ROI paradigms and modeled their predictive value with contingency tables in [Table 3](#) and compared their ratio of true cases (true positives/true negatives) to false cases (false positives/false negatives). We show that the best performing FA threshold for TMS significantly outperforms the best performing FA

threshold for anatomic tractography ( $P = .018$ ), the current standard of care at our institution.

[Figure 3](#) describes two case examples that illustrate these statistical findings. Patient 1 shows a false negative case for anatomic tractography that contributed to its comparatively lower negative predictive value. Patient 2 shows a false positive case that contributed to the comparatively lower positive predictive value for anatomic tractography. A low negative predictive value can falsely indicate a safe gross total resection as seen in patient 1, while a low positive predictive value can needlessly prohibit a gross total resection as seen in patient 2.

We found in this study that many patients undergo the resection of WMTs identified by anatomic seeded DTI tractography and do not show a corresponding permanent deficit. We also previously found that a subset of WMTs identified at lower FA thresholds can be safely resected, possibly due to lack of recent activity, shown to decrease myelination and in turn decrease fractional anisotropy.<sup>5</sup> This study extends these findings, showing that not only the FA threshold can determine resectability of WMTs, but the cortical ROI also distinguishes between WMTs safe for resection and WMTs indispensable for intact long-term neurological function. These results could be explained by previous work describing glioma-induced topographic displacement of specialized cortical hubs through latent networks of cortical interneurons. These hubs then recruit local WMTs to send their specialized information, leading



**Figure 3** Case examples illustrating the clinical impact of TMS versus anatomic tractography in two separate patients. Top row shows preoperative imaging. Bottom row shows the postoperative MRI overlaid onto the preoperative MR, or “perioperative overlay”. In Patient 1, the resection disrupted the DTI tracts generated from TMS points (left) and preserved the standard-of-care DTI tracts generated from anatomy (precentral gyrus). The patient had severe permanent motor deficits persisting through 3 month follow up. In Patient 2, the resection disrupted the standard-of-care anatomic DTI tracts (right) and preserved the TMS tracts (left). A gross total resection was achieved instead of a subtotal resection that would have resulted from preserving the anatomic DTI tracts. This patient had no postoperative neurological deficits.

to a distinction between active and latent WMTs consistent with the hodological framework of cerebral processing.<sup>21</sup>

Hodologic theory conceptualizes brain function emerging from a dynamic, global network instead of distinct, static regions.<sup>22</sup> Original neuroscience experiments used lesion-based methods to study brain functional anatomy, correlating loss-of-function phenotypes with the lesioned anatomic area. The resulting “localizationist” theory postulated that brain function resides in static cortical centers with specialized WMTs, forming the basis for neurosurgical anatomic grading criteria. However, more recent studies have shown that these experiments fail to account for the necessity of temporal synchronization from distant, functionally connected networks.<sup>23</sup> These recent experiments have led to more global conceptualizations of brain function composed of an ensemble of shifting cortical hubs using ambiguous, interconnected WMT “roads” capable of transmitting many different types of information.<sup>22</sup>

These advances undermined the dogma of a static CNS organization unable to compensate for injury to “eloquent” areas and formed the basis for neuroplastic injury adaptation theories, specifically with applications to gliomas.<sup>24</sup> Recent studies have shown significant glioma-induced neuroplasticity that exploits the preexisting architecture of hierarchical redundancies underlying healthy global connectivity and synchronization.<sup>21</sup> Data from our cohort provides further evidence for this phenomenon, showing TMS points significantly displaced from the precentral gyrus. Not only does the cortical origination of specialized information undergo topographic displacement, but new, anatomically distinct WMT “bridges” are recruited for

information transmission, driving their myelination, and increased fractional anisotropy.<sup>21,25</sup> This dynamic system renders neurosurgical interventions difficult, obfuscating which tissue must be preserved for functional recovery. However, perhaps TMS combined with tractography can capture the state of this patient-specific process before surgery, acting as a preoperative “snapshot”. Our results provide preliminary evidence that presurgical TMS cortical mapping can not only capture the location of displaced cortical hubs, but perhaps also can exploit tractography using various FA thresholds to identify clinically relevant WMTs recently used for information transmission.

We found that many patients underwent resection of WMTs identified by anatomic seeded tractography without permanent deficits. These results are striking considering previous studies establishing significant correlation between anatomic tractography and intraoperative mapping data.<sup>26-33</sup> Additionally, previous work from our group showed that a subset of TMS points can be safely resected, despite an established corresponding significant correlation between cortical TMS points and intraoperative DCS data.<sup>5,34</sup> Perhaps the mechanistic details of intraoperative mapping can provide insight into this phenomenon. Intraoperative motor mapping interrogates structural connections by correlating exogenous cortical and subcortical stimulation with motor evoked potentials (MEPs) recorded from electrodes on the upper and lower extremity. A positive MEP is assumed to result from electrical current propagation from the site of stimulation to the electrode.<sup>35</sup> Because latent WMTs resulting from glioma-induced neuroplasticity presumably retain structural connection,<sup>21</sup> this mechanism seems to imply

a lack of ability to distinguish between signal propagation through latent versus active WMTs. Perhaps mere structural connection does not necessarily indicate long-term functional or clinical relevance. In other words, perhaps DCS provides sensitive but not *specific* identification of eloquent, nonresectable structures. This study provides more evidence that may suggest a subset of DCS points can be safely resected, though this hypothesis lacks direct evidence.

Data from this study indicates that TMS combined with TMS ROI DTI tractography is the main predictor of nonresectable eloquent tissue. Multivariate analysis showed that resection of tissue identified by TMS tractography predicts permanent deficits regardless of anatomic location. Many of these TMS points were significantly displaced from the precentral gyrus, however their removal still led to permanent motor deficits. These results indicate the need to account for glioma-induced neuroplasticity when selecting patients and planning for surgery, supporting previous authors questioning current surgical indications primarily based on anatomic and structural considerations. Duffau asserts that a topographic reductionist approach for patient selection has resulted in inappropriate patient exclusion.<sup>36</sup> He writes that most series do not report patients not selected for resection, resulting in a considerable bias in the literature and lack of ability to robustly study current surgical indications.<sup>36</sup>

Southwell et al reported on a cohort of 58 patients with supratentorial gliomas deemed unresectable at other institutions by preoperative imaging modalities. The authors operated on these patients who were previously ruled out of surgery after initial workup at outside institutions. Despite presumed tumor involvement of eloquent areas determined by preoperative MRI, stimulation mapping rarely revealed functional sites in or around the lesion. They achieved an average extent of resection of nearly 90% with no new postoperative neurological deficits, concluding that current preoperative imaging is inadequate for decision making.<sup>37</sup> This study outlines the practical consequence of using anatomic factors or unreliable functional data to predict eloquence, resulting in inappropriate patient selection. Resources should be allocated towards developing accessible preoperative functional imaging modalities capable of accurate and precise identification of true “eloquent,” nonresectable cortex for appropriate patient selection and surgical planning. Data from our cohort provides preliminary evidence that TMS combined with DTI tractography can accomplish this task with both a high positive predictive value and negative predictive value.

Despite the small patient cohort, this study could provide insight into how machine learning principles can solve neurosurgical problems. The hazy separation between statistics and machine learning lies mostly in the nature of the data, complexity of the models, and goal of the study.<sup>38</sup> While we focused on inferences describing statistically significant relationships between variables, extrapolating the design of this study could lead to machine learning applications. Supervised machine learning generates a predictive algorithm using “training sets,” namely an input correlated to an outcome.<sup>39</sup> In our study, we used the resection or preservation of various structures as the input and long-term clinical status as the outcome. Recent sophisticated

advances in artificial intelligence have yielded potent methodology for generating predictions based on training sets. The barrier to application in neurosurgery lies in obtaining robust data with relevant outcomes. The skeleton design of this “knockout” study at scale could provide high quality training sets to feed into the most sophisticated machine learning algorithms. The resulting model could provide powerful outcome predictions resulting from various surgical approaches with respect to preoperative imaging features. Future research should explore the neurosurgical application of machine learning principles with high volume data sets and outcomes of interest.

Future work should further refine methodology for addressing brain shift occurring during the perioperative course and confounding the fidelity of MRI overlays. Despite the measures taken in this study, future work expanding similar “knockout” studies would greatly benefit from improved overlays. Additionally, the conclusions drawn from this data are limited by the retrospective nature of this cohort. Future work should perform prospective studies with more standardized and longer-term outcomes. Similarly designed studies should be extended to cohorts with language eloquent lesions with emphasis on aphasic outcomes. TMS should be compared to other preoperative functional imaging modalities such as functional MRI or magnetoencephalography (MEG) using similar outcome measures. Perhaps future studies could use TMS tractography to explore the identification of a subset of DCS points that can be safely resected. Finally, future studies should explore the combination of TMS with more sophisticated tractography methods such as q-ball or constrained spherical deconvolution.<sup>40,41</sup>

## Conclusion

Almost half of the patients in our cohort exhibited signs of significant tumor induced plasticity. TMS seeded tractography provided significantly higher predictive value for identifying true nonresectable eloquent cortex compared to anatomic seeded tractography. TMS seeded tractography provided superior preoperative imaging data, possibly by capturing clinically relevant neuroplasticity.

## Keywords

anatomy | glioma | neurological deficit | tractography | transcranial magnetic stimulation.

## Funding

No external sources of funding were used for this research.

**Conflict of interest statement.** The authors declare that they have no competing interests.



**Authorship statement.** Matthew Muir: Conception, design, data analysis, writing, editing. Sarah Prinsloo: Conception, data acquisition, editing. Hayley Michener: Data acquisition, editing. Arya Shetty: Data acquisition. Dhiego Chavez de Almeida Bastos: Data acquisition. Jeffrey Traylor: Editing. Chibawenye Ene: Editing. Sudhakar Tummala: Data acquisition. Vinodh Kumar: Data acquisition, editing. Sujit Prabhu: Conception, data acquisition, editing.

## References

1. Sawaya R, Hammoud M, Schoppa D, et al. Neurosurgical outcomes in a modern series of 400 craniotomies for treatment of parenchymal tumors. *Neurosurgery*. 1998; 42(5):1044–1055; discussion 1055–1046.
2. Pouratian N, Bookheimer SY. The reliability of neuroanatomy as a predictor of eloquence: a review. *Neurosurg Focus*. 2010; 28(2):E3.
3. Rossi M, Sciortino T, Conti Nibali M, et al. Clinical pearls and methods for intraoperative motor mapping. *Neurosurgery*. 2021; 88(3):457–467.
4. Raffa G, Scibilia A, Conti A, et al. The role of navigated transcranial magnetic stimulation for surgery of motor-eloquent brain tumors: a systematic review and meta-analysis. *Clin Neurol Neurosurg*. 2019; 180:7–17.
5. Muir M, Prinsloo S, Michener H, et al. TMS seeded diffusion tensor imaging tractography predicts permanent neurological deficits. *Cancers*. 2022; 14(2):340.
6. Sollmann N, Wildschuetz N, Kelm A, et al. Associations between clinical outcome and navigated transcranial magnetic stimulation characteristics in patients with motor-eloquent brain lesions: a combined navigated transcranial magnetic stimulation-diffusion tensor imaging fiber tracking approach. *J Neurosurg*. 2018; 128(3):800–810.
7. Silva LL, Tuncer MS, Vajkoczy P, Picht T, Rosenstock T. Distinct approaches to language pathway tractography: comparison of anatomy-based, repetitive navigated transcranial magnetic stimulation (rTMS)-based, and rTMS-enhanced diffusion tensor imaging-fiber tracking. *J Neurosurg*. 2021; 1:12.
8. Sollmann N, Zhang H, Fratini A, et al. Risk assessment by presurgical tractography using navigated TMS maps in patients with highly motor- or language-eloquent brain tumors. *Cancers*. 2020; 12(5):1264.
9. Krieg SM, Shibani E, Buchmann N, et al. Utility of presurgical navigated transcranial magnetic brain stimulation for the resection of tumors in eloquent motor areas. *J Neurosurg*. 2012; 116(5):994–1001.
10. Frey D, Strack V, Wiener E, et al. A new approach for corticospinal tract reconstruction based on navigated transcranial stimulation and standardized fractional anisotropy values. *Neuroimage*. 2012; 62(3):1600–1609.
11. Plaza M, Gatignol P, Leroy M, Duffau H. Speaking without Broca's area after tumor resection. *Neurocase*. 2009; 15(4):294–310.
12. Pouratian N, Bookheimer SY, Rex DE, Martin NA, Toga AW. Utility of preoperative functional magnetic resonance imaging for identifying language cortices in patients with vascular malformations. *J Neurosurg*. 2002; 97(1):21–32.
13. Tuncer MS, Salvati LF, Grittner U, et al. Towards a tractography-based risk stratification model for language area associated gliomas. *Neuroimage Clin*. 2021; 29:102541.
14. Belotti F, Tuncer MS, Rosenstock T, et al. Predicting the extent of resection of motor-eloquent gliomas based on TMS-guided fiber tracking. *Brain Sci*. 2021; 11(11):1517.
15. Due-Tonnessen P, Rasmussen I, Berntsen EM, Bjornerud A, Emblem KE. Identifying the central sulcus in patients with intra-axial lesions: a multicenter study comparing conventional presurgical MRI to topographical analysis and BOLD-fMRI. *J Comput Assist Tomogr*. 2014; 38(1):1–8.
16. Säisänen L, Julkunen P, Niskanen E, et al. Motor potentials evoked by navigated transcranial magnetic stimulation in healthy subjects. *J Clin Neurophysiol*. 2008; 25(6):367–372.
17. Bulubas L, Sardesh N, Traut T, et al. Motor cortical network plasticity in patients with recurrent brain tumors. *Front Hum Neurosci*. 2020; 14:118.
18. Kong NW, Gibb WR, Badhe S, Liu BP, Tate MC. Plasticity of the primary motor cortex in patients with primary brain tumors. *Neural Plast*. 2020; 2020:3648517.
19. Cargnelutti E, Ius T, Skrap M, Tomasino B. What do we know about pre- and postoperative plasticity in patients with glioma? A review of neuroimaging and intraoperative mapping studies. *Neuroimage Clin*. 2020; 28:102435.
20. Šimundić AM. Measures of diagnostic accuracy: basic definitions. *Ejifcc*. 2009; 19(4):203–211.
21. Duffau H. Does post-lesional subcortical plasticity exist in the human brain? *Neurosci Res*. 2009; 65(2):131–135.
22. Duffau H. Hodotopy, neuroplasticity and diffuse gliomas. *Neurochirurgie*. 2017; 63(3):259–265.
23. De Benedictis A, Duffau H. Brain hodotopy: from esoteric concept to practical surgical applications. *Neurosurgery*. 2011; 68(6):1709–1723; discussion 1723.
24. Desmurget M, Bonnetblanc F, Duffau H. Contrasting acute and slow-growing lesions: a new door to brain plasticity. *Brain*. 2007; 130(4):898–914.
25. Pujar SS, Seunarine KK, Martinos MM, et al. Long-term white matter tract reorganization following prolonged febrile seizures. *Epilepsia*. 2017; 58(5):772–780.
26. Javadi SA, Nabavi A, Giordano M, Faghihzadeh E, Samii A. Evaluation of diffusion tensor imaging-based tractography of the corticospinal tract: a correlative study with intraoperative magnetic resonance imaging and direct electrical subcortical stimulation. *Neurosurgery*. 2017; 80(2):287–299.
27. Zhu FP, Wu JS, Song YY, et al. Clinical application of motor pathway mapping using diffusion tensor imaging tractography and intraoperative direct subcortical stimulation in cerebral glioma surgery: a prospective cohort study. *Neurosurgery*. 2012; 71(6):1170–1183; discussion 1183–1174.
28. González-Darder JM, González-López P, Talamantes F, et al. Multimodal navigation in the functional microsurgical resection of intrinsic brain tumors located in eloquent motor areas: role of tractography. *Neurosurg Focus*. 2010; 28(2):E5.
29. Romano A, D'Andrea G, Calabria LF, et al. Pre- and intraoperative tractographic evaluation of corticospinal tract shift. *Neurosurgery*. 2011; 69(3):696–704; discussion 704–695.
30. Ohue S, Kohno S, Inoue A, et al. Accuracy of diffusion tensor magnetic resonance imaging-based tractography for surgery of gliomas near the pyramidal tract: a significant correlation between subcortical electrical stimulation and postoperative tractography. *Neurosurgery*. 2012; 70(2):283–293; discussion 294.
31. Vassal F, Schneider F, Nuti C. Intraoperative use of diffusion tensor imaging-based tractography for resection of gliomas located near the pyramidal tract: comparison with subcortical stimulation mapping and contribution to surgical outcomes. *Br J Neurosurg*. 2013; 27(5):668–675.
32. Bonney PA, Conner AK, Boettcher LB, et al. A simplified method of accurate postprocessing of diffusion tensor imaging for use in brain tumor resection. *Oper Neurosurg*. 2017; 13(1):47–59.
33. Castellano A, Bello L, Michelozzi C, et al. Role of diffusion tensor magnetic resonance tractography in predicting the extent of resection in glioma surgery. *Neuro Oncol*. 2012; 14(2):192–202.

34. Jeltema HR, Ohlerth AK, de Wit A, et al. Comparing navigated transcranial magnetic stimulation mapping and “gold standard” direct cortical stimulation mapping in neurosurgery: a systematic review. *Neurosurg Rev.* 2020; 44(4):1903–1920.
35. Sanai N, Berger MS. Intraoperative stimulation techniques for functional pathway preservation and glioma resection. *Neurosurg Focus.* 2010; 28(2):E1.
36. Duffau H. Brain connectomics applied to oncological neuroscience: from a traditional surgical strategy focusing on glioma topography to a meta-network approach. *Acta Neurochir.* 2021; 163(4):905–917.
37. Southwell DG, Birk HS, Han SJ, et al. Resection of gliomas deemed inoperable by neurosurgeons based on preoperative imaging studies. *J Neurosurg.* 2018; 129(3):567–575.
38. Bzdok D, Altman N, Krzywinski M. Statistics versus machine learning. *Nat Methods.* 2018; 15(4):233–234.
39. Fabris F, Magalhães JP, Freitas AA. A review of supervised machine learning applied to ageing research. *Biogerontology.* 2017; 18(2):171–188.
40. Becker D, Scherer M, Neher P, et al. Q-ball—high resolution fiber tractography of language associated tracts-quantitative evaluation of applicability for glioma resections. *J Neurosurg Sci.* 2019. Online ahead of print.
41. Becker D, Scherer M, Neher P, et al. Going beyond diffusion tensor imaging tractography in eloquent glioma surgery-high-resolution fiber tractography: Q-ball or constrained spherical deconvolution? *World Neurosurg.* 2020; 134:e596–e609.