

# Non-V600E BRAF mutation in hairy cell leukemia variant

Anjanaa Vijayanarayanan<sup>1</sup> | Sa A. Wang<sup>1</sup> | Sofia Garces<sup>1</sup> | Karan Saluja<sup>2</sup> |  
L. Jeffrey Medeiros<sup>1</sup> | Beenu Thakral<sup>1</sup> 

<sup>1</sup>Department of Hematopathology, The University of Texas MD Anderson Cancer Center, Houston, Texas, USA

<sup>2</sup>Department of Pathology and Laboratory Medicine, McGovern Medical School, The University of Texas Health Science Center at Houston, Houston, Texas, USA

## Correspondence

Beenu Thakral, Department of Hematopathology, UT MD Anderson Cancer Center, 1515 Holcombe Blvd, Unit 72, Houston, TX 77030, USA.  
Email: [bthakral@mdanderson.org](mailto:bthakral@mdanderson.org)

## KEYWORDS

BRAF, hairy cell leukemia, lymphoma, spleen, variant

An 89-year-old-woman presented with an elevated white blood cell (WBC) count of  $27.5 \times 10^9/L$  (normal,  $4-11 \times 10^9/L$ ) and splenomegaly (17.8 cm) in 2021. Peripheral blood (PB) flow cytometry immunophenotyping (FCI) performed elsewhere identified CD5-negative, CD10-negative lambda+ B-cells suggestive of splenic B-cell lymphomas, possibly splenic marginal zone lymphoma (SMZL). The patient was observed until 2023 when she developed weight loss, marked leukocytosis (WBC,  $191.9 \times 10^9/L$ ), and splenomegaly (19.4 cm) without lymphadenopathy. Due to progressive symptoms, the patient underwent a bone marrow (BM) evaluation. BM and PB smears (Figure 1, Panel A) showed numerous atypical lymphocytes with cytoplasmic projections, some with distinct nucleoli. FCI identified CD5-negative, CD10-negative lambda+ B-cells positive for CD11c (bright), CD19 (bright), CD20 (bright), CD22 (bright), and CD103 (partial+), and negative for CD5, CD10, CD23, CD25, CD38, CD43, and CD200 (Figure 1, Panel B). BM was hypercellular with an atypical interstitial, intrasinusoidal, and focally nodular lymphoid infiltrate (Figure 1, Panel C) positive for CD20 (Figure 1, Panel D) and DBA.44, and negative for CD123, BRAF V600E, annexin A1, and cyclin D1. Next-generation sequencing (162 gene panel) detected a BRAF c.1406G > C p.G469A mutation (VAF 44%). The clinicopathologic and immunophenotypic findings, along with the absence of canonical BRAF p.V600E mutation, supported a diagnosis of hairy cell leukemia, variant (HCLv). However, splenic B-cell lymphomas, such as splenic diffuse red pulp B-cell lymphoma, were also considered in the differential diagnosis. She was recommended cladribine and rituximab therapy.

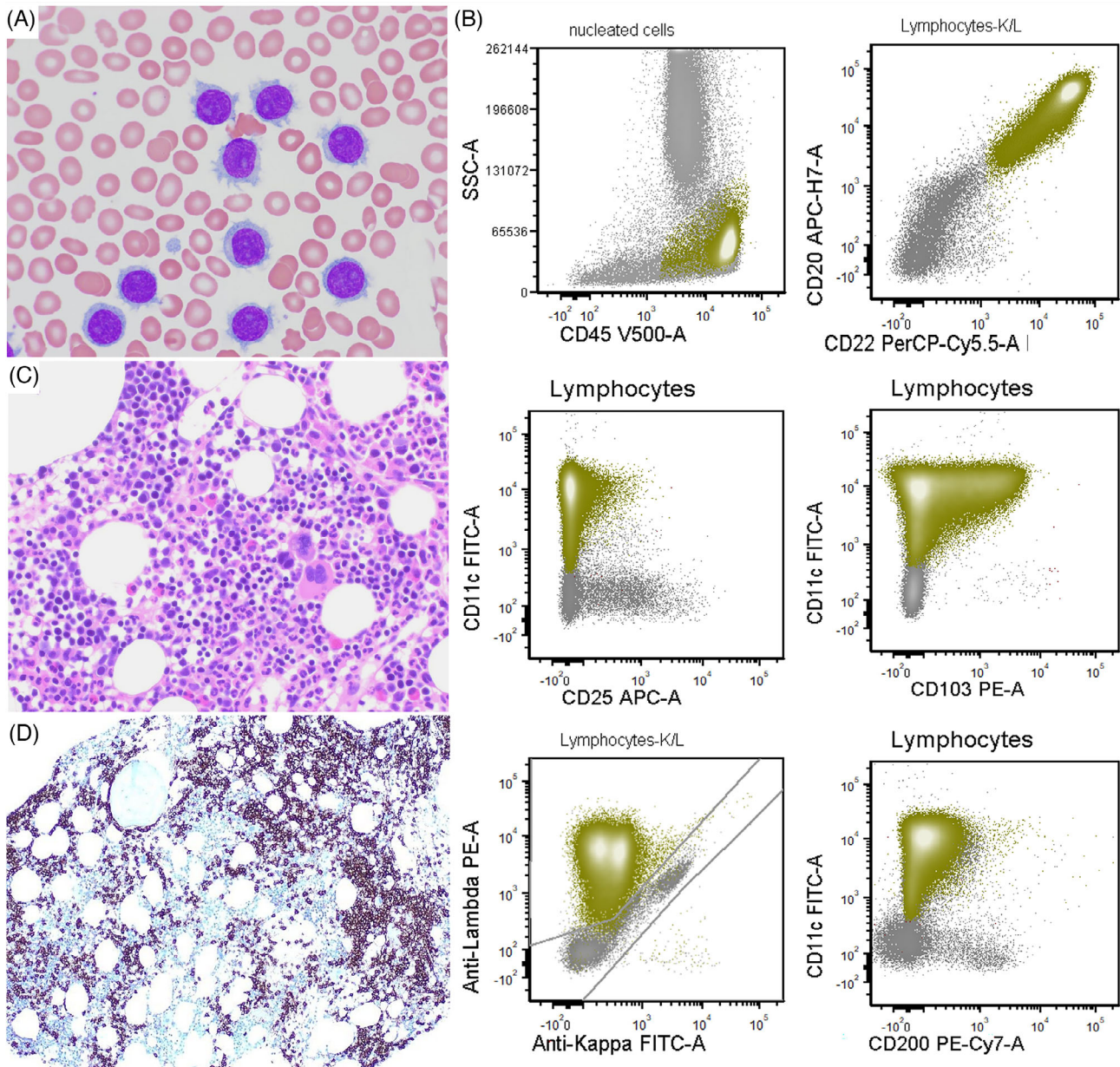
Patients with HCLv tend to be older and have higher PB WBC counts when compared to patients with classic hairy cell leukemia (cHCL) who usually present with cytopenias [1]. There is a clinicopathologic overlap between HCLv and splenic diffuse red pulp small B-cell lymphoma. FCI remains a cornerstone for accurately distinguishing HCLv from other splenic low-grade B-cell lymphomas. HCLv shows a bright expression of pan B-cell markers and lacks CD25, CD123, CD200, TRAP, and annexin A1 which are typically positive in cHCL. Most HCLv cases are brightly positive for CD103 [2], but dim/partial CD103 expression as seen in this case has been reported in 3–9% of HCLv [1, 2]. CD103 is a useful marker that can distinguish cHCL from most cases of HCLv and from SMZL which are CD103 negative [3].

BRAF p.V600E is specific for cHCL, and is consistently absent in HCLv [3]. Non-p.V600E mutations in BRAF exon 11 (p.F468C and p.D449E) have been described in rare cases of cHCL [4]. However, non-V600E BRAF mutation(s) have not been reported in HCLv [3, 5, 6]. The genomic landscape of HCLv, based on limited data, shows recurrent mutations in MAP2K1, TP53, U2AF1, and KDM6A. BRAF p.G469A mutation is a class II hotspot mutation within the protein kinase domain that results in increased BRAF dimerization, kinase activity, and downstream ERK activation. This mutation is rare in hematologic malignancies but has been described more frequently in lung and prostate adenocarcinomas.

In conclusion, this case of HCLv highlights that partial expression of CD103 can be seen in this entity and should not be overlooked. In addition, we report the presence of a novel BRAFp.G469A mutation in this neoplasm.

This is an open access article under the terms of the [Creative Commons Attribution-NonCommercial-NoDerivs](https://creativecommons.org/licenses/by-nc-nd/4.0/) License, which permits use and distribution in any medium, provided the original work is properly cited, the use is non-commercial and no modifications or adaptations are made.

© 2023 The Authors. *eJHaem* published by British Society for Haematology and John Wiley & Sons Ltd.



**FIGURE 1** Panel A: Wright and Giemsa Stain (1000x magnification, 100x objective) shows atypical lymphoid cells with moderate cytoplasm with villi, some with distinct nucleoli; Panel B: Flow cytometry immunophenotyping shows neoplastic B-cells positive for CD11c (bright), CD19 bright, CD20 bright, CD22 bright (not shown), CD103 (partial, ~36%), lambda monoclonal and negative for CD25, and CD200; Panel C: Hematoxylin and eosin (400x magnification, 40x objective) core biopsy shows increased interstitial and some intrasinusoidal B-cell infiltrate as highlighted by CD20 in Panel D (CD20 immunostain, 400x, magnification, 40x objective).

#### AUTHOR CONTRIBUTIONS

All the authors have contributed to the manuscript. AV and BT wrote the manuscript, SAW provided flow cytometry plots, SG analyzed the molecular data, KS took images, and LJM edited the manuscript.

#### CONFLICT OF INTEREST STATEMENT

All the authors have no disclosures or conflict of interest.

#### FUNDING INFORMATION

None.

#### DATA AVAILABILITY STATEMENT

Data from this manuscript will be shared upon request.

#### ETHICS APPROVAL STATEMENT

The authors have confirmed ethical approval statement is not needed for this submission.

#### PATIENT CONSENT STATEMENT

The authors have confirmed patient consent statement is not needed for this submission.

**PERMISSION TO REPRODUCE MATERIAL FROM OTHER SOURCES - CLINICAL TRIAL REGISTRATION (INCLUDING TRIAL NUMBER)**

The authors have confirmed clinical trial registration is not needed for this submission.

**ORCID**

Beenu Thakral  <https://orcid.org/0000-0001-5140-3633>

**REFERENCES**

1. Shao H, Calvo KR, Grönborg M, Tembhare PR, Kreitman RJ, Stetler-Stevenson M, et al. Distinguishing hairy cell leukemia variant from hairy cell leukemia: development and validation of diagnostic criteria. *Leuk Res.* 2013;37(4):401–9. <https://doi.org/10.1016/j.leukres.2012.11.021>
2. Angelova EA, Medeiros LJ, Wang W, Muzzafar T, Lu X, Khoury JD, et al. Clinicopathologic and molecular features in hairy cell leukemia-variant: single institutional experience. *Mod Pathol.* 2018;31(11):1717–32. <https://doi.org/10.1038/s41379-018-0093-8>
3. Waterfall JJ, Arons E, Walker RL, Pineda M, Roth L, Killian JK, et al. High prevalence of MAP2K1 mutations in variant and IGHV4-34-expressing hairy-cell leukemias. *Nat Genet.* 2014;46(1):8–10. <https://doi.org/10.1038/ng.2828>
4. Tschernitz S, Flossbach L, Bonengel M, Roth S, Rosenwald A, Geissinger E. Alternative BRAF mutations in BRAF V600E-negative hairy cell leukaemias. *Br J Haematol.* 2014;165(4):529–33. <https://doi.org/10.1111/bjh.12735>
5. Oscier D, Stamatopoulos K, Mirandari A, Strefford J. The genomics of hairy cell leukaemia and splenic diffuse red pulp lymphoma. *Cancers (Basel).* 2022;14(3):697. <https://doi.org/10.3390/cancers14030697>
6. Maitre E, Tomowiak C, Lebecque B, Bijou F, Benabed K, Naguib D, et al. Deciphering genetic alterations of hairy cell leukemia and hairy cell leukemia-like disorders in 98 patients. *Cancers.* 2022;14:1904. <https://doi.org/10.3390/cancers14081904>

**How to cite this article:** Vijayanarayanan A, Wang SA, Garces S, Saluja K, Medeiros LJ, Thakral B. Non-V600E BRAF mutation in hairy cell leukemia variant. *eJHaem.* 2024;5:266–68. <https://doi.org/10.1002/jha2.836>