

# Hybrid repair strategies for acute type B aortic dissection complicating prior standard and complex endovascular aortic repair

Jesse Chait, DO,<sup>a</sup> Bernardo C. Mendes, MD,<sup>a</sup> Lily E. Johnston, MD, MPH,<sup>b</sup> Fahad Shuja, MBBS,<sup>a</sup> Gustavo S. Oderich, MD,<sup>c</sup> and Manju Kalra, MBBS,<sup>a</sup> Rochester, MN; Sacramento, CA; and Houston, TX

## ABSTRACT

Type B aortic dissection (TBAD) in the presence of an existing aortic endograft is a rare, but potentially catastrophic, event. False lumen pressurization and propagation leads to several failure modes. Endograft collapse can lead to spinal cord, visceral, or lower extremity ischemia, and rupture of a previously sealed aneurysm sac is often fatal. A successful treatment strategy must incorporate the patient's symptoms, urgency of intervention, extent of dissection, and the location and status of the existing graft. In this series, we present three cases of TBAD complicating prior endovascular aortic repairs—infrarenal, iliac branched, and thoracoabdominal branched endografts—successfully treated with tailored, hybrid interventions. (*J Vasc Surg Cases Innov Tech* 2023;9:1-9.)

**Keywords:** Aortic aneurysm; Aortic banding; Aortic dissection; Hybrid procedures; Ruptured aneurysm; STABLE technique

Late, antegrade type B aortic dissection (TBAD), remote from the periprocedural period of the original endovascular abdominal aortic repair (EVAR), is an extremely rare event. Unlike the hypothesized etiologies for perioperative TBAD associated with the initial EVAR of excessive endograft oversizing, neck angulation, and wire manipulation, it is believed to be noniatrogenic and primary, with only a few case reports in the literature.<sup>1</sup> The presence of an existing aortic endograft further complicates TBAD because it contributes to a significant increase in false lumen pressure by preventing outflow distally into the stented iliac arteries and a lack of fenestrations within the abdominal aorta. This can result in

catastrophic sequelae of TBAD with pressurization of the previously treated infrarenal aneurysm sac leading to acute rupture at the caudal end or complete collapse of the EVAR stent and true lumen, resulting in lower extremity, renal, and mesenteric ischemia.

No standard recommendations are available for management of late TBAD, and the outcomes in the reported cases have been far from desirable. In this series, we present three cases of TBAD complicating prior endovascular aortic repairs—infrarenal, iliac branch, and thoracoabdominal branch endografts—successfully treated with tailored, hybrid reconstruction. All three patients provided written informed consent for the report of their case details and imaging studies.

---

From the Division of Vascular and Endovascular Surgery, Mayo Clinic, Rochester<sup>a</sup>; the Kaiser Permanente, Sacramento<sup>b</sup>; and the Department of Cardiothoracic and Vascular Surgery, McGovern Medical School, University of Texas Health Science Center at Houston, Houston.<sup>c</sup>

Author conflict of interest: G.S.O. receives consulting fees from Centerline Biomedical, Cook Medical, GE Healthcare, and W.L. Gore & Associates and research grant support from GE Healthcare, Cook Medical, and W.L. Gore & Associates and has a global principal investigator agreement with Cook Medical. B.C.M. receives consulting fees and research support from Cook Medical and W.L. Gore & Associates and is a regional aortic advisor for Medtronic with all fees paid to Mayo Clinic. J.C., L.E.J., F.S., and M.K. have no conflicts of interest.

Additional material for this article may be found online at [www.jvscit.org](http://www.jvscit.org).

Correspondence: Manju Kalra, MBBS, Division of Vascular and Endovascular Surgery, Mayo Clinic, 200 1st St SW, Rochester MN 55905 (e-mail: [kalra.manju@mayo.edu](mailto:kalra.manju@mayo.edu)).

The editors and reviewers of this article have no relevant financial relationships to disclose per the Journal policy that requires reviewers to decline review of any manuscript for which they may have a conflict of interest.

2468-4287

© 2023 The Author(s). Published by Elsevier Inc. on behalf of Society for Vascular Surgery. This is an open access article under the CC BY-NC-ND license (<http://creativecommons.org/licenses/by-nc-nd/4.0/>).

<https://doi.org/10.1016/j.jvscit.2023.101200>

## CASE REPORT

### Patient 1: rupture of a previously excluded infrarenal aortic aneurysm

**Clinical presentation.** A 72-year-old man was transferred to our institution with acute onset back pain radiating to the abdomen. Eight weeks prior, he underwent aortic root and hemiarch replacement with coronary artery bypass grafting for the treatment of an ascending aortic aneurysm and coronary artery disease. Routine postoperative imaging after proximal aortic replacement demonstrated no evidence of iatrogenic dissection, intramural hematoma, or intimal disruption. He had been treated 6 years previously for an infrarenal abdominal aortic aneurysm with a Gore Excluder endograft (W.L. Gore & Associates; [Table 1](#)).

The initial single-phase, non-contrast computed tomography (CT) scan from the referring facility demonstrated an acute TBAD<sub>2,9</sub> originating at the level of the left subclavian artery (LSA) with extension to the level of the renal arteries. On initial evaluation, the infrarenal endograft was excluding the aneurysm appropriately ([Fig 1, A](#)). However, a second single-phase CT

**Table 1.** Clinical characteristics, management, and outcomes of three patients with type B aortic dissection (TBAD) complicating prior endovascular aortic repair

Pt. No.; Time from age, EVAR to years; dissection, sex months	Risk factors	Devices and position	Dissection morphology	Management	Outcome	False lumen
1; 72; Male	72 Hypertension; ASCVD; previous cardiac surgery; CABG, aortic valve, root, and hemiarch replacement	Excluder <sup>a</sup> ; infrarenal aorta	B <sub>2,9</sub> , complicated by infrarenal aortic rupture	TEVAR (TAG <sup>a</sup> ) plus exploratory laparotomy with aortic banding	Alive at 6 years of follow-up	Complete thoracic thrombosis, patent paravisceral false lumen
2; 81; Male	30 Hypertension; ASCVD; previous cardiac surgery; CABG	Excluder C3 <sup>a</sup> ; infrarenal aorta; IBE <sup>a</sup> ; right iliac system	B <sub>3,9</sub> , complicated by bilateral lower extremity malperfusion	CSBG plus TEVAR (cTAG <sup>a</sup> ) plus bare metal aortic stent (Zenith TX2 dissection stent <sup>b</sup> )	Alive at 2 years of follow-up	Complete thrombosis
3; 70; Male	6 Hypertension; ASCVD; previous cardiac surgery; aortic valve, root, and hemiarch replacement	Patient-specific four-vessel endograft with CA, SMA, and BRA branches <sup>b</sup> ; Zenith iliac branch device <sup>b</sup> ; right iliac system	B <sub>3,6</sub> , complicated by endograft compression and impending arch rupture	CSBG plus TEVAR (Zenith Alpha <sup>b</sup> ) plus left common carotid artery bare metal stenting	Alive at 2 years of follow-up, reintervention for asymptomatic type IIIa endoleak at 6 months	Complete thrombosis

ASCVD, Atherosclerotic cardiovascular disease; BRA, bilateral renal artery; CA, celiac artery; CABG, coronary artery bypass grafting; CSBG, carotid-to-subclavian bypass graft; EVAR, endovascular aortic repair; IBE, iliac branch endoprosthesis; Pt. No., patient number; SMA, superior mesenteric artery; TEVAR, thoracic endovascular aortic repair.  
<sup>a</sup>W.L. Gore & Associates.  
<sup>b</sup>Cook Medical Inc.

scan with contrast performed at the outside facility 3 hours after the index scan demonstrated a new hematoma tracking from the left wall of the infrarenal abdominal aorta into the retroperitoneum and pelvis without evidence of active contrast extravasation, suggestive of contained rupture (Fig 1, B). The celiac, superior mesenteric, and bilateral renal arteries were patent and perfused via the true lumen; however, the left renal artery was compressed by the false lumen.

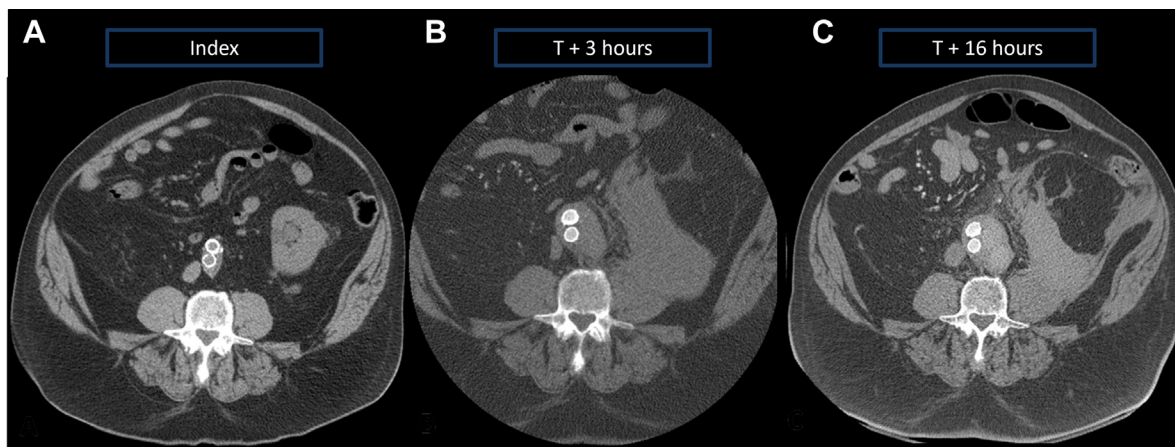
Upon arrival to our institution, the patient had no signs or symptoms of organ or extremity malperfusion and reported minimal low back pain with resolution of his upper back pain. Therefore, he was initially managed medically with intravenous anti-impulse therapy. However, the patient had persistent hypertension that was difficult to manage adequately in the intensive care unit despite multiple maximally dosed vasoactive infusions. Repeat CT angiography (CTA) with contrast at 12 hours demonstrated 1 cm of false lumen expansion in the area of the previously identified hematoma with a maximal sac diameter of 68 mm (Figs 1, C, and 2). Because of the rapid expansion of the false lumen and refractory hypertension with maximal medical therapy, all parties elected to proceed to the hybrid operating room for repair.

**Operative technique.** To exclude the entry tear at the level of the aortic arch, a 31 × 150-mm Gore TAG endograft (W.L. Gore & Associates) was positioned and deployed to span zones 2 to 4 once the location in the true lumen was confirmed with

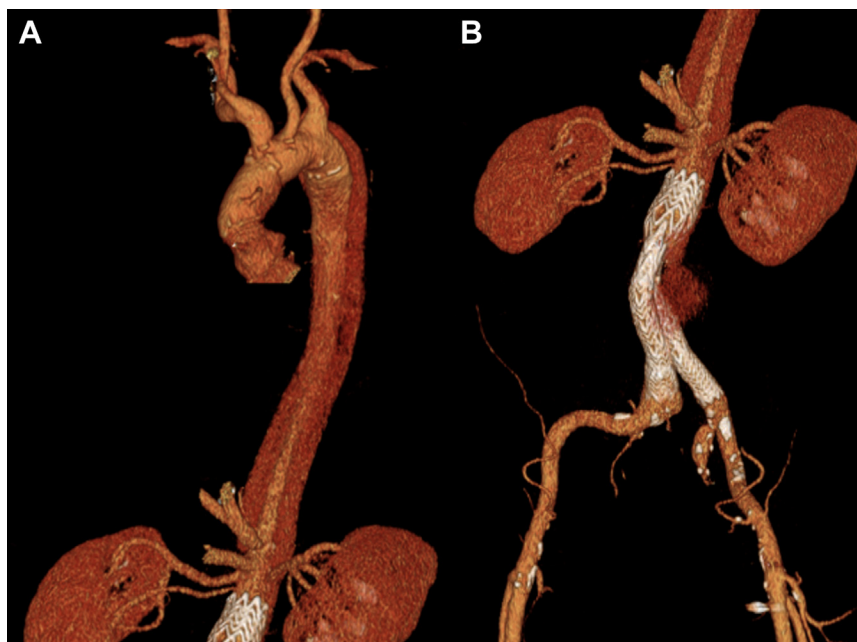
intravascular ultrasound (IVUS; Fig 3, A and B). Completion arch aortography demonstrated obliteration of antegrade flow into both the false lumen and the LSA. Abdominal aortography from within the true lumen revealed patency of the infrarenal endograft without obvious filling of the rapidly enlarging false lumen. However, the proximal extent of the infrarenal Excluder endograft was hypermobile with dynamic compression of the true lumen via a pseudo-type Ia endoleak into the false lumen with each cardiac cycle, likely due to the numerous fenestrations within the paravisceral aortic segment (Supplementary Video, online only).

Because of the radiographic evidence of intra-abdominal hemorrhage and the hypermobility of the proximal main body of the infrarenal endograft, a decision was made to explore the abdomen via a midline laparotomy. Dissection and exposure of the left lateral aspect of the infrarenal aorta revealed an easily visible, bounding, pulsatile false lumen with associated hematoma extending around the infrarenal endograft, despite coverage and exclusion of the entry tear site (Fig 3, C).

Circumferential control of the proximal infrarenal aorta was obtained, and an external reinforcing cuff was fashioned from two 1-in. × 6-in. Dacron patches (Fig 3, D and E), which were cinched down to prevent flow through the false lumen distally. The cuff was sutured in two layers using polypropylene, with the second layer tacking down the suture line to the aortic adventitia (Fig 3, F and G), such that the false lumen was no longer pulsatile



**Fig 1.** Serial computed tomography (CT) evaluations of the infrarenal aorta demonstrating no evidence of rupture at the initial presentation (**A**), new demonstration of a retroperitoneal hematoma and aneurysm sac expansion after 3 hours (**B**), and marked expansion and contrast opacification of the aneurysm sac and retroperitoneal hematoma 16 hours after presentation (**C**).



**Fig 2.** Preoperative computed tomography (CT) angiogram demonstrating type B<sub>2,9</sub> aortic dissection (TBAD<sub>2,9</sub>; **A**) with contained rupture of a previously excluded infrarenal abdominal aortic aneurysm (**B**) due to false lumen perfusion.

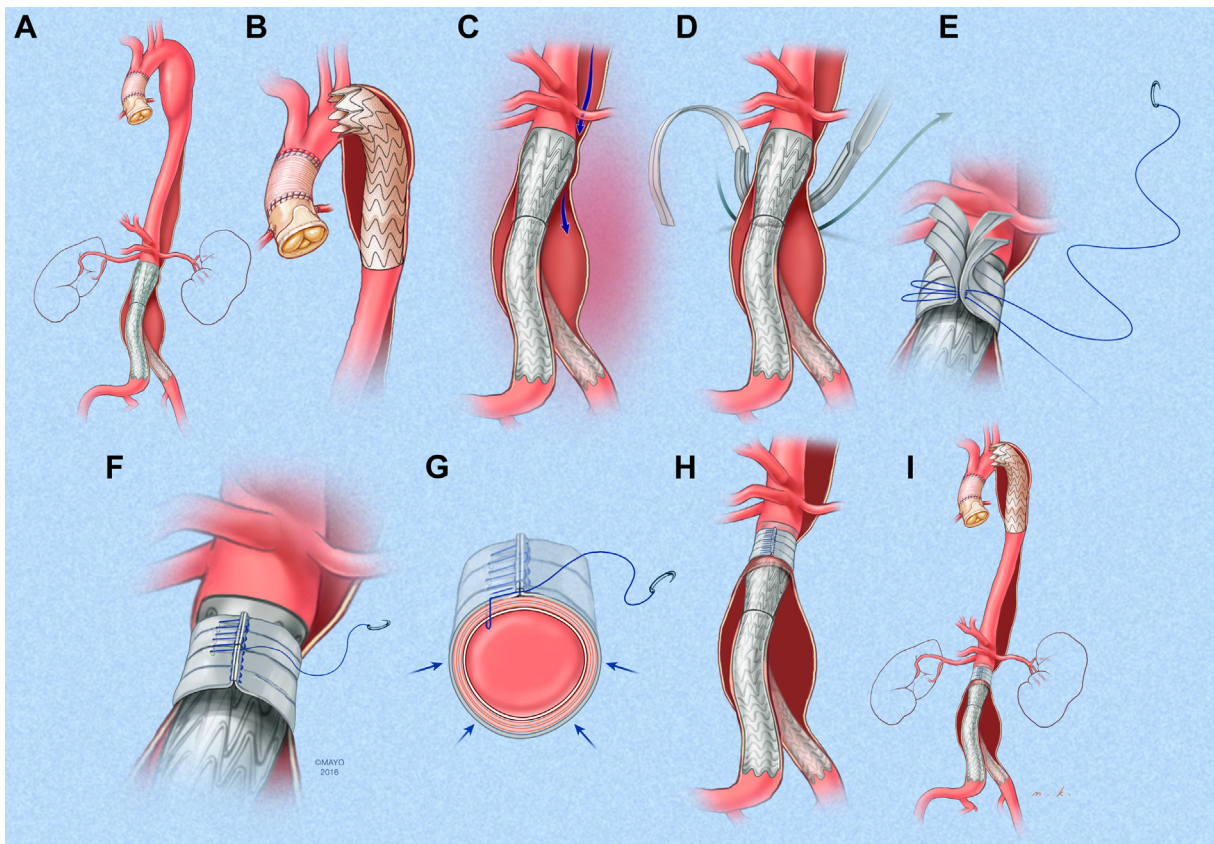
(Fig 3, H and I). Of note, the cuff was sutured to the adventitia to the right side, away from the friable false lumen (Fig 3, G). The main body and right iliac limb of the endograft were then expanded with a 32-mm noncompliant occlusion balloon. The abdomen was closed primarily, and the patient awoke moving all four extremities to command. His postoperative course was uneventful, with eventual discharge on postoperative day 9.

At 1 month postoperatively, CTA demonstrated sac regression from 68 mm to 61 mm and a reduction in sac volume from 202 cm<sup>3</sup> to 150 cm<sup>3</sup>. At 6 years of follow-up, CTA demonstrated both complete sac regression and a thoracic false lumen

thrombosis with a small residual area of patent paravisceral false lumen that is being monitored with annual CTA.

#### **Patient 2: endograft collapse with bilateral lower extremity malperfusion**

**Clinical presentation.** An 81-year-old man presented to our emergency department with acute onset chest, back, and right leg pain that began shortly after sexual intercourse. Thirty months prior, he underwent treatment of an abdominal aortic aneurysm and bilateral common iliac artery aneurysms with infrarenal EVAR, right iliac branch endoprosthesis (IBE; W.L. Gore



**Fig 3.** **A**, Illustration of type B aortic dissection (TBAD) and distal arch aneurysm with false lumen propagation and abdominal aortic aneurysm expansion. Zone 2 thoracic endograft placement (**B**) did not stop false lumen flow into the previously excluded infrarenal abdominal aortic aneurysm (**C**). Exploratory laparotomy was next performed with exposure and control of the proximal infrarenal neck. Dacron patches were passed around the infrarenal neck (**D**), which were cinched and sutured to incorporate the endograft and aortic wall (**E**). **F**, Aortic bites were taken away from the left posterolateral aortic wall, which was weakened by false lumen propagation. **G**, Following completion of the aortic banding, the false lumen was no longer pulsatile. **H**, Proximal and distal attachment sites were ballooned, and the patient's abdomen was closed primarily. **I**, Postoperative imaging demonstrated an excellent result with thoracic false lumen thrombosis and no further evidence of aneurysm perfusion.

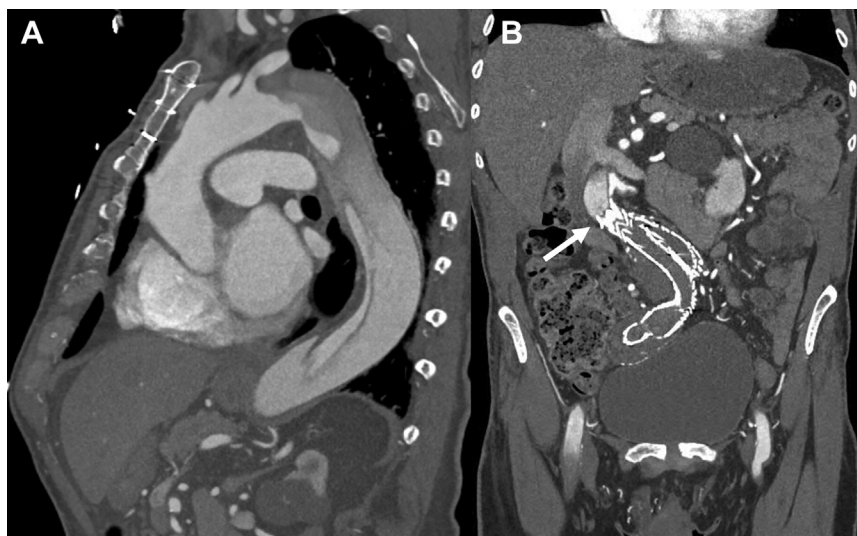& Associates) placement, and left internal iliac artery embolization with extension of the EVAR into the external iliac artery ("coil and cover"; Table 1).

The physical examination findings were consistent with Rutherford type IIa and IIb acute limb ischemia of the left and right lower extremities, respectively, with absent femoral, popliteal, and distal Doppler signals bilaterally. The right leg was cold and mottled with no motor or sensory function below the knee. CTA revealed TBAD<sub>3,9</sub> with absence of flow through the infrarenal aorta, because the dissection flap had ended at, compressed, and, consequently, occluded the proximal aspect of the bifurcated endograft (Fig 4). The right IBE was also occluded. Sluggish reconstitution of flow was noted in the bilateral external iliac arteries, with dependent layering of contrast in the right femoropopliteal artery, although no evidence of perfusion distal to the P2 segment was evident.

**Operative technique.** The patient was taken emergently to the hybrid operating room and underwent left carotid-to-subclavian bypass grafting to preserve flow to a patent left

internal mammary artery to left anterior descending artery graft and prevent spinal cord injury in the setting of bilateral hypogastric artery occlusions with planned coverage of zone 2. Bilateral femoral artery exposures were performed to allow for both endovascular access and expedient lower extremity revascularization. After IVUS confirmed wire placement within the true lumen from below, a wire was passed through the ostium of the left common carotid artery via the carotid-to-subclavian graft and a brachial artery cutdown to precisely identify and protect the carotid artery origin before deployment of a conformable cTAG (W.L. Gore & Associates) spanning from zones 2 to 5 (Fig 5). Several Zenith bare metal dissection stents (Cook Medical Inc) were then placed, spanning from the thoracic endograft to the previous infrarenal repair. Repeat IVUS demonstrated complete true lumen reexpansion. The proximal LSA origin was occluded on completion angiography and did not require embolization.

Thromboembolectomy of the bilateral iliac limbs and femoropopliteal arteries was then performed. In addition, right



**Fig 4.** Preoperative computed tomography (CT) angiogram demonstrating type B<sub>3,9</sub> aortic dissection (TBAD<sub>3,9</sub>; **A**) complicated by proximal endograft (arrow) compression and thrombosis (**B**).

common femoral artery patch angioplasty and right lower extremity four compartment fasciotomies were performed. The internal iliac branch of the IBE was not recanalized. Delayed onset extremity weakness was noted on the physical examination several hours postoperatively, suggestive of spinal cord ischemia. A cerebrospinal fluid drain was placed emergently and after the mean arterial pressure was increased using vasopressors. The patient had improved motor function immediately after drain placement and regained full neurologic function ~72 hours thereafter. The patient was discharged on postoperative day 20, with a prolonged stay secondary to delirium, acute kidney injury secondary to rhabdomyolysis, and poor wound healing of the medial fasciotomy incision requiring a split-thickness skin graft. At 2 years of follow-up, the carotid-to-subclavian bypass graft, thoracic endograft, bare metal dissection stent, and bifurcated abdominal endograft were patent. He had no residual lower extremity occlusive or neurologic symptoms.

### **Patient 3: type Ia endoleak with branched endograft compression**

**Clinical presentation.** A 70-year-old man presented at an outside institution with chest pain, dyspnea, and elevated systolic blood pressure. Six months prior, he underwent endovascular repair of an 8.1-cm extent III thoracoabdominal aortic aneurysm and 3.9-cm right common iliac artery aneurysm using a patient-specific four-vessel branched endograft and iliac branch device (William Cook Australia). CTA demonstrated an acute TBAD<sub>3,6</sub> (Fig 6) with a large type Ia endoleak and proximal endograft compression (Table 1). The patient was urgently transferred to our institution and directly admitted to the intensive care unit for blood pressure and pain control while the hybrid operating room was prepared.

**Operative technique.** Given the need for a zone 2 landing and LSA preservation in the setting of previous supraceliac aorta coverage, a left carotid-to-subclavian bypass was created, followed by zone 2 thoracic EVAR (TEVAR; Zenith Alpha; Cook

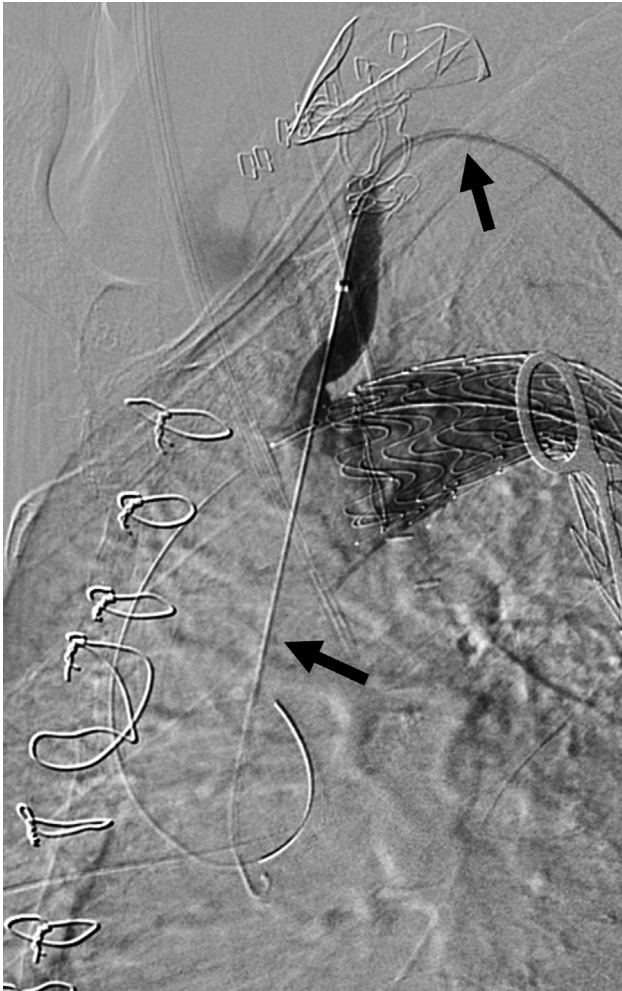Medical Inc) landed into the prior thoracoabdominal branched graft. Following successful deployment, the LSA origin was embolized with an Amplatzer Vascular Plug II (St Jude Medical) through an ipsilateral brachial artery cutdown.

Completion cone-beam CT demonstrated patent stent grafts, successful treatment of the dissection with no flow in the false lumen, and a widely patent innominate artery. A flow-limiting dissection in the left common carotid artery was treated with self-expanding, bare metal stent placement via transbrachial access through the carotid-to-subclavian bypass. An immediate improvement in the left carotid artery pulse was appreciated after stent deployment, and the patient awoke neurologically intact without any deficits. He experienced an uneventful perioperative course and was discharged on postoperative day 7. The patient underwent placement of an additional thoracic endograft for an asymptomatic type IIIa endoleak discovered via routine surveillance at 6 months and was alive at 3 years postoperatively with false lumen thrombosis, no further endoleak, and no residual aortic-related morbidity.

### **DISCUSSION**

The two catastrophic presentations of TBAD in the setting of prior EVAR are represented in this series: (1) sudden reperfusion of a previously excluded aneurysm sac via the false lumen, leading to rupture (patient 1); and (2) true lumen compression resulting in endograft occlusion and distal malperfusion (patients 2 and 3; Table 1).

Since the first report of rupture in this situation by Yamamoto et al<sup>2</sup> in 2013 that was left untreated and resulted in mortality, only three further cases have been reported, with one third left untreated. Open repair was performed in two cases, including one aortobifemoral graft resulting in fatality and one axillobifemoral bypass performed for initial presentation with endograft occlusion, followed by endograft explantation and aortic



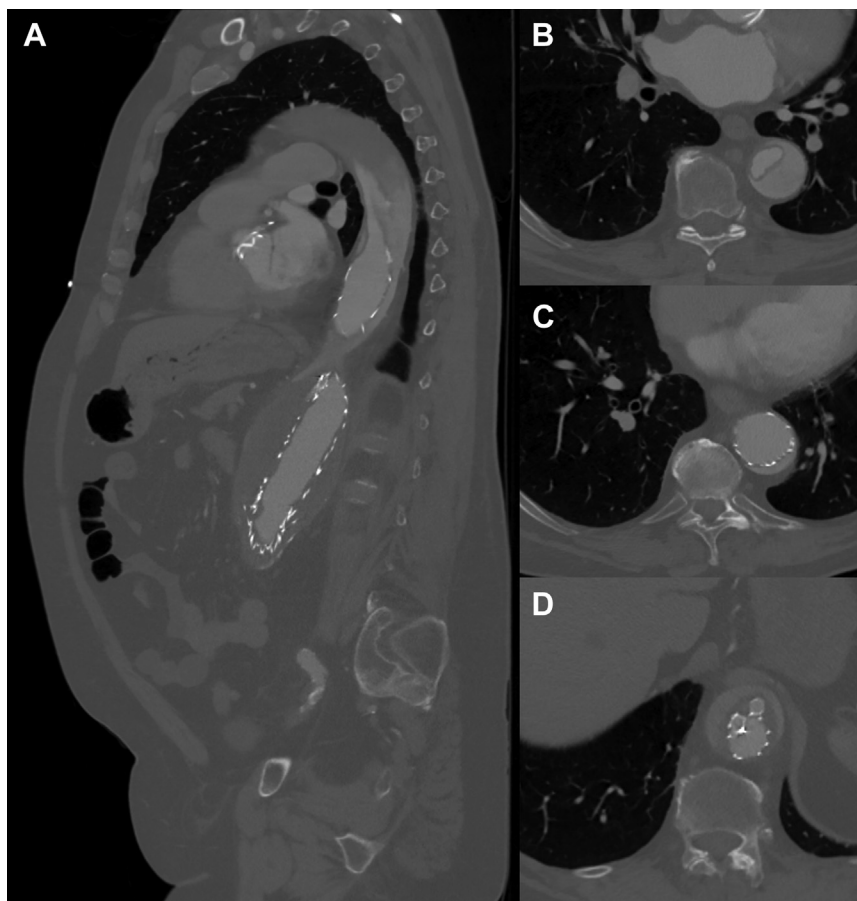
**Fig 5.** Deployment of a thoracic endograft in zone 3 with a wire placed in the left common carotid artery through the existing carotid-to-subclavian bypass graft (arrows) to guide accurate deployment. The wire also allows for a bailout chimney stent should the endograft encroach on the carotid artery lumen.

modified endograft to connect the TEVAR and EVAR, was thought to be too great a risk for spinal cord ischemia, given the extensive aortic coverage.

At the time of this patient's presentation, bare metal, open cell dissection stents (Cook Medical Inc) were not yet approved for use. However, we believe that intraluminal true lumen reexpansion with such a low radial strength device likely would not have completely obliterated the false lumen flow to successfully treat rupture of the perfused infrarenal aneurysm sac. The results of STABLE (study for the treatment of complicated type B aortic dissection using endoluminal repair) revealed a decrease in the false lumen caliber by <50% immediately after implantation, but certainly not obliteration, which would be essential to treat rupture.<sup>5</sup> Aortic banding is an adjunctive technique that was used much more frequently before the development of fenestrated-branched EVAR to treat hostile, highly angulated, inappropriately dilated, or otherwise irregular juxtarenal aortic necks in the setting of EVAR to prevent proximal endoleaks and to treat a subsequent type Ia endoleak. It was a much simpler method of obtaining cessation of flow in the newly pressurized post-EVAR aneurysm sac with digital confirmation intraoperatively compared with attempted EVAR explantation in previous reports.<sup>6-10</sup>

Infrarenal endograft collapse secondary to remote TBAD resulting in malperfusion with acute, profound lower extremity ischemia was first reported by Haulon et al<sup>11</sup> in 2003 with the death of the untreated patient. It remains a rare occurrence, with only 10 further cases reported since then but with much better outcomes with treatment and survival compared with rupture with two fatalities (Table III).<sup>4,11-21</sup> Two of these occurred in patients who were treated with axillobifemoral bypass alone. The other eight patients, all of whom underwent TEVAR as part of their intervention, survived. TEVAR was combined with endovascular relining of the main body with or without an iliac limb, thromboembolectomy, axillobifemoral bypass, endograft explantation, and in situ aortic repair to reestablish lower extremity flow. The TEVAR likely helped preserve visceral and renal perfusion by partial expansion of the true lumen and prevented the catastrophic outcomes encountered in the few patients treated without TEVAR. The validity of this approach is borne out in our experience with patient 2, in whom the true lumen was further expanded by adding Zenith bare metal dissection stents (Cook Medical Inc) to bridge the gap between the TEVAR and prior EVAR, as described in the PETTICOAT (provisional extension to induce complete attachment) technique.<sup>22</sup> This maneuver has not been used in previously reported cases and likely prevented, not only visceral malperfusion, but also avoided the greater risk of permanent spinal cord injury in the absence of IBE salvage. Despite this and the left carotid-to-subclavian bypass that was concomitantly performed, the patient developed

stump creation for the rupture with successful survival but with limb loss (Table II).<sup>3,4</sup> TEVAR to seal the entry tear in the proximal thoracic aorta as the first step, followed by complete control of impulse in the false lumen proximal to the EVAR with aortic banding, such as was undertaken for patient 1, was a more successful strategy, with complete resolution of the pathology. The second step of exploratory laparotomy was necessary as demonstrated by continued false lumen pulsatility on aortography after TEVAR and confirmed on exposure of the infrarenal aorta, indicating that exclusion of the entry tear did not adequately obliterate sac perfusion, likely due to fenestrations within the paravisceral aorta. The same would apply if the TEVAR had been extended to the level of the celiac artery. This, along with the additional option of placement of an emergent fenestrated physician-modified endograft with a physician-



**Fig 6.** Preoperative computed tomography (CT) angiogram demonstrating proximal branched endograft compression and subsequent type Ia endoleak in sagittal (A) and axial (B-D) views.

**Table II.** Reported cases of type B aortic dissection (TBAD) after endovascular abdominal aortic repair (EVAR) with aneurysm rupture

Investigator	Time from EVAR to dissection	Device	Presenting symptoms	Treatment	Result
Yamamoto et al. <sup>2</sup> 2013	72 weeks	Zenith (Cook Medical Inc)	Retroperitoneal hematoma	None	Death
Daniel et al. <sup>3</sup> 2016	56 weeks	Endurant (Medtronic)	Mesenteric and left lower extremity malperfusion	Aortobifemoral bypass plus thrombectomy	Death
Nomura et al. <sup>19</sup> 2019	7 years	Zenith (Cook Medical Inc)	Back pain	None	Death
Motoji et al. <sup>4</sup> , 2020 <sup>a</sup>	3 years	Excluder (W.L. Gore & Associates)	Back pain and bilateral lower extremity malperfusion	Axillobifemoral bypass, followed by aortic stump ligation	Unilateral amputation, discharged to rehabilitation facility on day 92

<sup>a</sup>Patient presented with endograft collapse and occlusion treated by axillobifemoral bypass and then experienced aneurysm rupture, which was subsequently treated with aortic stump ligation.

transient paraparesis, which resolved with spinal cord drainage.

The Guidelines of the Society for Vascular Surgery recommend LSA revascularization when feasible during emergent TEVAR, individualized according to each

patient's situation.<sup>23,24</sup> In patient 1, the LSA was covered because of the urgency of the situation, placement of a single thoracic covered stent, and patency of the existing EVAR and bilateral internal iliac arteries. In patient 2, the LSA was revascularized with a left carotid-to-subclavian

**Table III.** Reported cases of type B aortic dissection (TBAD) after endovascular abdominal aortic repair (EVAR) with symptomatic aortic endograft collapse and occlusion

Investigator	Time from EVAR to dissection	Device	Presenting symptoms	Treatment	Result
Haulon et al, <sup>11</sup> 2003	20 weeks	Excluder (W.L. Gore & Associates)	Bilateral lower extremity malperfusion	None	Death
Iyer et al, <sup>12</sup> 2009	11 weeks	Zenith (Cook Medical Inc)	Abdominal pain and bilateral lower extremity malperfusion	TEVAR plus thromboembolectomy	Asymptomatic at 11 months of follow-up
van Keulen et al, <sup>13</sup> 2009	1.5 years	Talent (Medtronic)	Abdominal pain	TEVAR plus balloon-expandable stent within endograft main body	Death
Vainas et al, <sup>14</sup> 2014	10 years	Zenith Trifab (Cook Medical Inc)	Bilateral lower extremity malperfusion	Axillobifemoral bypass, followed by TEVAR plus endograft explantation plus aortoiliac bypass	Discharged on hospital day 20; no follow-up reported
Psacharopulo et al, <sup>15</sup> 2014	58 weeks	Excluder (W.L. Gore & Associates)	Back and lower extremity pain	Axillobifemoral bypass	Death
Yoshiga et al, <sup>16</sup> 2015	24 weeks	Endurant II (Medtronic)	Abdominal pain and melena	TEVAR plus EVAR relining plus iliac limb relining	Asymptomatic at 6 months of follow-up
Goto et al, <sup>17</sup> 2017	2 years	Excluder (W.L. Gore & Associates)	Bilateral lower extremity malperfusion	Axillobifemoral bypass	Paraplegia
Itoga et al, <sup>18</sup> 2018	4 years	Excluder (W.L. Gore & Associates)	Back and lower extremity pain	TEVAR plus thromboembolectomy + iliac limb relining	Asymptomatic at 6 months of follow-up
Nomura et al, <sup>19</sup> 2019	6 months	Excluder (W.L. Gore & Associates)	Back pain and bilateral lower extremity malperfusion	Axillobifemoral bypass	Death
Ostapenko et al, <sup>20</sup> 2019	"Several" years	Zenith (Cook Medical Inc)	Back pain and bilateral lower extremity malperfusion	TEVAR plus external iliac artery stent	Brain death from intracranial hemorrhage
Motoji et al, <sup>4</sup> 2020 <sup>a</sup>	3 years	Excluder (W.L. Gore & Associates)	Back pain and bilateral lower extremity malperfusion	Axillobifemoral bypass, followed by aortic stump ligation	Unilateral amputation, discharged to rehabilitation facility on day 92
Cooke et al, <sup>21</sup> 2022	16 months	Excluder (W.L. Gore & Associates)	Thoracoabdominal, back, and lower extremity pain	TEVAR plus iliac limb relining	Asymptomatic at 2 weeks of follow-up

TEVAR, Thoracic endovascular aortic repair.  
<sup>a</sup>Patient presented with endograft collapse and occlusion treated by axillobifemoral bypass and then experienced aneurysm rupture, which was subsequently treated with aortic stump ligation.

bypass performed concomitantly, with a second team performing the femoral exposures and thrombectomies, not only for spinal cord protection, but also because the patient had a prior left internal mammary artery graft. Patient 3 had presented with severe compression but

not complete collapse of the prior thoracoabdominal branched graft, which provided the luxury of time to perform LSA revascularization concomitantly with the TEVAR, which was deemed necessary to mitigate the risk of spinal cord ischemia due to prior extensive



supraceliac aortic coverage.<sup>25</sup> However, endovascular options with branched devices and in situ laser fenestration offer alternatives that might decrease the time to revascularization.<sup>26,27</sup>

## CONCLUSIONS

TBAD occurring remotely from prior EVAR is rare but can result in catastrophic consequences of endograft collapse and lower extremity and visceral malperfusion or, even more rarely, rupture of the newly pressurized false lumen. Based on our experience and the few case reports in the literature, TEVAR to seal the entry tear should be an essential component of the surgical intervention. This is best combined with further endovascular and/or hybrid techniques to restore and preserve patency of the prior endograft, resorting to open or extra-anatomic aortoiliac revascularization only if absolutely necessary. With a tailored, individualized approach, these patients can undergo successful treatment with satisfactory long-term outcomes despite their emergent, catastrophic presentation and anatomic and physiologic complexity.

## REFERENCES

1. Czaplinski EJR, Mira CM, Sifuentes DMA, Aldama JA. Acute type B aortic dissection One Month after fenestrated EVAR Procedure. *EJVES Short Rep* 2019;44:38-43.
2. Yamamoto S, Hoshina K, Takazawa Y, et al. Aortic dissection occurring 18 months after successful endovascular repair in an anatomically difficult case of abdominal aortic aneurysm. *Case Rep Vasc Med* 2013;2013:412708.
3. Daniel C, Ben Ahmed S, Warein E, Gallon A, Rosset E. Type B aortic dissection with abdominal aortic aneurysm rupture 1 year after endovascular repair of abdominal aortic aneurysm. *Ann Vasc Surg* 2016;33:229.e7-10.
4. Motoji Y, Kato T, Seki J, Tsumura K, Tomita S, Okawa Y. A case of collapsed stent graft, severe lower limb ischemia, and ruptured abdominal aortic aneurysm due to type B acute aortic dissection 3 years after endovascular aneurysm repair. *Ann Vasc Dis* 2020;13:308-11.
5. Lombardi JV, Cambria RP, Nienaber CA, et al. Five-year results from the study of thoracic aortic Type B dissection using endoluminal repair (STABLE I) study of endovascular treatment of complicated type B aortic dissection using a composite device design. *J Vasc Surg* 2019;70:1072-81.
6. Scarcello E, Serra R, Morrone F, Tarsitano F, Triggiani G, de Francis S. Aortic banding and endovascular aneurysm repair in a case of juxtarenal aortic aneurysm with unsuitable infrarenal neck. *J Vasc Surg* 2012;65:208-11.
7. Karkos CD, Mitka M, Pliatsios I, Xanthopoulou E, Giagtzidis IT, Papadimitriou CT, et al. Rupture after previous endovascular aneurysm repair due to type IA endoleak: complete endograft preservation is feasible with proximal suturing, aortic neck banding, and sac Plication. *Ann Vasc Surg* 2018;49:317.e5-8.
8. Hattori S, Noguchi K, Gunji Y, Nagatsuka M, Yamabe T, Ogino H, et al. Descending aortic banding for re-rupture of retrograde aortic dissection after emergency thoracic endovascular aortic repair. *Gen Thorac Cardiovasc Surg* 2020;68:70-3.
9. Moulakakis KG, Kakisis JD, Geroulakos G. Aortic banding to treat Simultaneously a type Ia endoleak and aortic neck rupture during endovascular abdominal aortic aneurysm repair. *Ann Vasc Surg* 2019;61:455-8.
10. Krajcer Z, Dougherty KC, Gregoric ID. Long-term results of aortic banding for Complex infrarenal neck anatomy and type I endoleak after endovascular abdominal aortic aneurysm repair. *Tex Heart Inst J* 2012;39:799-805.
11. Haulon S, Greenberg RK, Khwaja J, et al. Aortic dissection in the setting of an infrarenal endoprosthesis: a fatal combination. *J Vasc Surg* 2003;38:1121-4.
12. Iyer K, Rigby M, Vrabec G. Type B aortic dissection after endovascular abdominal aortic aneurysm repair causing endograft collapse and severe malperfusion. *J Vasc Surg* 2009;50:413-6.
13. van Keulen JW, Toorop RJ, de Borst GJ, et al. Abdominal stent-graft collapse due to progression of a Stanford type B dissection. *J Endovasc Ther* 2009;16:752-4.
14. Vainas T, Tielliu IFJ, de Vries BMW, van der Laan M, Zeebregts CJ, van den Dungen JJAM. Acute type B dissection complicated by infrarenal aortic stent-graft collapse with Spontaneous Re-expansion. *J Endovasc Ther* 2014;21:353-5.
15. Psacharopulo D, Ferrero E, Viazzo A, Ferri M, Ripepi M, Nessi F. Abdominal aortic endograft collapse due to false lumen radial force of an acute type B aortic dissection. *Ann Vasc Surg* 2014;28:1931.e9-12.
16. Yoshiga R, Morisaki K, Matsubara Y, et al. Emergency thoracic aortic stent grafting for acute complicated type B aortic dissection after a previous abdominal endovascular aneurysm repair. *Surg Case Rep* 2015;1:99.
17. Goto Y, Hosoba S, Ogawa S, Kinoshita Y. Collapsed stent graft and severe malperfusion 2 years after endovascular aortic repair. *Eur J Cardiothorac Surg* 2017;52:599-600.
18. Itoga NK, Wu T, Dake MD, Dalman RL, Lee JT. Acute type B dissection causing collapse of EVAR endograft and iliac limb occlusion. *Ann Vasc Surg* 2018;46:206.e1-4.
19. Nomura Y, Nagao K, Hasegawa S, et al. Fatal Complications of new-onset complicated type B aortic dissection after endovascular abdominal aortic aneurysm repair: report of 2 cases and literature review. *Vasc Endovascular Surg* 2019;53:255-8.
20. Ostapenko A, Richard MN, Dietzek AM. Rare case of acute type B dissection causing complete collapse of EVAR stent. *Vasc Endovascular Surg* 2019;53:420-3.
21. Cooke PV, Bai H, George JM, Marin ML, Tadros R. Collapsed endograft and lower limb ischemia from type B dissection repaired with thoracic endovascular aortic graft and iliac stenting: a case report and review of the literature. *J Vasc Surg Cases Innov Tech* 2022;8:256-60.
22. Nienaber CA, Kische S, Zeller T, et al. Provisional extension to Induce complete attachment after stent-graft placement in type B aortic dissection: the PETTICOAT Concept. *J Endovasc Ther* 2006;13:738-46.
23. Lombardi JV, Hughes GC, Appoo JJ, et al. Society for Vascular Surgery (SVS) and Society of thoracic Surgeons (STS) reporting standards for type B aortic dissections. *J Vasc Surg* 2020;71:723-47.
24. Upchurch GR Jr, Escobar GA, Azizzadeh A, et al. Society for Vascular Surgery clinical practice guidelines of thoracic endovascular aortic repair for descending thoracic aortic aneurysms. *J Vasc Surg* 2021;73:55-83S.
25. Eagleton MJ, Shah S, Petkosevek D, Mastracci M, Greenberg RK. Hypogastric and subclavian artery patency affects onset and recovery of spinal cord ischemia associated with aortic endografting. *J Vasc Surg* 2014;59:89-94.
26. Dake MD, Brinkman WT, Han SM, et al. Outcomes of endovascular repair of aortic aneurysms with the GORE thoracic branch endoprosthesis for left subclavian artery preservation. *J Vasc Surg* 2022;76:1141-9.
27. Zhao Z, Qin J, Yin M, et al. In situ laser stent graft fenestration of the left subclavian artery during thoracic endovascular repair of type B aortic dissection with limited proximal landing zones: 5-year outcomes. *J Vasc Interv Radiol* 2020;31:1321-7.