

# Submental Island Flaps for Lateral Reconstruction: Technical Refinements for Optimal Outcomes and Resource Efficiency

Melissa S. Oh, MD , Nikhil T. Vettikattu, BS, Harry Michael Baddour, MD, Jennifer H. Gross, MD, Brian J. Boyce, MD, Mihir R. Patel, MD, Nicole C. Schmitt, MD, Clementino Arturo Solares, MD, Jackson R. Vuncannon, MD, and Azeem S. Kaka, MD 

## Abstract

**Objective.** To describe our modifications to the submental island flap (SMIF) in a case series that demonstrates improved reproducibility, shortened length of stay (LOS), and reduced utilization of hospital resources.

**Study Design.** This retrospective case series with chart review included adult patients who underwent resection of malignant or benign tumors resulting in lateral facial, parotid, or temporal bone defects, which were reconstructed with SMIF.

**Setting.** A tertiary-care academic referral center.

**Methods.** Retrospective case series included all adult patients who underwent SMIF reconstruction between March 2020 and August 2021. Patient demographic and clinical data were collected. Primary outcomes were measures of hospital utilization including duration of surgery, LOS, and post-operative outcomes.

**Results.** Twenty-eight patients were included with a mean age of 71.7 years. Eighty percent were male. All patients underwent parotidectomy, and the mean operative time was 347 minutes. The median LOS was 2.5 days (range 0-16 days). Seventy-five percent of the flaps drained into the internal jugular vein, and 25% drained into the external jugular vein. No patients required reoperation or readmission. All flaps survived.

**Conclusion.** SMIFs are a safe and effective option for reconstruction of lateral facial, parotid, and temporal bone defects. Compared to free flap reconstruction, SMIFs offer reduced length of surgery, decreased use of health care resources, and lower rate of reoperation. As health care resource allocation is increasingly important, the SMIF offers an excellent alternative to free flap reconstruction of lateral defects.

## Keywords

COVID-19, lateral facial, mastoidectomy, parotid, reconstruction, regional flap, submental island flap, temporal bone

Received August 3, 2023; accepted February 5, 2024.

The coronavirus disease 2019 (COVID-19) pandemic led to significant challenges in the surgical management of head and neck malignancies. According to the Georgia Department of Public Health, the first documented cases were in early March 2020.<sup>1</sup> Hospitals were forced to evaluate utilization of resources and postpone both elective and urgent surgical cases. As COVID-19-related admissions increased, advanced head and neck cancer cases were sometimes canceled due to the shortage of bed availability for patients who would typically need 6 to 7 days in the hospital after free flap reconstruction.<sup>2</sup> Delays in care created unacceptable hardships for patients, including the potential for unfavorable oncologic and functional outcomes. In addition, the delay in care for critically ill patients increased frustration for providers, schedulers, and hospital administrators. This reality was an unfortunate consequence of limitations in inpatient staffing and bed availability, compounded by staff attrition and the subsequent reliance on travel nurses.<sup>3</sup>

Free flap reconstruction is the pinnacle of the reconstructive ladder and offers the most freedom to design a reconstruction for patient-specific goals.<sup>4</sup> However, during

---

Department of Otolaryngology–Head and Neck Surgery, Division of Head and Neck Oncology and Reconstruction, Emory University School of Medicine, Atlanta, Georgia, USA

This research was orally presented at the American Head and Neck Society 11th International Conference on Head and Neck Cancer; July 12, 2023; Montreal, Quebec, Canada.

## Corresponding Author:

Azeem S. Kaka, MD, Department of Otolaryngology–Head and Neck Surgery, 550 Peachtree Street Northeast, MOT Suite 1135, Atlanta, GA 30308, USA.

Email: azeem.kaka@emoryhealthcare.org

the COVID-19 pandemic, free flap reconstruction placed a greater strain on hospital resources and decreased the ability to treat a maximal number of patients. Free flap reconstructions typically incorporate a 2-team approach, involve longer operative time and longer duration of stay for flap monitoring and management of the donor site, and have a range of associated complications, often leading to increased hospital resource utilization. These factors also subject more health care providers to the risk of COVID-19 exposure compared to other reconstruction techniques.<sup>4</sup> Furthermore, during the COVID-19 pandemic, technical limitations arose when attempting to use face shields or respirators concomitantly with surgical microscopes or magnifying loupes for microvascular surgery. It is prudent to consider locoregional flap in cases where it can accomplish the same functional and cosmetic outcomes as a free flap.

We aim to describe our experience with the submental island flap (SMIF) for reconstruction of lateral head and neck defects and to understand its impact on hospital resource utilization during the COVID-19 pandemic and beyond. Further, we aim to discuss additional technical modifications that are highly reliable and can be performed without microsurgical fellowship training.

## Methods

The Emory University Institutional Review Board approved this retrospective review in May 2022 (STUDY00004496). We identified all adult patients who underwent SMIF for lateral head and neck defects including skin (preauricular or infra-auricular, temporal or facial), auricle, parotid, mastoid, and lateral temporal bone. Patient demographics and medical and clinical history were collected from the electronic medical record. The flap area was calculated as  $\pi \times \text{radius}^1 \times \text{radius}^2$ .<sup>5</sup> Contrast-enhanced computed tomography (CT) images of the neck were reviewed. Venous drainage patterns of the submental vein were documented and recorded. The diameter of ipsilateral anterior jugular veins (AJVs) was measured, and prominent AJV was defined as greater than 3 mm in diameter. Descriptive statistics were calculated. Disease-free survival was defined as the time from surgery to follow-up for patients who did not have a recurrence.

## Surgical Technique

After a patient was identified as a candidate for the SMIF, we evaluated his or her preoperative imaging to determine venous drainage. The vein lateral to the submandibular gland was identified as the primary flap drainage. This vein was followed proximally on axial CT images to determine if it drained into the internal (IJV) or external jugular vein (EJV). CT images that represent the 2 drainage patterns are available in Supplemental Figures S1 and S2, available online. If the scan had sufficiently thin slices, this vein could typically be followed distally to the submental vein. In cases when a neck dissection was indicated, the SMIF was

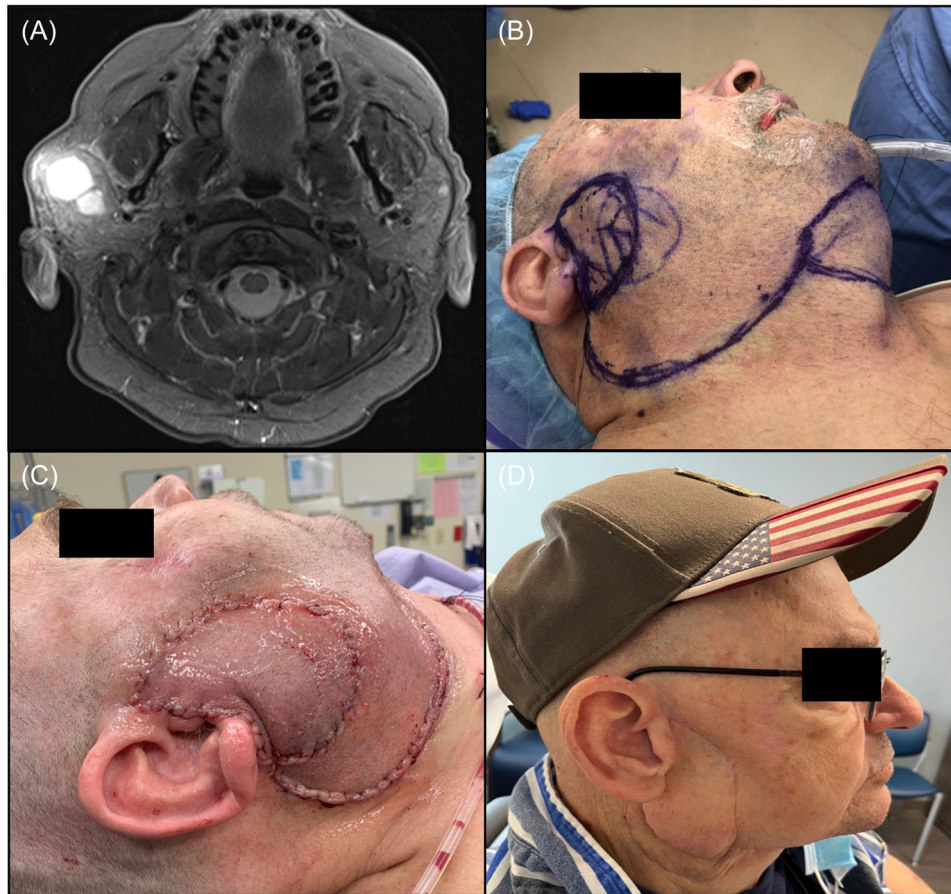
harvested prior to the neck dissection. The ipsilateral anterior belly of digastric and mylohyoid muscle were incorporated into the flap as previously described.<sup>6,7</sup> The flap was fully mobilized and protected prior to performing the neck dissection, which was particularly important in preserving the flap in patients with primary venous drainage to the EJV. Additional branches of the facial artery, specifically the ascending palatine and tonsillar arteries, were ligated in order to increase flap length and decrease tension at the distal tip. The submental donor site was closed primarily in all cases. Representative images of preoperative flap design and primary closure are included in **Figure 1**. One surgical team was used for all cases.

## Results

Twenty-eight patients met an inclusion criteria and were included in the study. The mean age of the study population was 72 years (median 76 years, range 26-85 years) at the time of surgery, and 71% (20 of 28 patients) were male. The median body mass index was 28.6 kg/m<sup>2</sup> (range 20-43 kg/m<sup>2</sup>). One patient had a history of head and neck irradiation to the contralateral neck. Fifty percent (14 of 28 patients) had undergone prior head and neck oncologic surgery. Of these, 79% (11 of 14) had a resection of cutaneous malignancy, and 21% (3 of 14) had a parotidectomy with local recurrence. Pathologic diagnoses of the resected tumors are shown in **Table 1**.

All patients underwent reconstruction with the ipsilateral SMIF, and all flaps survived without arterial or venous compromise. Flap size ranged from 8.7 to 44.0 cm<sup>2</sup> with a mean flap area of 28.6 cm<sup>2</sup>. Eleven percent (3 of 28) had no cutaneous defect, and therefore, reconstruction was performed with de-epithelized buried SMIFs. Thirty-two percent (9 of 28) of cases involved partial or total auriclectomy. Eleven percent of patients (3 of 28) underwent lateral temporal bone resection. All patients underwent parotidectomy. Fifty-seven percent (16 of 28) underwent radical parotidectomy, and all other patients had facial nerve preservation with superficial (29%, 8 of 28) or total parotidectomy (14%, 4 of 28). Of the 16 patients who underwent radical parotidectomy, facial nerve sacrifice occurred at the main trunk in 44% (7 of 16), the upper division in 19% (3 of 16), and the lower division in 38% (6 of 16). Nerve grafts or transfers were performed in 38% (6 of 16) with facial nerve sacrifice. Static reanimation procedures to address the eye (direct brow lift, lateral tarsal strip, and eyelid gold weight) were performed in 60% (6 of 10) patients with the sacrifice of the upper division or main trunk. Midface suspension was performed in 31% (4 of 13) of patients with sacrifice of the lower division or main trunk. This data is summarized in **Table 2**.

The median length of stay (LOS) was 2.5 days (range 0-16 days). The mean operative time was 347 minutes (median 319 minutes, range 176-624 minutes) (**Table 2**). Four patients had postoperative complications within 30 days of surgery, including 2 patients with a stroke, 1 patient with acute



**Figure 1.** SMIF reconstruction following resection of squamous cell carcinoma. Patient discharged postoperative day 0. (A) Preoperative axial magnetic resonance imaging. (B) Preoperative outline of resection and submental island flap (SMIF). (C) Immediate postoperative appearance. (D) Well-healed SMIF at 2-year follow-up.

**Table 1.** Pathologic Diagnoses of the Resected Tumors

Pathologic diagnosis	n (%)
Cutaneous malignancies	15 (54)
Squamous cell carcinoma	10 (67)
Basal cell carcinoma	3 (20)
Melanoma	1 (7)
Merkel cell carcinoma	1 (7)
Salivary gland malignancies	11 (39)
Mucoepidermoid carcinoma	4 (36)
Adenocarcinoma NOS	2 (18)
Salivary duct carcinoma ex PA	2 (18)
Adenoid cystic carcinoma	1 (9)
Acinic cell carcinoma	1 (9)
Recurrent PA	1 (9)
Temporal bone squamous cell carcinoma	2 (11)

Abbreviations: NOS, not otherwise specified; PA, pleomorphic adenoma.

delirium, and 1 patient with a submental infection, which required incision and drainage at the bedside. One of the patients who suffered a stroke was discharged to hospice and subsequently passed away 11 days after surgery. The patient

with the infection was immunocompromised, and on dialysis, and required inpatient hospitalization for 16 days. No patients returned to the operating room within 30 days or had surgical complications related to the reconstruction after discharge. All flaps remained viable, and none exhibited partial necrosis, venous compromise, or dehiscence.

Median follow-up was 8.1 months (range 0.3-33 months). Fifty percent (14 of 28) of patients received adjuvant radiation following surgery with a median of 50 days (range 31-51 days) between their operation and the start of radiotherapy. Twenty-one percent (3 of 14) of those patients met a 6-week postoperative radiation treatment target time. Eleven percent (3 of 28) patients experienced recurrence in the head and neck, and 7% (2 of 28) experienced distant metastases. Of the patients who experienced recurrence in the head and neck, 1 had recurrence in the superior helix, 1 in the ipsilateral orbit, and the last patient in the ophthalmic division of the trigeminal nerve and the parietal lobe. There were no recurrences to cervical lymph nodes or local recurrences related to the submental flap. The median time between surgery and diagnosis of local and distant recurrence was 249 and 68 days, respectively. Two patients were lost to

**Table 2.** Characteristics and Outcomes of SMIF Reconstruction Patients

Age [mean (SD)]	72 (14)
Gender = male (%)	20 (71)
Smoking history = yes (%)	14 (50)
Prior H&N surgery (%)	14 (50)
Primary site cutaneous (%)	15 (54)
Primary site parotid (%)	11 (39)
Primary site temporal bone (%)	2 (7)
Total parotidectomy (%)	4 (14)
Superficial parotidectomy (%)	8 (30)
Radical parotidectomy (%)	16 (57)
FN complete resection (%)	7 (44)
FN upper division resection (%)	3 (19)
FN lower division resection (%)	6 (38)
FN graft (%)	6 (38)
Facial reanimation	9 (56)
Main trunk or upper division resection (%)	10 (62)
Eyelid procedures (%)	6 (60)
Main trunk or lower division resection (%)	13 (81)
Midface suspension (%)	4 (31)
Neck dissection (%)	27 (96)
Auriculectomy (%)	9 (32)
Cortical mastoidectomy	2 (7)
Temporal bone resection	3 (11)
Operative time in minutes [mean (range)]	347 (174-624)
Length of stay in days [median (range)]	2.5 (0-16)
Immediate postoperative complications (%)	4 (14)
Medical complications (%)	3 (75)
Surgical site complication (%)	1 (25)
Postoperative complications within 30 days (%)	2 (7)
Days to postoperative radiation therapy (median, range)	50 (31-51)
Local recurrence (%)	3 (11)
Distant recurrence (%)	2 (7)
Median time until recurrence [d (range)]	230 (31-469)
Time to follow-up [d (range)]	242 (9-977)

Abbreviations: FN, facial nerve; H&N, head and neck; SMIF, submental island flap.

follow-up. Excluding those patients, median disease-free survival was 193 days (range 9-469 days) for patients with a malignant tumor (**Table 2**).

Venous drainage patterns were analyzed for the 24 patients who had available preoperative imaging with thin slice contrast-enhanced CT. Seventy-five percent (18 of 24) had primary venous drainage into the IJV via the common facial vein, and 25% (6 of 24) had primary venous drainage into the EJV. Thirty-eight percent (9 of 24) had additional venous drainage through a prominent AJV. One patient, with the largest flap measuring 12 × 7 cm, underwent a hybrid venous coupling from a prominent AJV to the EJV to augment venous outflow in addition to the main drainage from the common facial vein. Primary venous drainage patterns were confirmed intraoperatively for all patients.

## Discussion

In this study, we describe our modifications to the SMIF and the use of this in the reconstruction of lateral facial, parotid, and temporal bone defects. The SMIF is a safe and reliable flap with minimal donor site morbidity, simple harvest, and excellent contour and color match for lateral head and neck defects.<sup>8</sup> Multiple locoregional flaps have been described for reconstruction of lateral facial defects including myofascial flaps, such as the temporalis or sternocleidomastoid, and axial flaps, including the supraclavicular island, lower trapezius island, and pectoralis major myocutaneous flaps. However, muscle flaps may create unsightly cosmetic deformities and have a tendency to atrophy significantly over time.<sup>9</sup> While the supraclavicular flap does offer a pliable skin paddle with reasonable color match, this flap is limited in its reach above the zygoma, and the distal tip of the flap is often unreliable in patients with poor vascularity.<sup>9,10</sup>

Initially described by Martin et al in 1993,<sup>11</sup> the SMIF has since been used for reconstruction of oral cavity, pharyngeal, lateral skull base, lateral facial, and parotidectomy defects.<sup>2,12,13</sup> The SMIF has strong reliability, and a technical modification involving the inclusion of the mylohyoid muscle has led to increased efficiency and reliability of the flap harvest.<sup>2,6,7</sup> The SMIF can be incorporated into the neck incision, requiring decreased dissection and donor site morbidity compared to other locoregional flaps.<sup>2</sup> This flap also offers an excellent color match and contour for lateral defects. There is no oncologic inferiority with the submental flap, as Level IA is rarely involved with lateral tumors and can still be dissected with appropriate technique.<sup>14</sup>

In our opinion, these technical modifications<sup>6,7</sup> as well as a fundamental understanding of venous drainage patterns as described here contributed to our success rate. Others have described multiple consecutive failures of this flap,<sup>15-17</sup> which may be due to lack of experience, as other high-volume institutions have also demonstrated similar success.<sup>2,13,18</sup> It is noteworthy that major complications including partial and total flap loss were significantly more common in patients who were previously irradiated.<sup>17</sup> None of our patients were irradiated to the ipsilateral neck, and only 1 patient was irradiated to the contralateral neck. The advantages of shorter LOS and operative time elevated this flap into our reconstructive algorithm for lateral facial and parotid defects at our institution since the start of the COVID-19 pandemic. Although only 21% of patients (3 of 14) who received adjuvant radiation achieved a 6-week postoperative radiotherapy goal despite reduced LOS and lack of readmission, the COVID-19 pandemic contributed to delays in accessing radiation, which was noted at other institutions as well.<sup>19</sup> The size of the cutaneous paddle is dependent on the submental skin laxity and ability to achieve primary closure at the donor site, and sizes up to 12 × 7 cm were harvested in our case series. Ligation of

cervical branches of the facial artery further improves maximum flap length and reduces tension at the distal tip, which contributed to the absence of flap dehiscence in our series.

Morbidity as a function of operative time for the head and neck cancer patient remains a factor in surgical treatment algorithms. Our mean operative time was 347 minutes, which included facial nerve reanimation procedures as indicated. These results are comparable to prior studies using the SMIF with mean operative times of 413 minutes for reconstruction of lateral soft tissue and parotid defects and 544 minutes for lateral skull base defects.<sup>2,12</sup> In contrast, the mean operative time was 544 minutes for free flap reconstruction for lateral soft tissue and parotid defects and 683 minutes for lateral skull base defects.<sup>2,12</sup> In our study, the median LOS was 2.5 days, with the minimal LOS being 0 days for a patient who could not be admitted due to the lack of inpatient hospital beds. Initially, this patient was planned to have a free flap reconstruction that would have been canceled if unable to be discharged on Postoperative Day 0. This LOS is lower than other published studies showing median LOS with SMIF as 4.5 days for parotidectomy and lateral facial soft tissue defects and 5 days for lateral skull base defects.<sup>2,12</sup> Increased emphasis on time-to-discharge in the setting of the COVID-19 pandemic likely contributed to this difference in LOS. There were no readmissions in our study. This LOS is compared to a free flap LOS, which has been reported as a median of 6 and 7 days for similar defects.<sup>2,12</sup>

Venous insufficiency is a major cause of SMIF compromise.<sup>15</sup> Preoperatively defining the venous drainage of the flap on CT imaging has led to the high rate of success of this flap at our institution. This method has not been extensively described in the literature. As seen in our study, 75% of patients had drainage into the IJV system. Given that 25% of patients had drainage into the EJV, we recommend harvest of the SMIF prior to performing the neck dissection. Drainage patterns in our patient cohort align with those reported in a retrospective review describing intraoperative findings of drainage to IJV in 72.9% and EJV in 27.1% of patients.<sup>20</sup> In the case of drainage to the EJV, the flap must be fully mobilized and rotated posteriorly so the anterior border of the sternocleidomastoid muscle can be dissected. For this reason, the flap is typically done by a single surgeon. In cases with a 2-team approach, typically the surgery is safer and more efficient if the reconstructive surgeon performs both the neck dissection and reconstruction to avoid extra switching between teams and any inadvertent flap vessel injury.

We also reported the incidence of secondary drainage through large AJVs. In our cohort, 38% (9 of 24) of patients had prominent AJVs, which could be used to create a hybrid outflow for the flap and increase venous output. A prominent AJV was defined as greater than 3 mm in our study. This size cutoff was chosen due to the

ease of venous coupler application, but smaller veins could be coupled for additional venous outflow if required. In our patients, adjunctive venous drainage through AJV coupling was not required in any of our flaps as none developed venous insufficiency intraoperatively or postoperatively, but we did hybridize our largest SMIF to ensure that venous outflow would be sufficient in the postoperative setting. Hybrid venous outflow can be created relatively easily with loupe magnification using a venous coupling apparatus. Typically, the AJV is coupled to the EJV to facilitate further outflow in an IJV-dominant flap. When harvesting SMIFs in patients with a prominent AJV on preoperative imaging, our standard practice now is to dissect the AJV to the sternal notch, ligate it at the sternal notch, and elevate the vein off the visceral fascia into the flap. In cases of venous congestion intraoperatively or postoperatively, one should consider coupling the AJV to the EJV to improve flap drainage.

The major limitation of this flap is size. If the patient does not have the sufficient skin laxity for primary closure of the submentum, then another reconstructive option should be considered. Indeed, a free flap was planned for several of the larger defects in this series in case the SMIF was determined to be insufficient. Patients were typically consented for an anterolateral thigh flap in addition to the SMIF. However, this was not necessary in any of the patients. It has been shown previously that SMIFs are typically selected for the reconstruction of smaller defects,<sup>21</sup> but ultimately this decision is patient-dependent. In published studies, the mean area of the flap was similar to our study (28.6 vs 32.4 cm<sup>2</sup>).<sup>2</sup> Based on our own experience, the maximum reach of this flap superiorly is 5 cm above the zygoma. Donor site morbidity is minimal, but it should be discussed with the care team as surgical options are under consideration. The SMIF does affect neck extension and can produce some component of dysphagia, both as a function of neck tightness and harvest of the anterior belly of digastric and mylohyoid muscles. Based on our institutional experience, dysphagia is most noticeable in the older, previously radiated patient population and increases as the width of the flap increases.

In our experience, patients welcome the discussion of this flap as an option, often preferring a shorter operative time and LOS if there are no functional or oncologic downsides. Patients frequently report high satisfaction with cosmetic appearance of the reconstruction. The flap has excellent color match to the facial defect, and excising submental laxity leads to a more youthful appearance.

Limitations of this study include the lack of a comparative control group of free flap patients and its retrospective nature. Further directions include creating models for dysphagia after harvest of the flap by using quantitative swallow tests and correlating this with patient and flap characteristics. This would help counsel patients appropriately and help determine in which patients the SMIF should be avoided.

## Conclusion

During the COVID-19 pandemic, the SMIF served as a workhorse for lateral facial, parotid, and temporal bone defects and reduced LOS and operative times while permitting major head and neck surgery when hospitals had little to no bed availability. The results were so encouraging, the SMIF has remained the reconstruction of choice for the above defects as the pandemic has dissipated. We present our experience and technical modifications to hopefully increase the use and success of this flap.

## Author Contributions

**Melissa S. Oh**, study design, acquisition, analysis, and interpretation of data, writing of manuscript; **Nikhil T. Vettikattu**, acquisition, analysis, and interpretation of data, writing of the manuscript; **Harry Michael Baddour**, study design, revised manuscript; **Jennifer H. Gross**, study design, revised manuscript; **Brian J. Boyce**, study design, revised manuscript; **Mihir R. Patel**, study design, revised manuscript; **Nicole C. Schmitt**, study design, revised manuscript; **Clementino Arturo Solares**, study design, revised manuscript; **Jackson R. Vuncannon**, study design, revised manuscript; **Azeem S. Kaka**, study design, analysis and interpretation of data, writing of manuscript.

## Disclosures



**Competing interests:** Nicole C. Schmitt discloses research funding from Astex Pharmaceuticals and consulting for Sensorion and Checkpoint Surgical (unrelated to this work). The other authors (Melissa S. Oh, Nikhil T. Vettikattu, Harry Michael Baddour, Jennifer H. Gross, Brian J. Boyce, Mihir R. Patel, Clementino Arturo Solares, Azeem S. Kaka) declare that they have no conflicts of interest.

**Funding source:** Department of Otolaryngology–Head and Neck Surgery, Emory University School of Medicine.

## Supplemental Material

Additional supporting information is available in the online version of the article.

## ORCID iD

Melissa S. Oh  <http://orcid.org/0000-0002-2379-8663>  
Azeem S. Kaka  <http://orcid.org/0000-0002-4528-4460>

## References

1. Georgia Department of Public Health. Daily status report. 2021. Accessed January 7, 2023. <https://dph.georgia.gov/covid-19-daily-status-report>
2. Patel AV, Thuener JE, Clancy K, Ascha M, Manzoor NF, Zender CA. Submental artery island flap versus free flap reconstruction of lateral facial soft tissue and parotidectomy defects: comparison of outcomes and patient factors. *Oral Oncol.* 2018;78:194-199. doi:10.1016/j.oraloncology.2018.01.027
3. Lavoie-Tremblay M, Gélinas C, Aubé T, et al. Influence of caring for COVID-19 patients on nurse's turnover, work satisfaction and quality of care. *J Nurs Manag.* 2022;30(1):33-43. doi:10.1111/jonm.13462
4. Desai SC, Seth R. Shifting paradigms in head and neck reconstructive surgery during the COVID-19 crisis. *Facial Plast Surg Aesthet Med.* 2020;22(3):152-154. doi:10.1089/fpsam.2020.0186
5. Schmidt M, Cristofari S, Al Madani O, et al. Bipedicled dorsal intercostal artery propeller flaps for reconstruction of extensive cervicothoracic midline defects. *Microsurgery.* 2020;40(6):656-662. doi:10.1002/micr.30595
6. Patel UA, Bayles SW, Hayden RE. The submental flap: a modified technique for resident training. *Laryngoscope.* 2007;117(1):186-189. doi:10.1097/01.mlg.0000246519.77156.a4
7. Zenga J, Emerick KS, Deschler DG. Submental island flap: a technical update. *Ann Otol Rhinol Laryngol.* 2019;128(12):1177-1181. doi:10.1177/0003489419862582
8. Steuer CE, Hanna GJ, Viswanathan K, et al. The evolving landscape of salivary gland tumors. *CA Cancer J Clin.* 2023;73(6):597-619. doi:10.3322/caac.21807
9. Richmon JD, Yarlagadda BB, Wax MK, Patel U, Diaz J, Lin DT. Locoregional and free flap reconstruction of the lateral skull base. *Head Neck.* 2015;37(9):1387-1391. doi:10.1002/hed.23725
10. Patel NS, Modest MC, Brobst TD, et al. Surgical management of lateral skull base defects. *Laryngoscope.* 2016;126(8):1911-1917. doi:10.1002/lary.25717
11. Martin D, Pascal JF, Baudet J, et al. The submental island flap: a new donor site. Anatomy and clinical applications as a free or pedicled flap. *Plast Reconstr Surg.* 1993;92(5):867-873.
12. Howard BE, Nagel TH, Barrs DM, Donald CB, Hayden RE. Reconstruction of lateral skull base defects: a comparison of the submental flap to free and regional flaps. *Otolaryngol Head Neck Surg.* 2016;154(6):1014-1018. doi:10.1177/0194599816634296
13. Bayon R, Davis AB. Submental flap for soft tissue reconstruction following radical parotidectomy. *Otolaryngol Head Neck Surg.* 2019;160(6):1130-1132. doi:10.1177/0194599819827822
14. Eskander A, Strigenz D, Seim N, Ozer E. Submental artery island flap with simultaneous level I neck dissection. *Head Neck.* 2018;40(4):842-845. doi:10.1002/hed.25044
15. Shires CB, Sebelik M. The submental flap: be wary. *Clin Case Rep.* 2022;10(1):e05260. doi:10.1002/ccr3.5260
16. Faisal M, Adeel M, Riaz S, et al. The submental island flap in head and neck cancer. *Ann Maxillofac Surg.* 2018;8(2):287-291. doi:10.4103/ams.ams\_225\_18
17. Taghinia AH, Movassaghi K, Wang AX, Pribaz JJ. Reconstruction of the upper aerodigestive tract with the submental artery flap. *Plast Reconstr Surg.* 2009;123(2):562-570. doi:10.1097/PRS.0b013e3181977fe4
18. Paydarfar JA, Patel UA. Submental island pedicled flap vs radial forearm free flap for oral reconstruction: comparison of outcomes. *Arch Otolaryngol Head Neck Surg.* 2011;137(1):82-87. doi:10.1001/archoto.2010.204
19. Mitra S, Simson D, Khurana H, et al. Treatment delay during radiotherapy of cancer patients due to COVID-19 pandemic. *Asian Pac J Cancer Prev.* 2022;23(7):2415-2420. doi:10.31557/APJCP.2022.23.7.2415.

- 
20. Lin HC, Huang YS, Chu YH, et al. Vascular anatomy is a determining factor of successful submental flap raising: a retrospective study of 70 clinical cases. *PeerJ*. 2017;5:e3606. doi:10.7717/peerj.3606
  21. Mooney SM, Sukato DC, Azoulay O, Rosenfeld RM. Systematic review of submental artery island flap versus free flap in head and neck reconstruction. *Am J Otolaryngol*. 2021;42(6):103142. doi:10.1016/j.amjoto.2021.103142