

The Hand Patient: Fracture-dislocation of the base of the first meta-carpal bone (Bennett's Fracture)

Prof Ulrich Mennen

MBChB, FRCS(Glasg), FRCS(Edin), FCS(SA)Orth. MMedOrth), MD(Orth) Pret
Head: Department of Hand-and Microsurgery, MEDUNSA

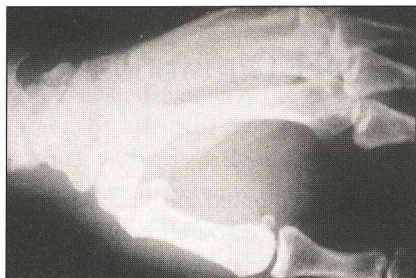


Figure 1: The proximal and radial displacement of the base of the thumb metacarpal is due to the strong pull by the APL tendon. The avulsed fragment is still attached by the strong inter metacarpal ligaments.

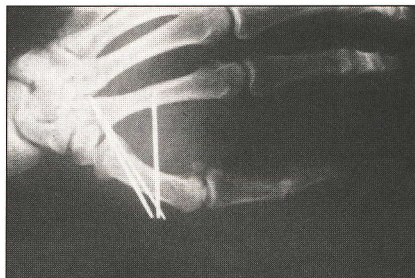

Figure 2: Reduction and stability can only be achieved by closed reduction and percutaneous fixation (protected by a plaster cast) for six weeks.

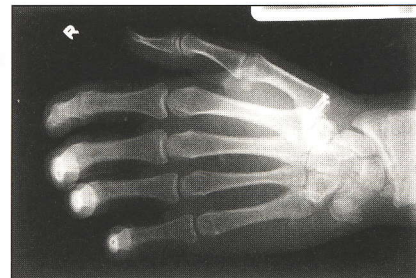

Figure 3: With the advent of mini-screws and –plates, some surgeons with the necessary technical training fix these small fragments in an anatomical and stable position. This has the advantage of early mobilization without the use of any splints.

Dear Colleague,

Re: Your patient with a hyper-abduction injury of the left hand thumb (Bennett's fracture)

Thank you for your referral of Mr. A F M a thirty-three year old right dominant sales man who was involved in a motor vehicle accident two days ago. He complains of severe pain at the base of his left thumb. He believes that the thumb was severely hyper-abducted during the accident. He did not suffer any other injuries.

On **examination** the base of the thumb is swollen and bluish discoloured. The thumb is very painful with movement. The rest of the hand is neuro-vascular intact. The only **special investigation** needed was a plain x-ray of both hands which revealed an avulsion fracture of the base of the first meta-carpal. The first meta-carpal is dislocated and proximally displaced. No other fractures or dislocations are seen. The **diagnosis** is a fracture-dislocation of the first meta-carpal bone. This is called a Bennett's fracture.

The **treatment** used to be conservative with a plaster cast keeping the thumb in abduction. However reduction is very seldom adequate and usually displaces again once the swelling subsides. The only certain method of ensuring adequate reduction and maintenance is by percutaneous Kirschner wire stabilization. The thumb should be pulled distally while the second force reduces the dislocation by direct pressure on the base of the meta-carpal. This position is confirmed by intra operative x-rays or screening. Once reduction is achieved percutaneous K-wires should be placed through the first meta-carpal into the second meta-carpal across the first web space. This position is now protected with an external plaster-of-Paris splint to prevent the K-wires from bending. The plaster cast should stay on for six weeks at which time the K-wires are also removed.

DISCUSSION

The Bennett's fracture should be distinguished from a transverse fracture of the base of the first meta-carpal which is called a Rolando fracture. Two types of Rolando fractures are described namely ulnar deviated and radial deviated. The ulnarly deviated fractures (i.e. bent towards the index finger) are usually stable and can be treated conservatively with splinting for two or three weeks after which active mobilization is allowed. The radially deviated fracture (i.e. bent away from the index finger) is usually an unstable fracture and should be internally fixed.

The pathology of a Bennett's fracture is a hyper-abduction injury. The dislocation proximal and radial wards is due to the strong pull by the abductor pollicis longus tendon. This should be countered when reduction is done. The avulsed ulnar bony fragment is still attached to the intact strong inter-meta-carpal ligaments.

Untreated Bennett's fractures may develop post-traumatic osteo-arthritis. This will then have to be addressed with e.g. an excision arthroplasty. However this is seldom necessary.

With sincere regards,

Ulrich Mennen