

Visualization of anatomical structures in the carpal region of the horse using cone beam computed tomography (CBCT) in comparison with conventional multidetector computed tomography (MDCT)

M. Hagenbach¹, J. Bierau¹, AM. Cruz¹, C. Koch², G. Manso-Díaz³, K. Büttner⁴, C. Staszuk⁵, M. Röcken¹

¹ Equine Clinic (Surgery, Orthopedics), Justus-Liebig-University Giessen, Germany

² Swiss Institute of Equine Medicine (ISME), Department of Clinical Veterinary Medicine, Vetsuisse Faculty, University of Bern, Switzerland

³ Faculty of Veterinary Medicine, Department of Animal Medicine and Surgery, Universidad Complutense de Madrid, Spain

⁴ Unit for Biomathematics and Data Processing, Justus-Liebig-University Giessen, Germany

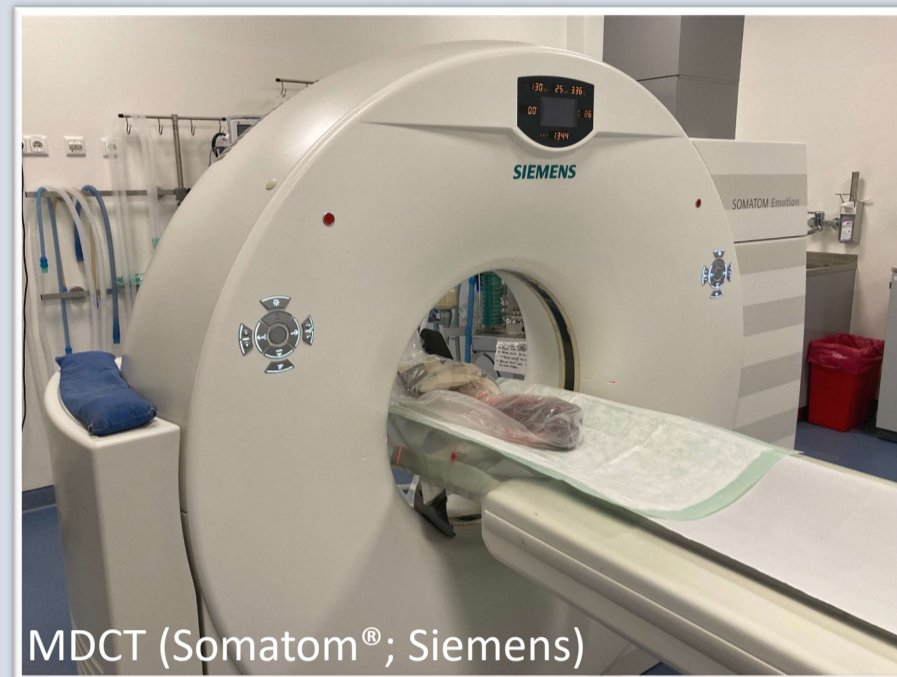⁵ Institute of Veterinary-Anatomy, -Histology and -Embryology, Faculty of Veterinary Medicine, Justus-Liebig-University Giessen, Germany

Materials and Methods

• twenty-eight forelimbs from fifteen horses, MDCT and CBCT scans before and after intraarticular contrast enhancement

MDCT

- fan-shaped X-ray beam and multi-row detector
- rotation in helical progression



CBCT

- cone-shaped X-ray beam and flat panel detector
- single rotation with multiple projections

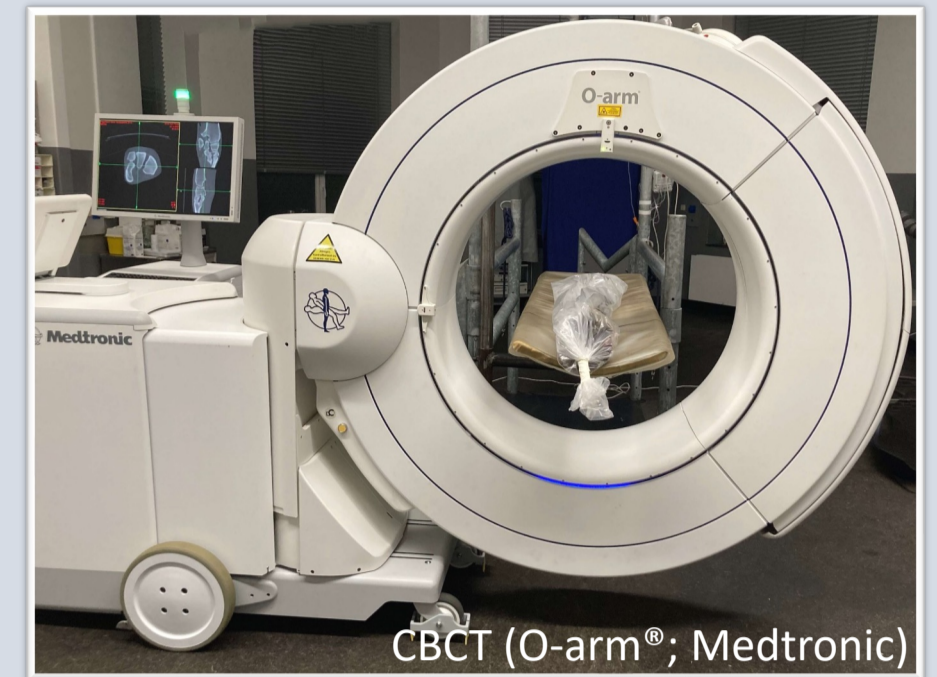
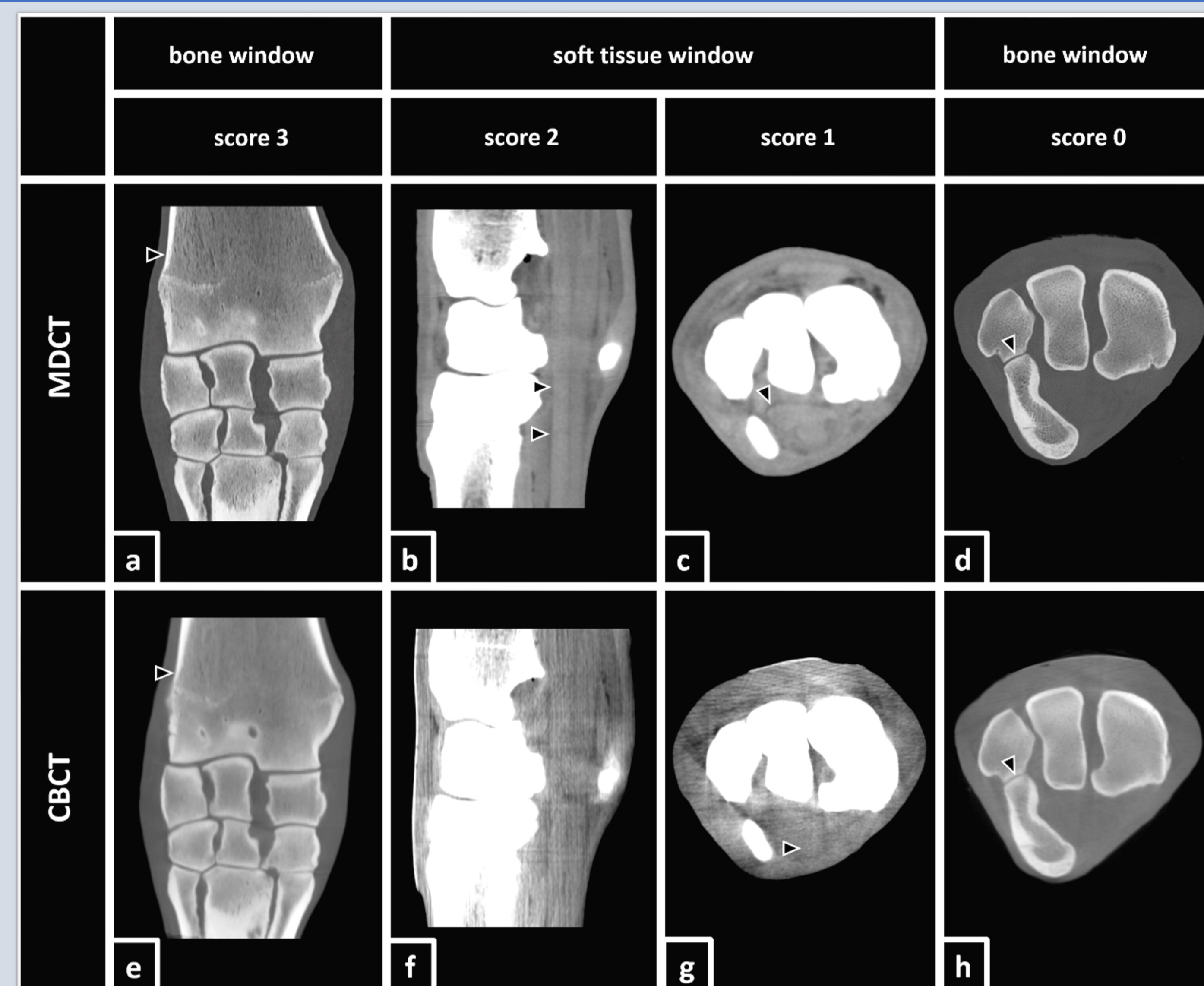


Image Evaluation



Modified visual scoring system^{1,2}:

0: structure was not visible.

→ (d, h): lining of cortical bone (ulnar and accessory carpal bone) is clearly visible, remaining cartilage is not visible in both, MDCT and CBCT

1: structure was poorly visualized but detectable and could only be identified by its location and signal intensity but not by margins, shape or size.

→ (c): carpal flexor tendon sheath was scored 1

(g): superficial digital flexor tendon was scored 1

2: structure could be clearly identified by its location, shape and signal intensity but the margins were not clearly delineated.

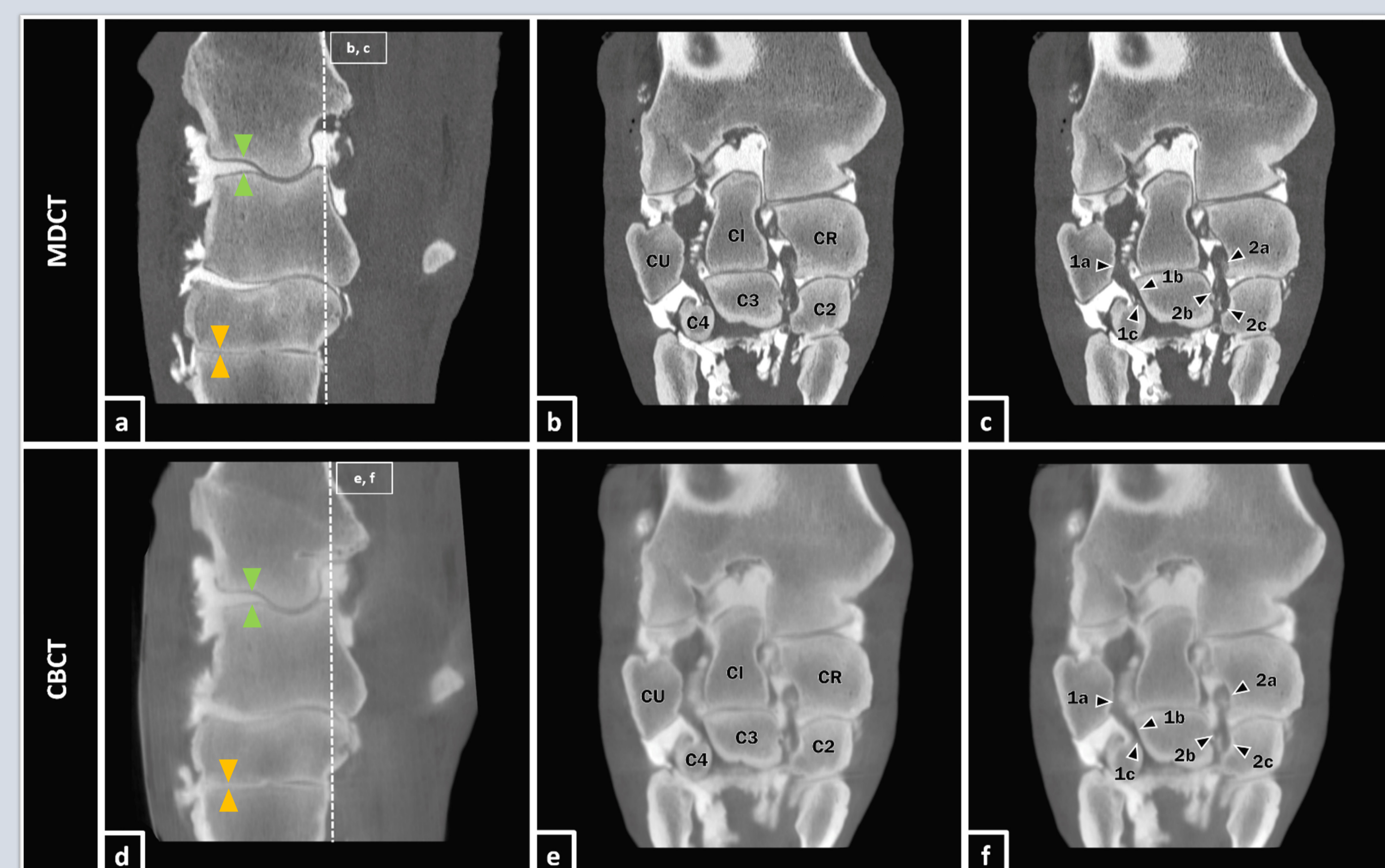
→ (b): deep digital flexor tendon was scored 2

(f): none of the structures was scored 2

3: structure was well visualized and clearly delineated by its location, shape, signal intensity, size and margins.

→ (a, e): distal aspect of the radius was scored 3 in both, MDCT and CBCT

Results



Osseous structures

- well visualized before and after contrast enhancement in both, MDCT and CBCT (mean score = 3, interobserver agreement = 100 %)

Cartilage

- not visible without contrast enhancement in both, MDCT and CBCT
- poorly to clearly visualized in CBCT (mean score = 1.50), clearly to well visualized in MDCT (mean score = 2.38) after contrast enhancement
- proximal joint levels (a, d; ▶) better visualized than distal joint levels (a, d; ►) in both, MDCT and CBCT

Soft tissue (tendons, tendon sheaths, ligaments)

- poorly visualized before and after contrast enhancement in both, MDCT and CBCT (coronal section: MDCT b, c and CBCT e, f)
- lateral (c, f; 1a-c) & medial (c, f; 2a-c) palmar intercarpal ligaments were clearly to well visualized after contrast enhancement in both, MDCT (mean score = 2.67) and CBCT (mean score = 2.50)

Discussion/Conclusion

Presented results were confirmed statistically.

CBCT represents a cost-effective and practical option in diagnostic imaging of osseous structures of the equine carpal joint. Contrast enhancement is unavoidable for the visualization of cartilage in both, MDCT and CBCT. Soft tissue structure visualization is rather poor, except for the lateral and medial palmar intercarpal ligaments after contrast enhancement.

References

1. Vallance, S. A., et al. "Comparisons of computed tomography, contrast enhanced computed tomography and standing low-field magnetic resonance imaging in horses with lameness localised to the foot. Part 1: anatomic visualization scores." *Equine Veterinary Journal* 44.1 (2012): 51-56.
2. Bierau J, Cruz AM, Koch C, Manso-Diaz G, Büttner K, Staszuk C, et al. Visualization of anatomical structures in the fetlock region of the horse using cone beam computed tomography in comparison with conventional multidetector computed tomography. *Front Vet Sci* (2023) 10:1278148. doi:10.3389/fvets.2023.1278148