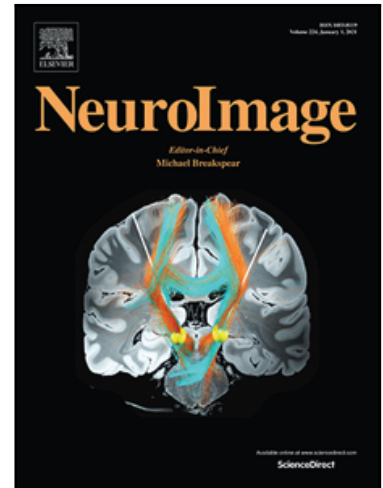

## Journal Pre-proof

### Analyzing Fractal Dimension in Electroconvulsive Therapy: Unraveling Complexity in Structural and Functional Neuroimaging

Niklaus Denier , Matthias Grieder , Kay Jann , Sigrid Breit ,  
Nicolas Mertse , Sebastian Walther , Leila M. Soravia ,  
Agnes Meyer , Andrea Federspiel , Roland Wiest , Tobias Bracht

PII: S1053-8119(24)00166-6  
DOI: <https://doi.org/10.1016/j.neuroimage.2024.120671>  
Reference: YNIMG 120671



To appear in: *NeuroImage*

Received date: 19 February 2024  
Revised date: 21 May 2024  
Accepted date: 6 June 2024

Please cite this article as: Niklaus Denier , Matthias Grieder , Kay Jann , Sigrid Breit ,  
Nicolas Mertse , Sebastian Walther , Leila M. Soravia , Agnes Meyer , Andrea Federspiel ,  
Roland Wiest , Tobias Bracht , Analyzing Fractal Dimension in Electroconvulsive Therapy:  
Unraveling Complexity in Structural and Functional Neuroimaging, *NeuroImage* (2024), doi:  
<https://doi.org/10.1016/j.neuroimage.2024.120671>

This is a PDF file of an article that has undergone enhancements after acceptance, such as the addition of a cover page and metadata, and formatting for readability, but it is not yet the definitive version of record. This version will undergo additional copyediting, typesetting and review before it is published in its final form, but we are providing this version to give early visibility of the article. Please note that, during the production process, errors may be discovered which could affect the content, and all legal disclaimers that apply to the journal pertain.

© 2024 Published by Elsevier Inc.  
This is an open access article under the CC BY-NC-ND license  
(<http://creativecommons.org/licenses/by-nc-nd/4.0/>)

## Highlights

- First study to use complexity measures to investigate ECT-effects
- Significant increase of Higuchi's fractal dimension (HFD) following ECT
- Right anterior hippocampal HFD was associated with reduction in depression severity
- Predictive value of temporal pole fractal dimension of cortical morphology (FD-CM)
- Complexity measures provide a novel complementary measure to investigate ECT

Journal Pre-proof

# Analyzing Fractal Dimension in Electroconvulsive Therapy: Unraveling Complexity in Structural and Functional Neuroimaging

Niklaus Denier <sup>1,2\*</sup>, Matthias Grieder <sup>1</sup>, Kay Jann <sup>3</sup>, Sigrid Breit <sup>1,2</sup>, Nicolas Mertse <sup>1,2</sup>, Sebastian Walther <sup>1,2</sup>, Leila M. Soravia <sup>1,2</sup>, Agnes Meyer <sup>1</sup>, Andrea Federspiel <sup>2,4</sup>, Roland Wiest <sup>2,4</sup>, Tobias Bracht <sup>1,2</sup>

1. Translational Research Center, University Hospital of Psychiatry and Psychotherapy, University of Bern, Bern, Switzerland
2. Translational Imaging Center (TIC), Swiss Institute for Translational and Entrepreneurial Medicine, Bern, Switzerland
3. USC Stevens Neuroimaging and Informatics Institute, Keck School of Medicine of USC, University of Southern California, Los Angeles, CA, United States
4. Institute of Diagnostic and Interventional Neuroradiology, University of Bern, Bern, Switzerland.

\* Corresponding author:

Niklaus Denier, MD  
University Hospital of Psychiatry and Psychotherapy  
University of Bern  
Switzerland  
[niklaus.denier@unibe.ch](mailto:niklaus.denier@unibe.ch)

Key words: electroconvulsive therapy, depression, neuroimaging, functional MRI, neuroplasticity, connectivity.

## Abstract

**Background:** Numerous studies show that electroconvulsive therapy (ECT) induces hippocampal neuroplasticity, but findings are inconsistent regarding its clinical relevance. This study aims to investigate ECT-induced plasticity of anterior and posterior hippocampi using mathematical complexity measures in neuroimaging, namely Higuchi's fractal dimension (HFD) for fMRI time series and the fractal dimension of cortical morphology (FD-CM). Furthermore, we explore the potential of these complexity measures to predict ECT treatment response.

**Methods:** Twenty patients with a current depressive episode (16 with major depressive disorder and 4 with bipolar disorder) underwent MRI-scans before and after an ECT-series. Twenty healthy controls matched for age and sex were also scanned twice for comparison purposes. Resting-state fMRI data were processed, and HFD was computed for anterior and posterior hippocampi. Group-by-time effects for HFD in anterior and posterior hippocampi were calculated and correlations between HFD changes and improvement in depression severity were examined. For FD-CM analyses, we preprocessed structural MRI with CAT12's surface-based methods. We explored group-by-time effects for FD-CM and the predictive value of baseline HFD and FD-CM for treatment outcome.

**Results:** Patients exhibited a significant increase in bilateral hippocampal HFD from baseline to follow-up scans. Right anterior hippocampal HFD increase was associated with reductions in depression severity. We found no group differences and group-by-time effects in FD-CM. After applying a whole-brain regression analysis, we found that baseline FD-CM in the left temporal pole predicted reduction of overall depression severity after ECT. Baseline hippocampal HFD did not predict treatment outcome.

**Conclusion:** This study suggests that HFD and FD-CM are promising imaging markers to investigate ECT-induced neuroplasticity associated with treatment response.

## Introduction

Depression is a highly prevalent mental disorder and globally the leading cause of disability (WHO, 2021). One-third of patients with depression remain resistant to treatment regimens with pharmacotherapy (Rush et al., 2006). More than 50% of these patients respond to treatment with electroconvulsive therapy (ECT) (Group, 2003; van Diermen et al., 2018). ECT-induced volume increase in limbic structures, including bilateral hippocampi and amygdalae, are well-documented findings observed in multiple studies (Bracht et al., 2023; Gryglewski et al., 2021; Nordanskog et al., 2010; Takamiya et al., 2018). Whilst some studies found associations between overall volume increase and clinical improvements (Joshi et al., 2016; Nordanskog et al., 2010), findings of a meta-analysis and a large mega-analysis, suggest that overall volume increase in the hippocampi is unrelated to treatment response (Gryglewski et al., 2021; Oltedal et al., 2018). Consequently, it was proposed that overall enlargements of the entire hippocampus might rather be a non-specific effect of ECT than the primary driver of treatment response. However, other findings suggest that clinical response may be related to structural and functional alterations in specific segments or subcompartments of the hippocampi (Bracht et al., 2023; Leaver et al., 2019; Leaver et al., 2021; Nuninga et al., 2020). Accordingly, it was hypothesized that changes in functional networks of these subcompartments distinguish ECT-responders from non-responders (Leaver et al., 2021). Furthermore, ECT-induced structural changes have not only been identified in the hippocampi but also in hippocampal connection pathways of extended networks related to anterior or posterior hippocampi (Kubicki et al., 2019), which were associated with a disruption of the hippocampus-default mode network (Denier et al., 2023; Gbyl et al., 2024). Thus, for further advancement, novel methods are required that complement and exceed the interpretation of measures that simply assess overall grey matter volume or structural and functional connectivity.

The incorporation of mathematical complexity analyses offer a transformative perspective on existing data, serving as a valuable complementary measure to conventional neuroimaging metrics. Fractal dimension (FD), originally introduced by the renowned mathematician Benoit Mandelbrot in 1967, represents a pivotal concept. It furnishes a quantitative measure of intricacy and self-similarity, opening new avenues for understanding complex neurological phenomena (Mandelbrot, 1967). Fractals are captivating geometric constructs known for their intricate detail and repeated patterns across various scales, maintaining a similar structure regardless of magnification levels (Kenneth, 1990; Mandelbrot and Mandelbrot, 1982). In contrast to traditional Euclidean geometry, which deals with shapes of integer dimensions (e.g., lines [1D], planes [2D], solids [3D]), Fractal Dimension (FD) expands this concept to embrace non-integer dimensions (e.g., dimension of  $1.\bar{3}$ ). This unique property makes FD also a valuable tool for quantifying the complexity and irregularity present in neuroscience measurements (Burns and Rajan, 2015; King et al., 2009). It allows to decipher and model intricate data, finding widespread utility in the analysis of cortical morphology within a clinical context (Meregalli et al., 2022), and also in studies involving patients with depression (Schmitgen et al., 2020; Schmitt et al., 2022). Traditionally, the assessment of FD in cortical morphology (FD-CM) relies on the box-counting method (Madan and Kensinger, 2016). However, more expedient approximation techniques exist, such as the reconstruction of spherical harmonics (Yotter et al., 2011b). Regional FD-CM represents a comprehensive gauge of gyrification, amalgamating data from folding frequency, sulcal depth, convolution of gyral shape, and cortical thickness into a singular metric. This composite measure has the potential to offer insights into dendrite complexity and synaptic density (Im et al., 2006), enriching our understanding of cortical intricacies.

Paralleling efforts in quantifying spatial fractals, Higuchi's Fractal Dimension (HFD) emerges as a powerful technique for quantifying the intricacy and self-similarity within one-dimensional data, such as time series (Higuchi, 1988; Liehr and Massopust, 2020). In contrast to other non-linear methods it is considered as highly accurate in estimating FD (Kesić and Spasić, 2016). HFD analysis has proven invaluable in unraveling the complexities and altered connectivity patterns within the brains of individuals affected by various neurological disorders including migraine and neurodegenerative diseases (Djuričić et al., 2023; Garehdaghi and Sarbaz, 2023; Porcaro et al., 2020; Porcaro et al., 2022; Varley et al., 2020). Surprisingly, while HFD has gained traction in exploring depressive disorders, primarily using ECG (George et al., 2023) and EEG data (Kaushik et al., 2023; Kawe et al., 2019; Lord and Allen, 2023), it has remained largely unexplored in the realm of neuropsychiatric disorders and functional MRI data. Transferring HFD to functional neuroimaging might present an opportunity to harness HFD's potential for gaining fresh insights into the landscape of these complex conditions. In the context of depression and ECT, the hippocampus in particular is interesting for further investigations with HFD. HFD has been proven effective in revealing the intricate temporal EEG patterns of hippocampal activity in rats (Spasic et al., 2011).

This is the first study that exploits HFD and FD-CM to explore ECT-induced neuroplasticity through the lens of complexity measurements. We applied these measures in a sample of 20 patients with depression who were scanned before and after an ECT-index series and in 20 healthy controls who were also scanned twice. It was the primary objective of this study to investigate whether ECT induces changes of functional MRI signal complexity in the anterior and posterior hippocampi as assessed with HFD. Secondary outcome measures were associations between changes in HFD and improvements in depression severity and the predictive value of baseline measures of FD-CM and HFD for treatment outcome. In essence, our study

sought to introduce FD metrics including FD-CM and HFD into the analysis of depression and ECT treatment, shedding new light on the phenomena of ECT induced neuroplasticity.

## Methods

### Participants

This same sample was used in previous analyses (Bracht et al., 2023; Denier et al., 2023). Baseline measurements of patients with major depressive disorder (MDD) or bipolar disorder (BD) and healthy controls (HC) were also included in larger samples investigating cross-sectional group differences (Bracht et al., 2022a; Bracht et al., 2022c; Denier et al., 2024; Mertse et al., 2022). We recruited 20 patients with a current depressive episode who were scheduled for an ECT-series at the University Hospital of Psychiatry and Psychotherapy Bern. Inclusion criteria were a diagnosis of MDD or BD according to the Diagnostic and Statistical Manual of Mental Disorders (DSM-5) by the American Psychiatric Association (APA, 2013) and age between 18-65 years. Patients with neurological disorders, substance use disorders, psychotic disorders, personality disorders, known claustrophobia, or other contraindications to undergo an MRI scan were excluded. We conducted diagnostic screening using the Mini International Neuropsychiatric Interview (MINI) (Sheehan et al., 1998) and the Structured Clinical Interview for DSM-IV Axis II (SCID-II) (Wittchen et al., 1997). The Edinburgh Handedness Inventory (Oldfield, 1971) was used to assess handedness. Depression severity was assessed using the 21-item Hamilton Rating Scale for Depression (HAM-D) (Hamilton, 1967). The depression rating scales were administered both before and after the ECT-index series on the day of the MRI scan. We also included 20 healthy controls (HC) who were matched with the patients regarding age and sex. HC underwent the same assessments. All subjects provided written informed consent, and the



study was approved by the local cantonal ethics committee (KEK-number: 2017-00731). For more details of the sample, see table 1.

### **ECT treatment**

The ECT-treatments, using a Thymatron IV system, were conducted in the anesthetic recovery room of the University Hospital in Bern, Switzerland. Most patients (n=17) received right unilateral stimulation as their primary treatment approach. However, among these 17 patients, five switched to bitemporal stimulation, and one patient switched to bifrontal stimulation during the ECT-index series. Additionally, two patients underwent an ECT-index series with bitemporal stimulation, while one patient received bifrontal stimulation. The decisions regarding the initial placement of electrodes and any subsequent switches during the ECT-index series were based on each patient's clinical presentation and progress. The titration-based method was employed to determine the initial seizure threshold and stimulus intensity. General anesthesia was administered using etomidate, and succinylcholine was utilized for muscle relaxation. The quality of the seizures was monitored using electroencephalogram (EEG) and electromyography (EMG) recordings. The ECT patients received an average of  $12.7 \pm 4.0$  ECT sessions between the MRI scans.

### **MRI acquisition**

Each participant underwent two MRI scans using a 3 Tesla MRI scanner (Magnetom Prisma, Siemens, Erlangen, Germany) with a 64-channel head and neck coil at the Swiss Institute for Translational and Entrepreneurial Medicine (SITEM) associated with the University Hospital of Bern. The ECT group was scanned before and after an ECT-index series, while the HC group was also scanned at two timepoints, with a similar duration between scans. For the acquisition of T1-weighted data, a bias-field corrected MP2RAGE sequence was employed. The following

parameters were used for the MP2RAGE acquisition: field of view (FOV) =  $256 \times 256$  mm<sup>2</sup>, matrix =  $256 \times 256$ , slices = 256, voxel resolution =  $1 \times 1 \times 1$  mm<sup>3</sup>, repetition time (TR)/echo time (TE) = 5000/2.98 ms, inversion time (TI) = 700 ms, and echo time 2 (T2) = 2500 ms. Resting-state functional MRI (rs-fMRI) was acquired using echo planar imaging (EPI) continuously for 8 minutes, with participants in an ‘eyes closed’ condition. The following parameters were used for the acquisition: 480 volumes with 48 slices per volume, FOV =  $230 \times 230$  mm<sup>2</sup>, matrix =  $94 \times 94$ , voxel resolution =  $2.4 \times 2.4 \times 2.4$  mm<sup>3</sup> isotropic, TR = 1000 ms, and TE = 30 ms.

### **Pre-processing of resting-state fMRI**

Rs-fMRI pre-processing was conducted using the CONN 21a toolbox (Whitfield-Gabrieli and Nieto-Castanon, 2012) and involved several procedures. First, the EPI volumes were realigned and co-registered to the MP2RAGE images. Segmentation and normalization to the MNI space were then performed, followed by smoothing with an FWHM kernel of  $8 \times 8 \times 8$  mm. In contrast to traditional analysis of low frequency fluctuations (0.01 – 0.1 Hz) no band-pass filter was applied to analyze the whole spectrum.

### **Calculation of Higuchi’s fractal dimension (HFD) in resting-state fMRI**

Higuchi introduced an algorithm to determine the FD of a time series by quantifying the intricacy of waveforms (Higuchi, 1988). We used Matlab R2023a (Mathworks, Natick, Massachusetts) and the `higuchi_fractal_dimension.m` script of the Complexity toolbox (<https://github.com/kayjann/complexity/tree/master>) and performed calculations on UBELIX (<http://www.id.unibe.ch/hpc>), the HPC cluster at the University of Bern.

The signal in each voxel  $x$  of rs-fMRI with  $N = 480$  time points is defined as a time sequence  $x(1), x(2), \dots, x(N)$ . From this time sequence, we calculated self-similar time sequences

$X_m^k: x(m), x(m+k), x(m+2k), \dots, x(m + \text{int}[\frac{N-m}{k}]k)$  for  $k \in \{1, \dots, k_{max}\}$  and  $m \in$

$\{1, \dots, k\}$ . Parameter  $k$  is the time interval and  $k_{max}$  is a free parameter which we defined as  $k_{max} = 5$ . The formula  $z = \text{int} \left[ \frac{N-m}{k} \right]$  is defined as the upper border of total in time intervals of a sequence with length  $k$  with  $\text{int}$  as the integer part of the fraction. For each time sequence  $X_m^k$  we computed the length  $L_m(k) = \frac{N-1}{zk^2} (\sum_{i=1}^z |x(m+ik) - x(m+(i-1)k)|)$ . The mean curve length for each time interval  $k = 1, \dots, k_{max}$  was calculated as  $L(k) = \frac{\sum_{m=1}^k L_m(k)}{k}$ . HFD is defined as the best fitting function the double logarithmic dataset  $\{\ln(L(k)), \ln(1/k)\}$ . See figure 1.

For computation of anterior and posterior hippocampi, we used the uncus apex as a standard for landmark-based segmentation of the bilateral hippocampi obtained by the Automatic Anatomical Labelling (AAL) atlas (Tzourio-Mazoyer et al., 2002) by defining a separation plane in standard MNI space of  $y = -21$  (Bracht et al., 2023; Poppenk et al., 2013). We extracted mean values of the anterior and posterior bilateral hippocampi for HFD using Matlab.

### Calculation of fractal dimension using structural imaging

We performed structural MRI data pre-processing of MP2RAGE images using the Computational Anatomy Toolbox (CAT12, <http://www.neuro.unijena.de/cat/>). We used standard fully automated pipelines for processing surface-based morphometry and reconstruction of the surface (Dahnke et al., 2013; Gaser et al., 2022). For measurement of FD-CM, CAT12 implemented an approach using spherical harmonic reconstructions (Yotter et al., 2011a; Yotter et al., 2011b). The surface shape of the brain was reconstructed multiple times by increasing bandwidth of frequency of spherical harmonic reconstructions. Local FD-CM was calculated by finding the slope of a double logarithmic plot regressing area versus dimension with pairs  $\{\ln(\text{surface area}), \ln(\text{scale of measurement})\}$ . Prior to the second-level analyses, local FD-CM information was re-parameterized into a standard coordinate system across all subjects and

smoothed with a recommended large Gaussian full width at half maximum kernel of 20 mm.

See figure 2.

## Statistical analyses

### Primary outcome measure

We used the Statistical Package for Social Sciences SPSS 29.0 (SPSS, Inc., Chicago, Illinois) to analyze HFD. We measured reliability of hippocampal HFD measurements within HC using Cronbach's  $\alpha$  and intraclass correlation coefficient (ICC) (Vaz et al., 2013). To investigate if time effects between the 2 MRI-scans differ between ECT-patients and HC, two separate repeated measures ANCOVAs with the independent variable group (ECT, HC), the within subject factors timepoint (baseline, follow-up) and hemisphere (left, right), the covariates age and sex and the dependent variables HFD (anterior and posterior hippocampus) were calculated. Significant group  $\times$  time effects were followed up using post hoc paired t-tests comparing HFD.

### Secondary outcome measures

To investigate if there are associations between HFD changes over time and clinical improvement (relative changes between baseline (bl) and follow-up (fu):  $\text{HAMD}_{\% \Delta} = \frac{\text{HAMD}_{bl} - \text{HAMD}_{fu}}{\text{HAMD}_{bl}} \times 100\%$ .) within patients, we calculated exploratory Spearman correlations.

To investigate the predictive value of baseline hippocampal HFD, we performed 4 separate regression analyses (anterior, posterior, left and right hippocampi), adjusting for age, sex and global HFD. P-values were Bonferroni corrected ( $\frac{p}{4}$ ).

To investigate longitudinal changes in FD-CM, we conducted a group-by time whole-brain analysis using a  $2 \times 2$  repeated measures ANCOVA flexible-factorial design in SPM12/CAT12. As covariates of no interest we defined total intracranial volume (TIV), age and sex. Inference

statistics were done with a peak-level threshold of  $p < 0.05$  and a Holm-Bonferroni correction of  $p < 0.05$ .

To determine the predictive value of baseline FD-CM for HAMD reduction during the ECT-series a whole-brain multiple regression analysis was performed using baseline measures of FD-CM, adjusting age, sex and total intracranial volume, as covariates of no interest. Multiple regression was performed using the cortical parcellations of the Destrieux (aparc.a2009s) atlas (Destrieux et al., 2010). Inference statistics were done with a peak-level threshold of  $p < 0.05$  and a Holm-Bonferroni correction of  $p < 0.05$ .

### **Additional exploratory analyses**

In addition, we performed exploratory analyses regarding group differences at baseline, associations between the complexity measures HFD, FD-CM, and conventional structural and functional neuroimaging measures, and the predictive value of FD-CM on hippocampal HFD-changes (see supplementary material).

## **Results**

### **Primary outcome measure**

All hippocampal HFD values within HC showed no change over time with a good Test–Retest reliability as measured by Cronbachs'  $\alpha$  and ICC (see table 2). Longitudinal analyses revealed significant group  $\times$  time interactions for anterior hippocampal HFD ( $F_{1,36} = 5.071$ ,  $p < 0.037$ ,  $\eta^2 = 0.123$ ) and posterior hippocampal HFD ( $F_{1,36} = 6.001$ ,  $p < 0.019$ ,  $\eta^2 = 0.143$ ). Follow up paired t-tests revealed significant increase of HFD values over time in the left anterior and bilateral posterior hippocampus within ECT patients (see table 3 and figure 3).

## Secondary outcome measures

Within patients, clinical improvement in HAMD correlated positively with HFD increase in the right anterior hippocampus ( $r = 0.49$ ,  $p = 0.03$ ;  $r = 0.45$ ,  $p = 0.07$  after removal of one case [+2,8 SD]), but not in other hippocampal structures (see figure 4).

There was no significant group-by-time effect that survived Holm-Bonferroni correction.

Within ECT patients higher baseline FD-CM in the left temporal pole predicted clinical improvement in the ECT group as assessed with reduction in total HAMD scores. See table 4 and figure 5. Baseline hippocampal HFD values did not predict clinical improvement in HAMD after Bonferroni correction (see table 5).

## Discussion

Our study aimed to investigate neuroplastic changes in patients with a current depressive episode undergoing ECT treatment by applying two complexity measurements of functional and structural MRI. This is the first study that investigates changes in HFD in a neuropsychiatric population using rs-fMRI. Through calculation of HFD, a functional metric of complexity, we demonstrated an ECT-induced increase in time-series complexity in bilateral hippocampi in patients. The increase in the right anterior hippocampus was positively associated with clinical improvement. In addition, by analyzing baseline FD-CM of structural data, we found that higher complexity of the left temporal pole was predictive for treatment response.

Our main finding was an ECT-induced increase in time-series complexity in bilateral anterior and left posterior hippocampi as assessed with HFD. Higher HFD post-ECT suggests increased complexity and irregularity in the blood-oxygen-level-dependent (BOLD) signal fluctuations, potentially indicating more intricate brain dynamics and communication across brain regions.

This could reflect diverse cognitive processes or task demands influencing the fractal properties of the brain's activity. Increase in the HFD in the right anterior hippocampus was associated with reductions in overall depression severity. Our results suggest a differential role of the anterior and the posterior hippocampi for treatment outcome and complement previous research separating these hippocampal compartments (Bracht et al., 2023; Leaver et al., 2019; Leaver et al., 2021). Our finding of an association between an increase of HFD in the right anterior hippocampus and clinical improvements fits the finding of (Leaver et al., 2021) who reported an ECT-induced volume increase in the right anterior hippocampus that was specific for ECT-treatment responders. However, Leaver et al. also reported that an increase in cerebral blood flow (CBF) in ECT-responders was located in the right middle and left posterior hippocampus (Leaver et al., 2021). Our previous analysis of this sample revealed an association between volume increase of the right posterior hippocampus and clinical improvement (Bracht et al., 2023). Thus, associations between volumetric and functional changes of hippocampal subcompartments and clinical response remain to be elucidated. In light of our previous finding of reduced functional connectivity between the hippocampus and the default mode network after ECT (Denier et al., 2023), the question arises as to how HFD and functional connectivity are related. Researchers have explored how the fractal dimension of brain activity, as measured by methods like HFD, relates to functional connectivity patterns within the brain (Varley et al., 2020). Higher HFD values might indicate more complex or organized dynamics in the brain's activity, which could potentially relate to different patterns of functional connectivity. Conversely, changes in functional connectivity patterns might also influence the HFD of brain activity. Overall, the relationship between functional connectivity and HFD is a topic of ongoing neuroscience research, aiming to understand the underlying principles governing the organization and dynamics of brain activity. However, by analyzing the connectivity strength of the hippocampus to the rest of the whole brain using the intrinsic connectivity (IC) we found neither

significant group differences nor changes over time in IC (see supplementary material S3 and table S1).

In addition to our finding of changes of HFD, we identified predictors of treatment outcome using FD-CM, a structural measure of complexity. Applying a multiple regression analysis of the whole brain, we found that higher FD-CM in the left temporal pole predicted clinical improvement following an ECT-index series. The identification of a structural measure located in the temporal pole makes sense because it is near the anterior hippocampus a region with connection pathways that have been linked to ECT-treatment response (Kubicki et al., 2019) and to structural grey matter remodeling in treatment responders (Leaver et al., 2021). In addition, volume reductions in the temporal pole have been reported in patients with MDD and BD (Neves et al., 2015; Webb et al., 2014). FD-CM is a measure of complexity that incorporates structural features such as gyrification, folding frequency, sulcal depth, convolution and gyral shape. Sulcal patterns are mainly determined before birth and stable across the lifespan (Cachia et al., 2016; Tissier et al., 2018), and are linked to cognition (Cachia et al., 2021). Thus, there may be strong impact on individual developmental processes related to genetics (Huang et al., 2023). If replicated in larger samples, FD-CM may contribute to distinguish ECT-treatment responders to non-responders in the future.

Our results provide further support for concepts that link hippocampal neuroplasticity to ECT treatment response. However, neuroimaging does not provide definite answers on the underlying neurobiological processes. Animal studies have demonstrated that seizures induced by electroconvulsive shocks are associated with enhanced hippocampal proliferation of neural stem-like cells, synapse formation, gliogenesis and angiogenesis (Chen et al., 2009; Hellsten et al., 2005; Newton et al., 2006; Olesen et al., 2017; Scott et al., 2000; Segi-Nishida et al., 2008;



Wennström et al., 2004). The exact mechanism through which ECT enhances neurogenesis is not fully understood, but it likely involves the stimulation of various neurotrophic factors (e.g. brain-derived neurotrophic factor (BDNF), endothelial growth factor (VEGF) and basic fibroblast growth factor) which are believed to modulate hippocampal circuitries (Bolwig, 2011; Newton et al., 2003; Ueno et al., 2019). Furthermore, hippocampal N-methyl d-aspartate (NDMA) receptor (NR2B subtype) expression, important in neuroplasticity, was found to be increased after ECT (Dong et al., 2010) and simultaneously linked with reduction of depression severity and disturbed spatial memory (Dong et al., 2010). Preclinical work also identified an increase in dendritic growth and increased synaptic density at excitatory synapses in the ventral CA1 of the hippocampus as the major contributor to the observed hippocampal volume increase following ECT (Abe et al., 2024b). (Abe et al., 2024a) In humans, in contrast to the well-studied and replicated volumetric changes in the hippocampus, findings regarding neurotrophic factors are still limited. One recent ECT-study has shown, that hippocampal volume increase is particularly associated with VEGF (Van Den Bossche et al., 2019). Furthermore, ECT-induced hippocampal volume increase may be related to the dose of ECT-sessions and to electrode placement. However, recent research suggests that these factors may not only be related to antidepressive response but also to cognitive side effects (Argyelan et al., 2021; Bracht et al., 2023; Joshi et al., 2016; Leaver et al., 2022; Subramanian et al., 2022).

Overall, the search for further hippocampal and temporal lobe metrics continues to be of interest, as classical morphology and connectivity analyses to date have not yielded a conclusive picture (Gryglewski et al., 2021; Oltedal et al., 2018). In our data, we used HFD, a measure of functional complexity that so far has not been applied to ECT-research. It is worth mentioning that identified HFD changes did not correlate with volumetric and cerebral blood flow (CBF)

increases after the ECT-index series (see supplementary material S2, figure S2 and S3). Therefore, HFD measurement could be regarded as a complementary assessment to conventional neuroimaging methods. This suggests that HFD-assessed functional complexity is independent from MRI-assessed volumetric and CBF measures. Furthermore, it supports assumptions that the neurobiology of treatment response is too complex to be simply attributed to volumetric measures. Further research is needed to understand what the HFD measure represents in rs-fMRI. The functional aspects of the hippocampus in ECT treatment are far from being fully understood. It has been proposed, that neuroplastic changes in the hippocampus and its interactions with other brain regions, such as the thalamocortical and cerebellar networks, may play a role in the antidepressant response to ECT (Leaver et al., 2021). In a previous study, we proposed that remodeling of structural and functional connectivity between the hippocampus and the self-referential default mode network may be associated with a reduction in rumination, a core feature of depression (Denier et al., 2023). Overall, it is likely that hippocampal communication behaviour is becoming more complex, which may be due to neurogenesis, synaptogenesis and dendritogenesis (Sartorius et al., 2022). This in turn may be associated with clinical improvements in depression pathophysiology, which is likely related to hippocampal pathology (Bracht et al., 2022b; Schmaal et al., 2016).

While to the best of our knowledge HFD has not been applied in rs-fMRI in mood disorders, researchers applied the Hurst Exponent (HE), another mathematical metric of complexity. By comparing HFD and HE, HFD focuses on the local self-similarity and roughness of a time series, and HE is more concerned with the long-range statistical dependence and self-similarity of data. They are used for different purposes and provide different insights into the structure and behaviour of time series data (Krakovská and Krakovská, 2016). By assessing temporal dynamic of brain activity HE of the ventromedial prefrontal cortex was positively associated

with rumination and mediated the association between rumination and depression (Gao et al., 2023). Using machine learning classification approaches the HE metric also helped to distinguish between major depression and healthy controls (Wei et al., 2013) and between remitted and current major depression (Jing et al., 2017). This highlights the potential of complexity measures for understanding the neurobiology of depression and remission plasticity.

Our study has certain limitations. Firstly, the sample size is modest and findings warrant replication in larger data sets (e.g. combining data with help of consortia (Oltedal et al., 2017)). Secondly, the population of depressed patients exhibits heterogeneity in terms of diagnoses, encompassing both MDD and BD, as well as variations in clinical characteristics such as the severity and duration of episode. However, this reflects clinical practice and therefore increases external validity. Thirdly, investigated measures of HFD and FD-CM are complex and do not allow for a straightforward neurobiological interpretation. Additional comprehensive research is imperative to deepen our understanding of the interplay between HFD and FD-CM and conventional metrics such as cortical thickness or functional connectivity, as well as their specific role in the reduction of depression symptomatology and well-known temporary impairment of memory functions after ECT. Furthermore, additional measurements, such as task-based fMRI or simultaneous EEG-fMRI recordings, may complement the understanding and interpretation of increased HFD complexity. Fourth and finally, HFD and FD-CM reveal only monofractal patterns in the brain. A monofractal process is characterized by a single dimension, which means that the complexity of a time series is the same across all scales. Future research may apply wavelet-based multifractal analysis to overcome limitations of capturing the full complexity of an fMRI time series, as already successfully applied in EEG, magnetoencephalography (MEG) and fMRI data (Ciuciu et al., 2017; La Rocca et al., 2018).

In conclusion, this study marks the pioneering exploration of HFD and FD-CM in the context of mood disorders and ECT. Our findings revealed a bilateral HFD increase in anterior and posterior hippocampi. Notably, the increase in HFD in the right anterior hippocampus was associated with clinical improvements. In addition, FD-CM measurements in the left temporal pole may be predictive for treatment response. Collectively, the utilization of complexity measurements such as HFD and FD-CM represent a novel and intriguing avenue for investigating neuropsychiatric disorders, particularly in patients undergoing ECT-treatment. Future studies with larger datasets are needed to further assess their predictive capabilities and associations with clinical improvements more comprehensively.

Journal Pre-proof

## **Acknowledgements**

This study received funding from the Robert Enke Foundation and the Novartis Foundation for medical biological research (to Tobias Bracht and Sebastian Walther) and the Swiss Life Foundation (to Tobias Bracht). Niklaus Denier and Tobias Bracht were both funded independently by a grant from the Adrian et Simone Frutiger Foundation.

## **Disclosures**

All authors report no biomedical financial interests or potential conflicts of interest.

Journal Pre-proof

## References

- Abe, Y., Erchinger, V.J., Ousdal, O.T., Oltedal, L., Tanaka, K.F., Takamiya, A., 2024a. Neurobiological mechanisms of electroconvulsive therapy for depression: Insights into hippocampal volumetric increases from clinical and preclinical studies. *J Neurochem*.
- Abe, Y., Yokoyama, K., Kato, T., Yagishita, S., Tanaka, K.F., Takamiya, A., 2024b. Neurogenesis-independent mechanisms of MRI-detectable hippocampal volume increase following electroconvulsive stimulation. *Neuropsychopharmacology*.
- APA, 2013. *Diagnostic and Statistical Manual of Mental Disorders (5th ed.; DSM-5; American Psychiatric Association [APA], 2013)*
- Argyelan, M., Lencz, T., Kang, S., Ali, S., Masi, P.J., Moyett, E., Joanlanne, A., Watson, P., Sanghani, S., Petrides, G., Malhotra, A.K., 2021. ECT-induced cognitive side effects are associated with hippocampal enlargement. *Transl Psychiatry* 11, 516.
- Bolwig, T.G., 2011. How does electroconvulsive therapy work? Theories on its mechanism. *Can J Psychiatry* 56, 13-18.
- Bracht, T., Denier, N., Wallimann, M., Walther, S., Mertse, N., Breit, S., Federspiel, A., Wiest, R., Soravia, L., 2022a. Hippocampal volume and parahippocampal cingulum alterations are associated with avoidant attachment in patients with depression. *Journal of Affective Disorders Reports* 10.
- Bracht, T., Denier, N., Wallimann, M., Walther, S., Mertse, N., Breit, S., Federspiel, A., Wiest, R., Soravia, L.M., 2022b. Hippocampal volume and parahippocampal cingulum alterations are associated with avoidant attachment in depression. *Journal of Affective Reports* 10.
- Bracht, T., Mertse, N., Walther, S., Ludi, K., Breit, S., Federspiel, A., Wiest, R., Denier, N., 2022c. Link between structural connectivity of the medial forebrain bundle, functional connectivity of the ventral tegmental area, and anhedonia in unipolar depression. *Neuroimage Clin* 34, 102961.
- Bracht, T., Walther, S., Breit, S., Mertse, N., Federspiel, A., Meyer, A., Soravia, L.M., Wiest, R., Denier, N., 2023. Distinct and shared patterns of brain plasticity during electroconvulsive therapy and treatment as usual in depression: an observational multimodal MRI-study. *Transl Psychiatry* 13, 6.
- Burns, T., Rajan, R., 2015. Combining complexity measures of EEG data: multiplying measures reveal previously hidden information. *F1000Res* 4, 137.
- Cachia, A., Borst, G., Jardri, R., Raznahan, A., Murray, G.K., Mangin, J.F., Plaze, M., 2021. Towards Deciphering the Fetal Foundation of Normal Cognition and Cognitive Symptoms From Sulcation of the Cortex. *Front Neuroanat* 15, 712862.
- Cachia, A., Borst, G., Tissier, C., Fisher, C., Plaze, M., Gay, O., Rivière, D., Gogtay, N., Giedd, J., Mangin, J.F., Houdé, O., Raznahan, A., 2016. Longitudinal stability of the folding pattern of the anterior cingulate cortex during development. *Dev Cogn Neurosci* 19, 122-127.

Chen, F., Madsen, T.M., Wegener, G., Nyengaard, J.R., 2009. Repeated electroconvulsive seizures increase the total number of synapses in adult male rat hippocampus. *European neuropsychopharmacology* 19, 329-338.

Ciuciu, P., Wendt, H., Combrexelle, S., Abry, P., 2017. Spatially regularized multifractal analysis for fMRI data. *Annu Int Conf IEEE Eng Med Biol Soc* 2017, 3769-3772.

Dahnke, R., Yotter, R.A., Gaser, C., 2013. Cortical thickness and central surface estimation. *NeuroImage* 65, 336-348.

Denier, N., Breit, S., Soravia, L.M., Mertse, N., Krone, L., Federspiel, A., Wiest, R., Bracht, T., 2024. Low sleep quality in major depressive disorder is associated with thinning and decreased functional connectivity of the insular cortex: Insular cortex and sleep quality in depression. *Journal of Affective Disorders Reports*.

Denier, N., Walther, S., Breit, S., Mertse, N., Federspiel, A., Meyer, A., Soravia, L.M., Wallimann, M., Wiest, R., Bracht, T., 2023. Electroconvulsive therapy induces remodeling of hippocampal co-activation with the default mode network in patients with depression. *Neuroimage Clin* 38, 103404.

Destrieux, C., Fischl, B., Dale, A., Halgren, E., 2010. Automatic parcellation of human cortical gyri and sulci using standard anatomical nomenclature. *NeuroImage* 53, 1-15.

Djuričić, G.J., Ahammer, H., Rajković, S., Kovač, J.D., Milošević, Z., Sopta, J.P., Radulovic, M., 2023. Directionally Sensitive Fractal Radiomics Compatible With Irregularly Shaped Magnetic Resonance Tumor Regions of Interest: Association With Osteosarcoma Chemoresistance. *J Magn Reson Imaging* 57, 248-258.

Dong, J., Min, S., Wei, K., Li, P., Cao, J., Li, Y., 2010. Effects of Electroconvulsive Therapy and Propofol on Spatial Memory and Glutamatergic System in Hippocampus of Depressed Rats. *The Journal of ECT* 26.

Gao, W., Biswal, B., Yang, J., Li, S., Wang, Y., Chen, S., Yuan, J., 2023. Temporal dynamic patterns of the ventromedial prefrontal cortex underlie the association between rumination and depression. *Cereb Cortex* 33, 969-982.

Garehdaghi, F., Sarbaz, Y., 2023. Analyzing global features of magnetic resonance images in widespread neurodegenerative diseases: new hope to understand brain mechanism and robust neurodegenerative disease diagnosis. *Med Biol Eng Comput* 61, 773-784.

Gaser, C., Dahnke, R., Thompson, P.M., Kurth, F., Luders, E., 2022. CAT-a computational anatomy toolbox for the analysis of structural MRI data. *BioRxiv*, 2022.2006. 2011.495736.

Gbyl, K., Labanaukas, V., Lundsgaard, C.C., Mathiassen, A., Ryszczuk, A., Siebner, H.R., Rostrup, E., Madsen, K., Videbech, P., 2024. Electroconvulsive therapy disrupts functional connectivity between hippocampus and posterior default mode network. *Progress in Neuro-Psychopharmacology and Biological Psychiatry*, 110981.

- George, S.V., Kunkels, Y.K., Smit, A., Wichers, M., Snippe, E., van Roon, A.M., Riese, H., 2023. Predicting recurrence of depression using cardiac complexity in individuals tapering antidepressants. *Transl Psychiatry* 13, 182.
- Group, U.E.R., 2003. Efficacy and safety of electroconvulsive therapy in depressive disorders: a systematic review and meta-analysis. *Lancet* 361, 799-808.
- Gryglewski, G., Lanzenberger, R., Silberbauer, L.R., Pacher, D., Kasper, S., Rupprecht, R., Frey, R., Baldinger-Melich, P., 2021. Meta-analysis of brain structural changes after electroconvulsive therapy in depression. *Brain Stimul* 14, 927-937.
- Hamilton, M., 1967. Development of a rating scale for primary depressive illness. *Br J Soc Clin Psychol* 6, 278-296.
- Hellsten, J., West, M.J., Arvidsson, A., Ekstrand, J., Jansson, L., Wennström, M., Tingström, A., 2005. Electroconvulsive seizures induce angiogenesis in adult rat hippocampus. *Biological psychiatry* 58, 871-878.
- Higuchi, T., 1988. Approach to an irregular time series on the basis of the fractal theory. *Physica D: Nonlinear Phenomena* 31, 277-283.
- Huang, Y., Zhang, T., Zhang, S., Zhang, W., Yang, L., Zhu, D., Liu, T., Jiang, X., Han, J., Guo, L., 2023. Genetic Influence on Gyral Peaks. *NeuroImage* 280, 120344.
- Im, K., Lee, J.M., Yoon, U., Shin, Y.W., Hong, S.B., Kim, I.Y., Kwon, J.S., Kim, S.I., 2006. Fractal dimension in human cortical surface: multiple regression analysis with cortical thickness, sulcal depth, and folding area. *Human Brain Mapping* 27, 994-1003.
- Jing, B., Long, Z., Liu, H., Yan, H., Dong, J., Mo, X., Li, D., Liu, C., Li, H., 2017. Identifying current and remitted major depressive disorder with the Hurst exponent: a comparative study on two automated anatomical labeling atlases. *Oncotarget* 8, 90452-90464.
- Joshi, S.H., Espinoza, R.T., Pirnia, T., Shi, J., Wang, Y., Ayers, B., Leaver, A., Woods, R.P., Narr, K.L., 2016. Structural Plasticity of the Hippocampus and Amygdala Induced by Electroconvulsive Therapy in Major Depression. *Biol Psychiatry* 79, 282-292.
- Kaushik, P., Yang, H., Roy, P.P., van Vugt, M., 2023. Comparing resting state and task-based EEG using machine learning to predict vulnerability to depression in a non-clinical population. *Sci Rep* 13, 7467.
- Kawe, T.N.J., Shadli, S.M., McNaughton, N., 2019. Higuchi's fractal dimension, but not frontal or posterior alpha asymmetry, predicts PID-5 anxiousness more than depressivity. *Sci Rep* 9, 19666.
- Kenneth, F., 1990. *Fractal Geometry: Mathematical Foundation & Applications*. John Wiley and sons.
- Kesić, S., Spasić, S.Z., 2016. Application of Higuchi's fractal dimension from basic to clinical neurophysiology: A review. *Comput Methods Programs Biomed* 133, 55-70.



King, R.D., George, A.T., Jeon, T., Hynan, L.S., Youn, T.S., Kennedy, D.N., Dickerson, B., 2009. Characterization of Atrophic Changes in the Cerebral Cortex Using Fractal Dimensional Analysis. *Brain Imaging Behav* 3, 154-166.

Krakovská, H., Krakovská, A., 2016. Fractal dimension of self-affine signals: four methods of estimation. *arXiv preprint arXiv:1611.06190*.

Kubicki, A., Leaver, A.M., Vasavada, M., Njau, S., Wade, B., Joshi, S.H., Loureiro, J., Hellemann, G., Woods, R.P., Espinoza, R., Narr, K.L., 2019. Variations in Hippocampal White Matter Diffusivity Differentiate Response to Electroconvulsive Therapy in Major Depression. *Biol Psychiatry Cogn Neurosci Neuroimaging* 4, 300-309.

La Rocca, D., Zilber, N., Abry, P., van Wassenhove, V., Ciuciu, P., 2018. Self-similarity and multifractality in human brain activity: A wavelet-based analysis of scale-free brain dynamics. *J Neurosci Methods* 309, 175-187.

Leaver, A.M., Espinoza, R., Wade, B., Narr, K.L., 2022. Parsing the Network Mechanisms of Electroconvulsive Therapy. *Biol Psychiatry* 92, 193-203.

Leaver, A.M., Vasavada, M., Joshi, S.H., Wade, B., Woods, R.P., Espinoza, R., Narr, K.L., 2019. Mechanisms of Antidepressant Response to Electroconvulsive Therapy Studied With Perfusion Magnetic Resonance Imaging. *Biol Psychiatry* 85, 466-476.

Leaver, A.M., Vasavada, M., Kubicki, A., Wade, B., Loureiro, J., Hellemann, G., Joshi, S.H., Woods, R.P., Espinoza, R., Narr, K.L., 2021. Hippocampal subregions and networks linked with antidepressant response to electroconvulsive therapy. *Mol Psychiatry* 26, 4288-4299.

Liehr, L., Massopust, P., 2020. On the mathematical validity of the Higuchi method. *Physica D: Nonlinear Phenomena* 402, 132265.

Lord, B., Allen, J.J.B., 2023. Evaluating EEG complexity metrics as biomarkers for depression. *Psychophysiology*, e14274.

Madan, C.R., Kensinger, E.A., 2016. Cortical complexity as a measure of age-related brain atrophy. *NeuroImage* 134, 617-629.

Mandelbrot, B., 1967. How long is the coast of Britain? Statistical self-similarity and fractional dimension. *science* 156, 636-638.

Mandelbrot, B.B., Mandelbrot, B.B., 1982. *The fractal geometry of nature*. WH freeman New York.

Meregalli, V., Alberti, F., Madan, C.R., Meneguzzo, P., Miola, A., Trevisan, N., Sambataro, F., Favaro, A., Collantoni, E., 2022. Cortical complexity estimation using fractal dimension: A systematic review of the literature on clinical and nonclinical samples. *Eur J Neurosci* 55, 1547-1583.

Mertse, N., Denier, N., Walther, S., Breit, S., Grosskurth, E., Federspiel, A., Wiest, R., Bracht, T., 2022. Associations between anterior cingulate thickness, cingulum bundle microstructure, melancholia and depression severity in unipolar depression. *J Affect Disord* 301, 437-444.

Neves, M.d.C.L., Albuquerque, M.R., Malloy-Diniz, L., Nicolato, R., Silva Neves, F., de Souza-Duran, F.L., Busatto, G., Corrêa, H., 2015. A voxel-based morphometry study of gray matter correlates of facial emotion recognition in bipolar disorder. *Psychiatry Research: Neuroimaging* 233, 158-164.

Newton, S.S., Collier, E.F., Hunsberger, J., Adams, D., Terwilliger, R., Selvanayagam, E., Duman, R.S., 2003. Gene profile of electroconvulsive seizures: induction of neurotrophic and angiogenic factors. *J Neurosci* 23, 10841-10851.

Newton, S.S., Girgenti, M.J., Collier, E.F., Duman, R.S., 2006. Electroconvulsive seizure increases adult hippocampal angiogenesis in rats. *European Journal of Neuroscience* 24, 819-828.

Nordanskog, P., Dahlstrand, U., Larsson, M.R., Larsson, E.M., Knutsson, L., Johanson, A., 2010. Increase in hippocampal volume after electroconvulsive therapy in patients with depression: a volumetric magnetic resonance imaging study. *J ECT* 26, 62-67.

Nuninga, J.O., Mandl, R.C.W., Boks, M.P., Bakker, S., Somers, M., Heringa, S.M., Nieuwdorp, W., Hoogduin, H., Kahn, R.S., Luijten, P., Sommer, I.E.C., 2020. Volume increase in the dentate gyrus after electroconvulsive therapy in depressed patients as measured with 7T. *Mol Psychiatry* 25, 1559-1568.

Oldfield, R.C., 1971. The assessment and analysis of handedness: the Edinburgh inventory. *Neuropsychologia* 9, 97-113.

Olesen, M.V., Wörtwein, G., Folke, J., Pakkenberg, B., 2017. Electroconvulsive stimulation results in long-term survival of newly generated hippocampal neurons in rats. *Hippocampus* 27, 52-60.

Oltedal, L., Bartsch, H., Sorhaug, O.J., Kessler, U., Abbott, C., Dols, A., Stek, M.L., Ersland, L., Emsell, L., van Eijndhoven, P., Argyelan, M., Tendolkar, I., Nordanskog, P., Hamilton, P., Jorgensen, M.B., Sommer, I.E., Heringa, S.M., Draganski, B., Redlich, R., Dannlowski, U., Kugel, H., Bouckaert, F., Sienaert, P., Anand, A., Espinoza, R., Narr, K.L., Holland, D., Dale, A.M., Oedegaard, K.J., 2017. The Global ECT-MRI Research Collaboration (GEMRIC): Establishing a multi-site investigation of the neural mechanisms underlying response to electroconvulsive therapy. *Neuroimage Clin* 14, 422-432.

Oltedal, L., Narr, K.L., Abbott, C., Anand, A., Argyelan, M., Bartsch, H., Dannlowski, U., Dols, A., van Eijndhoven, P., Emsell, L., Erchinger, V.J., Espinoza, R., Hahn, T., Hanson, L.G., Hellemann, G., Jorgensen, M.B., Kessler, U., Oudega, M.L., Paulson, O.B., Redlich, R., Sienaert, P., Stek, M.L., Tendolkar, I., Vandenbulcke, M., Oedegaard, K.J., Dale, A.M., 2018. Volume of the Human Hippocampus and Clinical Response Following Electroconvulsive Therapy. *Biol Psychiatry* 84, 574-581.

Poppenk, J., Evensmoen, H.R., Moscovitch, M., Nadel, L., 2013. Long-axis specialization of the human hippocampus. *Trends Cogn Sci* 17, 230-240.

Porcaro, C., Di Renzo, A., Tinelli, E., Di Lorenzo, G., Parisi, V., Caramia, F., Fiorelli, M., Di Piero, V., Pierelli, F., Coppola, G., 2020. Haemodynamic activity characterization of resting state networks by fractal analysis and thalamocortical morphofunctional integrity in chronic migraine. *J Headache Pain* 21, 112.

Porcaro, C., Di Renzo, A., Tinelli, E., Parisi, V., Di Lorenzo, C., Caramia, F., Fiorelli, M., Giuliani, G., Cioffi, E., Seri, S., Di Piero, V., Pierelli, F., Di Lorenzo, G., Coppola, G., 2022. A Hypothalamic

Mechanism Regulates the Duration of a Migraine Attack: Insights from Microstructural and Temporal Complexity of Cortical Functional Networks Analysis. *Int J Mol Sci* 23.

Rush, A.J., Trivedi, M.H., Wisniewski, S.R., Nierenberg, A.A., Stewart, J.W., Warden, D., Niederehe, G., Thase, M.E., Lavori, P.W., Lebowitz, B.D., McGrath, P.J., Rosenbaum, J.F., Sackeim, H.A., Kupfer, D.J., Luther, J., Fava, M., 2006. Acute and longer-term outcomes in depressed outpatients requiring one or several treatment steps: a STAR\*D report. *Am J Psychiatry* 163, 1905-1917.

Sartorius, A., Karl, S., Zilles-Wegner, D., 2022. Hippocampal neuroplasticity, major depression and, not to forget: ECT. *Mol Psychiatry*.

Schmaal, L., Veltman, D.J., van Erp, T.G., Samann, P.G., Frodl, T., Jahanshad, N., Loehrer, E., Tiemeier, H., Hofman, A., Niessen, W.J., Vernooij, M.W., Ikram, M.A., Wittfeld, K., Grabe, H.J., Block, A., Hegenscheid, K., Volzke, H., Hoehn, D., Czisch, M., Lagopoulos, J., Hatton, S.N., Hickie, I.B., Goya-Maldonado, R., Kramer, B., Gruber, O., Couvy-Duchesne, B., Renteria, M.E., Strike, L.T., Mills, N.T., de Zubicaray, G.I., McMahon, K.L., Medland, S.E., Martin, N.G., Gillespie, N.A., Wright, M.J., Hall, G.B., MacQueen, G.M., Frey, E.M., Carballo, A., van Velzen, L.S., van Tol, M.J., van der Wee, N.J., Veer, I.M., Walter, H., Schnell, K., Schramm, E., Normann, C., Schoepf, D., Konrad, C., Zurowski, B., Nickson, T., McIntosh, A.M., Pappmeyer, M., Whalley, H.C., Sussmann, J.E., Godlewska, B.R., Cowen, P.J., Fischer, F.H., Rose, M., Penninx, B.W., Thompson, P.M., Hibar, D.P., 2016. Subcortical brain alterations in major depressive disorder: findings from the ENIGMA Major Depressive Disorder working group. *Mol Psychiatry* 21, 806-812.

Schmitgen, M.M., Kubera, K.M., Depping, M.S., Nolte, H.M., Hirjak, D., Hofer, S., Hasenkamp, J.H., Seidl, U., Stieltjes, B., Maier-Hein, K.H., Sambataro, F., Sartorius, A., Thomann, P.A., Wolf, R.C., 2020. Exploring cortical predictors of clinical response to electroconvulsive therapy in major depression. *Eur Arch Psychiatry Clin Neurosci* 270, 253-261.

Schmitt, S., Meller, T., Stein, F., Brosch, K., Ringwald, K., Pfarr, J.-K., Bordin, C., Peusch, N., Steinsträter, O., Grotegerd, D., Dohm, K., Meinert, S., Förster, K., Redlich, R., Opel, N., Hahn, T., Jansen, A., Forstner, A.J., Streit, F., Witt, S.H., Rietschel, M., Müller-Myhsok, B., Nöthen, M.M., Dannlowski, U., Krug, A., Kircher, T., Nenadić, I., 2022. Effects of polygenic risk for major mental disorders and cross-disorder on cortical complexity. *Psychological Medicine* 52, 4127-4138.

Scott, B.W., Wojtowicz, J.M., Burnham, W.M., 2000. Neurogenesis in the dentate gyrus of the rat following electroconvulsive shock seizures. *Experimental neurology* 165, 231-236.

Segi-Nishida, E., Warner-Schmidt, J.L., Duman, R.S., 2008. Electroconvulsive seizure and VEGF increase the proliferation of neural stem-like cells in rat hippocampus. *Proceedings of the National Academy of Sciences* 105, 11352-11357.

Sheehan, D.V., Lecrubier, Y., Sheehan, K.H., Amorim, P., Janavs, J., Weiller, E., Hergueta, T., Baker, R., Dunbar, G.C., 1998. The Mini-International Neuropsychiatric Interview (M.I.N.I.): the development and validation of a structured diagnostic psychiatric interview for DSM-IV and ICD-10. *J Clin Psychiatry* 59 Suppl 20, 22-33;quiz 34-57.

Spasic, S., Kesic, S., Kalauzi, A., Saponjic, J., 2011. Different anesthesia in rat induces distinct inter-structure brain dynamic detected by Higuchi fractal dimension. *Fractals* 19, 113-123.

- Subramanian, S., Lopez, R., Zorumski, C.F., Cristancho, P., 2022. Electroconvulsive therapy in treatment resistant depression. *J Neurol Sci* 434, 120095.
- Takamiya, A., Chung, J.K., Liang, K.C., Graff-Guerrero, A., Mimura, M., Kishimoto, T., 2018. Effect of electroconvulsive therapy on hippocampal and amygdala volumes: systematic review and meta-analysis. *Br J Psychiatry* 212, 19-26.
- Tissier, C., Linzarini, A., Allaire-Duquette, G., Mevel, K., Poirel, N., Dollfus, S., Etard, O., Orliac, F., Peyrin, C., Charron, S., Raznahan, A., Houdé, O., Borst, G., Cachia, A., 2018. Sulcal Polymorphisms of the IFC and ACC Contribute to Inhibitory Control Variability in Children and Adults. *eNeuro* 5.
- Tzourio-Mazoyer, N., Landeau, B., Papathanassiou, D., Crivello, F., Etard, O., Delcroix, N., Mazoyer, B., Joliot, M., 2002. Automated Anatomical Labeling of Activations in SPM Using a Macroscopic Anatomical Parcellation of the MNI MRI Single-Subject Brain. *NeuroImage* 15, 273-289.
- Ueno, M., Sugimoto, M., Ohtsubo, K., Sakai, N., Endo, A., Shikano, K., Imoto, Y., Segi-Nishida, E., 2019. The effect of electroconvulsive seizure on survival, neuronal differentiation, and expression of the maturation marker in the adult mouse hippocampus. *J Neurochem* 149, 488-498.
- Van Den Bossche, M.J.A., Emsell, L., Dols, A., Vansteelandt, K., De Winter, F.L., Van den Stock, J., Sienaert, P., Stek, M.L., Bouckaert, F., Vandenbulcke, M., 2019. Hippocampal volume change following ECT is mediated by rs699947 in the promotor region of VEGF. *Transl Psychiatry* 9, 191.
- van Diermen, L., van den Ameele, S., Kamperman, A.M., Sabbe, B.C.G., Vermeulen, T., Schrijvers, D., Birkenhager, T.K., 2018. Prediction of Electroconvulsive Therapy Response and Remission in Major Depression: Meta-analysis - CORRIGENDUM. *Br J Psychiatry* 212, 322.
- Varley, T.F., Craig, M., Adapa, R., Finoia, P., Williams, G., Allanson, J., Pickard, J., Menon, D.K., Stamatakis, E.A., 2020. Fractal dimension of cortical functional connectivity networks & severity of disorders of consciousness. *PLoS One* 15, e0223812.
- Vaz, S., Falkmer, T., Passmore, A.E., Parsons, R., Andreou, P., 2013. The case for using the repeatability coefficient when calculating test-retest reliability. *PLoS One* 8, e73990.
- Webb, C.A., Weber, M., Mundy, E.A., Killgore, W.D.S., 2014. Reduced gray matter volume in the anterior cingulate, orbitofrontal cortex and thalamus as a function of mild depressive symptoms: a voxel-based morphometric analysis. *Psychological Medicine* 44, 2833-2843.
- Wei, M., Qin, J., Yan, R., Li, H., Yao, Z., Lu, Q., 2013. Identifying major depressive disorder using Hurst exponent of resting-state brain networks. *Psychiatry Res* 214, 306-312.
- Wennström, M., Hellsten, J., Tingström, A., 2004. Electroconvulsive seizures induce proliferation of NG2-expressing glial cells in adult rat amygdala. *Biological psychiatry* 55, 464-471.
- Whitfield-Gabrieli, S., Nieto-Castanon, A., 2012. Conn: a functional connectivity toolbox for correlated and anticorrelated brain networks. *Brain Connect* 2, 125-141.
- WHO, 2021. <https://www.who.int/news-room/fact-sheets/detail/depression>.

Wittchen, H.U., Zaudig, M., Fydrich, T., 1997. Strukturiertes klinisches Interview für DSM-IV. Hogrefe, Göttingen.

Yotter, R.A., Dahnke, R., Thompson, P.M., Gaser, C., 2011a. Topological correction of brain surface meshes using spherical harmonics. *Human Brain Mapping* 32, 1109-1124.

Yotter, R.A., Nenadic, I., Ziegler, G., Thompson, P.M., Gaser, C., 2011b. Local cortical surface complexity maps from spherical harmonic reconstructions. *NeuroImage* 56, 961-973.

Journal Pre-proof

## Table legends

**Table 1:** Clinical characteristics of groups. See Denier et al., 2023 (Denier et al., 2023).

	<b>ECT</b> <b>(n=20)</b>	<b>HC</b> <b>(n=20)</b>	<b>Analyzes</b>
<b>Age (years)</b>	44.9 ± 12	43.6 ± 14	p = 0.75
<b>Sex (female, male)</b>	8, 12	8, 12	p = 1.00
<b>Handedness</b> <b>(right, left, ambidextrous)</b>	15, 2, 3	17, 2, 1	p = 0.57
<b>HAMD-21 (Baseline)</b>	21.4 ± 5.3	0.65 ± 1.0	p < 0.001 **
<b>Duration of episode (months)</b>	19.8 ± 17	n/a	n/a
<b>Number of episodes</b>	5.2 ± 4	n/a	n/a
<b>Time between scans (days)</b>	52.6 ± 24	61.2 ± 17	p = 0.20
<b>HAMD-21 (Follow up)</b>	10.9 ± 8.1	0.25 ± 0.8	p < 0.001 **
<b>n (remitter<sup>1</sup>)</b>	9	n/a	n/a
<b>n (responder or remitter<sup>2</sup>)</b>	11	n/a	n/a
<b>n (non-responder)</b>	9	n/a	n/a

Demographic and clinical variables were compared between ECT and healthy controls using an independent t-tests and  $\chi^2$  tests. Abbreviations: ECT: electroconvulsive therapy; HC: healthy controls; 1 remitter: HAMD-21 < 8 points; 2 responder or remitter: HAMD-21 reduction > 50%; n/a: not applicable.

**Table 2:** Test-Retest reliability for hippocampal HFD in healthy controls

HFD	T1 mean (SD)	T2 mean (SD)	Cronbach's $\alpha$	ICC	$\Delta$ Mean	$\Delta$ SD
Ant. hippocampus left	1.928 (0.043)	1.935 (0.05)	0.844	0.732	0.0069	0.0344
Ant. hippocampus right	1.923 (0.046)	1.927 (0.054)	0.837	0.72	0.0041	0.0375
Post. hippocampus left	1.933 (0.037)	1.937 (0.05)	0.868	0.767	0.0045	0.03
Post. hippocampus right	1.927 (0.038)	1.933 (0.045)	0.825	0.702	0.0052	0.0321

HFD: Higuchi's fractal dimension; ICC: intraclass correlation coefficient; SD: standard deviation; T1: first MRI scan; T2: second MRI scan;  $\Delta$ : difference.

**Table 3:** Post hoc paired t-tests for anterior and posterior hippocampal HFD in baseline vs. follow-up.

<b>Hemisphere</b>	<b>ECT</b>	<b>HC</b>
<b>HFD of anterior hippocampus</b>		
<b>left</b>	$T_{19} = -2.240, p = 0.037$	$T_{19} = -0.895, p = 0.554$
<b>right</b>	$T_{19} = -1.617, p = 0.122$	$T_{19} = -0.495, p = 0.627$
<b>HFD of posterior hippocampus</b>		
<b>left</b>	$T_{19} = -2.166, p = 0.043$	$T_{19} = -0.667, p = 0.513$
<b>right</b>	$T_{19} = -2.303, p = 0.033$	$T_{19} = -0.724, p = 0.478$



**Table 4:** Significant association of clinical improvement ( $\% \Delta$  HAMD) and baseline FD-CM.

Direction	Region (aparc_a2009s)	Hemisphere	T-value	Holm-Bonfer- roni p-value
positive	temporal pole	Left	3.324	0.020
negative	none			

aparc.a2009s: Destrieux atlas.

Journal Pre-proof

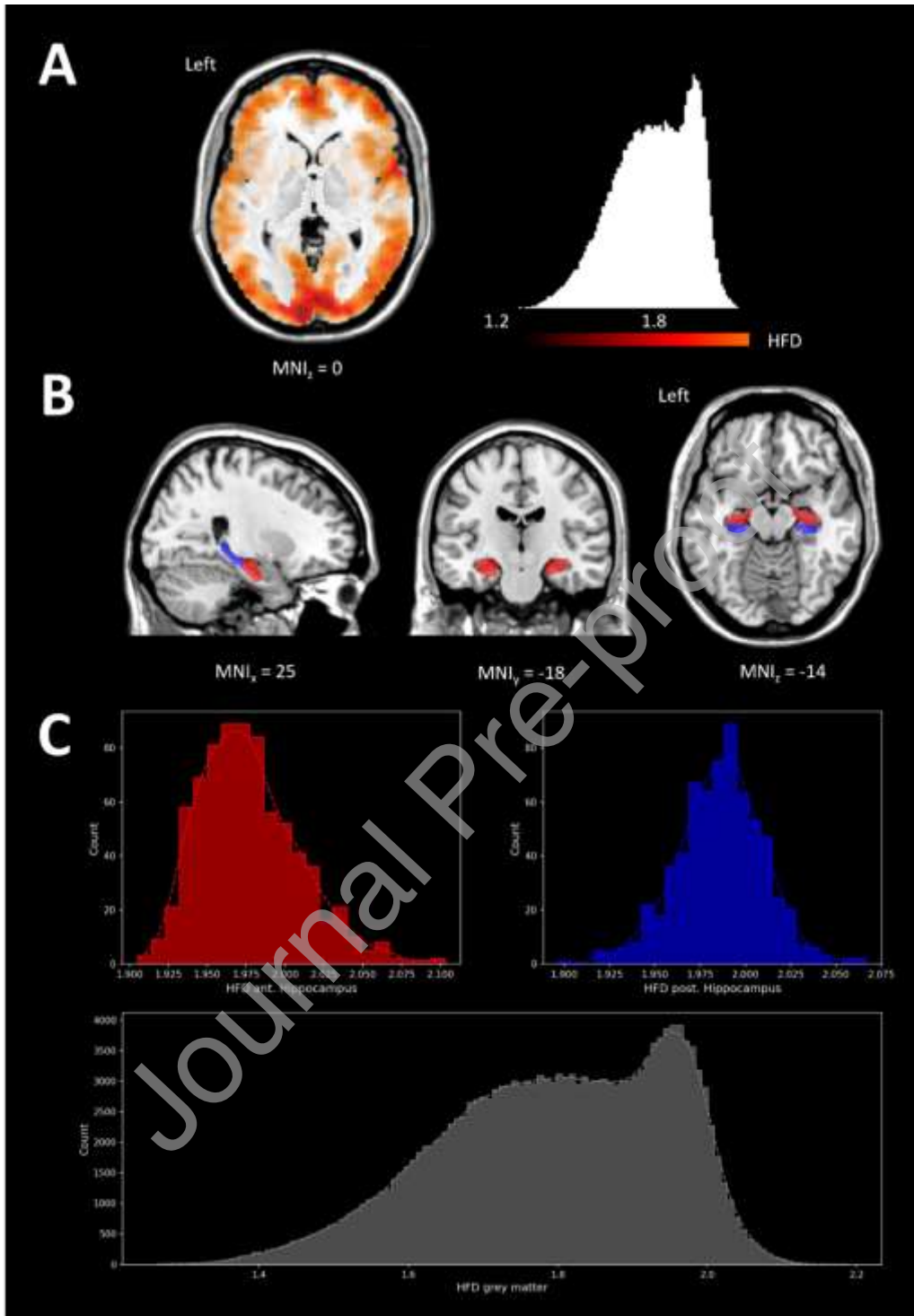
**Table 5:** Association of clinical improvement (% $\Delta$  HAMD) and baseline HFD.

Baseline HFD	T-value	p-value	Bonferroni correction $\frac{p}{4}$
Anterior hippocampus left	-1.805	0.091	0.364
Anterior hippocampus right	-2.305	0.036*	0.144
Posterior hippocampus left	-2.351	0.033*	0.132
Posterior hippocampus right	-1.339	0.201	0.804

\*p &lt; 0.05

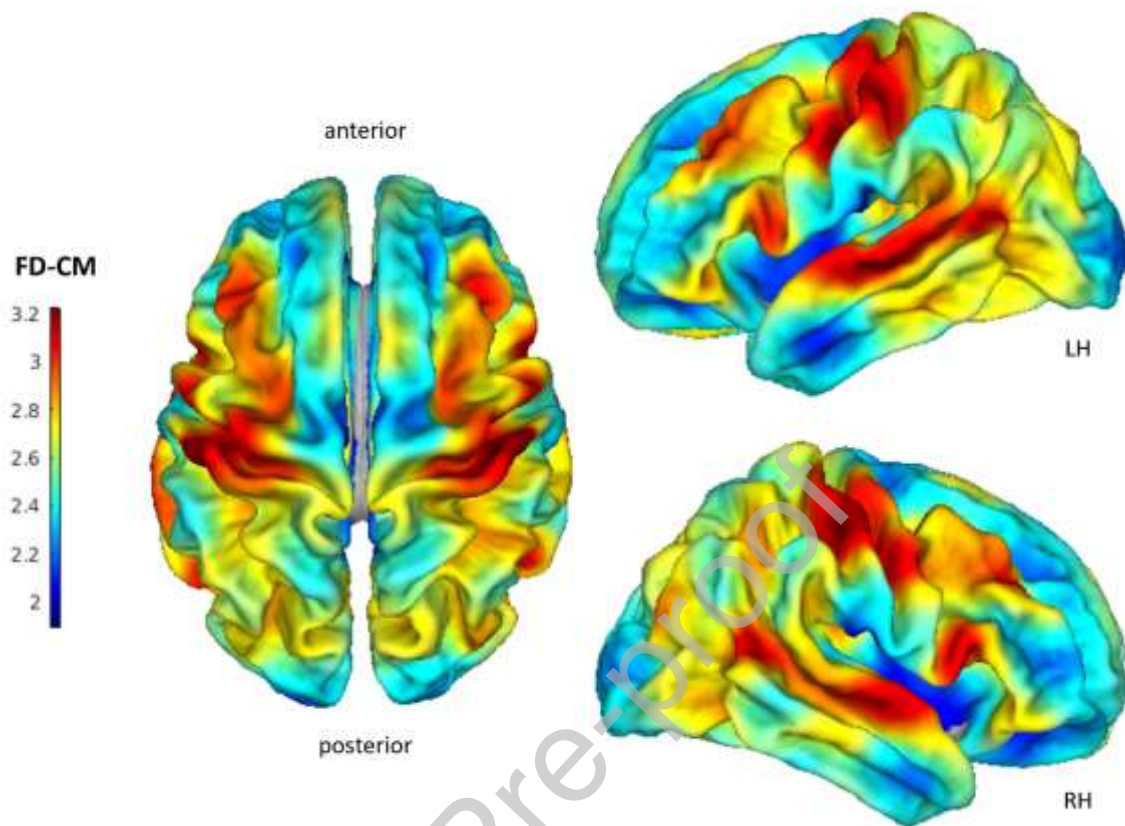
Journal Pre-proof

**Figure 1:** HFD distribution and visualization in a sample subject.

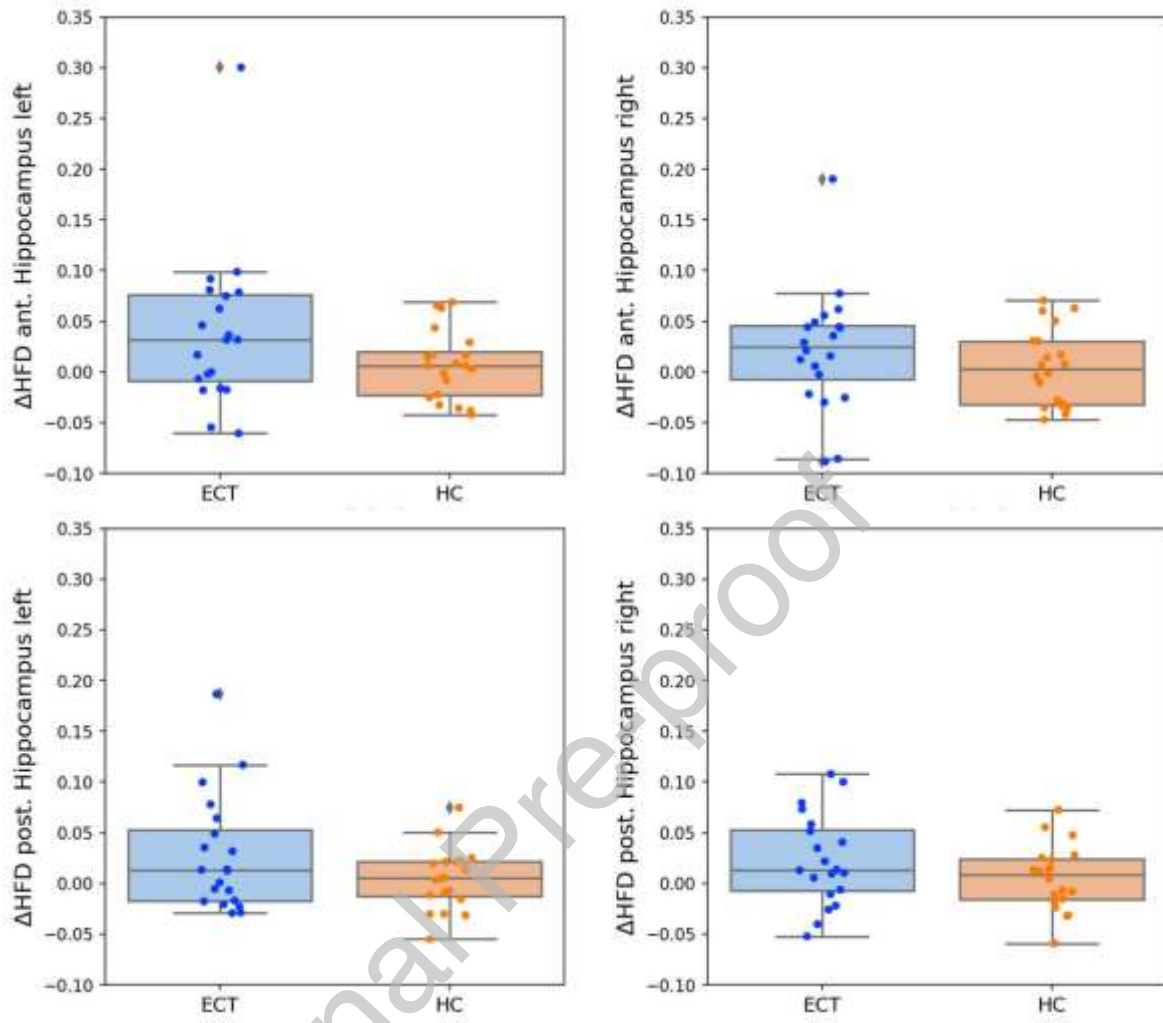


**A:** Color-coded HFD map of grey matter. **B:** Binary masks of anterior (red) and posterior (blue) parts of the hippocampi. **C:** HFD Histogram of total grey matter and anterior/posterior part of the hippocampi. L: left; MNI: Montreal Neurological Institute space.

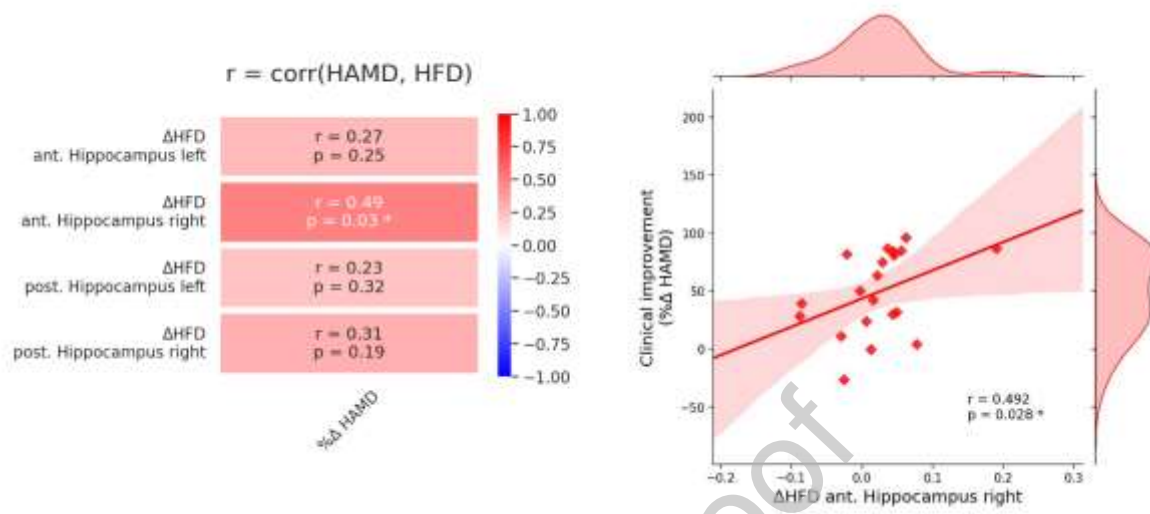
**Figure 2:** Overall mean of baseline FD-CM.



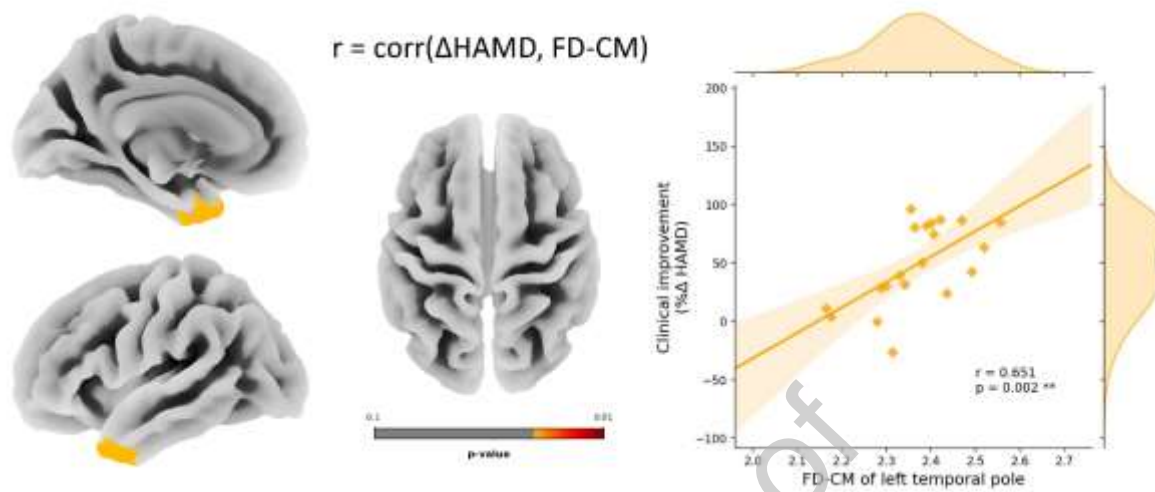
LH: left hemisphere; RH: right hemisphere.

**Figure 3:** Hippocampal group differences in HFD.

**Figure 4:** Positive association of clinical improvement and increase in HFD in the right anterior hippocampus.



**Figure 5:** Positive association of the baseline FD-CM of the temporal pole and clinical improvement.



### Data and Code Availability Statement

The data for this project are confidential. Researchers interested in access to the data or the analysis scripts may contact Niklaus Denier at [niklaus.denier@unibe.ch](mailto:niklaus.denier@unibe.ch).

### Declaration of Interest Statement

All authors report no biomedical financial interests or potential conflicts of interest.