

ISSLS 2024

[Jump to step: Preview ▾](#)

Please ensure that the information below is correct and is displayed correctly.

### **The Bone Morphogenetic Protein 2 Analogue L51P Enhances Spinal Fusion in Combination with BMP2 in an *In Vivo* Rat Tail Model (100468)**

**Benjamin Gantenbein**<sup>1,2</sup>, Katharina AC Oswald<sup>1,2</sup>, Georg F Ehrbach<sup>1</sup>, Andreas S Croft<sup>2</sup>, Paola Bermudez Lekerika<sup>2</sup>, Franziska Strunz<sup>2</sup>, Sebastian Bigdon<sup>1</sup>, Christoph Albers<sup>1</sup>

1. Department of Orthopedic Surgery & Traumatology, Inselspital, University of Bern, Bern, Switzerland

2. Department for BioMedical Research (DBMR), University of Bern, Bern, Switzerland

#### INTRODUCTION

Non-union and pseudoarthrosis remain major complications after spinal fusion surgery, resulting in unsatisfactory outcomes and high socio-economic costs [1,2]. Several biomaterials and osteobiologics have improved spinal fusion, including bone morphogenetic protein (BMP) 2. However, its necessary high-dose application often leads to adverse effects. L51P, a BMP-2 analogue and inhibitor of BMP antagonists, has been shown to augment BMP-induced bone formation and lower the required doses. The current study, therefore, aimed to demonstrate the effects of L51P and BMP-2 on spinal fusion *in vivo*.

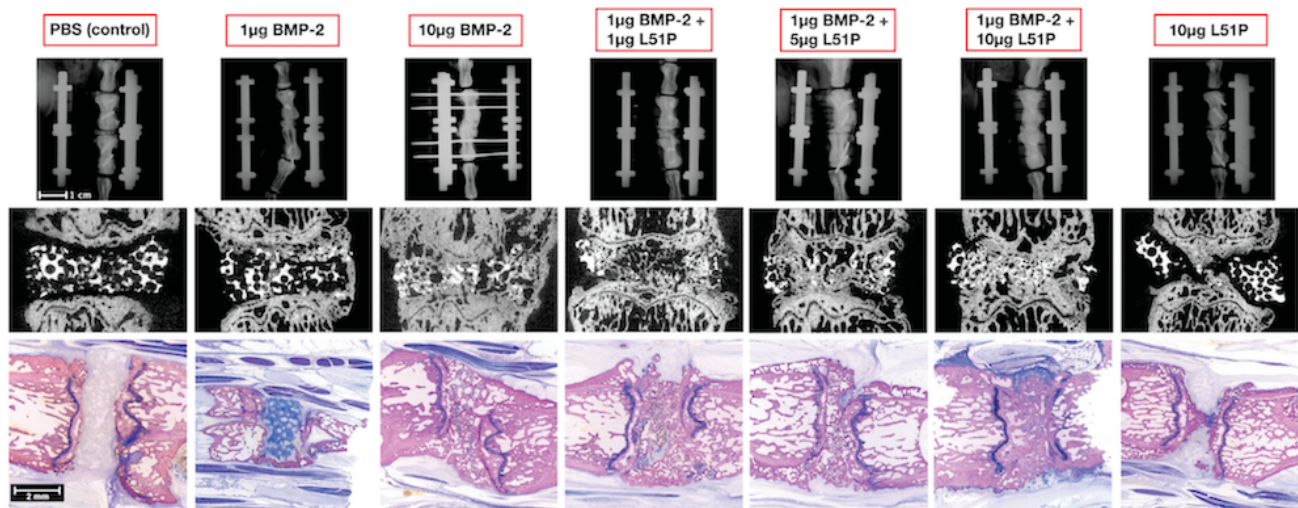
#### METHODS

46 elderly Wistar rats (~12 months, 52% female, 423±78g) underwent a two-step spinal fusion surgery [3,4]. Firstly, a custom external fixator was applied in the proximal tail. Secondly, discectomy and disc replacement with a  $\beta$  tri-calcium-phosphate ( $\beta$ -TCP) carrier were conducted. Carriers were loaded with the study compounds based on random and blinded allocation into seven groups: g Digital X-rays were performed on day zero, at six weeks, and twelve weeks postoperatively. After twelve weeks, high-resolution  $\mu$ CT scans and histology were obtained.

#### RESULTS

At twelve weeks, 10  $\mu$ g BMP-2, 1  $\mu$ g BMP-2 + 5  $\mu$ g L51P and 1  $\mu$ g BMP-2 + 10  $\mu$ g L51P showed significantly higher fusion rates compared to the PBS control in X-ray analysis.  $\mu$ CT analysis showed significantly higher fusion rates for all groups than the control group. 1  $\mu$ g BMP-2 + 1  $\mu$ g L51P demonstrated significantly higher fusion rates than 1  $\mu$ g BMP2 alone and equivalent ossification

ISSLS 2024  
 compared to 10  $\mu$ g BMP-2; higher doses of L51P did not lead to a better fusion outcome. Histological analysis confirmed the radiographical results. Figure 1 provides representative images of the seven experimental groups for each investigated read-outs, i.e., 2D X-rays,  $\mu$ CT and histology.



**Figure 1.** Overview of the results of the proximal tail region of coccygeal spinal fusion model of elderly Wistar rats twelve weeks post-operatively, showing one representative image per 2D X-ray, apical position (Faxitron), b) Mid-sagittal plane section of  $\mu$ CT images, in white colour remaining  $\beta$ TCP carrier, in grey colour bone c) histology of PMMA-embedded thick sections ( $\sim$ 200  $\mu$ m).

## DISCUSSION

Combining low doses of L51P and BMP-2 enhances spinal fusion equivalent to high-dose BMP-2 and may reduce BMP-2 doses and side effects at similar to higher efficacy in clinical application. Our study is the first to confirm that mixtures of BMP2 and L51P are highly efficient in reducing the doses of BMP2 in a spinal fusion model. Our results align with previous results reported in rats and mice and in long bone fracture models [5-7].

1. Martin BI, Mirza SK, Comstock BA, Gray DT, Kreuter W, Deyo RA (2007) Reoperation rates following lumbar spine surgery and the influence of spinal fusion procedures. *Spine* 32(3):382-387 <https://doi.org/10.1097/01.brs.0000254104.55716.46>
2. Wieser S, Horisberger B, Schmidhauser S, Eisenring C, Brügger U, Ruckstuhl A, Dietrich J, Mannion AF, Elfering A, Tamcan O, Müller U (2011) Cost of low back pain in Switzerland in 2005. *Eur J Health Econ* 12(5):455-467 <https://doi.org/10.1007/s10198-010-0258-y>
3. Oswald KAC, Bigdon SF, Croft AS, Bermudez-Lekerika P, Bergadano A, Gantenbein B, Albers CE (2021) Establishment of a Novel Method for Spinal Discectomy Surgery in Elderly Rats in an In Vivo Spinal Fusion Model. *Meth & Prot* 4(4): <https://doi.org/10.3390/mps4040079>
4. Quinn R (2005) Comparing rat's to human's age: how old is my rat in people years? *Nutrition* 21(6):775-777 <https://doi.org/10.1016/j.nut.2005.04.002>
5. Khattab HM, Ono M, Sonoyama W, Oida Y, Shinkawa S, Yoshioka Y, Maekawa K, Tabata Y, Sugama K, Sebald W, Kuboki T (2014) The BMP2 antagonist inhibitor L51P enhances the osteogenic potential of BMP2 by simultaneous and delayed synergism. *Bone* 69: 165-173 <https://doi.org/10.1016/j.bone.2014.09.011>
6. Albers CE, Hofstetter W, Sebald HJ, Sebald W, Siebenrock KA, Klenke FM (2012) L51P - A BMP2 variant with osteoinductive activity via inhibition of Noggin. *Bone* 51(3):401-406 <https://doi.org/10.1016/j.bone.2012.06.020>

7. Hauser M, Siegrist M, Denzer A, Saulacic N, Grosjean J, Bohner M, Hofstetter W (2018)  
Bisphosphonates reduce biomaterial turnover in healing of critical-size rat femoral defects. J  
Orthop Surg (Hong Kong) 26(3):2309499018802487. <https://doi.org/10.1177/2309499018802487>