

ORIGINAL ARTICLE

Combined portal and hepatic vein embolisation in perihilar cholangiocarcinoma

Jens Smits^{1,2}, Steven Chau¹, Sinéad James^{1,2}, Remon Korenblik^{1,2}, Madita Tschögl³, Pieter Arntz⁴, Jan Bednarsch⁵, Luis Abreu de Carvalho⁶, Olivier Detry⁷, Joris Erdmann⁴, Thomas Gruenberger³, Laurens Hermie⁸, Ulf Neumann⁹, Per Sandström¹⁰, Robert Sutcliffe¹¹, Alban Denys¹², Emmanuel Melloul¹³, Maxime Dewulf¹, Christiaan van der Leij^{2,14}, Ronald M. van Dam^{1,2,5} for the EuroLVD and DRAGON Trials Collaborative^a

¹Department of Surgery, Maastricht University Medical Centre, P. Debyelaan 25, 6229, HX, ²GROW – School for Oncology and Reproduction, Maastricht University, Universiteitssingel 40, 6229, ER, Maastricht, The Netherlands, ³Department of Surgery, HPB Centre Vienna Health Network, Clinic Favoriten, Wienerbergstraße 13, 1100, Vienna, Austria, ⁴Department of Surgery, Amsterdam University Medical Centre Location AMC, Meibergdreef 9, 1105, AZ, Amsterdam, The Netherlands, ⁵Department of General, Visceral and Transplant Surgery, University Hospital Aachen, Pauwelsstraße 30, 52074 Aachen, Germany, ⁶Department of HPB Surgery and Liver Transplantation, Ghent University Hospital, Corneel Heymanslaan 10, 9000, Ghent, ⁷Department of Abdominal Surgery and Transplantation, CHU Liege, University of Liege, Avenue de l'Hôpital 1, 4000, Liège, ⁸Department of Vascular and Interventional Radiology, Ghent University Hospital, Corneel Heymanslaan 10, 9000, Ghent, Belgium, ⁹Department of General, Visceral and Transplantation Surgery, Essen University Hospital, Hufelandstraße 55, 45147, Essen, Germany, ¹⁰Department of Surgery in Linköping and Biomedical and Clinical Sciences, Linköping University, Universitetssjukhuset, 581 85 Linköping, Sweden, ¹¹Department of Surgery, Queen Elizabeth Hospital Birmingham NHS, Mindelsohn Way, Birmingham, B15 2GW, United Kingdom, ¹²Department of Radiology and Interventional Radiology, CHUV University of Lausanne, ¹³Department of Visceral Surgery, Lausanne University Hospital and University of Lausanne, CHUV, Rue du Bugnon 46, 1011, Lausanne, Switzerland, and ¹⁴Department of Radiology and Nuclear Medicine, Maastricht University Medical Centre, P. Debyelaan 25, 6229, HX, Maastricht, The Netherlands

Abstract

Background: Major hepatectomy in perihilar cholangiocarcinoma (pCCA) patients with a small future liver remnant (FLR) risks posthepatectomy liver failure (PHLF). This study examines combined portal and hepatic vein embolisation (PVE/HVE) to increase preoperative FLR volume and potentially decrease PHLF rates.

Methods: In this retrospective, multicentre, observational study, data was collected from centres affiliated with the DRAGON Trials Collaborative and the EuroLVD registry. The study included pCCA patients who underwent PVE/HVE between July 2016 and January 2023.

Results: Following PVE/HVE, 28% of patients (9/32) experienced complications, with 22% (7/32) necessitating biliary interventions for cholangitis. The median degree of hypertrophy after a median of 16 days was 16% with a kinetic growth rate of 6.8% per week. 69% of patients (22/32) ultimately underwent surgical resection. Cholangitis after PVE/HVE was associated with unresectability. After resection, 55% of patients (12/22) experienced complications, of which 23% (5/22) were Clavien-Dindo grade III or higher. The 90-day mortality after resection was 0%.

Conclusion: PVE/HVE quickly enhances the kinetic growth rate in pCCA patients. Cholangitis impairs chances on resection significantly. Resection after PVE/HVE is associated with low levels of 90-day mortality. The study highlights the potential of PVE/HVE in improving safety and outcomes in pCCA undergoing resection.

Received 29 April 2024; revised 21 June 2024; accepted 11 July 2024

Correspondence

Ronald M. van Dam, Department of Surgery, Maastricht University Medical Centre, P. Debyelaan 25, 6229 HX Maastricht, the Netherlands; GROW – School for Oncology and Reproduction, Maastricht University, Universiteitssingel 40, 6229 ER Maastricht, the Netherlands. E-mail: r.van.dam@mumc.nl (R.M. van Dam)

Correspondence

Maxime Dewulf, Department of Surgery, Maastricht University Medical Centre, P. Debyelaan 25, 6229 HX Maastricht, the Netherlands. E-mail: maxime.dewulf@mumc.nl (M. Dewulf)

^a The members of the the EuroLVD group and DRAGON Collaborative Group collaborators are listed at the Acknowledgments section.

Introduction

Perihilar cholangiocarcinoma (pCCA), or Klatskin tumour, constitute 10–25% of all hepatobiliary malignancies and its global incidence is increasing worldwide.¹ Currently, surgical resection is the sole treatment for potential long-term survival, illustrated by a 28–46% five-year overall survival rate (OS) after surgery.^{2,3} In contrast, patients receiving only palliative systemic treatment have a median OS of 11.5–12.8 months.^{4,5}

Nevertheless, resection rates in pCCA remain low and are highly dependent on the hospital of diagnosis.⁶ Postoperative mortality within 90 days is reported to be between 10 and 17%, mainly due to posthepatectomy liver failure (PHLF).^{1,7} This risk for PHLF is especially more pronounced in those with a small future liver remnant (FLR), which is often the case in pCCA patients. Furthermore, pCCA patients are often complicated with cholangitis, which in combination with FLR volumes below 30% is associated with higher rates of PHLF.^{8,9}

Portal vein embolisation (PVE), the current standard in preoperative liver hypertrophy-inducing techniques, demonstrates efficacy in reducing PHLF and overall postoperative morbidity in pCCA patients.^{10,11} Recent retrospective studies revealed encouraging outcomes in FLR hypertrophy and resection rates in patients with colorectal liver metastases and primary liver cancer treated with combined portal vein and hepatic vein embolisation (PVE/HVE), as compared to PVE alone.¹² However, data on PVE/HVE in pCCA patients, who present specific preoperative challenges, is limited.^{13,14} Histological examinations after PVE/HVE have revealed higher levels of necrosis compared to PVE alone.¹⁵ Therefore, the implementation of this novel technique in pCCA patients requires caution, as an exacerbation of cholangitis, a need for further biliary interventions, and a declining performance status could potentially exclude them from surgery.

This study aims to assess the safety and feasibility of PVE/HVE in pCCA patients, addressing a critical gap in existing literature and rapidly evolving clinical practice.

Methods

Study design

In this retrospective, multicentre, observational study, we collected data from specialised hepatopancreaticobiliary centres affiliated with the EuroLVD registry and the DRAGON Trials Collaborative. The DRAGON Trials Collaborative, coordinated at Maastricht University, is an international group of centres with the collective aim to investigate and safely implement PVE/HVE as a hypertrophy-inducing procedure before major hepatectomy. The EuroLVD registry, initiated at Lausanne University Hospital, is a multicentric research collaborative endorsed by the European-African Hepato-Pancreato-Biliary Association (E-AHPBA) with a similar objective. Ethical approval for retrospective analysis of the online PVE/HVE registry of the DRAGON Trials Collaborative was granted by the medical ethics review committee of University

Hospital of Maastricht (azM) and Maastricht University (METC2021-2578). All centres involved in the DRAGON Trials Collaborative and EuroLVD registry obtained ethical approval and patient consent for retrospective data analysis, as required by national legal and regulatory requirements. Data are reported according to the STROBE reporting guidelines for cohort studies.¹⁶

Participants

All patients diagnosed with perihilar cholangiocarcinoma (pCCA) who underwent combined portal and hepatic vein embolisation (PVE/HVE) prior to resection between July 2016 and January 2023 and who were registered in the DRAGON Trials Collaborative or EuroLVD registry, were considered eligible for inclusion. Patients receiving hepatic vein embolisation (HVE) in a sequential session were excluded from this analysis. Patients were deemed eligible for resection if the FLR was considered sufficient by the respective centre. Additional data collection entailed evaluation of electronic patient records, multidisciplinary tumour board reports, laboratory and pathology values, surgery logs, and interventional radiology records. Each centre conducted the data collection process independently and actively updated the registry with all patients undergoing PVE/HVE up to January 2023. For this study, database-lock occurred on April 1st, 2023.

Outcomes and definitions

The primary endpoint of this study was overall safety of PVE/HVE, assessed through postprocedural complications. Secondary endpoints focused on specifics of the PVE/HVE procedure, liver hypertrophy measurements, resection rates and perioperative outcomes. Complications were reported using the Clavien-Dindo (CD) classification.¹⁷ Standardised FLR (sFLR) was calculated based on the Vauthey calculation, which adjusts FLR for body surface area and is expressed in percentage (%).¹⁸ Change in sFLR was expressed as degree of hypertrophy (DH), percent-change of FLR (%hypertrophy), and kinetic growth rate (KGR). DH was defined as the difference between pre-PVE/HVE FLR volume (sFLR1) and post-PVE/HVE FLR volume (sFLR2) ($DH = sFLR2 - sFLR1$). KGR was defined as DH divided by the number of weeks after intervention.¹⁹ Percent-change of FLR (%hypertrophy) was calculated by dividing DH by sFLR1 in percentage. Perioperative outcomes included duration of surgery, type of resection, estimated blood loss, R-status, 90-day postoperative complications according to Clavien-Dindo classification, PHLF according to the International Study Group of Liver Surgery (ISGLS) criteria and 90-day postoperative mortality.^{17,20–22}

Data acquisition and management

Data from each centre were collected using the Castor Electronic Data Capture (EDC) system (Castor EDC, Amsterdam, The Netherlands). Liver volumetry was performed using Syngo.via (Siemens Healthineers, Erlangen, Germany), Synapse 3D

(Fujifilm, Tokyo, Japan) and IntelliSpace Portal (Phillips, Amsterdam, The Netherlands) software. Volumetrics were carried out independently by each centre and the choice of software was at their discretion.

Statistical analysis

Continuous variables were reported as median and interquartile range (IQR), categorical variables were presented as numbers and percentages. Data on overall survival were estimated using the Kaplan–Meier method using IBM SPSS Statistics 27 (IBM Corp., Armonk, NY, USA). Graphs were generated using Python (Python Software Foundation).

Results

Recruitment and baseline characteristics

Thirty-two patients were included in this analysis, with 22 recruited from the DRAGON registry and an additional 10 from the EuroLVD registry. Patient demographics, tumour characteristics and biochemical values before PVE/HVE are detailed in Table 1. Most patients (20/32–63%) were classified as Bismuth type III or IV pCCA, with a median serum bilirubin of 56 $\mu\text{mol/L}$ and C-reactive protein of 11 mg/L at time of embolisation. Biliary drainage was performed in 81% of cases (26/32) by means of endoscopic retrograde biliary drainage (ERBD) or percutaneous transhepatic biliary drainage (PTBD), additional details regarding biliary drainage are listed in Supplementary Table 1.

Primary safety outcome

Postembolisation complications were observed in 28% of patients (9/32), with 22% of patients (7/32) having a severe complication ($\text{CD} \geq 3$) between embolisation and the decision to resect. All severe complications were specifically related to cholangitis and required biliary reintervention. One patient (1/32–3%) passed away due to biliary sepsis 14 days after embolisation. Of the remaining eight patients with adverse outcomes after PVE/HVE, six could not proceed to resection, mainly due to persistent cholangitis in five patients, four of whom also developed tumour progression. Details of the embolisation outcomes are summarised in Table 2.

Embolisation and volumetric response

All patients underwent single-session embolisation of both portal and hepatic veins. PVE was mainly performed with an ipsilateral transhepatic approach (31/32–97%) with glue (NBCA + lipiodol) as embolic agent (27/32–84%). For HVE, a transhepatic approach was applied in 19% of cases (6/32) and vascular plug(s) as the only embolic agent in 38% (12/37). Details regarding embolisation technique are listed in Supplementary Table 2. The median baseline FLR volume was 437 ml (IQR 339–572 ml), with a median sFLR of 29% (IQR 25–35%). After a median of 16 days (IQR 8–22 days), subsequent volumetry indicated a DH of 16% in sFLR (IQR 9–24%)

Table 1 Baseline characteristics

Characteristic	Patients (n = 32)
Age (years), median (IQR)	64 (60–70)
Sex, male	17 (53)
BMI (kg/m^2), median (IQR)	25 (22–27)
Charlson Co-morbidity Index, median (IQR)	2 (2–4)
Performance Status	
ECOG 0	5 (16)
ECOG 1	23 (72)
ECOG 2	3 (9)
ECOG 3	1 (3)
Bismuth-Corlette Classification ^a	
Bismuth I	3 (10)
Bismuth II	6 (21)
Bismuth IIIa	15 (52)
Bismuth IIIb	3 (10)
Bismuth IV	2 (7)
Total bilirubin at time of embolisation ($\mu\text{mol/L}$) ^b , median (IQR)	56 (22–202)
INR before at time of embolisation ^b , median (IQR)	1.0 (0.97–1.1)
CA19-9 at time of embolisation (IU/ml) ^c , median (IQR)	54.0 (38.2–202)
C-reactive protein at time of embolisation (mg/L), median ^d (IQR)	11 (9–45)
Biliary drainage	26 (81)
Neoadjuvant chemotherapy, n (%)	0 (0)

Baseline data of patients. Data are n (%) unless otherwise specified. BMI: Body Mass Index; ECOG: Eastern Clinical Oncology Group; INR: International Normalised Ratio; CA-19-9: Carbohydrate antigen 19-9; IQR: Interquartile range.

^a Data was available for 29/32 patients regarding bismuth classification.

^b Data was available for 31/32 patients regarding serum bilirubin and INR, to convert bilirubin to mg/dL, divide values by 17.104.

^c Data was available for 23/32 patients regarding CA19-9.

^d Data was available for 27/32 patients regarding C-reactive protein, to convert C-reactive protein to mg/dL, divide values by 10.

and a KGR of 6.8% per week (IQR 3.6–14%). Details on DH and KGR are listed in Table 2. Trends in liver volume after embolisation are depicted in Fig. 1.

Resection

Of the 32 patients, 22 (69%) underwent surgical resection. Details on resectability rates are listed in Table 2. Mean time between embolisation and resection was 37 days (IQR 26–51 days). All resected patients underwent a right-sided resection. An R0 resection was performed in 55% of patients (12/22). After resection, 55% of patients (12/22) experienced complications, of which 23% (5/22) were Clavien-Dindo grade III or higher. One patient experienced ISGLS grade B PHLF (1/22–4.5%) and no grade C PHLF was observed within this cohort. No mortality within 90 days after surgery was seen in this analysis. Median

Table 2 Liver hypertrophy and PVE/HVE outcomes

Outcome	Patients (n = 32)
Baseline FLR (cc), median (IQR)	437 (339–572)
Baseline sFLR (%), median (IQR) FLR	29 (25–35)
Time from embolization to volumetry (days), median (IQR)	16 (8–22)
Postembolization FLR (cc), median (IQR)	664 (490–787)
Postembolization sFLR (%), median (IQR)	45 (34–52)
Degree of hypertrophy (sFLR%), median (IQR)	16 (9–24)
%Hypertrophy (%), median (IQR)	60 (39–105)
Kinetic growth rate, median (IQR)	6.8 (3.6–14)
Time from embolization to resection in days, median (IQR)	37 (26–51)
Any morbidity after embolization	9 (28)
Any major complication (CD \geq Grade III)	7 (22)
Cholangitis - Need for biliary reintervention	6 (19)
Biliary sepsis requiring ICU admission	1 (3)
Resected patients	22 (69)
Reasons for failure to resect	
Ongoing cholangitis	5
Progression of disease	5
Insufficient liver growth	3
Declining performance status	1
Biliary sepsis	1

Double vein embolization data of patients. Data are n (%) unless otherwise specified. sFLR: Standardized future liver remnant (volume), CD: Clavien-Dindo classification.

Table 3 Perioperative outcomes of resection

Outcome	Patients (n = 22)
Duration of surgery (minutes), median (IQR)	421 (323–488)
Blood loss ^a (cc), median (IQR)	1200 (925–1275)
Surgical technique	
Right hemihepatectomy	4 (18)
Extended right hemihepatectomy	18 (82)
90-day postoperative complications	
Any complication	12 (55)
Any major complication (CD \geq Grade III)	5 (23)
Posthepatectomy liver failure ^b	
None	17 (77)
Grade A	4 (18)
Grade B	1 (5)
90-day mortality after resection ^c	0 (0)
Resection margin	
Negative resection margins (R0)	12 (55)
Microscopic tumour infiltration (R1)	5 (23)
Macroscopic residual tumour (R2)	5 (23)
Lymph node invasion	12 (55)
Retrieved lymph nodes, median (IQR)	5 (2–9)
Follow-up time (days), median (IQR)	469 (182–625)
No recurrence at last follow-up	14 (64)

Resection data of patients. Data are n (%) unless otherwise specified. IQR: Interquartile range; CD: Clavien-Dindo classification.

^a Data was available for 14/22 patients regarding blood loss.

^b According to International Study Group of Liver Surgery (ISGLS) criteria.

^c Data was available for 21/22 patients regarding 90-day mortality.

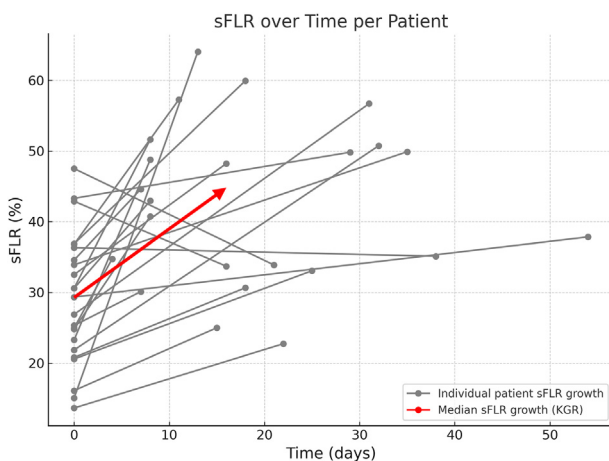


Figure 1 Overview of liver hypertrophy over time. sFLR: standardised future liver remnant; KGR: Kinetic Growth Rate. KGR is calculated by dividing the difference in sFLR by the number of weeks

follow-up after embolisation was 332 days (IQR 146–553 days). Mortality was 50% amongst the resected patients (11/22) and 60% amongst the unresected patients (6/10). Median estimated survival time post-PVE/HVE was 617 days for the resection group and 148 days for the non-resected cohort. Detailed perioperative outcomes are presented in [Table 3](#).

Discussion

In this study, we explored the safety and efficacy of combined PVE/HVE in patients with pCCA, aiming to optimise preoperative procedures to improve resectability rates, surgical outcomes and ultimately, long-term outcomes.

Our study has shown a morbidity rate of 28% following PVE/HVE procedures, all of them related to (recurrent) cholangitis, often requiring biliary reintervention. Most patients did undergo a surgical resection and the majority of those who did not proceed to surgery was because of biliary infectious complications.

Amongst those who proceeded to resection, the application of PVE/HVE in this study was associated with notably low rates of PHLF and an absence of 90-day mortality after resection.

In our cohort, we did not observe complications specifically related to the PVE/HVE procedure. Reported complications after PVE/HVE comprised only infectious biliary events. Biliary complications after PVE have received limited attention in existing literature. Di Stefano et al. documented complications in 12.8% of their patients after PVE (24 out of 188 cases), which included thrombosis of the portal vein supplying the future remnant liver, embolic material migration within the portal vein feeding the FLR, haemoperitoneum, haemobilia, subcapsular haematoma, and liver failure.²³ Nagino et al. conducted a study in Asia involving 240 patients with biliary cancer, primarily to explore the role of PVE in managing these cancers. They reported that there were no complications related to PVE requiring blood transfusion, radiological, or surgical intervention. Surprisingly, the study did not report any episodes of cholangitis after embolisation.²⁴ Recurrent cholangitis is one of the main challenges in patients with malignant hilar biliary obstruction and is often seen in patients that do not undergo embolisation. Our data does not allow to conclude that PVE/HVE induces (recurrent) cholangitis in this patient population, nor does existing literature allow for a comparison with a PVE population. The prevalence of cholangitis in patients undergoing PVE/HVE may reflect underlying disease complexities or pre-existing conditions rather than being a direct outcome of the procedure itself.

The volumetric analysis of the FLR post-PVE/HVE revealed a median DH of 16% and a KGR of 6.8% per week, indicating a faster growth rate of the liver compared to standard PVE in general, and in pCCA patients specifically.^{13,25,26} Notably, the median interval between embolisation and surgery in our cohort was 37 days, indicating a longer waiting time than generally reported in existing literature on PVE/HVE or LVD.^{13,24,27} Given the rapid hypertrophy observed, this long interval may represent an opportunity to expedite surgical scheduling, avoiding the occurrence of preoperative infectious biliary complications and associated repeated biliary interventions.

The resectability rate observed in our study was 69%, slightly lower than the resection rates reported in other studies. For instance, Nagino and colleagues achieved an 80.4% resection rate in 240 patients with biliary tract cancer (150 cholangiocarcinomas and 90 gallbladder cancers) who underwent PVE.²⁴ Ebata et al. reported a resection rate of 75.3% in 494 patients, and Higuchi and colleagues noted a resection rate of 78% in 811 patients.^{24,28} This discrepancy could possibly be attributed to regional differences in pCCA case complexity, selection bias, local surgical experience and culture, and standards in both indication, approach and experience in biliary drainage.²⁹ In the study by Nagino et al., patients exclusively underwent percutaneous transhepatic biliary drainage (PTBD) procedures by highly experienced teams. The method, timing

and technical success of biliary drainage could be critical factors influencing resection rates.³⁰ It is crucial to acknowledge that still a significant portion of potentially resectable pCCA patients receive drainage in non-specialised centres, which may compromise resectability rates and (surgical) outcomes.³¹ In this study, biliary drainage differed significantly between participating centres, complicating interpretation and generalisation of these data.

More than half of patients had a complication after surgery. This is comparable to reported numbers in current literature in pCCA patients after major resection. Notably, the 90-day mortality rate observed in our cohort was zero. Different studies reported varying 90-day mortality rates, grossly between 10 and 17%, in current Western series.^{32–35} Relative to established benchmarks in the field, the enhanced liver hypertrophy induced by this approach could have reduced the risk of PHLF, a key factor in postoperative mortality.⁷

This study is subject to several limitations, including selection bias, its retrospective, non-comparative design and the small sample size. Patients in this study were specifically selected for PVE/HVE across multiple centres. The possible differences in patient populations, those selected for a new and potentially more aggressive procedure like PVE/HVE versus those in standard PVE studies, can affect outcomes such as resection rates, safety profiles, and postoperative recovery. This limits the extent to which our findings can be generalised to all pCCA patients undergoing liver hypertrophy procedures. Moreover, the limited sample size restricts the statistical power of our findings and may not accurately represent the broader patient population. Furthermore, data on the increase in liver function after PVE/HVE are lacking. These factors limit the generalisability of our results and emphasises the need for larger, prospective trials. Future research should ideally include large, multicentre randomised studies to validate the safety of PVE/HVE, and assess the long-term benefits on quality of life and survival rates.

In conclusion, this study suggests that PVE/HVE safely induces liver hypertrophy and improves KGR and preoperative FLR volume in patients with pCCA. Resection after PVE/HVE was associated with low levels of PHLF and 90-day mortality. The study underscores the potential value of PVE/HVE in improving safety and outcomes in pCCA patients undergoing resection, while also pointing out the impact of cholangitis on resection feasibility and outcomes.

Grant support

The Dutch Cancer Society provided financial support for the DRAGON trials (Grant number 12501).

Conflicts of interest

None to declare.

Acknowledgments

Euro LVD group

Patrick Chevallier, Department of Diagnosis and Interventional Imaging, University Hospital of Nice, France; Stephen Wigmore, Clinical Surgery, University of Edinburgh & Royal Infirmary of Edinburgh, Scotland; Timothy Newhook, Department of Surgical Oncology, The University of Texas MD Anderson Cancer Center, Houston, TX, USA; Jean-Nicolas Vauthey, Department of Surgical Oncology, The University of Texas MD Anderson Cancer Center, Houston, TX, USA; Riccardo Memeo, Department of Hepato-Pancreatic-Biliary Surgery, Miulli Hospital, Bari, Italy; Bobby VM Dasari, Department of Hepatobiliary and Pancreatic Surgery, Queen Elizabeth Hospital, Birmingham, United Kingdom; Eva Braunwarth, Department of Visceral, Transplantation and Thoracic Surgery, Medical University of Innsbruck, Innsbruck, Austria.

DRAGON Collaborative Group

Luca Aldrighetti, Department of Surgery, Ospedale San Raffaele, Milan, Italy; Esteban Cugat Andorrà, Department of Surgery, University Hospital Germans Trias I Pujol, Badalona, Spain; Pieter Arntz, Department of Surgery, Cancer Center Amsterdam, Amsterdam UMC, University of Amsterdam, The Netherlands; Bulent Arslan, Department of Interventional Radiology, Rush University Medical Center, Chicago, USA; Laurens van Baardewijk, Department of Radiology, Maxima Medical Center, Eindhoven, Netherlands; Ivan Baclija, Department of Radiology, Clinic Favoriten, Vienna, Austria; Chad Ball, Department of Surgery, Foothills Medical Centre, Calgary, Alberta, Canada; Louise Barbier, Department of Surgery, Auckland District Health Board, Auckland, New Zealand; Jan Bednarsch, Department of Surgery, University Hospital Aachen, Aachen, Germany; Marc Bemelmans, Department of Surgery, Maastricht University Medical Center+, Maastricht, Netherlands; Clare Bent, RBCH, Royal Bournemouth and Christchurch Hospital, Bournemouth, United Kingdom; Frans van den Bergh, Department of Radiology, Universitair Ziekenhuis Brussel, Brussels, Belgium; Kevin Billingsley, Department of Surgery, Yale University School of Medicine, New Haven, USA; Christoph Binkert, Clinic of Interventional Radiology and Vascular Surgery, Kantonsspital Winterthur, Winterthur, Switzerland; Bergthor Björnsson, Department of Surgery, Linköping University Hospital, Linköping, Sweden; Marieke T. de Boer, Department of Surgery, University Medical Center Groningen, Groningen, The Netherlands; Reinoud P.H. Bokkers, Department of Radiology, University Medical Center Groningen, Groningen, Netherlands; Diederick de Boo, Department of Radiology, Monash Health, Clayton, Australia; Francisco Javier Garcia Borobia, Department of Surgery, Hospital Parc Taulí de Sabadell, Sabadell, Spain; Dries Braat, Department of Surgery, Leids Universitair Medisch Centrum, Leiden, Netherlands; David Breen, Department of Radiology, University Hospital Southampton NHS, Southampton, United Kingdom; Stefan Breitenstein, Department of Visceral and Thoracic Surgery, Kantonsspital Winterthur, Winterthur, Switzerland; Karine Brousseau, Department of Surgery, The Ottawa Hospital, University of Ottawa, Ottawa, Canada; Ruther Bruijnen, Department of Radiology and Nuclear Medicine, University Medical Center Utrecht, Utrecht, The Netherlands; Philipp Bruners, Department of Radiology, University Hospital Aachen, Aachen, Germany; Christiane Bruns, Department of General, Visceral, Cancer and Transplant Surgery, Faculty of Medicine, University Hospital of Cologne, University of Cologne, Cologne, Germany; Alexander Bunck, Department of Radiology, Faculty of Medicine and University Hospital Cologne, University of Cologne, Cologne, Germany; Mark Burgmans, Department of Radiology, Leids Universitair Medisch Centrum, Leiden, Netherlands; Alberta Cappelli, Department of Radiology, IRCCS Azienda Ospedaliero-Universitaria di Bologna, Bologna, Italy; Ulrik Carling, Department of Radiology, Rikshospitalet, Oslo University Hospital, Oslo, Norway; Luis Abreu de Carvalho, Department of HPB Surgery and Liver Transplantation, Ghent University Hospital, Ghent, Belgium; Charles Cha, Department of Surgery, Yale University School of Medicine, New Haven, USA; Benjamin Chan, Department of Liver Surgery, Liverpool University Hospitals NHS, Liverpool United Kingdom; Belinda Chand, Department of Radiology, Monash Health, Clayton, Australia; Thierry Chapelle, Department of Hepatobiliary and Transplantation Surgery, Antwerp University Hospital, Edegem, Belgium; Francesco De Cobelli, Department of Radiology, Ospedale San Raffaele, Milan, Italy; Laurent Coubeau, Department of Abdominal Surgery and Transplantation, Cliniques Universitaires Saint-Luc, Université catholique

de Louvain, Brussels, Belgium; Eva Criado, Interventional Radiology Unit, UDIAT-Centre Diagnòstic, Hospital Universitario Parc Taulí Sabadell, Medicine Department Universidad Autónoma de Barcelona, Barcelona, Spain; Daniel Croagh, Department of Surgery, Monash Health, Clayton, Australia; Mathieu D'Hondt, Department of Digestive and Hepatobiliary/Pancreatic Surgery, Groeninge Hospital, Kortrijk, Belgium; Ronald van Dam, Department of Surgery, Maastricht University Medical Center+, Maastricht, Netherlands; Steven Olde Damink, Department of Surgery, Maastricht University Medical Center+, Maastricht, Netherlands; Rob Davis, Department of Interventional Radiology, Liverpool University Hospitals NHS, Liverpool, United Kingdom; Martin Delle, Division of Radiology, Department of Clinical Science, Intervention and Technology, Karolinska Institutet, Karolinska University Hospital, Stockholm, Sweden; Alban Denys, Department of Radiology and Interventional Radiology, CHUV University of Lausanne, Lausanne, Switzerland; Fabrice Deprez, Department of Radiology, CHU- Uclouvain-Namur, Yvoir, Belgium; Olivier Detry, Department of Abdominal Surgery and Transplantation, University of Liege, CHU Liege, Liege, Belgium; Maxime Dewulf, Maastricht University Medical Center+, Maastricht, Netherlands; Alexandra Dili, Department of Surgery, CHU UCLouvain Namur, Namur, Belgium; Matthew Dixon, Department of Surgery, Rush University Medical Center, Chicago, USA; Rafael Díaz-Nieto, Department of Liver Surgery, Liverpool University Hospitals NHS, Liverpool United Kingdom; Joris I. Erdmann, Department of Surgery, Cancer Center Amsterdam, Amsterdam UMC, University of Amsterdam, The Netherlands; Rukshan Fernando, Department of Radiology, Auckland District Health Board, Auckland, New Zealand; Jaume Codina Font, Department of Radiology, University Hospital Dr Josep Trueta de Girona, Girona, Spain; Suomi Fouraschen, Department of Surgery, University Medical Center Groningen, Groningen, The Netherlands; Olivier François, Department of Medical Imaging, AZ Groeninge, Kortrijk, Belgium; Åsmund A. Fretland, Department of Surgery, Rikshospitalet, Oslo University Hospital, Oslo, Norway; Yilian Fundora, Department of Surgery, Hospital Clínic de Barcelona, Barcelona, Spain; Sameer Gadani, Section of Vascular and Interventional Radiology, Imaging Institute, Cleveland Clinic, Cleveland, Ohio, USA; Steven Gallinger, Department of Surgery, University Health Network, Toronto, Canada; Alexandra Geleabert, Department of Radiology, Hospital Parc Taulí de Sabadell, Sabadell, Spain; Laurent Gerard, Department of Radiology, CHU Liege, Liege, Belgium; Josep Guitart Giménez, Department of Radiology, University Hospital Mútua Terrassa, Terrassa, Spain; Paul Gobardhan, Department of Surgery, Amphia, Breda, Netherlands; Pierre Goffette, Department of Radiology, Cliniques Universitaires Saint-Luc, Brussels, Belgium; Lukasz Filip Grochola, Department of Visceral and Thoracic Surgery, Kantonsspital Winterthur, Winterthur, Switzerland; Lukasz Filip Grochola, Department of Visceral and Thoracic Surgery, Kantonsspital Winterthur, Winterthur, Switzerland; Thomas Gruenberger, Department of Surgery, HPB Center, Clinic Favoriten, Health Network Vienna, Vienna, Austria; Dirk Grünhagen, Department of Surgery, Erasmus Medisch Centrum, Rotterdam, The Netherlands; Felice Guiliante, Department of Surgery, Gemelli University Hospital Rome, Rome, Italy; Fernando Gómez, Department of Radiology, Hospital Clínic de Barcelona, Barcelona, Spain; Jeroen Hagendoorn, Department of Surgery, University Medical Center Utrecht, Utrecht, The Netherlands; John Hammond, Department of Surgery, The Newcastle upon Tyne Hospitals, Newcastle, United Kingdom; Margot Heijmans, Department of Surgery, Maxima Medical Center, Eindhoven, Netherlands; Jan Heil, Department of Surgery, University of Ulm, Germany; Daniel Heise, Department of Surgery, University Hospital Aachen, Aachen, Germany; Laurens Hermie, Department of Vascular and Interventional Radiology, Ghent University Hospital, Ghent, Belgium; Eric Herrero, Department of Surgery, University Hospital Mútua Terrassa, Terrassa, Spain; Gebriel Hess, Department of Surgery, Clarunis University Hospital, Basel, Switzerland; Sam Heye, Department of Radiology, Jessa Ziekenhuis, Hasselt, Belgium; Martin Hoffmann, Department of Radiology, St Clara Hospital, Basel, Switzerland; Roberto Iezzi, Department of Radiology, Gemelli University Hospital, Rome, Italy; Farshad Imani, Department of Radiology, Amphia Breda, Breda, Netherlands; Sinéad James, Department of Surgery, Maastricht University Medical Center+, Maastricht, Netherlands; Thomas Jardinot, Department of Radiology, Antwerp University Hospital, Edegem, Belgium; Kunal Joshi, Department of General Surgery, University Hospital Birmingham, Birmingham, United Kingdom; Elio Jovine, Department of Surgery, Maggiore Hospital, Bologna, Italy; Jennifer Kaili, McGill University Medical Center, Montreal, Canada; Paul Karanicolas, Division of General Surgery, Sunnybrook Health

Sciences Centre, Canada; Geert Kazemier, Department of Surgery, Cancer Center Amsterdam, Amsterdam UMC, University of Amsterdam, The Netherlands; Lars Kern, Department of Visceral and Thoracic Surgery, Kantonsspital Winterthur, Winterthur, Switzerland; Peter Kingham, Department of Surgery, Memorial Sloan Kettering Cancer Center, New York, United States; Darren Klass, Department of Surgery, Vancouver General Hospital, Vancouver, Canada; Bas Groot Koerkamp, Department of Surgery, Erasmus Medisch Centrum, Rotterdam, The Netherlands; Otto Kollmar, Department of Surgery, Clarunis University Hospital, Basel, Switzerland; Remon Korenblik, Maastricht University Medical Center+, Maastricht, Netherlands; Choon Kwon, Department of Hepato-Pancreato-Biliary/Liver Transplant Surgery, Cleveland Clinic Foundation, Cleveland, Ohio, USA; Céline Lambrecht, Department of Abdominal Surgery and Transplantation, University of Liege, CHU Liege, Liege, Belgium; Sven Lang, Department of General, Visceral and Transplantation Surgery, Essen University Hospital, Essen, Germany; Laura-Ann, Department of General, Visceral and Thoracic Surgery, Surgical Oncology, Klinikum Saarbruecken, Saarbruecken, Germany; Wouter Leclercq, Department of Surgery, Maxima Medical Center, Eindhoven, Netherlands; Christiaan van der Leij, Department of Radiology, Maastricht University Medical Center+, Maastricht, Netherlands; Richard Lindsay, Department of Radiology, Belfast Health and Social Care Trust, Belfast, United Kingdom; Santiago Lopez-Ben, Department of Surgery, University Hospital Dr Josep Trueta de Girona, Girona, Spain; Valerio Lucidi, Department of Abdominal Surgery, Clinic of Hepato-Biliary Surgery and Liver Transplantation, Erasme University Hospital – ULB, Brussels, Belgium; Jordi Navinés López, Department of Surgery, University Hospital Germans Trias I Pujol, Badalona, Spain; Andrew Macdonald, Department of Radiology, Oxford University Hospitals NHS Foundation Trust, Oxford, United Kingdom; David C. Madoff, Department of Radiology, Yale School of Medicine, New Haven, United States; George Markose, Department of Radiology, Hamilton Health Sciences, McMaster University, Hamilton, Ontario, Canada; Gilbert Maroune, Department of Vascular and Interventional Radiology, Sunnybrook Health Sciences Center, University of Toronto, Toronto, Canada; Guillaume Martel, Department of Surgery, The Ottawa Hospital, University of Ottawa, Ottawa, Canada; Ernesto Santos Martin, Department of Radiology, Memorial Sloan Kettering Cancer Center, New York, USA; Homoyon Mehrzad, Department of Imaging and Interventional Radiology, Queen Elizabeth Hospital Birmingham, University Hospital Birmingham, Birmingham, United Kingdom; Martijn Meijerink, Department of Radiology, Amsterdam UMC, University of Amsterdam, Amsterdam, The Netherlands; Emmanuel Melloul, Department of Visceral Surgery, Lausanne University Hospital and University of Lausanne, CHUV, Lausanne, Switzerland; Nouredin Messaoudi, Department of Surgery, Universitair Ziekenhuis Brussel, Brussels, Belgium; Peter Metrakos, Department of Surgery, McGill University Health Centre, Montréal, Canada; Sachin Modi, Department of Radiology, University Hospital Southampton NHS Trust, Southampton, United Kingdom; Nicola Montanari, Department of Radiology, Maggiore Hospital, Bologna, Italy; Jaume Sampere Moragues, Department of Radiology, University Hospital Germans Trias I Pujol, Badalona, Spain; Amol Mujoomdar, Division of Interventional Radiology, Department of Medical Imaging, London Health Sciences, London, Ontario, Canada; Ulf Neumann, Department of General, Visceral and Transplantation Surgery, Essen University Hospital, Essen, Germany; Jelmer Oor, Department of Surgery, University Medical Center Utrecht, Utrecht, The Netherlands; Patroklos Pappas, Department of Surgery, Rush University Medical Center, Chicago, USA; Kay Pieterman, Department of Radiology and Nuclear Medicine, Erasmus MC, Erasmus University, Rotterdam, the Netherlands; John Primrose, University Surgery, University Hospital Southampton NHS Trust, Southampton, United Kingdom; Xudong Qu, Department of Interventional Radiology, Zhongshan hospital, Fudan University, Shanghai, China; Francesca Ratti, Department of Surgery, Ospedale San Raffaele, Milan, Italy; Fourat Ridouani, Department of Radiology, Memorial Sloan Kettering Cancer Center, New York, United States; Inne H.M. Borel Rinkes, Department of Surgery, University Medical Center Utrecht, Utrecht, The Netherlands; Margarida Casellas i Robert, Department of Radiology, University Hospital Dr Josep Trueta, Girona, Spain; Steffen Ross, Institute for Diagnostic and Interventional Radiology and Neuroradiology, Klinikum Saarbruecken, Saarbruecken, Germany; Leyo Ruo, Department of Surgery, Hamilton Health Sciences, McMaster University, Hamilton, Ontario, Canada; Stephen Ryan, Department of Radiology, The Ottawa Hospital, University of Ottawa, Ottawa, Canada; Aysun Salik, Department of Radiology, Linköping

University Hospital, Linköping, Sweden; Per Sandström, Department of Surgery, Linköping University Hospital, Linköping, Sweden; Jonas Santol, Department of Surgery, HPB Center, Clinic Favoriten, Health Network Vienna, Vienna, Austria; Luis Sarría, Department of Radiology, University Hospital Miguel Servet, Saragossa, Spain; Benedikt Schaarschmidt, Department of Diagnostic and Interventional Radiology and Neuroradiology, University Hospital Essen, Essen, Germany; Erik Schadde, Department of Surgery, Klinik Hirslanden, Luzern and Zurich, Switzerland; Marc Schiesser, Department of Surgery, Klinik Hirslanden, Luzern and Zurich, Switzerland; Moritz Schmelzle, Department of General, Visceral and Transplant Surgery, Hannover Medical School, Hannover, Germany; Nico Seeger, Department of Visceral and Thoracic Surgery, Kantonsspital Winterthur, Winterthur, Switzerland; Maja Segedi, Department of Surgery, Vancouver General Hospital, Vancouver, Canada; Matteo Serenari, Hepato-biliary and Transplant Unit, IRCCS Azienda Ospedaliero-Universitaria di Bologna, Bologna, Italy; Gregory Azienga, Department of Digestive and Hepatobiliary/Pancreatic Surgery, Jessa Hospital, Hasselt, Belgium; Alejandro Serrablo, Department of Surgery, University Hospital Miguel Servet, Saragossa, Spain; Sorina Simon, Department of Radiology, Maastricht University Medical Center+, Maastricht, Netherlands; Anton Skaro, Department of Surgery, London Health Sciences Centre, London, Ontario, Canada; Maarten Smits, Department of Radiology and Nuclear Medicine, University Medical Center Utrecht, Utrecht, the Netherlands; Jens Smits, Department of Surgery, Maastricht University Medical Center+, Maastricht, Netherlands; Andreas Snitzbauer, Department of Surgery, University Hospital Frankfurt, Frankfurt, Germany; Zahir Soonawalla, Department of Surgery, Oxford University Hospitals NHS Foundation Trust, Oxford, United Kingdom; Ernesto Sparrelid, Division of Surgery and Oncology, Department of Clinical Science, Intervention and Technology, Karolinska Institutet, Karolinska University Hospital, Stockholm, Sweden; Elmar Spuentrup, Institute for Diagnostic and Interventional Radiology and Neuroradiology, Klinikum Saarbruecken, Saarbruecken, Germany; Gregor Stavrou, Department of General, Visceral and Thoracic Surgery, Surgical Oncology, Klinikum Saarbruecken, Saarbruecken, Germany; Robert Sutcliffe, Department of General Surgery, University Hospital Birmingham, Birmingham, United Kingdom; Rutger-Jan Swijnenburg, Department of Surgery, Cancer Center Amsterdam, Amsterdam UMC, University of Amsterdam, The Netherlands; Ilario Tancredi, Department of Radiology, Erasme University Hospital – ULB, Brussels, Belgium; Jordan C. Tasse, Department of Interventional Radiology, Rush University Medical Center, Chicago, USA; Madita Tschögl, Department of Surgery, HPB Center, Clinic Favoriten, Health Network Vienna, Vienna, Austria; Venkatesha Udupa, Department of HPB Surgery, Oxford University Hospitals NHS Foundation Trust, Oxford, United Kingdom; David A. Valenti, Department of Radiology, McGill University Health Centre, Montréal, Canada; David Vass, Department of Surgery, Belfast Health and Social Care Trust, Belfast, United Kingdom; Ariadne Lisa van der Velden, Department of Radiology, Maastricht University Medical Center+, Maastricht, Netherlands; Thomas Vogl, Department of Radiology, University Hospital Frankfurt, Frankfurt, Germany; Frank Wacker, Department of Diagnostic and Interventional Radiology, Hannover Medical School, Hannover, Germany; Xiaoying Wang, Department of Liver Surgery, Zhongshan hospital, Fudan University, Shanghai, China; Jürgen Weitz, Department of Visceral, Thoracic and Vascular Surgery, University Hospital Carl Gustav Carus, Technische Universität Dresden, Dresden, Germany; Steven White, Department of Surgery, The Newcastle upon Tyne Hospitals, Newcastle, United Kingdom; Rizky Widyaningsih, Department of General, Visceral and Thoracic Surgery, Surgical Oncology, Klinikum Saarbruecken, Saarbruecken, Germany; Jean-François De Wispelaere, Department of Radiology, CHU UCLouvain Namur, Namur, Belgium; Ijsbrand Zijlstra, Department of Radiology, Amsterdam UMC, University of Amsterdam, Amsterdam, The Netherlands;

References

1. Sarcognato S, Sacchi D, Fassan M, Fabris L, Cadamuro M, Zanus G *et al.* (2021 Jun 1) Cholangiocarcinoma. *Pathologica* 113:158–169.
2. Neuhaus P, Jonas S, Bechstein WO, Lohmann R, Radke C, Kling N *et al.* (1999) Extended resections for hilar cholangiocarcinoma. *Ann Surg* 230: 808.
3. Bednarsch J, Czigan Z, Lurje I, Tacke F, Strnad P, Ulmer TF *et al.* (2020 Mar 1) Left- versus right-sided hepatectomy with hilar en-bloc resection

- in perihilar cholangiocarcinoma. *HPB* 22:437–444. <https://doi.org/10.1016/j.hpb.2019.07.003>.
4. Primrose JN, Fox RP, Palmer DH, Malik HZ, Prasad R, Mirza D *et al.* (2019 May 1) Capecitabine compared with observation in resected biliary tract cancer (BILCAP): a randomised, controlled, multicentre, phase 3 study. *Lancet Oncol* 20:663–673. [https://doi.org/10.1016/S1470-2045\(18\)30915-X](https://doi.org/10.1016/S1470-2045(18)30915-X).
 5. Do-Youn O, Aiwu RH, Shukui Q, Li-Tzong C, Takuji O, Arndt V *et al.* (2022 Jul 26) Durvalumab plus gemcitabine and cisplatin in advanced biliary tract cancer. *NEJM Evid* 1EVIDoa2200015. <https://doi.org/10.1056/EVIDoa2200015>.
 6. de Jong DM, Gilbert TM, Nooijen LE, Braunwarth E, Ninkovic M, Primavesi F *et al.* (2023) Preoperative endoscopic biliary drainage by metal versus plastic stents for resectable perihilar cholangiocarcinoma. *Gastrointest Endosc* 99:566–576.e8. Available from: <https://www.sciencedirect.com/science/article/pii/S0016510723029954>.
 7. Mueller M, Breuer E, Mizuno T, Bartsch F, Ratti F, Benzing C *et al.* (2021) Perihilar cholangiocarcinoma – novel benchmark values for surgical and oncological outcomes from 24 expert centers. *Ann Surg* 274. Available from: https://journals.lww.com/annalsurgery/fulltext/2021/11000/perihilar_cholangiocarcinoma___novel_benchmark.15.aspx.
 8. Ribero D, Zimmitti G, Aloia TA, Shindoh J, Forchino F, Amisano M *et al.* (2016) Preoperative cholangitis and future liver remnant volume determine the risk of liver failure in patients undergoing resection for hilar cholangiocarcinoma. *J Am Coll Surg* 223.
 9. Bednarsch J, Czigany Z, Lurje I, Amygdalos I, Strnad P, Halm P *et al.* (2021) Insufficient future liver remnant and preoperative cholangitis predict perioperative outcome in perihilar cholangiocarcinoma. *HPB* 23: 99–108. Available from: <https://www.sciencedirect.com/science/article/pii/S1365182X20301441>.
 10. Olthof PB, Aldrighetti L, Alkhanov R, Cescon M, Groot Koerkamp B, Jarnagin WR *et al.* (2020) Portal vein embolization is associated with reduced liver failure and mortality in high-risk resections for perihilar cholangiocarcinoma. *Ann Surg Oncol* 27:2311–2318. <https://doi.org/10.1245/s10434-020-08258-3>.
 11. Clocchiatti L, Marino R, Ratti F, Pedica F, Casadei Gardini A, Lorenzin D *et al.* (2023) Defining and predicting textbook outcomes for perihilar cholangiocarcinoma: analysis of factors improving of achievement of desired post-operative outcomes. retrospective cohort study. *Int J Surg* 110:209–218. Available from: https://journals.lww.com/international-journal-of-surgery/fulltext/9900/defining_and_predicting_textbook_outcomes_for.689.aspx.
 12. Heil J, Korenblik R, Heid F, Bechstein WO, Bemelmans M, Binkert C *et al.* (2021 Jul 1) Preoperative portal vein or portal and hepatic vein embolization: DRAGON collaborative group analysis. *Br J Surg* 108: 834–842. <https://doi.org/10.1093/bjs/znaa149>.
 13. Hocquet A, Sotiriadis C, Duran R, Guiu B, Yamaguchi T, Halkic N *et al.* (2018) Preoperative portal vein embolization alone with biliary drainage compared to a combination of simultaneous portal vein, right hepatic vein embolization and biliary drainage in Klatskin tumor. *Cardiovasc Intervent Radiol* 41:1885–1891. <https://doi.org/10.1007/s00270-018-2075-0>.
 14. Marino R, Ratti F, Della Corte A, Santangelo D, Clocchiatti L, Canevari C *et al.* (2023) Comparing liver venous deprivation and portal vein embolization for perihilar cholangiocarcinoma: is it time to shift the focus to hepatic functional reserve rather than hypertrophy? *Cancers* 15:4363.
 15. Guiu B, Chevallier P, Denys A, Delhom E, Pierredon-Foulongne M-A, Rouanet P *et al.* (2016) Simultaneous trans-hepatic portal and hepatic vein embolization before major hepatectomy: the liver venous deprivation technique. *Eur Radiol* 26:4259–4267. <https://doi.org/10.1007/s00330-016-4291-9>.
 16. von Elm E, Altman DG, Egger M, Pocock SJ, Gøtzsche PC, Vandenbroucke JP. (2008 Apr 1) The Strengthening the Reporting of Observational Studies in Epidemiology (STROBE) statement: guidelines for reporting observational studies. *J Clin Epidemiol* 61:344–349. <https://doi.org/10.1016/j.jclinepi.2007.11.008>.
 17. Dindo D, Demartines N, Clavien P-A. (2004) Classification of surgical complications: a new proposal with evaluation in a cohort of 6336 patients and results of a survey. *Ann Surg* 240:205–213.
 18. Vauthey J-N, Abdalla EK, Doherty DA, Gertsch P, Fenstermacher MJ, Loyer EM *et al.* (2002) Body surface area and body weight predict total liver volume in Western adults. *Liver Transplant* 8:233–240.
 19. Shindoh J, Truty MJ, Aloia TA, Curley SA, Zimmitti G, Huang SY *et al.* (2013) Kinetic growth rate after portal vein embolization predicts post-hepatectomy outcomes: toward zero liver-related mortality in patients with colorectal liver metastases and small future liver remnant. *J Am Coll Surg* 216:201–209.
 20. Balzan S, Belghiti J, Farges O, Ogata S, Sauvanet A, Delefosse D *et al.* (2005) The “50-50 criteria” on postoperative day 5: an accurate predictor of liver failure and death after hepatectomy. *Ann Surg* 242:824.
 21. Rahbari NN, Garden OJ, Padbury R, Brooke-Smith M, Crawford M, Adam R *et al.* (2011) Posthepatectomy liver failure: a definition and grading by the international study group of liver surgery (ISGLS). *Surgery* 149:713–724.
 22. Koch M, Garden OJ, Padbury R, Rahbari NN, Adam R, Capussotti L *et al.* (2011) Bile leakage after hepatobiliary and pancreatic surgery: a definition and grading of severity by the International Study Group of Liver Surgery. *Surgery* 149:680–688.
 23. Di Stefano DR, de Baere T, Denys A, Hakime A, Gorin G, Gillet M *et al.* (2005 Feb 1) Preoperative percutaneous portal vein embolization: evaluation of adverse events in 188 patients. *Radiology* 234:625–630. <https://doi.org/10.1148/radiol.2342031996>.
 24. Nagino M, Kamiya J, Nishio H, Ebata T, Arai T, Nimura Y. (2006) Two hundred forty consecutive portal vein embolizations before extended hepatectomy for biliary cancer: surgical outcome and long-term follow-up. *Ann Surg* 243. Available from: https://journals.lww.com/annalsurgery/fulltext/2006/03000/two_hundred_forty_consecutive_portal_vein.13.aspx.
 25. Ribero D, Abdalla EK, Madoff DC, Donadon M, Loyer EM, Vauthey JN. (2007) Portal vein embolization before major hepatectomy and its effects on regeneration, resectability and outcome. *J Br Surg* 94: 1386–1394.
 26. Chebaro A, Buc E, Durin T, Chiche L, Brustia R, Didier A *et al.* (2021) Liver venous deprivation or associating liver partition and portal vein ligation for staged hepatectomy?: a retrospective multicentric study. *Ann Surg* 274:874–880.
 27. Ebata T, Yokoyama Y, Igami T, Sugawara G, Takahashi Y, Nagino M. (2012) Portal vein embolization before extended hepatectomy for biliary cancer: current technique and review of 494 consecutive embolizations. *Dig Surg* 29:23–29.
 28. Higuchi R, Yamamoto M. (2014) Indications for portal vein embolization in perihilar cholangiocarcinoma. *J Hepato-Biliary-Pancreatic Sci* 21: 542–549.

- 29.** Olthof PB, Miyasaka M, Koerkamp BG, Wiggers JK, Jarnagin WR, Noji T *et al.* (2019 Mar 1) A comparison of treatment and outcomes of perihilar cholangiocarcinoma between Eastern and Western centers. *HPB* 21: 345–351. <https://doi.org/10.1016/j.hpb.2018.07.014>.
- 30.** Kloek JJ, van der Gaag NA, Aziz Y, Rauws EAJ, van Delden OM, Lameris JS *et al.* (2010) Endoscopic and percutaneous preoperative biliary drainage in patients with suspected hilar cholangiocarcinoma. *J Gastrointest Surg* 14:119–125. <https://doi.org/10.1007/s11605-009-1009-1>.
- 31.** van Keulen A-M, Franssen S, van der Geest LG, de Boer MT, Coenraad M, van Driel LMJW *et al.* (2021 Aug 1) Nationwide treatment and outcomes of perihilar cholangiocarcinoma. *Liver Int* 41:1945–1953. <https://doi.org/10.1111/liv.14856>.
- 32.** Farges O, Regimbeau JM, Fuks D, Le Treut YP, Cherqui D, Bachellier P *et al.* (2013) Multicentre European study of preoperative biliary drainage for hilar cholangiocarcinoma. *J Br Surg* 100:274–283.
- 33.** Nuzzo G, Giuliani F, Ardito F, Giovannini I, Aldrighetti L, Belli G *et al.* (2012) Improvement in perioperative and long-term outcome after surgical treatment of hilar cholangiocarcinoma: results of an Italian multi-center analysis of 440 patients. *Arch Surg* 147:26–34.
- 34.** De Jong MC, Marques H, Clary BM, Bauer TW, Marsh JW, Ribero D *et al.* (2012) The impact of portal vein resection on outcomes for hilar cholangiocarcinoma: a multi-institutional analysis of 305 cases. *Cancer* 118:4737–4747.
- 35.** Olthof PB, Coelen RJS, Wiggers JK, Koerkamp BG, Malago M, Hernandez-Alejandro R *et al.* (2017) High mortality after ALPPS for perihilar cholangiocarcinoma: case-control analysis including the first series from the international ALPPS registry. *HPB* 19:381–387.

Appendix A. Supplementary data

Supplementary data to this article can be found online at <https://doi.org/10.1016/j.hpb.2024.07.407>.