





**Please cite the Published Version**

Alruhaimi, Reem S , Hassanein, Emad H M , Ahmeda, Ahmad F, Atwa, Ahmed M , Alnasser, Sulaiman M, Sayed, Ghadir A, Alotaibi, Meshal, Alzoghaibi, Mohammed A and Mahmoud, Ayman M  (2024) Farnesol attenuates cadmium-induced kidney injury by mitigating oxidative stress, inflammation and necroptosis and upregulating cytoglobin and PPAR in rats. *Tissue and Cell*, 90. 102526 ISSN 0040-8166

**DOI:** <https://doi.org/10.1016/j.tice.2024.102526>

**Publisher:** Elsevier

**Version:** Accepted Version

**Downloaded from:** <https://e-space.mmu.ac.uk/635574/>

**Usage rights:**  [Creative Commons: Attribution 4.0](https://creativecommons.org/licenses/by/4.0/)

**Additional Information:** This is an accepted manuscript of an article which appeared in final form in *Tissue and Cell*

**Data Access Statement:** The manuscript contains all data supporting the reported results.

**Enquiries:**

If you have questions about this document, contact [openresearch@mmu.ac.uk](mailto:openresearch@mmu.ac.uk). Please include the URL of the record in e-space. If you believe that your, or a third party's rights have been compromised through this document please see our Take Down policy (available from <https://www.mmu.ac.uk/library/using-the-library/policies-and-guidelines>)

Title:

**Farnesol attenuates cadmium-induced kidney injury by mitigating oxidative stress, inflammation and necroptosis and upregulating cytoglobin and PPAR $\gamma$  in rats**

**Authors and affiliations:**

**Reem S. Alruhaimi<sup>1</sup>, Emad H.M. Hassanein<sup>2</sup>, Ahmad F. Ahmeda<sup>3,4</sup>, Ahmed M. Atwa<sup>5</sup>, Sulaiman M. Alnasser<sup>6</sup>, Ghadir A Sayed<sup>7</sup>, Meshal Alotaibi<sup>8</sup>, Mohammed A. Alzoghaibi<sup>9</sup>, Ayman M. Mahmoud<sup>10,11\*</sup>**

<sup>1</sup>Department of Biology, College of Science, Princess Nourah bint Abdulrahman University, Riyadh 11671, Saudi Arabia.

<sup>2</sup>Department of Pharmacology & Toxicology, Faculty of Pharmacy, Al-Azhar University-Assiut Branch, Egypt

<sup>3</sup>Department of Basic Medical Sciences, College of Medicine, Ajman University, Ajman 346, United Arab Emirates.

<sup>4</sup>Center of Medical and Bio-allied Health Sciences Research, Ajman University, Ajman 346, United Arab Emirates.

<sup>5</sup>Department of Pharmacology and Toxicology, Faculty of Pharmacy, Egyptian Russian University, Cairo 11829, Egypt.

<sup>6</sup>Department of Pharmacology and Toxicology, College of Pharmacy, Qassim University, Qassim 51452, Saudi Arabia.

<sup>7</sup>Department of Biochemistry, Faculty of Pharmacy, Egyptian Russian University, Cairo 11829, Egypt.

<sup>8</sup>Department of Pharmacy Practice, College of Pharmacy, University of Hafr Albatin, Hafar Al Batin 39524, Saudi Arabia.

<sup>9</sup>Physiology Department, College of Medicine, King Saud University, Riyadh, 11461, Saudi Arabia.

<sup>10</sup>Department of Life Sciences, Faculty of Science and Engineering, Manchester Metropolitan University, Manchester M1 5GD, UK.

<sup>11</sup>Molecular Physiology Division, Zoology Department, Faculty of Science, Beni-Suef University, Beni-Suef 62514, Egypt.

\*Corresponding author:

**Ayman M. Mahmoud**

Department of Life Sciences, Faculty of Science and Engineering, Manchester Metropolitan University, Manchester M1 5GD, UK

ORCID ID: 0000-0003-0279-6500

E-mail: [a.mahmoud@mmu.ac.uk](mailto:a.mahmoud@mmu.ac.uk)

## **Abstract:**

Heavy metals are environmental pollutants that can harm animals and humans even at low concentrations. Cadmium (Cd) is known for its serious health effects on different organs and its toxicity is associated with oxidative stress (OS) and inflammation. Farnesol (FAR), a sesquiterpene alcohol found in many vegetables and fruits, possesses promising anti-inflammatory and antioxidant activities. This study evaluated the effect of FAR on Cd-induced kidney injury, pinpointing its effect of the redox status, inflammation, fibrosis and necroptosis. Rats in this study received FAR for 14 days and Cd on day 7. Elevated serum creatinine, urea and uric acid, and several kidney histopathological alterations were observed in Cd-administered rats. Cd increased MDA, decreased antioxidants, downregulated PPAR $\gamma$  and upregulated NF- $\kappa$ B p65, IL-6, TNF- $\alpha$ , and IL-1 $\beta$ . Necroptosis mediators (RIP1, RIP3, MLKL, and caspase-8) and  $\alpha$ -SMA were upregulated, and collagen deposition was increased in Cd-administered rats. FAR ameliorated kidney injury markers and tissue damage, attenuated OS, suppressed NF- $\kappa$ B and inflammatory mediators, and enhanced antioxidants. In addition, FAR suppressed RIP1, RIP3, MLKL, caspase-8, and  $\alpha$ -SMA, and enhanced kidney cytoglobin and PPAR $\gamma$ . In conclusion, FAR protects against Cd nephrotoxicity by suppressing OS, inflammatory response and necroptosis, effects associated with enhanced antioxidants, cytoglobin, and PPAR $\gamma$ .

**Keywords:** Heavy metals; Nephrotoxicity; Oxidative stress; Inflammation; Farnesol; Necroptosis.

## **1. Introduction**

Heavy metals (HMs) are chemical elements with specific characteristics and have been classified as environmental pollutants [1]. HMs, including cadmium (Cd) can accumulate within the body and cause damage to different organs, resulting in serious health problems [1]. Cd can reach and accumulates in the body of animals and humans through different sources,

including oil extraction, mining, welding, stone quarrying, cigarette smoking, contaminated water and others [2-5]. The use of nanomaterials containing Cd in different applications represents another source of this HM [6]. Exposure to Cd can negatively impact different organs and cause dysfunction of the kidney, liver, heart, bone and nervous system [2, 3, 7, 8]. The hazardous effects of Cd and its direct cytotoxic effects on different organs has led to its classification as a category I human carcinogen [9]. Despite the lack of Cd-specific transport channels, it enters the body cells through channels of other essential elements with which it shares similar physical and chemical properties [10]. The toxic effects of Cd are linked to the increase in reactive oxygen species (ROS) generation and oxidative stress (OS), inflammation and cell injury [11, 12]. Different ROS, including superoxide ( $\bullet\text{O}_2$ ) and hydroxyl ( $\bullet\text{OH}$ ) radicals have been reported to increase following Cd exposure [13, 14]. The Cd-mediated ROS can attack and damage different cell components and macromolecules, such as DNA, proteins and lipids, culminating in cell death [13, 14]. Besides elevated ROS, Cd is implicated in the depletion of cellular antioxidants, mainly reduced glutathione (GSH) and its toxicity is associated with inflammation as reported in different studies [8, 15]. Both OS and inflammation can provoke a programmed form of necrotic cell death called necroptosis [16].

Kidney injury is among the hazardous consequences of exposure to Cd and other HMs [17, 18]. There is a well-characterized relationship between kidney injury and occupational as well as environmental exposure to HMs [17]. Cd-induced kidney injury depends on many factors, including the route of ingestion, age, sex, dose and the length of exposure [19]. Following its absorption by pulmonary or intestinal cells, Cd enters the systemic circulation and is finally deposited mainly in the liver and kidney [20, 21]. Therefore, the kidney is a target organ for HM toxicity due to its efficacy in reabsorption and concentration of divalent metals [22]. Acute exposure to Cd results in acute kidney injury (AKI) in which the ionized form of Cd reduces glucose and phosphate tubular transport, inhibits mitochondrial respiration, damages proximal

tubule (PT) cells membrane and causes cell death [22, 23]. About 50% of the total body Cd accumulates in the cells of PTs, resulting in disrupted reabsorption and proteinuria [24]. Mitochondrial dysfunction and OS represent the main mechanisms underlying toxicity and kidney injury induced by Cd [25]. Therefore, attenuation of OS and its related inflammatory response can protect the kidney against the toxic effects of Cd.

Natural products from plants have shown beneficial effects on diseases associated with OS and inflammation, including kidney disorders [26, 27]. Neutralization of free radicals, inhibition of inflammatory response and cytoprotection are among the main mechanisms underlying the benefits of natural products [26-28]. Farnesol (FAR) exhibited promising biological and pharmacological effects in several ailments affecting the nervous system, kidney, liver, and other organs [29, 30]. It is a sesquiterpene found in the essential oils of several aromatic plants such as cyclamen, citronella and ambrette seeds [31]. In food industry, FAR is employed as a flavoring agent [32]. It showed radical-scavenging, anti-microbial, anti-tumor and anti-inflammatory efficacies as demonstrated in many *in vivo* and pre-clinical studies [29-31, 33]. The anti-inflammatory and antioxidant efficacies of FAR were demonstrated in our previous studies in rat models of hypercholesterolemia [30] and chlorpyrifos (CPF) nephrotoxicity [26]. Other studies revealed the beneficial effect of FAR against OS and hepatocyte injury in mice challenged with acetaminophen (APAP) [34]. Despite these demonstrated effects of FAR in several disorders, its ability to prevent Cd nephrotoxicity has not yet been elucidated. In this study, the effects of FAR on Cd-induced OS, inflammation, and necroptosis in rat kidney were investigated.

## **2. Materials and Methods**

### **2.1. Experimental design and treatments**

Twenty-four male Wistar rats ( $190 \pm 10$  g) were included to study the nephroprotective effect of FAR. The rats were kept under standard laboratory temperature and humidity on a 12 h dark

light cycle and provided free access to water and food. The study included four experimental groups ( $n = 6$ ). Groups I and II received 0.5% carboxymethyl cellulose (CMC) and 10 mg/kg FAR (Sigma, USA) [26] via oral gavage for 14 days and intraperitoneal (i.p.) injection of 0.9% saline on day 7. Groups III and IV received 0.5% CMC and FAR (10 mg/kg) via oral gavage for 14 days and a single i.p. injection of CdCl<sub>2</sub> (1.2 mg/kg) [35] (Sigma, USA) on day 7. FAR and CdCl<sub>2</sub> were administered in 0.5% CMC and 0.9% saline as vehicles, respectively. 24 h after the last treatment, the rats were anesthetized with ketamine/xylazine and blood was collected via cardiac puncture. After dissection, kidney samples were fixed in 10% neutral buffered formalin (NBF) and another set of samples was stored in RIPA buffer with proteinase inhibitors at -80°C. Other samples were used for biochemical assays following homogenization in cold Tris-HCl buffer (10 mM, pH = 7.4).

## **2.2. Biochemical assays**

Creatinine, urea and uric acid in serum, malondialdehyde (MDA), superoxide dismutase (SOD), GSH, and catalase (CAT) in kidney homogenate were measured using Bio-diagnostic (Egypt) kits. Interleukin-1beta (IL-1 $\beta$ ), IL-6, tumor necrosis factor (TNF)- $\alpha$  were assayed using ELISA kits (ELabsience, China).

## **2.3. Histopathology and immunohistochemical investigations**

Following fixation of the kidney samples in 10% NBF for 24 h, the samples were dehydrated in ethyl alcohol series, cleared in xylene, infiltrated in pure soft paraffin, and embedded in paraffin. Five- $\mu$ m sections were prepared using a microtome and stained with H&E, periodic acid-Schiff (PAS), and Sirius red. Other sections were processed for staining with anti-peroxisome proliferator activated receptor (PPAR)- $\gamma$ , anti-nuclear factor-kappaB (NF- $\kappa$ B) p65, anti-iNOS, and anti-cytoglobin (Biospes, China). In brief, paraffin was removed and the sections were rehydrated and treated with 0.05 M citrate buffer (pH 6.8) and 0.3% H<sub>2</sub>O<sub>2</sub>. After blocking and incubation with 1<sup>st</sup> antibodies overnight at 4°C, the sections were washed,

incubated with 2<sup>nd</sup> antibodies (Biospes, China), followed by DAB in H<sub>2</sub>O<sub>2</sub>. Counterstaining with hematoxylin was carried out and color intensity was measured in captured images (6/rat) using ImageJ (NIH, USA).

#### **2.4. Western blotting**

Kidney samples in RIPA buffer were homogenized, centrifuged and protein in the supernatant was assayed using Bradford reagent. Forty µg protein was electrophoresed on SDS-PAGE and the separated protein was transferred onto PVDF membranes. After blocking in 5% bovine serum albumin (BSA), the membranes were probed with antibodies for alpha-smooth muscle actin (α-SMA), mixed lineage kinase domain-like protein (MLKL), receptor interacting protein kinase (RIP)-1, RIP3, caspase-8, and β-actin (Biospes, China) overnight at 4 °C. Following incubation with secondary antibodies and washing, the bands were developed, and the band intensity was determined using ImageJ (NIH, USA).

#### **2.5. Statistical analysis**

The results are expressed as mean ± SEM. Group comparisons were carried out using one-way ANOVA and Tukey's tests on GraphPad 8. A P value <0.05 was considered significant.

### **3. Results**

#### **3.1. FAR attenuates Cd-induced kidney dysfunction and tissue injury**

To evaluate the protective effect of FAR against kidney injury induced by Cd, we determined the levels of circulating creatinine, urea and uric acid and carried out histopathological examinations. Cd caused kidney dysfunction and injury as shown by significant elevation of serum creatinine, urea and uric acid (Fig. 1A-C) in rats (P<0.001). FAR remarkably ameliorated creatinine, urea and uric acid in Cd-administered rats (P<0.001). Examination of H&E- and PAS-stained kidney sections showed standard histological structure of renal cortex and positive PAS staining alongside brush border of PTs and basement membrane of proximal and distal tubules in control and FAR-treated rats (Fig. 2). Cd provoked necrotic areas, dilation

of interglomerular space, vacuolation of glomeruli with distributed RBCs, severe degeneration with desquamation of tubular epithelial lining, pyknotic nuclei of lining epithelium, hyaline cast in the tubular lumen, interstitial hemorrhage, and declined PAS staining (Fig. 2). Treatment with FAR resulted in substantial tissue restoration revealed by numerous normal size renal corpuscles with few vacuolations and RBCs, normally assembled tubules with few degenerative changes and apoptotic nuclei, and some inflammatory cells encircling renal corpuscles (Fig. 2).

### **3.2. FAR mitigates Cd-induced kidney OS and inflammation**

Changes in MDA, antioxidants, NF- $\kappa$ B and pro-inflammatory mediators were determined in the kidney of rats to evaluate the protective effect of FAR against Cd-induced OS and inflammation. Cd administration increased kidney MDA (Fig. 3A) and decreased GSH (Fig. 3B), SOD (Fig. 3C) and CAT (Fig. 3E) in rats ( $P < 0.001$ ). FAR effectively decreased kidney MDA and restored GSH and enzymatic antioxidants in Cd-administered rats. IHC revealed upregulated immunostaining of NF- $\kappa$ B p65 in the kidney of rats that received Cd ( $P < 0.001$ ; Fig. 4A-B). Likewise, iNOS (Fig. 4A-B) and the cytokines TNF- $\alpha$ , IL-1 $\beta$  and IL-6 (Fig. 5A-C) revealed a remarkable increase in Cd-treated rats ( $P < 0.001$ ). FAR ameliorated kidney NF- $\kappa$ B p65, iNOS, TNF- $\alpha$ , IL-1 $\beta$  and IL-6 in Cd-challenged rats.

### **3.3. FAR attenuates Cd-induced kidney fibrosis and necroptosis**

The ability of FAR to mitigate Cd-induced fibrosis and necroptosis in the kidney of rats was evaluated through assessment of the expression of  $\alpha$ -SMA, RIP1, RIP3, MLKL and caspase-3, and Sirius red staining of collagen.  $\alpha$ -SMA (Fig. 6A-B) was upregulated significantly in Cd-administered rat kidney which showed increased collagen disposition resulting in interstitial fibrosis (Fig. 6C). Normal and FAR-treated rats showed minimal collagen fiber amount between renal tubules and around renal corpuscles (Fig. 6C). FAR decreased  $\alpha$ -SMA and collagen deposition in the kidney of Cd-administered rats. Moreover, Cd upregulated kidney



RIP1, RIP3, MLKL and caspase-3 as demonstrated in Fig. 6A, D-G ( $P < 0.001$ ), and effect that was ameliorated in FAR-treated rats.

### **3.4. FAR upregulates kidney PPAR $\gamma$ and cytoglobin in Cd-administered rats**

The effects of Cd and/or FAR on the expression of PPAR $\gamma$  and cytoglobin in the kidney of rats were determined using IHC staining. Cd-administered rats showed suppressed kidney PPAR $\gamma$  (Fig. 7A-B) and cytoglobin (Fig. 7A, C) as compared to control rats ( $P < 0.001$ ). Treatment with FAR upregulated kidney PPAR $\gamma$  and cytoglobin in Cd-administered rats. Of note, FAR had no effect on all measurements when supplemented to normal animals.

## **4. Discussion**

Kidney injury is one of the main health issues related to exposure to Cd [17]. Cd enters the body and accumulates within the cells resulting in dysfunction and damage to cell organelles and macromolecules [36]. Although the underlying mechanism is not fully understood, OS has been demonstrated to be central in Cd nephrotoxicity [36]. Owing to its promising antioxidant properties, this study investigated the potential of FAR to prevent OS, inflammation and necroptosis in the kidney of Cd-administered rats.

Cd caused kidney injury evidenced by both biochemical and histopathological findings. Circulating creatinine, urea and uric acid were increased following Cd administration, indicating kidney dysfunction and damage as previously reported [37]. Elevated creatinine is an indicator of disrupted glomerular filtration, an effects that provokes the accumulation of various toxicants within the kidney [38]. In line with the biochemical data, examination of the kidney sections revealed serious tissue damage manifested by necrotic areas, interstitial hemorrhage, dilated interglomerular space, interstitial fibrosis, and severe degeneration of renal tubules. Desquamation and pyknotic nuclei of epithelial lining and hyaline casts were observed in PTs. In the kidney, approximately half of total body Cd accumulates in the PTs and this accumulation suppresses reabsorption and provokes proteinuria [24]. Following its

glomerular filtration, Cd is reabsorbed by the epithelium of PTs and its entry into the cells has been proposed to occur via voltage-dependent  $\text{Ca}^{2+}$  channels, organic cation transporter and several receptors [36]. In addition, the transport of Cd-metallothionein (MT) complexes to the kidney boosts Cd accumulation in the tubular cells. Once absorbed by pulmonary or intestinal cells, Cd enters the systemic circulation and reaches hepatocytes where it induces MT synthesis and the formation of Cd-MT complexes [39]. These complexes are transported to the kidney where Cd is released and facilitates the formation of more Cd-MT complexes [39]. Inhibition of the multidrug and toxin extrusion protein which eliminates cationic drugs and toxins by Cd contributes to its accumulation in kidney cells and their subsequent dysfunction and injury [40]. FAR mitigated Cd-induced kidney damage manifested by decreased creatinine, urea, and uric acid, and amelioration of histopathological alterations. These data demonstrated the nephroprotective efficacy of FAR and run in parallel with our recent study showing the ability of FAR to prevent CPF nephrotoxicity [26]. FAR decreased creatinine and urea and prevented kidney tissue injury induced by CPF [26]. In addition, FAR protected rat kidney against injury induced by Fe-NTA [33]. Given the central involvement of OS and its related inflammatory response in the toxicity of Cd [11] and the demonstrated antioxidant and anti-inflammatory efficacies of FAR [26, 31], the nephroprotective role of FAR could be directly ascribed to mitigation of OS and inflammation. In this study, elevated kidney MDA and declined GSH, SOD and CAT demonstrated OS in Cd-challenged rats. These data are consistent with our previous and other investigators findings of Cd-induced OS not only in the kidney but in different tissues of rodents [8, 41]. Reduced antioxidants and promoted LPO have been associated with ROS produced as a result of Cd exposure [11]. ROS are not produced directly by Cd via redox reactions but  $\bullet\text{O}_2$ ,  $\bullet\text{OH}$ ,  $\text{H}_2\text{O}_2$  are generated indirectly through Fenton-type reactions and other reactions provoked via Cd-mediated liberation of unbound iron [13, 14, 42]. ROS damage cell macromolecules, resulting in cell death, and  $\bullet\text{O}_2$  can react with NO to

generate peroxynitrite that oxidizes DNA and increases ROS [43]. Cd-induced OS is also related to its direct binding to the sulfhydryl groups on GSH and other proteins, leading to depletion of antioxidants [1], and mitochondrial dysfunction that further increases ROS generation [44]. Mitochondrial dysfunction is a key factor in kidney cell death because it is the second organ after the heart with the highest number of mitochondria and oxygen consumption [45]. Moreover, Cd negatively impacts the activity SOD by disturbing its catalytic function [46] and CAT by interacting to its catalytic center [47].

Besides OS, the role of inflammation in Cd toxicity has been acknowledged [48]. Excess ROS and OS provoked by Cd induce an inflammatory response by eliciting many molecules, including NF- $\kappa$ B. Activation of this transcription factor promotes the expression of many cytokines and therefore the development of an inflammatory response. Cd is among the environmental agents known to promote the release of inflammatory mediators [48]. In accordance, Cd upregulated NF- $\kappa$ B and its regulated inflammatory mediators IL-6, IL-1 $\beta$ , TNF- $\alpha$ , and iNOS, demonstrating an inflammatory response. In this context, Cd induced inflammation in rat kidney [37, 49], murine hepatocytes [48] and human hepatoma cell line HepG2 [50]. In these studies, Cd promoted inflammation by upregulating IL-6, IL-1 $\beta$ , TNF- $\alpha$ , and iNOS [37, 49]. The produced cytokines along with ROS promote cell death via a programmed form of necrotic cell death called necroptosis [16, 51]. Here, Cd caused necroptosis as shown by upregulated RIP1, RIP3, MLKL and caspase-8. Necroptosis is inflammation-driven type of cell death that results in morphological changes similar to apoptosis [52]. RIP3 is a serine/threonine kinase that is central in necroptosis via its association with RIP1 to form necrosome that recruits MLKL. This results in plasma membrane disruption and endogenous molecules are released outside the cell [53]. IL-1 $\beta$  and TNF- $\alpha$  are necroptosis-inducing factors [54], and ROS are a driving force for necroptosis [55]. TNF- $\alpha$  induces mitochondrial ROS generation resulting in enhancement of necrosome formation [56].

Moreover, RIP1 can sense ROS through cysteine residues modification of and subsequent phosphorylation on S161 resulting in efficient recruitment of RIP3 and necrosome formation [57]. Therefore, attenuation of OS and inflammation is effective in inhibition of necroptosis. FAR prevented kidney OS, inflammation and necroptosis in Cd-administered rats, findings that explain the observed nephroprotection. Treatment with FAR remarkably suppressed LPO, NF- $\kappa$ B, pro-inflammatory mediators, RIP3, RIP1, MLKL and caspase-8. These findings demonstrated the potent efficacy of FAR against Cd-induced kidney OS, inflammatory response and necroptotic cell death. We have previously reported the ability of FAR to prevent OS and inflammation associated with hypercholesterolemia [30] and exposure to the pesticide CPF [26]. Other studies have demonstrated the beneficial effect of FAR against inflammation and OS in other organs [58-60]. In murine asthma, FAR mitigated inflammation via TNF- $\alpha$  suppression in the lung [58]. FAR prevented LPO and inflammation and enhanced antioxidants in the lung of rats following exposure to cigarette smoke extract [59], and downregulated TNF- $\alpha$ , IL-6, and iNOS levels in mice with gliosis [61]. Furthermore, FAR prevented early tumorigenesis and oxidative damage in the kidney of Fe-NTA-induced rats [33], and downregulated inflammatory genes in primary human renal epithelial cells [62]. Our findings added support to the efficacy of FAR to mitigate OS and inflammation. In addition, our study introduced new information that FAR can prevent necroptosis associated with Cd nephrotoxicity. Furthermore, we investigated the effect of FAR on PPAR $\gamma$  and cytoglobin in the kidney of Cd-administered rats. PPAR $\gamma$  is a transcription factor that suppresses OS, inflammation and fibrogenesis when activated [63]. Cd administration suppressed kidney PPAR $\gamma$  in rats, an effect that was prevented in FAR-supplemented rats. PPAR $\gamma$  activation enhances antioxidant enzymes and suppress inflammation by preventing NF- $\kappa$ B activation. PPAR $\gamma$  controls the transcriptional activity of NF- $\kappa$ B, reduces p65 nuclear translocation and inhibits I $\kappa$ B $\alpha$  degradation [64, 65]. PPAR $\gamma$  activation suppressed fibrogenesis in different

organs by downregulating the TGF- $\beta$ /Smad signaling and expression of  $\alpha$ -SMA [66]. This explained the ability of FAR to suppress  $\alpha$ -SMA and fibrosis in the kidney of Cd-administered rats. The positive effect of FAR on PPAR $\gamma$  has been scarcely reported. Torabi and Mo [67] demonstrated PPAR $\gamma$  upregulation in FAR-treated pre-adipocytes, and Vivas et al [68] reported the role of PPAR $\gamma$  upregulation in mediating the effect of FAR on the maturation of human dendritic cells. Our data supported the positive effect of FAR on PPAR $\gamma$  and pointed to its involvement in the protective effect of FAR on Cd nephrotoxicity. The observed potent efficacy of FAR on Cd-induced OS could also be connected to its ability to upregulate cytoglobin, a new information introduced in this study. Cytoglobin is a defensive protein found within the cells and functions to scavenge ROS and prevent OS, thereby maintaining cellular redox balance [69]. Studies revealed that cytoglobin suppression promotes cell injury via oxidative DNA damage whereas its upregulation suppressed ROS and prevents cell death [69, 70]. Interestingly, Zweier et al [71] reported the SOD activity of cytoglobin and its mediated effective suppression of  $\bullet$ O<sub>2</sub>, NO and peroxynitrite formation. Furthermore, cells and organs lacking cytoglobin exhibited a high susceptibility to fibrogenesis and inflammation following exposure to radiation [69].

## **5. Conclusion**

The findings of this study introduced novel information on the protective role and possible underlying mechanism of FAR on Cd nephrotoxicity. Cd induced kidney tissue injury, inflammation, OS, fibrogenesis and necroptosis and declined PPAR $\gamma$  and cytoglobin in rats. FAR prevented kidney injury by attenuating OS, inflammation, and necroptosis, and enhancement of PPAR $\gamma$  and antioxidants. Therefore, FAR effectively protected the kidney of rats against Cd toxicity and could be invaluable to protect individuals at risk of Cd toxicity.

Nevertheless, further studies to elucidate the underlying mechanisms and clinical trials are recommended.

#### Acknowledgment

Princess Nourah bint Abdulrahman University Researchers Supporting Project Number (PNURSP2024R381), Princess Nourah bint Abdulrahman University, Riyadh, Saudi Arabia.

#### Declaration of Competing Interest

All authors declare no conflict of interests in relation to the manuscript.

#### Ethics declarations:

All animal experiments comply with the National Institutes of Health guide for the care and use of Laboratory animals (NIH Publications No. 8523, revised 1996). The study was approved by the ethics committee of Al-Azhar University (AZ-AS/PH-REC/43/24).

#### Availability of data and materials

The manuscript contains all data supporting the reported results.

#### References:

- [1] K. Renu, R. Chakraborty, H. Myakala, R. Koti, A.C. Famurewa, H. Madhyastha, B. Vellingiri, A. George, A. Valsala Gopalakrishnan, Molecular mechanism of heavy metals (Lead, Chromium, Arsenic, Mercury, Nickel and Cadmium) - induced hepatotoxicity – A review, *Chemosphere* 271 (2021) 129735.
- [2] L.T. Friberg, G.-G. Elinder, T. Kjellstrom, G.F. Nordberg, *Cadmium and health: A toxicological and epidemiological appraisal: Volume 2: Effects and response*, CRC press 2019.
- [3] L. Järup, A. Åkesson, Current status of cadmium as an environmental health problem, *Toxicology and applied pharmacology* 238(3) (2009) 201-208.
- [4] F.S. Al-Otaibi, J.S. Ajarem, M.A. Abdel-Maksoud, S. Maooda, A.A. Allam, G.I. Al-Basher, A.M. Mahmoud, Stone quarrying induces organ dysfunction and oxidative stress in *Meriones libycus*, *Toxicol Ind Health* 34(10) (2018) 679-692.
- [5] A. Almalki, J. Ajarem, A.A. A, A.E.-S. H, N.M. S, M.M. A, Use of *Spilopelia senegalensis* as a Biomonitor of Heavy Metal Contamination from Mining Activities in Riyadh (Saudi Arabia), *Animals (Basel)* 9(12) (2019).
- [6] B.A. Rzigalinski, J.S. Strobl, Cadmium-containing nanoparticles: perspectives on pharmacology and toxicology of quantum dots, *Toxicol Appl Pharmacol* 238(3) (2009) 280-8.
- [7] S. Satarug, S.H. Garrett, M.A. Sens, D.A. Sens, Cadmium, Environmental Exposure, and Health Outcomes, *Environmental Health Perspectives* 118(2) (2010) 182-190.

- [8] R.S. Alruhaimi, E.H. Hassanein, M.N. Bin-Jumah, A.M. Mahmoud, Cadmium cardiotoxicity is associated with oxidative stress and upregulated TLR-4/NF- $\kappa$ B pathway in rats; protective role of agomelatine, *Food and Chemical Toxicology* 180 (2023) 114055.
- [9] I.A.f.R.o. Cancer, I.A.f.R.o. Cancer, Beryllium, cadmium, mercury, and exposures in the glass manufacturing industry, IARC, World Health Organization 1993.
- [10] D.A. Vesey, Transport pathways for cadmium in the intestine and kidney proximal tubule: focus on the interaction with essential metals, *Toxicol Lett* 198(1) (2010) 13-9.
- [11] J. Liu, W. Qu, M.B. Kadiiska, Role of oxidative stress in cadmium toxicity and carcinogenesis, *Toxicology and applied pharmacology* 238(3) (2009) 209-214.
- [12] A.-J. Lin, X.-H. Zhang, M.-M. Chen, C. Qing, Oxidative stress and DNA damages induced by cadmium accumulation, *Journal of Environmental Sciences* 19(5) (2007) 596-602.
- [13] C.O. Ikediobi, V.L. Badisa, L.T. Ayuk-Takem, L.M. Latinwo, J. West, Response of antioxidant enzymes and redox metabolites to cadmium-induced oxidative stress in CRL-1439 normal rat liver cells, *Int J Mol Med* 14(1) (2004) 87-92.
- [14] A. Cuypers, M. Plusquin, T. Remans, M. Jozefczak, E. Keunen, H. Gielen, K. Opdenakker, A.R. Nair, E. Munters, T.J. Artois, Cadmium stress: an oxidative challenge, *Biometals* 23 (2010) 927-940.
- [15] Z. Wang, Y. Sun, W. Yao, Q. Ba, H. Wang, Effects of Cadmium Exposure on the Immune System and Immunoregulation, *Front Immunol* 12 (2021) 695484.
- [16] J. Wei, L. Chen, D. Wang, L. Tang, Z. Xie, W. Chen, S. Zhang, G. Weng, Upregulation of RIP3 promotes necroptosis via a ROS-dependent NF- $\kappa$ B pathway to induce chronic inflammation in HK-2 cells, *Mol Med Rep* 24(5) (2021).
- [17] E.C. Moody, S.G. Coca, A.P. Sanders, Toxic Metals and Chronic Kidney Disease: a Systematic Review of Recent Literature, *Curr Environ Health Rep* 5(4) (2018) 453-463.
- [18] X. Lv, M. Ren, T. Xu, M. Gao, H. Liu, H. Lin, Selenium alleviates lead-induced CIK cells pyroptosis and inflammation through IRAK1/TAK1/IKK pathway, *Fish Shellfish Immunol* 142 (2023) 109101.
- [19] S. Satarug, Dietary Cadmium Intake and Its Effects on Kidneys, *Toxics* 6(1) (2018).
- [20] A.E. Egger, G. Grabmann, C. Gollmann-Tepeköylü, E.J. Pechriggl, C. Artner, A. Türkcan, C.G. Hartinger, H. Fritsch, B.K. Keppler, E. Brenner, M. Grimm, B. Messner, D. Bernhard, Chemical imaging and assessment of cadmium distribution in the human body, *Metallomics* 11(12) (2019) 2010-2019.
- [21] J.L. Young, X. Yan, J. Xu, X. Yin, X. Zhang, G.E. Arteel, G.N. Barnes, J.C. States, W.H. Watson, M. Kong, L. Cai, J.H. Freedman, Cadmium and High-Fat Diet Disrupt Renal, Cardiac and Hepatic Essential Metals, *Sci Rep* 9(1) (2019) 14675.
- [22] P. Lentini, L. Zanolli, A. Granata, S.S. Signorelli, P. Castellino, R. Dell'Aquila, Kidney and heavy metals - The role of environmental exposure (Review), *Mol Med Rep* 15(5) (2017) 3413-3419.
- [23] B.A. Fowler, Mechanisms of kidney cell injury from metals, *Environ Health Perspect* 100 (1993) 57-63.
- [24] H. Yang, Y. Shu, Cadmium transporters in the kidney and cadmium-induced nephrotoxicity, *Int J Mol Sci* 16(1) (2015) 1484-94.
- [25] G. Gobe, D. Crane, Mitochondria, reactive oxygen species and cadmium toxicity in the kidney, *Toxicol Lett* 198(1) (2010) 49-55.
- [26] R.S. Alruhaimi, M.F. Alotaibi, S.M. Alnasser, M.A. Alzoghaibi, M.O. Germoush, M. Alotaibi, E.H.M. Hassanein, A.M. Mahmoud, Farnesol prevents chlorpyrifos nephrotoxicity by modulating inflammatory mediators, Nrf2 and FXR and attenuating oxidative stress, *Food Chem Toxicol* 190 (2024) 114788.
- [27] J. Huang, Y. Liang, L. Zhou, Natural products for kidney disease treatment: Focus on targeting mitochondrial dysfunction, *Front Pharmacol* 14 (2023) 1142001.

- [28] A.M. Sayed, E.H.M. Hassanein, S.H. Salem, O.E. Hussein, A.M. Mahmoud, Flavonoids-mediated SIRT1 signaling activation in hepatic disorders, *Life Sci* 259 (2020) 118173.
- [29] R. Santhanasabapathy, G. Sudhandiran, Farnesol attenuates lipopolysaccharide-induced neurodegeneration in Swiss albino mice by regulating intrinsic apoptotic cascade, *Brain Research* 1620 (2015) 42-56.
- [30] M.H. Abukhalil, O.E. Hussein, M. Bin-Jumah, S.A.M. Saghir, M.O. Germoush, H.A. Elgebaly, N.M. Mosa, I. Hamad, M.M. Qarmush, E.M. Hassanein, E.M. Kamel, R. Hernandez-Bautista, A.M. Mahmoud, Farnesol attenuates oxidative stress and liver injury and modulates fatty acid synthase and acetyl-CoA carboxylase in high cholesterol-fed rats, *Environmental Science and Pollution Research* 27(24) (2020) 30118-30132.
- [31] Y.Y. Jung, S.T. Hwang, G. Sethi, L. Fan, F. Arfuso, K.S. Ahn, Potential anti-inflammatory and anti-cancer properties of farnesol, *Molecules* 23(11) (2018) 2827.
- [32] G. de Araújo Delmondes, D.S. Bezerra, D. de Queiroz Dias, A. de Souza Borges, I.M. Araújo, G. Lins da Cunha, P.F.R. Bandeira, R. Barbosa, H.D. Melo Coutinho, C.F.B. Felipe, J.M. Barbosa-Filho, I.R. Alencar de Menezes, M.R. Kerntopf, Toxicological and pharmacologic effects of farnesol (C<sub>15</sub>H<sub>26</sub>O): A descriptive systematic review, *Food and Chemical Toxicology* 129 (2019) 169-200.
- [33] T. Jahangir, T.H. Khan, L. Prasad, S. Sultana, Farnesol prevents Fe-NTA-mediated renal oxidative stress and early tumour promotion markers in rats, *Human & experimental toxicology* 25(5) (2006) 235-242.
- [34] R. Gayatri Devi, D. Ezhilarasan, Concurrent administration of farnesol protects acetaminophen-induced acute hepatic necrosis in mice, *J Biochem Mol Toxicol* 37(11) (2023) e23478.
- [35] E.C. de Lima, C.F.G. de Moura, M.J.D. Silva, W. Vilegas, A.B. Santamarina, L.P. Pisani, F. de Oliveira, D.A. Ribeiro, Therapeutical properties of *Mimosa caesalpinifolia* in rat liver intoxicated with cadmium, *Environmental science and pollution research international* 27(10) (2020) 10981-10989.
- [36] E.Y. Hernández-Cruz, I. Amador-Martínez, A.K. Aranda-Rivera, A. Cruz-Gregorio, J. Pedraza Chaverri, Renal damage induced by cadmium and its possible therapy by mitochondrial transplantation, *Chemico-Biological Interactions* 361 (2022) 109961.
- [37] M. Umar Ijaz, M. Batool, A. Batool, K.A. Al-Ghanim, S. Zafar, A. Ashraf, F. Al-Misned, Z. Ahmed, S. Shahzadi, A. Samad, U. Atique, N. Al-Mulhm, S. Mahboob, Protective effects of vitexin on cadmium-induced renal toxicity in rats, *Saudi J Biol Sci* 28(10) (2021) 5860-5864.
- [38] S.E. Orr, C.C. Bridges, Chronic Kidney Disease and Exposure to Nephrotoxic Metals, *Int J Mol Sci* 18(5) (2017).
- [39] I. Sabolić, D. Breljak, M. Škarica, C.M. Herak-Kramberger, Role of metallothionein in cadmium traffic and toxicity in kidneys and other mammalian organs, *BioMetals* 23(5) (2010) 897-926.
- [40] H. Yang, S. Zhou, D. Guo, O.N. Obianom, Q. Li, Y. Shu, Divergent Regulation of OCT and MATE Drug Transporters by Cadmium Exposure, *Pharmaceutics* 13(4) (2021).
- [41] R.S. Alruhaimi, E.H.M. Hassanein, M.K. Abd El-Aziz, M. Siddiq Abduh, A. Bin-Ammar, E.M. Kamel, A.M. Mahmoud, The melatonin receptor agonist agomelatine protects against acute pancreatitis induced by cadmium by attenuating inflammation and oxidative stress and modulating Nrf2/HO-1 pathway, *International Immunopharmacology* 124 (2023) 110833.
- [42] E. Casalino, C. Sblano, C. Landriscina, Enzyme activity alteration by cadmium administration to rats: the possibility of iron involvement in lipid peroxidation, *Archives of biochemistry and biophysics* 346(2) (1997) 171-179.
- [43] P. Pacher, J.S. Beckman, L. Liaudet, Nitric Oxide and Peroxynitrite in Health and Disease, *Physiol Rev.* 87(1) (2007) 315-424.
- [44] K. Qi, L. Ren, Z. Bai, J. Yan, X. Deng, J. Zhang, Y. Peng, X. Li, Detecting cadmium during ultrastructural characterization of hepatotoxicity, *J Trace Elem Med Biol* 62 (2020) 126644.



- [45] J.M. Forbes, Mitochondria-Power Players in Kidney Function?, *Trends in Endocrinology and Metabolism* 27(7) (2016) 441-442.
- [46] E. Casalino, G. Calzaretto, C. Sblano, C. Landriscina, Molecular inhibitory mechanisms of antioxidant enzymes in rat liver and kidney by cadmium, *Toxicology* 179(1-2) (2002) 37-50.
- [47] T. Wrońska-Nofer, J. Wisniewska-Knypl, E. Dziubaltowska, K. Wyszzyńska, Prooxidative and genotoxic effect of transition metals (cadmium, nickel, chromium, and vanadium) in mice, *Trace Elements and Electrocytes* 16(2) (1999) 87-92.
- [48] L. Liu, R. Tao, J. Huang, X. He, L. Qu, Y. Jin, S. Zhang, Z. Fu, Hepatic oxidative stress and inflammatory responses with cadmium exposure in male mice, *Environmental Toxicology and Pharmacology* 39(1) (2015) 229-236.
- [49] S. Das, S. Dewanjee, T.K. Dua, S. Joardar, P. Chakraborty, S. Bhowmick, A. Saha, S. Bhattacharjee, V. De Feo, Carnosic Acid Attenuates Cadmium Induced Nephrotoxicity by Inhibiting Oxidative Stress, Promoting Nrf2/HO-1 Signalling and Impairing TGF- $\beta$ 1/Smad/Collagen IV Signalling, *Molecules* 24(22) (2019).
- [50] V. Souza, M. del Carmen Escobar, L. Gómez-Quiroz, L. Bucio, E. Hernández, E.C. Cossio, M.C. Gutiérrez-Ruiz, Acute cadmium exposure enhances AP-1 DNA binding and induces cytokines expression and heat shock protein 70 in HepG2 cells, *Toxicology* 197(3) (2004) 213-228.
- [51] Y. Lei, T. Xu, W. Sun, X. Wang, M. Gao, H. Lin, Evodiamine alleviates DEHP-induced hepatocyte pyroptosis, necroptosis and immunosuppression in grass carp through ROS-regulated TLR4 / MyD88 / NF- $\kappa$ B pathway, *Fish Shellfish Immunol* 140 (2023) 108995.
- [52] T.V. Berghe, N. Vanlangenakker, E. Parthoens, W. Deckers, M. Devos, N. Festjens, C.J. Guerin, U.T. Brunk, W. Declercq, P. Vandenabeele, Necroptosis, necrosis and secondary necrosis converge on similar cellular disintegration features, *Cell Death & Differentiation* 17(6) (2010) 922-930.
- [53] H. Wang, L. Sun, L. Su, J. Rizo, L. Liu, L.F. Wang, F.S. Wang, X. Wang, Mixed lineage kinase domain-like protein MLKL causes necrotic membrane disruption upon phosphorylation by RIP3, *Mol Cell* 54(1) (2014) 133-146.
- [54] W. Declercq, T. Vanden Berghe, P. Vandenabeele, RIP kinases at the crossroads of cell death and survival, *Cell* 138(2) (2009) 229-32.
- [55] W. Li, X. Yuan, G. Nordgren, H. Dalen, G.M. Dubowchik, R.A. Firestone, U.T. Brunk, Induction of cell death by the lysosomotropic detergent MSDH, *FEBS Lett* 470(1) (2000) 35-9.
- [56] V. Goossens, J. Grooten, K. De Vos, W. Fiers, Direct evidence for tumor necrosis factor-induced mitochondrial reactive oxygen intermediates and their involvement in cytotoxicity, *Proc Natl Acad Sci U S A* 92(18) (1995) 8115-9.
- [57] Y. Zhang, S.S. Su, S. Zhao, Z. Yang, C.Q. Zhong, X. Chen, Q. Cai, Z.H. Yang, D. Huang, R. Wu, J. Han, RIP1 autophosphorylation is promoted by mitochondrial ROS and is essential for RIP3 recruitment into necrosome, *Nat Commun* 8 (2017) 14329.
- [58] C.-M. Ku, J.-Y. Lin, Farnesol, a sesquiterpene alcohol in herbal plants, exerts anti-inflammatory and antiallergic effects on ovalbumin-sensitized and-challenged asthmatic mice, *Evidence-Based Complementary and Alternative Medicine* 2015 (2015).
- [59] W. Qamar, S. Sultana, Farnesol ameliorates massive inflammation, oxidative stress and lung injury induced by intratracheal instillation of cigarette smoke extract in rats: an initial step in lung chemoprevention, *Chemico-biological interactions* 176(2-3) (2008) 79-87.
- [60] R. Khan, S. Sultana, Farnesol attenuates 1, 2-dimethylhydrazine induced oxidative stress, inflammation and apoptotic responses in the colon of Wistar rats, *Chemico-biological interactions* 192(3) (2011) 193-200.
- [61] R. Santhanasabapathy, S. Vasudevan, K. Anupriya, R. Pabitha, G. Sudhandiran, Farnesol quells oxidative stress, reactive gliosis and inflammation during acrylamide-induced neurotoxicity: Behavioral and biochemical evidence, *Neuroscience* 308 (2015) 212-227.

- [62] A. Müller, M. Lozoya, X. Chen, V. Weissig, M. Nourbakhsh, Farnesol Inhibits PI3 Kinase Signaling and Inflammatory Gene Expression in Primary Human Renal Epithelial Cells, *Biomedicines* 11(12) (2023).
- [63] A.M. Mahmoud, M.Y. Alexander, Y. Tutar, F.L. Wilkinson, A. Venditti, Oxidative Stress in Metabolic Disorders and Drug-Induced Injury: The Potential Role of Nrf2 and PPARs Activators, *Oxid Med Cell Longev* 2017 (2017) 2508909.
- [64] S. Kersten, B. Desvergne, W. Wahli, Roles of PPARs in health and disease, *Nature* 405(6785) (2000) 421-424.
- [65] A.H. Remels, R.C. Langen, H.R. Gosker, A.P. Russell, F. Spaapen, J.W. Voncken, P. Schrauwen, A.M. Schols, PPARgamma inhibits NF-kappaB-dependent transcriptional activation in skeletal muscle, *Am J Physiol Endocrinol Metab.* 297(1) (2009) E174-E183.
- [66] A.M. Mahmoud, W.G. Hozayen, I.H. Hasan, E. Shaban, M. Bin-Jumah, Umbelliferone Ameliorates CCl4-Induced Liver Fibrosis in Rats by Upregulating PPAR $\gamma$  and Attenuating Oxidative Stress, Inflammation, and TGF- $\beta$ 1/Smad3 Signaling, *Inflammation* 42(3) (2019) 1103-1116.
- [67] S. Torabi, H. Mo, Trans, trans-farnesol as a mevalonate-derived inducer of murine 3T3-F442A pre-adipocyte differentiation, *Exp Biol Med (Maywood)* 241(5) (2016) 493-500.
- [68] W. Vivas, I. Leonhardt, K. Hünninger, A. Häder, A. Marolda, O. Kurzai, Multiple Signaling Pathways Involved in Human Dendritic Cell Maturation Are Affected by the Fungal Quorum-Sensing Molecule Farnesol, *The Journal of Immunology* 203(11) (2019) 2959-2969.
- [69] F.E. McDonald, J.M. Risk, N.J. Hodges, Protection from intracellular oxidative stress by cytoglobin in normal and cancerous oesophageal cells, *PloS one* 7(2) (2012) e30587.
- [70] N.J. Hodges, N. Innocent, S. Dhanda, M. Graham, Cellular protection from oxidative DNA damage by over-expression of the novel globin cytoglobin in vitro, *Mutagenesis* 23(4) (2008) 293-8.
- [71] J.L. Zweier, C. Hemann, T. Kundu, M.G. Ewees, S.A. Khaleel, A. Samouilov, G. Ilangoan, M.A. El-Mahdy, Cytoglobin has potent superoxide dismutase function, *Proceedings of the National Academy of Sciences* 118(52) (2021) e2105053118.

Figures:

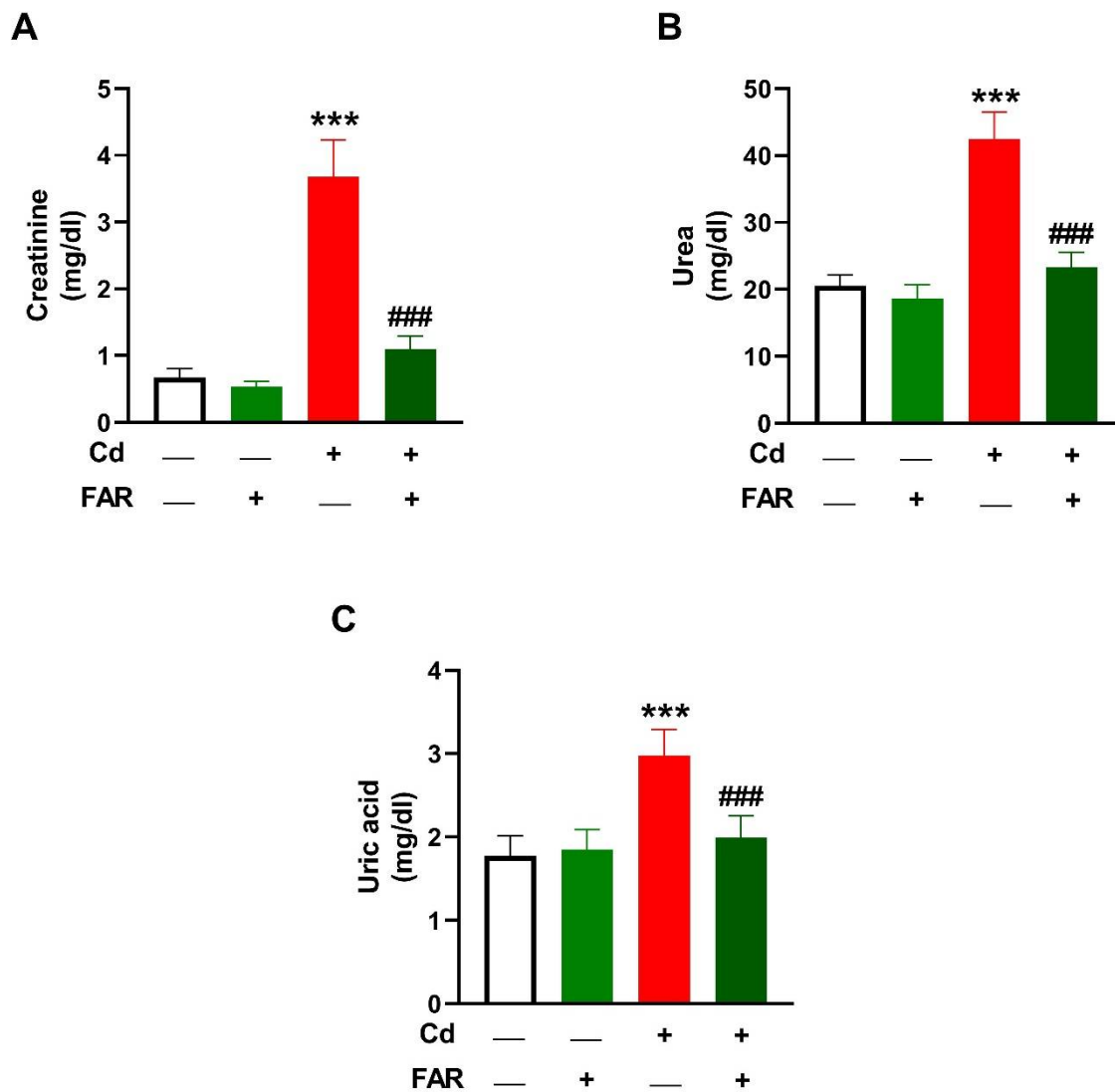


Figure 1. FAR ameliorated serum creatinine (A), urea (B), and uric acid (C) in Cd-administered rats. Data are mean  $\pm$  SD, ( $n = 6$ ). \*\*\* $P < 0.001$  versus Control. ### $P < 0.001$  versus Cd.

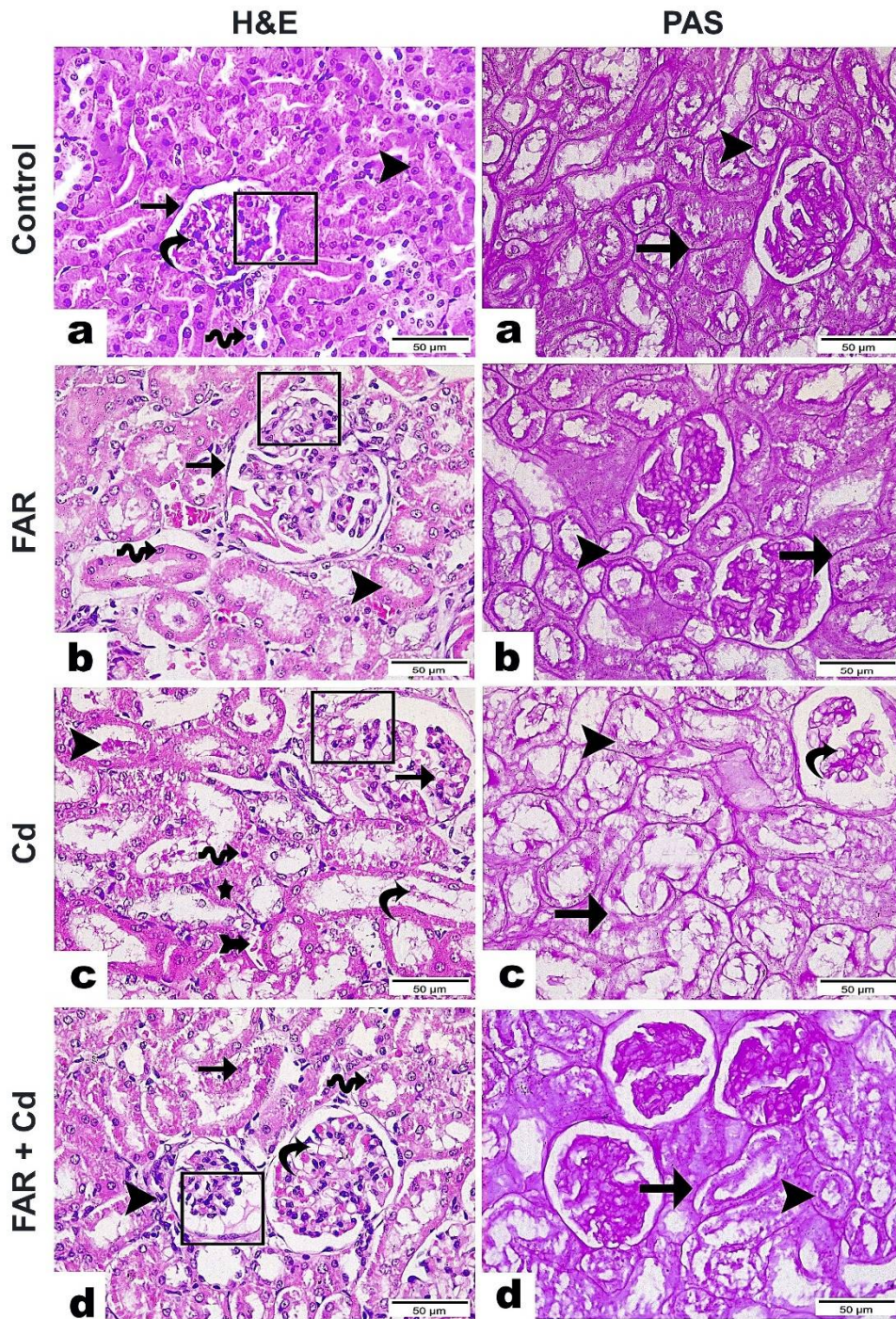


Figure 2. Photomicrographs show the nephroprotective effect of FAR on histopathological alterations induced by Cd. **H&E**: Kidney sections from control (a) and FAR-treated (b) rats showing normal renal corpuscles (rectangle), Bowman's capsule (arrow), glomeruli (curve arrow), and proximal (wave arrow) as well as distal (arrowhead) convoluted tubules.; Cd-administered group (c) showing necrotic areas (star), dilated interglomerular space (rectangle), vacuolated glomeruli with distributed RBCs (arrow), severe tubular degeneration with desquamation of epithelial lining (curvy arrow), pyknotic nuclei (wave arrow), hyaline cast (arrowhead), and interstitial hemorrhage (arrow with tail); and Cd-administered rats treated with FAR (d) showing substantial tissue restoration revealed by normal size renal corpuscles with few vacuolations and RBCs (curvy arrow), while other corpuscles were small in size and

showed dilated interglomerular space (rectangle), mostly normal renal tubules (wave arrow) but some appeared degenerated with apoptotic nuclei (arrow), and some inflammatory cells encircling renal corpuscle (arrowhead). (x400, Scale bar= 50  $\mu$ m). **PAS:** Kidney sections from control (a) and FAR-treated (b) rats showing positive PAS staining alongside brush border of proximal convoluted tubule (arrowhead) and basement membrane of proximal and distal convoluted tubules (arrow); Cd-administered group (c) showing noticeable decline in PAS staining along vacuolated glomerulus (curvy arrow), brush border of proximal convoluted tubule (arrowhead), and basement membrane tubules (arrow); and Cd-administered rats treated with FAR (d) showing marked increase in staining intensity. (x400, Scale bar= 50  $\mu$ m).

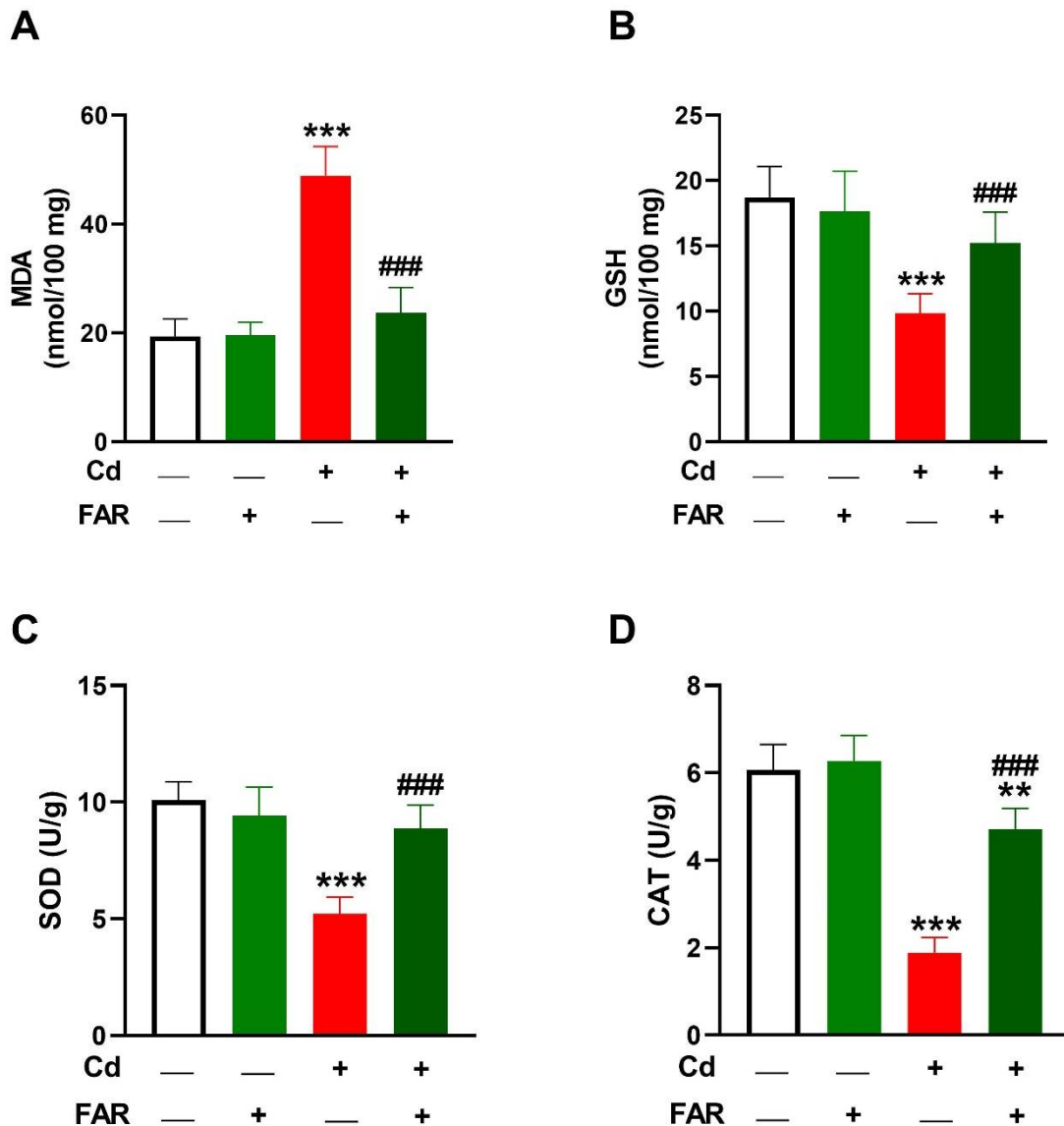


Figure 3. FAR decreased kidney MDA (A), and increased GSH (C), SOD (D), and catalase (E) in Cd-administered rats. Data are mean  $\pm$  SD, ( $n = 6$ ). \*\* $P < 0.01$ , and \*\*\* $P < 0.001$  versus Control. #### $P < 0.001$  versus Cd.

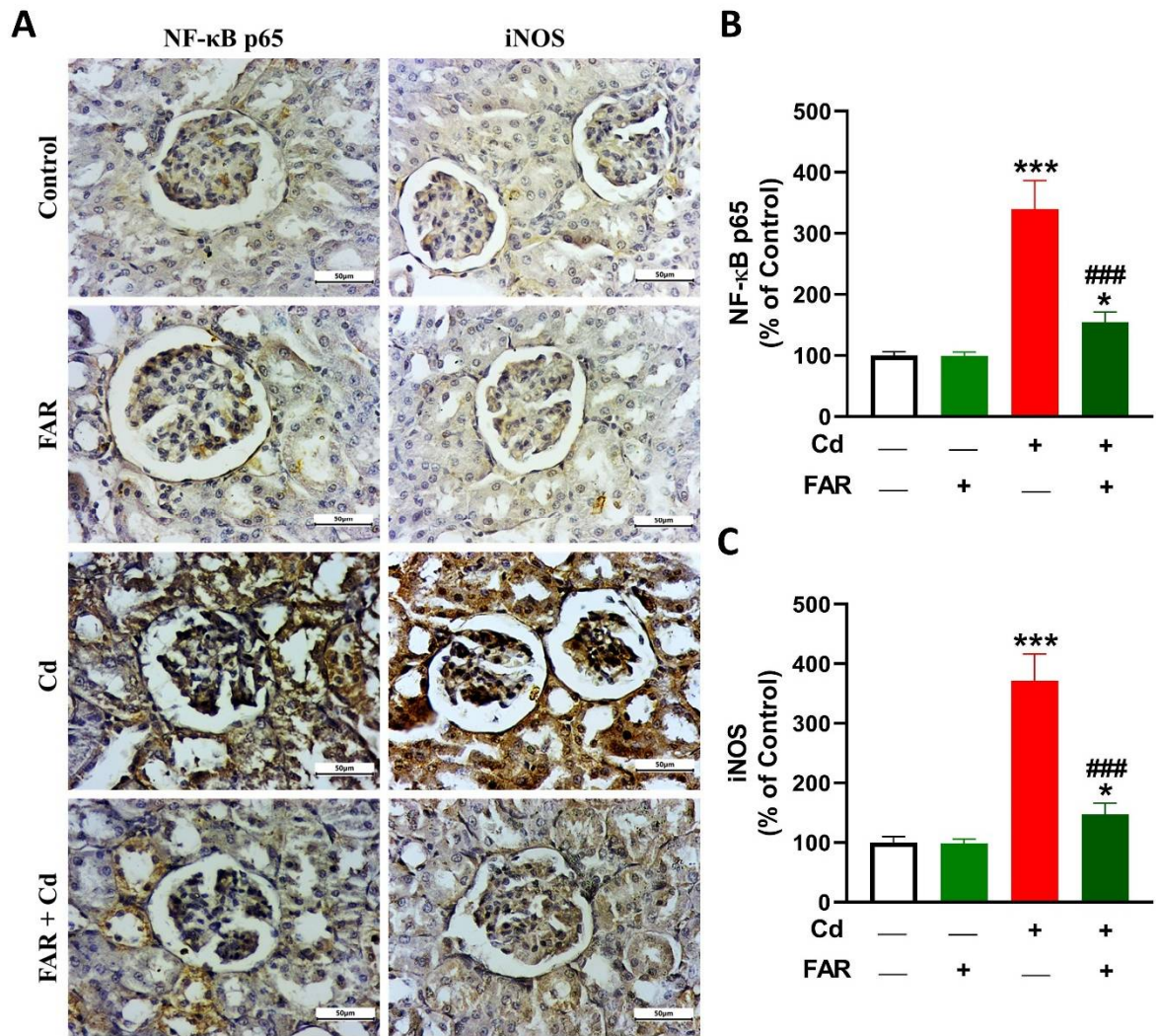


Figure 4. FAR downregulated kidney NF- $\kappa$ B p65 (A,B) and iNOS (A,C) in Cd-administered rats. Data are mean  $\pm$  SD, ( $n = 6$ ). \* $P < 0.05$  and \*\*\* $P < 0.001$  versus Control. ### $P < 0.001$  versus Cd.

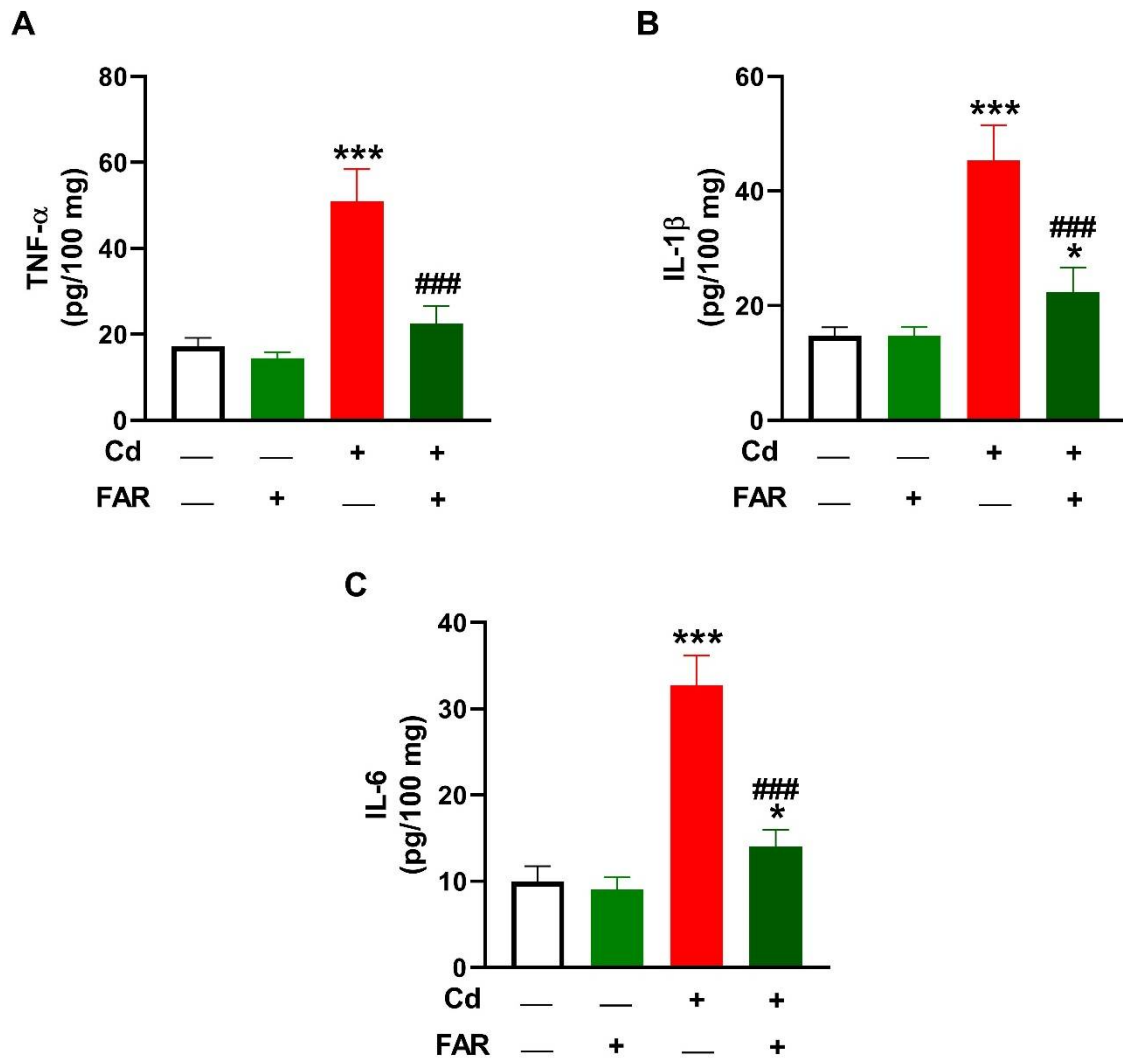


Figure 5. FAR decreased kidney TNF- $\alpha$  (A), IL-1 $\beta$  (B), and IL-6 (C) in Cd-administered rats. Data are mean  $\pm$  SD, ( $n = 6$ ). \* $P < 0.05$  and \*\*\* $P < 0.001$  versus Control. ### $P < 0.001$  versus Cd.

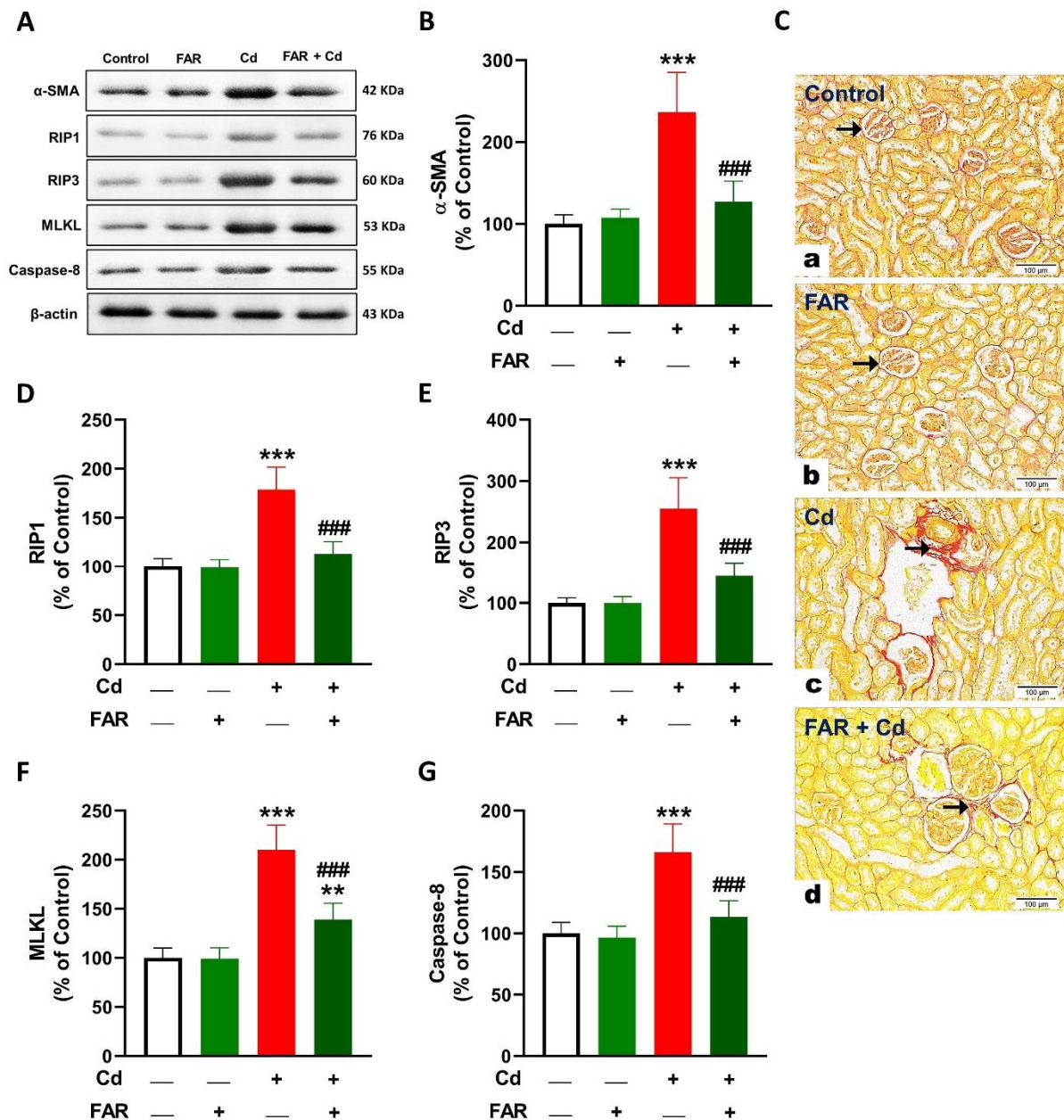


Figure 6. FAR attenuated fibrosis and necroptosis in kidney of Cd-administered rats. (A, B) FAR decreased kidney  $\alpha$ -SMA in Cd-administered rats. (C) Sirius red-stained kidney sections from control (a) and FAR-treated (b) rats showing little collagen fiber interstitial between renal tubules and encircle renal corpuscle (arrows); Cd-administered group (c) showing high amount of collagen (arrow); and Cd-administered rats treated with FAR (d) showing noticeable decline in collagen fibers (arrow). (x200, Scale bar= 100  $\mu$ m). (A, D-G) FAR downregulated RIP1 (D), RIP3 (E), MLKL (F) and caspase-8 (G) in Cd-administered rat kidney. Data are mean  $\pm$  SD, ( $n = 6$ ). \*\* $P < 0.01$  and \*\*\* $P < 0.001$  versus Control. ### $P < 0.001$  versus Cd.



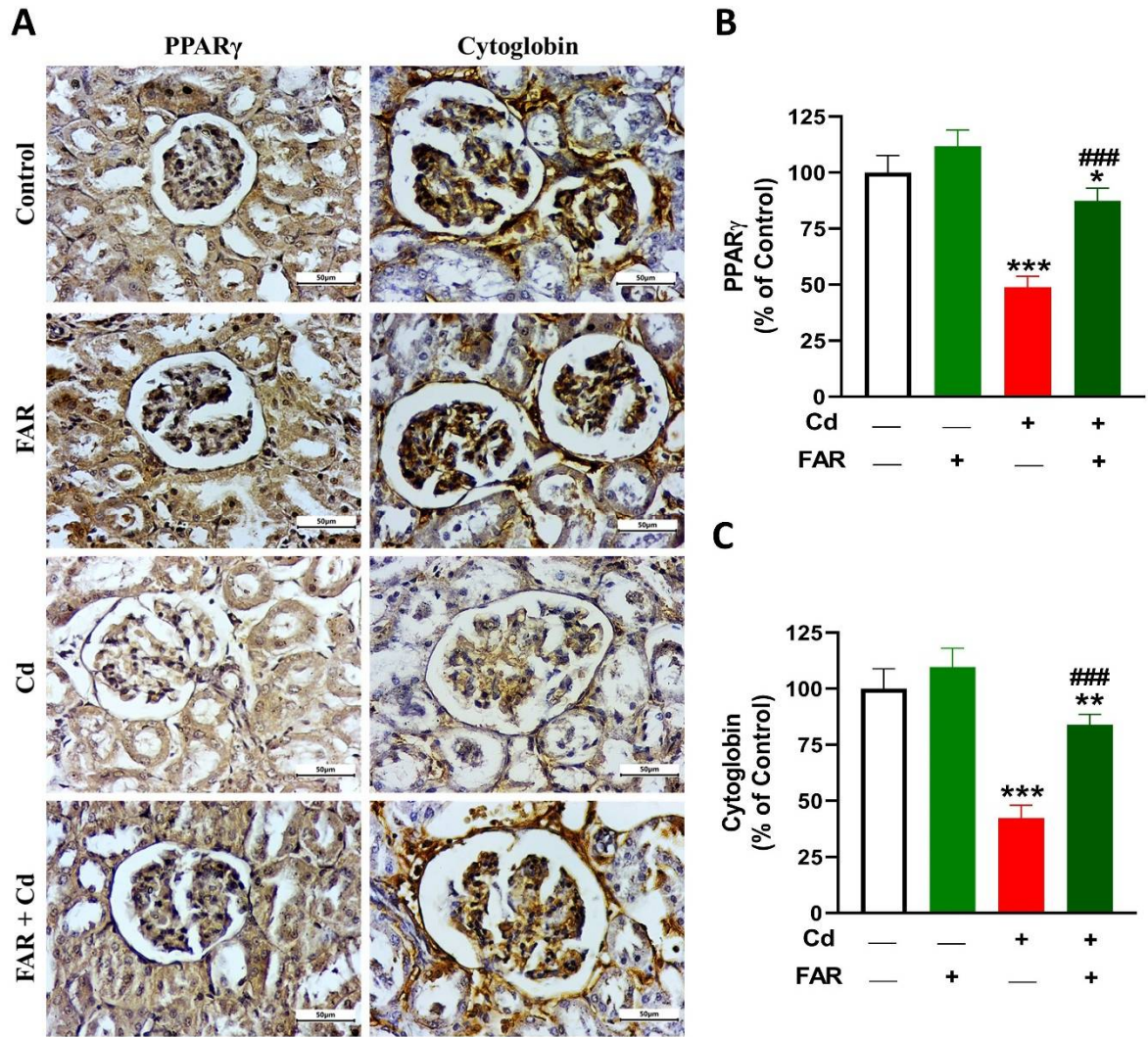


Figure 7. FAR increased kidney PPAR $\gamma$  (A,B) and cytoglobin (A,C) in Cd-administered rats (A-B). Data are mean  $\pm$  SD, ( $n = 6$ ). \* $P < 0.05$ , \*\* $P < 0.01$  and \*\*\* $P < 0.001$  versus Control. ### $P < 0.001$  versus Cd.