

<https://doi.org/10.31689/rmm.2024.31.2.191>

CASE REPORTS

# Scalp Flap Surgery - an Efficient Way to Save the Cranial Bone Flaps

Cătălin Gheorghe BEJINARIU<sup>1\*</sup>, Anca BORDIANU<sup>2</sup>

## Abstract

Brain surgery often requires wide excisions to ensure the radicality of the surgical intervention. In this context, the role of the plastic surgeon becomes essential in the reconstructive stage where outstanding soft tissue defects following life-saving neurosurgical interventions often require creation of large local flaps. By effectively covering the defects with quality tissues, the rapid healing of patients is ensured, as well as obtaining stable results over time. This paper presents the salvage surgical approach in the case of a patient operated for the recurrence of a brain tumor, the rotation scalp flap being the optimal choice for this case.

**Keywords:** scalp reconstruction, brain tumor, locoregional flap, scalp flap, reconstructive surgery.

## Rezumat

Chirurgia cerebrală impune deseori efectuarea de excizii largi pentru asigurarea radicalității intervenției chirurgicale. În acest context rolul chirurgului plastician devine esențial în etapa reconstructivă, defectele de părți moi restante în urma intervențiilor neurochirurgicale salvatoare impun de cele mai multe ori realizarea de lambouri locale de mari dimensiuni. Prin acoperirea eficientă cu țesuturi de calitate, este asigurată vindecarea rapidă a pacienților, precum și obținerea unor rezultate stabile în timp. Lucrarea de față prezintă abordarea chirurgicală salvatoare în cazul unui pacient operat pentru recidiva unei formațiuni tumorale cerebrale, evoluția postoperatorie a acestuia fiind favorabilă.

**Keywords:** reconstrucția scalpului, tumorală cerebrală, lambou loco-regional, volet cranian, chirurgie reconstructivă

<sup>1</sup>Bagdasar-Arseni Emergency Clinical Hospital, Department of Plastic and Reconstructive Surgery, Bucharest, Romania

<sup>2</sup>Carol Davila University of Medicine and Pharmacy, Bucharest, Romania

**\*Corresponding author:**

Cătălin Gheorghe BEJINARIU, Bagdasar-Arseni Emergency Clinical Hospital, Department of Plastic and Reconstructive Surgery, 12 Șoseaua Berceni, 041915, Bucharest, Romania  
E-mail: drbejinariu@gmail.com

## INTRODUCTION

The brain tumor surgery is an important branch of neurosurgery, both from the perspective of the increased incidence as well as the complexity of the surgical techniques required to solve these cases<sup>1-3</sup>. The multidisciplinary approach is often the key for solving complex cases in which tumors overcome regional anatomical barriers, invading neighboring structures<sup>4-7</sup>. Together with the neurosurgeon, the radiologist and the plastic surgeon contribute to the effective resolution of these cases, in order to obtain the best results and to accelerate the socio-professional reintegration process of the patients<sup>8</sup>.

Performing neurosurgical interventions on the brain involves, in complex cases, the dissection of large flaps, which requires an adequate surgical attitude to preserve their viability. In most cases the use of local scalp flaps proves to be the saving solution for covering the remaining defects after neurosurgical excision and for bone protection<sup>9-11</sup>. In situations where this is required, duraplasties are performed with fascia lata, the efficient harvesting of the fascial graft being performed by the plastic surgeons' team. In these particular situations where the dural defect has extensive dimensions, it can be covered with fascia lata grafts with dimensions that reach up to 20/10 cm, without significant damage to the donor area. Due to the abundant vascularization, the loco-regional scalp flaps can cover large soft tissue defects up to 25/15 cm.

The specialized literature shows, and our experience confirms, that local rotated flaps are the most frequently used reconstructive method for covering soft tissue defects of the scalp. Versatility, reliability and high rotation angle are the main advantages of scalp flaps<sup>12</sup>. Their use for covering bone flaps gives rotated scalp flaps the attribute of lifesaving surgery in reconstructive surgery at the cephalic extremity level.

The use of split skin grafts for coverage of the remaining defect at the donor area is characterized by a rapid healing, the postoperative complications associated with this procedure being easily managed by giving the patients the specific treatment, as well as a careful monitoring of the case<sup>13-15</sup>. The rapid integration of the graft is facilitated by the existence of a good quality receptor bed, in the conditions of performing the dissection in the suprapariosteal plane.

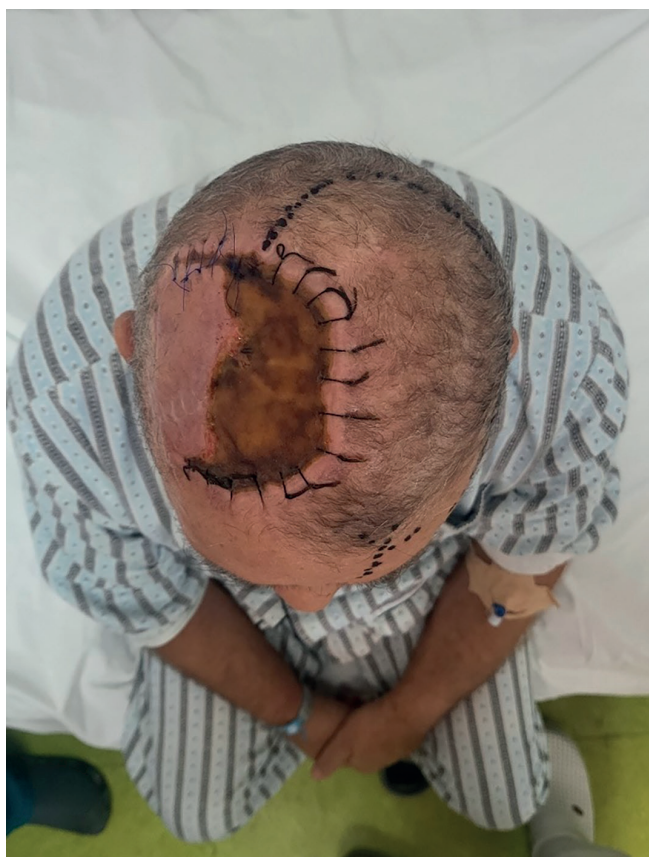The use of three Limberg flaps is also an effective method for managing these cases. However, this

method is reserved for smaller skin defects, as well as those that are not associated with the presence of bone flaps.

Of course, there might be other reconstructive techniques that can provide satisfactory results in covering soft tissue defects of the scalp. Radial, latissimus dorsi and ALT freely transferred flaps can be used for coverage of large tissue defects remaining after excision of invasive tumors<sup>16</sup>. However, the high operative complexity and the possible complications associated with this type of procedures have restricted their use to those cases that cannot benefit from reconstruction by rotating a scalp flap.

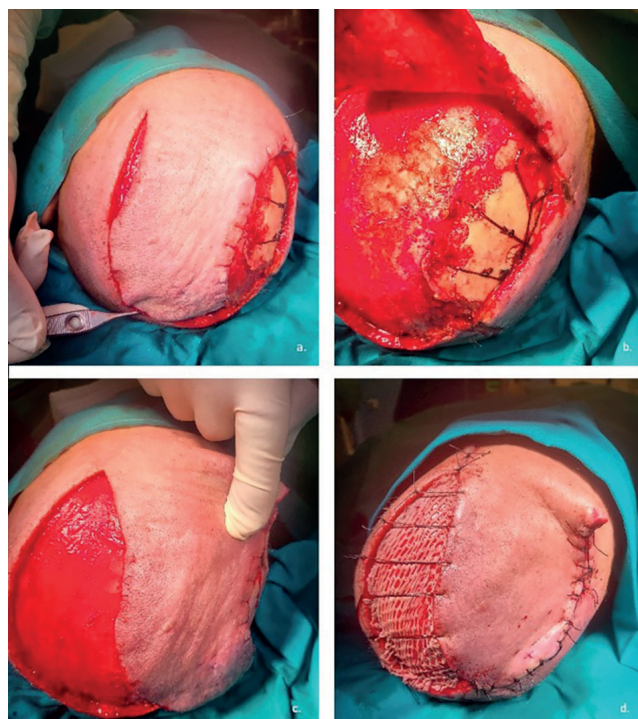
## MATERIALS AND METHODS

This paper presents the case of a 61-year-old patient who developed a local recurrence following the excision of a right frontal neural tumor at the admission in our hospital. The patient's personal pathological history includes third grade hypertension and type II diabetes mellitus. Initially, the tumor recurrence was excised with a favorable evolution of the parietal flaps in the first three days postoperatively. In day four after the neurosurgical intervention, the first signs of vascular insufficiency were noted, with an evolution towards a dry necrosis in the following three days (Fig. 1) on a surface of approximately 150 cm<sup>2</sup>. The patient benefited from topical treatment, in order to prevent wound infection. The product applied for the local management of the lesion contained hyaluronic acid in association with silver sulfadiazine 1%, its choice being based on the antibacterial effects exerted by silver ions, as well as on the moisturizing properties of hyaluronic acid. The clinical experience of the authors confirms the effectiveness of this association in the treatment of skin necrosis, from the perspective of reducing bacterial contamination while maintaining a hydrated environment to avoid the extension of the necrosis.



**Figure 1.** Fronto-parietal skin necrosis after tumor excision

Two weeks after the first signs of vascular insufficiency were noted, in the context of parietal skin necrosis with dimensions of 15/10 cm involving the flap used in the neurosurgical intervention, the excision of the necrotic area was performed, followed by reconstruction with a local rotated scalp flap, for coverage of the defect remained after excision (Fig. 2). Moreover, the flap dissection was performed in a periosteal plane in order to obtain as much mobility as possible and to ensure a good vascular bed for the split thickness skin graft.



**Figure 2.** Intraoperative aspect – a. Flap dissection, b. Bone flap exposed, c. Bone flap coverage, d. Immediate postoperative aspect

The immediate postoperative evolution was favorable, under antibiotic treatment with 3rd generation cephalosporins, anti-inflammatory treatment (ketoprofen) and gastric protection (pantoprazole). 48 hours after the reconstruction, the local examination of the flap revealed a thrombosed vascular path with signs of regional venous insufficiency. Treatment with enoxaparin sodium (60mg/0.6ml) was instituted and topical heparin sodium (100000IU/100g) was applied. After adapting the therapeutic scheme to the new clinical context, the local evolution was favorable, with the signs of venous insufficiency being gradually reduced, so that the patient could be discharged from the hospital in day seven after the surgical intervention.

Outpatient monitoring also provided favorable results, with sutures being removed at 14 days postoperatively. The patient has been followed-up for three months after the surgery, with the fully integration of the flap and no signs of local recurrence (Fig. 3).



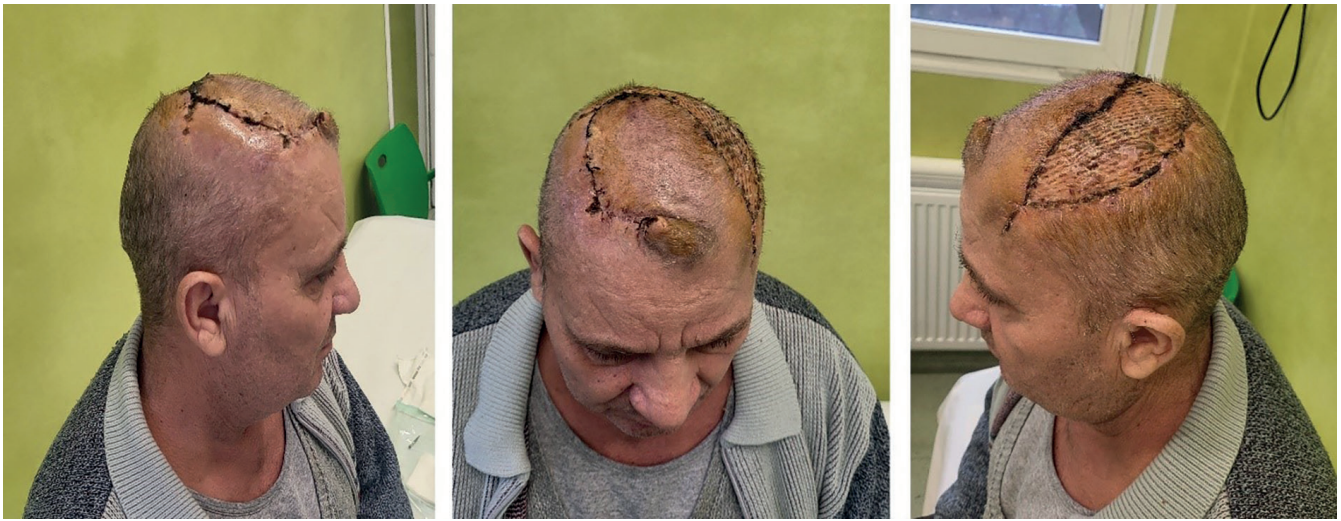

Figure 3. Postoperative aspect (14 days after surgery)

## RESULTS AND DISCUSSIONS

The scalp flap proved to be the saving solution for solving this complex case, which required the covering of the remaining defect following the excision of the skin necrosis, in the context of an underlining bone flap. The reconstruction had to be performed at the same surgical time with the necrectomy.

Outpatient monitoring also provided favorable results, with sutures being removed 14 days postoperatively. At the last postoperative control performed 90 days after the operation, it was found that the patient is cured, with the flap being fully integrated.

The choice of the reconstructive protocol was influenced in the present case by the patient's personal pathological history. The clinical context characterized by the presence of diabetes mellitus and third grade high blood pressure under treatment, oriented the reconstructive approach towards the use of the rotated scalp flap, a therapeutic option that confirmed its reliability on this occasion as well.

Scalp flaps remain popular among plastic surgeons dedicated to reconstructive surgery of the cephalic region. The rich vascularization, generous vascular axes and increased predictability of their trajectory make these flaps the first line of defense in multidisciplinary surgery dedicated to brain tumor pathology.

Aesthetic considerations such as residual alopecia from the donor area do not represent an impediment in obtaining the informed consent of the patients, especially in situations where the malignant tumor pathology is the one which guides the therapeutic protocol.

The easy operative technique, the short duration of the surgical intervention and the rapid integration of the flap are also indisputable advantages of using the rotated scalp flap.

## CONCLUSIONS

The rotated scalp flap is the first therapeutic option for patients with medium and large soft tissue defects of the scalp. The increased reliability of these flaps, the rich vascularization and the predictability of the trajectory of the main vascular axes, make this reconstructive method the best therapeutic option in the case of lesions located on the scalp. The use of the rotated scalp flap has proven to be the saving solution for covering a soft tissue defect resulting after the excision of the necrosis of the parietal flap.

**Compliance with ethics requirements:** The authors declare no conflict of interest regarding this article. The authors declare that all the procedures and experiments of this study respect the ethical standards in the Helsinki Declaration of 1975, as revised in 2008(5), as well as the national law. Informed consent was obtained from the patient included in the study.

## References

1. Hoteit, B., Caprarella, E., Casoli, V., Delgove, A., & Michot, A. (2024). Superficial temporal and occipital arteries in free flap scalp reconstruction: anatomical and radiologic study. *European Journal of Plastic Surgery*, 47(1), 1-8.

2. Rodio, M., Tettamanzi, M., Trignano, E., Rampazzo, S., Serra, P. L., Grieco, F., ... & Rubino, C. (2024). Multidisciplinary Management of Cutaneous Squamous Cell Carcinoma of the Scalp: An Algorithm for Reconstruction and Treatment. *Journal of Clinical Medicine*, 13(6), 1581.
3. Hoteit, B., Caprarella, E., Casoli, V., Delgove, A., & Michot, A. (2024). Superficial temporal and occipital arteries in free flap scalp reconstruction: anatomical and radiologic study. *European Journal of Plastic Surgery*, 47(1), 1-8.
4. Madorsky, S., & Rauchut, E. (2024). Temporoparietal Fasciocutaneous Island Flap for Forehead and Anterior Scalp Reconstruction. *Facial Plastic Surgery & Aesthetic Medicine*, 26(1), 23-27.
5. Wong, Z. Y., Wickham, N., Bagirathan, S., Leggate, A., Smith, S. J., & Pollock, J. (2024). Craniectomy with soft tissue reconstruction for locally advanced non-melanoma skin cancer of scalp with calvarial invasion: The Nottingham experience. *Journal of Plastic, Reconstructive & Aesthetic Surgery*, 90, 175-182.
6. Sidarta, E. P., Malelak, E. B., Datusanantyo, R. A., Lauren, C., & Maliawan, S. (2024). Successful reconstruction of severe traumatic scalp defect with exposed bones in a 6-year-old boy: a case report. *Journal of Surgical Case Reports*, 2024(1), rjad454.
7. Song, G., Gosain, A. K., Buganza Tepole, A., Rhee, K., & Lee, T. (2024). Exploring uncertainty in hyper-viscoelastic properties of scalp skin through patient-specific finite element models for reconstructive surgery. *Computer Methods in Biomechanics and Biomedical Engineering*, 1-15.
8. Bejinariu, C. G., Manescu, R., Boghian, L. M., Gheorghiu-Branaru, M., Popescu, S., & Marinescu, S. A. (2020). Scalp Reconstruction With Three Rhomboid Flaps After Squamous Cell Carcinoma Excision.
9. Sulciner, M. L., Wang, J., Lam, M. B., Hornick, J. L., Orgill, D. P., Baldini, E. H., ... & Fairweather, M. (2024). MULTIDISCIPLINARY MANAGEMENT OF PLEOMORPHIC DERMAL SARCOMA OF THE SCALP: A SINGLE INSTITUTION STUDY. *Surgical Oncology Insight*, 100036.
10. Grassi, D., De Monti, M., Espeli, V., & De Pellegrin, L. (2024). Use of a Dermal Regeneration Template in a two-stage reconstruction after extensive skin surgery for Bowen's disease of the anterior neck-Case report. *International Journal of Surgery Case Reports*, 115, 109208.
11. Hongaiah, D., Kattepur, A. K., George, E. V., Mahadev M, A., Kenkere, D., & Dasappa, A. (2024). Free flap reconstruction at a rural-based tertiary medical college hospital: Barriers and outcomes. *Journal of Surgical Oncology*.
12. Bordianu, A., Bobircă, F., & Pătrașcu, T. (2018). Skin grafting in the treatment of diabetic foot soft tissue defects. *Chirurgia (Bucur)*, 113(5), 644-650.
13. Bejinariu, C., Marinescu S., Enescu, D.M. The Romanian National Breast Reconstruction Program - Results and Conclusions after 5 Year. *Medicina Moderna - Modern Medicine*. 2019; 26(1). 23-30. <https://doi.org/10.31689/rmm.2019.26.1.23>
14. Alessandri-Bonetti, M., David, J., & Egro, F. M. (2023). Pedicled latissimus dorsi flap for extensive scalp reconstruction in acute burns. *Plastic and Reconstructive Surgery-Global Open*, 11(8), e5217.
15. Bejinariu, C., Boghian, L., Popescu, S., Marinescu, S. The Treatment of the Cubital Tunnel Syndrome Using the Anterior Transposition Surgical Technique, *Medicina Moderna - Modern Medicine*. 2020; 27(1), 25-28. <https://doi.org/10.31689/rmm.2020.27.1.25>.
16. Lauck, K. C., Rickstrew, J. J., & Tolkachjov, S. N. (2024). Bilateral Forehead Rotation Flap with Skin Substitute Application for Convexity Replacement. *Plastic and Reconstructive Surgery-Global Open*, 12(1), e5590.