

CHOP-21 for the treatment of post-transplant lymphoproliferative disorders following solid organ transplantation

There is no definitive treatment for post-transplant lymphoproliferative disorder (PTLD) that does not respond to reduction of immunosuppression. With a median follow-up of 8.8 years, the current retrospective analysis of standard CHOP (cyclophosphamide, doxorubicin, vincristine and prednisone) in 26 adults with PTLD demonstrated an overall response rate of 65% and median overall and progression-free survivals of 13.9 and 42 months, respectively.

Haematologica 2007; 92: 273-274

Chemotherapy is effective in PTLD, but is associated with significant toxicity, including substantial treatment-related mortality (TRM). Reports of chemotherapy in PTLD are generally based on small cohorts, including patients with a broad spectrum of different subtypes of PTLD, and heterogeneous chemotherapy regimens,¹⁻⁷ (Table 1, *online version only*). A large retrospective analysis, however, has demonstrated improved overall survival (OS) with multidrug regimens compared with single-agent chemotherapy in PTLD.⁴ Although some small trials of CHOP suggest a favorable efficacy in adults, response rates, toxicity and risk factors are not well defined in this setting.

The current study was undertaken to evaluate treatment with CHOP-21 in a well characterized population of adult recipients of solid organ transplants. Patients unresponsive

to a reduction of immunosuppression and subsequently treated with CHOP chemotherapy were identified in the databases of the Charité University Hospital Campus Virchow Clinic in Berlin and the Hôpital Pitié-Salpêtrière in Paris. Patients treated with antiviral drugs, surgical resection, irradiation, CD20 antibody or other cytostatic substances prior to CHOP were excluded from the study. The median age of the patients was 46.5 years (range 22-68 years) and there was a predominance of males (69%). The patient cohort comprised predominantly heart and kidney transplant recipients (38% and 35%, respectively), with liver and lung transplant recipients representing 15% and 12% of patients, respectively. The median time from transplantation to diagnosis of PTLD was 32 months (range 5-329 months) and an association with Epstein Barr virus (EBV) infection was demonstrated in 38% of cases. The predominant morphology was monomorphic (85%) and the majority of patients (85%) had a B-cell neoplasm. More than half of the patients had stage IV disease (58%) and a substantial proportion had significantly impaired performance (ECOG ≥ 2). Lactate dehydrogenase (LDH) concentration was documented in 58% of the patients. The median follow-up was 8.8 years. All patients received prophylactic granulocyte colony-stimulating factor (G-CSF) after CHOP chemotherapy.

Following CHOP chemotherapy, 13 of 26 (50%) patients achieved a complete remission (CR), and four patients (15%) achieved a partial remission. Five patients are in continuous CR, with seven patients still alive. The median progression-free survival (PFS) was 42 months, with 5- and 10-year PFS rates of 43% and 32%, respectively (Figure 1A). The median overall survival (OS) was 13.9 months (Figure 1B). Twelve patients died within 12 months of the start of therapy, with death attributed to

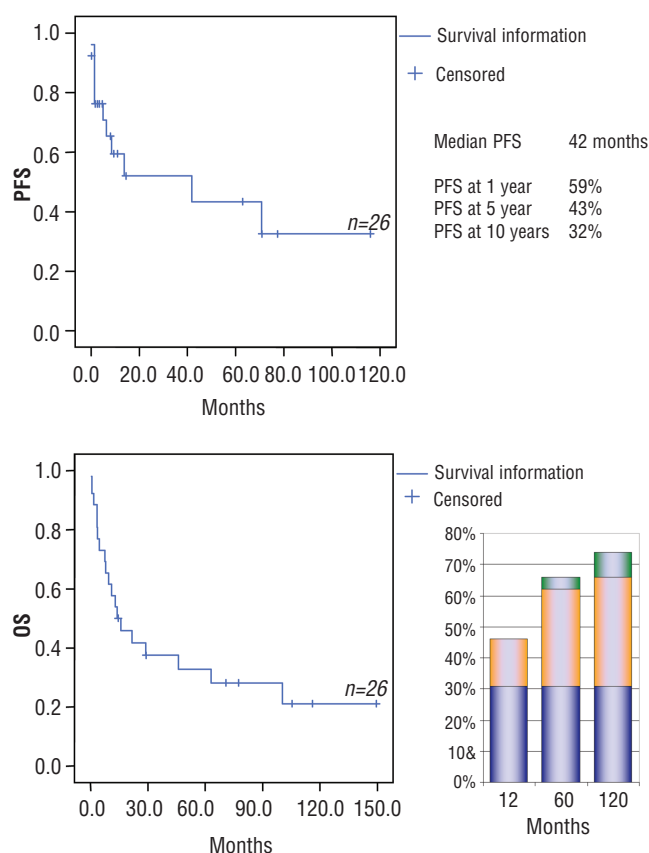


Figure 1. A. Progression-free survival (PFS) after second-line CHOP treatment of PTLD unresponsive to a reduction in immunosuppression. **B.** Overall survival (OS) after second-line CHOP treatment of PTLD unresponsive to a reduction in immunosuppression.

Blue

CHOP-associated mortality (infectious <12 months from initiation of therapy; 7 patients, liver failure: 1 patient)

Orange

PLTD-associated mortality (death due to PTLD-progression or death associated with salvage therapy)

Green

death from any other cause (acute leukemia: 1 patient; subdural hematoma: 1 patient).

PTLD progression (n=4), infectious complications (n=7) and treatment-related acute liver failure (n=1). Nine late deaths (>1 year post-therapy) were documented and attributed to progressive disease (n=5), complications of salvage therapy (n=2), acute myeloid leukemia (M6; n=1) and subdural hematoma of unknown origin (n=1). The TRM rate was 31%, and PTLD-associated mortality rates were 15%, 31% and 38% at 1, 5 and 10 years, respectively (Figure 1B).

Prognostic factors predictive for OS were analyzed using the multivariate Cox proportional-hazards model. No significant effects were demonstrated for age, sex, early versus late PTLD, EBV-association, histology-subtype, serum LDH or performance status. A significant effect was also demonstrated for the International Prognostic Index score (median OS in patients with IPI <2 vs ≥2: 72 vs 19 months; $p=0.0395$). After CHOP, the next most predictive factor for OS was attainment of CR (median OS of patients achieving CR versus no CR: 100.4 vs 7.5 months; $p=0.0008$). Notably, 40% of patients with CR after CHOP had no evidence of disease at a 10-year follow-up.

These data indicate that CHOP chemotherapy offers a potential for cure of PTLD in a significant proportion of patients achieving CR. However, CHOP is associated with substantial toxicity in PTLD, with a TRM rate of 31% observed in this study. Rituximab monotherapy is not associated with TRM,^{8,9} thus supporting its use in sequence and/or combination with CHOP. In patients with PTLD, sequential CHOP-21 chemotherapy after rituximab markedly improved CR rates and was associated with lower TRM compared with that associated with chemotherapy alone.¹⁰ The improved tolerability of CHOP-21 after rituximab is presumed to be attributable to improved performance status after treatment with rituximab, an empiric use of G-CSF and the prophylactic use of antibiotics.

It is likely that further improvement in the clinical management of PTLD will require new approaches and improved identification of patients who would benefit from less aggressive therapies.

Sylvain Choquet,* Ralf Trappe,* Veronique Leblond,*
Ulrich Jäger,* Frederic Davi,* Stephan Oertel^o

*The first two authors contributed equally to this work and share first authorship.

*Department of Haematology, Hôpital Pitié-Salpêtrière, Paris, France; ^oDepartment of Hematology and Oncology, Charité, Universitätsmedizin Berlin, Campus Virchow-Klinikum, Berlin, Germany; ^oDepartment of Hematology and Haemostaseology, AKH, Wien, Austria

Key words: post-transplant lymphoproliferative disorder, immunosuppression, chemotherapy, CHOP, rituximab.

Correspondence: Ralf Ulrich Trappe, Deutsche Studiengruppe Posttransplantationslymphome, Charité, Universitätsmedizin Berlin, Campus Virchow Klinikum, Medizinische Klinik mit Schwerpunkt Hämatologie und Onkologie, Augustenburger Platz 1, 13353 Berlin, Germany. Phone: international +49.030.450553510. Fax: international + 49.030.450553901. E-mail: ralf.trappe@charite.de

References

- Garrett TJ, Chadburn A, Barr ML, Drusin RE, Chen JM, Schulman LL, et al. Posttransplantation lymphoproliferative disorders treated with cyclophosphamide-doxorubicin-vincristine-prednisone chemotherapy. *Cancer* 1993; 72:2782–5.
- Mamzer-Bruneel MF, Lome C, Morelon E, Levy V, Bourquelot P, Jacobs F, et al. Durable remission after aggressive chemotherapy for very late post-kidney transplant lymphoproliferation: a report of 16 cases observed in a single center. *J Clin Oncol* 2000;18:3622–32.
- Norin S, Kimby E, Ericzon BG, Christensson B, Sander B, Soderdahl G, et al. Posttransplant lymphoma: a single-center experience of 500 liver transplantations. *Med Oncol* 2004;21:273–84.
- Buell JF, Gross TG, Hanaway MJ, Trofe J, Muthiak C, First MR, et al. Chemotherapy for posttransplant lymphoproliferative disorder: the Israel Penn International Transplant Tumor Registry experience. *Transplant Proc* 2005; 37: 956–7.
- Elstrom RL, Andreadis C, Aqui NA, Ahya VN, Bloom RD, Brozna SC, et al. Treatment of PTLD with rituximab or chemotherapy. *Am J Transplant* 2006;6:569–76.
- Fohrer C, Caillard S, Koumariou A, Ellero B, Woehl-Jaegle ML, Meyer C, et al. Long-term survival in post-transplant lymphoproliferative disorders with a dose-adjusted ACVBP regimen. *Br J Haematol* 2006;134:602–12.
- Taylor AL, Bowles KM, Callaghan CJ, Wimperis JZ, Grant JW, Marcus RE, et al. Anthracycline-based chemotherapy as first-line treatment in adults with malignant posttransplant lymphoproliferative disorder after solid organ transplantation. *Transplantation* 2006;82:375–81.
- Oertel SH, Verschuuren E, Reinke P, Zeidler K, Papp-Vary M, Babel N, et al. Effect of anti-CD 20 antibody rituximab in patients with post-transplant lymphoproliferative disorder (PTLD). *Am J Transplant* 2005;5:2901–6.
- Choquet S, Leblond V, Herbrecht R, Socie G, Stoppa AM, Vandenberghe P, et al. Efficacy and safety of rituximab in B-cell post-transplant lymphoproliferative disorders: results of a prospective multicentre phase II study. *Blood* 2006;107:3053–7.
- Trappe R, Oertel SH, Choquet S, LeBlond V, Papp-Vary M, Riess H. Sequential treatment with the anti-CD 20 antibody rituximab and CHOP+GCSF chemotherapy in patients with post-transplant lymphoproliferative disorder (PTLD): first results of a multicenter phase II study. *Blood* 2005;106:932.