
Electronic Thesis and Dissertation Repository

9-24-2015 12:00 AM


A Randomized Clinical Trial to Compare the Effect of Non Operative Treatment With and Without Autologous Conditioned Plasma (ACP) on Healing and Function in Patients with Achilles Tendon Ruptures

Tyler M. Pratt
The University of Western Ontario

Supervisor
Dr. Dianne Bryant
The University of Western Ontario Joint Supervisor
Dr. Kevin Willits
The University of Western Ontario

Graduate Program in Health and Rehabilitation Sciences
A thesis submitted in partial fulfillment of the requirements for the degree in Master of Science

© Tyler M. Pratt 2015
Follow this and additional works at: <https://ir.lib.uwo.ca/etd>

 Part of the [Medical Anatomy Commons](#), [Orthopedics Commons](#), [Physical Therapy Commons](#), [Physiotherapy Commons](#), [Podiatry Commons](#), and the [Sports Medicine Commons](#)

Recommended Citation

Pratt, Tyler M., "A Randomized Clinical Trial to Compare the Effect of Non Operative Treatment With and Without Autologous Conditioned Plasma (ACP) on Healing and Function in Patients with Achilles Tendon Ruptures" (2015). *Electronic Thesis and Dissertation Repository*. 3242.
<https://ir.lib.uwo.ca/etd/3242>

This Dissertation/Thesis is brought to you for free and open access by Scholarship@Western. It has been accepted for inclusion in Electronic Thesis and Dissertation Repository by an authorized administrator of Scholarship@Western. For more information, please contact wlsadmin@uwo.ca.

A Randomized Clinical Trial to Compare the Effect of Non-operative Treatment with
or without Autologous Conditioned Plasma (ACP) on Healing and Function in
Patients with Achilles Tendon Ruptures

(Thesis format: Monograph)

by

Tyler Martin Pratt

Graduate Program in Health and Rehabilitation Science

A thesis submitted in partial fulfillment
of the requirements for the degree of
Masters of Science

The School of Graduate and Postdoctoral Studies
The University of Western Ontario
London, Ontario, Canada

© Tyler Pratt, 2015

Abstract

The purpose of this study was to determine whether there is evidence to support conducting a larger randomized control trial (RCT) to compare the non-operative treatment of Achilles tendon (AT) ruptures with or without Autologous Conditioned Plasma (ACP®). Twenty-four patients were randomized to receive an ACP® or saline injection within seven days and again at two weeks post-rupture. Tendon healing was longitudinally evaluated using ultrasound (US) and magnetic resonance imaging (MRI). Functional and patient-reported quality of life measures were also assessed. A small sample size limited our ability to detect statistically significant differences. The mean rankings of healing were slightly higher in the ACP® group at most time points for MRI and US. Functional and patient-reported outcomes were also slightly higher in the ACP® group at most time points. The consistency of these preliminary results suggests that there is evidence to support conducting a larger RCT.

Keywords

Plasma, platelets, Achilles tendon, rupture, non-operative, healing, functional rehabilitation

Co-Authorship Statement

This randomized control trial was designed by Drs. Willits, Bryant, and Spouge. I was responsible for patient identification and recruitment; patient scheduling for clinic, ultrasound, and magnetic resonance imaging; and data collection and analysis. I wrote the original draft of this thesis document. Drs. Bryant and Willits made comments and suggestions towards the final submission.

Acknowledgments

I would like to thank my co-supervisors, Drs. Dianne Bryant and Kevin Willits, for their continued support and guidance throughout my Master's at Western University. Additionally, I would like to thank the following people for their support and assistance over the past two years:

- Dr. Alison Spouge for her expertise and assistance with the imaging portion of this study.
- Nicole Kaniki and Alliyah Remtulla for helping me transition into graduate school, and helping with various aspects of my study.
- Marsha, Kathy, and Anne for their help with accommodating study patients, and for their kindness and friendship in clinic.
- Sam Malian for his support and friendship before and during our Master's studies
- Special thanks to my girlfriend, Nicole Fields, for constantly believing in me and motivating me to achieve my goals.
- Finally, I would like to sincerely thank my parents for their unconditional love and support, which has allowed me to pursue every possible opportunity in my life.

Table of Contents

| | |
|---|------|
| Abstract..... | ii |
| Co-Authorship Statement..... | iii |
| Acknowledgments..... | iv |
| Table of Contents..... | v |
| List of Tables | ix |
| List of Figures..... | x |
| List of Appendices | xiii |
| Appendix A: Research Ethics Board Approval | xiii |
| Appendix B: Letter of Information and Consent | xiii |
| Appendix C: Image and Table Permissions..... | xiii |
| Appendix D: MR Imaging Sequences | xiii |
| Acronyms..... | xiv |
| Chapter 1..... | 1 |
| 1 Introduction..... | 1 |
| Chapter 2..... | 3 |
| 2 Literature Review..... | 3 |
| 2.1 Anatomy of the Achilles Tendon..... | 3 |
| 2.2 Achilles Tendon Rupture | 4 |
| 2.2.1 Epidemiology..... | 4 |
| 2.2.2 Etiology..... | 6 |
| 2.2.3 Mechanism of Injury..... | 8 |
| 2.2.4 Clinical Presentation..... | 9 |
| 2.3 Healing Following Achilles Tendon Rupture..... | 13 |
| 2.3.1 Clinical Assessment of Healing..... | 14 |

| | | |
|-----------|---|----|
| 2.3.2 | Using Imaging to Assess Tendon Healing..... | 14 |
| 2.4 | Treatment of Achilles Tendon Rupture | 23 |
| 2.4.1 | Operative Treatment | 23 |
| 2.4.2 | Non-Operative Treatment..... | 24 |
| 2.4.3 | Operative vs. Non-Operative Treatment: A Review of the Literature..... | 25 |
| 2.5 | Rehabilitation: Immobilization versus Early Mobilization..... | 28 |
| 2.5.1 | Controlled Early Motion..... | 28 |
| 2.5.2 | Controlled Early Weight-Bearing..... | 30 |
| 2.5.3 | Controlled Early Motion and Weight-Bearing | 31 |
| 2.6 | A Novel Non-Operative Option: Platelet-rich Plasma..... | 33 |
| 2.6.1 | Platelet Biology..... | 34 |
| 2.6.2 | Preparation of PRP..... | 37 |
| 2.6.3 | Delivery of PRP | 40 |
| 2.6.4 | PRP in the Treatment of Orthopedic Injuries | 41 |
| 2.6.5 | PRP in the Treatment of Achilles Tendon Ruptures: A Review of the Literature..... | 42 |
| 2.7 | Summary..... | 51 |
| Chapter 3 | | 53 |
| 3 | Objectives..... | 53 |
| 3.1 | Primary Objective | 53 |
| 3.2 | Secondary Objectives..... | 53 |
| 3.3 | Overall Study Objective..... | 53 |
| Chapter 4 | | 54 |
| 4 | Methods..... | 54 |
| 4.1 | Study Design..... | 54 |
| 4.2 | Eligibility Criteria | 54 |

| | |
|---|----|
| 4.3 Treatment & Rehabilitation Protocol..... | 55 |
| 4.3.1 Acute Treatment..... | 55 |
| 4.3.2 Intervention Protocol | 55 |
| 4.3.3 Autologous Conditioned Plasma (ACP®)..... | 55 |
| 4.3.4 Rehabilitation..... | 57 |
| 4.4 Primary Outcome – Healing | 58 |
| 4.4.1 Ultrasound..... | 58 |
| 4.4.2 MRI..... | 59 |
| 4.5 Secondary Outcomes | 60 |
| 4.5.1 Isokinetic Strength | 60 |
| 4.5.2 Range of Motion | 61 |
| 4.5.3 Calf Circumference..... | 62 |
| 4.5.4 Leppilahti Score..... | 62 |
| 4.5.5 Ankle-Hindfoot Scale (AOFAS)..... | 62 |
| 4.5.6 Achilles Tendon Total Rupture Score (ATRS)..... | 63 |
| 4.6 Plan for Analysis..... | 64 |
| Chapter 5..... | 66 |
| 5 Results..... | 66 |
| 5.1 Participant Flow | 66 |
| 5.2 Demographic Information..... | 68 |
| 5.3 Injection Information | 69 |
| 5.3.1 “PAW” Classification..... | 69 |
| 5.4 Location of Tendon Rupture..... | 70 |
| 5.5 Primary Outcome | 70 |
| 5.5.1 Estimated Percent Healing..... | 70 |
| 5.6 Secondary Outcomes | 77 |

| | | |
|-------|--------------------------------------|-----|
| 5.6.1 | Patient-Reported Outcomes | 77 |
| 5.6.2 | Functional Outcomes | 78 |
| 5.7 | Re-Ruptures and Adverse Events | 81 |
| 6 | Discussion | 82 |
| 6.1 | Study Strengths | 91 |
| 6.2 | Study Limitations..... | 92 |
| 7 | Conclusion..... | 92 |
| 7.1 | Directions for Future Research | 93 |
| | References..... | 94 |
| | Appendices..... | 117 |

List of Tables

| | |
|---|----|
| Table 1 Platelet α -granule contents and their functional categories. Secreted proteins with reported pro-angiogenic properties are underlined while those with anti-angiogenic potential are also identified (*). | 36 |
| Table 2 Plasma-Based and Buffy Coat-Based PRP Systems | 39 |
| Table 3 Timeline for all study outcome measures | 64 |
| Table 4 Patient demographics | 68 |
| Table 5 White blood cell and platelet counts of patients' blood and ACP samples | 69 |
| Table 6 Ultrasound and MRI agreement on ordinal ratings of estimated percent healing at 6, 12, and 24 weeks | 77 |
| Table 7 American Orthopedic Foot and Ankle Society score, Achilles Tendon Total Rupture Score at 6, 12, and 24 weeks and Leppilahti score at 24 weeks post-rupture | 78 |
| Table 8 Range of motion and calf circumference measurements at 6, 12, and 24 weeks post-rupture | 80 |
| Table 9 Isokinetic strength ratio of the injured to uninjured Achilles at 24 weeks post-rupture | 81 |

List of Figures

| | |
|--|----|
| Figure 1 Calf muscles and Achilles tendon | 4 |
| Figure 2 Ultrasonographic appearance of a normal Achilles tendon..... | 11 |
| Figure 3 Ultrasonographic appearance of a ruptured Achilles tendon | 12 |
| Figure 4 Follow-up scan at 29 months demonstrating a healed tendon with resolution of the hematoma (arrows). The overlapping healed ends remain visible | 16 |
| Figure 5 Follow-up scan at 15 months demonstrating a healed tendon with no discernable gap. The hypoechoic band (white arrows) and the slight bulge along the anterior margin of the tendon (black arrows) define the site of prior injury. There is mild residual distortion of the normal fibrillar architecture | 17 |
| Figure 6 Follow-up scan at nine months demonstrating the healed tendon with a subtle hypoechoic band indicating the site of previous rupture (white arrows). Note the irregular contour along the anterior tendon (black arrows)..... | 18 |
| Figure 7 Full thickness tear of the Achilles tendon (T1-weighted sagittal MRI). There is discontinuity of the tendon with retraction of the proximal portion (red arrow). The distal tendon is tendinopathic and appears thickened and of increased signal intensity (white arrow)..... | 20 |
| Figure 8 PRP "PAW" Classification System | 40 |
| Figure 9 Centrifuge | 56 |
| Figure 10 Three-layer ACP..... | 57 |
| Figure 11 Biodex Dynamometer..... | 61 |
| Figure 12 Participant flow through the trial..... | 68 |
| Figure 13 Estimated percent healing at two weeks post injection with ACP or saline based on ultrasound imaging..... | 71 |

Figure 14 Estimated percent healing at four weeks post injection with ACP or saline based on ultrasound imaging..... 72

Figure 15 Estimated percent healing at six weeks post injection with ACP or saline based on ultrasound imaging (left) and MRI (right) 73

Figure 16 Estimated percent healing at eight weeks post injection with ACP or saline based on ultrasound imaging..... 74

Figure 17 Estimated percent healing at 12 weeks post injection with ACP or saline based on ultrasound imaging (left) and MRI (right) 75

Figure 18 Estimated percent healing at 24 weeks post injection with ACP or saline based on ultrasound imaging (left) and MRI (right) 76

Figure 19 Baseline US of an acute Achilles tendon rupture (inflammatory phase). Long axis view at the rupture site shows discontinuity of tendon fibres (T) with a gap (arrows demarcate proximal and distal ends of the torn fibres) and a small anechoic fluid collection (*) likely related to a hematoma. The Torn tendon fibres are hypoechoic, mildly redundant and show loss of the normal fibrillar pattern 86

Figure 20 Ultrasound image at six weeks (proliferative phase) in the same patient as Figure 19. The previous anechoic fluid collection at the tear site has resorbed. A prominent gap is evident at the site of the tear (arrows) filled with echogenic tissue (*) which may correspond to granulation tissue. The tendon fibres adjacent to the tear are thickened, disorganized and hypoechoic, potentially corresponding to persistent edema and/or fibrous tissue..... 87

Figure 21 MR image at six weeks (same patient). Sagittal fast inversion recovery image (water weighted) shows a complete tear of the Achilles tendon with a residual gap at the site of the tear (arrow) marked by increased signal intensity. Increased fluid manifested by high signal intensity likely corresponding to extensive edema is present, most conspicuous within the proximal aspect of the tendon (*). 88

Figure 22 Ultrasound image at 24 weeks (late remodeling phase). Panorama long axis ultrasound. The Achilles tendon (T) is thickened, hypoechoic with mild redundancy, loss of

the normal fibrillar pattern and disorganization of the tendon fibres, likely reflecting post-traumatic scarring due to extensive background microtearing. There is slightly increased signal at the site of previous discrete tear (arrows), without a residual gap evident. 89

Figure 23 MR image at 24 weeks (late remodeling phase). Sagittal fast inversion recovery (water weighted). The previous gap is even more inconspicuous filled with hypointense/dark tissue (*), likely corresponding to fibrous tissue. The tendon remains thickened and abnormal 90

List of Appendices

Appendix A: Research Ethics Board Approval

Appendix B: Letter of Information and Consent

Appendix C: Image and Table Permissions

Appendix D: MR Imaging Sequences

Acronyms

ACP® - Autologous Conditioned Plasma

PRP – platelet rich plasma

US – ultrasound

MRI – magnetic resonance imaging

Chapter 1

1 Introduction

Rupture of the Achilles tendon (AT) is one of the most common tendinous injuries within the adult population. Throughout the last two decades, the incidence of AT rupture has significantly increased as a result of more adults participating in high-demand sports¹⁻³. Tissue healing and regeneration in the AT is a slow process which results in a slow return of normal function. Management of AT ruptures can be broadly classified into operative and non-operative treatment, although there is considerable debate regarding which treatment is optimal as each has unique advantages and disadvantages. In the past, operative treatment has been associated with a lower risk for re-rupture at the expense of a higher risk of surgical and post-surgical complications, whereas non-operative treatment is associated with a lower risk of complications but a higher risk for re-rupture.

However, in 2010, Willits et al⁴ published the results of a randomized control trial that reported similar functional and patient-reported outcomes, as well as similar re-rupture rates between operatively and non-operatively treated patients. They hypothesized that the similarity in re-rupture rates was attributed to the early mobilization rehabilitation protocol. A recent meta-analysis of the literature by Soroceanu et al (2012)⁵ yielded similar conclusions regarding re-rupture rates when the non-operative management included early mobilization.

Platelet-rich plasma (PRP) is a generic term describing products that contain above-average amounts of platelets in a small volume of plasma. PRP has been used increasingly for the treatment of various orthopedic injuries⁶. The physiological rationale for concentrating platelets at a site of injury is to optimize the healing environment, although there is no clear indication for the clinical efficacy of PRP.

One limitation of PRP research is the lack of standardization of the intervention, preparation methods and contents of the PRP. Different preparation methods yield PRP samples with different platelet concentrations and leukocyte concentrations. Some samples also require an exogenous platelet activator. To determine the most effective method of PRP preparation and administration, this information must be reported and more head to head comparisons evaluated⁷.

To date, there has been one study that has examined the effectiveness of ACP® for the non-operative management of AT ruptures⁸. The results of this study did not support a measurable clinical or functional benefit of ACP® when compared to non-operative management without ACP®. The notable limitations of this study include the use of a retrospective control group, and an ACP® injection period spanning 14 days from the time of rupture. There is anecdotal evidence that suggests that earlier PRP injections (i.e. at the time of surgery, less than seven days post-rupture) may yield more favorable functional and histochemical results⁹⁻¹². This may be related to the contents of the PRP and because the PRP may be most effective during the inflammatory phase of tendon healing. One of the significant characteristics of this phase of healing is the activation of platelets at the site of tendon injury, which can last up to seven days post-injury¹³⁻¹⁵.

Thus, the purpose of this randomized control trial is to determine whether ACP® injections within seven days post AT rupture and again at two weeks post-rupture demonstrate better tendon healing on imaging (i.e. ultrasound and magnetic resonance imaging), better functional outcomes, and more favorable patient-reported outcomes than patients with AT rupture who receive saline injections at the same time points. Should this study demonstrate that earlier ACP® injections yield more favorable outcomes, then a larger RCT would be warranted.

Chapter 2

2 Literature Review

2.1 Anatomy of the Achilles Tendon

A tendon is a type of connective tissue that is interposed between muscle and bone. Tendons are comprised primarily of collagen (specifically type I collagen) and elastin embedded in a proteoglycan-water matrix, with collagen and elastin accounting for 65-80% and 2-4% of the tendon's dry mass, respectively¹⁶. The fibro-elastic nature of the tendon makes it resistant to mechanical loads, thus allowing the force generated within the muscle to be transmitted to bone, ultimately enabling movement about a joint¹⁶.

The Achilles tendon (AT) is the thickest and strongest tendon in the human body^{17,18}. The distal aspects of the gastrocnemius and soleus muscles merge to form the origin of the AT (Figure 1). The gastrocnemius is a fusiform muscle formed by medial and lateral heads originating from the distal femoral condyles¹⁹, and is the most superficial muscle in the dorsal aspect of the lower leg^{19,20}. The soleus is deep to the gastrocnemius and can be described as a pennate muscle originating from a fibrous arch between the tibia and fibula in the middle third of the lower leg and from the posterior surface of the head of the fibula^{19,21}. The gastrocnemius and soleus form the triceps surae, which acts to plantarflex the ankle joint via the AT²⁰.

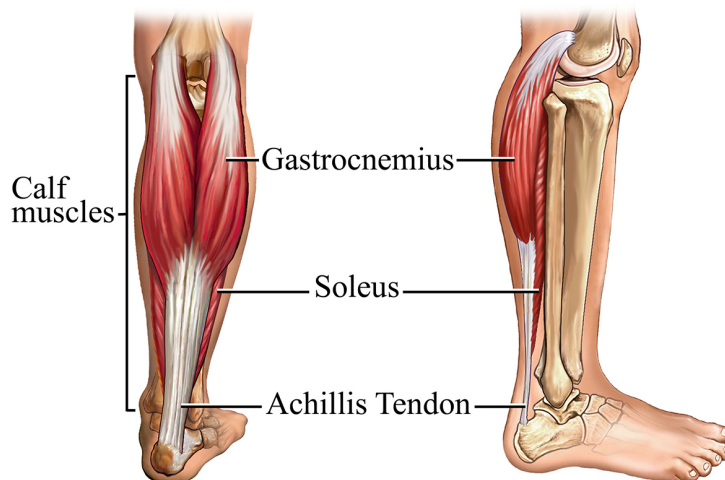


Figure 1 Calf muscles and Achilles tendon

Medical Illustration Copyright © 2015 Nucleus Medical Media

The average length of the AT is 15 cm, but can range from 11 to 26 cm^{20,22,23}. At its proximal origin the AT is rounded, but flattens out at the distal insertion. The mean width of the AT is 6.8 cm (4.5-8.6 cm) at its origin and gradually decreases distally. The AT inserts at the midpoint of the posterior surface of the calcaneus, with a mean width of 3.4 cm (2.0-4.8 cm)^{20,23}.

2.2 Achilles Tendon Rupture

2.2.1 Epidemiology

Although the AT is the most commonly ruptured tendon in the body²⁴, few studies have examined the epidemiology of AT ruptures. Leppilahti et al (1996)²⁵ detailed the incidence of AT rupture in Oulu, Finland from 1979 to 1994. During this 16-year period, there were 110 ruptures. The incidence increased from two ruptures per 10⁵ individuals

between 1979 to 1986, to 12 ruptures per 10^5 individuals between 1987-1994. The peak age-specific annual rupture incidence was in individuals aged 30-39 ($r=0.74$, $p<0.001$). The rupture ratio of males to females was 5.5:1. Additionally, 81% of ruptures occurred during sporting activities with 88% of those occurring during ball games.

Similarly, Möller et al (1996) studied the incidence of AT rupture in Malmö, Sweden from 1987-1991. They reported 153 diagnosed cases during this span. The average annual age incidence per 10^5 was calculated for each 10-year age interval. The highest incidence was found in the 30-39 year age group with an incidence of 30.4 per 10^5 individuals. There were significantly more men (132) than women (21) that were diagnosed with AT rupture. Sports injuries (98) were more common than other injuries (55), with badminton, soccer, and tennis being the sport most often leading to AT rupture.

A literature review conducted by Leppilahti & Orava (1998)¹ found similar results to the previous study conducted by Leppilahti et al (1996)²⁵ with respect to the average rupture ratio of males to female (6:1) and the age of peak incidence (30-40). Additionally, they found that an average of 75% of AT ruptures were sports-related, especially recreational sports demanding sudden acceleration and jumping. Within this group, an average of 8 to 20% of AT ruptures occurred in elite athletes, 75% in recreational athletes, and 10 to 12% did not take part in any sports.

Suchak et al (2005)²⁶ retrospectively examined the incidence of AT rupture in the North American population, specifically in Edmonton, Canada. They found a comparable incidence (8.3 ruptures per 10^5 individuals) to those reported in European communities (range 6 to 37 per 10^5 individuals). The rupture ratio of males to females was 4:1, with the mean age of males being 40.6 years and females being 44.5 years. The 30-39 and 40-49 year old age groups were most frequently associated with AT rupture in men and

women, respectively. The percentage of ruptures associated with sporting activities was 78.6%.

Gwynne-Jones et al (2011)²⁷ conducted an epidemiological study in Dunedin, New Zealand. They found an incidence of approximately 24 per 10⁵ individuals over an 8.5 year period. Out of 363 AT rupture patients, 197 (54%) were males and 166 (46%) were females. They also found an equal gender distribution up until the age of 50, but there were significantly more males (73%, p=0.0007) in the age group 51-60 years. The mean age of males was significantly higher than females [41.2 years (SD, 9.6) vs. 37.6 years (SD, 9.3), p=0.0004]. The majority (78.5%) of AT ruptures occurred during sporting events, with 31% of these attributed to netball.

More recently, Lantto et al (2014)²⁸ examined the epidemiology of AT rupture over a 33 year period in Oulu, Finland from 1979 to 2011. There were 528 ruptures in 515 patients (456 male, 59 female) with a mean age of 43 years for all patients (SD 13, range 19-90). Sports-related injuries accounted for 70% of cases. The overall incidence increased from 2.1 (95% CI 0.3-7.7) per 10⁵ person-years in 1979 to 21.5 (95% CI 14.6-30.6) per 10⁵ person-years in 2011. For each 11-year period, the incidence of ruptures increased in all age groups; in the first 11-year period (1979-1989) the highest incidence was in the 40-49 years old age group, but for the next two 11-year periods (1990-2000, 2001-2011) the highest incidence was in the 30-39 year old age group.

2.2.2 Etiology

There are two main theories advocated for the cause of, or predisposition to, AT rupture within the orthopaedic literature: the degenerative theory and the mechanical theory^{1,2}. Several other factors have also been associated with AT rupture but with little agreement amongst researchers regarding definitive contributions¹⁷. These factors include poor

tendon vascularity^{17,29}, iatrogenic effects from drug therapies (corticosteroids, fluoroquinolones, anabolic steroids)^{15,16,32}, hyperthermia-associated rupture³³, and underlying genetic and autoimmune conditions^{34,35}.

2.2.2.1 The Degenerative Theory

The degenerative theory suggests that chronic degeneration of the tendon leads to a rupture without excessive loads being applied². Arner et al (1959)³⁶ were the first to report degenerative changes in patients with AT rupture, however, the histologic specimens were obtained more than two days post-rupture. Davidsson & Salo (1969)³⁷ reported marked degeneration in the AT of two patients whom were operated on the day of their injury, indicating that these changes had developed prior to rupture. Kannus & Jozsa (1991)³⁸ suggested that degenerative changes are common in the tendons of people greater than 35 years of age, and that these changes can be associated with spontaneous rupture. Additionally, failure of the extracellular matrix has been proposed to lead to intratendinous degeneration. Jozsa et al (1989)³⁹ observed fibronectin on the torn surfaces of ruptured ATs. Fibronectin is normally located in basement membranes, and binds more readily to denatured collagen than to normal collagen, indicating pre-existing collagen denaturation⁴⁰.

2.2.2.2 The Mechanical Theory

According to McMaster (1933)⁴¹, a healthy tendon would not rupture even when subjected to a substantial strain. Barfred (1971)^{1,42}, however, noted that McMaster's experiment involved applying straight traction to the tendon which would ultimately distribute the strain equally throughout the muscle-tendon-bone complex rather than to the tendon itself. Oblique loads or traction during maximal muscle contraction when the tendon length is initially short yields the highest risk of rupture concentrated at the

tendon⁴². These circumstances are likely common in many athletic movements requiring a rapid push-off.

It has been demonstrated that participation in sports plays a significant role in the development of AT problems⁴³. Structural disturbances in lower leg mechanics from overtraining, functional overpronation, and gastrocnemius-soleus insufficiency has been proposed to lead to AT injury. Additionally, repeated microtrauma resulting from eccentric loading of a fatigued muscle may also play an important role in tendon injury⁴⁴. Tendon rupture is ultimately a consequence of multiple micro-ruptures which lead to failure of the tendon after reaching a critical point⁴⁵.

Inglis and Sculco (1981)⁴⁶ hypothesized that malfunction of the proprioceptive inhibitory mechanism which prevents excessive or uncoordinated muscle contractions could cause rupture of an otherwise normal tendon. They further proposed that this mechanism explains why athletes who return to or begin training after a period of inactivity are at greater risk for a rupture.

2.2.3 Mechanism of Injury

Arner & Lindholm⁴⁷ were first to describe the three main categories of indirect trauma resulting in AT rupture. The first category (53% of ruptures in their series) involved pushing-off with the weight-bearing forefoot while extending the knee, as in a 'sprint-start' or jump initiation. The second category (17% of ruptures) involved a sudden, unexpected dorsiflexion of the ankle. The third category (10% of ruptures) was violent dorsiflexion of a plantarflexed foot, as would occur when falling from a height. In all of these mechanisms, traumatic rupture occurs because the force exerted on the rapidly loaded tendon exceeds the tendon's tensile strength⁴⁸.

2.2.4 Clinical Presentation

Patients with acute AT rupture typically describe the sensation of being hit in the posterior aspect of the lower leg at the time of rupture. Some patients report an audible ‘snap’. This is followed by pain, an inability to bear weight, an inability to plantar-flex the ankle, weakness or stiffness in the calf muscle of the affected ankle. Physical examination may reveal edema and bruising; a palpable gap may be felt along the tendon at the site of the rupture, depending on the amount of swelling present. The calf-squeeze test (Thompson test or Simmonds test) and the Knee-flexion (Matles) test are the most sensitive (0.96, 0.88 respectively) and specific (0.93, 0.85 respectively) tests for diagnosing AT rupture⁴⁹.

2.2.4.1 Calf-Squeeze (Thompson or Simmonds) Test

The calf-squeeze test is performed with the patient prone on the examination table and the ankles clear over the edge of the table. The examiner squeezes the bulk of the calf muscle, deforming the soleus muscle and causing the overlying Achilles tendon to bow away from the tibia, resulting in plantarflexion of the ankle if the tendon is intact⁵⁰.

Limited or no movement of the ankle compared to the contralateral (i.e. uninjured) ankle indicates a rupture⁵¹.

2.2.4.2 Knee Flexion (Matles) Test

Also lying prone on the examination table, patients are asked to actively flex their knees to 90 degrees. During flexion, if the injured foot falls into neutral or dorsiflexion, an AT rupture can be diagnosed⁵².

2.2.4.3 Imaging

Although clinical examination is generally sufficient for a diagnosis of a full AT rupture, some researchers have reported that more than 20% of full ruptures can be missed clinically upon initial presentation⁵³⁻⁵⁵. The ability to correctly distinguish a full versus a partial rupture or tendinopathy has clinical implications that directly affect patient care, as the treatment algorithm can be different for each diagnosis⁵⁶. In a study evaluating the ultrasonographic differentiation of full versus partial Achilles tendon ruptures, Hartgerink et al (2001)⁵⁶ reported the following results: sensitivity=100%; specificity=83%; accuracy=92%; positive predictive value=88%; negative predictive value=100%. Evidently, imaging can be a useful adjunct to clinical evaluation and diagnosis.

2.2.4.3.1 Ultrasonography

Ultrasonography (US) is a medical imaging technique that uses high-frequency sound waves and their echoes to produce a two-dimensional image of anatomical structures⁵⁷. Superficial tendons, such as the AT, are well suited to evaluation by high-resolution real-time US⁵⁸. US is a rapid, reliable, and cost-effective means of evaluating the integrity of the AT^{56,59,60}. US has been used increasingly in the investigation of the AT, from the diagnosis of ruptures and tendinopathy to post-treatment followup^{56,61-63}.

Ultrasonography of the AT with linear probes produces a dynamic and panoramic image of the tendon⁶⁴. The AT is composed of longitudinally arranged collagen bundles, which reflect the ultrasound beam. A normal AT appears as a hypoechogenic, ribbon-like image that is contained within two hyperechogenic bands (Figure 2)⁶⁵. Tendon fascicles appear as alternate hypoechogenic and hyperechogenic bands that are separated when the tendon is relaxed and more compact when the tendon is strained⁶⁶. The number of fascicles that are visible with US closely correlates with the frequency of the ultrasound probe used⁶¹.

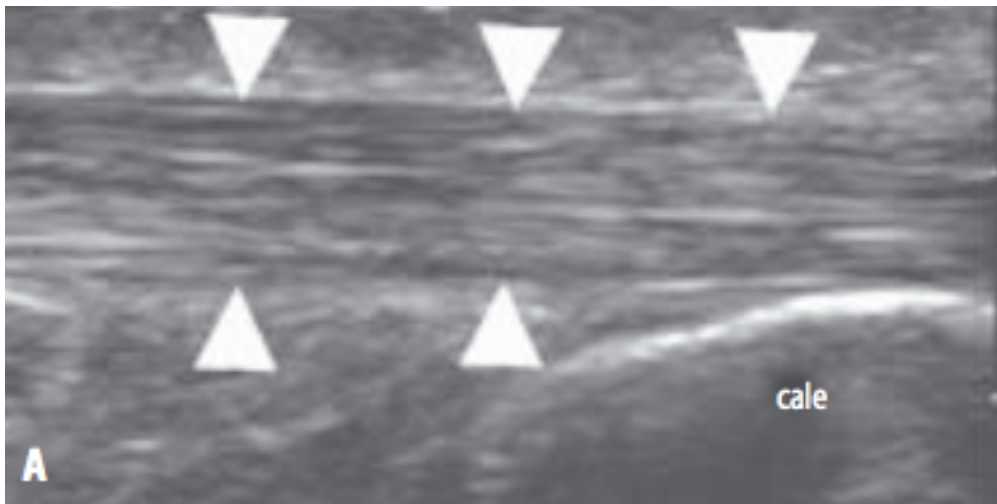


Figure 2 Ultrasonographic appearance of a normal Achilles tendon

Reproduced with permission of W.B./Saunders Co. in the format thesis/dissertation via Copyright Clearance Centre (order detail ID: 68044510)

When the AT is ruptured, the site of rupture will appear as an “acoustic vacuum,” which represents a gap in the tendon, with irregular edges on the ultrasonography image^{67,68} and possible hypoechoic fluid distension of the synovial sheath⁶⁹ (Figure 3)⁵⁶. Partial tears appear as abnormal hypoechoic or anechoic clefts typically within an enlarged tendon surrounded by anechoic or hypoechoic fluid⁶⁹. In cases of diagnostic uncertainty, dynamic evaluation of the tendon during dorsi- and plantar-flexion movements can aid in detecting tendon discontinuity, which indicates full rupture⁷⁰.

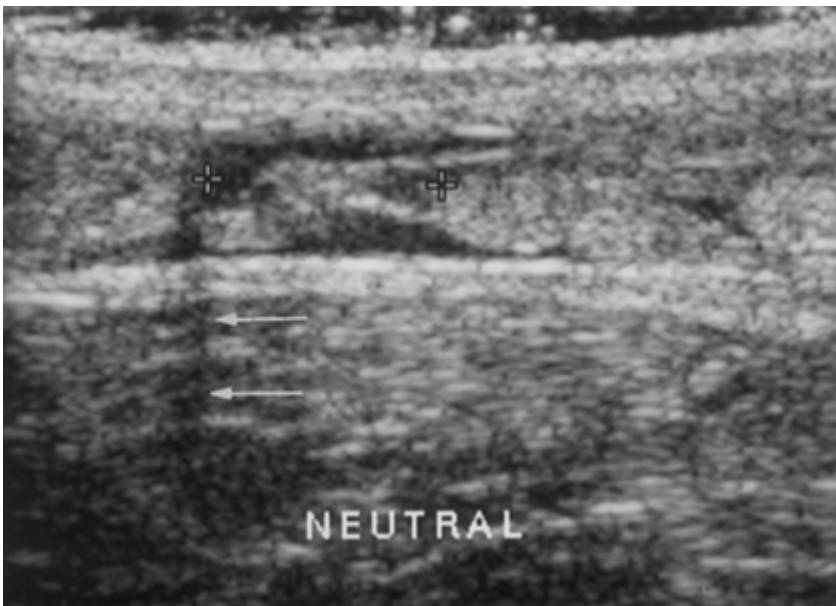


Figure 3 Ultrasonographic appearance of a ruptured Achilles tendon

Reproduced with permission from Hartgerink, Fessell, Jacobson, et al (2001); *Radiological Society of North America*; 220; 406-412

2.2.4.3.2 Magnetic Resonance Imaging

A magnetic resonance imaging (MRI) scan is a diagnostic imaging procedure whereby powerful magnets and radio waves produce images of the internal structures of the body. MRI is a powerful and versatile diagnostic tool that can provide definitive diagnoses for a wide range of musculoskeletal pathology⁷¹. There are several factors that influence the quality of the images obtained, including: lack of motion during the procedure; the signal intensity and resolution of structures; and tissue contrast⁷². Different MRI sequences or protocols are used when evaluating different structures of interest (i.e. tendons, ligaments, bone, etc.) in order to optimize the intensity, resolution, and contrast of the images⁷².

2.3 Healing Following Achilles Tendon Rupture

Tissue regeneration and turnover in the Achilles tendon is an extremely slow process. It has been demonstrated that the core of the AT are formed during skeletal growth and maturity, with very little regeneration thereafter⁷³. In contrast, the periphery of the tendon is capable of altering its structure, composition, and mechanical properties in response to mechanical forces through fibroblast-mediated biomechanical signaling. The physiological and pathological changes associated with this process are not well understood^{74,75}.

The repair of injured tendons can generally be described in three overlapping phases: the inflammatory phase; the proliferative or reparative phase; and the remodeling phase^{14,15}. In the inflammatory phase, bleeding caused by the rupture leads to hematoma and subsequent activation of platelets and neutrophils, which leads to the release of growth factors, chemotactic factors, and vasoactive factors. These factors recruit tendon fibroblasts to begin collagen (type III) synthesis and deposition. This phase of healing generally lasts between 24 and 48 hours, but these processes can occur up to seven days and overlap into the next phase of healing. Approximately three days after the injury, the proliferative phase begins which is highlighted by increased angiogenesis and collagen production. Water content and glycosaminoglycan concentration are high during this time. After approximately six weeks, the remodeling phase begins and can last for several years. This phase is characterized by decreased cellularity, decreased type III collagen synthesis, and a gradual increase in type I collagen synthesis. The repaired tissue changes to fibrous tissue, which again changes to scar-like tendon tissue after 10 weeks. During the latter stages of remodeling, covalent bonding between collagen fibres increases which results in higher stiffness and tensile strength in the repaired tissue^{14,15,74-77}.

2.3.1 Clinical Assessment of Healing

The clinical assessment of AT healing uses many of the same criteria as the clinical diagnosis of AT rupture (i.e. palpation of the tendon, Thompson's test, Matles test). Additionally, there are functional criteria that clinicians use to subjectively assess the integrity and healing of the tendon such as the unilateral heel-rise test, active and passive range of motion, and tendon elongation measures. During the heel-rise test, the patient is asked to perform a heel-rise on their uninjured leg to establish a baseline, followed by a heel-rise on their injured leg. A successful heel-rise is acknowledged if the heel can be lifted at least 2 cm off of the ground with an extended knee. The heel-rise appears to reflect the general level of subjective and objective healing in AT rupture patients⁷⁸. Tendon elongation can be assessed in the Matles test position, where if the injured foot falls into neutral or dorsiflexion it is indicative of tendon elongation⁵². Passive range of motion can also be assessed in this position.

2.3.2 Using Imaging to Assess Tendon Healing

2.3.2.1 Ultrasound

US is frequently used to diagnose tendon injuries, but is less commonly used to assess the state of healing in these structures⁷⁹. US studies that examined tendon structure after rupture or tears of the Achilles tendon have qualitatively assessed several criteria, including: the appearance of torn tendon ends; focal areas of echogenicity; peritendinous reactions, such as edema or effusion; hyperemia via colour Doppler US; the presence of calcifications; and the overall appearance of the tendon with respect to thickening or thinning^{56,58,61,68,80,81}. Several of these criteria are associated with other tendon pathologies, such as tendinitis or tendinosis^{79,80,82}. Additionally, these criteria have not been consistently correlated with clinical or functional parameters^{81,83}. The relative

importance or contribution of each of these criteria to tendon healing after rupture is therefore unknown.

Hollenberg et al (2000)⁶¹ described the gray-scale and colour Doppler sonographic appearance of healed AT ruptures that have been treated non-operatively. A total of 11 patients were evaluated at baseline and at a mean of 22.4 (range 7-38) months post-injury, when the treating physician considered the patient clinically healed. Distortion of the fibrillar architecture decreased markedly in all follow-up scans. In only 4 of 11 cases were the tendon ends still visible at the torn rupture site (Figure 4)⁶¹. Gaps between the torn tendon ends seen acutely in three patients were resolved upon tendon healing. Hematomas were present in all initial scans, and were resolved in all but one follow-up scan. The healed rupture sites were notable for mild residual distortion of the normal fibrillar architecture, slight anterior bulging or irregularity of the healed tendon, and a hypoechoic area at the site of prior rupture (Figure 5, Figure 6)⁶¹. The authors concluded that the healed AT after rupture has a different appearance than a normal AT, but that predictions of the appearance the healed tendon could not be made based on the appearance of the initial ruptured tendon.

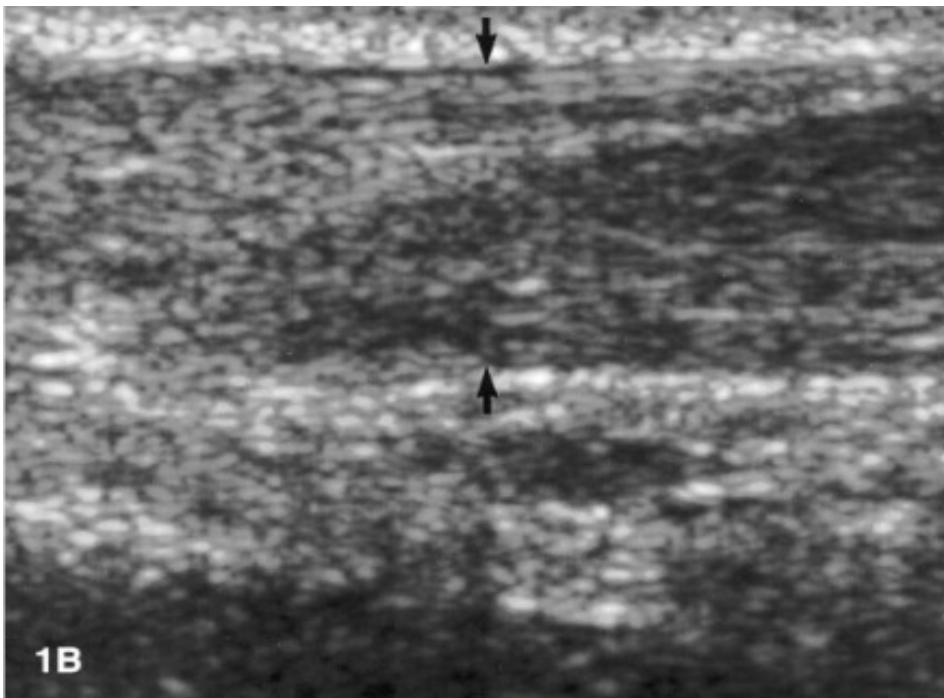


Figure 4 Follow-up scan at 29 months demonstrating a healed tendon with resolution of the hematoma (arrows). The overlapping healed ends remain visible

Reproduced with permission of Springer-Verlag in the format thesis/dissertation via Copyright Clearance Center (order detail ID: 67331498)

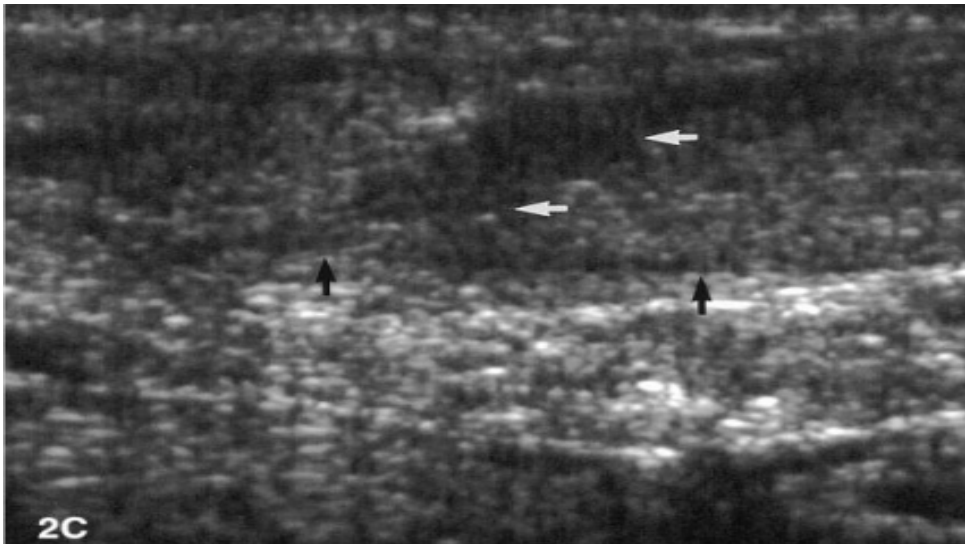

Figure 5 Follow-up scan at 15 months demonstrating a healed tendon with no discernable gap. The hypoechoic band (white arrows) and the slight bulge along the anterior margin of the tendon (black arrows) define the site of prior injury. There is mild residual distortion of the normal fibrillar architecture

Reproduced with permission of Springer-Verlag in the format thesis/dissertation via Copyright Clearance Center (order detail ID: 67331498)

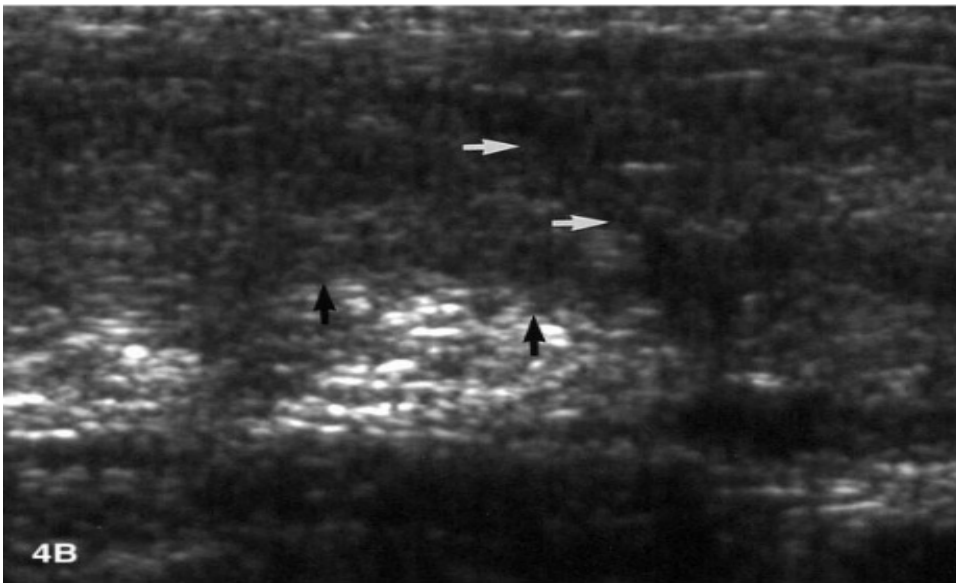


Figure 6 Follow-up scan at nine months demonstrating the healed tendon with a subtle hypoechoic band indicating the site of previous rupture (white arrows). Note the irregular contour along the anterior tendon (black arrows)

Reproduced with permission of Springer-Verlag in the format thesis/dissertation via Copyright Clearance Center (order detail ID: 67331498)

Möller et al (2002)⁸¹ serially evaluated the AT at 6, 12, and 24 months after complete rupture in patients that were randomized to operative and non-operative treatment. Edema and tendon defects were a common finding at six months, but were detected with less frequency after one year. Tendon thickening was noted in 100% of patients at 6 and 12 months, and a transition from a generalized thickness to a fusiform thickness was also noted between these time points. A heterogeneous echogenicity pattern was present in 100% of patients at six months, and 97% of patients at one year. This is consistent with the US findings of Rupp et al (1995)⁸⁴, who found persistent heterogeneity from 2 to 19 years after surgical repair in 56 of 60 patients. The authors of this study concluded no

significant difference in the number of positive imaging findings between operatively- and non-operatively treated patients. Furthermore, there was no correlation between the US imaging outcomes and the clinical and functional outcomes of the patients. A significant limitation of this study is that there was no baseline US images of the tendons which prevents documentation of any changes in appearance between injury and six months post-injury.

2.3.2.2 Magnetic Resonance Imaging

On MRI, a normal AT is generally low signal intensity on all pulse sequences. Some normal ATs may have slightly increased signal intensity near its calcaneal insertion as a result of non-tendinous fatty material interposed between the tendon fibers as it widens. There is a solid vertical line of high signal intensity in the mid-substance of many normal ATs, which likely represents the gastrosoleus complex and should not be mistaken for pathology⁸⁵.

The first sign of tendon abnormality on MRI is often an increase in signal intensity, which could represent a combination of fluid, hematoma, partial tears, or tendon lesions. Complete rupture of the AT appears as a focal disruption with absence of the tendon fibers for variable distances⁸⁵ (Figure 7)⁸⁶. Healing tendons are characterized by having diffusely abnormal signal intensity and tendon thickening on most MRI sequences. From an imaging standpoint, a tendon can be considered healed when the tendon is satisfactorily aligned without a gap⁸⁷.

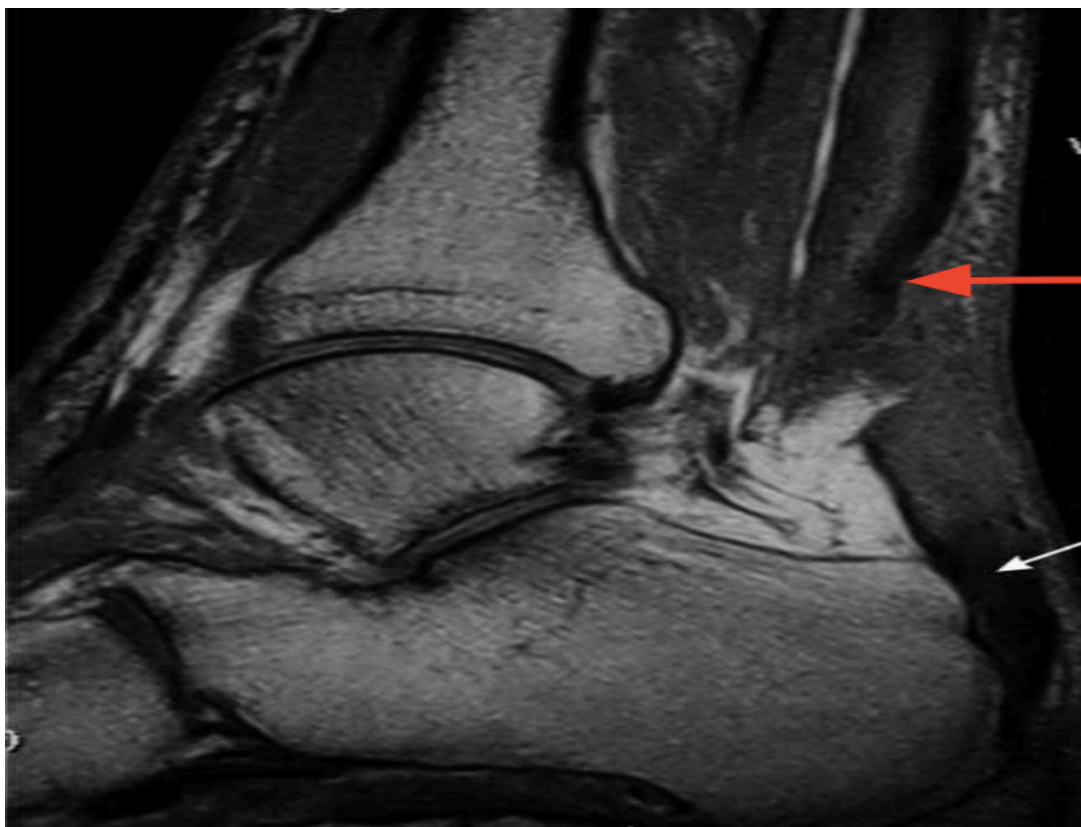


Figure 7 Full thickness tear of the Achilles tendon (T1-weighted sagittal MRI). There is discontinuity of the tendon with retraction of the proximal portion (red arrow). The distal tendon is tendinopathic and appears thickened and of increased signal intensity (white arrow).

Reproduced with permission of BIR in the format republic in a thesis/dissertation via Copyright Clearance Center (order detail ID: 67464872)

Karjalainen et al (1997)⁸⁸ examined MR images of 21 consecutively recruited patients who underwent surgical repair after AT rupture. Images were obtained at 3, 6, 12, and 24 weeks post-surgery. Clinical and functional evaluation occurred at the same time points. An intratendinous area of increased signal intensity (intermediate signal intensity, n=9;

high signal intensity, n=10) was observed in 19 of 21 tendons at three months post-rupture on proton density- and T2-weighted images. The three patients with the largest tendon lesions at three months on MRI had clinically poor outcomes at three months. Furthermore, patients with an abnormal gait pattern at three months (n=5) had significantly larger intratendinous lesions than patients who could walk normally (p=0.03). In all patients, the cross-sectional area of the healing AT showed the largest increase between 6 weeks and 12 weeks post-surgery. Of the nine patients who had intermediate signal intensity lesion at three months, only one patient had a lesion present at six months. Of the ten patients who had areas of high signal intensity at six months, nine still had areas of increased signal intensity but were all reduced in size. The authors concluded that MRI provides a precise valuable tool to evaluate the post-surgical internal structure of the AT. A potential limitation of this study is the use of the 0.1 T MRI scanner, which would yield less contrast and detail in anatomic structures and areas of increased signal intensity versus the conventional 1.5 T MRI scanners used in the present study.

Fujikawa et al (2007)⁸⁹ examined the MRI features of normal AT healing, specifically with respect to the residual gap, in 30 patients who underwent percutaneous repair after AT rupture. AT contour and contrast enhancement at the rupture site was also assessed. Images were obtained approximately 4, 8, and 12 weeks post-surgery. A residual gap was found in 100%, 80%, 0% of the tendons on T1-weighted images and 90%, 100%, and 100% of the T2-weighted images at 4, 8, and 12 weeks, respectively. At eight weeks post-surgery, palpation of the tendon by the clinician did not confirm the presence of a gap despite the tendon gap appearing on MR images. The authors hypothesized that the original gap at the rupture site may have been filled with granulation tissue at eight weeks, but mature fibrous tissue is likely absent. This suggests that palpation of the AT may not be an accurate reference standard for assessing tendon fusion. Intratendinous

enhancement (i.e. abnormal signal intensity) was present in 100%, 73%, and 7% of the tendons at 4, 8, and 12 weeks post-surgery. The authors concluded that the tendon gap visible on MR images can be expected to disappear approximately 12 weeks post-surgery, and that the time-course of the MRI features of the AT after percutaneous repair can be considered to reflect normal healing.

2.3.2.3 Ultrasound Versus MRI in Assessing Healing of Tendon Injuries

Both MRI and US are well-suited to tendon imaging and evaluation, but MRI has been considered the gold standard because of its ability to provide a broader anatomic overview and excellent soft tissue contrast⁹⁰. However, US is a more rapidly performed examination, has greater spatial resolution than MRI, and allows for the dynamic evaluation of the tendon. Furthermore, the advent of US extended-field-of-view imaging allows an image of the entire length of the tendon to be obtained, similar to MRI's ability to display a large anatomic region. It has been proposed⁹⁰ that US should best be considered a focused examination that concentrates on a distinct area of clinical suspicion of pathology, whereas MRI can provide a global assessment of a region of concern.

Several studies that have used both US and MRI to assess various tendon abnormalities have found comparably high levels of accuracy with both modalities^{56,59,91-94}. A recent meta-analysis⁹⁵ of 65 studies comparing MRI, US, and MR arthrogram of rotator cuff tendon tears found that MRI and US were grossly comparable in both sensitivity (85.5% versus 85.1%, respectively; 95% CI=83.7% to 87.3% versus 83.5% to 86.7%, respectively) and specificity (90.4% versus 92%, respectively; 95% CI=89.2% to 91.6% versus 90.8% to 93.2%, respectively). These results, combined with the lower cost and testing duration, suggest that US may be the most cost-effective method of screening for rotator cuff tendon tears. With respect to the longitudinal assessment of tendon healing,

however, Connell et al (2004)⁹⁴ found that MRI was more sensitive than US to follow-up imaging of healing hamstring tendons. To our knowledge, there have been no studies that have longitudinally evaluated the healing AT using both US and MRI.

2.4 Treatment of Achilles Tendon Rupture

AT rupture can be managed by both operative and non-operative strategies, although there is controversy as to which is the optimal treatment. The reason for this controversy is that each treatment has unique advantages and disadvantages. Specifically, operative treatment has been associated with a lower risk for re-rupture but a higher risk for complications (deep infection, deep vein thrombosis, extreme tendon lengthening, scar adhesion, sensibility disturbance), whereas non-operative treatment has previously been associated with a higher risk for re-rupture but lower risk for complications^{3,96,97}.

However, there is recent evidence to suggest that the differing rehabilitation protocols between operative and non-operative management can significantly affect re-rupture rate. When accelerated functional rehabilitation is employed, similar re-rupture rates are evident between operative and non-operative treatment^{5,98-103}. There is little consensus regarding differences in functional recovery between operative and non-operative treatment, primarily due to inconsistencies in how this is assessed⁹⁶.

2.4.1 Operative Treatment

Operative treatment options for AT rupture include open, minimally invasive, and percutaneous repair¹⁰⁴. There are several open surgical techniques, but there is no evidence that adequately demonstrates the superiority of one method over another. Open surgery involves passing heavy, non-absorbable sutures through each stump of the tendon¹⁰⁵. Evidence suggests that the strength of the repair is directly proportional to the number of strands that cross the repair site¹⁰⁶. Percutaneous repair involves using stab

wounds to pass suture through the tendon. This technique minimizes the risk of complications associated with open surgical repair but increases the risk for sural nerve injury^{107,108}.

A recent systematic review conducted by Del Buono et al (2014) compared minimally invasive (including percutaneous repair) and open surgical techniques for treatment of AT rupture. They found that minimally invasive surgery yields a lower rate of complications (re-rupture, deep infections, deep vein thrombosis, and scar adhesion), than open surgery, with comparable functional outcomes (range-of-motion, strength, return to work time), clinical outcomes (pain, calf-circumference) and patient-reported outcomes (AOFAS scale). It was also noted that minimally invasive surgery is less expensive, less time-demanding, and more cosmetically appealing than open repair but future research should address the minimization of iatrogenic complications to the sural nerve during percutaneous repair.

2.4.2 Non-Operative Treatment

Surgical and post-surgical complications have been the primary reason behind the continued focus on non-operative management of AT ruptures. Traditionally, non-operative treatment consisted of immobilized casting of the lower extremity for eight weeks, followed by a standardized rehabilitation protocol. Reports of decreased range of motion, muscle atrophy, and loss of proprioception associated with immobilization¹⁰⁹ have recently challenged this approach. Instead, early dynamic mobilization and weight-bearing with removable below-knee orthoses has become increasingly advocated, as it has been suggested that this can reduce the high risk for re-rupture associated with non-operative treatment^{5,98,110}.

2.4.3 Operative vs. Non-Operative Treatment: A Review of the Literature

A meta-analysis conducted by Bhandari et al (2002)¹¹¹ reviewed articles comparing operative versus non-operative treatment of AT ruptures in the Medline, Grateful Med, and Cochrane databases from 1969 to 2001. The primary outcome of interest was re-rupture rate, and secondary outcomes included deep infection rates, return to normal function, and spontaneous complaints. Three investigators independently reviewed abstracts and graded study quality. Of 273 citations initially identified, six met all eligibility criteria (n=448 patients). Pooled analysis revealed that surgical repair significantly reduced the risk of re-rupture when compared with non-operative treatment (3.1% versus 13%, respectively; RR=0.32; 95% CI=0.14 to 0.71; p=0.005). Five studies provided information on infection rates (n=421 patients) and it was demonstrated that infections only occurred in surgically treated patients (4.7%; range 4% to >20%). The relative risk (RR) of infection with surgical repair was 4.6 times greater than the cast treatment (95% CI 1.2 to 17.8; p=0.03). There was no significant difference in return to normal function and spontaneous complaints. The authors could not provide a strong recommendation for surgery based on these results.

Khan et al (2005)⁹⁷ meta-analyzed all randomized, controlled trials (RCTs) comparing operative and non-operative methods for the treatment of AT rupture. The databases searched included in their search were Embase, CINAHL, and Medline. The outcomes of interest were re-rupture and treatment complications as these were the only consistently reported outcomes that were conducive to meta-analysis. Four reviewers independently assessed all trials and assigned study-strength scores based on methodological rigor. Of the 36 articles identified with their search strategy, 24 were excluded due to retrospective study design, inadequate randomization, and insufficient information. The pooled re-rupture rate for operative treatment versus non-operative treatment was 3.5% (6/173) and

12.6% (23/183), respectively (RR=0.27; 95% CI=0.11 to 0.64). With respect to treatment complications (infection, scar adhesion, disturbed skin sensibility) operative treatment was associated with a higher risk compared to non-operative treatment (34.1% versus 2.7%, respectively; RR=10.60; 95% CI=4.82 to 23.28). The authors noted that future prospective, randomized studies should include larger samples, full reporting of outcomes, and blinded assessors in order for more accurate meta-analysis.

More recently, Jiang et al (2012)⁹⁶ conducted a meta-analysis comparing operative versus non-operative management of AT rupture. Two authors searched six electronic databases (Medline, Embase, Clinical Ovid, BIOSIS, and Cochrane registry of controlled trials) for RCTs between 1980 and 2011. Ultimately, ten trials were recruited for meta-analysis (n=894 patients). The modified Jadad scale was used to assess methodological quality, with eight studies being deemed good or excellent. The primary outcomes of interest were incidences of re-rupture and complications other than re-rupture. Secondary outcomes included the number of patients who returned to pre-injury sports, mean time for sick leave, and results for subgroup analysis (scar adhesion, superficial infection, deep vein thrombosis, sensibility disturbance). The results of the meta-analysis revealed that the operative group had significantly lower re-rupture rate compared to the non-operative group (4.31% versus 9.71%, respectively; RR=0.44; 95% CI=0.26 to 0.74; p=0.002). The operative group demonstrated significantly higher complication rates than the non-operative group (26.6% versus 7.19%, respectively; RR=4.07; 95% CI=1.56-10.67; p=0.004). The mean time for sick leave was shorter following operative treatment than non-operative treatment (MD=-23.75; 95% CI=-41.6 to -5.89; p=0.009). There was no significant difference between the two methods in the number of patients who returned to pre-injury sports. Significant differences were found in favour of the non-operative group with respect to scar adhesion (RR=11.76; 95% CI=4.64 to 29.80; p<0.00001), superficial infection (RR=4.43; 95% CI=0.97 to 20.23; p=0.05), and sensibility disturbance

(RR=7.53; 95% CI=2.55 to 22.18; p=0.0003). There were no significant differences regarding deep infection or extreme Achilles tendon lengthening. Functional assessment could not be assessed in this meta-analysis due to a lack of standardized assessment systems. A significant limitation of this meta-analysis is that the authors did not separately analyze studies that used immobilization versus those that used early mobilization, which is an important distinction since early mobilization has been shown to equalize outcomes^{4,5}

Soroceanu et al (2012)⁵ conducted a meta-analysis of RCTs comparing operative versus non-operative treatment of AT rupture. Two independent reviewers screened 615 abstracts within the most commonly used medical databases (Cochrane, Medline, Web of Science, and Embase) and was the first meta-analysis to include foreign language papers. Ten studies were used for meta-analysis (n=826 patients). The main outcomes of interest were re-rupture rate and complications other than re-rupture (infection, skin and tendon necrosis, fistulas, scar adhesion, sural nerve damage, decreased ankle motion, deep vein thrombosis, and pulmonary embolus). Meta-analysis revealed that if functional rehabilitation with early range-of-motion was employed, there was no significant difference in re-rupture rate between operative and non-operative management (RD=1.7%; p=0.45). However, if the non-operative treatment protocol involved prolonged immobilization the absolute risk reduction (ARR) in the re-rupture risk was 8.8% in favour of the surgical intervention (p=0.001). With respect to other complications, meta-analysis revealed that the risk difference (RD) was 15.8% in favour of non-surgical treatment (p=0.016). The authors of this trial suggested that non-surgical management is equivalent to surgical management with regard to re-rupture rate when functional rehabilitation with early range-of-motion is employed.

2.5 Rehabilitation: Immobilization versus Early Mobilization

Over the past decade, rehabilitation has shifted from immobilizing management towards early mobilization¹¹². The concept of mobilization can be further divided into: controlled early motion, controlled early weight-bearing, or a combination of both. Controlled early motion can be achieved with the use of a dynamic brace which permits movement of the ankle, or using a removable brace and instructing patients to periodically remove the brace and perform ankle exercises⁷⁵. There are varying descriptions of controlled early weight-bearing protocols, however, they generally involve functional bracing of the ankle in an equinus position and weight-bearing immediately post-rupture.

There are several physiological and biomechanical factors that explain the benefits of early mobilization instead of immobilization for rehabilitation protocols¹¹³. Compared to immobilization, early mobilization will: increase blood and lymphatic flow to aid in healing¹¹⁴⁻¹¹⁷; produce tension to stimulate tissue repair for faster healing¹¹⁷⁻¹¹⁹; produce tension to improve tissue alignment during healing¹²⁰⁻¹²²; limit connective tissue fibrosis^{119-121,123,124}; preserve coordination caused by neuromuscular activation from exercise and movement^{125,126}; preserve ROM to avoid or minimize joint fibrosis^{120,121,127}; maintain proprioceptive functions^{123,124}; produce quicker recovery and return to activity^{114,121,123,127}. However, in situations where there are severe open wounds or fractures associated with muscle, tendon, or ligament injuries then immobilization may be necessary¹¹³.

2.5.1 Controlled Early Motion

Cetti et al (1994)⁹⁹ prospectively randomized 60 patients who underwent operative repair of AT rupture to be placed in a new mobile cast (n=30) or a rigid below-knee immobilizing cast (n=30). The mobile cast was constructed such that to allow motion and

weight-bearing as-tolerated during the casting period. All patients had their casts removed at six weeks post-rupture. All patients in the rigid cast group reported painful edema of the injured leg daily during the casting period; there were no such reports in the mobile cast group. Twenty-three patients (77%) thought that the mobile cast was excellent, and six patients (20%) thought that the rigid cast was excellent ($p < 0.00005$). Patients in the rigid cast group had significantly greater calf muscle atrophy upon removal of the cast compared to the mobile cast group (28.7 mm; range = 10-45 mm versus 18 mm; range 8-30 mm, respectively; $p = 0.0019$). Upon removal of the cast at six weeks patients in the mobile cast group had significantly greater active range-of-motion in the ankle compared to the rigid cast group (54.3°; range 30° dorsiflexion to 70° plantar flexion versus 29.5°; range 5° to 60° plantar flexion, respectively; $p < 0.00001$). Ankle mobility remained significantly greater in the mobile cast group at six months and one year ($p < 0.01$). With respect to plantar flexion calf strength, the mobile cast group was significantly stronger at three months, six months, and one year post rupture ($p < 0.01$). There was no statistically significant difference in re-rupture rate between the mobile cast group and rigid cast group. The results of this study suggest early mobilization can lead to favorable outcomes with respect to pain, range of motion, and strength compared to immobilization.

Mortensen et al (1999)¹⁰⁰ conducted a randomized control trial comparing early restricted motion of the ankle ($n=36$) versus conventional cast immobilization ($n=35$) in post-operative AT rupture patients. Early restricted motion was accomplished by bracing the patients in an equinus position (30 degrees plantar flexion) with an elastic band that permits active dorsiflexion to neutral positioning. The immobilization group was casted with their ankle in the equinus position. Both groups were in their respective braces for six weeks post-surgery. The early motion group had significantly greater range of motion than the immobilizing group upon removal of the brace/cast ($p < 0.001$) and at 12 weeks

($p < 0.05$) post-surgery. There were no differences between groups at the final clinical assessment, which ranged from 12 to 24 months post-surgery. There were no significant differences between groups regarding atrophy of calf muscles. The early motion group had significantly better outcomes with respect to subjective result of rehabilitation ($p < 0.05$), scar-adhesion complications ($p < 0.01$), earlier time to resume sports ($p < 0.001$), and earlier time to return to pre-injury sport status ($p < 0.001$). There was one re-rupture in the early motion group, and two in the immobilizing group. The authors concluded that early motion appears to shorten the rehabilitation period while posing no additional adverse risks, suggesting that larger studies are warranted to confirm these findings.

A randomized control trial by Kangas et al (2003)¹⁰¹ compared early functional treatment ($n=25$) versus cast immobilization ($n=25$) in post-operative AT rupture rehabilitation. Early functional treatment involved movement of the ankle from active plantar flexion and active dorsiflexion to neutral while in a brace for six weeks post-surgery, whereas immobilized patients' ankles were fixed at neutral for six weeks. The isokinetic calf muscle strength scores were excellent in 56%, good in 32%, fair in 8%, and poor in 4% of the patients in the early functional treatment group and excellent in 29%, good in 50%, and fair in 21% of the immobilized patients. There were no significant differences with respect to pain, stiffness, subjective calf muscle weakness, or footwear restrictions between groups. There was one re-rupture in the early functional treatment group and two in the immobilization group. The authors advocated the use of early functional treatment due to the potential for slightly better strength outcomes while obtaining similar results in all other functional and subjective outcomes.

2.5.2 Controlled Early Weight-Bearing

Suchak et al (2008)¹⁰² prospectively randomized post-operative AT rupture patients to a rehabilitation protocol that included early weight bearing ($n=55$) or non-weight bearing

(n=55). Early weight bearing commenced at two weeks post-surgery, whereas the non-weight bearing group was immobilized and non-weight bearing for six weeks post-surgery. At six weeks, the early weight bearing group had significantly higher scores on the RAND-36 domains of physical functioning, social functioning, role-emotional, and vitality scores ($p<0.05$). Additionally, patients in the early weight bearing group reported fewer limitations of daily activities at six weeks ($p<0.001$). There were no significant differences between groups at six months. The authors concluded that early weight bearing improves the patients' quality of life in the early post-operative period with no detrimental effect on long-term recovery.

2.5.3 Controlled Early Motion and Weight-Bearing

Saleh et al (1992)¹²⁸ conducted a RCT to compare the effects of early motion and weight bearing (i.e. early mobilization) versus cast immobilization in the non-operative management of patients with AT rupture. Patients randomized to the early mobilization group were placed in a cast for three weeks followed by controlled movement in a Sheffield splint for three to eight weeks. Those in the immobilization group wore a full-leg cast with for four weeks followed by four weeks in a below-knee cast, with weight bearing permitted during the final two weeks. Patients in the early mobilization group had significantly greater dorsiflexion at 3, 6, and 12 months post-rupture ($p<0.001$). Patients in this group also regained mobility (i.e. ability to comfortable weight bear) significantly more quickly than patients in the immobilization group (mean=6 versus 11 weeks, respectively; $p<0.001$). There was one re-rupture in each group. No differences between groups were found regarding plantar flexion range-of-motion or strength at any interval. These results suggest that early mobilization can lead to quicker recovery of dorsiflexion and quicker return to normal activities than immobilization in a plaster cast.

Costa et al (2006)¹²⁹ conducted two RCTs comparing immediate weight bearing mobilization versus cast immobilization in patients with AT rupture. In the first RCT, 48 patients consented to operative management of their injury (n=23 randomized to immediate mobilization group, n=25 to control group). In the second RCT, 48 patients consented to non-operative management of their injury (n=22 randomized to immediate mobilization group, n=26 randomized to control group). Patients in the operative trial began their respective rehabilitation assignments on the first post-operative day. Those in the immediate weight bearing mobilization group were placed in a carbon-fiber orthosis with three 1.5 cm heel-wedges, and those in the immobilization group were placed in a plaster cast. Patients were reviewed every two weeks for an eight week period, where the number of wedges or equinus position of the plaster was reduced at each visit. The cast or orthoses were discontinued at eight weeks. A significant difference was found in favor of the immediate mobilization group versus the control group for the time to return to walking (median=12.5 weeks versus 18 weeks, respectively; 95% CI=10 to 18 versus 18 to 22; p=0.027) and stair climbing (median=13 weeks versus 22 weeks, respectively; 95% CI= 10 to 18 weeks versus 18 to 22 weeks, respectively; p<0.023). There were no significant differences regarding time to return to work or sport, or quality-of-life assessments (EQoL and E5D). There were two re-ruptures in the treatment group due to breaching the rehabilitation protocol. The authors provided further evidence of improved functional outcomes for patients immediately mobilized following operative repair of AT rupture.

In the second trial¹²⁹ the same protocol was employed, with the exception of the orthosis or cast being removed at twelve weeks instead of eight and the removal of wedges or plaster at two-weekly intervals after the six week mark. There were no significant differences between any of the outcome measures in the second trial. There was one re-rupture in the treatment group and one re-rupture in the control group. There were no

significant differences in any of the functional or clinical outcomes for the non-operative trial. The authors suggested, however, that the practical advantages associated with immediate mobilization do not appear to predispose patients to a higher re-rupture rate. They ultimately recommend immediate weight bearing mobilization for all AT rupture patients. It should be noted that, overall, these trials are subject to selection bias as older individuals were recommended non-operative treatment whereas younger and more active individuals were recommended operative treatment, ultimately preventing any between-group comparisons.

More recently, Barfod et al (2014)¹⁰³ completed a RCT comparing early motion and weight bearing (n=30) to early motion without early weight bearing (n=30) in the non-operative treatment of patients with AT rupture. Both groups remained in a foot orthosis for eight weeks, with controlled early motion commencing at two weeks post-rupture. The only difference was that the intervention group could begin weight bearing immediately. The results yielded no significant differences between groups with respect to the Achilles Tendon Total Rupture Score (ATRS), heel-rise work, heel-rise height, time to return to work, or time to return to sport. A significant difference was found in favor of the early weight-bearing group for the quality of life during the eight weeks of treatment (p=0.009). There were three re-ruptures in the treatment group and two re-ruptures in the control group. The authors concluded that immediate weight bearing appears to be a safe recommendation that can improve quality of life during the non-operative treatment period of AT rupture patients.

2.6 A Novel Non-Operative Option: Platelet-rich Plasma

Platelet-rich plasma (PRP) is a generic term referring to products that contain autologous blood-derived platelets concentrated in a small volume of plasma. Specific PRP products

differ with respect to the commercial preparation system used, the absolute concentration of platelets, the presence or absence of platelet activators, the presence or absence of leukocytes, and the delivery technique to the tissue site⁷. PRP has been used in several fields of medicine including cardiovascular surgery, plastic surgery, dental surgery, and more recently in the treatment of orthopedic injuries¹³⁰. Platelets are recognized as the primary source of the growth factors and proteins that are responsible for initiating and regulating tissue healing through the recruitment, proliferation, and differentiation of cells at the site of injury¹³¹. The theoretical concept that concentrating platelets at the site of tissue damage could optimize healing mechanisms provides the rationale for the continued research of PRP in the treatment of orthopedic injuries.

2.6.1 Platelet Biology

Platelets, also called “thrombocytes,” are cytoplasmic fragments of megakaryocytes and are formed in the bone marrow. They are round or slightly oval in shape, measuring approximately 2 μm in diameter. Platelets are anucleate but contain organelles and cellular structures such as mitochondria, microtubules, and granules (α , δ , λ)¹³¹. The α -granules are most abundant¹³² and are the primary source of the growth factors and bioactive proteins that are involved in haemostasis and tissue healing¹³³.

Platelets circulating in the blood stream are inactive; they become activated by von Willebrand factor, collagen (exposed endothelium), or thrombin binding to respective platelet receptors which ultimately initiates a haemostatic intracellular signaling cascade¹³⁴. Subsequently, histopromotive factors released by the platelets facilitate tissue healing via cellular chemotaxis, proliferation and differentiation of cells, removal of tissue debris, angiogenesis, and the formation of the extracellular matrix^{135,136}. More detail regarding this process is provided below.

2.6.1.1 Proteins and Growth Factors in PRP and their Roles

The α -granules of the platelet contain and secrete more than 60 bioactive proteins and growth factors that initiate and/or regulate tissue healing¹³³. Table 1¹³³ outlines these proteins and growth factors in their functional categories and their respective biological role. It should be noted that, although proteins are grouped according to function, some may have multiple potential roles.

| Category | Term | Biological activities |
|---|---|--|
| Adhesive proteins | VWF + pro-peptide, Eg. <u>Fn*</u> , <u>Vn</u> , <u>TSP-1*</u> , <u>laminin-8</u> | Cell contact interactions, clotting, extracellular matrix composition |
| Clotting factors and associated proteins | <u>Factor V/Va</u> , <u>Factor XI</u> , multimerin, <u>gas6</u> , protein S, high-molecular weight kininogen*, antithrombin*, tissue factor pathway inhibitor (TFPI)* | Thrombin production and its regulation, angiogenesis |
| Fibrinolytic factors and associated proteins | <u>Plasminogen</u> , <u>PAI-1*</u> , <u>u-PA</u> , <u>osteonectin*</u> , <u>α2-antiplasmin*</u> , <u>histidine-rich glycoprotein</u> , TAFI, <u>α2-macroglobulin</u> | Plasmin production and vascular modelling |
| Proteases and anti-proteases | Tissue inhibitor of metalloprotease-4 (TIMP-4)*, <u>metalloprotease-4</u> , platelet inhibitor of FIX, protease nexin-2*, C1 inhibitor, <u>α1-antitrypsin*</u> | Angiogenesis, vascular modelling, regulation of coagulation, regulation of cellular behaviour |
| Growth factors cytokines and chemokines | <u>PDGE</u> , <u>TGF-β-1*</u> and -2, <u>EGF*</u> , <u>IGF-1</u> , <u>VEGF (A and C)</u> , <u>bFGF</u> and <u>FGF-2</u> , <u>hepatocyte growth factor*</u> , <u>RANTES</u> , <u>IL-8</u> , <u>MIP-1α</u> , <u>growth-regulated oncogene-α</u> , <u>ENA-78</u> , <u>MCP-3</u> , <u>angiopoietin-1</u> , <u>IL-1β</u> , <u>IGF BP-3</u> , neutrophil chemotactic protein | Chemotaxis, cell proliferation and differentiation, angiogenesis |
| Basic proteins and others | PF4*, <u>β-thromboglobulin*</u> , platelet basic protein, connective-tissue-activating peptide III, neutrophil-activating-peptide-2, endostatins* | Regulation of angiogenesis, vascular modelling, cellular interactions |
| Anti-microbial proteins | Thrombocidins | Bactericidal and fungicidal properties |
| Others | Chondroitin 4-sulfate, albumin, immunoglobulins | Diverse |
| Membrane glycoproteins | <u>αIbβ3</u> , <u>αvβ3</u> , GPIb, PECAM-1, most plasma membrane constituents, receptors for primary agonists, <u>CD40L</u> , <u>tissue factor</u> , P-selectin | Platelet aggregation and adhesion, endocytosis of proteins, inflammation, thrombin generation, platelet-leukocyte interactions |

Table 1 Platelet α -granule contents and their functional categories. Secreted proteins with reported pro-angiogenic properties are underlined while those with anti-angiogenic potential are also identified (*).

Reproduced with permission from Anitua et al. *Autologous platelets as a source of proteins for healing and tissue regeneration*. *Thrombosis & Haemostasis* 2004; 91. 4-15

2.6.1.2 Mechanism of Effect on Tissue

Upon platelet activation, the α -granules fuse to the platelet cell membrane where the proteins and growth factors are completed to a bioactive state by the addition of histones and carbohydrate side chains. The secreted growth factors immediately bind to the external surface of cell membranes of cells of the damaged tissue via transmembrane receptors, ultimately initiating an intracellular signaling cascade which results in the expression of genes responsible for cellular proliferation, matrix formation, osteoid production, collagen synthesis, etc. After the initial burst of PRP-related growth factors, the platelets synthesize and secrete additional growth factors for the remaining seven days of their life span. Once the platelet is exhausted and dies off, the macrophage, which has arrived in the region via the vascular in-growth (i.e. angiogenesis) stimulated by the platelets, assumes the function of wound healing regulation by secreting some of the same growth factors as well as others¹³⁷.

2.6.2 Preparation of PRP

A sample of PRP can be prepared in various pre-treatment settings, including a laboratory, operating room, or a clinic. Once a patient's blood has been obtained, the autologous PRP sample can be prepared in minutes. There are three methods of preparation to obtain a sample of PRP: gravitational platelet sequestration (GPS), standard cell separators, and autologous selective filtration technology (plateletpheresis)¹³¹.

The first method, the GPS is a table-top centrifuge system that separates anti-coagulated blood into three distinct layers of red blood cells, white blood cells, and plasma from bottom to top, respectively. The PRP yield is approximately 10% of the volume of blood drawn. It is important to note that not all centrifugal devices are adequate for the purposes

of preparing PRP, as the centrifugation force may be a critical step in yielding undamaged platelets in the PRP sample¹³¹.

The second method, standard cell separators generally use a continuous-flow centrifuge bowl or a continuous-flow disk separation technique and both a hard (fast) and a soft (slow) spin, yielding platelet concentrations from 2 to 4 times baseline¹³⁸. In this method, a full unit of blood is required from the patient. Most of the red blood cells and platelet-poor plasma can be returned to the patient to maintain circulating volume¹³⁹.

The final method, selective filtration technology or plateletpheresis depends on a single-use disposable proprietary filter designed to concentrate platelets from whole blood. The platelets are captured on the filter and are then harvested to provide a platelet-rich concentrate (PRC) without the need for centrifugation. This method yields a similar platelet concentration compared to the commercial centrifugation method¹⁴⁰.

2.6.2.1 Classification of PRP

Each preparation method will yield a different PRP product with respect to platelet concentration, the presence (buffy-coat) or absence of leukocytes, and the need of a platelet activator (Table 2)⁷. It is also important to note that an individual's platelet count can vary considerably on different days, which could also impact the concentration of platelets in a sample of PRP¹⁴¹. Furthermore, this information is rarely documented in PRP trials, which ultimately limits the ability to make comparisons and meta-analyze data across these trials. DeLong et al (2012)⁷ have proposed a classification system that enables efficient identification of the contents in a PRP sample (Figure 8). Identifying and classifying the contents of PRP samples is a major step towards potentially discovering an optimum dosage or preparation method of PRP⁷.

| Device Name | Centrifuge Time (min) | Initial Blood Volume (mL) | Final PRP Volume (mL) | Platelet Concentration From Baseline | WBC Content | References |
|---|-------------------------|---------------------------|--------------------------|--------------------------------------|----------------------------|----------------|
| Plasma-based PRP systems | | | | | | |
| Arthrex (Naples, FL)/ ACP (Edison, NJ) | 5 | 16 | 4-7 | 2×-3× | Minimal to none | 22 |
| Cascade/MTF Fibrinet | 6 (plasma) 21 (clot) | 9 | 4.5 (plasma) 2 (clot) | 1.3×-1.7× (plasma) | Minimal to none | 14, 23-25 |
| BTI (Vitoria-Gasteiz, Spain)/ PRGF | 8 | 9 | 2-3 | 2×-3× | Minimal to none | 26-28 |
| Buffy coat-based PRP systems | | | | | | |
| Biomet (Warsaw, IN) GPS II/III | 12-15 | 30 or 60 | 3 or 6 | 2×-8× | Increased over baseline | 29-33 |
| Harvest (Plymouth, MA) SmartPReP 2/DePuy (Warsaw, IN) Symphony II | 12-15 | 20 or 60 | 3 or 7-10 | 3×-7× | Increased over baseline | 24, 32-35 |
| Arteriocyte Medtronic (Minneapolis, MN)/Magellan | 14-20 | 30 or 60 | 3-10 | 3×-7× | Increased over baseline | 14, 33, 36, 37 |
| Emcyte (Fort Myers, FL)/ Genesis CS/Exactech (Gainesville, FL) Accelerate | 12 | 30 or 60 | 3 or 10 | 7×-10× | Increased over baseline | 38-40 |

Abbreviations: ACP, autologous conditioned platelets; BTI, Biotechnology Institute; GPS, gravitational platelet separation; MTF, musculoskeletal transplant foundation; PRGF, platelet rich growth factor.

Table 2 Plasma-Based and Buffy Coat-Based PRP Systems

Reprinted from The Journal of Arthroscopy & Related Surgery, 28 (7), Delong, Russel, & Mazzocca, *Platelet rich plasma: the PAW classification system*, 998-1009, 2012, with permission from Elsevier

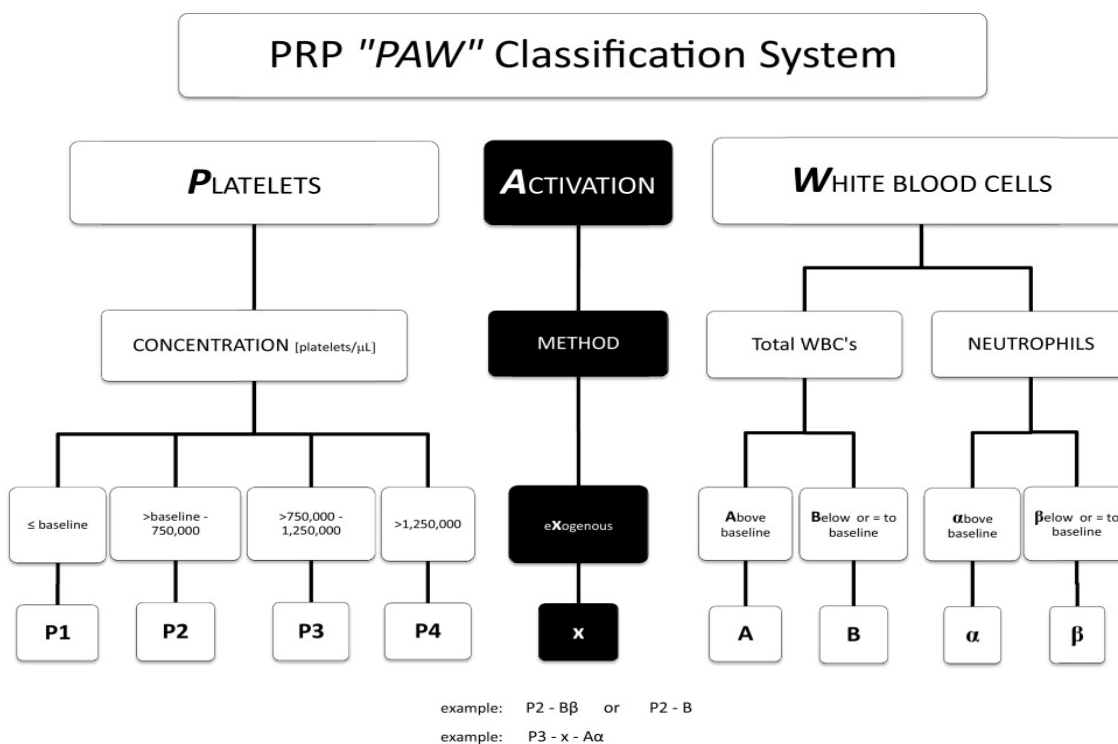


Figure 8 PRP "PAW" Classification System

Reprinted from The Journal of Arthroscopy & Related Surgery, 28 (7), Delong, Russel, & Mazzocca, *Platelet rich plasma: the PAW classification system*, 998-1009, 2012, with permission from Elsevier

2.6.3 Delivery of PRP

Once a PRP sample is prepared, it is stable in the anticoagulated state for eight hours¹⁴². In some instances anticoagulants are used to maintain platelet viability. Anticoagulant citrate dextrose-A (ACD-A) and citrate phosphate dextrose (CPD) are the most commonly used, with the latter being less effective of the two¹⁴³. Upon delivery or application of PRP, the platelets must be activated to release the contents of their α -granules, which can be accomplished exogenously or endogenously. Exogenous activation via external clotting factors results in rapid coagulation of platelets and clot

formation and for this reason are generally applied manually to the tissues, rather than administered by injection⁷. Common exogenous platelet activators include thrombin, calcium chloride, and calcium chloride plus thrombin. Endogenous activation occurs via the platelets binding to exposed tissue collagen and, to a lesser extent, needle-induced bleeding from an injection¹⁴⁴.

2.6.4 PRP in the Treatment of Orthopedic Injuries

A meta-analysis was conducted by Sheth et al (2012)¹³⁰ to determine the efficacy of autologous blood concentrates in the treatment of orthopaedic bone and soft-tissue injuries. They screened 895 potential studies in Medline and Embase databases and identified 23 randomized controlled trials and ten prospective cohort studies that compared PRP or autologous blood concentrates with a control therapy in patients with an orthopaedic injury. Of the 33 studies, 10 examined ligamentous injuries, 14 examined bone injuries, and 9 examined tendinous injuries. A total of 27 different functional outcome measures were used, 11 of which served as the primary outcome of the study. Of the 23 RCTs, six showed that PRP provided a significant functional benefit, 15 demonstrated no difference, one showed that the control provided significant functional benefit, and one did not evaluate functional outcomes. Of the 10 prospective studies, 3 showed PRP provided a significant functional benefit, 6 demonstrated no difference, and 1 showed that the control provided significant functional benefit. There were no commonalities amongst the studies that found a benefit to PRP with respect to: the type of procedure or pathology; the PRP manufacturer/preparation method; the use of an anticoagulant; the activation method; the number of PRP treatment applications; or the volume of PRP used per treatment. The authors concluded that their analysis was limited by marked variability among the studies.. Ultimately, these results suggested that there

was uncertainty regarding the evidence supporting the use of PRP in the treatment of orthopaedic injuries.

A similar conclusion was reached by Willits et al (2013)⁶ who reviewed the literature regarding the use of PRP in the treatment of orthopaedic injuries. Many of the studies included in the aforementioned meta-analysis¹³⁰ were part of this review. Studies were selected for review based on the highest levels of evidence. A total of 17 studies were selected for review: 13 RCTs, two retrospective cohort studies, one prospective cohort study, and one pilot study. Of the 17 studies, 10 examined PRP in the tendon healing, 2 examined PRP in bone healing, 2 examined PRP in muscle healing, and 3 examined PRP in the treatment of intra-articular pathologies. A systematic review and subsequent meta-analysis on the clinical efficacy of PRP in arthroscopic rotator cuff repair was also reviewed. The conclusions of this review suggest no clear indications for the use of PRP in the treatment of musculoskeletal injuries. This is largely due to a lack of homogenous, high level studies, which precludes attempts to compare results across PRP studies.

2.6.5 PRP in the Treatment of Achilles Tendon Ruptures: A Review of the Literature

2.6.5.1 Animal Trials

In an animal study, Aspenberg & Virchenko (2004)⁹ examined effect of platelet concentrate (PC) injections on AT repair in an established rat model. Sprague-Dawley rats (n=263) had their AT surgically transected transversely 3 mm proximal to the calcaneal insertion and a 3 mm long segment was also removed to enlarge the defect. The rats were then randomized to the treatment or control (saline) group by taking coloured marbles out of a hat, randomizing groups of ten rats at a time. Whole blood was collected from three donor rats to prepare the PC sample for injection. The injections took place six hours after the transection. Initially, 20 rats were randomized to receive the PC injection

or control injection. At eight days, the rats were killed and their AT was removed to undergo mechanical evaluation using a material-testing machine that fixed each end of the tendon between two metal clamps and pulled at a speed of 1mm/s until failure. Peak force, stiffness, and energy uptake was recorded for each mechanical evaluation. After a significant improvement was found for this initial test, a repeat experiment was performed which did not reach statistical significance. The authors then conducted three additional experiments using the same parameters. Four more experiments were conducted with different times allotted for healing (11, 14, 21, and 28 days). Mechanical evaluation of the tendons occurred for each of these additional experiments, and histological evaluation of the tendons occurred in the 11 day- and 21 day healing experiments. The eight-day results indicated a significant increase in force at failure (mean=27%; 95% CI=10-44%; $p=0.001$) and stiffness (mean=35%; 95% CI=14-56%; $p<0.001$) in favor of the PC group. No significant differences were observed regarding maximum stress or energy uptake between groups. The reported mechanical results for the remaining healing times are as follows: the force at failure was increased at for all times ($p<0.001$) with the largest difference occurring at 21 days (mean=36%; 95% CI=5-67%); the transverse area was increased by PC treatment at 8 and 11 days, but after 14 days the areas were similar in both groups; the maximum stress was increased in all PC treatment groups ($p=0.004$); The stiffness in all groups increased with healing time ($p<0.001$) and with PC ($p<0.001$), with the largest effect of PC at 11 days (mean=41%; 95% CI=12-70%); the energy uptake in all groups was increased with time ($p<0.001$) and with PC treatment ($p=0.02$), with the largest effect at 21 days (mean=18%; 95% CI=-12%-48%). The histological findings indicated that PC treatment had no detectable effect at 11 days ($p=0.40$), but at 21 days the tendon calluses in the PC group were more mature ($p=0.02$). Although promising, the results of this study should be interpreted cautiously as the methodology of the study should be questioned. The authors did not clearly state a

priori that it was their intention to conduct five sets of identical trials, as it seems that they conducted the additional trials due to the second trial not reaching statistical significance. Furthermore, the effect of PC in these trials was highly variable which the authors attribute to premature platelet activation in some batches of PC samples. The authors ultimately concluded that a single PC injection can improve tendon repair in rats and that these effects can be seen up to four weeks post-injection.

Stemming from the results of Aspenberg & Virchenko (2004)⁹, Virchenko & Aspenberg (2006)¹⁰ evaluated the interplay between platelet-concentrate (PC) injections and mechanical loading in a rat model in an attempt to explain the lasting effects of a single PC injection on AT repair. Tendons were either unloaded with *Botulinum toxin A* (Botox) or mechanically stimulated in activity cages. Sprague Dawley rats (n=130) were used in a series of separate trials with ten rats in each respective group. All experiments included tendon transection with spontaneous healing and were evaluated mechanically. All experiments were evaluated after 14 days except the final experiment which was evaluated at 5 days. In the first experiment, 20 rats received Botox injections and underwent tendon transection seven days later, at which time paralysis (i.e. unloading) appeared complete. Six hours after tendon transection, the rats were randomized to receive an injection of PC (n=10) or a buffer control injection (n=10). This trial demonstrated that with unloading by Botox, there were no stimulatory effects of PC which suggests that mechanical loading is a prerequisite for stimulation of repair by platelets. In the next experiment, 20 rats were randomized to activity cages or normal (i.e. non-activity) cages. After an acclimatization period to their cage, the rats underwent tendon transection and returned to their cages. Upon mechanical evaluation 14 days later, the tendons from activity cages had increased force, energy uptake, and transverse area. This experiment was then repeated with the addition of platelet gel, yielding 4 separate groups: activity cage rates with platelet gel; activity cage rats with no platelet gel; normal

cage rats with platelet gel; and normal cage rats with no platelet gel. These results showed that platelets increased stiffness, reduced area, and increased stress at mechanical failure of the tendon. There was no evidence to suggest that cage activity influenced the tendon's response to platelets. The authors then combined the results of the activity cage experiments (excluding platelet-treated groups from the aforementioned trial) and found that activity increased force (mean increase=12%; 95% CI=0.8-23%; p=0.04), energy uptake (mean increase=18%; 95% CI=2-34%; p=0.04), and tendon area (mean increase=24%; 95% CI=4.6-43%; p=0.02). In the final experiment, 40 rats received Botox injections, followed by randomized to platelet or control treatment after tendon transection and were evaluated after five days. These results showed that platelet treatment increased force (mean increase=37%; 95% CI=11-63%; p=0.01), stiffness (mean increase=52%; 95% CI=15-87%; p=0.01), and area (mean increase=64%; 95% CI=-25-154%; p=0.009). In summary, these results suggest that activity (i.e. mechanical loading) increases size (and thereby force and energy) of the tendon and platelets improve material properties early in the healing process. This appears to occur in sequence, rather than in synergism, as the effects of platelets are absent after 14 days without mechanical loading. This proposed principle, however, does not show directly what time point mechanical loading starts to stimulate repair. With respect to clinical implications in humans, the authors suggest that these results support the use of mobilization in AT rupture rehabilitation and that platelet injections can increase the response of tendon cells to loading of the tendon.

Lyras et al (2009)¹⁴⁵ examined the influence of PRP on angiogenesis during the early (i.e. inflammatory and proliferative) phase of healing in 48 rabbits. The rabbits were randomized to receive PRP (n=24) or a saline injection (n=24) during surgery in both of their transected ATs. Six rabbits from each group were sacrificed at one, two, three, and four weeks, respectively, at which time an immunohistochemical analysis was performed

on the tendons. Microscopic images of the tendons were obtained and an angiogenesis analysis was performed using an established technique. Vessel density (mean number of vessels per mm²) was significantly higher in the PRP group (mean=495) than the control group (mean=322) at one week ($p<0.0001$) and at two weeks (mean=1736 versus 309; $p<0.0001$). At three and four weeks, the control group had significantly higher vessel density than the PRP group ($p<0.0001$). These results suggest that PRP can significantly increase the vascularity of injured ATs in the early stages of healing, corresponding to the inflammatory and proliferative phases. Given that tendons are poorly vascularized structures, an increase in vascularity could contribute to more substantial healing and remodeling of the tendon. It is important to note that although these results demonstrate increased vascularity, there was no biomechanical or functional evaluation of these tendons. These results, therefore, do not have any functional implications.

In 2010, Lyras et al¹⁴⁶ investigated the effect of PRP on transforming growth factor $\beta 1$ (TGF- $\beta 1$) expression during tendon healing in rabbits. The authors hypothesized that PRP alters the tendon healing process by altering the expression of the multifunctional growth factor TGF- $\beta 1$. Expression of TGF- $\beta 1$ was assessed by immunostaining the specimens with anti-TGF- $\beta 1$ primary antibody to which TGF- $\beta 1$ would bind to. A total of 48 rabbits (96 limbs) were randomized to receive a PRP injection or no injection upon surgical transection of their AT. TGF- $\beta 1$ levels were assessed at one, two, three, and four weeks post-transection. The results indicated that the PRP group had significantly higher expression of TGF- $\beta 1$ at one and two weeks ($p<0.0001$), and the control group had significantly higher TGF- $\beta 1$ expression at three and four weeks ($p<0.0001$). In the control group in this study, TGF- $\beta 1$ expression progressively increased over the four week period. Conversely, TGF- $\beta 1$ expression progressively decreased in the PRP group. Ultimately, these results suggest that PRP alters the temporal expression of TGF- $\beta 1$. The significance of this is not completely understood, but the authors suggest that further

study of how various growth factor expression is altered after PRP injections could lead to a more thorough understanding of how PRP affects the healing process.

Kaux et al (2012) studied the effects of PRP on the healing of surgically transected ATs of 120 Sprague-Dawley rats. The rats received either a PRP injection (n=60) or a control injection (n=60), defined as a “physiological solution”. It was not explicitly stated how the rats were allocated into treatment or control groups. Injections were performed two hours after the tendons had been surgically transected. Biomechanical and histological analyses were performed at 5, 15, and 30 days post-injection. Biomechanical evaluation was performed using a traction-compression testing machine, and values for ultimate tensile strength (UTS) were normalized by accounting for the cross-sectional area of the tissue. The UTS represents the amount of force applied to the tissue at its failure point. Histological evaluation was accomplished by staining sections of the tendons and subsequently obtaining photomicroscopic images which enabled the quantification of collagen content. Additionally, tenocyte proliferation was assessed by quantitative reverse-transcription polymerase chain reaction (RT-PCR). The biomechanical results showed that the UTS was higher in the PRP group than the control group at all time points, with statistically significant differences at 15 and 30 days ($p < 0.05$). There were no obvious histological differences in tissue organization between groups. There was, however, increased deposition of structured collagen fibres at day five in the PRP group ($p = 0.03$). Ultimately, these results suggest that PRP influences the early phase of tendon healing from a histochemical standpoint, which results in stronger mechanical resistance during later phases of healing.

2.6.5.2 Human Trials

2.6.5.2.1 Operative Trials

Sanchez et al (2007) examined the effect of PRP injection and a platelet-rich fibrin matrix (PRFM) scaffold application in 12 athletes who underwent open surgical repair of their AT rupture. Six athletes received the PRP treatment and their outcomes were retrospectively compared with six athletes who underwent open surgical repair with no PRP augmentation. Identical surgical procedures were performed in each group, with the addition of a PRP injection into tendon fibers after the tendon was sutured followed by a PRFM application. The PRP treatment group experienced significantly earlier restoration of functional range of motion (7 versus 11 weeks; $p < 0.05$), earlier time to running (11 versus 17 weeks; $p < 0.05$), and earlier time to return to normal training activities (14 versus 21 weeks; $p < 0.05$). Additionally, the mean increase in cross-sectional area of the operated tendon was significantly less in the PRP group than the control group ($298\% \pm 90\%$ versus $499\% \pm 91\%$, respectively; $p = 0.009$). There were no re-ruptures in either group. The authors concluded that the addition of PRP and PRFM scaffolding in open suture repair of AT ruptures could provide opportunities for enhanced healing and functional recovery, although a larger RCT is warranted to confirm these results

In a randomized, patient-blinded study, Schepull et al (2011)¹⁴⁷ consecutively recruited 30 patients for PRP injection ($n = 16$) or no injection ($n = 14$) at the time of open surgical repair of an AT rupture. All patients were operated on within five days of their injury. The primary outcomes were the E-modulus (which describes the elastic property of a tissue) at 7 weeks and the heel raise index at 52 weeks. There were no significant differences in the E-modulus between groups at any time point. Furthermore, there were no significant differences found in the heel raise index at 52 weeks. The patient-reported Achilles tendon rupture score (ATRS) was significantly lower (i.e. inferior

function) in the PRP group than the control group (78 versus 89; $p=0.014$) at 52 weeks. There was one re-rupture in the PRP group who was lost to follow-up, and no reruptures in the control group. The authors concluded that there was no clinical or functional benefit to PRP treatment in AT surgical repair. One possible explanation for the lack of a treatment effect is the fact that patients were immobilized in a plaster cast for seven weeks post-surgery, as it has been demonstrated in animal studies that there is an interplay between autologous platelet augmentation and early mechanical loading in AT repair¹⁰. A weakness of this study is that there was no control injection, which prevented blinding of the clinical investigators to the treatment group of the patients. Investigator blinding could have been accomplished by having saline injections for the control group, and masking the contents of all syringes with opaque tape.

De Carli et al (2015)¹⁴⁸ alternately assigned 30 patients on a case-by-case basis to receive PRP ($n=15$) or no PRP ($n=15$) during surgical repair of AT rupture. Liquid PRP and PRP gel was applied at the suture site in the treatment group. All surgeries were performed within three days of the rupture. Patient-reported outcome measures were assessed at 1, 3, 6, and 24 months and included the VISA-A, FAOS, and VAS. Functional outcome measures were assessed at 6 months and included isokinetic strength assessment and jumping capability assessment. MRI and ultrasound images were also obtained at six months. The results of this study demonstrated that there was no statistically significant differences in any of the patient-reported or functional outcome measures. Furthermore, ultrasound and MRI revealed similar morphostructural findings in both groups with respect to tendon integrity and structure. The authors concluded that, due to substantial equivalence in structural and functional results between groups, there appears to be no clinical benefit to the addition of PRP to surgical treatment of AT rupture. A weakness of this study is the alternate assignment of patients to treatment or control groups, which

enables investigators to deduce the allocation to grouping. Additionally, there was no mention of whether or not patients were blinded to group allocation.

2.6.5.2.2 Non Operative Trials

In a retrospective comparative study, Kaniki et al (2014)⁸ compared the clinical and functional outcomes of consecutively recruited patients (n=73) who received PRP injections in the non-operative management of AT rupture to a historical control group who solely underwent non-operative management (n=72). All injections were performed within 14 days of rupture. The primary outcome was isokinetic strength ratio for plantar flexion of the injured ankle to the uninjured ankle at one year and two years. Secondary outcomes included ROM, calf circumference, Leppilahti score, and AOFAS score. The mean isokinetic strength ratio at 30°/s for the PRP and non-PRP groups was 87.9% ($\pm 19.6\%$) and 92.2% ($\pm 33.9\%$), respectively, at one year and 87.8% ($\pm 15.7\%$) and 91% ($\pm 35.7\%$), respectively, at two years. At 60°/s, the isokinetic strength ratio between the PRP and non-PRP groups was 90% ($\pm 23.3\%$) and 87.6% ($\pm 25.6\%$), respectively at one year and 89.6% ($\pm 21.3\%$) and 84.8% ($\pm 21.1\%$), respectively, at two years. The mean between-group differences were not statistically significant for any speed at any time point. Furthermore, there were no statistically significant differences between groups for any of the secondary outcomes. Two patients in the PRP group and three patients in the control group experienced re-ruptures. Ultimately, these results suggest that there is no measureable clinical or functional benefit from PRP in AT healing. A limitation of this study is the timing of the PRP injections. Patients were injected up to 14 days post-rupture, corresponding to the late proliferative (i.e. secondary) phase of tendon healing. In the present study, we aimed to address this limitation by injecting patients in the late inflammatory (i.e. primary) or early proliferative healing phase in hopes that the effects of the PRP would be more pronounced in this phase.

2.7 Summary

The AT is the most commonly ruptured tendon in the human body; occurring more often in men and in individuals between 30 and 39 years of age. There is some evidence that the incidence of AT rupture increases within the last two to three decades. AT ruptures are more likely to occur during sporting activities, especially those that involve rapid, eccentric, impact loading. Additionally, there are several documented risk factors that can potentially predispose an individual to tendon rupture, but consensus is lacking amongst researchers regarding the definitive contributions of these factors.

AT ruptures can be treated operatively or non-operatively, although the optimal treatment remains controversial. Traditionally, operative treatment of AT rupture has been associated with a lower re-rupture rate compared to non-operative treatment but also a higher complication rate. However, there is evidence to suggest that the rehabilitation protocol, not the initial treatment, has a significant influence on re-rupture rate. Specifically, when an accelerated functional rehabilitation protocol is followed, re-rupture rates are similar between patients treated operatively and non-operatively.

The effectiveness of PRP in the treatment of musculoskeletal injuries remains controversial because studies evaluating its effectiveness use different preparation methods, ultimately yielding a different PRP product with respect to the platelet concentration, the presence or absence of leukocytes, and the need for a platelet activator. Furthermore, this information is rarely documented, limiting the ability to make accurate comparisons across studies.

Achilles tendon healing is a slow process that occurs in three overlapping phases: the inflammatory phase; the proliferative phase; and the remodeling phase. The inflammatory phase lasts approximately 24 to 48 hours and is characterized by the activation of

platelets and neutrophils which leads to the release of bioactive factors that initiate the healing response. Approximately three to five days after injury, the proliferative phase begins whereby angiogenesis and collagen production increases. At approximately six weeks, the remodeling phase begins which results in a gradual increase in type I collagen synthesis. This phase can last for several years. Since platelets activation is generally the most pronounced in the inflammatory phase, it is thought that PRP could have a more pronounced effect if introduced to the ruptured tendon as early as possible, which provides the rationale for the timing of the injections in this study.

The use of imaging (US and MRI) as a measure of outcome in tendon healing has been attempted by researchers, although the criteria used to assess tendon healing differs from trial to trial and the relative importance of each criteria to tendon healing has not been established. Both US and MRI are well-suited to tendon evaluation, with MRI having the advantages of a broader anatomic overview and excellent soft-tissue contrast and US having the advantages of being more rapidly performed, more cost-effective, and the ability to perform dynamic evaluations. Ultimately, it has been demonstrated that US and MRI are grossly comparable with respect to sensitivity and specificity in the diagnosis of tendon pathologies. To our knowledge, however, no studies have longitudinally evaluated and attempted to quantify the healing AT using both US and MRI.

Chapter 3

3 Objectives

3.1 Primary Objective

Our primary objective was to compare the radiological assessments of tendon integrity and healing using ultrasound and magnetic resonance imaging between patients who received two ACP® injections and patients who received two placebo injections in the non-operative treatment of Achilles tendon ruptures.

3.2 Secondary Objectives

The secondary objective of this study was to compare the isokinetic strength scores, Ankle-Hindfoot Scale (AOFAS) scores, Leppilahti scores, Achilles Tendon Total Rupture (ATRS) scores, range of motion, and calf circumference between patients who received two ACP® injections and patients who received two placebo injections in the non-operative treatment of Achilles tendon ruptures.

3.3 Overall Study Objective

The ultimate objective of this study was to determine whether the results support conducting a larger RCT. This thesis is based on the six-month outcomes for 20 patients.

Chapter 4

4 Methods

4.1 Study Design

This study was a single-centre randomized trial where the patients and outcome assessors were blind to group allocation. Patients (n=20) were consecutively recruited from the Fowler Kennedy Sports Medicine Clinic upon referral from emergency rooms in London, Ontario, Canada and surrounding areas. This study was approved by the institutional Health Sciences Research Ethics Board at Western University (Appendix A).

4.2 Eligibility Criteria

Eligible patients had a complete rupture of the Achilles tendon that was confirmed by diagnostic ultrasound within seven days of the initial injury, were able to speak and understand the English language, were willing to follow the recommended rehabilitation protocol, and were between the ages of 16 and 70 years. Patients were excluded if they had previous injury to the Achilles tendon, significant ipsilateral injury (e.g. bone fracture), open injury to the Achilles tendon, avulsion of the Achilles tendon from the calcaneus, or fluoroquinolone-associated rupture. We excluded patients who were pregnant, had any neurological or collagen or vascular disease (stroke, Ehlers-Danlos syndrome, cerebral palsy), diabetic, or unable to tolerate magnetic resonance imaging (MRI).

4.3 Treatment & Rehabilitation Protocol

4.3.1 Acute Treatment

All patients were prescribed a removable below-knee orthosis with a 2 cm heel-lift upon diagnosis of an Achilles tendon rupture. The heel-lift provided approximately 20 degrees of plantar-flexion at the ankle joint, corresponding to the optimal position for healing of the Achilles tendon fibres. Patients were instructed to remain non-weight-bearing in the Aircast™ brace until six weeks post-injury during all activities of daily living with the exception of bathing.

4.3.2 Intervention Protocol

Patients were randomized by computer to receive either Autologous Conditioned Plasma (ACP®) or placebo (saline). All patients, including those in the placebo group, followed an identical injection procedure with the exception of the contents of the injection. Additionally, all patients had an extra vial of blood drawn (approximately 10 cc's) to obtain a complete blood count (CBC) analysis at the time of injection. The clinician (KW), data collectors, and patients were blinded to group allocation. Blinding was accomplished by having a third-party (nurse) perform the computer randomization and prepare the injections. The injections were prepared in a private room where the contents of the syringe were masked by opaque tape.

4.3.3 Autologous Conditioned Plasma (ACP®)

Approximately 10 cc's of blood was drawn from each patient into an Arthrex ACP® double-barrel syringe and spun in a table-top Rotafix 32A centrifuge (Figure 9) at 1500 rpm for five minutes. This process yielded a distinct three-layer distribution of blood components (Figure 10). The double barrel syringe enables the extraction of only the top plasma layer (platelet-rich) without significant contamination from the other two layers.

The amount of plasma obtained from this method ranged from 3 to 4 cc's. Approximately 0.25 cc's of ACP® was transferred to a separate vial in order to undergo a platelet and leukocyte quantification analysis.

Once the plasma had been isolated in the syringe and prepared for injection, the clinician (KW) used palpation and ultrasound measurements to identify the location of the rupture for injection. The injection site was sterilized and then anaesthetized with lidocaine (2%). The ACP® was subsequently injected into the marked site. A second injection was administered two weeks later following an identical protocol.



Figure 9 Centrifuge



Figure 10 Three-layer ACP

4.3.4 Rehabilitation

Patients were advised to begin physiotherapy at four weeks post-injury, placing an emphasis on active plantar/dorsi flexion to neutral, inversion/eversion below neutral, modalities to control swelling, knee/hip exercises, non-weight-bearing cardiovascular work, and hydrotherapy. From six to eight weeks, patients were advised to remove the heel-lift from their Aircast™ boot and begin weight-bearing as-tolerated. Stretching and resistance exercises, proprioceptive training, and cardiovascular training with weight-bearing as-tolerated were also introduced in the protocol. During weeks eight through twelve, patients were weaned off of the Aircast™ boot while using crutches as necessary, then weaned off of the crutches. Progressive increases in strength, proprioception, and range-of-motion (ROM) were also emphasized. After 12 weeks, patients were advised to continue progressing with strength exercise, proprioception, and range-of-motion, while also introducing plyometric training and sport-specific retraining if applicable.

4.4 Primary Outcome – Healing

Healing was assessed through a series of ultrasounds and MRI's. A single, blinded radiologist (AS) interpreted all images and an ordinal estimation of the healing percentage (i.e. 0 to 25%; 26 to 50%; 51 to 75%; 76 to 100%) of the tendon was provided based on objective criteria within each image. These criteria, as well as the methods for obtaining the images are listed below.

4.4.1 Ultrasound

Ultrasound images were obtained by an experienced musculoskeletal sonographer using a Phillips IU22 machine with the linear L12-5 probe (Phillips, Amsterdam, Netherlands). Patients laid prone with their feet hanging over the edge of the exam table in slight dorsiflexion. Transmission gel was used to optimize image quality. Sagittal images were obtained by aligning the long axis of the ultrasound probe with the long axis of the Achilles tendon beginning at the tendon insertion, moving proximally to the musculotendinous junction while simultaneously sweeping across the width of the tendon mediolaterally to visualize the tendon's full extent. Transverse evaluation was accomplished by orienting the long axis of the transducer 90° to the long axis of the Achilles tendon and sliding the probe from distal to proximal. Dynamic imaging consisting of dorsi- and plantarflexion maneuvers while positioning the probe in the sagittal plane was carried out in all patients at baseline and after 6 weeks. Colour Doppler was applied in the sagittal and transverse planes in the vicinity of the tear to assess for hyperemia.

Representative still images and cine clips on ultrasound were captured for review by a musculoskeletal radiologist (AS) with over 20 years of experience. Specifically, the radiologist (AS) quantified the length of the gap (average), presence of hyperemia on

colour Doppler, antero-posterior diameter of the gastrocnemius (injured and contralateral side), echogenicity of the gastrocnemius (isoechoic, hypoechoic, hyperechoic), location of the tear (distance from the calcaneal tuberosity), background tendon quality (normal or tendinosis), maximum tendon diameter remote from tear, and the presence of calcification. At six weeks and onward, dynamic uniform motion of the tendon was also evaluated. The main criteria factoring into the healing estimation for US are: the size or presence of a gap; the degree of uniform motion on dynamic evaluation; and the echogenicity and continuity of the tendon fibres.

4.4.2 MRI

MR images were obtained using a 1.5 T MRI scanner (CVMR, General Electric, Milwaukee, USA) with phased array extremity coil. Patients laid supine on the MRI table and then entered the MR tunnel. Images were obtained in the sagittal and axial planes (see Appendix D for detailed description of imaging sequences). Similar to the ultrasound protocol, these images were evaluated against objective criteria to ultimately yield a percent-healing estimation. Specifically, the radiologist (AS) quantified the length of the gap (average), signal intensity at the site of the tear relative to normal tendon signal (T1, T2, inversion recovery), presence of altered tendon contour, shape of the tendon (circular or ellipsoid), anterior margin of the tendon (concave or convex), maximum diameter of tendon at tear site, presence of peritendinous edema (none, mild, moderate, severe), gastrocnemius signal intensity (normal, mild fatty-infiltration, moderate fatty-infiltration, marked fatty-infiltration), location of tear from calcaneal tuberosity, background tendon quality (normal or tendinosis), and maximum tendon diameter remote from tear. The main criteria factoring into the healing estimation for MRI are: the size or presence of a gap; the T2 signal at the tear site; and the overall appearance and continuity of the tendon.

4.5 Secondary Outcomes

4.5.1 Isokinetic Strength

Strength was assessed using a Biodex Multi-Joint System 3 Dynamometer (Biodex Medical, Shirley, NY) (Figure 11) at six months and one year post-injury. The patient was seated with their hip flexed at 45° supported by a thigh rest with the thigh strapped into place to prevent upper-leg involvement in the strength assessment. The knee was flexed at approximately 30° so that the tibia and fibula were parallel to the floor. The medial malleolus was aligned with the dynamometers axis-of-rotation and the foot was fixed to the dynamometer footplate by two Velcro straps and a modified ankle strap.

Patients performed a set of reciprocal plantar and dorsiflexion contractions at three different testing velocities (30°/s, 60°/s, and 240°/s) on both the injured and uninjured ankle. A brief familiarization period was allotted prior to each new set of contractions. There were four reciprocal contractions at 30°/s and 60°/s and ten at 240°/s. One minute of rest was given between each test velocity. Peak torque (N•m) for plantar flexion and dorsiflexion was calculated by averaging peak torques of individual contractions at each velocity.



Figure 11 Biodes Dynamometer

4.5.2 Range of Motion

Plantar flexion and dorsiflexion was measured by a graduate student using a standard goniometer. The graduate student was trained prior to participant testing by a certified athletic therapist. The patient sat at the edge of the examination table with their knees and ankles positioned in a neutral position at approximately 90° . The axis of rotation was immediately inferior to the lateral malleolus and the long axis of the fibula was used as the fixed lever arm. The moving lever arm was aligned with the fifth metatarsal. The patient was instructed to move into plantar and dorsiflexion and the lever arm was moved accordingly to record the amount of movement in degrees relative to the neutral position. Assessment of plantar- and dorsiflexion ROM has high intra-rater reliability using a goniometer, however, there is little evidence to support high inter-rater reliability due to differences in rater training, the positioning of the patients, and the landmarks used¹⁴⁹.

4.5.3 Calf Circumference

Calf circumference was measured in centimeters using a standard flexible tape measure. Patients were seated at the edge of the examination table with their lower legs relaxed off of the table. Measurements were taken approximately halfway between the patella and the ankle joint at the largest muscle bulk in the gastrocnemius.

4.5.4 Leppilahti Score

The Leppilahti is a disease-specific and functional outcome measure that evaluates patient ratings of pain, calf muscle weakness and stiffness, footwear restrictions, range of motion, and progress satisfaction. Isokinetic strength data for patient plantar and dorsiflexion (30°/s, 60°/s, and 240°/s) is incorporated in the traditional scoring of the Leppilahti. This outcome measure was able to detect change in a similar sample of patients in a previous trial at our center comparing operative to non-operative management of AT rupture.

4.5.5 Ankle-Hindfoot Scale (AOFAS)

The AOFAS is an objective functional scale and a region-specific quality of life measure. This questionnaire examined the patient's function (seven items), alignment (one item) and pain (one item) with a combination of subjective grading from the patient and objective evaluation from the physician. Pain was rated by the patient and alignment was objectively rated by the physician; functional questions were answered by both the patient (four items) and the physician (three items). The AOFAS has demonstrated concurrent validity^{150,151}, criterion validity¹⁵¹, construct validity¹⁵², and test retest reliability¹⁵¹ in patients with various foot and ankle disorders.

4.5.6 Achilles Tendon Total Rupture Score (ATRS)

The ATRS is a self-administered instrument for measuring patient outcomes after treatment for Achilles tendon rupture. There are ten items in the questionnaire that assesses the patient's limitations as a result of their symptomology (i.e. pain, stiffness, etc.) and limitations in various physical activities (i.e. walking, running, climbing stairs, etc.). For each item the patient was required to rate their limitations on a scale of 0 (severe limitations) to 10 (no limitations). The sum of all responses represented their overall score out of 100. This outcome measure was originally in the Swedish population¹⁵³, however, it has demonstrated adequate validity, reliability, responsiveness, and sensitivity in English-speaking populations as well¹⁵⁴.

4.6 Timeline for Outcome Measures

| Outcome Measure | 0 W | 2 W | 4 W | 6 W | 8 W | 12 W | 24 W | 1 Y |
|-----------------|-----|-----|-----|-----|-----|------|------|-----|
| US | X | X | X | X | X | X | X | |
| MRI | | | | X | | X | X | |
| AOFAS | X | | | X | | X | X | X |
| ATRS | X | | | X | | X | X | X |
| ROM | | | | X | | X | X | X |
| Leppilahti | | | | | | | X | X |
| Strength | | | | | | | X | X |

Abbreviations. W = weeks; Y = year; US = ultrasound; MRI = magnetic resonance imaging; AOFAS = American Orthopedic Foot & Ankle Society; ATRS = Achilles tendon rupture score; ROM = range of motion

Table 3 Timeline for all study outcome measures

4.7 Plan for Analysis

We used SPSS version 22 to perform all data analyses except weighted-kappa calculations, for which we used MedCalc version 15.8. The demographic characteristics of each group were presented using descriptive statistics; means and standard deviations were used for continuous variables (e.g. age, height, weight) and proportions for nominal

variables (e.g. gender, affected foot, activity at onset). Because our sample is small, we used non-parametric analyses to test for between-group differences for all outcome measures. For the ordinal estimations of percent healing using US and MRI, we used the Mann-Whitney U test to determine the mean rankings of healing for each group. Additionally, a weighted-Kappa was used to measure the agreement between US and MRI assessments at coinciding time points. For outcome measures with baseline measurements (ATRS, AOFAS) we used the Mann-Whitney U test to determine the median difference in the change scores between baseline and each time point for each group. We used the Mann-Whitney U test when baseline data was not available to determine the median difference in outcome measures at each time point. In all instances, the independent variable was the treatment group and the dependent variable was the ordinal or continuous outcome measure. Outcome data for continuous variables for each group are presented as the median difference with the 25th to 75th interquartile range. A $p < 0.05$ was considered statistically significant. The intention-to-treat (ITT) principle was followed for one patient who was randomized to the ACP® group but was given saline injections due to technical difficulties with the centrifuge. We used last outcome carried forward to fill any missing end point data. Specifically, one patient in the saline group was missing his one-year range-of-motion, calf circumference, and isokinetic strength assessments because he moved out of the province; these outcomes carried forward from the six month assessment. He was able to complete all one-year patient-reported outcome measures (AOFAS, ATRS, Leppilahti, return-to-sport) via the online data management system (www.empowerhealthresearch.ca).

Chapter 5

5 Results

5.1 Participant Flow

The flow of patients through each stage of the study is outlined in Figure 13. Between February 2014 and June 2015, 74 patients were screened for eligibility. Of these, 42 did not meet the eligibility criteria and eight declined to participate. We excluded patients if they presented to clinic at their baseline visit greater than seven days post-rupture ($n=39$), were greater than 70 years of age ($n=2$), or were diabetic ($n=1$). Patients declined to participate in the study because they did not want to receive an injection ($n=3$) and because they were unable to commit to all follow-up appointments ($n=5$). A protocol deviation occurred for one patient who was greater than seven days post-rupture at the baseline visit but was enrolled in the trial. A total of 24 patients were included in our randomized control trial. One patient was lost to follow-up at the one year visit because he moved to a different province.

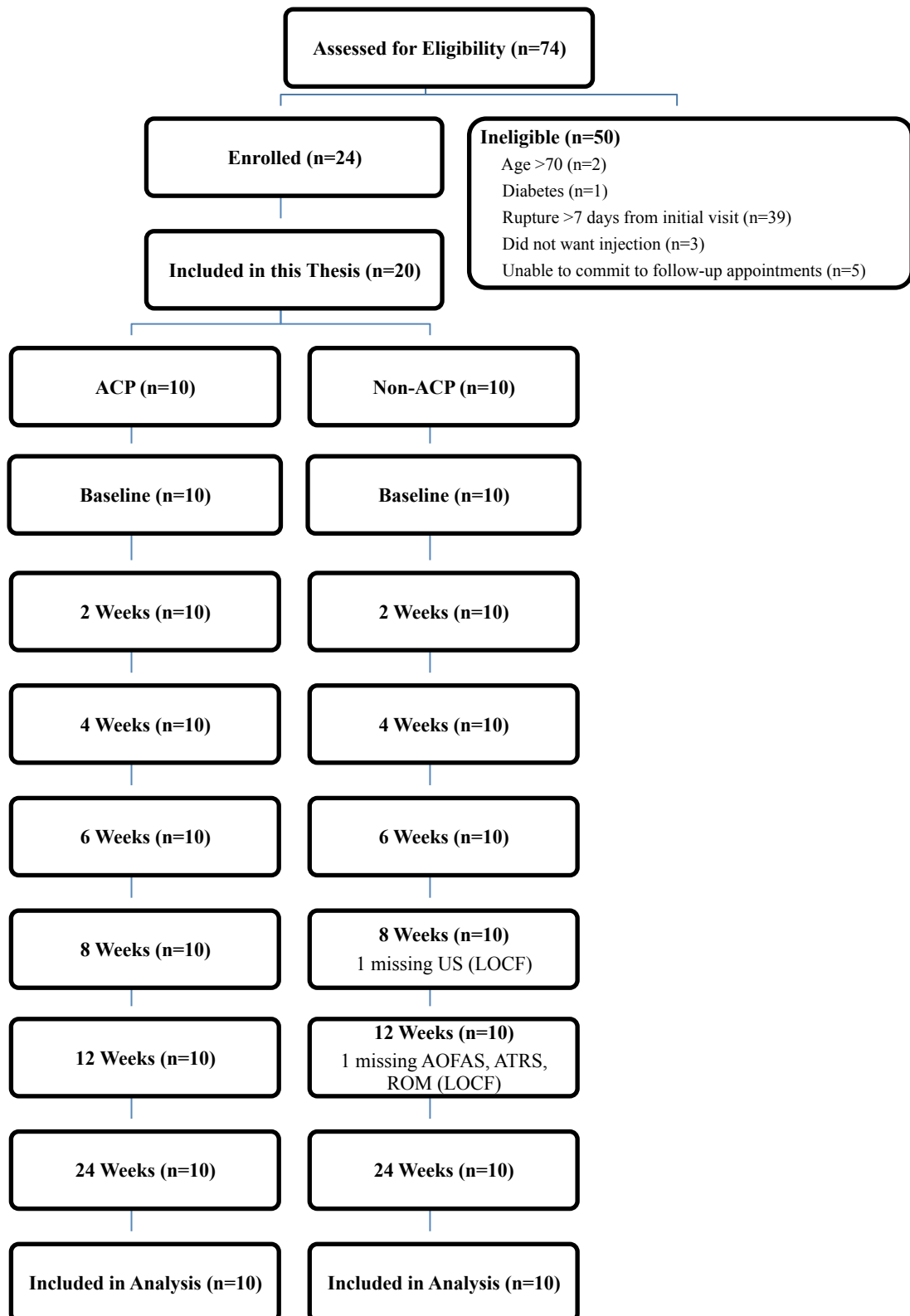


Figure 12 Participant flow through the trial

5.2 Demographic Information

At the time of analysis, 20 patients had completed the study protocol to six months of follow-up. Patient demographic characteristics were similar between groups (Table 4).

| Characteristics | ACP® (n=10) | Non-ACP® (n=10) |
|--|------------------------|------------------------|
| Sex, n (%) Male | 8 (80) | 8 (80) |
| Median Age (IQR), years | 39.0 (29.0 to 61.0) | 38.0 (33.0 to 46.0) |
| Median Height (IQR), cm | 177.8 (171.4 to 181.6) | 174.0 (165.1 to 180.7) |
| Median Weight (IQR), kg | 80.7 (75.0 to 91.8) | 87.0 (71.8 to 93.2) |
| Injured Achilles, n (%) Right | 5 (50) | 3 (30) |
| Injured Achilles, n (%) Dominant | 6 (60) | 6 (60) |
| Activity at injury, n (Sports or ADL) | 10 (Sports) | 10 (Sports) |

Abbreviations: IQR = Inter-quartile range; ADL = activities of daily living

Table 4 Patient demographics

5.3 Injection Information

White blood cell (WBC) and platelet quantification was conducted on both blood and ACP® samples from nine patients at baseline and at two weeks. One patient was missing WBC and platelet quantification on the ACP® sample at baseline because there was an insufficient amount of the sample to conduct the analysis (Table 5).

| Time | Blood WBC Count* (mean ± SD) | Blood Platelet Count* (mean ± SD) | ACP® WBC Count* (mean ± SD) | ACP® Platelet Count* (mean ± SD) | Amount Injected‡ (mean ± SD) |
|----------|------------------------------|-----------------------------------|-----------------------------|----------------------------------|------------------------------|
| Baseline | 7.7 (1.8) | 215.1 (16.9) | 0.9 (0.8) | 390.7 (41.2) | 3.2 (0.4) |
| 2 Weeks | 6.9 (1.6) | 232.2 (32.9) | 0.8 (1.0) | 441.6 (76.3) | 3.1 (0.2) |

Abbreviations. WBC = white blood cell; ACP = Autologous Conditioned Plasma; SD = standard deviation

*cell count x10⁹/L

‡cubic centimeters (cc's)

Table 5 White blood cell and platelet counts of patients' blood and ACP samples

5.3.1 “PAW” Classification

Based on the classification system proposed by DeLong et al (2012)⁷, our ACP® system would be classified as “P2-Bβ”. “P2” represents a platelet concentration that is above baseline and up to 750 x 10⁹ platelets/L. “B” and “β” represent below baseline concentrations of WBC and neutrophils, respectively.

5.4 Location of Tendon Rupture

Tendon ruptures occurred at a mean of 5.2 cm (\pm SD 1.3 cm) from the calcaneal insertion as measured by baseline US assessments.

5.5 Primary Outcome

5.5.1 Estimated Percent Healing

One patient in the non-ACP® group was missing eight week ultrasound data. There were no statistically significant differences between groups in the estimated percent healing at any time for US or MRI assessments. The mean rankings were higher in the ACP group versus the non-ACP group at 4 weeks (11.0 versus 10.0), 8 weeks (11.2 versus 9.8), and 12 weeks (11.85 versus 9.15) for ultrasound assessments. The mean rankings were equal at 24 weeks. The mean rankings were higher in the ACP group at 12 weeks (12.6 versus 8.4) and 24 weeks (11.4 versus 9.6) for MRI assessments. Figures 13-18 present the number of patients in each group that correspond to each healing range for both US and MRI at each time point.

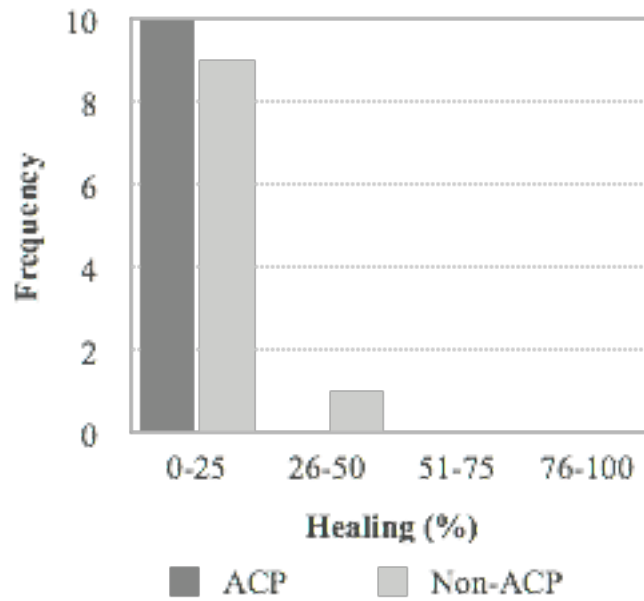


Figure 13 Estimated percent healing at two weeks post injection with ACP or saline based on ultrasound imaging

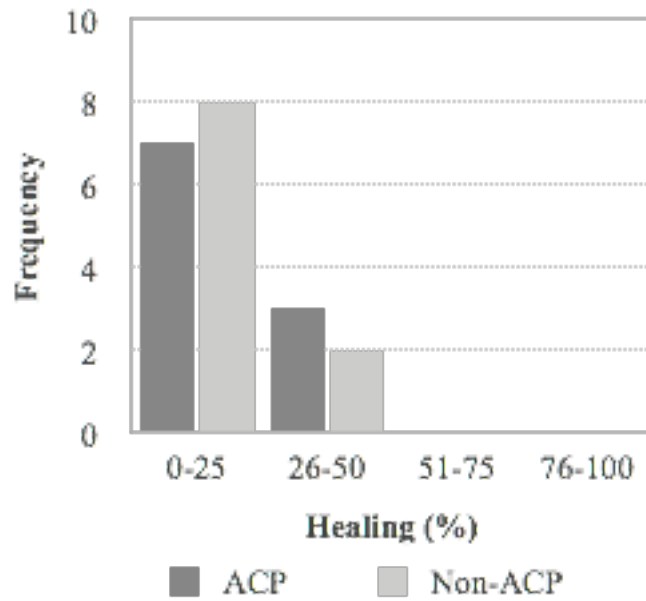


Figure 14 Estimated percent healing at four weeks post injection with ACP or saline based on ultrasound imaging

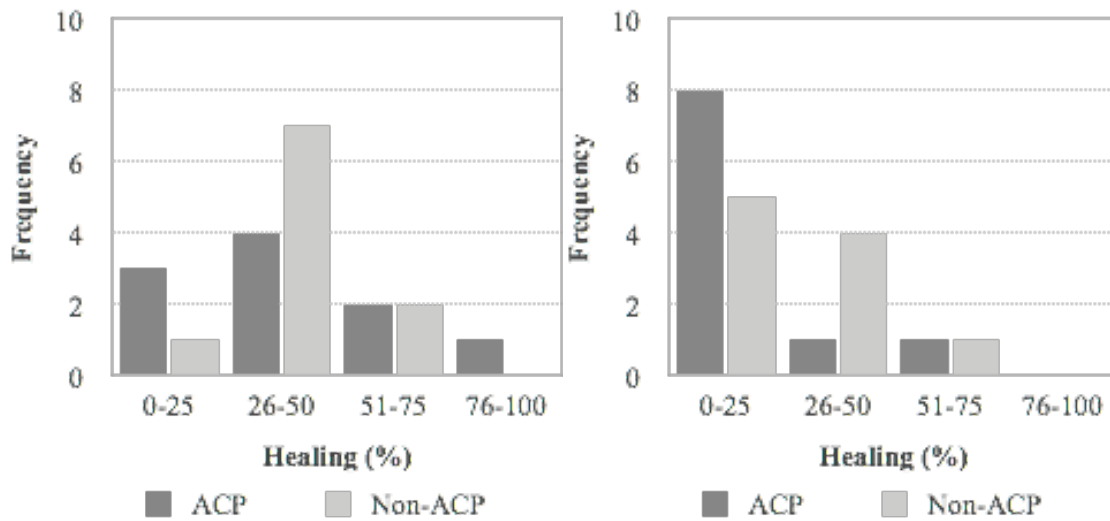


Figure 15 Estimated percent healing at six weeks post injection with ACP or saline based on ultrasound imaging (left) and MRI (right)

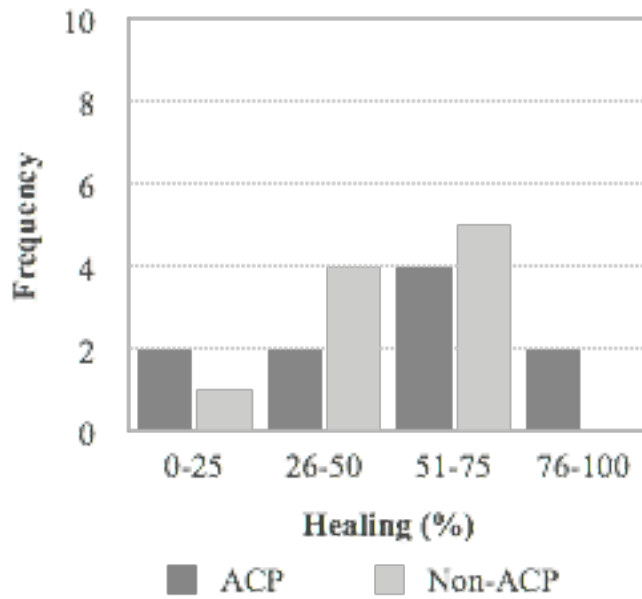


Figure 16 Estimated percent healing at eight weeks post injection with ACP or saline based on ultrasound imaging

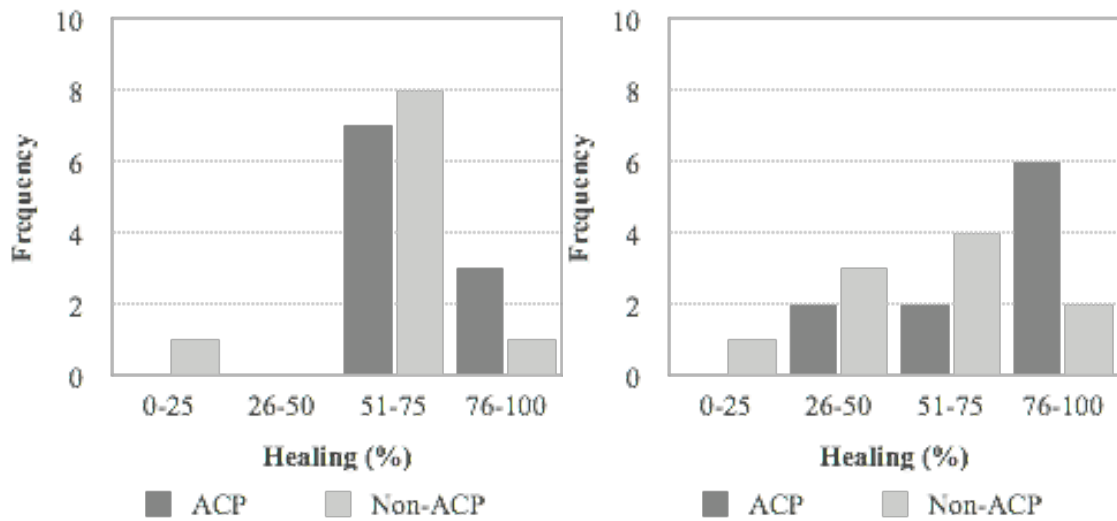


Figure 17 Estimated percent healing at 12 weeks post injection with ACP or saline based on ultrasound imaging (left) and MRI (right)

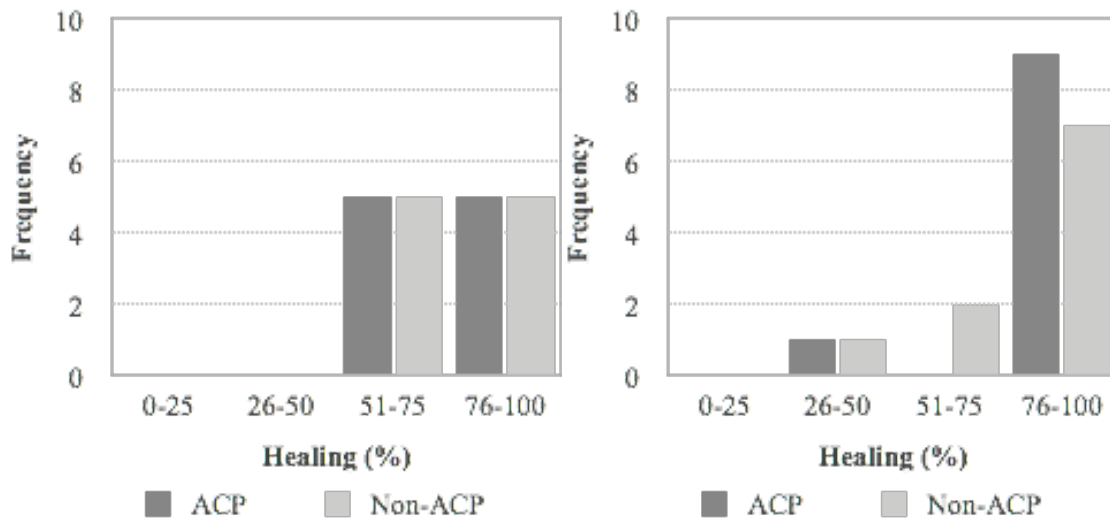


Figure 18 Estimated percent healing at 24 weeks post injection with ACP or saline based on ultrasound imaging (left) and MRI (right)

5.5.1.1 US and MRI Agreement

5.5.1.1.1 Estimated Percent Healing

The agreement between US and MRI ratings of healing was “fair” at 6 and 12 weeks, and “poor” at 24 weeks (Table 6).

| Test | Agreement (95% CI) | | |
|----------------|----------------------|---------------------|----------------------|
| | 6 Weeks | 12 Weeks | 24 Weeks |
| Weighted Kappa | 0.20 (-0.06 to 0.46) | 0.36 (0.03 to 0.68) | 0.17 (-0.10 to 0.43) |

Abbreviations. CI = confidence interval. *Note:* According to Altman (1999)¹⁵⁵ (slightly adapted from Landis & Koch (1977)¹⁵⁶), agreement is classified as ‘poor’ if $\kappa < 0.20$, ‘fair’ if $\kappa > 0.20$ to 0.40 , ‘moderate’ if $\kappa > 0.40$ to 0.60 , ‘good’ if $\kappa > 0.60$ to 0.80 , and ‘very good’ if $\kappa > 0.80$ to 1.00 .

Table 6 Ultrasound and MRI agreement on ordinal ratings of estimated percent healing at 6, 12, and 24 weeks

5.6 Secondary Outcomes

5.6.1 Patient-Reported Outcomes

There was one patient in the non-ACP® group who did not complete the 12 week AOFAS and ATRS questionnaires. The ACP® group had higher median AOFAS change scores at six weeks and higher median ATRS change scores at 12 and 24 weeks. There was no significant difference in the median change scores from baseline at any time point for the AOFAS or the ATRS outcome measures. Both groups had improved change scores at each successive visit. There was a statistically significant difference in favor of the ACP group at 24 weeks for the Leppilahti score ($p=0.04$) (Table 7).

| Time | Outcome | ACP® Median (IQR) | Non-ACP® Median (IQR) | p-value |
|----------|------------|----------------------|--------------------------|---------|
| 6 weeks | AOFAS | 32.0 (21.5 to 38.5) | 29.0 (23.8 to 36.3) | 0.80 |
| | ATRS | 12.0 (5.5 to 22.8) | 19.5 (10.5 to 32.0) | 0.44 |
| 12 weeks | AOFAS | 38.0 (26.0 to 56.3) | 40.5 (37.0 to 50.5) | 0.85 |
| | ATRS | 38.0 (15 to 47.5) | 32.0 (19.3 to 40.3) | 0.28 |
| 24 weeks | AOFAS | 45.5 (38.3 to 60.0) | 48.5 (36.8 to 55.3) | 0.63 |
| | ATRS | 66.5 (48.0 to 78.0) | 61.0 (37.5 to 80.0) | 0.74 |
| | Leppilahti | 75.0 (61.3 to 80) | 55.0 (42.5 to 71.3) | 0.04 |

Abbreviations. ACP® = Autologous Conditioned Plasma; AOFAS = American Orthopedic Foot and Ankle Society; ATRS = Achilles Tendon Total Rupture Score; IQR = Interquartile range (25% to 75%)

Table 7 American Orthopedic Foot and Ankle Society score, Achilles Tendon Total Rupture Score at 6, 12, and 24 weeks and Leppilahti score at 24 weeks post-rupture

5.6.2 Functional Outcomes

5.6.2.1 Range of Motion

One patient in the non-ACP® group was missing ROM data at 12 weeks. The ACP® group had a lower median side-to-side deficit in plantar flexion at 6 and 24 weeks, and a lower median side-to-side deficit in dorsiflexion at 12 and 24 weeks. There was a statistically significant difference in the median side-to-side difference in dorsiflexion

ROM at 12 and 24 weeks in favor of the ACP®. Additionally, the ACP® group had a lower deficit in median calf circumference at 6 and 24 weeks. There were no statistically significant differences in plantar flexion or calf circumference between groups at any time point (Table 8).

| Time | Measurement (unit) | ACP® Median Difference* (IQR) | Non-ACP® Median Difference* (IQR) | p-value |
|----------|--------------------|-------------------------------|-----------------------------------|---------|
| 6 weeks | PF° | 5.5 (-1.8 to 19.3) | 13.5 (4.5 to 18.3) | 0.35 |
| | DF° | 5.0 (0.0 to 9.5) | 5.0 (3.8 to 10.8) | 0.48 |
| | CC (cm) | 1.0 (0.8 to 3.3) | 2.5 (2.0 to 3.0) | 0.28 |
| 12 weeks | PF° | 5.5 (0.5 to 7.0) | 4.5 (3.8 to 9.8) | 0.63 |
| | DF° | 3.5 (-0.3 to 5.0) | 6.0 (5.0 to 8.0) | <0.01 |
| | CC (cm) | 1.5 (-0.3 to 2.5) | 1.5 (0.8 to 4.0) | 0.63 |
| 24 weeks | PF° | 2.0 (-1.0 to 4.5) | 5.0 (2.0 to 8.3) | 0.16 |
| | DF° | 1.5 (-2.8 to 3.3) | 6.5 (4.5 to 7.5) | <0.01 |
| | CC (cm) | 1.5 (1.0 to 2.0) | 2.0 (0.8 to 2.0) | 0.91 |

Abbreviations. ACP® = Autologous Conditioned Plasma; PF = plantar flexion; DF = dorsiflexion; CC = calf circumference; cm = centimeters; IQR = Interquartile range (25% to 75%)

Table 8 Range of motion and calf circumference measurements at 6, 12, and 24 weeks post-rupture

5.6.2.2 Isokinetic Plantar Flexion Strength

There were no statistically significant differences between groups at any speed at 24 weeks post-rupture for the median strength ratio of the injured to uninjured Achilles, as measured by the peak torque at each speed. The ACP® group had higher strength ratios at 30°/s and 240 °/s (Table 9).

| Speed (°/s) | ACP® Median Strength Ratio % (IQR) | Non-ACP® Median Strength Ratio % (IQR) | p-value |
|----------------|---------------------------------------|---|---------|
| 30 | 75 (55.8 to 83.8) | 71.5 (57.5 to 90.5) | 0.97 |
| 60 | 70.5 (62.5 to 85.0) | 73.0 (58.5 to 91.0) | 0.85 |
| 240 | 90.0 (70.3 to 106.3) | 84.5 (61.8 to 93.8) | 0.25 |

Abbreviations. ACP® = Autologous Conditioned Plasma; IQR = 25% to 75% Interquartile range

Table 9 Isokinetic strength ratio of the injured to uninjured Achilles at 24 weeks post-rupture

5.7 Re-Ruptures and Adverse Events

There were no re-ruptures or adverse events for any patients in either group.

6 Discussion

The purpose of this thesis was to compare the six month results for AT rupture patients who were randomized to receive ACP® or saline injections at baseline (i.e. within seven days) and two weeks post-rupture. Tendon healing was assessed using a longitudinal series of US and MR images. Functional assessments included isokinetic strength and ROM. Quality-of-life, pain, calf circumference, and subjective function was also assessed. We found a statistically significant difference in favor of the ACP® group at 24 weeks for the Leppilahti score; there were no other significant differences between groups at any time point for any other outcome measures. However, it should be noted that our study was not powered to detect statistically significant differences. The aim of this study was not to make clinical recommendations but rather to determine whether a larger RCT is warranted.

Slow tissue turnover and regeneration in the AT results in a lengthy return of normal function for patients with AT rupture. It has been demonstrated that non-operative management of AT ruptures can yield comparable results with respect to function and re-rupture rates to operative management when early mobilization (i.e. accelerated functional rehabilitation) is employed^{4,5}. The use of PRP to augment non-operative treatment to improve healing and function is a sound theory from a physiological perspective, although clinical benefits have yet to be conclusively demonstrated.

In 2014, Kaniki et al⁸ prospectively recruited patients (n=73) with AT ruptures and injected them with ACP® within 14 days post-rupture, followed by a second injection two weeks later. The clinical and functional outcomes of these patients were compared to a retrospective cohort of non-operatively treated patients who did not receive ACP®. There were no significant differences between the ACP® group and the historical control group for isokinetic strength, ROM, or Leppilahti scores. One potential explanation for

the lack of a treatment effect is that the injection period for patients in the ACP® group corresponded to the mid- to late-proliferative (or reparative) phase of tendon healing rather than the inflammatory phase of tendon healing. A significant characteristic of the inflammatory phase of tendon healing is the activation of platelets at the site of injury^{14,15}. It was therefore hypothesized that ACP® injection during this early phase of healing may have a more pronounced effect.

Our results demonstrate slightly more favorable assessments of healing in the ACP® group at 4, 8, and 12 weeks on US and at 12 and 24 weeks on MRI. Furthermore, the secondary outcomes in our study tended to favor the ACP® group over the non-ACP® group: the median ATRS was higher at 12 and 24 weeks; the median Leppilahti score was significantly higher at 24 weeks; the median side-to-side ROM differences were smaller in plantar flexion at 6 and 24 weeks and in dorsiflexion at 12 and 24 weeks; and the isokinetic strength ratio was larger at 30°/s and 240°/s.

One of the issues in the published literature that has made it difficult to draw definitive conclusions about the effectiveness of PRP is that most studies do not report the concentration of the components of the PRP used or the preparation method. Without accurate documentation of the concentration of platelets, the manner of platelet activation, and the presence or absence of WBCs the ability to truly contextualize study results is limited⁷. DeLong et al (2012)⁷ recently provided a means to classify solutions of PRP (Figure 8). According to this classification system, the PRP samples prepared for this study (i.e. ACP®) is “P2-Bβ” which means that the concentration of platelets is greater than baseline but less than $750 \times 10^9 /L$ (P2), the WBC concentration is below baseline (B), and the neutrophil concentration is below baseline (β). A sample of PRP that is too concentrated in platelets (i.e. $>1800 \times 10^9$) can potentially have a toxic effect, resulting in cellular apoptosis, growth factor receptor downregulation, and receptor

desensitization, which ultimately may result in a paradoxical inhibitory effect^{157,158}. PRP samples above baseline and less than 750×10^9 /L have produced favorable results in several studies^{12,159-165}. The presence of WBC and neutrophils above baseline levels in PRP samples has been linked to deleterious effects during tissue regeneration¹⁶⁶⁻¹⁷², thus our preparation method sought to avoid this potential issue by limiting their presence in our samples.

Several studies have described the US or MRI features of an acutely ruptured or healing Achilles tendon^{56,61,81,88,89}, but none have used imaging to provide an overall estimation of healing in the tendon. Furthermore, no other study has evaluated the tendon during the different phases of tendon healing: Hollenberg et al⁶¹ described the US appearance of ruptured ATs treated non-operatively within 48 hours of rupture and again at approximately two years; Möller et al⁸¹ described and evaluated the healing AT following surgery using US and MRI after 6, 12, and 24 weeks; Karjalainen et al⁸⁸ evaluated the AT 3, 6, 12, and 24 weeks post-surgery using MRI. Our study evaluates the non-operatively treated AT within seven days of rupture (inflammatory phase), and at 2 (proliferative phase), 4 (proliferative phase), 6 (proliferative/remodeling phase), 8 (remodeling phase), 12 (remodeling phase), and 24 (remodeling phase) weeks post-rupture, ultimately spanning all phases of the healing process.

Physiologically, the inflammatory phase is characterized by fluid infiltration causing edema and subsequent activation of platelets and inflammatory cells¹³⁻¹⁵. On US imaging, the fluid infiltration can be seen as an anechoic area located at or near the rupture site. Additionally, there was marked loss in the normal fibrillar architecture of the tendon (Figure 19). During the proliferative or reparative phase, tendon fibroblasts have begun collagen synthesis and deposition into the wound site^{14,15}. On US, collagen and other extracellular matrix components (collectively termed ‘granulation tissue’) appeared

echogenic (i.e. bright) relative to the tendon (Figure 20). Similarly, on most MR sequences, granulation tissue appears as increased signal intensity relative to the normal tendon (Figure 21). The remodeling phase is characterized by the transformation of granulation tissue to fibrous tissue, and again to scar-like tissue with high tensile strength^{14,15}. There is decreased cellularity and fluid presence at and around the injury site. Scar tissue appeared hypoechoic to the surrounding tissue on US (Figure 22), and hypointense on MRI (Figure 23). Disruption of the normal fibrillar architecture was evident at 24 weeks post-rupture is a well-documented finding on US as described in previous studies^{56,61,81} Additionally, tendon thickening is evident on both US and MRI also described in previous studies^{61,81,88,89}.

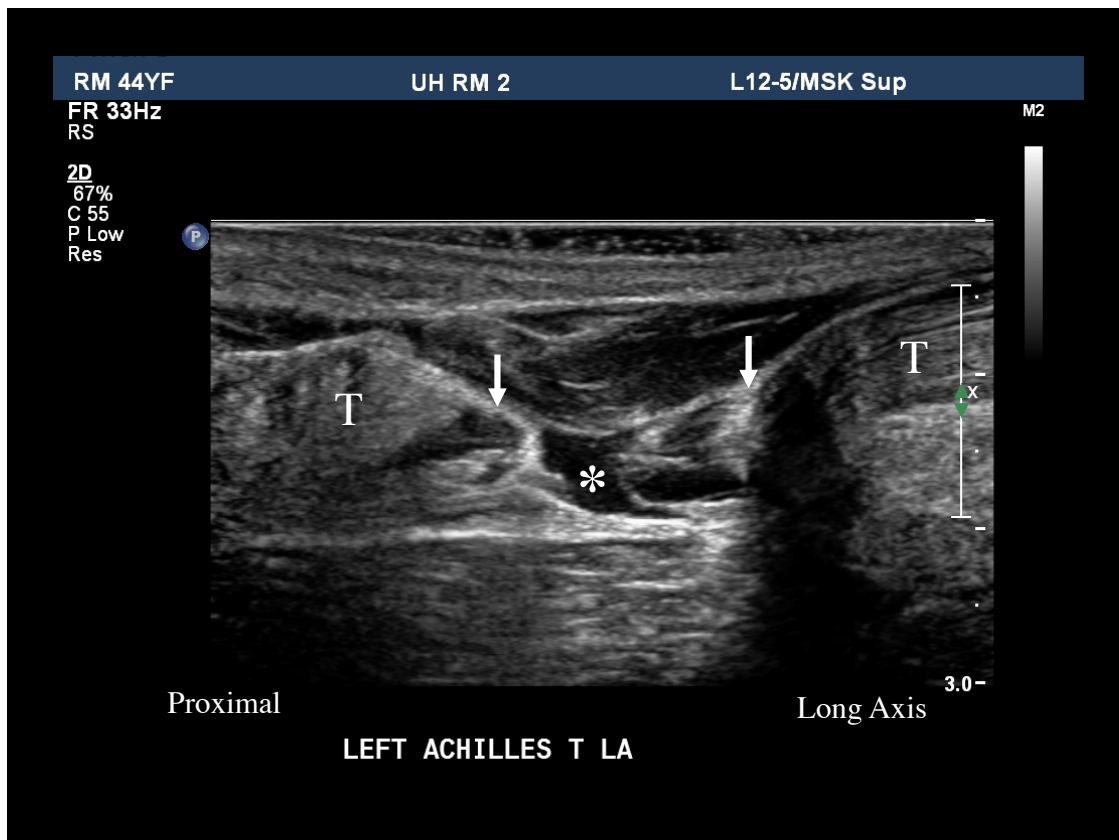


Figure 19 Baseline US of an acute Achilles tendon rupture (inflammatory phase). Long axis view at the rupture site shows discontinuity of tendon fibres (T) with a gap (arrows demarcate proximal and distal ends of the torn fibres) and a small anechoic fluid collection (*) likely related to a hematoma. The Torn tendon fibres are hypoechoic, mildly redundant and show loss of the normal fibrillar pattern

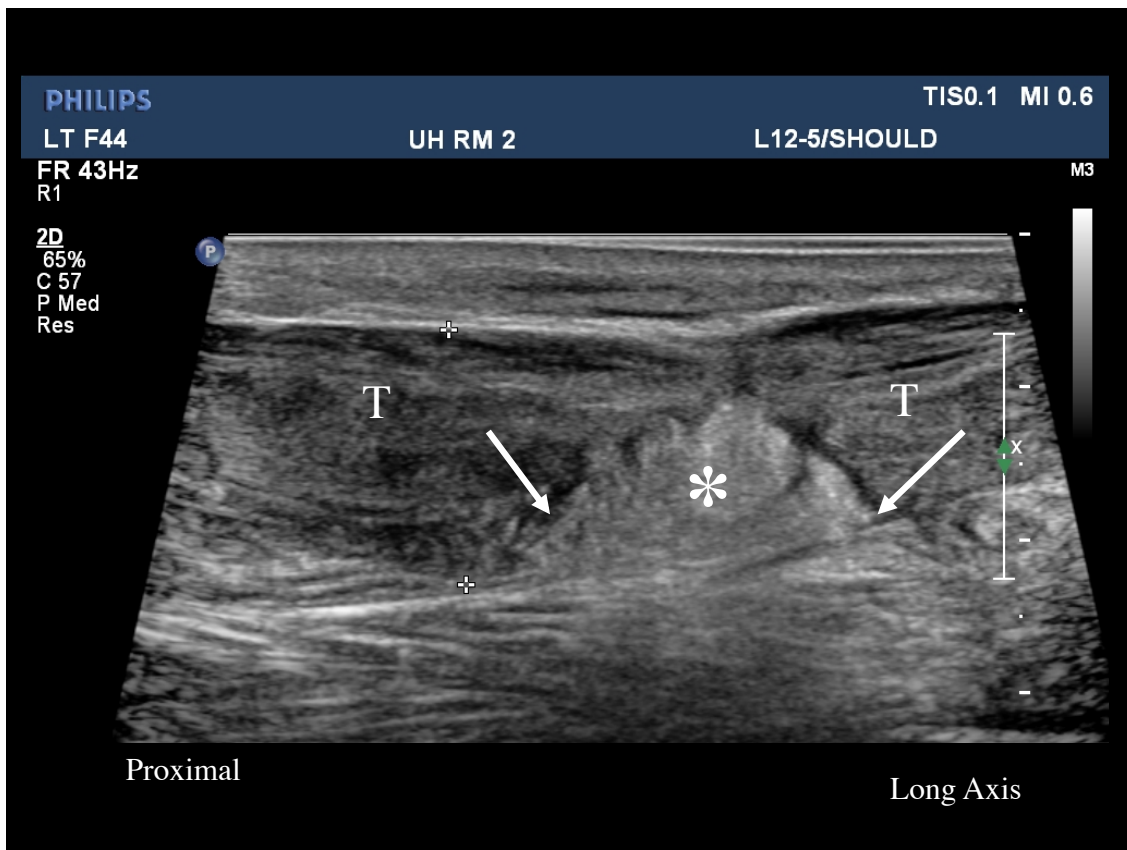


Figure 20 Ultrasound image at six weeks (proliferative phase) in the same patient as Figure 19. The previous anechoic fluid collection at the tear site has resorbed. A prominent gap is evident at the site of the tear (arrows) filled with echogenic tissue (*) which may correspond to granulation tissue. The tendon fibres adjacent to the tear are thickened, disorganized and hypoechoic, potentially corresponding to persistent edema and/or fibrous tissue

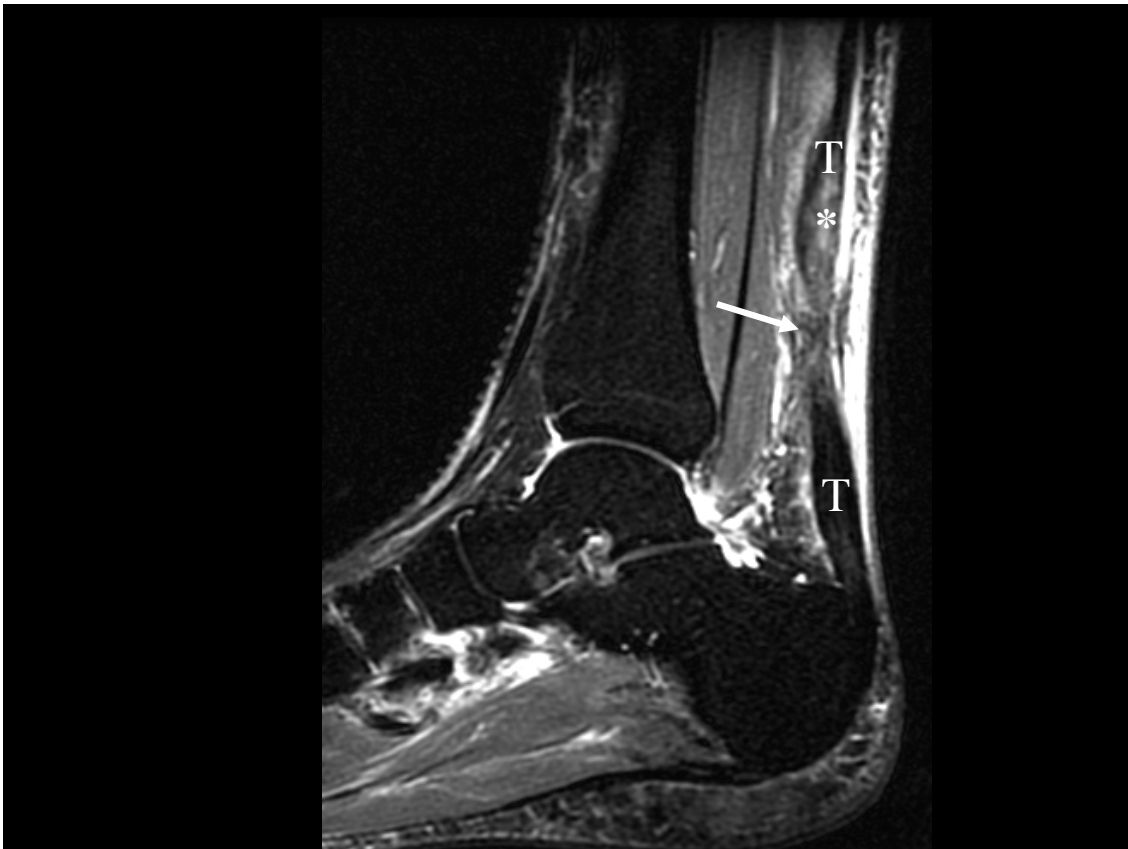


Figure 21 MR image at six weeks (same patient). Sagittal fast inversion recovery image (water weighted) shows a complete tear of the Achilles tendon with a residual gap at the site of the tear (arrow) marked by increased signal intensity. Increased fluid manifested by high signal intensity likely corresponding to extensive edema is present, most conspicuous within the proximal aspect of the tendon (*).

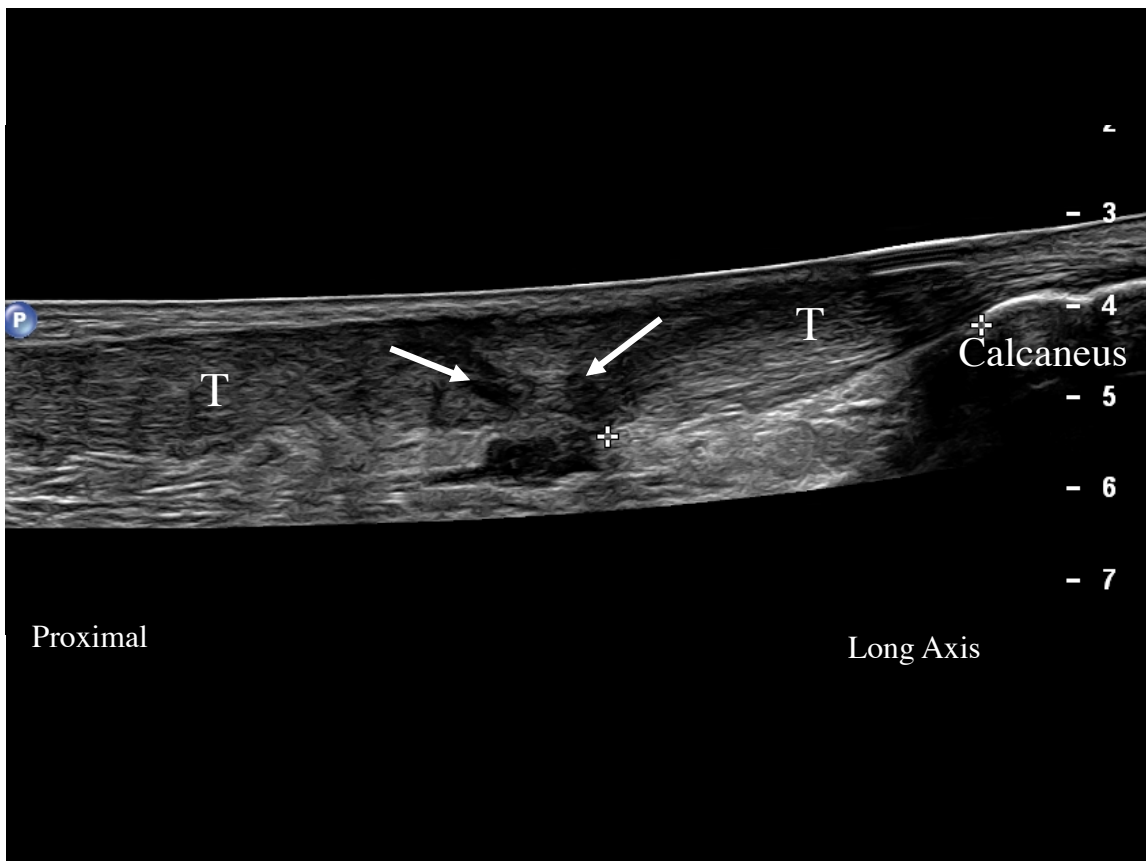

Figure 22 Ultrasound image at 24 weeks (late remodeling phase). Panorama long axis ultrasound. The Achilles tendon (T) is thickened, hypoechoic with mild redundancy, loss of the normal fibrillar pattern and disorganization of the tendon fibres, likely reflecting post-traumatic scarring due to extensive background microtearing. There is slightly increased signal at the site of previous discrete tear (arrows), without a residual gap evident.

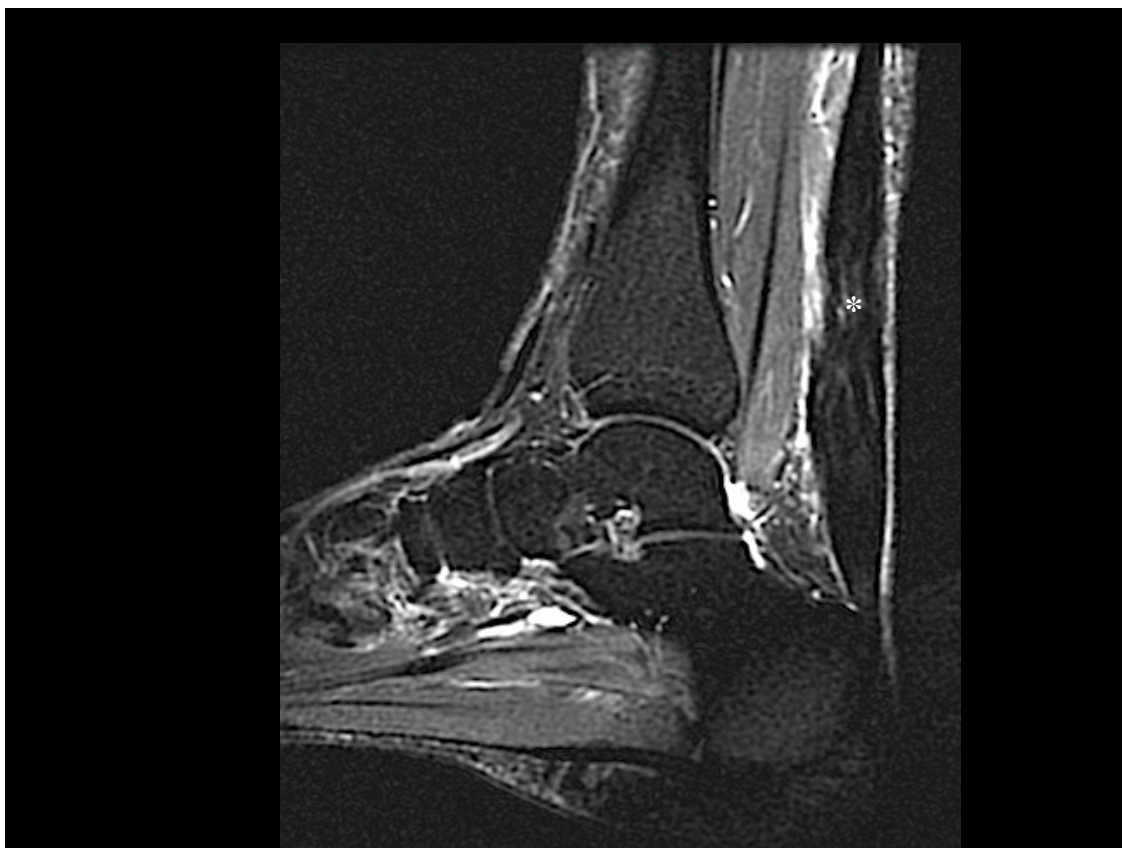


Figure 23 MR image at 24 weeks (late remodeling phase). Sagittal fast inversion recovery (water weighted). The previous gap is even more inconspicuous filled with hypointense/dark tissue (*), likely corresponding to fibrous tissue. The tendon remains thickened and abnormal

Ruptures of the AT occurred at a mean of 5.2 cm from the calcaneal insertion. Similarly, Karjalainen et al⁸⁸ and Hollenberg et al⁶¹ reported rupture sites at a mean of 5.9 cm and 6 cm from the calcaneal insertion, respectively. In a cadaveric study, Carr et al¹⁷³ reported that there is an area of low vascularity most prominent between 2 and 4 cm from the calcaneal insertion. In our series, few patients had ruptures below this region and therefore our results are in accordance with Schmidt et al¹⁷⁴ and Karjalainen et al⁸⁸ who

stated that the area of poor vascularization and the rupture site may not necessarily be correlated.

The agreement between US and MRI in our study at coinciding time points was considered “fair” at 6 and 12 weeks ($\kappa=0.20$ and $\kappa=0.36$, respectively) and “poor” at 24 weeks ($\kappa=0.17$) according to the guidelines proposed by Altman (1999)¹⁵⁵. This agreement was considerably lower than the agreement reported by Connell et al⁹⁴ ($\kappa=0.52$) in the MR and US evaluation of hamstring tears after six weeks. The most likely explanation for poor agreement is our small sample size. Discrepant assessments of healing between MRI and US have a pronounced effect on a small sample size compared to a large sample size, especially in cases of extreme disagreement (i.e. ratings that differ by two or more ordinal categories on a four category scale). Another potential explanation is that we injected patients with either ACP® or saline, ultimately increasing the amount of fluid at the injury site. This would likely present similarly to fluid/edema on both MRI and US. Fluid is easier to distinguish from fibrous tissue on MRI than US. On US both fluid and fibrous tissue appear hypoechoic, making distinction between the two sometimes difficult. On MR however, fluid or edema appears as increased signal intensity whereas fibrous tissue would appear as low signal intensity relative to the healthy tendon. It has been shown that edema can be present in healing ATs up to six months post-rupture⁸¹, therefore a discrepancy between US and MRI as a result of distinguishing fluid from fibrous tissue could have occurred at all time points in our study.

6.1 Study Strengths

Strengths of our study include the randomization of patients to intervention and control groups, reducing the chance of selection bias. We were also able to blind the patient, clinician, radiologist and outcome assessor to group allocation, reducing expectation and

performance biases. We also only lost one patient to follow up (5%) and only two patients had missing or incomplete data (10%). To our knowledge, our study is the first RCT for PRP in the non-operative management of AT ruptures. Additionally, our study is the first to attempt to quantify healing based on US and MR imaging.

6.2 Study Limitations

Our study was limited by a small sample size that limited our power to detect a statistically significant treatment effect. Although we were aware we would be underpowered, the small sample size led to a non-parametric distribution of data which prevented us from performing parametric statistical analyses.

Our primary outcome was not a valid or reliable outcome measure, as we are the first to attempt to quantify tendon healing based on imaging. Although there are objective criteria that are evaluated within each tendon image, the overall estimation of percent-healing is subjective to the radiologist interpreting the image. Furthermore, the radiologist was not blinded to the time-point of each image post-rupture, so it is possible that there was an observational bias whereby the number of weeks post-rupture could have influenced the healing rating. However, the radiologist was blinded to group allocation so any observational biases would have been equal between groups and thus should not have had a directional influence on the results.

7 Conclusion

This study compared the healing and function in non-operatively treated AT rupture patients receiving either ACP® (n=10) or saline (n=10) injections. The findings in this study are underpowered but there is sufficient evidence to suggest moving forward with a larger RCT for early ACP® injections.

7.1 Directions for Future Research

- A. We will continue data collection for one-year functional (isokinetic strength, ROM) and patient-reported (AOFAS, ATRS, Leppilahti) outcomes for all remaining patients.
- B. Further study into the use of different classifications of PRP (i.e. different concentration of platelets, different method of platelet activation) to determine if this will yield more favorable results.
- C. Further study into whether certain features of AT imaging are predictive of, or correlated to clinical or functional outcomes

References

1. Leppilahti J, Orava S. Total Achilles tendon ruptures: A review. *Sport Med*. 1998;25(2):79-100.
2. Longo UG, Ronga M, Maffulli N. Acute ruptures of the achilles tendon. *Sport Med Arthrosc*. 2009;17(2):127-138. doi:10.1097/JSA.0b013e3181a3d767.
3. Wilkins R, Bisson LJ. Operative Versus Nonoperative Management of Acute Achilles Tendon Ruptures: A Quantitative Systematic Review of Randomized Controlled Trials. *Am J Sports Med*. 2012;40:2154-2160. doi:10.1177/0363546512453293.
4. Willits K, Amendola A, Bryant D, et al. Operative versus nonoperative treatment of acute Achilles tendon ruptures: a multicenter randomized trial using accelerated functional rehabilitation. *J Bone Joint Surg Am*. 2010;92(17):2767-2775. doi:10.2106/JBJS.I.01401.
5. Soroceanu A, Sidhwa F, Aarabi S, Kaufman A, Glazebrook M. Surgical versus nonsurgical treatment of acute Achilles tendon rupture: a meta-analysis of randomized trials. *J Bone Joint Surg Am*. 2012;94(23):2136-2143. doi:10.2106/JBJS.K.00917.
6. Willits K, Kaniki N, Bryant D. The use of platelet-rich plasma in orthopedic injuries. *Sports Med Arthrosc*. 2013;21(4):225-230. doi:10.1097/JSA.0000000000000001.

7. Delong JM, Russell RP, Mazzocca AD. Platelet-rich plasma: The PAW classification system. *Arthrosc - J Arthrosc Relat Surg*. 2012;28(7):998-1009. doi:10.1016/j.arthro.2012.04.148.
8. Kaniki N, Willits K, Mohtadi NGH, Fung V, Bryant D. A Retrospective Comparative Study With Historical Control to Determine the Effectiveness of Platelet-Rich Plasma as Part of Nonoperative Treatment of Acute Achilles Tendon Rupture. *Arthrosc J Arthrosc Relat Surg*. 2014;30(9):1139-1145. doi:10.1016/j.arthro.2014.04.086.
9. Aspenberg P, Virchenko O. Platelet concentrate injection improves Achilles tendon repair in rats. *Acta Orthop Scand*. 2004;75(1):93-99. doi:10.1080/00016470410001708190.
10. Virchenko O, Aspenberg P. How can one platelet injection after tendon injury lead to a stronger tendon after 4 weeks? Interplay between early regeneration and mechanical stimulation. *Acta Orthop*. 2006;77(5):806-812. doi:10.1080/17453670610013033.
11. Kaux JF, Drion P V., Colige A, et al. Effects of platelet-rich plasma (PRP) on the healing of Achilles tendons of rats. *Wound Repair Regen*. 2012;20:748-756. doi:10.1111/j.1524-475X.2012.00826.x.
12. Sánchez M, Anitua E, Azofra J, Andía I, Padilla S, Mujika I. Comparison of surgically repaired Achilles tendon tears using platelet-rich fibrin matrices. *Am J Sports Med*. 2007;35(2):245-251. doi:10.1177/0363546506294078.

13. Weintraub W. The Nature of Tendons and Ligaments. In: *Tendon and Ligament Healing: A New Approach to Sports and Overuse Injury*. 2nd ed. Brookline, Massachussets: Paradigm Publications; 2003:11-50.
14. Frank C, Bray R, Hart D, et al. Soft tissue healing. In: Fu F, Harner K, Vince K, eds. *Knee Surgery*. Baltimore, MD: Williams and Wilkins; 1994:189-229.
15. Woo SL, Hildebrand K, Watanabe N, Fenwick JA, Papageorgiou CD, Wang JH. Tissue engineering of ligament and tendon healing. *Clin Orthop Relat Res*. 1999;(367 Suppl):S312-S323.
16. Kannus P. Structure of the tendon connective tissue. *Scand J Med Sci Sports*. 2000;10(3):312-320. doi:10.1034/j.1600-0838.2000.010006312.x.
17. Maffulli N. Current Concepts Review - Rupture of the Achilles Tendon Current Concepts Review Rupture of the Achilles Tendon *. *J Bone Jt Surg*. 2007;81:1019-1036.
18. Pierre-Jerome C, Moncayo V, Terk MR. MRI of the Achilles tendon: a comprehensive review of the anatomy, biomechanics, and imaging of overuse tendinopathies. *Acta Radiol*. 2010;51(4):438-454. doi:10.3109/02841851003627809.
19. Standring S, Gray H. *Gray's Anatomy: The Anatomical Basis of Clinical Practice*. 40th ed. Edinburgh: Churchill Livingstone / Elsevier; 2005.
20. Doral MN, Alam M, Bozkurt M, et al. Functional anatomy of the Achilles tendon. *Knee Surg Sports Traumatol Arthrosc*. 2010;18(5):638-643. doi:10.1007/s00167-010-1083-7.

21. Moore KL, Dalley AF. *Clinically Oriented Anatomy*. 4th ed. Lippincott Williams & Wilkins; 1999.
22. Cohen J. Anatomy and biomechanical aspects of the gastrocnemius complex. *Foot Ankle Clin*. 2009;14(4):617-626.
23. Apaydin N, Bozkurt M, Loukas M, Vefali H, Tubbs R, Esmer A. Relationships of the sural nerve with the calcaneal tendon: an anatomical study with surgical and clinical implications. *Surg Radiol Anat*. 2009;31(10):775-780.
24. Maffulli N, Waterston S, Squair J, Reaper J, Douglas A. Changing incidence of Achilles tendon rupture in Scotland: a 15-year study. *Clin J Sport Med*. 1999;9:157-160.
25. Leppilahti J, Puranen J, Orava S. Incidence of Achilles tendon rupture. *Acta Orthop Scand*. 1996;67(3):277-279.
26. Suchak A, Bostick G, Reid D, Blitz S, Jomha N. The incidence of Achilles tendon ruptures in Edmonton, Canada. *Foot ankle Int*. 2005;26(11):932-936.
27. Gwynne-Jones DP, Sims M, Handcock D. Epidemiology and outcomes of acute Achilles tendon rupture with operative or nonoperative treatment using an identical functional bracing protocol. *Foot ankle Int / Am Orthop Foot Ankle Soc [and] Swiss Foot Ankle Soc*. 2011;32:337-343. doi:10.3113/FAI.2011.0337.
28. Lantto I, Heikkinen J, Flinkkilä T, Ohtonen P, Leppilahti J. Epidemiology of Achilles tendon ruptures: Increasing incidence over a 33-year period. *Scand J Med Sci Sports*. 2014:1-6. doi:10.1111/sms.12253.
29. Williams J. Achilles tendon lesions in sport. *Sport Med*. 1993;16:216-220.

30. Newnham D, Douglas J, Legge J, et al. Achilles tendon rupture: an underrated complication of corticosteroid treatment. *Thorax*. 1991;46:853-854.
31. Dickey W, Patterson V. Bilateral achilles tendon rupture simulating peripheral neuropathy: unusual complication of steroid therapy. *J R Soc Med*. 1987;80:386-387.
32. Royer R, Pierfite C, Netter P. Features of tendon disorders with fluoroquinolones. *Therapie*. 1994;49:75-76.
33. Wilson A, Goodship A. Exercise-induced hyperthermia as a possible mechanism for tendon degeneration. *J Biomech*. 1994;27:899-905.
34. Dent C, Graham G. Osteogenesis imperfecta and Achilles tendon rupture. *Injury*. 1991;22:239-240.
35. Dodds W, Burry H. The relationship between Achilles tendon rupture and serum uric acid level. *Injury*. 1984;16:94-95.
36. Arner O, Lindholm A, Orell S. Histologic changes in subcutaneous rupture of the Achilles tendon. A study of 74 cases. *Acta Chir Scand*. 1959;116:484-490.
37. Davidsson L, Salo M. Pathogenesis of subcutaneous tendon ruptures. *Acta Chir Scand*. 1969;135:209-212.
38. Kannus P, Jozsa L. Histopathological changes preceding spontaneous rupture of a tendon. A controlled study of 891 patients. *J Bone Jt Surg*. 1991;73:1507-1525.
39. Jozsa L, Lehto M, Kannus P. Fibronectin and laminin in Achilles tendon. *Acta Orthop Scand*. 1989;60:469-471.

40. Lehto M, Jozsa L, Kvist M, et al. Fibronectin in the ruptured human Achilles tendon and its paratenon. An immunoperoxidase study. *Ann Chir Gynaecol.* 1990;79:72-77.
41. McMaster P. Tendon and muscle ruptures. Clinical and experimental studies on the causes and location of subcutaneous ruptures. *J Bone Jt Surg.* 1933;15:705-722.
42. Barfred T. Experimental rupture of the achilles tendon. Comparison of various types of experimental rupture in rats. *Acta Orthop Scand.* 1971;42:528-543.
43. Clain M, Baxter D. Achilles tendinitis. *Foot ankle Int.* 1992;13:482-487.
44. Clement D, Taunton J, Smart G. Achilles tendinitis and peritendinitis: etiology and treatment. *Am J Sports Med.* 1984;12:179-184.
45. Knorz E, Folkhard W, Geercken W, Al E. New aspects of the etiology of tendon rupture. An analysis of time-resolved dynamic-mechanical measurements using synchrotron radiation. *Arch Orthop Trauma Surg.* 1986;105:113-120.
46. Inglis A, Sculco T. Surgical repair of ruptures of the tendo Achilles. *Clin Orthop.* 1981;156:160-169.
47. Arner O, Lindholm A. Subcutaneous rupture of the Achilles tendon. *Acta Chir Scand.* 1959;239:7-51.
48. Wapner K. Achilles tendon rupture and subsequent repair. *Orthop.* 2011;34(7):530-531.

49. Maffulli N. The clinical diagnosis of subcutaneous tear of the Achilles tendon. *Am J Sports Med.* 1998;26(2):266-270.
50. Scott B, Chalabi A. How the Simmonds-Thompson test works. *J Bone Jt Surg.* 1992;74B(2):314-315.
51. Simmonds F. The diagnosis of the ruptured Achilles tendon. *Practitioner.* 1957;179:56-58.
52. Matles A. Rupture of the tendo Achilles: Another diagnostic sign. *Bull Hosp Jt Dis.* 1975;36:48-51.
53. Reinhetz R, Zawada S, Sheldon D. Recognizing unusual tendon pathology at the ankle. *J Foot Ankle Surg.* 1986;25:278-283.
54. Scheller A, Kasser J, Quigley T. Tendon injuries about the ankle. *Orthop Clin North Am.* 1980;11:801-811.
55. Saltzman C, Tearse D. Achilles tendon injuries. *J Am Academy Orthop Surg.* 1998;6:316-325.
56. Hartgerink P, Fessell DP, Jacobson JA, van Holsbeeck MT. Full- versus partial-thickness Achilles tendon tears: sonographic accuracy and characterization in 26 cases with surgical correlation. *Radiology.* 2001;220(2):406-412.
doi:10.1148/radiology.220.2.r01au41406.
57. Venables H. How does ultrasound work ? *Ultrasound.* 2011;19:44-49.

58. Bleakney RR, Tallon C, Wong JK, Lim KP, Maffulli N, Orth F. Long-term Ultrasonographic Features of the Achilles Tendon After Rupture. 2002;273-278. doi:10.1097/01.JSM.0000028923.29383.D4.
59. Astrom N, Gentz C, Nilsson P, Rausing A, Sjoberg S, Westlin N. Imaging in chronic Achilles tendinopathy: a comparison of ultrasonography, magnetic resonance imaging, and surgical findings. *Skeletal Radiol.* 1996;25:615-620.
60. Paavola M, Paakkala T, Kannus P, Jarvinen M. Ultrasonography in the differential diagnosis of Achilles tendon injuries and related disorders. A comparison between pre-operative ultrasonography and surgical findings. *Acta radiol.* 1998;39:612-619.
61. Hollenberg GM, Adams MJ, Weinberg EP. Sonographic appearance of nonoperatively treated Achilles tendon ruptures. *Skeletal Radiol.* 2000;29(5):259-264. doi:10.1007/s002560050604.
62. Maffulli N, Dymond N, Regine R. Surgical repair of ruptured Achilles tendon in sportsmen and sedentary patients: a longitudinal ultrasound assessment. *Int J Sports Med.* 1990;11:78-84.
63. Maffulli N, Thorpe a. P, Smith FW. Magnetic resonance imaging after operative repair of Achilles tendon rupture. *Scand J Med Sci Sports.* 2001;11(3):156-162. doi:10.1046/j.1524-4725.2001.110305_1.x.
64. Crass J, Van de Vegte G, Harkavy L. Tendon echogenicity: ex vivo study. *Radiology.* 1988;167(2):499-501.

65. Bleakney R, White L. Imaging of the Achilles tendon. *Foot Ankle Clin North Am.* 2005;10:239-254.
66. Barbolini G, Monetti G, Montosori G, Grandi M. Results with high definition sonography in the evaluation of Achilles tendon conditions. *Ital J Sport Traumatol.* 1988;10:225-334.
67. Bailey A, Lapiere C. Effect of an additional peptide extension of the N-terminus of collagen from dermosparactic calves on the cross-linking of collagen fibres. *Eur J Biomech.* 1973;34:91-96.
68. Maffulli N, Dymond N, Capasso G. Ultrasonographic findings in subcutaneous rupture of Achilles tendon. *J Sports Med Phys Fitness.* 1989;29:365-368.
69. Jacobson JA. Musculoskeletal sonography and MR imaging. *Radiol Clin North Am.* 1999;37(4):713-735. doi:10.1016/S0033-8389(05)70125-1.
70. Lento P, Primack S. Advances and utility of diagnostic ultrasound in musculoskeletal medicine. *Curr Rev Musculoskelet Med.* 2008;1:24-31.
71. Collins M, Ehman R. Interpretation of Magnetic Resonance Images. In: Berquist T, ed. *MRI of the Musculoskeletal System.* 6th ed. Lippincott Williams & Wilkins; 2013:34-62.
72. Helms C, Major N, Anderson M, Kaplan P, Dussault R. Basic Principles of Musculoskeletal MRI. In: Gaertner R, Milnes J, eds. *Musculoskeletal MRI.* 2nd ed. Philadelphia: Saunders Elsevier; 2009:1-19.

73. Heinemeier KM, Schjerling P, Heinemeier J, Magnusson SP, Kjaer M. Lack of tissue renewal in human adult Achilles tendon is revealed by nuclear bomb 14C. *FASEB J*. 2013;27(5):2074-2079. doi:10.1096/fj.12-225599.
74. Wang JHC. Mechanobiology of tendon. *J Biomech*. 2006;39(9):1563-1582. doi:10.1016/j.jbiomech.2005.05.011.
75. Barfod KW. Achilles tendon rupture; Assessment of non- operative treatment. 2014.
76. Sharma P, Maffulli N. Basic biology of tendon injury and healing. *Surgeon*. 2005;3(5):309-316. doi:10.1016/S1479-666X(05)80109-X.
77. Aspenberg P. Stimulation of tendon repair: Mechanical loading, GDFs and platelets. a mini-review. *Int Orthop*. 2007;31(6):783-789. doi:10.1007/s00264-007-0398-6.
78. Olsson N, Karlsson J, Eriksson B, Brorson A, Lundberg M, Silbernagel K. Ability to perform a single heel-rise is significantly related to patient-reported outcome after Achilles tendon rupture. *Scand J Med Sci Sports*. 2014;24:152-158.
79. Slavotinek J. Monitoring of Muscle, Tendon and Ligament Repair. In: *Imaging of Orthopedic Sports Injuries*. Springer Berlin Heidelberg; 2007:489-502. doi:10.1007/978-3-540-68201-1_29.
80. Del Buono A, Chan O, Maffulli N. Achilles tendon: Functional anatomy and novel emerging models of imaging classification. *Int Orthop*. 2013;37(4):715-721. doi:10.1007/s00264-012-1743-y.

81. Möller M, Kålebo P, Tidebrant G, Movin T, Karlsson J. The ultrasonographic appearance of the ruptured Achilles tendon during healing: A longitudinal evaluation of surgical and nonsurgical treatment, with comparisons to MRI appearance. *Knee Surgery, Sport Traumatol Arthrosc.* 2002;10(1):49-56. doi:10.1007/s001670100245.
82. Van Schie HTM, de Vos RJ, de Jonge S, et al. Ultrasonographic tissue characterisation of human Achilles tendons: quantification of tendon structure through a novel non-invasive approach. *Br J Sports Med.* 2010;44(16):1153-1159. doi:10.1136/bjism.2009.061010.
83. Khan KM, Forster BB, Robinson J, et al. Are ultrasound and magnetic resonance imaging of value in assessment of Achilles tendon disorders? A two year prospective study. *Br J Sports Med.* 2003;37(2):149-153. doi:10.1136/bjism.37.2.149.
84. Rupp S, Tempelhof S, Fritsch E. Ultrasound of the Achilles tendon after surgical repair: morphology and function. *Br J Radiol.* 1995;68:454-458.
85. Helms C, Major N, Anderson M, Kaplan P, Dussault R. Tendons and Muscles. In: Gaertner R, Milnes J, eds. *Musculoskeletal MRI.* 2nd ed. Philadelphia: Saunders Elsevier; 2009:50-79.
86. Hodgson R, O'Connor PJ, Grainger a. J. Tendon and ligament imaging. *Br J Radiol.* 2012;85(1016):1157-1172. doi:10.1259/bjr/34786470.
87. Berquist T. Foot, Ankle, and Calf. In: Berquist B, ed. *MRI of the Musculoskeletal System.* 6th ed. Lippincott Williams & Wilkins; 2013:460-596.

88. Karjalainen PT, Aronen HJ, Pihlajamäki HK, Soila K, Paavonen T, Böstman OM. Magnetic resonance imaging during healing of surgically repaired Achilles tendon ruptures. *Am J Sports Med.* 25(2):164-171. doi:10.1177/036354659702500204.
89. Fujikawa A, Kyoto Y, Kawaguchi M, Naoi Y, Ukegawa Y. Achilles tendon after percutaneous surgical repair: serial MRI observation of uncomplicated healing. *AJR Am J Roentgenol.* 2007;189(5):1169-1174. doi:10.2214/AJR.07.2260.
90. Chang a., Miller TT. Imaging of Tendons. *Sport Heal A Multidiscip Approach.* 2009;1(4):293-300. doi:10.1177/1941738109338361.
91. Gerling M, Pfirrmann C, Farrookis S, Al E. Posterior tibialis tendon tears comparison of the diagnostic efficacy of magnetic resonance imaging and ultrasonography for the detection of surgically created longitudinal tears in cadavers. *Invest Radiol.* 2003;28:51-56.
92. Grant T, Kelikian A, Jereb S, Al E. Ultrasound diagnosis of peroneal tendon tears: a surgical correlation. *J Bone Jt Surg.* 2005;87:1788-1794.
93. Teefey S, Rubin D, Middleton W, Hildebolt C, Leibold R, Yamaguchi K. Detection and quantification of rotator cuff tears: comparison of ultrasonographic, magnetic resonance imaging, and arthroscopic findings in seventy one consecutive cases. *J Bone Jt Surg.* 2004;86:708-716.
94. Connell DA, Schneider-Kolsky ME, Hoving JL, et al. Longitudinal study comparing sonographic and MRI assessments of acute and healing hamstring injuries. *AJR Am J Roentgenol.* 2004;183(4):975-984. doi:10.2214/ajr.183.4.1830975.

95. De Jesus JO, Parker L, Frangos AJ, Nazarian LN. Accuracy of MRI, MR arthrography, and ultrasound in the diagnosis of rotator cuff tears: A meta-analysis. *Am J Roentgenol*. 2009;192(6):1701-1707. doi:10.2214/AJR.08.1241.
96. Jiang N, Wang B, Chen A, Dong F, Yu B. Operative versus nonoperative treatment for acute Achilles tendon rupture: A meta-analysis based on current evidence. *Int Orthop*. 2012;36:765-773. doi:10.1007/s00264-011-1431-3.
97. Khan R, Fick D, Keogh A, Crawford J, et al. Treatment of Acute Achilles Tendon Ruptures: A meta-analysis of randomized controlled trials. *J Bone Jt Surg*. 2005;87(10):2202-2210.
98. Twaddle BC, Poon P. Early motion for Achilles tendon ruptures: is surgery important? A randomized, prospective study. *Am J Sports Med*. 2007;35:2033-2038. doi:10.1177/0363546507307503.
99. Cetti R, Henriksen LO, Jacobsen KS. A new treatment of ruptured Achilles tendons. A prospective randomized study. *Clin Orthop Relat Res*. 1994:155-165.
100. Mortensen HM, Skov O, Jensen PE. Early motion of the ankle after operative treatment of a rupture of the Achilles tendon. A prospective, randomized clinical and radiographic study. *J Bone Joint Surg Am*. 1999;81:983-990.
101. Kangas J, Pajala A, Siira P, Hämäläinen M, Leppilähti J. Early functional treatment versus early immobilization in tension of the musculotendinous unit after Achilles rupture repair: a prospective, randomized, clinical study. *J Trauma*. 2003;54(6):1171-1180; discussion 1180-1181. doi:10.1097/01.TA.0000047945.20863.A2.

102. Suchak A, Bostick G, Beaupre L, Durand D, Jomha N. The influence of early weight-bearing compared with non-weight-bearing after surgical repair of the Achilles tendon. *J Bone Jt Surg.* 2008;90(9):1876-1883.
103. Barfod K, Bencke J, Lauridsen H, Ban I, Ebskov L, Troelsen A. Nonoperative Dynamic Treatment of Acute Achilles. *J Bone Jt Surg.* 2014;96:1497-1503.
104. The diagnosis and treatment of acute Achilles tendon rupture: guideline and evidence report. *Am Acad Orthop Surg.* 2009.
105. Khan-Farooqi W, Anderson RB. Achilles tendon evaluation and repair. *J Musculoskelet Med.* 2006;23(5):347-347 - 9, 352, 353-354 passim.
<http://search.ebscohost.com/login.aspx?direct=true&db=cin20&AN=2009209053&site=ehost-live>.
106. Barrie K, Wolfe S, Shean C, et al. A biomechanical comparison of multistrand flexor tendon repairs using an in situ testing model. *J Hand Surg Am.* 2000;25A:499-506.
107. Maes R, Copin G, Averous C. Is percutaneous repair of the Achilles tendon a safe technique? A study of 124 cases. *Acta Orthop Belg.* 2006;72(2):179-183.
108. Haji A, Sahai A, Symes A, Vyas J. Percutaneous versus open tendo achilles repair. *Foot ankle Int.* 2004;25(4):215-218.
109. Tan G, Sabb B, Kadakia A. Non-surgical management of achilles ruptures. *Foot Ankle Clin.* 2009;14(4):675-684.

110. Young SW, Patel A, Zhu M, et al. Weight-Bearing in the Nonoperative Treatment of Acute Achilles Tendon Ruptures: A Randomized Controlled Trial. *J Bone Joint Surg Am.* 2014;96:1073-1079. doi:10.2106/JBJS.M.00248.
111. Bhandari M, Guyatt GH, Siddiqui F, et al. Treatment of acute Achilles tendon ruptures: a systematic overview and metaanalysis. *Clin Orthop Relat Res.* 2002;(400):190-200.
112. Mattila VM, Huttunen TT, Haapasalo H, Sillanpaa P, Malmivaara a, Pihlajamaki H. Declining incidence of surgery for Achilles tendon rupture follows publication of major RCTs: evidence-influenced change evident using the Finnish registry study. *Br J Sport Med.* 2013. doi:10.1136/bjsports-2013-092756.
113. Schils SJ, Turner T a. Review of Early Mobilization of Muscle, Tendon, and Ligament After Injury in Equine Rehabilitation. *Proc Am Assoc Equine Pract.* 2010;56:374-380.
114. Jung H, Fisher M, Woo S-Y. Role of biomechanics in the understanding of normal, injured, and healing ligaments and tendons. *Sport Med Arthrosc Rehabil Ther Technol.* 2009;1:1758-2555.
115. Thoren P, Floras J, Hoffmann P, et al. Endorphins and exercise. Physiological mechanisms and clinical implications. *Med Sci Sport Exerc.* 1990;4:417-428.
116. Jarvinen M, Lehto M. The effects of early mobilization and immobilization on the healing process following muscle injuries. *Sport Med.* 1993;15(78-89).
117. Esser K, White T. Mechanical load affects growth and maturation of skeletal muscle grafts. *J Appl Physiol.* 1995;78:30-37.

118. Bigard A, Serrurier B, Merinao D, et al. Myosin heavy chain composition of regenerated soleus muscle during hindlimb suspension. *Acta Physiol Scand*. 1997;161:23-30.
119. Kannus P, Josza L, Natri A, et al. Effects of training, immobilization and remobilization on tendons. *Scand J Med Sci Sports*. 1997;7:67-71.
120. Sherry M, Best T. A comparison of two rehabilitation programs in the treatment of acute hamstring strains. *J Orthop Sport Phys Ther*. 2002;4:116-125.
121. Clanton T, Coupe K. Hamstring strains in athletes: diagnosis and treatment. *J Am Academy Orthop Surg*. 1998;6:237-248.
122. Sharma P, Maffulli N. Tendon injury and tendinopathy: healing and repair. *J Bone Joint Surg Am*. 2005;87(1):187-202. doi:10.2106/JBJS.D.01850.
123. Oakes B. Repair of tendons and ligaments. In: Frontera W, ed. *Rehabilitation of Sports Injuries: Scientific Basis*. Malden, MA: Blackwell Science; 2003:274-287.
124. Iturri J. Proprioception and coordination in rehabilitation of sports injuries. In: Frontera W, ed. *Rehabilitation of Sports Injuries: Scientific Basis*. Malden, MA: Blackwell Science; 2003:274-287.
125. Bloomfield S. Changes in musculoskeletal structure and function with prolonged bed rest. *Med Sci Sport Exerc*. 1997;29(197-206).
126. Cruz-Martinez A, Ramirez A, Arpa J. Quadriceps atrophy after knee traumatism and immobilization: electrophysiological assessment. *Eur Neurol*. 2000;43:110-114.

127. Kannus P. Immobilization or early mobilization after an acute soft-tissue injury? *Phys Sportsmed.* 2000;28(3):55-63. doi:10.3810/psm.2000.03.775.
128. Saleh M, Marshall PD, Senior R, MacFarlane a. The Sheffield splint for controlled early mobilisation after rupture of the calcaneal tendon. A prospective, randomised comparison with plaster treatment. *J Bone Joint Surg Br.* 1992;74:206-209.
129. Costa ML, MacMillan K, Halliday D, et al. Randomised controlled trials of immediate weight-bearing mobilisation for rupture of the tendo Achillis. *J Bone Joint Surg Br.* 2006;88(1):69-77. doi:10.1302/0301-620X.88B1.16549.
130. Sheth U, Simunovic N, Klein G, et al. Efficacy of Autologous Platelet-Rich Plasma Use for Orthopaedic Indications: A Meta-Analysis. *J Bone Jt Surg.* 2012;94:298. doi:10.2106/JBJS.K.00154.
131. Alsousou J, Thompson M, Hulley P, Noble a, Willett K. The biology of platelet-rich plasma and its application in trauma and orthopaedic surgery: a review of the literature. *J Bone Joint Surg Br.* 2009;91(8):987-996. doi:10.1302/0301-620X.91B8.22546.
132. Blair P, Flaumenhaft R. Platelet alpha-granules: Basic biology and clinical correlates. *Blood Rev.* 2009;23(4):177-189. doi:10.1016/j.blre.2009.04.001.
133. Anitua E, Andia I, Ardanza B, Nurden P, Nurden AT. Autologous platelets as a source of proteins for healing and tissue regeneration. *Thromb Haemost.* 2004;91:4-15. doi:10.1160/TH03-07-0440.

134. Ahmad Z, Howard D, Brooks R a., et al. The role of platelet rich plasma in musculoskeletal science. *JRSM Short Rep.* 2012;3:40-40.
doi:10.1258/shorts.2011.011148.
135. Sanchez A, Sheridan P, Kupp L. Is platelet-rich plasma the perfect enhancement factor? a current review. *Int J Oral Maxillofac Implants.* 2003;18:93-103.
136. Einhorn T. The science of fracture healing. *J Orthop Trauma.* 2005;19:4-6.
137. Marx RE. Platelet-Rich Plasma: Evidence to Support Its Use. *J Oral Maxillofac Surg.* 2004;62:489-496. doi:10.1016/j.joms.2003.12.003.
138. Choi B, Zhu S, Kim B. Effect of platelet rich plasma (PRP) concentration on the viability and proliferation of alveolar bone cells: an in vitro study. *Int J Oral Maxillofac Surg.* 2005;34:420-424.
139. Weibrich G, Hanson T, Kleis W, Buch R, Hitzler W. Effect of platelet concentration in platelet-rich plasma on peri-implant bone regeneration. *Bone.* 2004;34(665-671).
140. Schoendorfer D, Williamson L, Sheckler V, Fitzgerald B. Platelet collection with the autophoresis-C apheresis system. *Vix Sang.* 1990;58:100-105.
141. Mazzocca AD, McCarthy M, Chowanec D. Platelet-rich plasma differs according to preparation method and human variability. *J Bone Jt Surg.* 2012;94:308-316.
142. Marx RE, Carlson ER, Eichstaedt RM, Schimmele SR, Strauss JE, Georgeff KR. Platelet-rich plasma: Growth factor enhancement for bone grafts. *Oral Surgery, Oral Med Oral Pathol Oral Radiol Endodontology.* 1998;85(6):638-646.
doi:10.1016/S1079-2104(98)90029-4.

143. Marx R. Platelet-rich plasma (PRP): What is PRP and what is not PRP? *Implant Dent.* 2001;10(4):225-228.
144. Harrison S, Vavken P, Kevy S, Jacobsen M, Zurakowski D, Murray M. Platelet activation by collagen provides sustained release of anabolic cytokines. *Am J Sports Med.* 2011;39:729-734.
145. Lyras DN, Kazakos K, Verettas D, et al. The influence of platelet-rich plasma on angiogenesis during the early phase of tendon healing. *Foot ankle Int / Am Orthop Foot Ankle Soc [and] Swiss Foot Ankle Soc.* 2009;30:1101-1106. doi:10.3113/FAI.2009.1101.
146. Lyras DN, Kazakos K, Tryfonidis M, et al. Temporal and spatial expression of TGF- β 1 in an Achilles tendon section model after application of platelet-rich plasma. *Foot Ankle Surg.* 2010;16(3):137-141. doi:10.1016/j.fas.2009.09.002.
147. Schepull T, Kvist J, Norrman H, Trinks M, Berlin G, Aspenberg P. Autologous platelets have no effect on the healing of human achilles tendon ruptures: a randomized single-blind study. *Am J Sports Med.* 2011;39:38-47. doi:10.1177/0363546510383515.
148. De Carli A, Lanzetti RM, Ciompi A, et al. Can platelet-rich plasma have a role in Achilles tendon surgical repair? *Knee Surgery, Sport Traumatol Arthrosc.* 2015. doi:10.1007/s00167-015-3580-1.
149. Elveru R a, Rothstein JM, Lamb RL. Goniometric reliability in a clinical setting. Subtalar and ankle joint measurements. *Phys Ther.* 1988;68(5):672-677.

150. Goldstein CL, Schemitsch E, Bhandari M, Mathew G, Petrisor B a. Comparison of different outcome instruments following foot and ankle trauma. *Foot ankle Int.* 2010;31(12):1075-1080. doi:10.3113/FAI.2010.1075.
151. Ibrahim T, Beiri A, Azzabi M, Best AJ, Taylor GJ, Menon DK. Reliability and validity of the subjective component of the American Orthopaedic Foot and Ankle Society clinical rating scales. *J Foot Ankle Surg.* 2007;46(2):65-74. doi:10.1053/j.jfas.2006.12.002.
152. Soohoo NF, Vyas R, Samini D. *Foot & Ankle International.* 2006. doi:10.1177/107110070602701111.
153. Nilsson-Helander K, Thomeé R, Silbernagel KG, et al. The Achilles tendon Total Rupture Score (ATRS): development and validation. *Am J Sports Med.* 2007;35(3):421-426. doi:10.1177/0363546506294856.
154. Carmont MR, Silbernagel KG, Nilsson-Helander K, Mei-Dan O, Karlsson J, Maffulli N. Cross cultural adaptation of the Achilles tendon Total Rupture Score with reliability, validity and responsiveness evaluation. *Knee Surg Sports Traumatol Arthrosc.* 2013;21(6):1356-1360. doi:10.1007/s00167-012-2146-8.
155. Altman D. *Practical Statistics for Medical Research.* 1st ed. London: Chapman & Hall; 1999.
156. Landis J, Koch G. The measurement of observer agreement for categorical data. *Biometrics.* 1977;44:159-174.
157. Haynesworth S, Kadiyala S, Liang L, et al. Mitogenic stimulation of human mesenchymal stem cells by platelet release suggest a mechanism for enhancement

- of bone repair by platelet concentrates. In: *48th Meeting of the Orthopedic Research Society*. Boston, MA; 2002.
158. Gruber R, Varga F, Fischer M, Watzek G. Platelets stimulate proliferation of bone cells: Involvement of platelet-derived growth factor, microparticles, and membranes. *Clin Oral Implants Res*. 2002;13:529-535.
 159. Sánchez M, Anitua E, Azofra J, Aguirre JJ, Andia I. Intra-articular injection of an autologous preparation rich in growth factors for the treatment of knee OA: A retrospective cohort study. *Clin Exp Rheumatol*. 2008;26(5):910-913.
<http://www.scopus.com/inward/record.url?eid=2-s2.0-57249116213&partnerID=tZOtx3y1>.
 160. Anitua E, Aguirre JJ, Algorta J, et al. Effectiveness of autologous preparation rich in growth factors for the treatment of chronic cutaneous ulcers. *J Biomed Mater Res Part B Appl Biomater*. 2008;84B(2):415-421. doi:10.1002/jbm.b.30886.
 161. Anitua E, Andia I, Sanchez M, et al. Autologous preparations rich in growth factors promote proliferation and induce VEGF and HGF production by human tendon cells in culture. *J Orthop Res*. 2005;23:281-286.
 162. Anitua E, Orive G, Pla R, Roman P, Serrano V, Andia I. The effects of PRGF on bone regeneration and on titanium implant osseointegration in goats: A histologic and histomorphometric study. *J Biomed Mater Res A*. 2009;91:158-165.
 163. Sanchez M, Anitua E, Azofra J, Prado R, Muruzabal F, Andia I. Ligamentization of tendon grafts treated with an endogenous preparation rich in growth factors: Gross morphology and histology. *Arthrosc - J Arthrosc Relat Surg*. 2010;26:470-480.

164. Sanchez M, Anitua E, Cugat R, et al. Nonunions treated with autologous preparation rich in growth factors. *J Orthop Trauma*. 2009;23:52-59.
165. Sanchez M, Azofra J, Anitua E, et al. Plasma rich in growth factors to treat an articular cartilage avulsion: A case report. *Med Sci Sport Exerc*. 2003;35:1648-1652.
166. Brickson S, Ji LL, Schell K, Olabisi R, St Pierre Schneider B, Best TM. M1/70 attenuates blood-borne neutrophil oxidants, activation, and myofiber damage following stretch injury. *J Appl Physiol*. 2003;95:969-976. doi:10.1152/jappphysiol.00005.2003.
167. Crinnion JN, Homer-Vanniasinkam S, Parkin SM, Gough MJ. Role of neutrophil-endothelial adhesion in skeletal muscle reperfusion injury. *Br J Surg*. 1996;83:251-254. doi:10.1002/bjs.1800830234.
168. Dovi J V, He L, Dipietro L a. Accelerated wound closure in neutrophil-depleted mice Abstract : The infiltration of neutrophils into injured tissue is known to protect wounds from in- repair process . To investigate the role of neutro-. *J Leukoc Biol*. 2003;73:448-455. doi:10.1189/jlb.0802406.http.
169. Groggaard B, Gerdin B, Reikerfis O. The polymorphonuclear leukocyte : has it a role in fracture healing ? *Arch Orthop Trauma Surg*. 1990;109:268-271.
170. Martin P, Leibovich SJ. Inflammatory cells during wound repair: The good, the bad and the ugly. *Trends Cell Biol*. 2005;15(11):599-607. doi:10.1016/j.tcb.2005.09.002.

171. Schneider B, Tildus P. Neutrophil infiltration in exercise-injured skeletal muscle: How do we resolve the controversy? *Sport Med.* 2007;37:837-856.
172. Toumi H, Best T. The inflammatory response: Friend or enemy for muscle injury? *Br J Sports Med.* 2003;37:284-286.
173. Carr a J, Norris SH. The blood supply of the calcaneal tendon. *J Bone Joint Surg Br.* 1989;71(1):100-101.
174. Schmidt-Rohlfing B, Graf J, Schneider U, Niethard FU. The blood supply of the Achilles tendon. *Int Orthop.* 1992;16(1):29-31.

Appendices

Appendix A: Research Ethics Board Approval



**Western
Research**

Use of Human Participants - Ethics Approval Notice

Research Ethics

*Re-issue
April 19/13
-S.W.-*

Principal Investigator: Dr. Kevin Willits
 File Number: 103375
 Review Level: Full Board
 Approved Local Adult Participants: 20
 Approved Local Minor Participants: 0
 Protocol Title: A randomized clinical trial to compare the effect of non-operative treatment with or without Autologous Conditioned Plasma (ACP) on healing and function in patients with Achilles tendon ruptures.
 Department & Institution: Schulich School of Medicine and Dentistry/Surgery, Western University
 Sponsor:
 Ethics Approval Date: April 11, 2013
 Ethics Expiry Date: April 30, 2014

Documents Reviewed & Approved & Documents Received for Information:

| Document Name | Comments | Version Date |
|---------------------------------|--|--------------|
| Letter of Information & Consent | | 2013/02/11 |
| Western University Protocol | (including study instruments & questionnaires) | |
| Approval Notice | | |

This is to notify you that the University of Western Ontario Health Sciences Research Ethics Board (HSREB) which is organized and operates according to the Tri-Council Policy Statement: Ethical Conduct of Research Involving Humans and the Health Canada/ICH Good Clinical Practice Practices: Consolidated Guidelines; and the applicable laws and regulations of Ontario has reviewed and granted approval to the above referenced study on the approval date noted above. The membership of this HSREB also complies with the membership requirements for REB's as defined in Division 5 of the Food and Drug Regulations.

The ethics approval for this study shall remain valid until the expiry date noted above assuming timely and acceptable responses to the HSREB's periodic requests for surveillance and monitoring information. If you require an updated approval notice prior to that time you must request it using the University of Western Ontario Updated Approval Request form.

Member of the HSREB that are named as investigators in research studies, or declare a conflict of interest, do not participate in discussions related to, nor vote on, such studies when they are presented to the HSREB.

The Chair of the HSREB is Dr. Joseph Gilbert. The HSREB is registered with the U.S. Department of Health & Human Services under the IRB registration number IRB 00000940.

Signature

Ethics Officer to Contact for Further Information

| | | |
|-------------------------------------|-------------------------------------|------------------------------------|
| Janece Sutherland (jsuth@uwo.ca) | Grace Kelly (grace.kelly@uwo.ca) | Shantel Watcom (shantel@uwo.ca) |
|-------------------------------------|-------------------------------------|------------------------------------|

This is an official document. Please retain the original in your files.

Appendix B Letter of Information and Consent



A randomized clinical trial to compare the effect of non-operative treatment with or without Autologous Conditioned Plasma (ACP) on healing and function in patients with Achilles tendon rupture

Principal Investigator:

Dr. Kevin Willits, MD, FRCSC,
Fowler Kennedy Sport Medicine Clinic,

Sponsor:

Arthrex, Inc.

Ethics Review #: 103375

You are being invited to participate in a study to determine the effectiveness of a new treatment for Achilles tendon tears. The new treatment is called an autologous conditioned plasma (ACP) injection, which involves removing some of your blood from your arm and injecting part of the blood, the plasma, back into your body at the site of your Achilles tendon rupture. The plasma contains platelets that release growth factors that may induce a healing process when injected at the site of the Achilles tendon tear. The objective of this study is to determine whether non-operative treatment plus an ACP injection will provide improved overall results when compared to non-operative treatment alone. Non-operative treatment consists of the use of an Air Cast boot for immobilization and specific exercise guidelines to be followed in physical therapy as indicated by your investigating surgeon. Twenty patients are expected to participate in this study.

To be eligible to participate in this study, this must be your first Achilles tendon tear and the injury must have occurred within 7 days of the clinic visit. If you decide to participate in this study approximately 4 teaspoons of blood will be

removed from your non-dominant arm by a nurse. Some of this blood (approximately 1 teaspoon) will be sent to the hospital laboratory to determine the concentration of platelets and white blood cells in your blood prior to injection. The remaining blood is then put into a machine that spins the blood until it separates into layers. One layer is the ACP, which your surgeon will remove from the tube and inject into your ankle at the site of the Achilles tendon rupture. A second injection utilizing the same method will occur 2 weeks following the first injection.

If you are randomized to the Non-ACP group, you will also have approximately 4 teaspoons of blood removed from your non-dominant arm by a nurse but instead of injecting ACP into your ankle, your surgeon will inject saline (salt-water).

You will be kept unaware of which group you are in. In the case of an emergency, you may ask to know what group you were randomized into.

Both groups of patients will receive an Air Cast boot splint applied with a 2 cm felt heel lift. At six weeks the heel lift will be removed. Weight bearing as tolerated on your injured side with crutch assistance will continue for six weeks. You will be allowed to remove the air cast boot and perform active ankle movements up to neutral with physiotherapy supervision. At six weeks your cast boot will be removed and strengthening and stretching exercises will be prescribed by your physical therapist.

Your surgeon will want to see you back in clinic for standard follow-up visits at 2 weeks, 6 weeks, 12 weeks, 24 weeks, and 1 year. As a participant in this study, we will ask that you complete a short questionnaire to assess your pain, functional ability, and range of motion. We will also measure your range of motion. At 24 weeks and 1 year, we will evaluate your strength. Strength testing takes place in the Wolf Orthopaedic Biomechanics Laboratory at the Fowler Kennedy Sport Medicine Clinic. To complete the test, you will be seat belted into the strength-testing machine (Biodex). Your ankle will also be strapped to the Biodex. You will then be asked to flex and contract your calf muscle at 3 different speeds. These follow-up visits will take about an hour.

In addition, as a participant in this study, we will ask you to undergo an ultrasound of your Achilles tendon at 2, 4, 6, 8, 12, and 24 weeks, and to undergo an MRI at 6, 12, and 24 weeks. Each of these tests will take approximately one hour and will take place at University Hospital. This imaging will be used to determine whether ACP produces a visible improvement in healing over no treatment.

Alternatives to Participation

If you decide not to participate, other options for treatment include non-operative treatment without the ACP injection or surgical repair of the Achilles tendon. Your surgeon will discuss with you the risks and benefits of all of your options.

Risks

There is a risk of bruising and discomfort as a result of taking your blood sample. Infection is a rare but potential risk any time blood is removed or an injection is given. The side effects of ACP injections are uncommon, but an increase in inflammation and pain after injection is possible. We will minimize discomfort and reduce the risks that these adverse events may occur by having only a qualified surgeon who has expertise and experience performing these injections.

Part of your participation in this study will involve a research test with Magnetic Resonance Imaging (MRI) system, a common medical diagnostic tool that uses a strong magnetic field, a low frequency magnetic field, and a radio frequency field. No X-rays are used. As with any technology there is a risk of death or injury. For MRI the risk of death is less than 1 in 10 million and the risk of injury is less than 1 in 100,000. These risks do not arise from the MRI process itself, but from a failure to disclose or detect MRI incompatible objects in or around the body of the subject or the scanner room. It is therefore very important that you answer all the questions honestly and fully on the MRI screening questionnaire. The questionnaire is used to ensure your safety and to make us aware of any conditions that could interfere with your MRI.

Almost all the deaths and injuries related to MRI scans have occurred because the MRI operator did not know that surgically implanted metal hardware (such as a cardiac pacemaker) was present inside the subject during the MRI scan. Other remote risks involve temporary hearing loss from the loud noise inside the magnet. This can be avoided with ear headphone protection that also allows continuous communication between the subject and staff during the scan. For comparison, the risk of death in an MRI is similar to travelling 10 miles by car, while the risk of injury during an MRI is much less than the risks associated with normal daily activities for 1 hour.

You may not be allowed to continue in this research study if you are unable to have a MRI scan because, for example, you have some MRI incompatible metal in your body, you may be pregnant or attempting to become pregnant, or you may have a drug patch on your skin that contains a metal foil. Should you require a medically necessary MRI scan in the future, the final decision as to whether you can be scanned will be made by a qualified physician considering all the risks and benefits.

MRI exclusion criteria

If you have any history of head or eye injury involving metal fragments, if you have some type of implanted electrical device (such as a cardiac pacemaker), if you have severe heart disease (including susceptibility to heart rhythm abnormalities), you should not have an MRI scan unless supervised by a physician. Additionally you should not have a MRI scan if you have conductive implants or devices such as skin patches, body piercing or tattoos containing metallic inks because there is a risk of heating or induction of electrical currents within the metal element causing burns to adjacent tissue.

This MRI machine uses a strong magnet and radio waves to make images of the body interior. You will be asked to lie on a long narrow couch for a certain amount of time [30 mins] while the machine gathers data. During this time you will be exposed to magnetic fields and radio waves. You will not feel either.

You will, however, hear repetitive tapping noises that arise from the magnets that surround you. You will be provided with earplugs or headphones that you will be required to wear to minimize the sound and protect your hearing. The space within the large magnet in which you lie is somewhat confined, although we have taken many steps to relieve the "claustrophobic" feeling. There are no known significant risks with this procedure at this time because the radio waves and magnetic fields, at the strengths used, are thought to be without harm. The exception is if you have a cardiac pacemaker, or a metallic clip in your body (e.g., an aneurysm clip in your brain), have severe heart disease, body piercings, tattoos containing metallic ink or slow release pharmaceutical skin patches.

There is a possibility that you will experience a localized twitching sensation due to the magnetic field changes during the scan. This is not unexpected and should not be painful. However, you can stop the exam at any time. The magnetism and radio waves do not cause harmful effects at the levels used in the MRI machine. However, because the MR scanner uses a very strong magnet that will attract metal, all metallic objects must be removed from your person before you approach the scanner. In addition, watches and credit cards should also be removed as these could be damaged. (These items will be watched for you).

Compensation

You will receive \$25 per visit to compensate you for any study-related expenses including parking at the University Hospital.

Benefits

Participation in this study may be of no direct benefit to you. The findings from this study however, will contribute to our understanding of ACP injections and their effectiveness when used with standard treatment options.

Voluntary Participation

Participation in this study is voluntary. You may refuse to participate, refuse to answer questions or withdraw from the study at any time with no effect on your future care. Should you choose to withdraw from the study, we will keep all data obtained up to the point that you chose to withdraw.

Participation in this study does not prevent you from participating in other research studies at the present time or in the future. Please be sure to tell us if you are participating in other research studies at the same time. You do not waive any legal rights by signing the consent form.

Photography

The investigating surgeon is requesting your permission to take pictures of the procedure on the day of your injection. On the day of your Achilles tendon injection the nurse or research assistant may record pictures of the steps involved in your injection. Over the next few follow-up appointments additional pictures will be taken of the affected Achilles tendon in order to visually record the healing progress. Neither your face nor any recognizable feature will appear in any of the photographs collected for this study. All photographs for this study will be identified by your initials and a subject identifying number only. By signing and dating the Photography section of the Consent Form, you are giving the investigating surgeon of this study permission to use and share your photographs. Your pictures will be handled with the same confidentiality as your other medical records. All pictures will be destroyed two years following the publication of research findings.

Confidentiality

Any personal health information collected or other information related to you will be coded by a unique number to ensure that persons outside of the study will not be able to identify you. In any publication, presentation or report, your name will not be used and any information that discloses your identity will not be released or published unless required by law. Despite these protections being in place, there is always a risk of unintentional release of information. The study personnel will protect your records and keep all the information in your study file confidential to the greatest extent possible. The chance that this information will be accidentally released is small.

The data that is collected from you is managed by a company called EmPower Health Research. Any information provided by you is protected by a username and password. It travels in a scrambled format to a server (storage computer) that is located in Montreal, Canada and to a backup server located in Vancouver, Canada. Your name, contact information and your date of birth are part of this database. The company that houses the database is a professional company with extremely high standards of physical and virtual security (Netelligent). We want to let you know however, that even with this high level of security, there is always a remote chance that your information could be accessed or "hacked" by someone who is not supposed to have your information. If we became aware that this had happened, we would inform you immediately.

By agreeing to participate in this study, you are allowing access to your study related medical records by the study personnel, authorized representatives (i.e., study monitor or auditor) of the sponsoring company, and representatives of The University of Western Ontario Health Sciences Research Ethics. Your name, contact information and date of birth cannot be downloaded into spreadsheets or extracted from the database. Representatives of the University of Western Ontario Health Sciences Research Ethics Board may contact you or may require access to your study related records to monitor the conduct of the research.

Questions?

If you have questions about the conduct of the study or your rights as a research participant, you may contact The Office of Research Ethics at [redacted] or by email at [redacted]. If you have further questions with regards to this research, please contact Dr. David Hill, Scientific Director Lawson Health Research Institute at [redacted].

Thank you for your time and interest in ongoing medical research. This letter is yours to keep.

Sincerely,

Dr. K. Willits and team

Contact Information

If you would like to receive a copy of the article upon the study's completion please fill out the following information. If your contact information should change at any time, please notify the research team.

Name: _____

Address: _____

City/Town: _____

Postal Code: _____



Title of Research:

A randomized clinical trial to compare the effect of non-operative treatment with or without Autologous Conditioned Plasma (ACP) on healing and function in patients with Achilles tendon rupture

I have read the letter of information, have had the nature of the study explained to me, and I agree to participate in the study. All questions have been answered to my satisfaction.

Printed Name of
the Participant

Signature of
the Participant

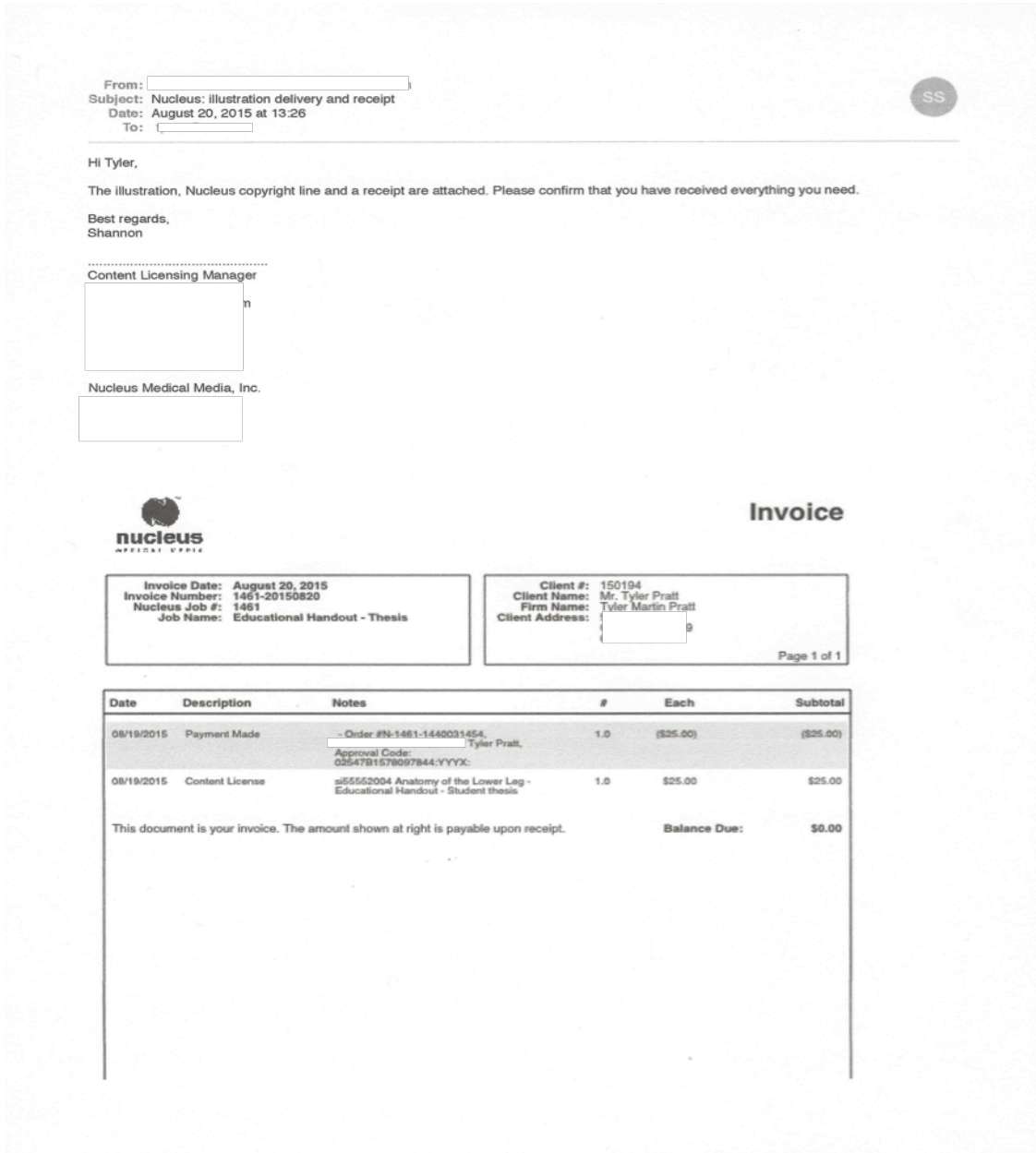
Date

Printed Name of the
Person Obtaining Consent

Signature of the Person
Obtaining Consent

Date

Appendix C: Image and Table Permissions





Confirmation Number: 11426722
Order Date: 08/19/2015

Customer Information

Customer: Tyler Pratt
Account Number: 3000898052
Organization: Tyler Pratt
Email: [REDACTED]
Phone: [REDACTED]
Payment Method: Invoice

This is not an invoice

Order Details

FOOT AND ANKLE CLINICS

Billing Status:
N/A

Order detail ID: 68044510
ISSN: 1083-7515
Publication Type: Journal
Volume:
Issue:
Start page:
Publisher: W.B./SAUNDERS CO.
Author/Editor: W.B. SAUNDERS COMPANY

Permission Status: **Granted**
Permission type: Republish or display content
Type of use: Thesis/Dissertation
Order License Id: 3692620832542

| | |
|--|-----------------------------------|
| Requestor type | Academic institution |
| Format | Print, Electronic |
| Portion | image/photo |
| Number of images/photos requested | 1 |
| Title or numeric reference of the portion(s) | Figure 4.8 A |
| Title of the article or chapter the portion is from | Imaging of the Achilles tendon |
| Editor of portion(s) | N/A |
| Author of portion(s) | Bleakney RR, White LM, Maffulli N |
| Volume of serial or monograph | 10 |
| Page range of portion | 239-254 |
| Publication date of portion | 2005 |
| Rights for | Main product |
| Duration of use | Life of current edition |
| Creation of copies for the disabled | no |
| With minor editing privileges | yes |

RADIOLOGICAL SOCIETY OF NORTH AMERICA



[Redacted box]

June 19, 2015

Tyler Pratt

[Redacted box]

Dear Tyler Pratt:

The Radiological Society of North America (RSNA®) is pleased to grant you permission to reproduce the following figure in print, electronic, and web formats for educational, non-profit use in your dissertation/thesis, provided you give full credit to the authors of the original publication.

Figure 2
Hartgerink P, Fessell D P, Jacobson J A, et al. Full-versus partial-thickness Achilles tendon tears: Sonographic accuracy and characterization in 26 cases with surgical correlation. *Radiology* 2001;220:406-412.

This permission is a one-time, non-exclusive grant for English-language use and is exclusively limited to the usage stated and underlined above. The requestor guarantees to reproduce the material as originally published. Permission is granted under the condition that a full credit line is prominently placed (i.e. author name(s), journal name, copyright year, volume #, inclusive pages and copyright holder).

This permission becomes effective upon receipt of this signed contract. Please sign a copy of this agreement, return a signed copy to me and retain a copy for your files. Thank you for your interest in our publication.

[Print Name]: TYLER PRATT

SIGNATURE: [Redacted Signature Box] Date: 06/19/2015

Sincerely,

[Redacted Signature Box]

Ashley E. Daly
Senior Manager, Journal Rights & Communications
Publications

[Redacted Box]

6/22/2015

Copyright Clearance Center



Confirmation Number: 11373562
Order Date: 06/03/2015

Customer Information

Customer: Tyler Pratt
Account Number: 3000898052
Organization: Tyler Pratt
Email: [redacted]
Phone: [redacted]
Payment Method: Invoice

This is not an invoice

Order Details

Skeletal radiology

Billing Status:
N/A

Order detail ID: 67331498
ISSN: 0364-2348
Publication Type: Journal
Volume:
Issue:
Start page:
Publisher: SPRINGER-VERLAG
Author/Editor: INTERNATIONAL SKELETAL SOCIETY

Permission Status: **Granted**
Permission type: Republish or display content
Type of use: Thesis/Dissertation
Order License Id: 3641521437950

Requestor type: Academic institution
Format: Print, Electronic
Portion: image/photo
Number of images/photos requested: 3
Title or numeric reference of the portion(s): figure 1B, figure 2C, Figure 4B
Title of the article or chapter the portion is from: Sonographic appearance of non operatively treated Achilles tendon ruptures
Editor of portion(s): International Skeletal Society
Author of portion(s): Hollenberg GM, Adams MJ, Weinberg EP
Volume of serial or monograph: 29
Page range of portion: 259-264
Publication date of portion: February 8, 2000
Rights for: Main product
Duration of use: Life of current edition
Creation of copies for the disabled: no
With minor editing privileges: yes
For distribution to: Worldwide
In the following language(s): Original language of publication
With incidental promotional use: no

6/22/2015

Copyright Clearance Center



Confirmation Number: 11384141
Order Date: 06/18/2015

Customer Information

Customer: Tyler Pratt
Account Number: 3000898052
Organization: Tyler Pratt
Email:
Phone:
Payment Method: Invoice

This is not an invoice

Order Details

British journal of radiology. BIR section

Billing Status:
N/A

Order detail ID: 67464872
ISSN: 2053-1303
Publication Type: Journal
Volume:
Issue:
Start page:
Publisher: BIR

Permission Status: **Granted**
Permission type: Republish or display content
Type of use: Republish in a thesis/dissertation
Job Ticket: 501021248
Order License Id: 3654270199790

| | |
|--|--------------------------------------|
| Requestor type | Academic institution |
| Format | Print, Electronic |
| Portion | image/photo |
| Number of images/photos requested | 1 |
| Title or numeric reference of the portion(s) | figure 10 |
| Title of the article or chapter the portion is from | Tendon and ligament imaging |
| Editor of portion(s) | N/A |
| Author of portion(s) | Hodgson RJ, O'Connor PJ, Grainger AJ |
| Volume of serial or monograph | 85 |
| Page range of portion | 1157-1172 |
| Publication date of portion | 2012 |
| Rights for | Main product |
| Duration of use | Life of current edition |
| Creation of copies for the disabled | no |
| With minor editing privileges | yes |
| For distribution to | Worldwide |
| In the following language(s) | Original language of publication |
| With incidental promotional use | no |

Mr. Tyler Pratt
University of Western Ontario - Research

E-Mail:

16 March 2015

Copyright Permission No 45//2015

Dear Mr. Pratt,

Thank you for your permission request of 14 March.

We grant you permission to reprint from (provided the approval of the senior author, which you have to obtain also before reprinting):

Journal: Thrombosis and Haemostasis 2004
Author: Anitua E, Andia I, Ardanza B, et al.
Title: Autologous platelets as a source of proteins for healing and tissue regeneration
Pages: Table 1, p. 6

The permission is granted for reprint in:

Publication: **your doctoral/master's thesis**

Terms and conditions:

The permission is granted only for scientific purposes on a non-exclusive, one-time only or life of the edition basis with distribution rights in the English language throughout the world.

Permission fee: none

Credit line: Anitua E, Andia I, Ardanza B, et al. Autologous platelets as a source of proteins for healing and tissue regeneration. Thromb Haemost 2004; 91. 4-15.

Voucher copy: none

Sincerely,

Carola Kalff

Rights and Permissions
Schattauer GmbH · www.schattauer.de
Publishers for Medicine and Natural Sciences

From: Alan Nurden
Subject: Re: Anitua et al (2004) - use of table for Masters thesis
Date: March 17, 2015 at 12:15
To:



Tyler, I would be happy for you to reproduce Table 1 in your thesis. Good luck with your studies.
Sincerely

Alan T Nurden
PS I attach a pdf of a more recent manuscript.

De: "
À: "a
Envoyé: Lundi 16 Mars 2015 21:12:09
Objet: Anitua et al (2004) - use of table for Masters thesis

Hello,

My name is Tyler Pratt. I am a Masters student at the University of Western Ontario in London, Ontario, Canada. I am doing my thesis project on platelet-rich plasma (PRP) for the treatment of Achilles tendon ruptures. I would like to use Table 1 in the article by Anitua et al (2004) *Autologous platelets as a source of proteins for healing and tissue regeneration* in my thesis.

I have obtained permission from the publisher to use this, and now I need your permission to use it as well. If you could confirm this, in writing, in a response to this email that would be sufficient.

If you have any questions, please don't hesitate to ask me.

I appreciate your consideration,

Tyler Pratt



Frontiers.pdf

6/22/2015

Rightslink Printable License

**ELSEVIER LICENSE
TERMS AND CONDITIONS**

Jun 22, 2015

This is a License Agreement between Tyler Pratt ("You") and Elsevier ("Elsevier") provided by Copyright Clearance Center ("CCC"). The license consists of your order details, the terms and conditions provided by Elsevier, and the payment terms and conditions.

All payments must be made in full to CCC. For payment instructions, please see information listed at the bottom of this form.

| | |
|--|--|
| Supplier | Elsevier Limited <input type="text"/> |
| Registered Company Number | 1982084 |
| Customer name | Tyler Pratt |
| Customer address | <input type="text"/> |
| License number | 3586480480126 |
| License date | Mar 12, 2015 |
| Licensed content publisher | Elsevier |
| Licensed content publication | Arthroscopy: The Journal of Arthroscopic & Related Surgery |
| Licensed content title | Platelet-Rich Plasma: The PAW Classification System |
| Licensed content author | Jeffrey M. DeLong,Ryan P. Russell,Augustus D. Mazzocca |
| Licensed content date | July 2012 |
| Licensed content volume number | 28 |
| Licensed content issue number | 7 |
| Number of pages | 12 |
| Start Page | 998 |
| End Page | 1009 |
| Type of Use | reuse in a thesis/dissertation |
| Portion | figures/tables/illustrations |
| Number of figures/tables/illustrations | 2 |
| Format | both print and electronic |
| Are you the author of this Elsevier article? | No |
| Will you be translating? | No |
| Original figure numbers | Table 1, figure 1 |

Appendix D: MR Imaging Sequences

| <i>Protocol</i> | <i>Field of View</i> | <i>TR, TE, (TI)</i> | <i>Echo Train Length</i> | <i>Slice Thickness, Spacing</i> | <i>Matrix (Frequency & Phase)</i> | <i>Number of Excitations</i> |
|---|----------------------|--------------------------|--------------------------|---------------------------------|---------------------------------------|------------------------------|
| Sagittal fast-spin echo T1 | 20 cm | 700 ms, 15 ms | 2 | 3.5 mm, 0.5 mm | 385 x 224 | 1 |
| Sagittal fast-recovery fast-spin echo T2 | 20 cm | 3000 ms, 70 ms | 12 | 3.5 mm, 0.5 mm | 320 x 224 | 2 |
| Sagittal 3D proton density CUBE | 20 cm | 3000 ms, minimum | 64 | 0.7, 0 | 192 x 192 | 0.5 |
| Sagittal fast inversion recovery | 20 cm | 4250 ms, 34 ms, (150 ms) | 8 | 3.5 mm, 0.5 mm | 245 x 224 | 2 |
| Axial fast-spin T2 | 14 cm | 4000 ms, 70 ms | 15 | 4 mm, 0.5 mm | 320 x 224 | 1 |

Curriculum Vitae

Tyler Pratt

EDUCATION

Master of Science

Health & Rehabilitation Sciences
Measurement & Methodology
University of Western Ontario, London, ON
September 2013 – September 2015

Bachelor of Human Kinetics

Movement Science
University of Windsor, Windsor, ON
Class of 2013
Graduated 'With Distinction'

RESEARCH EXPERIENCE

University of Western Ontario
Thesis Project
2013 – Present

Fowler-Kennedy Sports Medicine Clinic
Under the supervision of Dr. Dianne Bryant and co-supervision of Dr. Kevin Willits
"A randomized control trial to compare the effects of non operative treatment with and without Autologous Conditioned Plasma (ACP®) on healing and function in patients with Achilles tendon ruptures

University of Windsor
Undergraduate Thesis
2012

Cardiovascular Physiology Lab
Under the supervision of Dr. Cheri McGowan
"Gender differences in the neurovascular response to acute isometric handgrip (IHG) exercises and a complimentary ischemic-reperfusion cuff protocol

TEACHING EXPERIENCE

University of Western Ontario
 London, ON
Teaching Assistant
 2013-2015

Foundations of Research
 Occupational Therapy 9541

CONFERENCES & PRESENTATIONS

31st Annual Western
 Homecoming Sports Medicine
 Symposium
 London, ON
 September 2014

Thesis Presentation
 Accredited by the Royal College of Physicians
 and Surgeons of Canada

Measurement & Methods
 Seminar
 University of Western Ontario
 London, ON
 February 2014

Lecture Presentation
 'Calculating confidence intervals around
 effect-size estimates'

Fowler-Kennedy Sports
 Medicine Clinic
 Research Rounds
 January, 2014

Thesis Presentation
 In attendance: Orthopedic surgeons,
 primary care physicians, physiotherapists,
 and research staff at FKSMC

HONOURS AND AWARDS

2013-2015

Western Graduate Research Scholarship

2013

Graduated 'with distinction' from the University
 of Windsor (BHK)

2012

'Lancer Award' for outstanding leadership,
 commitment, and performance (University of
 Windsor Lancers, baseball)

- 2008 University of Windsor Faculty of Human Kinetics
Book Award (University of Windsor & St.
Thomas of Villanova)
- 2008 'Directors Award for Outstanding Academic and
Athletic Achievement' (University of Windsor &
St. Thomas of Villanova)