

## ORIGINAL ARTICLE

# Association of Retinal Nerve Fiber Layer (RNFL) Thickness with Smoking Using Optical Coherence Tomography (OCT) in Pakistani Population

Sahrish Mukhtar<sup>1</sup>, Sadaf Shaheen<sup>2</sup>, Nadia Yonus<sup>1</sup>, Asma Basharat<sup>1</sup>, Iffat Raza<sup>3</sup>, Mahrukh Kamran<sup>4</sup>

<sup>1</sup>Department of Anatomy, Jinnah Medical and Dental College, Karachi, <sup>2</sup>Department of Anatomy, Frontier Medical and Dental College, Abbottabad, <sup>3</sup>Department of Anatomy, Karachi Institute of Medical Sciences, <sup>4</sup>Department of Anatomy, Dow University of Health Sciences, Karachi, Pakistan.

## ABSTRACT

**Background:** Smoking has multisystem effects on human body due to hypoxia and systemic inflammation, which it produces. This contributory effect is observed in ocular tissues as well. The aim of the study was to evaluate retinal nerve fiber layer (RNFL) thickness in healthy individuals with a history of smoking, using optical coherence tomography (OCT).

**Methods:** Patients healthy eyes n=300 were examined. Two groups were made; Group A with history of smoking (n=50) and Group B with no history of smoking (n=250). Subjects with a history of diabetes, hypertension, raised intra ocular pressure (IOP >21 mmHg), any neurological disease or family history of glaucoma were excluded from the study. Independent t-test was used to assess the thickness variation with smoking status. ANOVA was used to analyze the differences in both groups. *p* value <0.05 was taken as significant.

**Results:** The mean retinal nerve fiber layer (RNFL) thickness was found to be  $96.44 \pm 9.32 \mu\text{m}$  in Group A eyes. It was found to be significantly increased ( $p=0.02$ ) in Group B  $99.54 \pm 9.32 \mu\text{m}$ . The mean RNFL thickness  $93.52 \pm 8.60 \mu\text{m}$  in smokers with history of more than 10 years was found decreased compared to the thickness  $98.66 \pm 3.96 \mu\text{m}$  in those with history of smoking less than 10 years.

**Conclusion:** Retinal nerve fiber layer (RNFL) was found to be decreased in subjects with positive history of smoking. This difference signifies that smoking is associated with ocular pathologies. Future protocols may be included in screening for RNFL thickness in smokers for early detection and prevention of optical diseases.

**Keywords:** Smoking; Retina; Retinal Nerve Fiber Layer (RNFL); Retinal Damage; Optical Coherence Tomography (OCT).

**Corresponding Author:****Dr. Sahrish Mukhtar**

Jinnah Medical and Dental College,  
Medicare and Cardiac General Hospital,  
Shaheed-e-Millat Road, Karachi, Pakistan.  
Email: dr.sahrish@gmail.com  
doi.org/10.36283/PJMD9-4/006

## INTRODUCTION

Smoking is the major lifestyle factor, which is affecting the health of the individual silently and continues to be an alarming public health issue in Pakistan<sup>1</sup>. According to the WHO statistics in 2014, tobacco use was the second most significant risk factor for developing several diseases. It is predicted that the number of annual tobacco-related deaths will reach 7.5 million by the year 2020

accounting for approximately 10% of all mortalities<sup>2</sup>. There are more than 4,000 chemicals in cigarette smoke were found that causes damage to multiple organs, bones and muscles of human body<sup>3-4</sup>. However, previously it was also documented that independent risk factor for the development of severe retinopathy of prematurity in preterm infants<sup>5</sup>. Smoking is also reported to have carcinogenic effects almost on every organ of body. Multiple cancer sites are evident in literature, which

are attributed to smoking<sup>6-8</sup>.

Tobacco smoking is known to be one of the important risk factors for the development of several ocular pathologies such as retinopathy, macular degeneration, ischemic optic neuropathy, cataract etc. It is also reported to have caused defects in the offspring of smokers<sup>9</sup>. Toxins of smoking tend to accumulate in lens and causes earlier cataract changes in smokers and less tear production<sup>10-11</sup>. It causes damage to posterior segment structures like choroid, macula, retina and its vasculature<sup>12-13</sup>. Out of 10 layers of retina, the retinal nerve fiber layer (RNFL), facing vitreous humor contains axons of the ganglionic cells present in retina. Axons of each optic tract synapse in the lateral geniculate nucleus (LGN) of the thalamus. From the LGN, axons project via the optic radiation to the occipital cortex of the cerebrum<sup>14</sup>.

Normally, the RNFL thickness tends to reduce with age<sup>15</sup>. This thickness is also known to be reduced earlier in certain diseases like diabetes and hypertension than normal age<sup>16-18</sup>. Thus, reduction in RNFL thickness dictates earliest damage to ocular tissue. It is also considered as the best indicator in screening for any posterior segment pathological conditions<sup>15</sup>. Along with the thickness of retinal or choroidal layers, quantitative analysis of chorioretinal vasculature is important to understand the pathophysiology of these disorders and to evaluate chorioretinal diseases. One best modality of analyzing these parameters is using the Optical Coherence Tomography (OCT) was first introduced in 1991<sup>19-20</sup>. It is the best non-invasive imaging modality used in ophthalmology for early detection of changes in ocular tissues especially retina and its layers, which leads to early diagnosis and yielding better prognosis<sup>21-22</sup>.

As smoking is associated with ocular damage, therefore, future protocols should include screening for RNFL thickness in smokers for early detection of optical diseases and awareness programs might started in order to decrease the frequency of smoking and thus, the incidence of retinal damage. Therefore, the objective of this study was to find the association of smoking and retinal nerve fiber layer (RNFL) thickness in healthy individuals by optical coherence tomography (OCT).

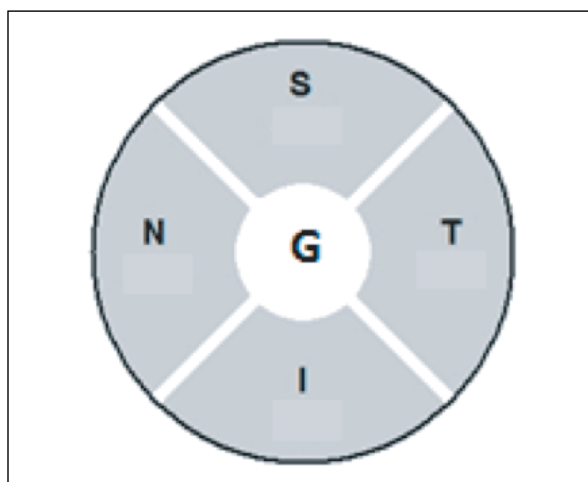
## METHODS

This study included 300 eyes from 150 individuals, including 75 females and 75 males aged 40 years and above, from an ophthalmic clinic in Karachi, Pakistan. This was a cross sectional study conducted in the year 2015 after getting the ethical approval from the ERC of Dr. Ziauddin University, Karachi, Pakistan (Reference number: 0271214SMANA). All subjects with normal intraocular pressure (IOP) and

cup disc ratio (CDR) <0.4 were included in the study. Subjects with history of intraocular surgery or laser therapy, high refractive errors, any retinal pathologies, and diabetic or hypertensive retinopathy and glaucoma were excluded from the study.

Initially an informed consent was obtained from all the subjects followed by detailed ophthalmic examination. The ophthalmic examination included testing for refractive error and visual acuity, slit-lamp biomicroscopy and CDR measurement by using direct ophthalmoscope and tonometry.

Subjects were divided into 2 groups; Group A and Group B. Group A included subjects with history of smoking (n=50). Group B included subjects who do not smoke or who had never smoked in their life (n=250). Group A was further divided into Group 1 and Group 2, depending upon the duration of smoking. Group 1 had people who were smoking for more than 10 years (n=38) and group 2 included those who had smoking history for less than 10 years (n= 12). OCT testing was performed by using Spectralis Heidelberg's OCT by a single experienced technician after dilating the eyes with 1% tropicamide eye drops. During OCT scanning, the cross-sectional retinal images along with defined macular margins were captured on the computer screen. Each subject was asked to fix his/her gaze at the light source seen through the lens of OCT apparatus for measurement of retinal layers thickness. The gaze fixation was to make sure suitable positioning of the RNFL with respect to the optic nerve head<sup>15</sup>. The predefined OCT software algorithm (Figure 1) helped in identifying the anterior and posterior margins of RNFL and thus in calculating the thickness in different sectors (nasal, temporal, superior and inferior) to give an average measurement of RNFL globally.



**Figure 1: Quadrants of optic disc; G: Global Average, S: Superior Quadrant, I: Inferior Quadrant, N: Nasal Quadrant, T: Temporal Quadrant.**

The high resolution and reliable results have made OCT an essential technique for diagnosis and monitoring various diseases involving the retina and optic nerve. For statistical analysis, SPSS version 20 was used. Mean  $\pm$  standard deviation was applied for quantitative variables. For qualitative variables, frequencies and percentages were used. Independent t-test was used to assess the thickness variation with smoking status. ANOVA was used to analyze the differences in both groups and  $p$  value  $<0.05$  was considered as significant.

## RESULTS

In this study out of 150 subjects, both males and females (75) had mean age of  $57.67 \pm 11.42$  years. Subjects were divided into 2 groups; Group A and Group B. The measurements of mean RNFL of Group A and Group B (Table 1) are mentioned according to the divisions of quadrants of optic nerve head. In Group A, the mean global retinal nerve fiber layer thickness  $96.44 \pm 9.32\mu\text{m}$  was found. The RNFL thickness (Table 1) was found  $118.70 \pm 16.77 \mu\text{m}$  in superior quadrant,  $124.12 \pm 14.39 \mu\text{m}$  in inferior quadrant,  $76.92 \pm 14.01 \mu\text{m}$  in nasal and  $66.14 \pm 10.62 \mu\text{m}$  in temporal quadrant.

**Table 1: Retinal nerve fiber layer (RNFL) measurements in each quadrant of optic nerve head in Group A (smokers) and Group (B) nonsmokers.**

Parameters	Total n = 300	Optic Nerve Head Quadrants Mean $\pm$ S.D. ( $\mu\text{m}$ )				
		Global	Superior	Inferior	Nasal	Temporal
Smokers	50	$96.44 \pm 9.32$	$118.70 \pm 16.77$	$124.12 \pm 14.39$	$76.92 \pm 14.01$	$66.14 \pm 10.62$
Non - Smokers	250	$99.54 \pm 8.96$	$122.06 \pm 14.63$	$126.92 \pm 16.57$	$79.41 \pm 13.98$	$69.44 \pm 13.50$
Mean		$99.02 \pm 9.08$	$121.50 \pm 15.03$	$126.45 \pm 16.23$	$78.99 \pm 13.99$	$68.89 \pm 13.10$
p-Value		0.001*	0.001*	0.001*	0.001*	0.001*

n=number of eyes, S.D. Standard deviation, \* statistically significant.

In Group B, the mean global retinal nerve fiber layer thickness  $99.54 \pm 8.96\mu\text{m}$  was found. Superior quadrant showed (Table 1) RNFL thickness of  $122.06 \pm 14.63\mu\text{m}$ ,  $126.92 \pm 16.57 \mu\text{m}$  was noted in inferior quadrant,  $79.41 \pm 13.98 \mu\text{m}$  in nasal and  $69.44 \pm 13.50\mu\text{m}$  in temporal quadrant. Depending upon the duration of smoking, Group A was

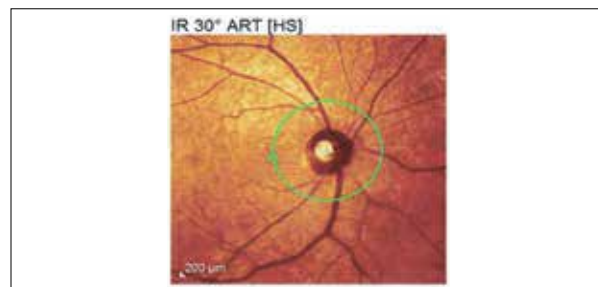
subdivided into Group 1, which included people who were smoking for more than 10 years and Group 2, which included people who had smoking history for less than 10 years. The mean global RNFL thickness in Group 1 (Table 2) was found decreased  $93.52 \pm 8.60 \mu\text{m}$  as compared to Group 2 in which it was calculated  $98.66 \pm 3.96 \mu\text{m}$ .

**Table 2: Effect of time duration of smoking on retinal nerve fiber layer (RNFL).**

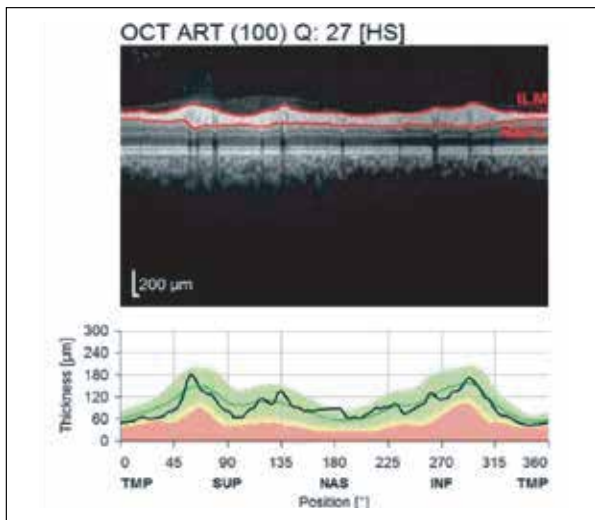
Status of smoking	Total n = 300	RNFL Thickness Mean $\pm$ S.D ( $\mu\text{m}$ )	p-Value
More than 10 years	38	$93.52 \pm 8.60$	0.00*
Less than 10 years	12	$98.66 \pm 3.96$	0.05*
No smoking	250	$99.54 \pm 8.96$	0.02*

n = number of eyes, S.D. Standard deviation, \* statistically significant.

The RNFL was measured by using OCT machine (Figure 2) identifying the optic nerve head as shown in. The software in OCT then generated the image (Figure 3) showing anterior and posterior margins of the specific layer. The study results signified that those who smoked for more duration had worse effects than those with lesser duration of smoking. The results also found early ocular changes occurring in RNFL in smokers by using OCT.



**Figure 2: Circle shows optic nerve head through optical coherence tomography (OCT).**



**Figure 3: Retinal nerve fiber layer (RNFL) thickness analysis (from anterior margin to posterior margin of RNFL layer) by using Spectralis software.**

### DISCUSSION

The RNFL thickness was measured in this study according to their smoking status. RNFL in each quadrant of optic nerve head was also measured and showed significant decrease in each quadrant favoring the adversity of smoking towards retina. This is in accordance to a study by Dervişoğulları et al., found the same effects of smoking on RNFL in their research and suggested that this should be considered while interpreting the results in such individuals<sup>22</sup>. Demirci et al. also suggested the decrease in RNFL with smoking, which was also supported by other study conducted in Turkey<sup>21</sup>. Nita et al. also reported in their study that multiple eye pathologies could occur because of smoking<sup>23</sup>.

Our study also highlighted that there was a uniform decrease in RNFL thickness. The reduction of thickness was in accordance with the ISNT rule (inferior > superior > nasal > temporal)<sup>24</sup>, which stated that RNFL thickness is maximum in inferior quadrant followed by superior, nasal and temporal quadrants. Jonas et al. established the ISNT rule in their study conducted in Germany in 1999<sup>24</sup>. It is an easy way to remember how the optic nerve is supposed to look in a normal eye showing the neuro-retinal rim the thinnest temporally and thickest inferiorly. Any deviation from ISNT rule will help the clinicians to detect the optic nerve pathologies at an early stage.

Cigarette smoking has been known for long to damage multiple systems of body<sup>25</sup>. It has been reported that smoking causes damage to auditory system, cardiovascular system, respiratory system, musculo-skeletal system thus, affecting almost every organ of the body sooner or later<sup>26-27</sup>. It has been anticipated that smoking results in transient boost in flow of blood

supply to choroid, retina and optic nerve head. However, it is still unclear that how this enhancement in blood velocity causes retinal changes. However, it has been assumed that there are few modulators that play certain role in causing changes in retinal thickness including macula<sup>28</sup>. A study by Eris et al. found the decreased thickness of choroid with smoke but got insignificant results for macular vascular and optic disc perfusion<sup>29</sup>. Whereas, another study suggests that the vessel density parameters are found decreased at acute period after smoking, even one cigarette when compared with non-smokers, which was supported by Dogan et al research<sup>30-31</sup>.

Furthermore, a study by Yu et al., discussed that cigarette smoking affects the brain matter of Lewis rats by increasing the expression of genes encoding for pro-oxidant iNOS, NOX4, dual oxidase1, and p22phox. The oxidative DNA damage marker 8-hydroxyguanosine was also found increased in the hippocampus of cigarette smoke-exposed Sprague-Dawley (SD) rats. The reduced expression of different synaptic proteins including synapsin-1, synaptophysin and protein of cytoskeleton e.g., tubulin and drebrin were detected in rats which were exposed to cigarette smoke possibly damaging synaptic connections leading to axonal deficits<sup>25,31</sup>. By seeing these results, the individuals will be aware of the toxic effects of smoking on eyes. It can be used to promote awareness sessions regarding smoking and controlling its effects on our body. In addition to this, these results will facilitate to conduct awareness sessions regarding smoking and ensuring its control. This will ultimately result in decreasing its bad outcomes.

This observation may help clinicians to screen the high-risk individuals prior to the onset of various retinal diseases leading to irreversible blindness. In addition, our results may be used as a platform for future researches like research at molecular level can be carried out to further find out the genetic or enzymatic effect of cigarette smoking on retina especially the nerve fiber layer.

### CONCLUSION

Smoking was found to have adverse effects on retina, which is directly proportional to duration of exposure. These results are still preliminary but promising and require nationwide studies on large scale for strengthening our results further.

### ACKNOWLEDGEMENTS

We highly acknowledge the support from Dr. Nuzhat Hassan being the supervisor, Dr. Ziauddin University for aiding us in our research and Dr. Akil bin Abdul Kadir Eye Institute for helping us in providing the samples for data.



### CONFLICT OF INTEREST

The authors declare no conflict of interest.

### ETHICAL APPROVAL

The ERC of Dr Ziauddin University ethically approved this research (Reference number: 0271214SMANA).

### PATIENT CONSENT

Consent form was filled for every patient before the examination was started.

### AUTHORS' CONTRIBUTION

SM wrote the manuscript and did data collection. SS helped in writing the manuscript. NY and AB helped in doing the statistical analysis and literature search. IR and MK also helped in literature search for the manuscript writing.

### REFERENCES

- Shah N, Siddiqui S. An overview of smoking practices in Pakistan. *Pak J Med Sci.* 2015;31(2): 467-470.
- World Health Organization. Global status report on noncommunicable diseases 2014 [Internet] World Health Organization; 2014 [cited 2020 July 16]. Available from: [https://apps.who.int/iris/bitstream/handle/10665/148114/9789241564854\\_eng.pdf;jsessionid=957DD7BDD7E9C8A58F9E5\\_BACDD7EE4A8?sequence=1](https://apps.who.int/iris/bitstream/handle/10665/148114/9789241564854_eng.pdf;jsessionid=957DD7BDD7E9C8A58F9E5_BACDD7EE4A8?sequence=1)
- Teberik K. The effect of smoking on macular, choroidal, and retina nerve fiber layer thickness. *Turk J Ophthalmol.* 2019;49(1): 20-24.
- Wang Z, Wang D, Wang Y. Cigarette smoking and adipose tissue: the emerging role in progression of atherosclerosis. *Mediat Inflamm.* 2017;1-12.
- Hudalla H, Bruckner T, Pöschl J, Strowitzki T, Kuon RJ. Maternal smoking as an independent risk factor for the development of severe retinopathy of prematurity in very preterm infants. *Eye.* 2020;1-6.
- Orth SR. Effects of smoking on systemic and intrarenal hemodynamics: influence on renal function. *J Am Soc Nephrol.* 2004;15(1 suppl):S58-S63.
- Lee HW, Park SH, Weng MW, Wang HT, Huang WC, Lepor H, *et al.* E-cigarette smoke damages DNA and reduces repair activity in mouse lung, heart, and bladder as well as in human lung and bladder cells. *Proc Nat Acad Sci.* 2018;115(7): E1560-E1569.
- Wang G, Shen Y, Cheng G, Bo H, Lin J, Zheng M, *et al.* Lysyl oxidase gene G473A polymorphism and cigarette smoking in association with a high risk of lung and colorectal cancers in a north Chinese population. *Int J Environ Res Public Health.* 2016; 13(7):635-652.
- Kantarci FA, Tatar MG, Colak HN, Uslu H, Yildirim A, Goker H, *et al.* A pilot study of choroidal thickness in long-term smokers. *Retina.* 2016;36(5):986-991.
- Langford-Smith A, Tilakaratna V, Lythgoe PR, Clark SJ, Bishop PN, Day AJ. Age and smoking related changes in metal ion levels in human lens: implications for cataract formation. *PLoS one.* 2016;11(1):e0147576;1-16.
- Sayin N, Kara N, Pekel G, Altinkaynak H. Effects of chronic smoking on central corneal thickness, endothelial cell, and dry eye parameters. *Cutan Ocul Toxicol.* 2014;33(3):201-205.
- Kumar S, Majumdar S, Mukherjee S, Biswas MC, Sengupta P. Evaluation of the effects of moderate to severe smoking on retinal nerve fibre layer thickness. *J Evid Based Med Healthc.* 2019;6: 379-383.
- Nita M, Grzybowski A. Smoking and eye pathologies. A systemic review. Part II. Retina diseases, uveitis, optic neuropathies, thyroid-associated orbitopathy. *Curr Phar Des.* 2017;23(4):639-654.
- Drake R, Vogl AW, Mitchell AW. *Gray's Anatomy for Students Flash Cards E-Book* [Internet]. Elsevier Health Sciences; 2019 [cited 2020 July 20]. p151. Available from, <https://www.elsevier.com/books/grays-anatomy-for-students-flash-cards/drake/978-1-4557-5898-2>
- Mukhtar S, Hassan N, Dawood Z, Zehra N. Retinal nerve fiber layer thickness in a subset of Karachi (Pakistan) population. *J Adv Med Med Res.* 2015;1-7.
- Mulè G, Vadalà M, La Blasca T, Gaetani R, Virone G, Guarneri M, *et al.* Association between early-stage chronic kidney disease and reduced choroidal thickness in essential hypertensive patients. *Hypertens Res.* 2019;42(7):990-1000.
- Kim YD, Noh KJ, Byun SJ, Lee S, Kim T, Sunwoo L, *et al.* Effects of hypertension, diabetes, and smoking on age and sex prediction from retinal fundus images. *Sci Rep.* 2020;10(1):1-14.
- Mukhtar S, Hassan N, Dawood Z. OCT—a window to retina. *Med Princ Pract.* 2015;4(3):45-49.
- Kemp NJ, McElroy AB, Piercy JP, inventors; Volcano Corp, assignee. Real time SD-OCT with distributed acquisition and processing [Internet]. United States patent US 9,347,765. 2016. Available from: <https://patents.google.com/patent/US20090093980>
- Dervişoğulları MS, Totan Y, Tenlik A, Yüce A, Güler E. Effect of smoking on retina nerve fiber layer and ganglion cell-inner plexiform layer complex. *Cutan Ocul Toxicol.* 2015;34(4):282-285.
- Demirci S, Gunes A, Demirci S, Kutluhan S, Tok L, Tok O. The effect of cigarette smoking on retinal nerve fiber layer thickness in patients with migraine. *C Cutan Ocul Toxicol.* 2015(0):1-5.
- Dervişoğulları MS, Totan Y, Tenlik A, Yüce A, Güler E. Effect of smoking on retina nerve fiber layer and ganglion cell-inner plexiform layer complex. *Cutan Ocul Toxicol.* 2014;1-4.
- Nita M, Grzybowski A. Smoking and eye pathologies. A systemic review. Part I. Anterior eye segment pathologies. *Curr Pharm Des.* 2017;23(4):629-638.
- Jonas JB, Budde WM, Panda-Jonas S. Ophthalmoscopic evaluation of the optic nerve head. *Surv Ophthalmol.* 1999;43(4):293-320.

25. Yu SS, Tang X, Ho YS, Chang RC, Chiu K. Links between the brain and retina: The effects of cigarette smoking-induced age-related changes in Alzheimer's disease and macular degeneration. *Front Neurol.* 2016;7:119:1-4.
26. Demir E, Celiker M, Afacan NN, Aydogan E, Balaban GA, Erdivanli OC, *et al.* Effects of smoking on the auditory system: is there a gender difference? *Ear Nose Throat J.* 2019:1-5.
27. Pandey A, Prakash V, Pandey M. Effect of smoking in patients with ankylosing spondylitis: A cross-sectional study in state of Madhya Pradesh, India. *Apollo Med.* 2019;16(2): 70-73.
28. Feng L, Nie K, Fan W. Effects of smoking on retina in wild type and cfh+/-mice: A new model for non-exudative AMD? *Invest Ophthalmol Vis Sci.* 2020;61(7):2267.
29. Eriş E, Aydın E, Özçift SG. The effect of the smoking on choroidal thickness, central macular vascular and optic disc perfusion. *Photodiagnosis Photodyn Ther.* 2019;28:142-145.
30. Kaymaz A, Ulaş F, Toprak G, Uyar E, Çelebi S. Evaluation of the acute effects of cigarette smoking on the eye of non-smoking healthy young male subjects by optical coherence tomography angiography. *Cutan Ocul Toxicol.* 2020;39(2):165-170.
31. Dogan M, Akdogan M, Gulyesil FF, Sabaner MC, Gobeka HH. Cigarette smoking reduces deep retinal vascular density. *Clin Exp Optom.* 2020; 10.1111/cxo.13070.
32. Abdelshafy M, Abdelshafy A. Functional and structural changes of the retinal nerve fiber layer and ganglion cell complex in heavy smokers. *Clin Ophthalmol.* 2020;14: 397-404.

