



ORIGINAL ARTICLE

Toxoplasmosis epidemic in a population of urbanised allied rock-wallabies (*Petrogale assimilis*) on Magnetic Island (Yunbenun), North Queensland

RO Bowater,^{a*} B Gummow,^{a,b} T Mackie,^a AR Thompson,^c DA Hayes,^d K Goudkamp^e and JD Taylor^a

A mortality event involving 23 allied rock-wallabies (*Petrogale assimilis*) displaying neurological signs and sudden death occurred in late April to May 2021 in a suburban residential area directly adjacent to Magnetic Island National Park, on Magnetic Island (Yunbenun), North Queensland, Australia. Three allied rock-wallabies were submitted for necropsy, and in all three cases, the cause of death was disseminated toxoplasmosis. This mortality event was unusual because only a small, localised population of native wallabies inhabiting a periurban area on a tropical island in the Great Barrier Reef World Heritage Area were affected. A disease investigation determined the outbreak was likely linked to the presence of free-ranging feral and domesticated cats inhabiting the area. There were no significant deaths of other wallabies or wildlife in the same or other parts of Magnetic Island (Yunbenun) at the time of the outbreak. This is the first reported case of toxoplasmosis in allied rock-wallabies (*Petrogale assimilis*), and this investigation highlights the importance of protecting native wildlife species from an infectious and potentially fatal parasitic disease.

Keywords Macropodidae; marsupialia; pneumonia; *Toxoplasma gondii*; wallaby

Aust Vet J 2024;102:256–263

doi: 10.1111/avj.13319

Toxoplasmosis is a zoonotic, opportunistic, parasitic, protozoan disease, with a global distribution that affects humans and a diversity of terrestrial and aquatic endothermic mammals and birds.^{1–4} The disease is caused by an apicomplexan, intracellular, coccidian parasite *Toxoplasma gondii*.^{1,2} The life cycle of *T. gondii* is complex with both asexual and sexual reproductive stages.^{1,2,5} The sexual life cycle of *T. gondii* is only completed in the definitive host, members of the *Felidae* family which includes domestic and feral cats.^{1,2} The asexual life stages can occur in a variety of endothermic intermediate host species including horses, cows, pigs, sheep, goats, dogs, cats, marsupials, birds, rodents, whales, dolphins, dugongs and sea otters.^{1–19} *T. gondii* has three different infectious stages including the motile

rapidly dividing tachyzoites, the slowly dividing bradyzoites within tissue cysts and the sporozoites present in sporulated infective oocysts.^{1,2,5} The definitive feline host, and intermediate hosts including humans may become infected with *T. gondii* in various ways including ingesting infectious sporulated oocysts in contaminated soil, food or water or by ingesting tissue cysts in undercooked or raw infected shellfish, meat or poultry.^{1,2,4,6}

Epidemiologic evidence indicates that cats are essential in perpetuation of the *T. gondii* life cycle, since *T. gondii* infection is rarely documented or is absent in humans or animals residing in areas devoid of cats.^{1,2,8} A single infected feral or domestic cat can intermittently shed large numbers of oocysts via their faeces, contaminating the local environment.^{1,2,6,7} The prepatent period to infection varies in the host and depends on the type of *T. gondii* infectious stage ingested by the host, in cats ranging from three to 10 days after ingesting tissue cysts; ≥ 18 days after ingesting oocysts and ≥ 13 days after ingesting tachyzoites.^{1,2,5} Nearly all cats will shed oocysts after ingesting tissue cysts within one to 21 days. The oocysts sporulate within 1–3 weeks and then become infectious.^{1,2,5} The presumptive mode of transmission for *T. gondii* in herbivorous marsupials such as macropods is the ingestion of oocysts acquired during feeding on contaminated pastures or grasses or drinking from a contaminated water source.⁷

Australian native marsupials, in particular the Macropodidae (wallabies, kangaroos and pademelons), are highly susceptible to toxoplasmosis.^{7,9–19} Various factors may influence the susceptibility of marsupials to infection, including host immunosuppression, stress and the virulence of local *T. gondii* strain types.^{7,9–19} Fatal cases of toxoplasmosis have been documented in a wide range of marsupial taxa, including koalas (family: Phascolarctidae), tree kangaroos (family: Macropodidae), wombats (family: Vombatidae), quolls, Tasmanian devils and antechinus (family: *Dasyuridae*), bandicoots and bilbies (family: Thylacomyidae), potoroos and rat kangaroos (family: Potoroidae) and many macropod species within the Family Macropodidae, but not in allied rock-wallabies.^{7,9–19} In many cases of fatal toxoplasmosis outbreaks in captive marsupials in zoos, feral cats were reported frequenting the enclosures where the animals were housed.^{7,10,13,16,17}

Allied rock-wallabies (*Petrogale assimilis*) are listed on the IUCN Red list of Threatened species as having a stable population.²⁰ Allied rock-wallabies are nocturnal and inhabit rocky outcrops, cliffs and

*Corresponding author.

^aCollege of Public Health, Medical and Veterinary Science, James Cook University, Solander Road, Townsville, Queensland 4811, Australia; rachel.bowater@jcu.edu.au^bDepartment of Production Animal Studies, Faculty of Veterinary Science, University of Pretoria, Pretoria, South Africa^cDepartment of Primary Industries, Parks, Water and Environment, Animal Health Laboratory, 165 Westbury Road, Prospect, Launceston, Tasmania 7250, Australia^dLaunceston General Hospital, Launceston, Tasmania 7250, Australia^eNelly Bay, Magnetic Island, Queensland 4819, Australia

boulder piles during the day to rest and prevent overheating.²¹ They are generalist herbivores that emerge in the early evening to forage on native grasses, forbs, occasional seeds, leaves and fruits of *Ficus* spp.^{21,22} The mean home range of allied rock-wallabies studied on pastoral lands is 0.12 km², but the home range, diet and foraging times vary according to seasonal changes in food availability and environmental conditions.^{21–23} Threats identified to local populations of allied rock-wallabies in north-eastern Queensland include disease, predation from feral cats, foxes, dingos and native habitat destruction from intensive pastoralisation.^{20,24} Feral cats have been observed hunting, killing and eating allied rock-wallabies and their young.²⁴

Materials and methods

Disease investigation

A disease investigation was conducted on 22 July in response to multiple reports by concerned residents of Nelly Bay, Magnetic Island (Yunbenun), North Queensland, of the death of 23 allied rock-wallabies during May 2021. The investigation followed the standard disease outbreak investigation steps followed by epidemiologists investigating an epidemic and focused on establishing the cause of deaths in allied rock-wallabies.^{25,26} Interviews were conducted with five local community members living in western Nelly Bay, where the wallaby deaths occurred. Detailed information on the date, location and clinical signs shown by sick or dying allied rock-wallabies before death was recorded by local community members and was tabulated into an Excel spreadsheet. The investigation team walked through and inspected the local suburban streets and nearby bushland to identify water sources and habitats used by wallabies and for evidence of toxins, poisons or toxic plants. A case definition was developed to focus the investigation and prevent ambiguity about the problem being investigated. A case was defined as an allied rock-wallaby found dead during May 2021 and/or that showed neurological signs of disorientation and/or histopathology evidence of interstitial pneumonia, nephritis and randomly distributed multifocal necrotising lesions.

Necropsy

Three dead allied rock-wallabies were necropsied; an adult female with a joey in pouch on 15 May (Case A); a male on 26 May (Case B) and a young female on 31 May (Case C) (Table 1). All carcasses (excluding the joey that went into care but died 2 days later) were refrigerated on Magnetic Island (Yunbenun), transported on ice by ferry to James Cook University and necropsied within 24 h. No other wallabies were necropsied due to autolysis of the carcasses.

Histology

Multiple organs and tissues were sampled variously from each wallaby for histopathology including the brain, eyes, heart, lungs, liver, kidney, spleen, adrenal gland, thyroid gland, lymph nodes, tongue, oesophagus, stomach, pancreas, small and large intestine, caecum, ovary, uterus, cervix, testes, prostate, bladder, skeletal muscle and bone marrow. Organs and tissues were fixed in 10% buffered neutral formalin for 48 h, then processed routinely for histology. Paraffin-embedded tissues were sectioned at 5 µm and stained with

Table 1. Estimated date of death and state of allied rock-wallaby (*Petrogale assimilis*) carcasses found in Nelly Bay, Magnetic Island (Yunbenun), North Queensland, in May 2021

Case number	Date reported	State of Carcase	Estimated date of death
1	02 May 21	Dead, few days	30 Apr 21
2	02 May 21	Dead, few days	30 Apr 21
3	03 May 21	Fresh	03 May 21
4	03 May 21	Fresh	03 May 21
5	03 May 21	Fresh	03 May 21
6	03 May 21	Fresh	03 May 21
7	06 May 21	Dead, few days	04 May 21
8	07 May 21	Dead, few days	05 May 21
9	08 May 21	Fresh	08 May 21
10	10 May 21	Dead, few days	08 May 21
12	11 May 21	Dead, few days	09 May 21
11	11 May 21	Decomposed	06 May 21
13	12 May 21	Dead, few days	10 May 21
16	12 May 21	Dead, few days	10 May 21
15	12 May 21	Dead, few days	10 May 21
14 ^a	12 May 21	Witnessed dying	12 May 21
17	13 May 21	Fresh	13 May 21
18	14 May 21	Fresh	14 May 21
19	18 May 21	Dead, few days	16 May 21
20	20 May 21	Dead, few days	18 May 21
21	20 May 21	Dead, few days	18 May 21
22 ^b	25 May 21	Witnessed dying	25 May 21
23 ^c	31 May 21	Fresh	31 May 21

^a Case A.

^b Case B.

^c Case C.

hematoxylin and eosin before histological evaluation. Special stains done included periodic acid-Schiff (PAS).

Bacteriology

Fresh lung tissue was sampled aseptically from Case A on necropsy, processed aseptically in a Biosafety Class II cabinet (ESCO), and dilution streaked onto a variety of selective and enrichment agars using standard microbiological procedures.²⁷ Tissues were incubated for up to 7 days at 37°C both anaerobically and aerobically. Representative colonies were identified using morphological and biochemical identification protocols for the bacteria.²⁷

Immunohistochemistry

Paraffin-embedded blocks of lung tissues from all three allied rock-wallabies were submitted for *Toxoplasma gondii* immunohistochemistry to the Animal Health Laboratory, DPIPW, Launceston. Paraffin-embedded blocks were sectioned at 3 µm and floated onto Superfrost plus slides (Menzel Glaser, Braunschweig, Germany). Tissue sections were dried and deparaffinised in xylene, then rehydrated through graded alcohol to water. Endogenous peroxidase

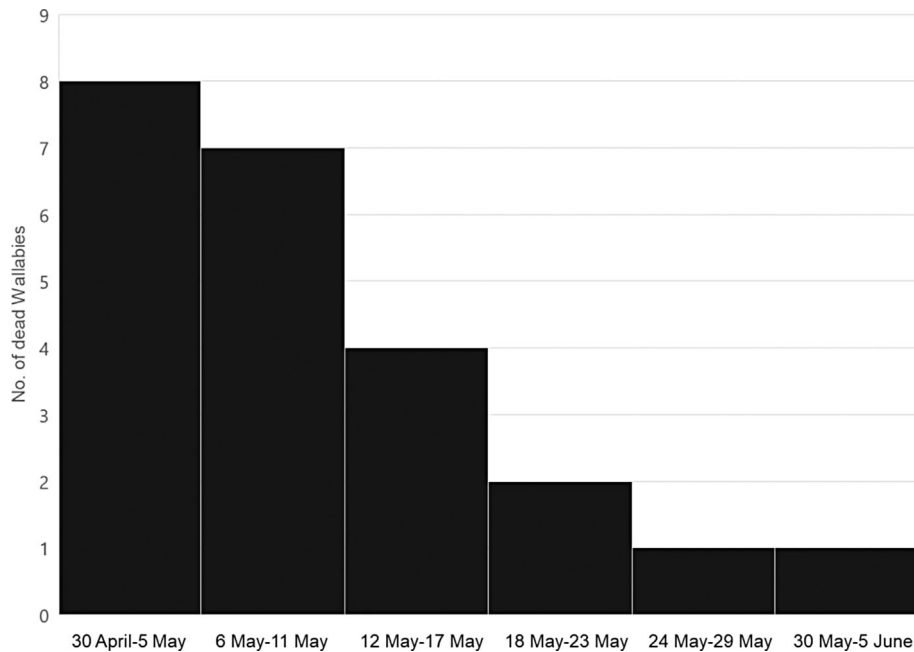


Figure 1. Frequency of deaths of allied rock-wallabies (*Petrogale assimilis*) grouped by 6-day periods in April to May 2021 from western Nelly Bay, Magnetic Island (Yunbenun), North Queensland.

activity was quenched using 3% hydrogen peroxide (Ajax Finechem, Sydney, Australia, 260) in methanol (Ajax, 723) for 30 min. Detection of antibodies was achieved using the Mach1 Universal HRP-Polymer kit (Biocare Medical, California, USA, M1U539L10) rinsing with tris buffered saline (Biocare Medical, TWB945) between all steps. A protein block was applied (Background sniper, BB966L) for 10 min, and the primary antibody was applied at room temperature for 30 min (Polyclonal Rabbit anti-*Toxoplasma gondii*, obtained from Dr J.P. Dubey, USA). Universal HRP-Polymer was applied for 30 mins. One drop of Betazoid DAB chromogen 3,3-diaminobenzidine (BDB900G) was added to 1 ml of substrate buffer (DB900) and applied to tissue sections for 4 min, slides were rinsed in RO water, stained with Mayer's haematoxylin (AHM1 Australian Biostain) for 1 min, rinsed with running tap water, blued in Scott's Tap Water for 3 min and then rinsed in running tap water. Tissue sections were then dehydrated, cleared and mounted in CV mount (Leica, 046430011). Positive controls used were brain tissue sections confirmed positive to *T. gondii* infection obtained from JP Dubey with added primary antibody as previously outlined above. Negative controls were the same sections but with omission of the primary antibody and substitution with buffer solution. All sections were viewed under light microscopy using an

Olympus BX41 microscope (Tokyo, Japan) and selected areas were photographed using an Olympus digital camera (DP20).

Results

Epidemiology

During the period of 2 May until 31 May, a total of 23 allied rock-wallaby deaths were recorded in western Nelly Bay, Magnetic Island (Yunbenun) (Table 1). All dead wallabies were found along one crescent with an exception of one wallaby found in a different street, but all were found within a 500 m radius. Allied rock-wallabies *Petrogale assimilis* were the only species reported affected during the outbreak. Wallaby carcasses were classified as freshly dead, dead for a few days, or decomposed, based on the level of decomposition observed by the local residents (Table 1). Most dead wallabies were found on the front or back lawns of residential properties or adjacent bushland of Magnetic Island National Park. Although no records of gender were kept, clarification of the information collected by community members and necropsies established that males and female of all age classes were affected.

The colony of allied rock-wallabies in western Nelly Bay was estimated by local ecologists to be around 30 before the disease outbreak, which would suggest the estimated mortality rate was

Table 2. Three allied rock-wallabies (*Petrogale assimilis*) necropsied from Nelly Bay, Magnetic Island (Yunbenun), North Queensland, Australia, in May 2021

Case	Date	Sex	Weight (kg)	Clinical signs
A	15 May	Female, adult, pouch young	4.2	Neurological
B	26 May	Male, adult	4.2	Neurological
C	31 May	Female, juvenile	1.7	Sudden death

approximately 77% (23/30). During May, only three wallabies were observed exhibiting clinical symptoms before death, giving a morbidity rate of only 10% (3/30). The case fatality rate thus appeared to be very high.

Temporal pattern of deaths. The deaths over the period of the outbreak, when regrouped into 6-day periods, showed a sharp rise in deaths within the first 6-day period of the outbreak, followed by a plateau for another 6 days and then a decline (Figure 1). This temporal pattern of deaths conformed to a point source epidemic. It was postulated the common source to be within 4 km of the urban streets where deaths occurred.

Behaviour and feeding patterns. The local colony of allied rock wallabies was considered “urbanised” because of their observed feeding behaviours and adaptation to human presence. Small groups of one to five allied rock wallabies were observed daily departing their natural habitat of rocky outcrops in the surrounding National Park in the early evenings, following a common pathway through the bush behind residents’ properties, towards their common feeding grounds largely consisting of grassed lawns at the front or back of properties, gardens or native grasses in local bushland. Allied rock wallabies were observed grazing mainly on urban grassy lawns down to the bare earth during dry periods. Allied rock wallabies were frequently observed drinking from backyard ponds and fountains in the dry season and from the flowing tributaries of the local creek

following rainfall in late April 2021. Before the disease outbreak, the creek was stagnant in March and most of April. A late wet season rain event saw the tributaries flowing for a period of 24–36 h and then reduced to only one main stagnant pool, that also received water occasionally from a domestic sprinkler system. A feral cat and free-roaming domestic cats were also observed by local residents to inhabit the same urban streets of western Nelly Bay and nearby National Park where wallabies resided and were feeding. One long-term resident reported that there has been a feral cat and semistray cat problem on Magnetic Island (Yunbenun) for at least 21 years, with cats observed at many locations and congregating at the landfill site in Picnic Bay located on the other side of the hill from where the colony of allied rock wallabies inhabited.

Clinical signs

Three allied rock wallabies were observed showing neurological signs including ataxia, disorientation, “apparent” blindness, before dying and necropsy (Cases A and B, Table 2). Two allied rock wallabies were reported with what was assumed to be impaired vision, running into objects or trees, before dying (Case A and another allied rock wallaby not necropsied). Case B was observed for a few days before dying with neurological signs including disoriented movements hopping in a strange way across a resident’s backyard, trying to climb up a mango tree, then reportedly “falling out of the tree”, moving between two parked cars, lying down, then standing up suddenly, before lying down and dying.

Gross pathology

Three allied rock wallabies necropsied had variable body condition ranging from poor to fair, all with bony prominences, and with minimal subcutaneous and abdominal fat reserves. All three wallabies had ectoparasites, each with five to 10 ticks on the inner ears and body identified as *Haemaphysalis bancrofti*, and a few lice (unidentified).

Postmortem examination of all three wallabies showed consistent gross lesions of the lungs, that were wet and heavy, aerated, failed to collapse and were mottled pink to red in colour (Figure 2). There were multifocal, randomly scattered, poorly defined, round to oval white foci, ranging in size from 1 to 2 mm in diameter throughout all lung lobes (Figure 2). The mesenteric lymph nodes were grossly enlarged in all three wallabies. One wallaby had yellow-tinged mesenteric fat (Case A), and one had coning of the cerebellum (Case B). The stomachs contents of all three wallabies consisted of macerated grasses with low to moderate numbers of coiled nematodes. One wallaby (Case A) had erythema of the pyloric gastric mucosa, and one wallaby (Case B) had a very small amount of cracked grain in the stomach. All three wallabies had well-formed faecal pellets in the colon and rectum.

Histopathology, immunohistochemistry and bacteriology

Protozoal cysts, bradyzoites and tachyzoites resembling those of *Toxoplasma gondii* were detected in multiple organs and tissues from histological examination of tissue sections stained with haematoxylin and eosin in all three allied rock wallabies (Table 3, Figure 3). Tissue cysts, bradyzoites or tachyzoites stained positive with PAS. Tissue cysts of *T. gondii* are indistinguishable from *Neosporium caninum* cysts by histopathology alone, but together with bradyzoites

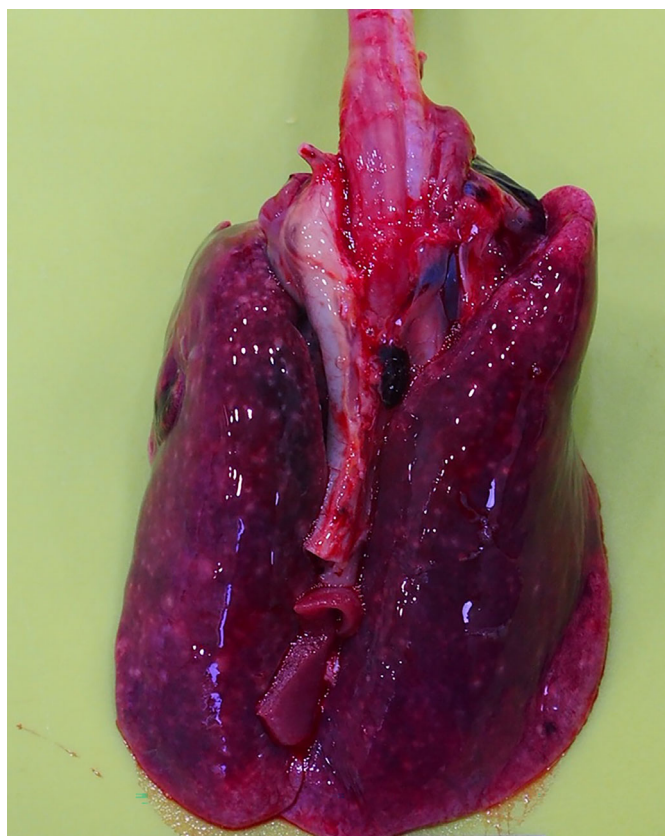

Figure 2. Lungs from an allied rock-wallaby (*Petrogale assimilis*) with severe, diffuse pulmonary congestion.

Table 3. Summary of histopathology from three allied rock-wallabies (*Petrogale assimilis*) infected with toxoplasmosis from Nelly Bay, Magnetic Island (Yunbenun), North Queensland, Australia.

Tissue ^a	Histopathology lesions ^b	Distribution	Severity	<i>T. gondii</i> cysts	Tachyzoites bradyzoites
Lung ^c	Interstitial pneumonia L, P, H	Diffuse	Severe	+	+
Heart	Myocarditis	MF	Moderate	+	+
Brain	Encephalitis	MF	Moderate	+	+
Eye	Keratoconjunctivitis L, P, H	MF	Mild	+	+
Liver	Cholangiohepatitis N, L	MF	Moderate	+	+
Spleen	Splenitis, N	MF to Co	Moderate	+	+
Kidney	Nephritis, ha, L	MF	Mild	+	–
Adrenal gland	Adrenitis, N, ha, L, H	MF	Mild–moderate	+	+
Thyroid gland (A, C)	Thyroiditis, N, L, ha	MF	Moderate	+	+
Thymus (B, C)	NAD	–	–	–	–
Bladder (A)	NAD	–	–	–	–
Gastrointestinal tract	Gastritis, E	Diffuse	Mild	–	+
Pancreas	Pancreatitis	MF	Mild	+	+
Skeletal muscle	Myositis, N	MF	Moderate	+	–
Mesenteric lymph nodes	Lymphadenitis F, N, ha	F to MF	Moderate to marked	+	+
Paracloacal gland (A)	NAD	–	–	–	–
Testis (B)	NAD	–	–	–	–

^a Tissues were examined from all three wallabies unless otherwise specified (cases for which tissues were only examined are in brackets).

^b Histological lesions detected.

^c Lungs positive by immunohistochemistry for *T. gondii* antigens.

Co, Coalescing; E, eosinophilic; H, histiocytic; Ha, haemorrhagic; L, lymphocytic; MF, multifocal; N, necrotising; NAD, no abnormalities detected; P, plasmocytic; +, detected; – not detected.

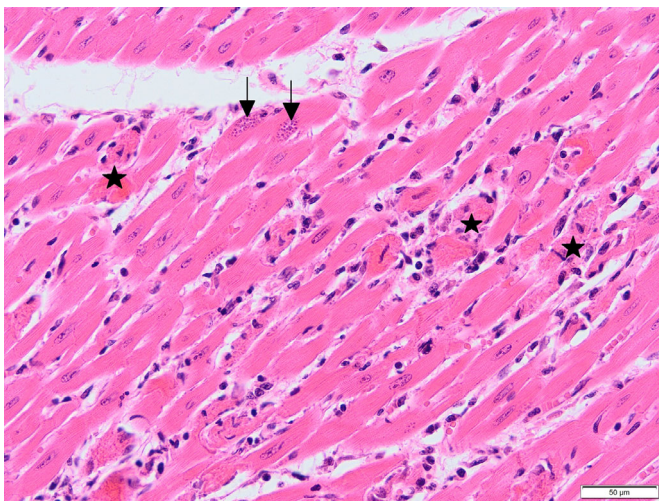


Figure 3. Photomicrograph showing *Toxoplasma gondii* tissue cysts in the myocardium (arrows) with myonecrosis (star) and a mild mixed inflammatory response in an allied rock-wallaby (*Petrogale assimilis*). H&E stain. Scalebar, 50 µm.

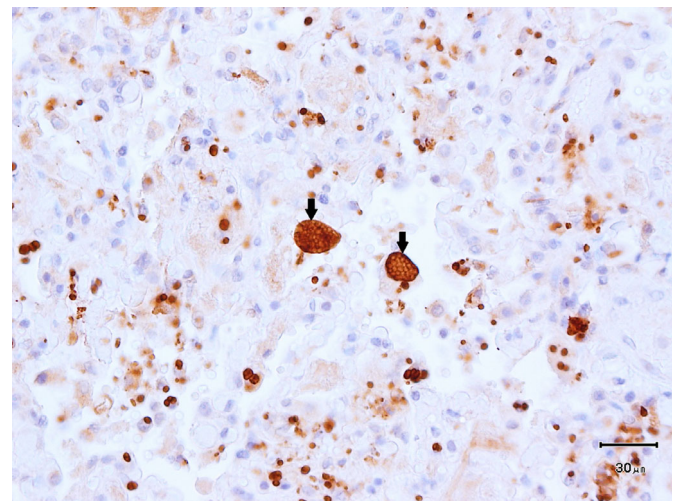


Figure 4. Numerous *Toxoplasma gondii* cysts (arrows) in lung parenchyma of an allied rock-wallaby (*Petrogale assimilis*). Peroxidase labelling, formalin-fixed paraffin-embedded, polyclonal rabbit anti-*T. gondii*. Scalebar, 30 µm.

and tachyzoites, were positively identified as *T. gondii* by immunohistochemistry done on selected lung tissues from all three cases (Table 3, Figure 4). There were randomly scattered small foci of multifocal necrosis with a mild predominantly mononuclear cell infiltrate associated with the presence of *T. gondii* cysts, bradyzoites or tachyzoites (Table 3, Figure 3).

All three wallabies had a diffuse interstitial pneumonia characterised by alveolar thickening and congestion and with a mixed inflammatory cell infiltrate dominated by mononuclear cells. The inflammatory infiltrate extended into alveolar spaces, with areas of fibrin exudation and type II pneumocyte proliferation. There were larger numbers of tissue cysts,

bradyzoites and tachyzoites detected in the lungs of cases A and B and fewer cysts bradyzoites and tachyzoites in case C. All three wallabies had a nonsuppurative encephalitis with astrocytosis and gliosis in the cerebrum and cerebellum associated with randomly scattered tachyzoites, tissue cysts with rare perivascular cuffing. Intranuclear inclusion bodies were also detected by light microscopy in the kidney proximal tubule epithelial cells of all three wallabies but were not associated with *T. gondii* cysts or with inflammation.

No aerobic or anaerobic bacteria were cultured from the heart, lungs or kidneys, and PCR was negative for *Chlamydia* species.

Discussion

The cause of death of the allied rock-wallabies was determined as toxoplasmosis based on clinical signs, gross pathology, histopathology and immunohistochemistry specific for *T. gondii* antigens. The disease investigation established that allied rock-wallabies died acutely after showing neurological signs of disorientation and had histopathological evidence of disseminated toxoplasmosis. The pathology lesions observed in the allied rock-wallabies were similar to those lesions previously described in other marsupials infected with *T. gondii*. Numerous *T. gondii* tachyzoites and bradyzoites were disseminated throughout the brain, heart, lungs, liver, spleen, kidneys, adrenal glands, mesenteric and bronchial lymph nodes, and skeletal muscle in association with multifocal, necrotising lesions.^{7,18,28–30} There was no pathology indicative of an intoxication as was initially suspected by local residents. The intranuclear inclusion bodies in the kidney proximal tubule epithelial cells were unrelated to *T. gondii* infection and have previously described in healthy macropods as incidental findings.³¹

Australian marsupials infected with toxoplasmosis can manifest with a range of clinical signs including diarrhoea, dyspnoea, coughing, blindness, ataxia disorientation, incoordination or other neurological signs, lymphadenopathy, pyrexia, anorexia and sudden death.^{7,9–18,28–30} In acute infections, *T. gondii* infective stages replicate in cells in various organs and tissues, including the brain, heart, lungs, liver, kidney, spleen, pancreas, adrenal gland, lymph nodes and skeletal muscle. The process of replication of the bradyzoites in multiple organs and tissues, with the subsequent release of tachyzoites, causes localised and widespread tissue necrosis, resulting in disseminated toxoplasmosis that can be fatal.^{1,2,5,10,29} In this case, the dying wallabies seen by residents displayed neurological symptoms including ataxia, disorientation, unusual behaviour and prostration similar to clinical signs shown by other acutely infected marsupials where *T. gondii* has disseminated to the central nervous system.^{1,2,7,9,10,13–18,28–30} The clinical signs vary, depending on the hosts' immune factors, the location of tissue cysts and other infective stages, the course of the infection and the *T. gondii* strain type.^{7,14–18}

This outbreak was unusual because only a small population of allied rock-wallabies in a periurban environment were affected, despite other populations of allied rock-wallabies and agile wallabies residing in other nearby urban areas of Nelly Bay, Magnetic Island (Yunbenun) and in the wider ranges of Magnetic Island National Park. There were no significant deaths of other wildlife in the local area or elsewhere on Magnetic Island (Yunbenun) during the disease

outbreak or after it subsided, despite the known susceptibility of macropods and other marsupials to *T. gondii*.⁷ It is unknown why the allied rock-wallabies were susceptible to toxoplasmosis, but host immunosuppression, stress, and virulence factors of different *T. gondii* strain types have been postulated to influence the susceptibility of Australian marsupials to infection with *T. gondii*.^{7,13–18} Canfield (1990) proposed that evolution, genetics and ecology may play a role in the susceptibility of Australian native marsupials to *T. gondii* infection, since cats were not present in Australia before European settlement, over 254 years ago. This seems a plausible hypothesis, since Australian native fauna may have insufficient exposure time to *T. gondii*, within the evolutionary time scale, to evolve natural immunity against *T. gondii*.²⁸ It is also possible a highly virulent strain of *T. gondii* infected the wallabies although strain type was not elucidated from this study.

The epidemiological findings from this disease investigation supported the pathology findings of toxoplasmosis caused by the apicomplexan protozoan parasite *T. gondii*. The allied rock-wallabies appeared highly susceptible to *T. gondii* infection, with 23 rock-wallabies dying over a period of 32 days. The case fatality rate was high, suggesting a highly virulent disease was the cause of death, with all age classes affected. The disease outbreak was localised to a small suburban area of western Nelly Bay, which supports a hypothesis of a common point source of infection occurring within 4 km of where all wallaby deaths occurred. This area is also within the mean home range of foraging for allied rock-wallabies.²³ The temporal epidemic pattern also suggested a common point source and that the disease was unlikely to have been infectious and spread by direct contact between wallabies as there was no build-up of cases typical of a propagating epidemic pattern. The known susceptibility of wallabies to *T. gondii* would explain the high case fatality rate. The most likely source for the *T. gondii* is a shedding cat. Previous studies have shown that oocysts shed from an infected feral or domestic cat are the main source of infection for herbivorous, ground-dwelling marsupials such as wallabies and kangaroos.^{9–19} Epidemiologic evidence from other studies support that cats are essential in perpetuation of the *T. gondii* life cycle, since *T. gondii* infection is rare or absent in areas devoid of cats.^{2,8} Environmental contamination with *T. gondii* oocysts from excreta of infected domestic or feral cats was therefore suspected as the main source of infection for the herbivorous, ground-dwelling allied rock-wallabies.

Typical common sources where multiple wallabies could have been exposed at the same time in this study included a contaminated common food source used by the wallabies, such as the grassed lawns in the local urban area or a contaminated water source such as the stagnant water pool in the area. Of note was that all three necropsied wallabies contained macerated lawn grasses making up the bulk of their stomach contents. Although the exact source of *T. gondii* could not be identified from our study, felids were identified as potentially contributing to environmental loading of oocysts in the urban area of western Nelly Bay where the toxoplasmosis outbreak occurred. There were multiple, domestic, free-ranging cats owned by local residents in the local area and feral cats were observed in the neighbourhood leading up to the mortality event. One domestic cat was identified by residents as living in close proximity to the mortality event and was seen roaming night and day.

A couple of weeks before the mortality event the cat went missing and returned home several days later.

The presence of feral and domestic cats, the only known definitive host for the parasite *T. gondii*, on Magnetic Island (Yunbenun), of which 78% is National Park, is of concern as many wildlife and bird species inhabit the island, including several marsupials at risk of infection.^{7,32} Marsupials species are known to be highly susceptible to toxoplasmosis and those at particular risk of *T. gondii* infection on Magnetic Island include a closed population of 800 koalas (*Phascolarctos cinereus*) listed as “vulnerable to extinction” under the IUCN Red List of threatened species 2023, the northern quoll (*Dasyurus hallucatus*) listed as “endangered”, agile wallabies (*Notamacropus agilis*), short-beaked echidnas (*Tachyglossus aculeatus*), brushtail possums (*Trichosurus vulpecula*) and many species of native rodents.^{7,20,32} A single infected cat may shed billions of infective *T. gondii* oocysts in their faeces into the local environment, contaminating lawns, creeks, water reservoirs, soil, gardens, school playgrounds, parks, sandpits, oceanic waters or anywhere where cats routinely defecate.^{1,2,6,7,25–27} *T. gondii* oocysts are environmentally resistant in tropical island climates and can remain viable for up to 24 months, surviving well in irrigated grassed lawns, soils, community parklands and in warm freshwater and oceanic tropical waters.^{1,2,7,25–27}

The OIE estimates approximately 30% of the global human population are currently asymptotically infected with *T. gondii* with clinical illness uncommon but with symptoms that may mimic other illnesses such as the flu, Lyme disease, Q fever or mumps.^{1,33–38} After the outbreak of toxoplasmosis in allied rock-wallabies, a woman living on Magnetic Island (Yunbenun) became ill and tested seropositive for *T. gondii* with an abnormally high titre. The woman reported clinical symptoms of chronic fatigue, lymphadenopathy, myalgia and headaches for several months before a medical diagnosis was made (*anonymous, personal communication*). It is unknown where the woman contracted toxoplasmosis, but it raised concerns among residents regarding the zoonotic risk of toxoplasmosis to humans. Given the human population on Magnetic Island (Yunbenun) is around 2540 with women of reproductive age and >60% of the population over 50 years old, this was of concern since pregnant women, the elderly and immune compromised persons are at increased risk of serious medical complications after zoonotic infection with *T. gondii*.^{1,2,33–38}

During the disease investigation, the Magnetic Island (Yunbenun) community expressed considerable concerns regarding the risk of potential infection of domestic animals or humans with *T. gondii*. Owners of domestic animals were encouraged to comply with local council animal laws, by confining domestic dogs and cats indoors or to their yards to minimise hunting or scavenging of infected live or dead wallaby carcasses potentially containing infective *T. gondii* tissue cysts and to reduce the risk of ingestion of environmental material potentially contaminated with *T. gondii* oocysts in the local area where the disease outbreak occurred. Feeding of raw kangaroo meat or offal to domestic cats was also discouraged since this practice is an identified risk factor for acquiring *T. gondii* infection in domestic cats in Australia.³⁹ The community group were advised to reduce the risk of human exposure to *T. gondii* by following the current Queensland Public Health guidelines for *T. gondii* and the OIE

recommendations.^{1,38} The local community was encouraged to report all sightings of feral or wandering domestic cats to their local Council. Prompt removal of feral cats and the control of wandering domestic cats on Magnetic Island (Yunbenun) is likely to minimise the potential spread of *T. gondii*, reducing the risk of future outbreaks in the local wildlife populations, domestic animals on the island or zoonotic parasitic transmission to humans.

Acknowledgments

Wildlife Health Australia Incorporated are gratefully acknowledged for providing funding for the scientific testing for this disease investigation. We acknowledge the Wulgarukaba people, the traditional owners of Yunbenun (Magnetic Island). We are grateful to the local community members of Magnetic Island (Yunbenun) for alerting us to this unusual wildlife mortality event. Special thanks to Veterinarian Dr Ali Bee, Mr Peter Illidge and Mrs Darrie Lisle for submitting dead wallabies for necropsy, despite logistical challenges in transporting chilled carcasses by ferry from Magnetic Island (Yunbenun) to the mainland. Veterinary microbiologist Dr Jackie Picard and Jasmin Mehonoshen are thanked for microbiology and Dr Con Constantinou is thanked for identifying ticks. We acknowledge the scientific technical assistance of Yissu Martinez, Walter Hautaniemi, Erin Roberts, Jemma Green, Jasmin Mehonoshen, Karen Reeks and Martin Kildey of James Cook University, School of Veterinary Sciences, Veterinary Diagnostic Pathology Services. Local residents of Magnetic Island (Yunbenun) Dr Sue Hill, Mr Gethin Morgan, Mr Peter Illidge and Mrs Darrie Lisle are thanked for providing information from interviews that was relevant to the disease outbreak. Information gathered from further interviews with other local community members and the Department of Environment and Science assisted us by providing additional valuable information during the disease investigation and we thank them for their contributions. Open access publishing facilitated by James Cook University, as part of the Wiley - James Cook University agreement via the Council of Australian University Librarians.

Conflict of interest and sources of funding

The authors declare no conflicts of interest or sources of funding for the work presented here.

References

- OIE. *Toxoplasma gondii*. 2023. <https://www.woah.org/app/uploads/2022/02/toxoplasma-gondii-infection-with.pdf>.
- Dubey JP, Beattie CP. *Toxoplasmosis of animals and man*. Boca Raton, CRC Press, Inc, 1988.
- Bowater RO, Norton J, Johnson S et al. Toxoplasmosis in indo-Pacific hump-backed dolphins (*Sousa chinensis*), from Queensland. *Aust Vet J* 2003;10: 627–632.
- Dubey JP. Toxoplasmosis - a waterborne zoonosis. *Vet Parasitol* 2004;126: 57–72.
- Dubey JP, Lindsay DS, Speer CA. Structures of *Toxoplasma gondii* tachyzoites, bradyzoites, and sporozoites and biology and development of tissue cysts. *Clin Microbiol Rev* 1998;11(2):267–299.
- López Ureña NM, Chaudhry U, Calero Bernal R et al. Contamination of soil, water, fresh produce, and bivalve mollusks with *Toxoplasma gondii* oocysts: a systematic review. *Microorganisms* 2022;10(3):517.

7. Dubey JP, Murata FH, Cerqueira-Cézar CK et al. Recent aspects on epidemiology, clinical disease, and genetic diversity of *Toxoplasma gondii* infections in Australasian marsupials. *Parasit Vector* 2021;14(1):1–8.
8. Dubey JP, Rollor EA, Smith K et al. Low seroprevalence of *Toxoplasma gondii* in feral pigs from a remote island lacking cats. *J Parasitol* 1997;83(5):839–841.
9. Attwood HD, Woolley PA, Rickard MD. Toxoplasmosis in dasyurid marsupials. *J Wildl Dis* 1975;11(4):543–551.
10. Jensen JM, Patton S, Wright BG et al. Toxoplasmosis in marsupials in a zoological collection. *J Zoo Anim Med* 1985;16(4):129–131.
11. Speare R, Donovan JA, Thomas AD. Kangaroos, Wallabies and Rat-Kangaroos. In: Grigg G, Jarman P, Hume I, editors. *Diseases of free-ranging Macropodidae*. Surry Beattie and Sons, Sydney, 1989;705–734.
12. Obendorf DL, Munday BL. Toxoplasmosis in wild eastern barred bandicoots, *Perameles gunnii*. In: Seebeck JH, Brown PR, Wallis RL, Kempe CM, editors. *Bandicoots and bilbies*. Surrey Beatty and Sons, Sydney, 1990;193–197.
13. Portas TJ. Toxoplasmosis in macropodids: a review. *J Zoo Wildl Med* 2010;41(1):1–6.
14. Parameswaran N, Thompson RCA, Sundar N et al. Non-archetypal type II-like and atypical strains of *Toxoplasma gondii* infecting marsupials of Australia. *Int J Parasitol* 2010;40(6):635–640.
15. Pan S, Thompson RA, Grigg ME et al. Western Australian marsupials are multiply infected with genetically diverse strains of *Toxoplasma gondii*. *PLoS ONE* 2012;7:e45147.
16. Guthrie A, Rooker L, Tan R et al. Newly described *Toxoplasma gondii* strain causes high mortality in red necked wallabies (*Macropus rufogriseus*) in a zoo. *J Zoo Wildl Med* 2017;48(3):694–702.
17. Spriggs M, Jiang T, Gerhold R et al. Genotype identification of *Toxoplasma gondii* in macropods from a zoological park in Florida, USA. *J Zoo Wildl Med* 2020;51(1):131–139.
18. Carossino M, Bauer R, Mitchell MA et al. Pathologic and immunohistochemical findings in an outbreak of systemic toxoplasmosis in a mob of red kangaroos. *J Vet Diagn Invest* 2021;33(3):554–565.
19. Fancourt BA, Nicol SC, Hawkins CE et al. Beyond the disease: is *Toxoplasma gondii* infection causing population declines in the eastern quoll (*Dasyurus viverrinus*)? *Int J Parasitol* 2014;3:102–112.
20. IUCN. The IUCN red list of threatened species. Version 2023-1. 2023. <https://www.iucnredlist.org>.
21. Horsup AB. The Behavioural ecology of the allied rock-wallaby, *Petrogale assimilis*. PhD Thesis, James Cook University, Townsville 1996.
22. Horsup A, Marsh H. The diet of the allied rock-wallaby, *Petrogale assimilis*, in the wet-dry tropics. *Wildlife Res* 1992;19:17–33.
23. Horsup A. Home range of the allied rock-wallaby, *Petrogale assimilis*. *Wildl Res* 1994;21:65–84.
24. Spencer P. Evidence of direct predation by a feral cat on an isolated rock-wallaby colony in tropical Queensland. *Aust Mammal* 1990;14:143–144.
25. Schwabe CW, Riemann H, Franti C. *Epidemiology in veterinary practice*. Philadelphia, Lea and Febiger, 1977.
26. Robinson B, Gummow B. A field investigation into a suspected outbreak of pyrrolizidine alkaloid toxicosis in horses in western Queensland. *Prev Vet Med* 2015;118:378–386.
27. Markey BK, Leonard FC, Archambault M et al. *Clinical veterinary microbiology*. 2nd edition. London, Elsevier Press, 2013. ISBN: 9780723432 371.
28. Canfield PJ, Hartley WJ, Dubey JP. Lesions of toxoplasmosis in Australian marsupials. *J Comp Pathol* 1990;103(2):159–167.
29. Bettiol SS, Obendorf DL, Nowarkowski M et al. Pathology of experimental toxoplasmosis in eastern barred bandicoots in Tasmania. *J Wildlife Dis* 2000;36(1):141–144.
30. Ladds P. Protozoal diseases in terrestrial mammals. In: De Kretser A, editor. *Pathology of Australian native wildlife*. CSIRO Publishing, Collingwood, 2009; 197–206.
31. Speare R, Donovan JA, Skerratt LF et al. Idiopathic intranuclear inclusion bodies in the renal epithelium of macropods. *Aust Vet J* 1997;75(6):446–447.
32. Department of Environment and Science, Queensland. Wildlife of Magnetic Island National Park. 2013. Wetland Info website, Available at: <https://wetlandinfo.des.qld.gov.au/wetlands/facts-maps/wildlife/?ArealD=national-park-magnetic-island> Accessed 21 December 2023.
33. Dubey JP. Outbreaks of clinical toxoplasmosis in humans: five decades of personal experience, perspectives and lessons learned. *Parasites Vect* 2021;14:263–275.
34. Dubey JP, Murata FH, Cerqueira-Cézar CK et al. Epidemiologic and public health significance of *Toxoplasma gondii* infections in venison: 2009–2020. *J Parasitol* 2021;107(2):309–319.
35. Torrey EF, Yolken RH. Toxoplasma oocysts as a public health problem. *Trends Parasitol* 2013;29(8):380–384.
36. Bowie WR, King AS, Werker DH et al. Outbreak of toxoplasmosis associated with municipal drinking water. *Lancet* 1997;350:173–177.
37. Ben-Harari RR, Connolly MP. High burden and low awareness of toxoplasmosis in the United States. *Postgrad Med* 2019;131(2):103–108.
38. Toxoplasmosis Fact Sheet Australia: Queensland Government, Queensland Health. Communicable disease control guidance website. Available at: <https://www.health.qld.gov.au/disease-control/conditions/toxoplasmosis>. Accessed 20 June 2023.
39. Brennan A, Hawley J, Dhand N et al. Seroprevalence and risk factors for *Toxoplasma gondii* infection in owned domestic cats in Australia. *Vector-Borne Zoonot Dis* 2020;20(4):275–280.

(Accepted for publication 21 January 2024)