
Electronic Thesis and Dissertation Repository

9-29-2014 12:00 AM

The Effect of Fixation Plate Length on Spinal Instability Following Anterior Cervical Plate Fixation for the Repair of in Vitro Flexion-Distraktion Injuries

Abdulaziz J. Al-Kuwari
The University of Western Ontario

Supervisor
Chris bailey
The University of Western Ontario

Graduate Program in Surgery
A thesis submitted in partial fulfillment of the requirements for the degree in Master of Science
© Abdulaziz J. Al-Kuwari 2014

Follow this and additional works at: <https://ir.lib.uwo.ca/etd>



Part of the [Biomechanics and Biotransport Commons](#), [Dynamics and Dynamical Systems Commons](#), [Medical Anatomy Commons](#), and the [Orthopedics Commons](#)

Recommended Citation

Al-Kuwari, Abdulaziz J., "The Effect of Fixation Plate Length on Spinal Instability Following Anterior Cervical Plate Fixation for the Repair of in Vitro Flexion-Distraktion Injuries" (2014). *Electronic Thesis and Dissertation Repository*. 2549.
<https://ir.lib.uwo.ca/etd/2549>

This Dissertation/Thesis is brought to you for free and open access by Scholarship@Western. It has been accepted for inclusion in Electronic Thesis and Dissertation Repository by an authorized administrator of Scholarship@Western. For more information, please contact wlsadmin@uwo.ca.

The Effect of Fixation Plate Length on Spinal Instability Following Anterior Cervical Plate Fixation for the Repair of in Vitro Flexion-Distractive Injuries

(Thesis format: Integrated Article)

by

Dr. Abdulaziz Alkuwari

Supervisors: Dr. Christopher Bailey and Dr. Cynthia Dunning

Laboratory: Jack McBain Biomechanical Testing Laboratory, Thompson Engineering Building, Western University, London, Ont., Canada.

A thesis submitted in partial fulfillment
of the requirements for the degree of
Masters of Surgery

The School of Graduate and Postdoctoral Studies
The University of Western Ontario
London, Ontario, Canada

© Abdulaziz Al-kuwari 2014

Abstract:

The Effect of Fixation Plate Length on Spinal Instability Following Anterior Cervical Plate Fixation for the Repair of *in Vitro* Flexion-Distracton Injuries

Introduction: Anterior cervical decompression and fusion with a plate (ACDFP) is a commonly performed treatment following a traumatic injury to the subaxial cervical spine. The purpose of the presented work was to determine the biomechanical effect of plate length on cervical spine kinematic stability following ACDFP stabilization for a simulated traumatic injury.

Methods: Eleven fresh-frozen cadaveric C5-C6 and C6-C7 motion segments were examined in this study. To assess kinematics, flexibility testing was performed on each specimen using a spinal loading simulator. A testing protocol was designed to assess the kinematics of the following conditions: i) preinjury, ii) simulated soft tissue injury (both facet capsules, 1/2 of the ligamentum flavum, and 2/3 of the annulus were sectioned along with an induced rotation to a unilateral facet perch), iii) ACDFP with 22.5mm plate fixation, and iv) ACDFP with 32.5mm fixation. Kinematic range of motion (ROM) data was collected and analyzed for motions of flexion-extension, axial rotation, and lateral bending.

Results: The injury produced significantly greater motion than the pre-injury state; with the greatest increase in motion occurring for axial rotation. Both plates were successful in significantly reducing the ROM (for all motion types) below the injured condition and there were no significant differences in the change in ROM between the two plate sizes. Furthermore, in flexion-extension, both plates also significantly reduced the ROM below that of the intact condition.

Discussion and Conclusions: The results would suggest that the simulated injury was successful in generating spinal instability consistent with the intended injury. The position of the plate in the frontal plane is responsible for impeding the flexion-extension ROM below the motions experienced by the intact condition. Finally, there were no differences between plate sizes for any of the measured motions. Therefore, we advise the use of smallest plates suitable to avoid the theoretical risk of adjacent level degeneration.

Keywords: Cervical spine; facet joint; soft tissue injury; spinal instrumentation; biomechanics; kinematics; anterior cervical fusion.

Co-Authorship Statement

The *in vitro* experiment performed in this thesis required a multi-disciplinary team with both surgical and engineering expertise. The individual contributions are listed:

- Chapter 1: Abdulaziz Alkuwari – sole author.
- Chapter 2: Abdulaziz Alkuwari– study design, data collection, data analysis, wrote manuscript; Stewart McLachlin – study design, data collection, data analysis, reviewed manuscript; Parham Rasoulinejad – study design, performed surgeries, data collection; Christopher Bailey – study design, reviewed manuscript; Cynthia Dunning – study design, reviewed manuscript. Timothy Burkhart – data collection, data analysis, reviewed manuscript
- Chapter 3: Abdulaziz Alkuwari – sole author.

ACKNOWLEDGMENTS

My sincerest thanks must first go to Prof. Abdulrahman Lawendy the person who believed in me when we met 5 years ago in Qatar, When I was a junior orthopaedic surgery resident he gave me invaluable guidance to my career and provided me with an amazing supervision through my masters.

A second massive thanks to my great teacher, supervisor and mentor Dr. Chris Bailey who not only supervised this academic work, but also has been a great friend who supported me in every possible way during my two years of fellowship in Canada and throughout my masters year. He taught me that no matter how complicated or difficult the situation is it can be solved with a big smile.

Another huge thanks goes to my colleague Dr Parham Rasoulinejad, who not only contributed in this project, but he taught me more important things in life than work. finally huge token of appreciation goes to Dr Stewart Maclachlin, Dr Timothy Burkhart and Dr Cynthia Dunning whom without their wonderful dedication and great experience in biomechanical engineering this project wouldn't come to life.

DEDICATION

To the love of my life my wife Buthina al-shareef whom without her continuous support I wouldn't have been able to achieve my goals.

To my parents whom they taught me the importance of knowledge and how to sail through challenges.

To my life Mentor and my older brother Dr Alateeq.

Table of Contents

Co-Authorship Statement	III
Acknowledgments	IV
Dedication	V
Abbreviations, Symbols, and Nomenclature.....	VIII
1 Chapter 1: Introduction	1
1.1 Anatomy of the Cervical Spine	1
1.1.1 Osseous anatomy	1
1.1.2 Articulating Joints of the Cervical Spine	3
1.1.3 Soft tissues.....	5
1.2 Cervical spine instability:.....	6
1.3 Cervical spine trauma fracture classification and Surgical Treatment	7
1.3.1 Classification of subaxial traumatic injuries	7
1.4 Treatment Options.....	10
1.4.1 Conservative Treatment	10
1.4.2 Surgical Treatment.....	11
1.5 Cervical Biomechanical Studies	21
1.6 Thesis Rationale	24
1.6.1 Objectives and Hypotheses.....	25
1.7 references	26
2 chapter 2:.....	35
2.1 Introduction	35
2.2 Methods	36
2.3 Results.....	40
2.4 Discussion	41
2.5 References	44
3 CHAPTER 3:	46
3.1 General discussion:.....	46
3.2 Limitations	50
3.3 Conclusion:	50
3.4 Future directions:	51
3.5 References:.....	51
4 Appendix A Glossary	54
5 Appendix B Raw Data from the experiments.....	56
Curriculum Vitae	58

List of tables

Table 1 AXIAL ROTATION ROM..... 57
Table 2 FLEXION EXTENSION ROM..... 57
Table 3 LATERAL BENDING ROM..... 57

List of figures

Figure 1 Bony Anatomy of the subaxial cervical vertebrae..... 2
Figure 2 Articulating Joints of the Cervical spine 3
Figure 3 Cervical Facet Joint Anatomy..... 4
Figure 4 Neck Range of Motion..... 4
Figure 5 Ligamentous Anatomy 6
Figure 6 Injury Mechanism..... 10
Figure 7 External Immobilization 11
Figure 8 TYPE OF SURGICAL FIXATION..... 13
Figure 9 Different Interbody fusion Options 16
Figure 10 New Interbody device..... 17
Figure 11 Failed Hardware..... 19
Figure 12 Failed hardware with loss of alignment..... 20
Figure 13..... 20
Figure 14 Finite Helical Axis 22
Figure 15 Spine simulator..... 23
Figure 16 Motion tracking system..... 24
Figure 17 Experimental setup of the specimen..... 37

ABBREVIATIONS, SYMBOLS, AND NOMENCLATURE

ACDFP: anterior cervical discectomy and fusion with plating

A: anterior

ALL: anterior longitudinal ligament

AR: axial rotation

BFD: bilateral facet dislocation

C1-C7: first to seventh cervical vertebrae

Co: contralateral;

CT: computed tomography

DOF: degree-of-freedom

FC: facet capsule

FE: flexion-extension

FHA: finite helical axis

IVD: intervertebral disc

LB: lateral bending

M: medial

MRI: magnetic resonance imaging

NP: neutral position

NZ: neutral zone

OA: osteoarthritis

PLL: posterior longitudinal ligament

PLC: posterior ligament complex

PMMA: polymethylmethacrylate

PVC: polyvinyl chloride

rmANOVA: repeated measures analysis of variance

ROM: range of motion

S: superior

S: second (unit of time)

SD: standard deviation

SIM: standardized injury model

SLIC: Subaxial Injury Classification

UFP: unilateral facet perch

UF#: unilateral facet fracture

1 CHAPTER 1: INTRODUCTION

OVERVIEW: This chapter introduces: the basic anatomy of the cervical spine, overview of spinal instability, followed by a review of cervical injury patterns and classification, surgical treatment options for flexion-distraction injuries, the evolution of surgical treatment techniques, the current standards of care and the most recent advances. This chapter concludes with thesis rationale and the overall objectives.

1.1 ANATOMY OF THE CERVICAL SPINE

The cervical spine anatomy is complex. It can be divided into osseous, ligamentous, muscular and neurovascular anatomy. The human spine allows motion of the head and neck throughout complicated neuromuscular control; it provides support for the head weight and absorbs shock for the skull and brain; it also provides protection for the important neurovascular (White, A.A., Panjabi, M.M, 1990). These functions are achieved by the osseous, ligamentous and soft tissues structures that stabilize the spine and generate mobility

1.1.1 OSSEOUS ANATOMY

Cervical spine is formed of seven vertebrae of the thirty-three human spine vertebrae; the seven cervical vertebrae (C1-C7) are smallest, yet may be the most diverse from an osteology standpoint (Figure 1) (White and Panjabi, 1990). Starting with C1 at the cranial end, the cervical spine articulates with the base of the skull (occiput). Caudally, it ends at C7, where it connects to the thoracic spine. All cervical vertebrae consist of similar components to other bones of the body; a hard, compact cortical bone outer shell surrounded by a lighter, spongy cancellous (or trabecular) bone. The cervical spine can be further subdivided into upper axial spine formed by C1-C2, and the subaxial spine consisting of C3-C7. We will discuss in detail the subaxial spine as it is relevant to this thesis.

The vertebrae of the subaxial spine have similar anatomical features. Each vertebra is formed of a body, the lamina, two pedicles, two transverse processes, two lateral masses and a spinous process (Figure 1) (White and Panjabi, 1990). The body is connected to a lamina through two pedicles. Pedicles in the cervical spine are short and not suitable for pedicle screw fixation with the exception of C2 and C7. Pedicles connect the lateral masses to the body. The lateral masses are divided into superior and inferior articular process. The laminae join in the midline to form the spinous process. This bony configuration forms a triangle “the vertebral foramen where the spinal cord runs”. Extending laterally from the body are the transverse processes, which form the transverse foramen in which the vertebral artery runs. Knowledge of this complex anatomy is essential to any surgeon treating with the cervical spine.

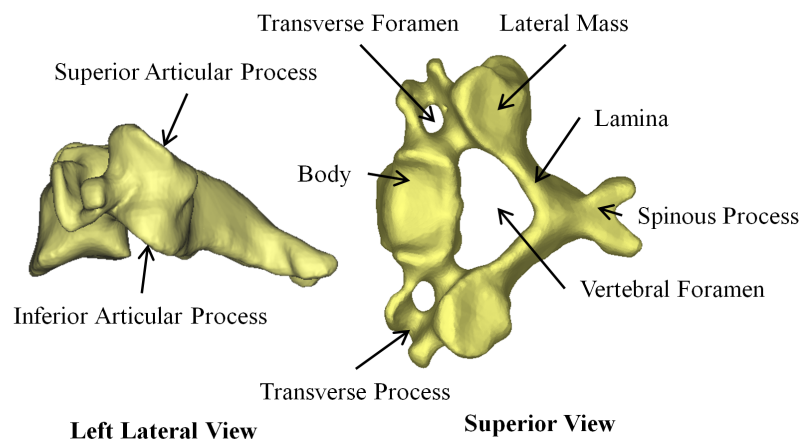


Figure 1 Bony Anatomy of the subaxial cervical vertebrae

Each vertebra is formed of a body, the lamina, two pedicles, two transverse processes, two lateral masses and a spinous process (White and Panjabi, 1990).

1.1.2 ARTICULATING JOINTS OF THE CERVICAL SPINE

Facet joints are relevant to this thesis. They are formed by the superior and inferior articular processes of the inferior and superior vertebrae respectively. The articular facets are zygoapophyseal joints i.e., (flat synovial joints). Articular processes form an elliptical shaped articular surface, along with the synovial fluid and cartilage provides a very efficient sliding type joint (White and Panjabi, 1990). The uncovertebral joints are the other joints in the cervical spine, they are formed by the uncinete processs (Figure 2). These joints span from C3-4 to C7-T1 and allow for spinal mobility and neck range of motion (ROM), which include 85 degrees of Flexion, 70 degrees extension, 40 degrees of rotation. (Figure 4).

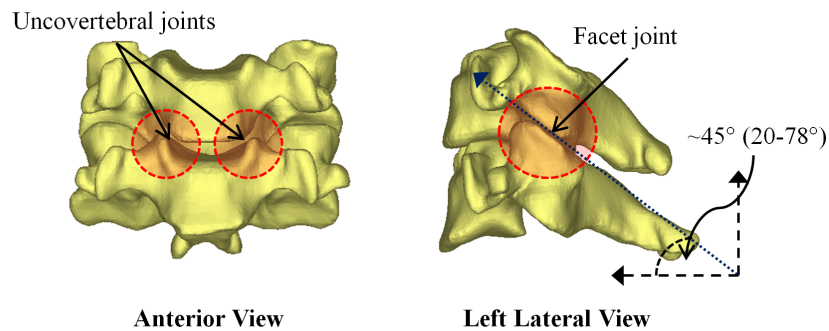


Figure 2 Articulating Joints of the Cervical spine

The uncovertebral joint formed by the uncinete process and the superior end plate of the adjacent level. The Facet joint formed by the inferior and superior articular processes of adjacent level.

Image from: McLachlin, Stewart D. (2013), "An Investigation of Subaxial Cervical Spine Trauma and Surgical Treatment through Biomechanical Simulation and Kinematic Analysis".

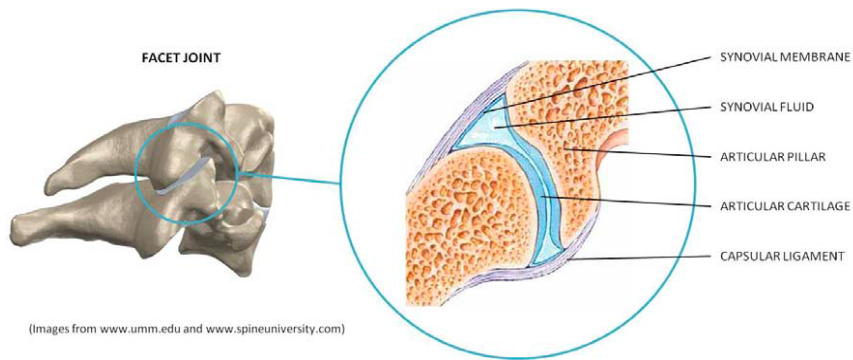


Figure 3 Cervical facet joint anatomy

Illustrates the capsular covering of the facet joint and its content.
 Images from www.spineuniversity.com

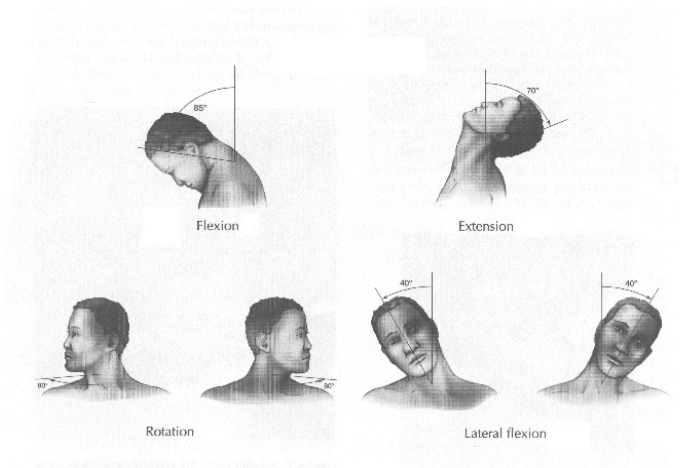


Figure 4 Neck range of motion

Image from: <http://www.thehealthybackblog.com>

1.1.3 SOFT TISSUES

Soft tissue structures of the cervical spine provide significant amount of stability. Intervertebral disc (IVD) sit between adjacent vertebral bodies. The disc is formed by annulus pulposes, a fibrous ring, which surrounds the nucleus pulposus. The nucleus pulposus is formed of a gelatinous mass. The annulus fibrosus provides resistance for high bending and torsional loads, whereas the nucleus pulposes which act hydrostatically to absorb and distribute compressive loads (White and Panjabi, 1990). The shape of the cervical IVD is a crescent like appearance unique to the cervical spine with a larger annulus anterior and a thin annulus posterior (Mercer & Bogduk, 1999).

Other important soft tissue stabilizers include the anterior longitudinal ligament (ALL), the posterior longitudinal ligament (PLL), the ligamentum flavum, and the posterior ligamentous complex. The ALL runs along the anterior body of the vertebrae and is an important stabilizer for extension and translation. The ALL is transected when an anterior cervical discectomy and fusion is performed. The plate spans the adjacent vertebral bodies to the fused level. The length of the plate is very relevant to this thesis and will be discussed later. The PLL runs along the posterior aspect of the vertebral body and stabilizes against distraction and translation (Figure 5). Other important soft tissue structures which mainly protects against flexion distraction and usually is injured in flexion distraction injuries comprise the posterior ligamentous complex (Holdsworth, 1970). The PLC includes the ligamentum flavum, interspinous and supraspinous ligaments, and capsular ligaments. The PLC provides passive restraint of ROM rather than primary stability (Rasoulinejad et al., 2012). The capsular ligaments covers the whole facet joint. Most ligaments are largely collagenous in their make-up; however, the ligamentum flavum, which runs along the interior face of the laminae, is primarily elastin and under constant tension in the neutral position (White and Panjabi, 1990). The interspinous and supraspinous ligaments connect the spinous processes.

Cervical spine musculature provides spinal stability. There are twenty-two muscles each has a specific role. Muscular function is not tested in this thesis.

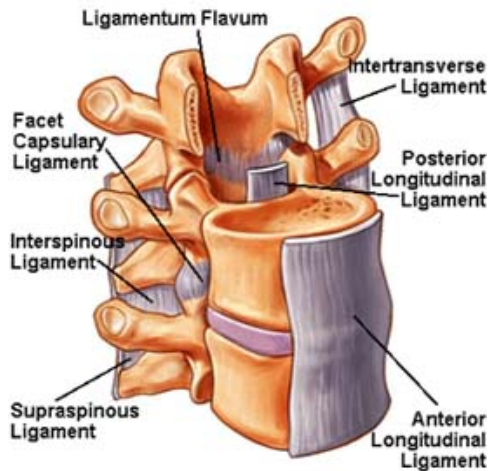


Figure 5 Ligamentous Anatomy

Illustrates different ligaments of the cervical spine
 Images from www.spineuniversity.com

abdulaziz alkuwari 7/18/14 2:13 PM
 Formatted: Normal, Indent: Left: 0.38",
 Line spacing: 1.5 lines

1.2 CERVICAL SPINE INSTABILITY:

Clinical instability is defined as the loss of the spine's ability, under physiologic loads, to maintain its pattern of displacement (White and Panjabi, 1990). Spinal stability is important to prevent pain, protect neural structures and allow motion. Clinical instability is identified when all the anterior or all the posterior elements are destroyed or unable to function or radiologically if more than 3.5 mm horizontal displacement present or more than 11 degrees of rotation is seen at a motion segment on x-ray (A. A. White 3rd, Johnson, Panjabi, & Southwick, 1975). Stability of a structure can be considered as a dynamic or static state. Its structures ligaments, discs, joints, and musculature maintain spine stability. Instability can occur when there is injury to these essential structures, or when these structures degenerate with aging. Instability can also be iatrogenic caused by surgical decompression. Spinal instability can result in debilitating pain that can significantly impact a patient's life. This pain can change the kinematics of the

cervical spine. Spinal instability is not easy to quantify or study (Reeves, Narendra, & Cholewicki, 2007). spine. Spinal instability is not easy to quantify or study (Reeves, Narendra, & Cholewicki, 2007). In our thesis, we are utilizing the percentage change in ROM to study the kinematics of the cervical spine instability. Neutral zone NZ is the range over which a spinal motion segment (SMS) moves with minimal resistance (Smit, van Tunen, van der Veen, Kingma, & van Dieen, 2011). Its widely used in biomechanical studies to Asses spinal stability (DeVries, Gandhi, Fredericks, Grosland, & Smucker, 2012; Rasoulinejad et al., 2012).

1.3 CERVICAL SPINE TRAUMA FRACTURE CLASSIFICATION AND SURGICAL TREATMENT

Cervical spine trauma can result in devastating injury with lifelong disability. Cervical spine injuries represent around 3-6% of emergency visits, which equate to around 150000 cases per year in North America. Forty percent of those injuries are considered unstable injuries (Milby, Halpern, Guo, & Stein, 2008). The subaxial spine accounts for 65% of all fractures (Vaccaro et al., 2007). We will discuss the classification of subaxial injuries followed by a discussion about options of treatment.

1.3.1 CLASSIFICATION OF SUBAXIAL TRAUMATIC INJURIES

Fractures can be classified by anatomical features, mechanism of injury or morphology. There is no all inclusive classification system for subaxial fractures. Frank Holdsworth classified the features of 1000 injuries according to clinical and radiographic features into wedge fracture, dislocation, rotational fracture dislocation, extension injury, burst injury, and shear fracture. He highlighted the importance of PLC posteroligamentous structures (Holdsworth, 1970). Allen-Ferguson system is a very popular classification system; it is a mechanistic classification of injury. Therefore, it is easier to apply in biomechanical studies. It divides cervical injuries into: flexion compression, vertical compression, flexion distraction, compressive extension, distractive extension, and lateral flexion (Allen, Ferguson, Lehmann, & O'Brien, 1982). Each mechanism is further subdivided according to the extent of the damage to the spinal column. This classification is a

good predictor of neurological outcome (Nakashima, Yukawa, Ito, Machino, & Kato, 2011).

Alexander Vaccaro proposed a classification system that includes morphology, status of discoligamentous complex (DLC), and neurological status that assigns points based on severity of injury and according to the total number of points directs the decision to operate or manage the patient conservatively (Vaccaro et al., 2007).

1.3.1.1 FLEXION-DISTRACTION INJURIES OF THE ALLEN-FERGUSON CLASSIFICATION

Allen et al divided flexion-distraction injuries into four different stages, based on the severity of post-injury translational displacement (Allen et al., 1982). Stage 1 involves an isolated posterior ligamentous injury resulting in facet subluxation. Stage 2 is a unilateral facet dislocation. Stage 3 involves a bilateral facet dislocation with 50 percent displacement of the superior vertebral body relative to the inferior vertebral body (50% anterolisthesis). Stage 4 is a complete dislocation of all three columns (100% anterolisthesis). This thesis focuses on stage 1 injury. The unilateral facet perch injury model, an in-vitro protocol to create this injury, has been designed and validated in our lab (Nadeau et al., 2012).

1.3.1.1.1 UNILATERAL FACET PERCH INJURY MODEL

Vaccaro et al studied this injury in depth, he identified ligamentum flavum, nucleus pulposus, and facet capsules as the most commonly disrupted structures observed on MRI, with the interspinous and supraspinous ligament also disrupted in 60% and 40% of their specimens, respectively (Vaccaro et al., 2001). However, Sim et al demonstrated that the disruption of anterior and posterior longitudinal ligaments is not necessary for a unilateral facet dislocation to occur (Sim et al., 2001). Again they found that ipsilateral facet capsule, anulus fibrosus, and ligamentum flavum to be the main soft tissue stabilizers that need to be disrupted to produce a unilateral facet dislocation. Nadeau et al created the model

for a unilateral facet perch in a cadaveric study. Following examination of the injury specimens, it was determined that there was a capsular injury in all specimens, ninety percent being a bilateral capsular injury. There was a one hundred percent injury to annulus. The injured portion of the annulus and nucleus pulposus was found to be contralateral to the facet perch. Eight of the nine specimens had at least 50% of the ligamentum flavum injured, with the ipsilateral side more often affected (67%). The interspinous ligament was injured in 30% of specimens, and the supraspinous ligament injury rate was 40%, it was stretched but never completely torn. Our injury protocol was developed from this injury model (Figure 6).

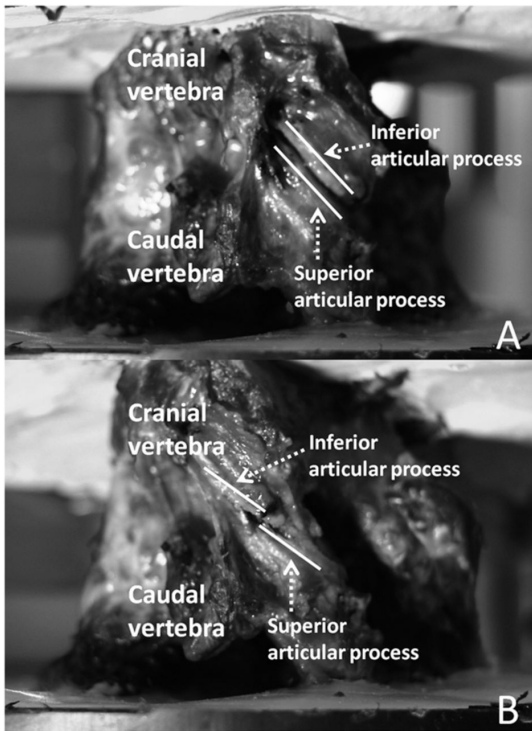


Figure 6 Injury Mechanism

A Photograph showing the direct visualization of the facet to be injured prior to testing, by virtue of a lateral capsular surgical slit. The solid white lines indicate the initial positions of the inferior articular process of the cranial vertebra and the superior articular process of the caudal vertebra (i.e., the facet joint). Small marks were defined on the anterior and posterior aspects of the articular processes to assist with identifying the instance of facet perch. B Photograph showing that when this position was achieved (as identified by the solid white lines), the mechanism of injury was halted (axial torque component) and rotated back into a reduced position.

Image from: Nadeau M et al. *J Bone Joint Surg Am* 2012;94:e156

1.4 TREATMENT OPTIONS

Cervical fractures present a wide array of injuries; there are many variable to consider when deciding the plan of treatment. Treatment can be either conservative with external immobilization with a halo or orthosis or by a surgical intervention in the form of a cervical fusion. The fusion level, the number of levels and the approach used depends on multiple factors. We will discuss these treatment options.

1.4.1 CONSERVATIVE TREATMENT

Conservative treatment in the form of closed reduction and external immobilization (Figure 7) can result in some improvement of neurological symptoms however there is high chance of late kyphosis requiring surgery (Koivikko, Myllynen, & Santavirta, 2004). Bransford et al reported 85 % success in treatment of 342 patients with cervical injuries and considers it a reasonable option with an acceptable rate of complications (Bransford, Stevens, Uyeji, Bellabarba, & Chapman, 2009). Complications of external immobilization include pin site infection, skull penetration pneumonia and loss of reduction (van Middendorp, Slooff, Nellestein, & Oner, 2009).



Figure 7 External Immobilization

This figure shows the halo bracing. This can be a valid option in select patients with risk of some complications including pin site infection, skull penetration pneumonia and loss of reduction (van Middendorp et al., 2009) .

Image source: <http://www.gferreira.co.za>

1.4.2 SURGICAL TREATMENT

Current literature suggests that surgical outcomes are superior to non-operative treatment with non-operatively treated patients reporting more pain at 18 months follow up (Table 1) (Dvorak et al., 2007; Sellin et al., 2014). The ultimate goal of the surgery is to provide a definitive stability through the injured level. This is most commonly accomplished by producing a fusion of the injured level. The fusion can be achieved by a variety of surgical techniques and multiple bone graft options. The first reports of surgical stabilization for cervical instability date to the 1900 when Hadara stabilized a fracture dislocation in a 30-year-old man with progressive neurological deficit (Denaro & Di Martino, 2011). Since then, a huge advancement in surgical techniques occurred especially with the introduction of the plate and screw fixation system by Roy-Camille, which utilized the fixation of the lateral masses (Roy-Camille & Saillant, 1972). This technique utilized a posterior

approach to the cervical spine. It remains a very commonly performed approach for treating subaxial facet fracture-dislocations.

Table 4. Dependent Variables Compared With Normative Values

Dependent Variable	Operative			Nonoperative	All	Normative
	All Operative	Follow-up <18 mo	Follow-up >18 mo			
NASS PD						
Mean	85	82.5	87.2	84.3	84.8	89.1
SD	18.5	18.3	18.7	15.8	17.9	15.5
Difference (SE)	-4.1 (2.15)			-4.8 (4.26)	-4.2 (1.92)	
P	0.028			0.13	0.014	
SF-36 BP						
Mean	68.3	63.3	72.7	63.0	67.2	75.2
SD	26.9	27.1	26.4	30.5	27.6	23.7
Difference (SE)	-6.9 (3.29)			-12.2 (6.54)	-8.0 (2.95)	
P	0.018			0.031	0.003	
SF-36 PCS						
Mean	49.5	46.3	52.3	47.8	49.1	50.0
SD	9.9	9.5	9.4	11.3	10.1	10.0
Difference (SE)	-0.5 (1.20)			-2.2 (2.39)	-0.9 (1.07)	
P	0.328			0.180	0.209	

The mean scores for NASS PD, SF-36 BP, and SF-36 PCS are shown for operative, nonoperative, all patients, and normative standards for an otherwise healthy population. Differences with standard error and P refer to the comparison against normative values.

TABLE 1: Mean score for NASS PD and SF-36 pain scores. Shows significantly less pain scores for operatively treated patients. TABLE from (Dvorak et al., 2007).

However, there is ample clinical evidence which also supports the use of an anterior approach in the form of Anterior Cervical Decompression and Fusion with plate (ACDFP).

(Henriques, Olerud, Bergman, & Jonsson, 2004; Lambiris, Zouboulis, Tyllianakis, & Panagiotopoulos, 2003; Ordonez, Benzel, Naderi, & Weller, 2000).

Hence, there remains controversy over the most appropriate surgical approach for stabilization (Johnson et al., 2004; Kwon et al., 2007). specially in the setting of a facet fracture. Kwon et. al. performed a prospective randomized controlled trial of anterior compared with posterior stabilization for unilateral facet injuries of the cervical spine and showed no significance difference in long term outcome, thus considering both options viable alternatives for treating these injuries (Kwon et al., 2007). Despite this clinical evidence, biomechanical testing consistently finds ACDFP to be less stable than a posterior screw rod construction, particularly in

axial rotation (McLachlin et al., 2011). Anterior Cervical Decompression and Fusion ACDF has been shown to reduce ROM in models of cervical injury (Duggal et al., 2005; Rasoulinejad et al., 2012). However when fractures are rotationally unstable, ACDF with a plate is not biomechanically sufficient (Smith, Lindsey, Doherty, Alexander, & Dickson, 1993), and a combined anterior-posterior approach or posterior only approach have been recommended in this case.

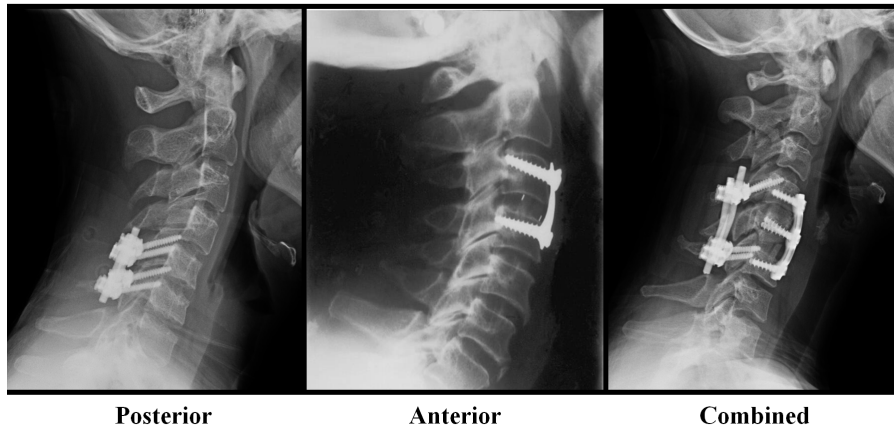


Figure 8 TYPE OF SURGICAL FIXATION

Posterior: Lateral mass screws and rods shown in the C5-C6 vertebrae. Anterior: ACDFP in the C3-C4 vertebrae. Combined: Multi-level ACDFP with supplemental lateral mass screws and rods in the C4-C6 vertebrae.

IMAGE from McLachlin, Stewart D., "An Investigation of Subaxial Cervical Spine Trauma and Surgical Treatment through Biomechanical Simulation and Kinematic Analysis" (2013). University of Western Ontario - Electronic Thesis and Dissertation Repository. Paper 1216.

<http://ir.lib.uwo.ca/etd/1216>

1.4.2.1 SURGICAL FUSION OPTIONS AND CONSIDERATIONS

In this section we will go through the evolution of ACDF, different fusion options and the new advances in the treatment of cervical fractures. We will also discuss possible reasons for hardware failure and adjacent level disease.

1.4.2.1.1 ANTERIOR CERVICAL FUSION

Anterior cervical fusion options are vast. They vary in configuration from the standard anterior plate with an iliac crest graft to the new innovations of interbody devices with fixation or without fixation as a stand alone cages, This last option is not suitable for trauma. There are advantages and disadvantages to all fusion devices. Anterior cervical fusion with a plate and iliac crest graft has been the standard of care for fusion. Plates designs have evolved from uni-cortical fixation, which had poor screw purchase, followed by bi-cortical screws, to the development of locked plate systems; which have revolutionized the anterior cervical fusion and made this fusion option the standard of care for cervical fusion for many years. However the associated morbidity with ACDF, which includes swallowing difficulty, persistent pain, pseudoarthrosis, adjacent level degeneration (Bullard & Valentine, 2013; J. Y. Park et al., 2013) , and morbidity from iliac crest harvest (Chau & Mobbs, 2009; Heneghan & McCabe, 2009; Silber et al., 2003) , have led surgeons to discover new techniques and fusion strategies.

Therefore, many innovative surgical techniques that have been discovered. Vanek P *et al.* compared three fusion options for ACDF for degenerative disc disease: a stand alone autograft vs autograft with a plate vs PEEK Cage with beta-tricalcium phosphate with a plate (Vanek, 2012).. The worst outcome was with the stand alone autograft, where as the best outcome was with autograft and a plate. He found similar results with using plate and cage filled with beta-tricalcium phosphate, which suggest beta-tricalcium phosphate a suitable alternative to autologous bone graft (Vanek, 2012). Another alternative to iliac crest autograft is Poly Ether Ketone PEEK cages filled with autologous iliac crest bone graft harvested percutaneously, Delepine *et al.* reported hundred percent fusion rate with this technique (Delepine, Jund, Schlatterer, & de Peretti, 2007) .

1.4.2.1.2 NON-INSTRUMENTED FUSION OPTIONS

There are many non instrumented interbody devices used as a stand alone interbody device. This technology doesn't apply to trauma routinely since there has been no trials proving their effectiveness to provide stability in the setting of trauma. However, we will discuss them briefly for the sake of completion of fusion options. Numerous non-instrumented fusion options are available (Figure 9) with good short-term results, but unknown long-term results. Cao L *et al.* compared the biomechanical stability of stand alone cages in sheep cervical spine and compared it to a novel polylactic acid nanosized beta tricalcium phosphate bio absorbable cage (BCFC) (Cao et al., 2012). This study showed no difference in stability in Range of motion among these devices except for a superiority of the BCFC device in flexion extension over other cages (Solis, Stryker Spine, South Allendale, NJ, USA). Anterior cervical fusion with a plate ACP and iliac crest graft showed better stability in flexion extension. Interestingly the design of the device with BCFC and the solis cage with a convex surface showed a better stability than the flat Medtronic cage (Cao et al., 2012) . These devices have a strong potential since they are technically much less demanding than ACDF with a plate.




Figure 9 Different Interbody fusion Options

A-Autologus bone graft. B-medtronic cage. C-solis cage. D- BCFC device.
 These devices are alternatives to structural autograft.
 Image from (Cao et al., 2012)

1.4.2.1.3 NEW INTERBODY FUSION OPTION

New techniques have recently been introduced to manage cervical flexion distraction injuries involving the use of an interbody spacers with a locked screw mechanism. Previously, this technique has been commonly used for the treatment of degenerative disc disease, however a recent biomechanical study by Wojewnik *B et al.* evaluated the stability of this device using a locked screw configuration (figure 10) ; they found a 66% reduction of ROM in the injured specimens (Wojewnik et al., 2013) . They claim this is satisfactory and advise to use it in the sitting of trauma with the addition of external immobilization with a collar. This technique is promising; it could be the future standard of care for cervical fusion as it is low profile which mean less chances of irritation to surrounding structures, has fewer complications than ACDF with plate and less technically demanding than ACDF with a plate. It might also prove to have a lower rate of adjacent level degeneration, as there is less chance of injury to anterior longitudinal ligament, hence less chance of changing spine kinematics.

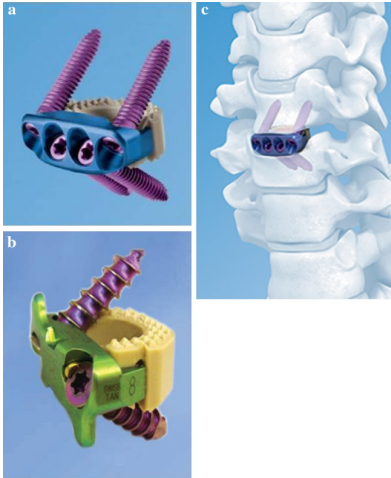


Figure 10 New Interbody device zero-p cage a new device that provides satisfactory stability in cervical trauma.

Image from (Wojewnik,B., 2013).

1.4.2.1.4 ACDF CONSTRUCT RELATED POSSIBLE COMPLICATIONS

There are long term related complications which might be related to the construct configuration i.e. the position of the screws, the plate size, the graft size and the technical aspect of the procedure which include proper end plate preparation for fusion and type of graft used. All these factors make it extremely difficult to ascertain the cause of failure of the construct. Construct integrity would, usually, fail if the fusion mass failed to unite (Figure 11). Another important point that might be related to the stability of the construct is loss of alignment, postoperative kyphosis (Figure 12) and adjacent level disease (Johnson et al., 2004).

Studies have showed that fusing one level result in a change in the kinematics of the adjacent level (Anderson et al., 2012) . Schwab et.al observed increased range of motion on adjacent segments to the fusion (Schwab, Diangelo, & Foley, 2006).

Moreover the larger plates may result in damage to the ALL spanning the adjacent level which might be a factor for adjacent level disease. Park Jb et. al retrospectively studied the lateral radiographs of 116 patients who had solid fusion post ACDFP to show that the plate to disc distance (PDD) is directly related to likelihood of acquiring adjacent level ossification. They proposed to have at least 5mm PDD (Figure 13) to reduce the likelihood of adjacent level ossification (J. B. Park, Cho, & Riew, 2005) . The graft size has been shown to affect the stability of ACDF construct where undersizing the graft results in both facet overlap and locking of the uncovertebral joints, providing greater stability in lateral flexion and axial rotation, while oversizing the graft provides greater stability in flexion-extension (Yao et al., 2014). Another crucial point that could have an impact on the stability of the construct is the morphology of the fracture a 13 % radiographic failure rate has been reported when a bilateral facet fracture is associated with a concomitant fracture of the superior endplate of the caudal vertebra involved in the injury. They also noted that most failures involved the pullout of the screws from the caudal vertebra, with the screws cutting out inferiorly. The authors suggested an inverse correlation between the distance between the inferior end plate and the lower screw and failure (Johnson et al., 2004).

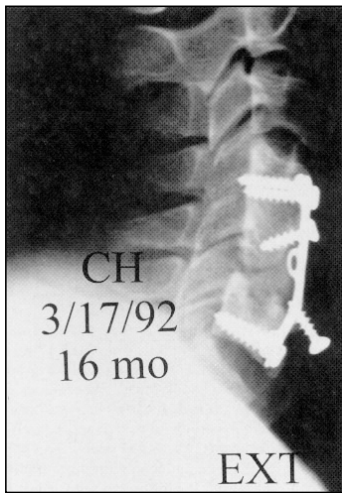


Figure 11 Failed Hardware

A lateral radiograph 16 months after surgery shows a nearly total disengagement of the screw and plate.

Image from: The Significance of Hardware Failure in Anterior Cervical Plate Fixation: Patients With 2- to 7-Year Follow-up. Lowery, Gary; McDonough, Richard. Spine 23(2):181-186, January 15, 1998.

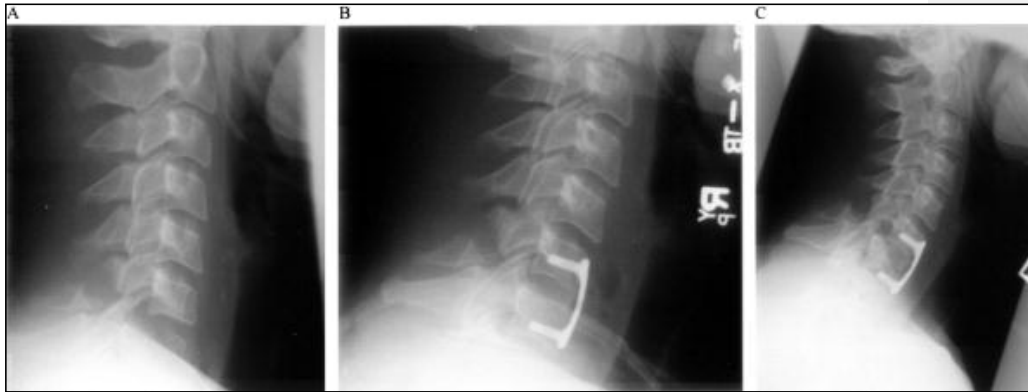

Figure 12 Failed hardware with loss of alignment

A. Lateral radiograph at the time of a C6-7 bilateral facet dislocation with fracture of the superior endplate of C7. B. Lateral radiograph immediately postoperatively, showing no translation and satisfactory alignment. C. Final follow-up radiograph revealing significant translation, kyphosis, and pull-out of the C7 screws

Image from: **The Radiographic Failure of Single Segment Anterior Cervical Plate Fixation in Traumatic Cervical Flexion Distraction Injuries.** Johnson, Michael; Fisher, Charles; Boyd, Michael; Pitzen, Tobias; Oxland, Thomas; Dvorak, Marcel. Spine 29(24):2815-2820, December 15, 2004.

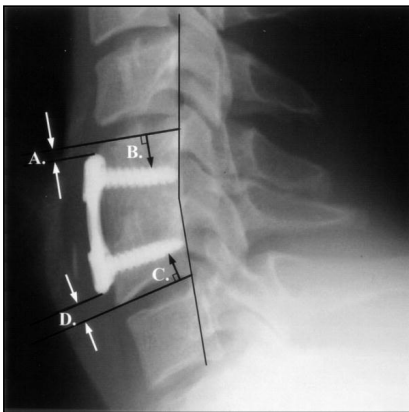


Figure 13

Illustrates the Plate to disc distance should be more than 5mm.

Image from: **The Radiographic Failure of Single Segment Anterior Cervical Plate Fixation in Traumatic Cervical Flexion Distraction Injuries.** Johnson, Michael; Fisher, Charles; Boyd, Michael; Pitzen, Tobias; Oxland, Thomas; Dvorak, Marcel. Spine 29(24):2815-2820, December 15, 2004.

1.5 CERVICAL BIOMECHANICAL STUDIES

Cervical biomechanical studies provide invaluable information about cervical kinematics; this information can improve surgical techniques hence improving patient outcomes. Extensive work in this field has been performed by Panjabi et al. through utilizing spinal simulators, They pioneered the techniques that became the standard of testing for new surgical devices (Panjabi & White, 1971). However there are disadvantages to this mode of testing. First, the cost of human cadaveric studies is high, this, usually, affects the sample size in any biomechanical study. The cadavers bone quality is not optimum as most specimens are from elderly osteoporotic patients. Decreased bone density has been shown to reduce stability (Dvorak et al., 2005). Porcine models have been an acceptable alternative (Hongo et al., 2008; Smith et al., 1993). Preparation and handling of specimens require meticulous surgical experience and time. Often specimens need to be thawed and frozen again, but biomechanical studies have shown that this doesn't affect the mechanical properties of specimens (Hongo et al., 2008).

Range of motion in spine assessed by measuring six degrees of motion (DOF), which is calculated by assessing finite helical axis FHA (Dugailly et al., 2013; M. Panjabi & White, 1971). This method is widely used in cervical biomechanical studies (Figure 2.5) (Anderst, Lee, Donaldson, & Kang, 2013; Nadeau et al., 2012). Motion is tracked using optical tracking systems. The system used in this work was the Optotrak Certus® (Northern Digital Inc., Waterloo, ON, Canada) which is a commonly used measurement tools for this purpose. Rigid body trackers are placed on each body of interest (i.e., cephalic and caudal vertebra), points on the object are digitized, and their motion is tracked relative to a fixed camera system. Coordinate systems were originally developed by Panjabi et al in 1981 (M. M. Panjabi, Krag, & Goel, 1981). Since then this method has improved, especially with the advances in computer and navigation technology (Kettler et al., 2004). This new technology and advances revolutionized the study of spine kinematics and made it a favorable method to examine and improve new surgical devices.

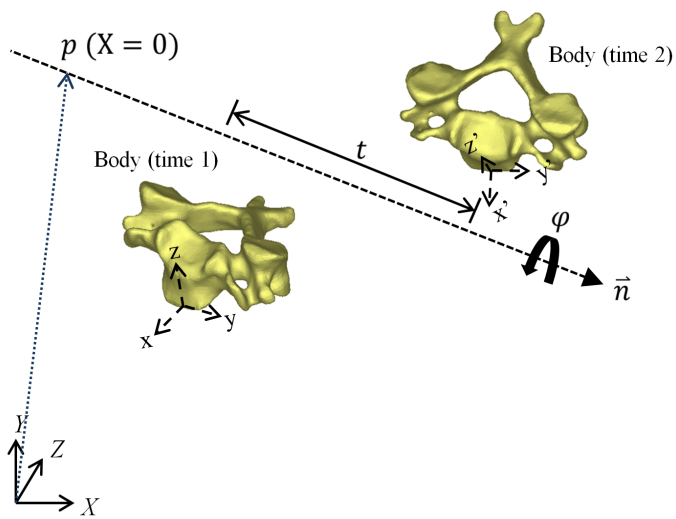


Figure 14 Finite Helical Axis

The finite helical axis describes a unique axis in space about which an object rotates (ϕ) and along which it translates (t) between two frames of motion. The axis is defined in space by a vector (n) and an intercept (p) with a plane of interest (as shown with YZ plane). This intercept is the centre of rotation in that plane.
 Image from McLachlin, Stewart D. (2013), "An Investigation of Subaxial Cervical Spine Trauma and Surgical Treatment through Biomechanical Simulation and Kinematic Analysis".

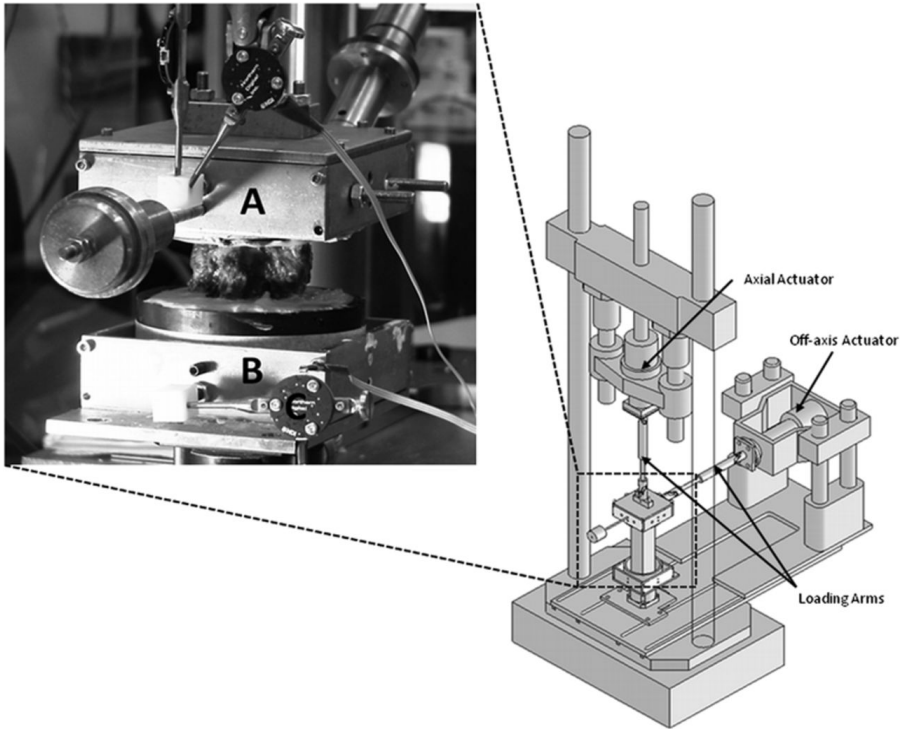


Figure 15 Spine simulator

Illustration showing the spine simulator that was built in our lab, a main axial and torque actuator along with an additional off-axis torque actuator. The two loading arms, ball splines with universal joints at each end, connect the actuators to the upper fixture to apply bending moments to the specimen. Inset photograph showing cadaveric cervical spine segments that were mounted in the upper (A) and lower (B) potting fixtures of the spinal loading simulator, with Optotrak Smart Markers (C) attached to each fixture for motion tracking.

Image from: Nadeau M et al. *J Bone Joint Surg Am* 2012;94:e156

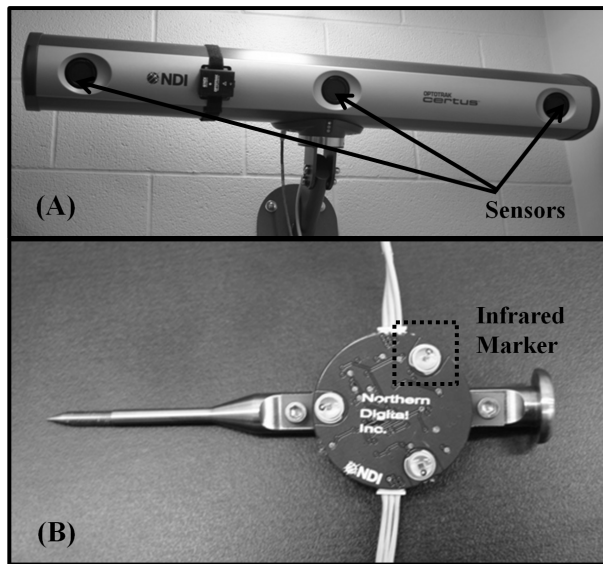


Figure 16 Motion tracking system

(A) An Optotrak Certus® motion tracking system was used to capture the induced spinal kinematics in this study (and subsequent chapters). The system consists of three camera sensors, which are used to identify the 3D location (*i.e.*, X , Y , and Z positions) of infrared markers in its visible capture volume. (B) The rigid body trackers were the prepackaged Optotrak® Smart Markers, which consist of three infrared markers used to output six-DOF pose information of the tracker (*i.e.*, three rotations and three translations).

Image from: Nadeau M et al. *J Bone Joint Surg Am* 2012;94:e156

1.6 THESIS RATIONALE

Cervical spine trauma is complex. There are multiple types of injuries, which subdivided into more specific and unique injuries. The most commonly utilized surgical treatment for a unilateral fracture dislocation is ACDFP. This treatment has been associated with short and long term complications. Some complications are attributed to the size of the plate used in ACDF, including post-fusion adjacent level degeneration, pseudo-arthritis, and hardware failure. Choosing the plate size remains poorly investigated and controversial. Currently, surgeons will typically choose a

larger plate thinking that the construct would be more stable. Stability is crucial for fusion and reduction of the chances of pseudo-arthritis and hardware failure. However, longer plates are associated with post fusion adjacent level degeneration. With the short plates there is sparing of a large portion of the vertebra between the plate-screw-bone interface and the adjacent disc level that might allow for some elasticity of the bone, which might have an effect on adjacent level degeneration. There is also sparing of adjacent level ALL, which might negatively affect the stability of adjacent level and predispose to adjacent level degeneration. Therefore, although large plates may result in a more stable construct, they are associated with an increased risk of adjacent level degeneration.

1.6.1 OBJECTIVES AND HYPOTHESES

The overall objective of this thesis was to investigate the change in kinematics of the cervical spine after a flexion-distraction injury fixed using ACDFP and specifically to determine if plate length significantly alters the biomechanical kinematics of ACDFP when stabilizing a unilateral cervical facet dislocation.

This will be accomplished through the following **specific objectives**:

1. Evaluate the intact cervical spine ROM.
2. Evaluate the cervical spine ROM after a flexion-distraction injury.
3. Evaluate the cervical spine ROM after a standard Anterior Cervical Decompression and Fusion using two plates of different sizes: large and small.

The **hypotheses** of this thesis were

1. The flexion-distraction injury will increase the ROM of Cervical Spine in all planes of motion: flexion-extension, axial rotation, and lateral bend.
2. Anterior Cervical Decompression and Fusion with a standard plate and graft can sufficiently stabilize the cervical spine.
3. A larger plate will provide better stability of the ACDFP than the smaller plates.

1.7 REFERENCES

- Allen, B. L., Jr, Ferguson, R. L., Lehmann, T. R., & O'Brien, R. P. (1982). A mechanistic classification of closed, indirect fractures and dislocations of the lower cervical spine. *Spine*, 7(1), 1-27.
- Anderson, P. A., Sasso, R. C., Hipp, J., Norvell, D. C., Raich, A., & Hashimoto, R. (2012). Kinematics of the cervical adjacent segments after disc arthroplasty compared with anterior discectomy and fusion: A systematic review and meta-analysis. *Spine*, 37(22 Suppl), S85-95.
- Bransford, R. J., Stevens, D. W., Uyeji, S., Bellabarba, C., & Chapman, J. R. (2009). Halo vest treatment of cervical spine injuries: A success and survivorship analysis. *Spine*, 34(15), 1561-1566.
- Bullard, D. E., & Valentine, J. S. (2013). Early morbidity of multilevel anterior cervical discectomy and fusion with plating for spondylosis: Does the number of levels influence early complications? A single surgeon's experience in 519 consecutive patients. *Evidencebased Spinecare Journal*, 4(1), 13-17.
- Cao, L., Duan, P. G., Li, X. L., Yuan, F. L., Zhao, M. D., Che, Wang H., Dong, J. (2012). Biomechanical stability of a bioabsorbable self-retaining polylactic acid/nano-sized beta-tricalcium phosphate cervical spine interbody fusion device in single-level anterior cervical discectomy and fusion sheep models. *International Journal of Nanomedicine*, 7, 5875-5880.

- Chau, A. M., & Mobbs, R. J. (2009). Bone graft substitutes in anterior cervical discectomy and fusion. *European Spine Journal*, 18(4), 449-464.
- Delepine, F., Jund, S., Schlatterer, B., & de Peretti, F. (2007). Experience with poly ether ether ketone (PEEK) cages and locking plate for anterior cervical fusion in the treatment of spine trauma without cord injury. [Resultats radiologiques des arthrodeses par cages radio-transparentes et plaque anterieure dans le traitement des traumatismes du rachis cervical sans lesions medullaires] *Revue De Chirurgie Orthopedique Et Reparatrice De L'Appareil Moteur*, 93(8), 789-797.
- Denaro, V., & Di Martino, A. (2011). Cervical spine surgery: An historical perspective. *Clinical Orthopaedics and Related Research*, 469(3), 639-648.
- DeVries, N. A., Gandhi, A. A., Fredericks, D. C., Grosland, N. M., & Smucker, J. D. (2012). Biomechanical analysis of the intact and destabilized sheep cervical spine. *Spine*, 37(16), E957-63.
- Dugailly, P. M., Sobczak, S., Lubansu, A., Rooze, M., Jan, S. S., & Feipel, V. (2013). Validation protocol for assessing the upper cervical spine kinematics and helical axis: An in vivo preliminary analysis for axial rotation, modeling, and motion representation. *Journal of Craniovertebral Junction and Spine*, 4(1), 10-15.
- Duggal, N., Chamberlain, R. H., Park, S. C., Sonntag, V. K., Dickman, C. A., & Crawford, N. R. (2005). Unilateral cervical facet dislocation: Biomechanics of fixation. *Spine*, 30(7), E164-8.

- Dvorak, M. F., Fisher, C. G., Aarabi, B., Harris, M. B., Hurbert, R. J., Rampersaud, Y. R., . . . Fehlings, M. G. (2007). Clinical outcomes of 90 isolated unilateral facet fractures, subluxations, and dislocations treated surgically and nonoperatively. *Spine*, 32(26), 3007-3013.
- Dvorak, M. F., Pitzén, T., Zhu, Q., Gordon, J. D., Fisher, C. G., & Oxland, T. R. (2005). Anterior cervical plate fixation: A biomechanical study to evaluate the effects of plate design, endplate preparation, and bone mineral density. *Spine*, 30(3), 294-301.
- Heneghan, H. M., & McCabe, J. P. (2009). Use of autologous bone graft in anterior cervical decompression: Morbidity & quality of life analysis. *BMC Musculoskeletal Disorders*, 10, 158-2474-10-158.
- Henriques, T., Olerud, C., Bergman, A., & Jonsson, H., Jr. (2004). Distractive flexion injuries of the subaxial cervical spine treated with anterior plate alone. *Journal of Spinal Disorders & Techniques*, 17(1), 1-7.
- Holdsworth, F. (1970). Fractures, dislocations, and fracture-dislocations of the spine. *The Journal of Bone and Joint Surgery. American Volume*, 52(8), 1534-1551.
- Hongo, M., Gay, R. E., Hsu, J. T., Zhao, K. D., Ilharreborde, B., Berglund, L. J., & An, K. N. (2008). Effect of multiple freeze-thaw cycles on intervertebral dynamic motion characteristics in the porcine lumbar spine. *Journal of Biomechanics*, 41(4), 916-920.

- Johnson, M. G., Fisher, C. G., Boyd, M., Pitzen, T., Oxland, T. R., & Dvorak, M. F. (2004). The radiographic failure of single segment anterior cervical plate fixation in traumatic cervical flexion distraction injuries. *Spine*, 29(24), 2815-2820.
- Kettler, A., Marin, F., Sattelmayer, G., Mohr, M., Mannel, H., Durselen, L., . . . Wilke, H. J. (2004). Finite helical axes of motion are a useful tool to describe the three-dimensional in vitro kinematics of the intact, injured and stabilised spine. *European Spine Journal*, 13(6), 553-559.
- Koivikko, M. P., Myllynen, P., & Santavirta, S. (2004). Fracture dislocations of the cervical spine: A review of 106 conservatively and operatively treated patients. *European Spine Journal*, 13(7), 610-616.
- Kwon, B. K., Fisher, C. G., Boyd, M. C., Cobb, J., Jebson, H., Noonan, V., . . . Dvorak, M. F. (2007). A prospective randomized controlled trial of anterior compared with posterior stabilization for unilateral facet injuries of the cervical spine. *Journal of Neurosurgery Spine*, 7(1), 1-12.
- Lambiris, E., Zouboulis, P., Tyllianakis, M., & Panagiotopoulos, E. (2003). Anterior surgery for unstable lower cervical spine injuries. *Clinical Orthopaedics & Related Research*, (411), 61-69.
- Mercer, S., & Bogduk, N. (1999). The ligaments and annulus fibrosus of human adult cervical intervertebral discs. *Spine*, 24(7), 619-26; discussion 627-8.

- Milby, A. H., Halpern, C. H., Guo, W., & Stein, S. C. (2008). Prevalence of cervical spinal injury in trauma. *Neurosurgical Focus*, 25(5), E10.
- Nadeau, M., McLachlin, S. D., Bailey, S. I., Gurr, K. R., Dunning, C. E., & Bailey, C. S. (2012). A biomechanical assessment of soft-tissue damage in the cervical spine following a unilateral facet injury. *Journal of Bone & Joint Surgery - American Volume*, 94(21), e156.
- Nakashima, H., Yukawa, Y., Ito, K., Machino, M., & Kato, F. (2011). Mechanical patterns of cervical injury influence postoperative neurological outcome: A verification of the allen system. *Spine*, 36(6), E441-6.
- Ordonez, B. J., Benzel, E. C., Naderi, S., & Weller, S. J. (2000). Cervical facet dislocation: Techniques for ventral reduction and stabilization. *Journal of Neurosurgery*, 92(1 Suppl), 18-23.
- Panjabi, M., & White, A. A.,3rd. (1971). A mathematical approach for three-dimensional analysis of the mechanics of the spine. *Journal of Biomechanics*, 4(3), 203-211.
- Panjabi, M. M., Krag, M. H., & Goel, V. K. (1981). A technique for measurement and description of three-dimensional six degree-of-freedom motion of a body joint with an application to the human spine. *Journal of Biomechanics*, 14(7), 447-460.
- McLachlin, Stewart D. (2013), "An Investigation of Subaxial Cervical Spine Trauma and Surgical Treatment through Biomechanical Simulation and Kinematic Analysis".

- Park, J. B., Cho, Y. S., & Riew, K. D. (2005). Development of adjacent-level ossification in patients with an anterior cervical plate. *The Journal of Bone and Joint Surgery.American Volume*, 87(3), 558-563.
- Park, J. Y., Kim, K. H., Kuh, S. U., Chin, D. K., Kim, K. S., & Cho, Y. E. (2013). What are the associative factors of adjacent segment degeneration after anterior cervical spine surgery? comparative study between anterior cervical fusion and arthroplasty with 5-year follow-up MRI and CT. *European Spine Journal : Official Publication of the European Spine Society, the European Spinal Deformity Society, and the European Section of the Cervical Spine Research Society*, 22(5), 1078-1089.
- Rasoulinejad, P., McLachlin, S. D., Bailey, S. I., Gurr, K. R., Bailey, C. S., & Dunning, C. E. (2012). The importance of the posterior osteoligamentous complex to subaxial cervical spine stability in relation to a unilateral facet injury. *Spine Journal: Official Journal of the North American Spine Society*, 12(7), 590-595.
- Reeves, N. P., Narendra, K. S., & Cholewicki, J. (2007). Spine stability: The six blind men and the elephant. *Clinical Biomechanics (Bristol, Avon)*, 22(3), 266-274.
- Roy-Camille, R., & Saillant, G. (1972). Surgery of the cervical spine. 3. complex fractures of the lower cervical spine. tetraplegia. [Chirurgie du rachis cervical. 3.

Fractures complexes du rachis cervical inferieur. Tetraplegies] *La Nouvelle Presse Medicale*, 1(40), 2707-2709.

Schwab, J. S., Diangelo, D. J., & Foley, K. T. (2006). Motion compensation associated with single-level cervical fusion: Where does the lost motion go? *Spine*, 31(21), 2439-2448.

Sellin, J. N., Shaikh, K., Ryan, S. L., Brayton, A., Fulkerson, D. H., & Jea, A. (2014). Clinical outcomes of the surgical treatment of isolated unilateral facet fractures, subluxations, and dislocations in the pediatric cervical spine: Report of eight cases and review of the literature. *Child's Nervous System : ChNS : Official Journal of the International Society for Pediatric Neurosurgery*

Silber, J. S., Anderson, D. G., Daffner, S. D., Brislin, B. T., Leland, J. M., Hilibrand, A. S., . . . Albert, T. J. (2003). Donor site morbidity after anterior iliac crest bone harvest for single-level anterior cervical discectomy and fusion. *Spine*, 28(2), 134-139. doi:10.1097/01.BRS.0000041587.55176.67

Smit, T. H., van Tunen, M. S., van der Veen, A. J., Kingma, I., & van Dieen, J. H. (2011). Quantifying intervertebral disc mechanics: A new definition of the neutral zone. *BMC Musculoskeletal Disorders*, 12, 38-2474-12-38. doi:10.1186/1471-2474-12-38; 10.1186/1471-2474-12-38

Smith, S. A., Lindsey, R. W., Doherty, B. J., Alexander, J. W., & Dickson, J. H. (1993). Cervical spine locking plate: In vitro biomechanical testing. *European Spine Journal : Official Publication of the European Spine Society, the European Spinal Deformity*

Society, and the European Section of the Cervical Spine Research Society, 1(4), 222-225.

Vaccaro, A. R., Hulbert, R. J., Patel, A. A., Fisher, C., Dvorak, M., Lehman, R. A., Jr., . . . Spine Trauma Study Group. (2007). The subaxial cervical spine injury classification system: A novel approach to recognize the importance of morphology, neurology, and integrity of the disco-ligamentous complex. *Spine, 32(21), 2365-2374.*

Vaccaro, A. R., Madigan, L., Schweitzer, M. E., Flanders, A. E., Hilibrand, A. S., & Albert, T. J. (2001). Magnetic resonance imaging analysis of soft tissue disruption after flexion-distraction injuries of the subaxial cervical spine. *Spine, 26(17), 1866-1872.*

an Middendorp, J. J., Slooff, W. B., Nellestein, W. R., & Oner, F. C. (2009). Incidence of and risk factors for complications associated with halo-vest immobilization: A prospective, descriptive cohort study of 239 patients. *The Journal of Bone and Joint Surgery.American Volume, 91(1), 71-79.*

White, A.A., Panjabi, M.M. (1990). *Clinical biomechanics of the spine* (2nd edition ed., pp. 1–125). Philadelphia: Lippincott Williams & Wilkins.

White, A. A.,3rd, Johnson, R. M., Panjabi, M. M., & Southwick, W. O. (1975). Biomechanical analysis of clinical stability in the cervical spine. *Clinical Orthopaedics and Related Research, (109)(109), 85-96.*

Wojewnik, B., Ghanayem, A. J., Tsitsopoulos, P. P., Voronov, L. I., Potluri, T., Havey, R. M., . . . Patwardhan, A. G. (2013). Biomechanical evaluation of a low profile, anchored cervical interbody spacer device in the setting of progressive flexion-distraction injury of the cervical spine. *European Spine Journal*, 22(1), 135-141.

McLachlin SD, Rasoulinejad P, Bailey SI, Gurr KR, Bailey CS, Dunning CE. Anterior versus posterior fixation for an isolated posterior facet complex injury in the sub-axial Cervical spine. Poster session presented at: 11th Annual Scientific Conference of the Canadian Spine Society; 2011, Mar 9-12; Quebec City, PQ.

2 CHAPTER 2:

OVERVIEW: This Chapter presents the thesis Integrated Article in the format of a Manuscript. The article is presented, as it will be submitted for the Journal, it contains an introduction, materials and methods, discussion and conclusion.

2.1 INTRODUCTION

Flexion-distraction injuries account for approximately 10% of subaxial cervical spine trauma, most commonly a result of motor vehicle accidents (Allen, Ferguson, Lehmann, & O'Brien, 1982). Within this injury mechanism, facet joint subluxation is a less common injury pattern compared to facet fracture-dislocations, yet is still characterized by significant soft tissue disruption (Allen et al., 1982; Dvorak, Fisher, Fehlings, et al., 2007). Prior in vivo and in vitro studies have identified the facet capsules, ligamentum flavum, annulus, and nucleus pulposus as the structures commonly involved in flexion-distraction injuries (Mélissa Nadeau et al., 2012; Sim, Vaccaro, Berzlanovich, Schwarz, & Sim, 2001; Vaccaro et al., 2001). Further biomechanical evidence has shown this injury pattern produces mechanical/kinematic instability at the injured motion segment which can be further exaggerated with the addition of a facet fracture (Neil R Crawford et al., 2002; Mélissa Nadeau et al., 2012). Current literature suggests that surgical patients report lower long term pain when compared to those treated with non-surgical interventions (Dvorak, Fisher, Aarabi, et al., 2007).

Although, the most appropriate surgical approach for stabilization remains controversial (Johnson et al., 2004; Kwon et al., 2007), especially with the presentation a facet fracture. There is clinical evidence that supports the use of Anterior Cervical Discectomy and Fusion with plating (ACDFP). (Henriques, Olerud, Bergman, & Jónsson, 2004; Lambiris, Zouboulis, Tyllianakis, & Panagiotopoulos, 2003; Ordonez, Benzel, Naderi, & Weller, 2000) ACDFP has been previously shown to restore kinematic stability in biomechanical models of unilateral facet injury (Duggal et al., 2005; Rasoulinejad et al., 2012). However, a variety of factors have been demonstrated to play a role in determining the overall construct stability following surgery, such as the severity of the soft tissue injury, degree of subluxation/dislocation, bone graft height, and the presence of an associated facet and/or endplate fracture (Johnson et al., 2004; J. Y. Park et al.,

2013; Yao et al., 2014). Another potentially important factor that, to the authors' knowledge, has not been investigated is the independent effect of plate length on the kinematics of the ACDFP construct. It was hypothesized that the effect of placing screws immediately adjacent to the endplates of the stabilized level with a shorter plate would provide less stabilizing than engaging the adjacent bone end plates located a greater distance from the stabilized level. Therefore, the purpose of the current study was to determine the biomechanical effect of plate length on cervical spine kinematic stability following ACDFP stabilization for the treatment of simulated traumatic injuries to the subaxial cervical spine.

2.2 METHODS

Eleven fresh-frozen cadaveric cervical spine segments of varying segments lengths (either C4-C7 or C5-C7) were used in this study. Prior to testing, each specimen was scanned via CT imaging to rule out any confounding pathology. The specimens were thawed overnight at room temperature and cleaned of all musculature while the ligaments, discs, and joint capsules were left intact. With an interest in examining motion at a single level, either C5-C6 or C6-C7 was left free, with the motion segments above and below the segments of interest immobilized with screws through the most distal and proximal endplates. Each end of the specimen was potted in sections of PVC tubing using dental cement (Denstone™ Heraeus Kulzer Inc., South Bend, IN).




Figure 17 Experimental setup of the specimen.

Shown is the application of FE and AR bending to induce a simulated unilateral facet perch injury. Two Optotrak smart markers track the motion of the C5-C6 segment to determine changes in kinematic stability.

Experimental testing, using the flexibility methodology, was performed on each specimen using a custom spinal loading simulator modified from a materials testing machine (Instron[®] 8874, Canton, MA) (Panjabi, 1992; Rasoulinejad et al., 2012). Loading was applied to the cranial end of each specimen via a custom designed loading arm to induce independent flexion-extension, axial rotation, and lateral bending motions (Figure 1). The loading arm was telescopic with universal joints at each end to transmit torsion in a single anatomic plane and allow for unconstrained motion in the remaining five degrees-of-freedom (Goertzen, Lane, & Oxland, 2004). For each motion, the specimens were loaded at 3°/s up to a target of $\pm 1.5\text{Nm}$ (Pitzen et al., 2003). To minimize viscoelastic effects, two preconditioning cycles were applied to the specimens followed by a third cycle from which the data were analyzed (Wilke, Wenger, & Claes, 1998). Spine motion was captured using an Optotrak Certus motion tracking system

(NDI, Waterloo, ON). Rigid body smart markers were attached to the cranial and caudal potting fixtures holding the respective ends of the free motion segment. Bony landmarks on each vertebrae were digitized to create local bone coordinate systems to determine anatomic rotations using Euler angle analysis (N R Crawford & Dickman, 1997).

To establish baseline motions, the specimens were initially tested in an intact, or pre-injury state. Subsequently, using a previously validated technique, (Melissa Nadeau, McLachlin, Bailey, Gurr, & Dunning, Cynthia E Bailey, 2012) a unilateral facet perch (UFP) injury in the right facet joint at C5-C6 was simulated. To generate this injury, the following structures were sectioned: both facet capsules, the right half of the ligamentum flavum, the complete left annulus and the anterior half of the right annulus. The remaining tissues were additionally stretched to a unilateral perched position through manual rotation and then rotated back to the initial position. The motion of the injured specimens was then evaluated prior to surgical fixation. Instrumented stabilization consisted of a standardized ACDFP surgical protocol using two different plate lengths: a shorter (22.5mm) and longer (32.5mm) version of the same plate (Atlantis, Medtronic, Memphis, TN) (Figure 2). For each ACDFP procedure, a standard (12mm wide x 10mm deep x 5mm height) Delrin™ plastic graft was inserted into the intervertebral space and testing of plate size was randomized. The plate was secured to the vertebrae using 4.0mm diameter x 13.0mm length locking screws applied with a constant insertional torque (0.3Nm) measured with a torque-limiting screwdriver (Ryken, Clausen, Traynelis, & Goel, 1995). To conduct the repeated-measures testing of the two plate lengths, four screw holes were made in both the cranial and caudal vertebrae. Due to the potentially compromised bone integrity from insertion of the four screws, the screw holes were augmented with approximately 2mL of PMMA bone cement (Simplex P, Stryker, Kalamazoo, MI) (Yao et al., 2014).

Repeated measures ANOVAs were conducted to determine the effect that each condition had on the absolute range of motion, for each type of movement independently. Post-hoc testing was performed with a Bonferonni adjustment and statistical significance was accepted at an alpha level of 0.05 for all statistical analyses. All statistical tests were conducted with SPSS software version 21 (IBM corporation, Armonk, NY).

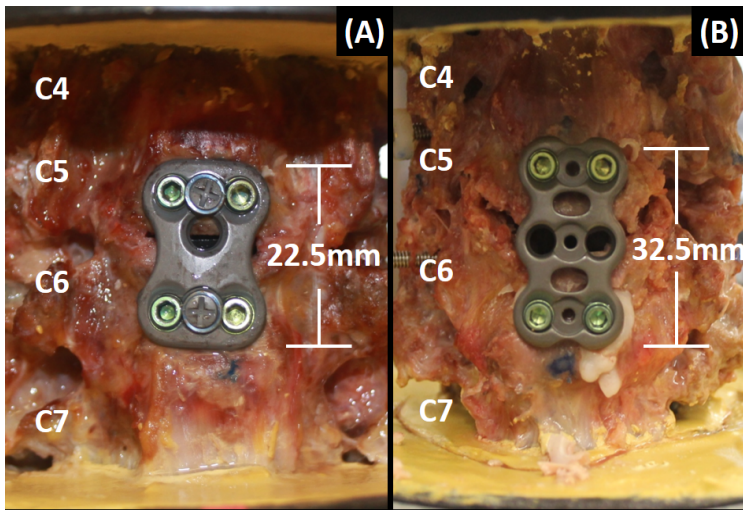


Figure 2: Placement of the 22.5 mm (A) and the 32.5 mm (B) ACDFP plates. Delrin® spacers were used as a bone graft surrogate. Cement was added to improve fixation during repeated tests.

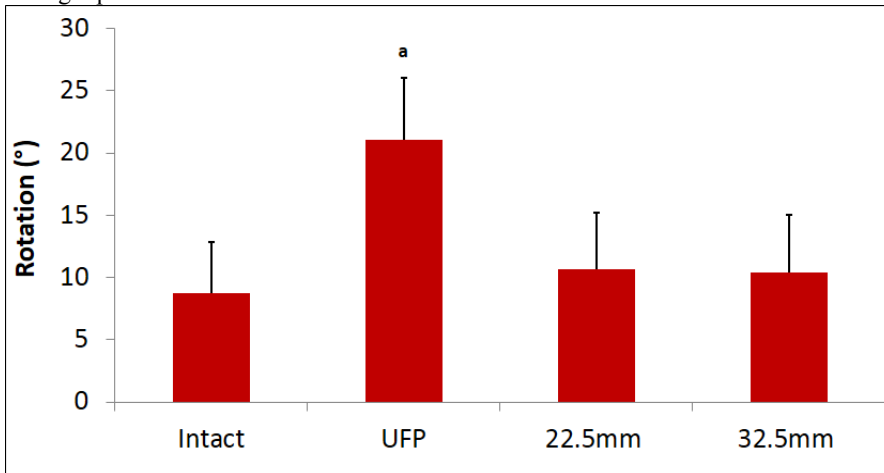


Figure 3: Comparison of the axial rotation mean range of motion across the four conditions (^a significantly different than all other conditions at $p < 0.05$).

2.3 RESULTS

Experimental testing in this study was completed without incident; all specimens except one were examined in the intact, injured, and two ACDFP scenarios. The specimen that was removed from testing had an autofusion that was not detected by the CT screening. Data for the flexion-extension and axial rotation trials of one specimen was also corrupted following testing and was excluded. Therefore, data analysis was performed using 10 specimens for lateral bending and 9 specimens for axial rotation and flexion-extension.

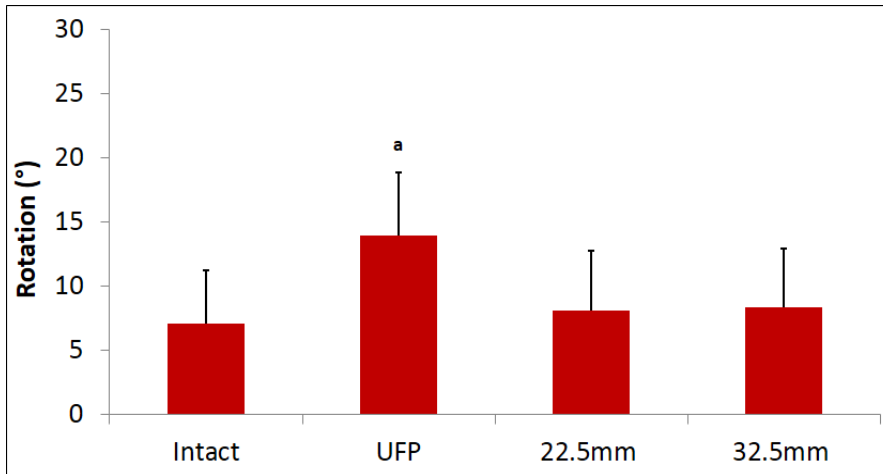


Figure 4: Comparison of the lateral bending mean range of motion across the four conditions (a) significantly different than all other conditions at $p < 0.05$).

Overall, the UFP injury produced significantly greater motions compared to all other conditions for flexion-extension ($p < 0.001$), lateral bending ($p < 0.001$) and axial rotation ($p < 0.001$). Although there was a decrease in axial rotation (Figure 3) and lateral bending (Figure 4), when both plates were compared to the pre-injury state, the differences were not significant. In contrast however, with respect to for flexion-extension (Figure 5), both plates contributed to a significant 2.5° decrease in the ROM, compared to the pre-injury state ($p < 0.001$). Finally, there no significant differences were identified in the kinematic stability between the two plates for any of the three motions tested.

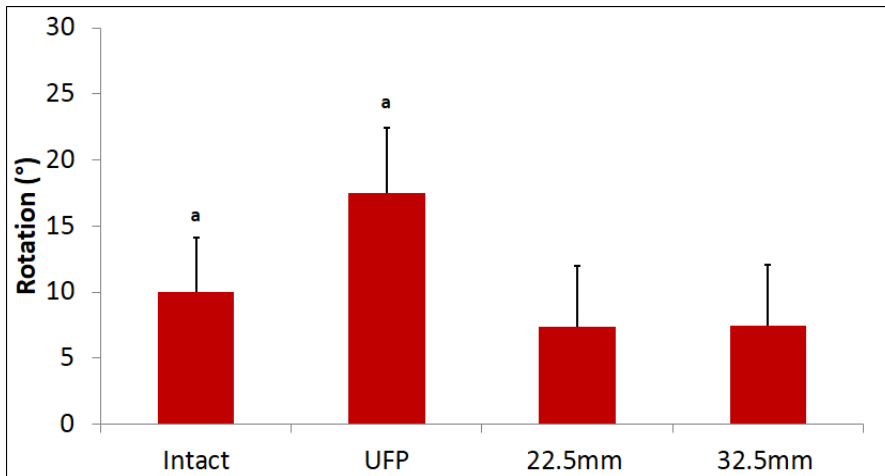


Figure 5: Comparison of the flexion-extension mean range of motion across the four conditions (a) significantly different than all other conditions at $p < 0.05$).

2.4 DISCUSSION

The aim of the current investigation was to determine the role of plate length on the kinematic stability of the ACDFP approach for instrumented fixation of a unilateral cervical facet dislocation type injury. It was hypothesized that an undersized plate would lead to reduced stability in all motions. However, the results from this work rejected the proposed hypothesis as no difference was identified between the larger (32.5mm) and smaller (22.5mm) plate lengths for any of the motions tested. This could be explained by the concept that the fixation points (i.e., the location of the screw-plate-bone interface) for both plates are located well beyond the fulcrum of intervertebral motion (Penning, 1978).

Previous research on this topic has suggested that plate fixation close to the adjacent disc level is associated with adjacent level ossification. Therefore, avoiding the use of a larger plate when setting a facet fracture-dislocation may prevent ossification in these areas. Park et al. who retrospectively studied lateral radiographs of 116 patients with fusion post ACDFP, showed that the plate to disc distance is directly related to adjacent level ossification and proposed a minimum plate to disc distance of 5mm to reduce the likelihood of this complication (J.-B. Park, Cho, & Riew, 2005). Larger plates may also increase the chance of adjacent level degeneration if they produce an anterior

longitudinal ligament or annulus fibrosis insufficiency, which may adversely affect the motion of the segment. Although there are many factors that play a role in the complex issue of post fusion adjacent level degeneration (e.g., number of levels fused, cervical alignment, level of fusion), the results presented in the current study suggest that shorter plates maintain the stability of the injured level while avoiding the risks associated with larger plates (Johnson et al., 2004; J. Y. Park et al., 2013).

Another important surgical complication associated with plate size is hardware failure. Johnson et al. reported a 13 % radiographic failure rate in the setting of a facet fracture with a concomitant fracture of the superior end plate in the caudal vertebra (Johnson et al., 2004). They noted that the majority of failures involved the pullout of the inferior screws and suggested an inverse correlation with failure and the distance between the inferior end plate and the lower screw. Although this is not consistent with current findings, the model used in this study was a fracture-dislocation that did not include an end plate fracture. Whether the addition of a destabilizing fracture would significantly influence the results of this study is not known but these results should not be generalized to this patient presentation.

ACDFP achieved a more stable construct when compared to the pre-injured state for flexion-extension but was unable to limit motion by a similar magnitude for axial rotation or lateral bend. This finding is consistent with previous biomechanical studies utilizing a facet fracture-dislocation model (Melissa Nadeau et al., 2012). Although the current study did not find plate length to influence ROM for axial rotation or lateral bend, undersizing the graft has previously been shown to provide greater stability because it results in both an increased overlapping of the inferior and superior articular processes of the cephalad and caudal vertebrae respectively and locking of the uncovertebral joints (Yao et al., 2014).

There are some potential limitations associated with this study that require consideration. The testing performed here used only a single plate fixation system (Atlantis, Medtronic) and may not extrapolate to all fixation devices. Another consideration that was not explored in this work is the stabilizing role of the spinal musculature. Presumably though the stabilizing effect of the musculature would have had a similar effect for all testing conditions and therefore minimize the confounding

effect on our results. Some of the specimens were also osteoporotic and screw purchase achieved was not optimal. To overcome this issue, the screws tracks were cemented prior to plate attachment so to minimize the potential for loosening at the screw-bone interface. Finally, while this work reflects immediate postoperative construct stability, it did not assess the stability associated with cyclic loading to failure that may be more representative of *in vivo* loading patterns.

In conclusion, the size of the plate used in an ACDFP procedure does not significantly affect the ROM of a C5-C6 motion segment subjected to a simulated facet dislocation. Based on these findings it can be advised that using a smaller plate is appropriate to reduce the potential risk of adjacent level degeneration while improving satisfactory stability.

2.5 REFERENCES

- Allen, B. L., Ferguson, R. L., Lehmann, T. R., & O'Brien, R. P. (1982). A mechanistic classification of closed, indirect fractures and dislocations of the lower cervical spine. *Spine*, 7(1), 1–27.
- Crawford, N. R., & Dickman, C. A. (1997). Construction of local vertebral coordinate systems using a digitizing probe. Technical note. *Spine*, 22(5), 559–63.
- Crawford, N. R., Duggal, N., Chamberlain, R. H., Park, S. C., Sonntag, V. K. H., & Dickman, C. A. (2002). Unilateral cervical facet dislocation: injury mechanism and biomechanical consequences. *Spine*, 27(17), 1858–1864.
- Duggal, N., Chamberlain, R. H., Park, S. C., Sonntag, V. K. H., Dickman, C. A., & Crawford, N. R. (2005). Unilateral cervical facet dislocation: biomechanics of fixation. *Spine*, 30(7), E164–168.
- Dvorak, M. F., Fisher, C. G., Aarabi, B., Harris, M. B., Hurlbert, R. J., Rampersaud, Y. R., ... Fehlings, M. G. (2007). Clinical outcomes of 90 isolated unilateral facet fractures, subluxations, and dislocations treated surgically and nonoperatively. *Spine*, 32(26), 3007–3013.
- Dvorak, M. F., Fisher, C. G., Fehlings, M. G., Rampersaud, Y. R., Oner, F. C., Aarabi, B., & Vaccaro, A. R. (2007). The surgical approach to subaxial cervical spine injuries: an evidence-based algorithm based on the SLIC classification system. *Spine*, 32(23), 2620–2629.
- Goertzen, D. J., Lane, C., & Oxland, T. R. (2004). Neutral zone and range of motion in the spine are greater with stepwise loading than with a continuous loading protocol. An in vitro porcine investigation. *Journal of Biomechanics*, 37(2), 257–261.
- Henriques, T., Olerud, C., Bergman, A., & Jónsson, H. (2004). Distractive flexion injuries of the subaxial cervical spine treated with anterior plate alone. *Journal of Spinal Disorders & Techniques*, 17(1), 1–7.
- Johnson, M. G., Fisher, C. G., Boyd, M., Pitzen, T., Oxland, T. R., & Dvorak, M. F. (2004). The radiographic failure of single segment anterior cervical plate fixation in traumatic cervical flexion distraction injuries. *Spine*, 29(24), 2815–2820.
- Kwon, B. K., Fisher, C. G., Boyd, M. C., Cobb, J., Jebson, H., Noonan, V., ... Dvorak, M. F. (2007). A prospective randomized controlled trial of anterior compared with posterior stabilization for unilateral facet injuries of the cervical spine. *Journal of Neurosurgery Spine*, 7(1), 1–12.

- Lambiris, E., Zouboulis, P., Tyllianakis, M., & Panagiotopoulos, E. (2003). Anterior surgery for unstable lower cervical spine injuries. *Clinical Orthopaedics and Related Research*, (411), 61–9.
- Nadeau, M., McLachlin, S. D., Bailey, S. I., Gurr, K. R., Dunning, C. E., & Bailey, C. S. (2012). A biomechanical assessment of soft-tissue damage in the cervical spine following a unilateral facet injury. *Journal of Bone and Joint Surgery*, 94(21), e156.
- Nadeau, M., McLachlin, S. D., Bailey, S. I., Gurr, K. R., & Dunning, Cynthia E Bailey, C. S. (2012). Evaluation of Instrumentation Techniques for a Unilateral Facet Fracture Dislocation Using a Validated Soft Tissue Injury Model. In *12th Annual Scientific Conference of the Canadian Spine Society*. Sun Peaks, BC, Canada.
- Ordonez, B. J., Benzel, E. C., Naderi, S., & Weller, S. J. (2000). Cervical facet dislocation: techniques for ventral reduction and stabilization. *Journal of Neurosurgery*, 92(1 Suppl), 18–23.
- Panjabi, M. (1992). The stabilizing system of the spine. Part II. Neutral zone and instability hypothesis. *Journal of Spinal Disorders*.
- Park, J. Y., Kim, K. H., Kuh, S. U., Chin, D. K., Kim, K. S., & Cho, Y. E. (2013). What are the associative factors of adjacent segment degeneration after anterior cervical spine surgery? Comparative study between anterior cervical fusion and arthroplasty with 5-year follow-up MRI and CT. *European Spine Journal : Official Publication of the European Spine Society, the European Spinal Deformity Society, and the European Section of the Cervical Spine Research Society*, 22(5), 1078–89.
- Park, J.-B., Cho, Y.-S., & Riew, K. D. (2005). Development of adjacent-level ossification in patients with an anterior cervical plate. *The Journal of Bone and Joint Surgery. American Volume*, 87(3), 558–63.
- Penning, L. (1978). Normal movements of the cervical spine. *American Journal of Roentgenology*, 130(2), 317–326.
- Pitzen, T., Lane, C., Goertzen, D., Dvorak, M., Fisher, C., Barbier, D., ... Oxland, T. (2003). Anterior cervical plate fixation: biomechanical effectiveness as a function of posterior element injury. *Journal of Neurosurgery Spine*, 99(1 Suppl), 84–90.
- Rasoulinejad, P., McLachlin, S. D., Bailey, S. I., Gurr, K. R., Bailey, C. S., & Dunning, C. E. (2012). The importance of the posterior osteoligamentous complex to subaxial cervical spine stability in relation to a unilateral facet injury. *The Spine Journal*, 12(7), 590–595.

- Ryken, T. C., Clausen, J. D., Traynelis, V. C., & Goel, V. K. (1995). Biomechanical analysis of bone mineral density, insertion technique, screw torque, and holding strength of anterior cervical plate screws. *Journal of Neurosurgery*, 83(2), 325–329.
- Sim, E., Vaccaro, A. R., Berzlanovich, A., Schwarz, N., & Sim, B. (2001). In vitro genesis of subaxial cervical unilateral facet dislocations through sequential soft tissue ablation. *Spine*, 26(12), 1317–1323.
- Vaccaro, A. R., Madigan, L., Schweitzer, M. E., Flanders, A. E., Hilibrand, A. S., & Albert, T. J. (2001). Magnetic resonance imaging analysis of soft tissue disruption after flexion-distraction injuries of the subaxial cervical spine. *Spine*, 26(17), 1866–1872.
- Wilke, H. J., Wenger, K., & Claes, L. (1998). Testing criteria for spinal implants: recommendations for the standardization of in vitro stability testing of spinal implants. *European Spine Journal*, 7(2), 148–154.
- Yao, R., McLachlin, S. D., Rasoulinejad, P., Gurr, K. R., Siddiqi, F., Dunning, C. E., & Bailey, C. S. (2014). Influence of graft size on spinal instability with anterior cervical plate fixation following in vitro flexion-distraction injuries. In *60th Annual Meeting of the Orthopaedic Research Society*. New Orleans, LA, USA.

3 CHAPTER 3:

OVERVIEW: This chapter contains general discussion, the results of this work, final conclusion and future directions

3.1 GENERAL DISCUSSION:

The aim of our study was to determine if plate length significantly alters the biomechanical kinematics of ACDFP when stabilizing a unilateral cervical facet dislocation. This is a unique injury type that had come under focus recently with multiple

studies, investigating different treatment options (M. Dvorak, Vaccaro, Hermsmeyer, & Norvell, 2010; Nadeau et al., 2012). Fusion is the ultimate goal for any surgical intervention which can be done either by an anterior or posterior approach (Kwon et al., 2007). To ensure a fusion a stable construct must be established. For an ACDFP it was hypothesized that, an undersized plate would lead to reduced stability in all three motion planes, This is particularly relevant however for the motion of flexion and extension because previous work has demonstrated that under sizing the disc space during reconstruction for a unilateral facet injury adversely effects stability in the sagittal plane. However, an undersized graft has been demonstrated to increase the stability of the ACDFP for both lateral bend and axial rotation. Therefore, with respect to this investigation, if a longer plate off-sets the adverse effect of under sizing the disc space graft in flexion-extension, then the advantages of using a undersized graft in lateral bend and axial rotation (as previously demonstrated) would be maintained. This would lead to an overall stronger biomechanical construct.

We tested the specimens in the intact state and found that the ROM between specimens varied. This was not unexpected as the ages of specimens ranged from 59 to 80 years of age, which resulted in varying degrees of stiffness as a result of varying severities of degenerative disc disease and arthritis. In fact, the pre-testing CT analysis found that some specimens had autofused, and had to be disqualified. The advantage of including older specimens is that it allowed the results of the investigation to be more broadly generalized to adults with different pre-morbid cervical motion.

The injury model for cervical flexion distraction injuries used was developed and validated in our lab (S. McLachlin et al., 2012), We were successful in generating this injury and as a result in increasing expected ROM in all specimens. This result confirmed our first hypothesis.

Our experimental hypothesis was that a small plate would result in less stability across all three planes of motion. However, this hypothesis was rejected since our results showed no significant difference between the large and small plates in all ranges of motion. ACDFP achieved a more stable construct than the pre-injury state for Flexion/Extension. This is well known that the plate will be the predominant stabilizer in Flexion/Extension.

ROM following ACDFP was not significantly different than intact for AR and LB. This finding is also consistent with that of previous studies using the same injury model (McLachlin, Nadeau, Bailey, Gurr, & Dunning, 2012). This result is particularly relevant when considering that the size of the graft may play a significant role in stabilizing the construct, as previously demonstrated in our lab (Yao et al., 2014). It was shown that changing the graft size effects locking of the uncovertebral joints resulting in a more stable construct when a smaller graft size is used. However, it is the author and mentors clinical experience that it is often difficult to “undersize” the intervertebral graft without it becoming displaced in the face of a significant facet fracture-dislocation. Therefore, it is frequent that larger than wanted grafts are utilized which leads to a potentially less stable construct in AR and LB. These are motions that are shown in this work (and others) to be less adequately stabilized with an anterior cervical plate construct. Furthermore, the work has demonstrated that increasing the plate size will not improve the stability of the construct.

The fact that no significant difference in ROM was demonstrated between plate sizes might be explained by the fact that both plates fixation points are beyond the fulcrum of motion of the vertebrae. The last hypothesis was to examine the stability of the construct post ACDFP; as previously discussed this work shows that a plate needs be only large enough to span the disc space (other factors being equal such as adequate bone quality for screw engagement) to be sufficient for regaining stability of a subaxial motion segment post unilateral facet injury

Whether to use a large plate is clinically relevant since it has been proven in the literature to be associated with adjacent level ossification. Park Jb et al. retrospectively studied lateral radiographs of 116 patients who had solid fusion post ACDFP and showed that the plate to disc distance (PDD) is directly related to adjacent level ossification and proposed to have at least 5mm PDD so to reduce the likelihood of adjacent level ossification. The effect of changing the plate size on the stability of the construct was poorly investigated, as there was concern that small plates might result in suboptimal stability, hence negatively affecting the chance of fusion. Although larger plates may

increase the chances of adjacent level degeneration there are many factors that play a role in this complex issue, including: number of levels fused, cervical alignment, and level of fusion (Yang, Li, Zhang, He, & Xu, 2012). We believe that using a large plate may result in damage to the anterior longitudinal ligament of adjacent level, negatively affecting its stability, which may be a further reason why those levels fail. Further complication this matter is that although adjacent level ossification or degeneration can occur its not always symptomatic. Carrier CS et al did a systematic review to evaluate adjacent segment degeneration, and the rate of symptomatic adjacent level disease. He found the rate of adjacent segment degeneration to be as high as 47 % whereas symptomatic adjacent level disease was around 11%. This illustrates that not all adjacent level degeneration can result in symptomatic disease (Carrier, Bono, & Lebl, 2013). With the invention of cervical arthroplasty it was hoped that the chances of adjacent level disease would reduce, however it didn't significantly lower the rate of adjacent level disease (Park et al., 2013; Yang et al., 2012). The question remains as to whether this is a phenomena related to fusion or it's a natural, inherent process of degeneration. The level of evidence in this matter is still lacking and more research needs to be done to investigate it.

Another important complication that might be influenced by plate size is hardware failure. Johnson mg et al. reported a 13% radiographic failure rate when the bilateral facet fracture had concomitant fracture of the superior endplate of the caudal vertebra involved in the injury (Johnson et al., 2004). They also noted that most failures involved the pullout of the caudal vertebra fused with screws cutting out inferiorly. They suggested an inverse correlation between construct failure and the distance between the inferior end plate and the lower screw. Lowery et al studied the hardware failure in anterior cervical plate fixation to show that hardware failure is associated with multiple fusion levels; the more levels fused the higher the chance of fusion. Interestingly he found that most instrumentation failures occurred after failure of the graft to achieve union, proving that the non-union is the cause of failed hardware (Lowery & McDonough, 1998).

New techniques has recently been introduced to manage cervical flexion distraction injuries., This involves the use of an interbody spacer with a locked screw mechanism.

This technique has been used for degenerative disc disease however there was a recent biomechanical study by Wojewnik *et al* evaluated the stability of these devices in the locked screw configuration. They found a 66% reduction in Flexion Extension ROM in injured specimens. They claim this is satisfactory and advise to use it in the sitting of trauma with the addition of external immobilization with a collar (Wojewnik et al., 2013). This technique may be the future standard of care for cervical fusion as it is low profile, with potentially fewer complications than ACDFP and less technically demanding. It might also prove to have a lower rate of adjacent level degeneration, as there is less chance of injury to anterior longitudinal ligament. Until further evidence is available the standard of care will remain ACDFP and the importance of this work will remain valuable.

3.2 LIMITATIONS

There are some potential limitations associated with this study that require consideration. The testing performed here used only a single plate fixation system (Atlantis, Medtronic) and may not extrapolate to all fixation devices. Another consideration that was not explored in this work is the stabilizing role of the spinal musculature. Presumably though the stabilizing effect of the musculature would have had a similar effect for all testing conditions and therefore minimize the confounding effect on our results. Some of the specimens were also osteoporotic and screw purchase achieved was not optimal. To overcome this issue, the screws tracks were cemented prior to plate attachment so to minimize the potential for loosening at the screw-bone interface. Finally, while this work reflects immediate postoperative construct stability, it did not assess the stability associated with cyclic loading to failure that may be more representative of *in vivo* loading patterns.

3.3 CONCLUSION:

The size of the plate used in an ACDFP procedure does not significantly affect the ROM of a C5-C6 motion segment subjected to a simulated facet dislocation. The stability is achieved by restoring alignment through graft plate interaction. Based on these

findings it can be advised that using a smaller plate is appropriate to reduce the potential risk of adjacent level degeneration while providing satisfactory stability.

3.4 FUTURE DIRECTIONS:

This model of testing can be utilized to investigate new surgical techniques not yet tested for traumatic injury like the above-mentioned interbody Devices, as biomechanical literature in this field is still lacking. Also, whether an interaction exists between the influence of graft height and plate length on segmental spinal stability should be a focus of future work. Another important factor that needs to be studied is the fracture morphology and its effect on the stability of the construct.

3.5 REFERENCES:

Carrier, C. S., Bono, C. M., & Lebl, D. R. (2013). Evidence-based analysis of adjacent segment degeneration and disease after ACDF: A systematic review. *The Spine Journal : Official Journal of the North American Spine Society*, 13(10), 1370-1378.

- Dvorak, M., Vaccaro, A. R., Hermsmeyer, J., & Norvell, D. C. (2010). Unilateral facet dislocations: Is surgery really the preferred option?. *Evidencebased Spinecare Journal*, 1(1), 57-65.
- Dvorak, M. F., Pitzen, T., Zhu, Q., Gordon, J. D., Fisher, C. G., & Oxland, T. R. (2005). Anterior cervical plate fixation: A biomechanical study to evaluate the effects of plate design, endplate preparation, and bone mineral density. *Spine*, 30(3), 294-301.
- Johnson, M. G., Fisher, C. G., Boyd, M., Pitzen, T., Oxland, T. R., & Dvorak, M. F. (2004). The radiographic failure of single segment anterior cervical plate fixation in traumatic cervical flexion distraction injuries. *Spine*, 29(24), 2815-2820.
- Kwon, B. K., Fisher, C. G., Boyd, M. C., Cobb, J., Jebson, H., Noonan, V., . . . Dvorak, M. F. (2007). A prospective randomized controlled trial of anterior compared with posterior stabilization for unilateral facet injuries of the cervical spine. *Journal of Neurosurgery Spine*, 7(1), 1-12.
- Lowery, G. L., & McDonough, R. F. (1998). The significance of hardware failure in anterior cervical plate fixation. patients with 2- to 7-year follow-up. *Spine*, 23(2), 181-6; discussion 186-7.
- McLachlin, S. D., Nadeau, M., Bailey, C. S., Gurr, K. R., & Dunning, C. E. (2012). *Evaluation of instrumentation techniques for a unilateral facet fracture using a validated soft Tissue Injury modell. canadian spine society 12th annual meeting, sun peaks, canada.*

- Nadeau, M., McLachlin, S. D., Bailey, S. I., Gurr, K. R., Dunning, C. E., & Bailey, C. S. (2012). A biomechanical assessment of soft-tissue damage in the cervical spine following a unilateral facet injury. *Journal of Bone & Joint Surgery - American Volume*, 94(21), e156.
- Park, J. Y., Kim, K. H., Kuh, S. U., Chin, D. K., Kim, K. S., & Cho, Y. E. (2013). What are the associative factors of adjacent segment degeneration after anterior cervical spine surgery? comparative study between anterior cervical fusion and arthroplasty with 5-year follow-up MRI and CT. *European Spine Journal : Official Publication of the European Spine Society, the European Spinal Deformity Society, and the European Section of the Cervical Spine Research Society*, 22(5), 1078-1089.
- S. McLachlin, M. Nadeau, S., Bailey, K. Gurr K, C. Bailey, & C. Dunning. (2012). *Development of a soft tissue injury model for a unilateral facet perch in the cervical spine. canadian orthopaedic research society annual meeting, ottawa, canada.*
Unpublished manuscript.
- Wojewnik, B., Ghanayem, A. J., Tsitsopoulos, P. P., Voronov, L. I., Potluri, T., Havey, R. M., . . . Patwardhan, A. G. (2013). Biomechanical evaluation of a low profile, anchored cervical interbody spacer device in the setting of progressive flexion-distraction injury of the cervical spine. *European Spine Journal*, 22(1), 135-141.
- Yang, B., Li, H., Zhang, T., He, X., & Xu, S. (2012). The incidence of adjacent segment degeneration after cervical disc arthroplasty (CDA): A meta analysis of randomized

controlled trials. *PloS One*, 7(4), e35032. doi:10.1371/journal.pone.0035032;
10.1371/journal.pone.0035032

Yao, R., Rasoulinejad, P., Gurr, K. R., Dunning, C. E., & Bailey, C. S. (2014). Influence of graft size on spinal instability with anterior cervical plate fixation following in vitro flexion-distraction injuries. . *In 60th Annual Meeting of the Orthopaedic Research Society. New Orleans, LA, USA.*,

4 APPENDIX A GLOSSARY

Allen-Ferguson System: a classification system for cervical spine trauma based on the describe mechanism of injury

Allograft: The transplant of an organ or tissue from one individual to another of the same species

Annulus Fibrosus: ring of fibrous tissue that encloses the intervertebral disc

Anterior: In the front of an object

Arthrodesis: the process were the joint is removed and replaced by a fusion mass

Articular: Joint related or part of a joint

Atlas: first cervical vertebra.

Autograft: The transplant of an organ or tissue within the same individual

Axial Rotation: rotation of the spine about the superior-inferior axis

Axis: second cervical vertebra

Caudal: situated beneath or inferior toward the foot

Cephalic: situated above or superior toward the head

Cervical Spine: the seven vertebrae of the neck

Corpectomy: the surgical procedure where part of the vertebra or a whole vertebra removed.

Discectomy: surgical procedure where part of the intervertebral disc is removed

Discoligamentous: the intervertebral disc and surrounding ligaments

Dislocation: displacement of one or more bones at a joint

Distraction: severe separation of two vertebrae

Euler Angles: to describe the orientation of three angles to define the dimension of an object

Extension: rotation of the spine in an anterior-posterior direction around an axis

Facet Joints: a joint structure that connects two vertebrae through articular process

Finite Helical Axis: a vector which defines the axis of rotation of a moving object

Flexion: rotation of the spine about the medial-lateral axis in an anterior direction

Foramen: an opening through a bone which nerves, arteries, veins, *etc.* pass through

Fracture: the act or process of breaking or the state of being broken

Fusion: surgical immobilization of a joint resulting in bony union across it

Graft: to implant tissue or organ in a living body

Inferior: in anatomy, used in reference to the lower surface of a structure, or to the lower of two (or more) similar structures

In Vitro: term describes procedure outside the living organism

In Vivo: within the living organism

Intervertebral Disc: tough elastic discs that are interposed between adjacent vertebrae

Kinematics: the branch of mechanics that studies motion of one body with respect to another without external forces

Lateral: toward the side of an object

Lateral Bending: rotation of the spine about the anterior-posterior axis to left or right sides

Laxity: state of being lax or loose

Medial: situated towards the mid-line or the middle of the body

MRI: magnetic resonance imaging

Neutral Zone: region of no or little resistance to motion

Nucleus Pulposus: gel-like substance in the middle of the intervertebral disc

Occiput: posterior region of the skull

Osseous: bony

Osteoarthritis: a non-inflammatory degenerative joint disease of the skeletal system, its articulations, and associated structures

Osteoligamentous: both the bone (osseous) and ligaments structures combined

Osteophyte: bony outgrowth caused by an inflammatory or degenerative process

Perched facet: excessive subluxation of inferior articular process on the superior articular process of the adjacent vertebra below immediately prior to dislocation

Posterior: situated behind toward the back

Proximal: situated in the beginning or near a point of attachment

Range of Motion: the full range of motion achieved by a motion

Sagittal Plane: the vertical passes anterior toposterior, divides the body into left and right lateral sides

Six Degree-of-Freedom: Six degrees of freedom refers to the freedom of movement of a rigid body in three-dimensional space

Subaxial: cervical vertebrae below the Axis (C2)

Subluxation: partial dislocation of a joint

Superior: above, or directed upward

Synovial Joint: a joint surrounded by a capsule that is filled with a lubricating fluid

Transverse Plane: an imaginary plane that divides the body into superior and inferior parts

Unilateral: affecting one side of the body

Vertebra(e): bones that make up the spinal column

5 Appendix B Raw Data from the experiments

Specimen	Intact	Injured	Small Plate	Large Plate
Specimen 1	7.05	24.58	8.48	10.58
Specimen 2	4.03	19.4	7.74	6.99
Specimen 3	10.53	13.54	6.35	6.68
Specimen 4	6.02	20.05	6.51	7.02
Specimen 6	9.54	24.44	17.95	18.11
Specimen 7	17.12	26.55	17.69	17.83
Specimen 8	4.61	16.26	7.63	7.22
Specimen 9	12.02	27.82	9.78	11.74
Specimen 11	7.74	17.21	13.47	7.41

Table 1 AXIAL ROTATION ROM

Specimen	Intact	Injured	Small Plate	Large Plate
Specimen 1	9.44	24.51	9.29	8.43
Specimen 2	11.19	17.74	7.56	9.66
Specimen 3	9.11	18.56	6.09	7.44
Specimen 4	5.81	14.81	5.21	5.19
Specimen 6	9.82	16.2	6.18	6.01
Specimen 7	12.7	15.24	8.44	7.27
Specimen 8	5.58	14.39	4.53	3.97
Specimen 9	16	20.44	10.63	10.66
Specimen 11	10.33	15.51	8.26	8.2

Table 2 FLEXION EXTENSION ROM

Specimen	Intact	Injured	Small Plate	Large Plate
Specimen 1	6.43	18.79	8.65	6.77
Specimen 2	6.53	17.14	13.53	14.89
Specimen 3	4.9	9.52	4.15	3.6
Specimen 4	5.6	13.39	7.72	6.97
Specimen 6	8.99	13.45	11.74	7.23
Specimen 7	10.5	14.73	9.35	13.59
Specimen 8	6.53	9.15	6.09	5.51
Specimen 9	2.97	12.95	5.01	4.32
Specimen 11	13.17	20.26	10.08	14.77
Specimen 12	5.52	9.71	4.96	5.52

Table 3 LATERAL BENDING ROM

CURRICULUM VITAE

Name: Abdulaziz Alkuwari MD

Post-secondary Education and Degrees: Royal college of surgeons in Ireland
Dublin, Ireland
Bachelor of science,
Bachelor of surgery,
Bachelor of medicine,
Bachelor of obstetrics and
gynecology.
1999-2005 . MB BCh BAO Degree

Arab Board Orthopaedic Surgery
Doha, Qatar
2005-2012. ABOS

The University of Western Ontario
London, Ontario, Canada
2012-2014 Spine fellowship.

Honours and Awards: Province of Ontario Graduate Scholarship
1993-1994, 1994-1995

Related Work Experience Spine Fellow
The University of Western Ontario
2012-2014

Publications:

Al-Hassani, A., Abdulrahman, H., Afifi, I., Almadani, A., Al-Den, A., Al-Kuwari, A., et al. (2010). Rib fracture patterns predict thoracic chest wall and abdominal solid organ injury. The American Surgeon, 76(8), 888-891.

OTHER ABSTRACTS AND PRESENTATIONS

Professional Society Memberships AO Spine 2011-2013
Arab Spine society 2014

Courses and conferences

June 2006	Basic Life Support .
Feb 2006	Basic surgical skills.
June 2006	Time management workshop.
May 2005	HMC General Orientation Program: Includes health and safety regulations, Recruitment and Development Performance Management, Quality Management, Patient Family Rights, Radiation Safety, Infection Control, And Occupational Health and Safety.
Aug 2005	Patient Doctor Communication skills workshop.
Aug 2006	Advanced trauma life support
Nov 2007	Bowel anastomosis workshop.
Aug 2009	Advanced vascular anastomosis workshop.
Nov 2010	PAN ARAB Orthopedic conference
Apr 2010	Advanced Orthopedic Trauma management Verona, Italy.
Nov 2010	AO principles Dubai.
May 2011	Stryker Middle East spine symposium.
June 2011	Johns Hopkins orthopedic review course. Baltimore USA
Dec 2011	AOSPINE advanced –Degenerative lumbar spine, deformities and tumors

Davos, Switzerland.

MAR 2012

ARAB BOARD OF Orthopedic Surgery.

May 2012

5th Annual Global Dubai Spine Masters; Complex Spine Reconstruction & and Deformity Management strategies Dubai UAE .