

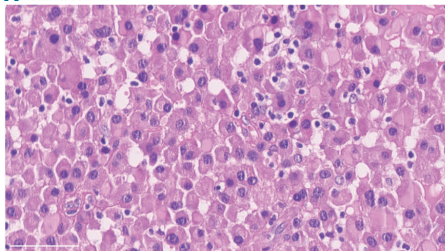
### An immunocompetent patient with a recurrence-free Epstein-Barr virus positive plasmacytoma possesses robust Epstein-Barr virus specific T-cell responses

Plasmacytomas are classified as plasma cell neoplasms and primarily occur in the bone or within soft tissue. Extramedullary plasmacytomas (EMP) represent 3-5% of all plasmacytomas and are commonly found in the upper respiratory tract.<sup>1</sup> Plasmacytomas and other plasma cell neoplasms express CD138 and are CD20 negative based on immunohistochemistry.<sup>2</sup> They are further distinguished from plasmablastic lymphoma (PBL) and marginal zone lymphoma (MZL) by their morphology. Approximately 15% of EMPs progress to plasma cell myeloma,<sup>3</sup> and this transition might be associated with poor immune control. Several studies indicate an association between plasma cell neoplasms and viral infection, especially for human immunodeficiency virus and hepa-

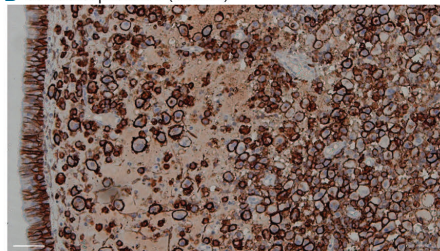
titis C virus, but rarely with Epstein-Barr virus (EBV).<sup>4,6</sup> EBV has been implicated in malignancies in immunocompromised individuals, including PBLs,<sup>7</sup> which are distinct from plasmacytomas and have poorer outcomes. Approximately 17% of plasmacytomas found in the head and neck region are EBV+.<sup>8</sup> CD8+ T cells have been implicated in EBV control. In particular, primary immunodeficiencies that compromise CD8 development, co-stimulation, and effector function predispose individuals to uncontrolled EBV infection;<sup>9</sup> CD8+ T-cell depletion resulted in higher viral loads and tumor burdens in humanized mice<sup>10</sup> and the adoptive transfer of EBV-specific T cells provide favorable outcomes for post-transplant lymphoproliferative disease (PTLD) patients.<sup>11</sup>

EBV is prevalent in more than 90% of the adult human population. EBV maintains lifelong latent infection in memory B cells from which it periodically reactivates.<sup>11</sup> EBV expresses more than eighty lytic gene products and only eight latent EBV antigens.<sup>12</sup> There are several latency

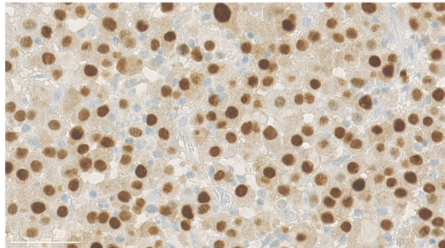
**A** H & E section



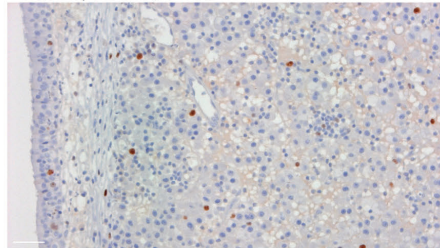
**B** CD138 expression (brown)



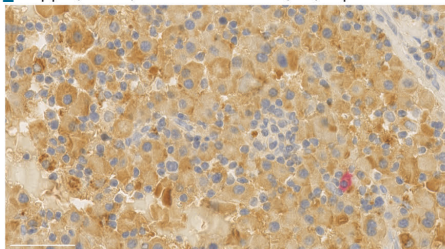
**C** IRF4 (brown)



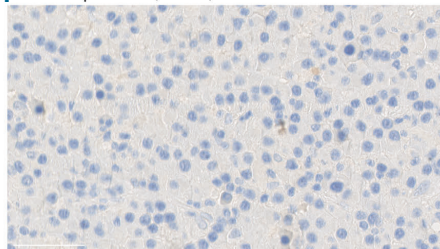
**D** Ki67 expression (brown)



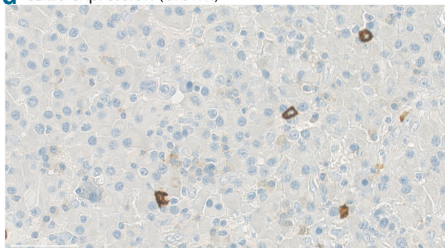
**E** Kappa (brown) and lambda chain (red) expression



**F** PAX5 expression (brown)



**G** CD20 expression (brown)



**Figure 1. Identification of a plasmacytoma.** Immunohistochemistry on paraffin-embedded sections examining H&E staining (A), CD138 expression on the tumor section (brown) (B), IRF4 expression in the nucleus (C), the Ki67 proliferative index as indicated by Mib-1 staining (D), light chain restriction (E), PAX5 expression (F), and CD20 expression (G). Scale bars are 50  $\mu$ m in length. Additional materials and methods can be found in the *Online Supplementary Materials*.

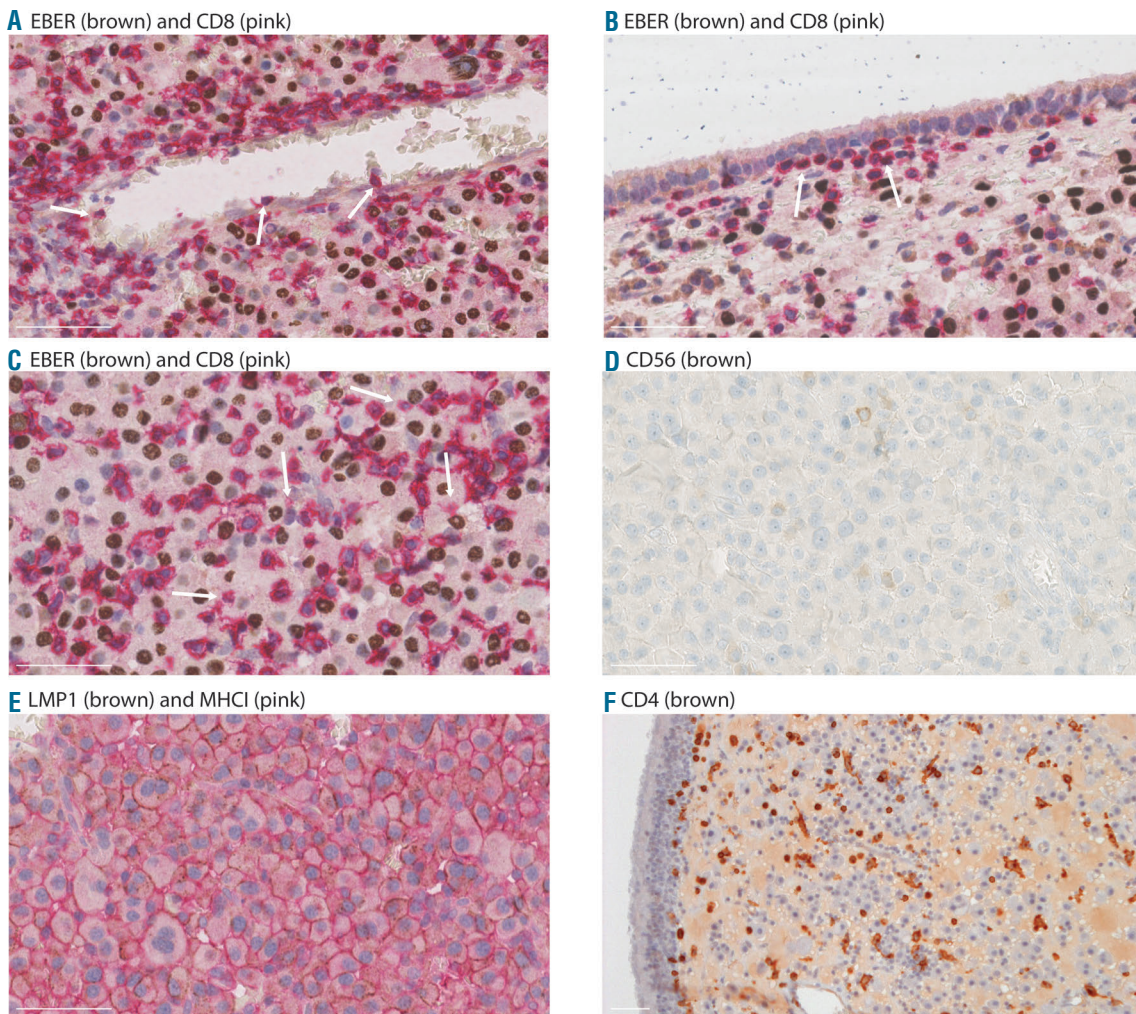
stages (Type III, II, I/0) that are distinguished as follows: all eight latent proteins (EBNA-1, -2, -3A-C, -LP, LMP1, and 2) are expressed by proliferative B cells during latency type III; type II latency is characterized by the expression of LMP1/2 and EBNA1, while type I latency is characterized by EBNA1 alone.

The immunology of EBV<sup>+</sup> plasmacytomas has not been extensively studied. Loghavi *et al.* described four patients with EBV<sup>+</sup> plasmacytomas that were EBER<sup>+</sup>, LMP1<sup>-</sup>, and had CD8<sup>+</sup> tumor infiltrates.<sup>13</sup> Interestingly, while they proposed that the infiltrating CD8<sup>+</sup> T cells might result in favorable patient outcomes, they did not assess EBV-specific T-cell reactivity. We have now identified an immunocompetent individual with an EBV<sup>+</sup> plasmacytoma whose tumor and PBMCs have been examined using immunohistochemistry and for EBV-specific T-cell reactivity, respectively, and who continues to be recurrence-free.

Our patient was a 51-year-old immunocompetent

Caucasian Swiss male living in Ghana who had a wart-like tumor in his right nasal cavity that was diagnosed as an EBV<sup>+</sup> extramedullary plasmacytoma in 2014. The laboratory and clinical examinations showed no signs of hypercalcemia, renal insufficiency, peripheral lymphadenopathy, or bone lesions. The patient was mildly anemic (124 g/L) and had slightly decreased peripheral lymphocytes (19.7%). No abnormal protein was found in the urine or blood (immunofixation negative). A staging examination with CT scan showed no systemic involvement. A benign tumor was found incidentally on the left adrenal gland, but without any discernible endocrine effects. This patient has had recurrent malaria infections: one serious infection in 1989, and less serious infections every two to three years thereafter. He is HIV, HBV, and HCV negative, has no transplantation history, and appears immunocompetent.

The tumor was surgically removed from the mucous membranes of the ethmoid sinus and examined by immunohistochemistry. The tumor consisted of medium-



**Figure 2. CD8<sup>+</sup> cells infiltrate the patient EBV<sup>+</sup> plasmacytoma.** Immunohistochemistry on paraffin-embedded sections examining the proximity of EBER<sup>+</sup> cells (brown) with CD8<sup>+</sup> cells (pink) at multiple magnifications and in different areas of the tumor (A-C) as well as CD56 expression (brown) (D). LMP1<sup>+</sup> cells (brown) and MHC class I<sup>+</sup> cells (pink) were examined for obvious MHC class I surface level differences (E). The infiltration and morphology of CD4<sup>+</sup> cells (brown) were examined (F). White arrows indicated CD8<sup>bright</sup> T cells in proximity of blood vessels in A and at the tumor edge in B, and CD8<sup>dim</sup>, possibly NK cells in C. All images are displayed using a 40x magnification. Scale bars are 50 μm in length.

sized cells with round nuclei as well as smaller infiltrating lymphocytes (Figure 1A). The tumor cells expressed both CD138 (Figure 1B) and IRF4 (Figure 1C), indicating the presence of plasma cells. These plasma cells had a mature plasmacytic rather than plasmablastic morphology. We found 10-20% of Ki67<sup>+</sup> proliferating cells (Figure 1D) and the tumor was negative for MYC rearrangement by fluorescence *in situ* hybridization analysis (data not shown), which excluded a PBL diagnosis. The tumor was kappa chain-restricted (Figure 1E) and IgA<sup>+</sup> (data not shown). Importantly, the tumor was PAX5 negative (Figure 1F), cyclin D1 negative (data not shown), and few infiltrating lymphocytes expressed CD20 (Figure 1G). These data together excluded MZL and MALT lymphoma. The tumor was KSHV negative (data not shown), ruling out a solid variant of primary effusion lymphoma. A bone marrow biopsy found a mild, hyporegenerative anemia but no infiltration by malignant plasma cells or other abnormalities, which further supported a plasmacytoma diagnosis. The tumor was EBV<sup>+</sup> (Figure 2A-C) and LMP1<sup>+</sup> (Figure 2E), indicating that the plasmacytoma was EBV<sup>+</sup>. Following surgery, the patient was treated with 50 Gy of local radiotherapy and remains recurrence-free.

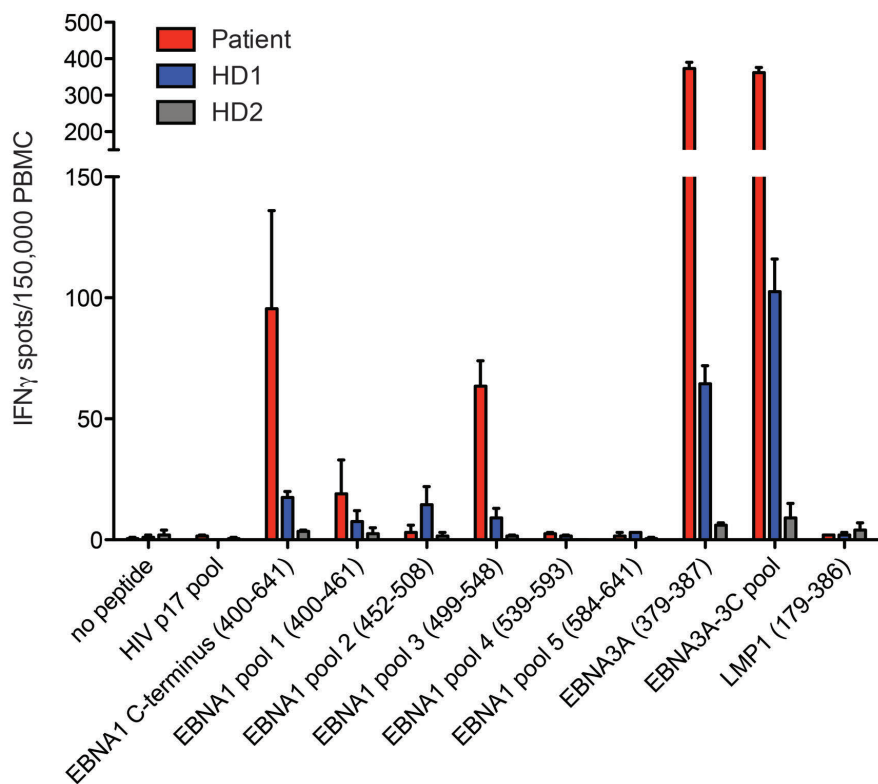
Because EBV<sup>+</sup> plasmacytomas are infrequent in immunocompetent individuals, we further characterized the tumor immune composition. We found a significant CD8<sup>+</sup> cell population (Figure 2A-C) that was localized adjacent to EBV<sup>+</sup> tumor cells. CD8<sup>+</sup> cells were near blood vessels (Figure 2A; arrows) and at the tumor periphery (Figure 2B; arrows). Both CD8<sup>dim</sup> and CD8<sup>bright</sup> cells were observed: the CD8<sup>dim</sup> cells may correspond to natural killer (NK) cells (Figure 2C; arrows), and the numerous CD8<sup>bright</sup> cells are likely CD8<sup>+</sup> cytotoxic T cells. Indeed, a CD56 labeling revealed the presence of NK cells that appear similar in frequency to the CD8<sup>dim</sup> population (Figure 2D). These data indicated that CD8<sup>+</sup> cells are present and may have been actively recruited into the

tumor.

We hypothesized that the surface levels of MHC class I molecules were altered due to plasma cell differentiation of some LMP1<sup>+</sup> cells, resulting in poor recognition of the tumor cells. We did not observe significant differences in surface MHC class I levels on LMP1-expressing cells (Figure 2E). Interestingly, it appeared that there were fewer LMP1 expressing cells compared to EBV expression, confirming the fluctuating expression of this antigen in EBV-associated lymphomas.<sup>12</sup>

We also investigated CD4<sup>+</sup> cell infiltration within the tumor. We found many bright, round CD4<sup>+</sup> T cells as well as CD4<sup>+</sup> cells with a myeloid morphology (Figure 2F), which could be infiltrating antigen-presenting cells such as macrophages. These data indicated that the tumor infiltrates included NK cells, CD8<sup>+</sup> T cells, CD4<sup>+</sup> T cells, and myeloid cells.

We hypothesized that the immune cells within the tumor microenvironment were not fully functional, but that upon surgical tumor removal and subsequent radiotherapy, the patient's immune cells were able to control further tumor dissemination. In order to better understand the patient's immune responses towards EBV, we performed an IFN $\gamma$ -specific ELISPOT assay using the patient's PBMCs and two healthy EBV<sup>+</sup> controls (HD1 and HD2) (Figure 3). Unexpectedly, we observed that the patient had particularly robust CD4<sup>+</sup> and CD8<sup>+</sup> T-cell responses to the EBNA1 C-terminus (aa 400-641) compared to HD1 and HD2, and that the reactivity was specific for EBNA1 pools 1 and 3 (aa 400-461 and aa 499-548) (Figure 3). HD1, in particular, has been documented to have robust EBV responses to multiple peptides. EBNA1-specific CD4<sup>+</sup> T cells are able to mount protective responses against EBV-transformed B cells,<sup>11</sup> and EBNA1-specific T cells have a protective effect against PTL.<sup>14</sup> EBNA1-specific CD8<sup>+</sup> T cells were observed for certain haplotypes, including HLA-B7.<sup>11</sup> Both the patient and



**Figure 3. Patient PBMCs react strongly to multiple latent EBV antigens.** Patient PBMCs or healthy donor PBMCs (HD1; HD2) were plated at 150,000 cells/well to prepared ELISPOT plates and the indicated peptides or peptide pools were added (see also Supplemental Figure 1) and incubated overnight at 37 °C. HD1 has been documented to react to multiple EBV antigens. IFN $\gamma$  spots were counted using an ELISPOT plate reader. The data were normalized as spots per 150,000 cells.

HD1 express HLA-B7. While they both responded to an EBNA3A-derived HLA-B7 restricted peptide (aa 379-387), the patient had much higher CD8<sup>+</sup> T-cell reactivity compared to HD1. Elevated EBV-specific CD8<sup>+</sup> T-cell reactivity in the patient was also observed using an EBNA3A-3C pool of immunodominant CD8<sup>+</sup> T-cell epitopes (Figure 3). Interestingly, despite LMP1 expression in the tumor, we did not observe T-cell reactivity to LMP1 (aa 179-386), which is a weak antigen compared to EBNA1.<sup>11</sup> The patient did not respond to control HIV peptides. In summary, we demonstrate that the patient has robust EBV-specific responses compared to two healthy EBV carriers.

In this study, we provide new evidence of significant EBV-specific immune reactivity in an immunocompetent male with an EBV<sup>+</sup> plasmacytoma. We excluded other diagnoses, including PBL, MZL/MALT lymphoma, and plasma cell myeloma. We found a significant population of immune infiltrates that were in close proximity to EBER<sup>+</sup> or IRF4<sup>+</sup> expressing cells, including CD8<sup>+</sup> cytotoxic T cells and NK cells, CD4<sup>+</sup> T cells, and CD4<sup>+</sup> myeloid cells. T cells have been implicated in the control of EBV infection in humans,<sup>11</sup> and in humanized mice.<sup>10</sup> Importantly, we demonstrated that the patient had highly reactive CD8<sup>+</sup> T-cell responses to EBNA3A, and CD4<sup>+</sup> and CD8<sup>+</sup> T-cell responses to EBNA3A-3C and EBNA1, but not LMP1, despite the presence of this protein within the tumor. While tumor-resident T cells have reduced anti-tumor activity, one can improve this by disrupting the immunosuppressive tumor microenvironment through chemotherapeutics or radiation therapy.<sup>15</sup> The resultant cell destruction releases tumor antigens, which can expand existing or prime new immune responses; immunosuppressive cells in the tumor are unable to exert their inhibitory effects as efficiently. In a recent study, four patients with EBV<sup>+</sup> plasmacytomas containing CD4<sup>+</sup> and CD8<sup>+</sup> cells had disease-free survival, however, this study did not examine EBV-specific responses.<sup>15</sup> We propose that tumor removal and subsequent local radiotherapy, together with the presence of strong EBV-specific T-cell responses, are responsible for the current healthy status of the patient, and that examining EBV-specific T-cell responses might be informative for future prognoses.

*Bithi Chatterjee,<sup>1</sup> Laura Sahli,<sup>2</sup> Obinna Chijioko,<sup>4,3</sup> Philip Went,<sup>4</sup> Christian Münz<sup>1</sup> and Andreas Trojan<sup>2</sup>*

<sup>1</sup>Institute for Experimental Immunology, University of Zürich;  
<sup>2</sup>OnkoZentrum Zürich; <sup>3</sup>Institute of Pathology and Molecular Pathology, University Hospital of Zürich and <sup>4</sup>Institute of Pathology, University Hospital of Basel, Switzerland

BC, LS contributed equally to this work; CM, AT contributed equally to this work.

Funding: this work was supported by the Swiss Tumor Institute, Zürich, Switzerland. CM is supported by grants from Cancer Research Switzerland (KFS-3234-08-2013), Worldwide Cancer

Research (14-1033), KFSPMS and KFSPHLD of the University of Zurich, the Sobek Foundation, the Swiss Vaccine Research Institute, the SPARKS Foundation (15UOZ01), COST Mye-EUNITER of EU FP7 and the Swiss National Science Foundation (310030\_162560 and CRSII3\_160708). OC is supported by a grant from Cancer Research Zurich. BC is a recipient of a Marie-Heim-Vögtlin fellowship of the Swiss National Science Foundation.

Correspondence: christian.muenz@uzh.ch  
doi:10.3324/haematol.2017.172791

Information on authorship, contributions, and financial & other disclosures was provided by the authors and is available with the online version of this article at [www.haematologica.org](http://www.haematologica.org).

## References

1. Yan B, Tan SY, Yau EX, Ng SB, Petersson F. EBV-positive plasmacytoma of the submandibular gland--report of a rare case with molecular genetic characterization. *Head Neck Pathol.* 2011;5(4):389-394.
2. Karuturi M, Shah N, Frank D, et al. Plasmacytic post-transplant lymphoproliferative disorder: a case series of nine patients. *Transpl Int.* 2013;26(6):616-622.
3. Campo E, Swerdlow SH, Harris NL, Pileri S, Stein H, Jaffe ES. The 2008 WHO classification of lymphoid neoplasms and beyond: evolving concepts and practical applications. *Blood.* 2011;117(19):5019-5032.
4. Gold JE, Schwam L, Castella A, Pike SB, Opfell R, Zalusky R. Malignant plasma cell tumors in human immunodeficiency virus-infected patients. *Cancer.* 1990;66(2):363-368.
5. Montella M, Crispo A, Russo F, Ronga D, Tridente V, Tamburini M. Hepatitis C virus infection and new association with extrahepatic disease: multiple myeloma. *Haematologica.* 2000;85(8):883-884.
6. Sadeghian MH, Ayatollahi H, Keramati MR, et al. The association of Epstein-Barr virus infection with multiple myeloma. *Indian J Pathol Microbiol.* 2011;54(4):720-724.
7. Loghavi S, Alayed K, Aladily TN, et al. Stage, age, and EBV status impact outcomes of plasmablastic lymphoma patients: a clinicopathologic analysis of 61 patients. *J Hematol Oncol.* 2015;8:65.
8. Aguilera NS, Kapadia SB, Nalesnik MA, Swerdlow SH. Extramedullary plasmacytoma of the head and neck: use of paraffin sections to assess clonality with in situ hybridization, growth fraction, and the presence of Epstein-Barr virus. *Mod Pathol.* 1995; 8(5):503-508.
9. Cohen JL. Primary Immunodeficiencies Associated with EBV Disease. *Curr Top Microbiol Immunol.* 2015;390(Pt 1):241-265.
10. Chatterjee B, Leung CS, Münz C. Animal models of Epstein Barr virus infection. *Journal of immunological methods.* 2014; 410:80-87.
11. Taylor GS, Long HM, Brooks JM, Rickinson AB, Hislop AD. The immunology of Epstein-Barr virus-induced disease. *Annu Rev Immunol.* 2015;33:787-821.
12. Kutok JL, Wang F. Spectrum of Epstein-Barr virus-associated diseases. *Annu Rev Pathol.* 2006;1:375-404.
13. Loghavi S, Khoury JD, Medeiros LJ. Epstein-Barr virus-positive plasmacytoma in immunocompetent patients. *Histopathology.* 2015;67(2):225-234.
14. Icheva V, Kayser S, Wolff D, et al. Adoptive transfer of Epstein-Barr virus (EBV) nuclear antigen 1-specific T cells as treatment for EBV reactivation and lymphoproliferative disorders after allogeneic stem-cell transplantation. *J Clin Oncol.* 2013;31(1):39-48.
15. Zitvogel L, Galluzzi L, Smyth MJ, Kroemer G. Mechanism of action of conventional and targeted anticancer therapies: reinstating immunosurveillance. *Immunity.* 2013;39(1):74-88.