

1973

Study Of Pits And Fissures On Occlusal Surfaces Of Human Teeth

Khadry A. Galil

Follow this and additional works at: <https://ir.lib.uwo.ca/digitizedtheses>

Recommended Citation

Galil, Khadry A., "Study Of Pits And Fissures On Occlusal Surfaces Of Human Teeth" (1973). *Digitized Theses*. 691.
<https://ir.lib.uwo.ca/digitizedtheses/691>

This Dissertation is brought to you for free and open access by the Digitized Special Collections at Scholarship@Western. It has been accepted for inclusion in Digitized Theses by an authorized administrator of Scholarship@Western. For more information, please contact tadam@uwo.ca, wlsadmin@uwo.ca.

The author of this thesis has granted The University of Western Ontario a non-exclusive license to reproduce and distribute copies of this thesis to users of Western Libraries. Copyright remains with the author.

Electronic theses and dissertations available in The University of Western Ontario's institutional repository (Scholarship@Western) are solely for the purpose of private study and research. They may not be copied or reproduced, except as permitted by copyright laws, without written authority of the copyright owner. Any commercial use or publication is strictly prohibited.

The original copyright license attesting to these terms and signed by the author of this thesis may be found in the original print version of the thesis, held by Western Libraries.

The thesis approval page signed by the examining committee may also be found in the original print version of the thesis held in Western Libraries.

Please contact Western Libraries for further information:

E-mail: libadmin@uwo.ca

Telephone: (519) 661-2111 Ext. 84796

Web site: <http://www.lib.uwo.ca/>



MICROFILMED
BY
CENTRAL MICROFILM UNIT
PUBLIC ARCHIVES
OF
CANADA
OTTAWA, ONTARIO

MICROFILMÉ
PAR LE
SERVICE CENTRAL DU MICROFILM
ARCHIVES PUBLIQUES
DU
CANADA
OTTAWA, ONTARIO

21/8/73 DATE

REDUCTION 15X

L. Goussier OPERATOR
OPERATEUR

EXPOSURE
EXPOSITION 3.2



**NATIONAL LIBRARY
OF CANADA**

**CANADIAN THESES
ON MICROFILM**

**BIBLIOTHÈQUE
NATIONALE
DU CANADA**

**THÈSES CANADIENNES
SUR MICROFILM**

1 4 9 4 8

STUDY OF PITS AND FISSURES ON
OCCLUSAL SURFACES OF HUMAN TEETH

by

Khadry A. A. Galil, D. D. S., D. Oral Surg.

Department of Anatomy

Submitted in partial fulfillment
of the requirements for the degree of
Doctor of Philosophy

Faculty of Graduate Studies
The University of Western Ontario
London, Canada

May, 1973

© Khadry A. A. Galil 1973

ABSTRACT

Occlusal pits and fissures are common sites for initiation and progress of caries. The need to stress the value of early detection of caries is of utmost importance. In recent years there has been growing interest in the role of adhesive resins in the prevention of occlusal caries, yet in spite of this the literature is deficient on many of the fundamental facts concerning pits and fissures. Recognizing this problem and also the technical problems associated with hard tissue studies, an investigation was undertaken to provide a better understanding of the morphology and contents of pits and fissures. A total of one thousand, two hundred and sixty-eight erupted and unerupted teeth were examined with the use of the light microscope, the scanning electron microscope, the transmission electron microscope and the dissecting microscope. The occlusal surface of unerupted teeth showed a follicular covering closely adapted to the fissures. Terminally, the ameloblasts lose their Tomes' processes yet small impressions persist on the occlusal surfaces and are referred to as rod-end pits.

The fissures of unerupted teeth contained ameloblasts

lining the fissure walls directly, while the core was filled with cells of the epithelial enamel organ. Occasionally fissures contained numerous blood elements. These might be attributed to local factors prior to eruption of the tooth. The ameloblasts might undergo, in certain fissures, a process of strangulation or squeezing ultimately leading to their entrapment and death. The occlusal surface of erupted teeth showed typical plaque material distributed in two principal areas termed heavy and light areas of plaque. The heavy areas were dominated by filamentous organisms while the light areas were dominantly coccoid. The heavy areas were almost exclusively located in the region of the occlusal orifice to the fissures, while the deeper parts were dominated by cocci. The erupted tooth fissure contained three morphological types of microorganisms, cocci, filamentous and rod shaped. The fissure contents of erupted teeth appeared to be composed of things other than the microorganism. Of these, dietary and salivary components assumingly undertook a significant role. This was evidenced by the histochemical results. An interesting phenomena was noticed whereby the contents of the fissures of erupted teeth were seen to be involved in a pattern of mineralization closely related to the microorganisms. This was termed "progressive mineralization of the fissure contents". The bacteria were seen to be soft and viable in the upper third of the fissure while the middle third showed deposition around the

bacteria and the lower third appeared as a solid mass. In other cases fissures demonstrated a total mineralization and different forms of crystallization. It is suggested that these phenomena are due to deposition of calcium phosphate within or between the microorganisms.

A new technique was developed for cleaning teeth in vitro. The effects of different cleansing solutions (agents) on teeth were tested. Sodium hypochlorite acted as an effective agent for the removal of organic material on occlusal surface, pits and fissures particularly on unerupted teeth. The results were documented both before and after treatment using scanning electron microscopy and direct observations guided by the use of the disclosing solutions. Further evidence was presented showing an inorganic solid plug (presumably calcified) located in the neck of certain fissures of older erupted teeth.

A technique was developed for the replication of pits and fissures of unerupted teeth using vinyl resin. This gave a three dimensional direct visualization of pit and fissure anatomy. The demonstration and illustration of different types of pits and fissures was presented, accompanied by stereo pair scanning micrographs. The results signify that the shape of pits and fissures in human teeth vary from one tooth to another and also within the same tooth. The different types and shapes which were observed imply their difficulty in classification.

White spots, located on the occlusal surface of unerupted teeth, were classified in relation to the occlusal surface and the fissures. The significance of these developmentally hypomineralized areas is not known.

A newly developed technique, termed the floatation technique, was presented whereby tooth integument was allowed to float free from the enamel surface. The material was carefully recovered thereby permitting its histological investigation. A modification of the camphene technique was introduced whereby erupted and unerupted teeth were examined with the scanning electron microscope.

This investigation was supported in part by a grant to Dr. A.J. Gwinnett from the Medical Research Council of Canada MA 3694. The author wishes to express his appreciation to this organization for its support.

ACKNOWLEDGMENT

This investigation has been made possible by the kind assistance of many people to whom the author is indebted. My thanks are extended to: Dr. P. Ponitz, clinical professor of orthodontics, University of Michigan, Ann Arbor, U.S.A., for providing some of the materials used in this study. My special thanks are extended to Miss Wendy Suhr and Mr. W. Daniels for their excellent technical assistance. My appreciation is also extended to Dr. D.G. Montemurro, Chairman of the Department, for the use of his laboratory and to my colleague Mr. J.E. Bruni for his technical advice, to Miss A. Overweel and Mrs. M. ter Haar for typing the manuscript and to the supervising committee, Dr. R.C. Buck and Dr. R.E. Jordan. I wish to acknowledge appreciation to Dr. L.N. Johnson for the use of the scanning electron microscope and to Mr. W. Kammrath for his technical assistance in its operation. I am truly indebted to Dr. A.J. Gwinnett, my supervisor who suggested the project, for his valuable guidance and direction during the course of this study.

Dedication

-- To Dr. A.J. Gwinett --

In deep appreciation of his liberal mind, companionship,
personality, friendship, and constant encouragement.

-- To the land I was born in - Nubia --

-- To my Family --

TABLE OF CONTENTS

	Page
Certificate of Examination.....	II
Abstract.....	III
Acknowledgment	VIII
Dedication	IX
Table of Contents	X
List of Figures	XVI
List of Tables	XXV
I Introduction	1
II Historical Review	6
1. Occlusal Surface of Erupted and Unerupted Teeth	6
A. Integument	6
i) Structures of Embryological origin ...	6
a) The Acellular Layer	7
b) The Cellular Layer.....	7
ii) Structures Acquired After Eruption...	8
a) The Acquired Pellicle	10
b) Food Debris	10
B. Plaque	10

	Page
C. White Spots	15
2. Pits and Fissures	16
A. Pit and Fissure Morphology	21
B. Histological Studies of Fissures	22
C. Pits and Fissure Contents: Erupted Teeth	23
3. In Vitro Tooth Cleaning	24
4. Three Dimensional Replica of Pits and Fissures	25
III. Materials and Methods	27
1. Occlusal Surface of Teeth	27
1. a General Histochemical Identification of Materials Covering Occlusal Surface of Erupted Teeth	27
1. b Scanning Electron Microscopy of Occlusal Surface of Unerupted Teeth	29
1. c Scanning Electron Microscopy of Erupted Teeth	30
1. d Observation on Occlusal Surface Enamel of Unerupted and Erupted Teeth	31
2. Pits and Fissures	31
2. a Experimental Trial on Decalcification of Enamel	32
2. b Light Microscopy of Contents of Pits and Fissures of Unerupted Teeth	34
2. c Scanning Electron Microscopy of Contents of Pits and Fissures of Unerupted Teeth .	34

	Page
2. d Light Microscopy of Contents of Pits and Fissures of Erupted Teeth	34
2. e Scanning Electron Microscopy of Contents of Pits and Fissures of Erupted Teeth	35
2. f Transmission Electron Microscopy of Contents of Pits and Fissures of Erupted Teeth	35
3. <u>In Vitro</u> Tooth Cleaning	36
3. a Experimental Trials with Different Solutions	36
3. b Technique Involving 6% Sodium Hypo- chlorite Solution	37
3. c Scanning Electron Microscopy of Treated Teeth	38
4. Replication of Teeth (three dimensional).....	38
4. a Experimentation with Different Materials	38
4. b Technique of Vinyl Resin Replication	39
4. c Scanning Electron Microscopy of Vinyl Resin Replicas of Unerupted Teeth (Occlusal Surfaces, Pits and Fissures)...	40
IV Observations and Results	41
1. Occlusal Surface of Teeth	41
1. a General Histochemical Identification of Materials Covering the Occlusal Surface of Erupted Teeth	41
1. b Scanning Electron Microscopy of Occlusal Surface of Unerupted Teeth	44

	Page
1. c Scanning Electron Microscopy of Erupted Teeth	51
1. d Observations on Occlusal Surfaces Enamel of Unerupted Teeth and Erupted Teeth ...	61
i) White Spots	62
2. Pit and Fissure Content	62
2. a Experimental Trials on Decalcification ..	62
2. b Unerupted Teeth	72
i) Light Microscopy	72
ii) Scanning Electron Microscopy	84
2. c Erupted Teeth	84
i) Light Microscopy	84
ii) Scanning Electron Microscopy	100
- Progressive Mineralization of Fissure Contents	107
- Total Mineralization and Crystal Formation	108
iii) Transmission Electron Microscopy	116
3. <u>In Vitro</u> Tooth Cleaning	116
3. a Experimental Trial	116
3. b Technique Using Sodium Hypochlorite Solution	116
3. c Scanning Electron Microscopy of Occlusal Surfaces of Teeth Treated with Sodium Hypochlorite	128
i) Unerupted Teeth	128

	Page
ii) Erupted Teeth	128
4. Replication of Teeth	135
4. a Experimental Trials	135
4. b Technique of Vinyl Resin.....	146
4. c Scanning Electron Microscopy of Replicated Occlusal Surfaces and Their Pits and Fissures	155
V Discussion.....	186
1. Occlusal Surface of Teeth	186
1. a General Histochemical Identification of Materials Covering the Occlusal Surface	186
1. b Scanning Electron Microscopy of Occlusal Surfaces of Unerupted Teeth.....	190
1. c Scanning Electron Microscopy of the Occlusal Surface of Erupted Teeth	192
1. d White Spots	195
2. Pit and Fissure Content.....	197
2. a Experimental Trials on Decalcification...	197
2. b Unerupted Teeth: Correlation Between Light Microscopy and Scanning Electron Microscopy	198
2. c Erupted Teeth	201
3. <u>In Vitro</u> Tooth Cleaning.....	209
4. Replication of Teeth	211

	Page
5. Comments on the Preparation of Tooth Material for Scanning Electron Microscopy as Used in this Investigation	213
VI Summary and Conclusion	214
Possible Avenues for Future Study	226
Bibliography	227
Vitae	252

LIST OF FIGURES

Figure	Page
1-2	Macrophotographs identifying occlusal surface integumental material..... 43,46
3	Scanning electron micrograph of the occlusal surface of an unerupted tooth demonstrating: A) follicular attachment to a molar tooth, B) follicular attachment to a premolar tooth..... 48
4	Scanning electron micrograph of the occlusal surface of an unerupted tooth demonstrating: A) blood elements associated with the fissures, B) red blood cells inside the fissure, C) follicular attachment and fissure content, D) rod end pits..... 50
5	Scanning electron micrograph of the occlusal surface of an erupted tooth demonstrating: A) heavy plaque covering, B) light plaque covering..... 53
6	Scanning electron micrograph of the occlusal surface of an erupted tooth demonstrating: A) integumental covering, B) two different areas of plaque, C) rods,

Figure	Page
D) cocci	55
7 Scanning electron micrograph of an erupted tooth showing: A) heavy and light areas of plaque, B) light area of plaque.....	57
8 Scanning electron micrograph of plaque showing: A) heavy areas, B) microorganisms related to an enamel depression, C) cocci in relation to fissures, D) the transitional zone.....	60
9-10 Macrophotographs of the occlusal surface of unerupted teeth demonstrating white spots distribution.	64,66
11 Macrophotograph demonstrating: A) erupted and unerupted tooth, B) decalcified unerupted tooth by Goland technique	69
12 Macrophotograph demonstrating: A, B, C) the floatation technique	71
13 Radiographs of teeth during decalcification A, B, C) different stages of decalcification, D) resistant surface enamel	74
14 A) macrophotograph of unerupted tooth, B) light micrograph of unerupted tooth	76
15 Light micrograph montage of a fissure of unerupted tooth	76
16 A and B) light micrograph of unerupted fissure	

Figure	Page
	81
17	83
18	86
19	88
20	90
21	92
22	95
23	97
24	99

Figure		Page
25	A, B, C) blood agar plated with cultures	102
26	A, B, C) light micrograph of the fissures of erupted teeth, using the Goland technique to show contents	104
27	A, B, C) scanning electron micrographs showing plaque in relation to the fissures and the occlusal surfaces	106
28	A, B, C) scanning electron micrographs of fissure contents	109
29	A) scanning electron micrographic stereo pair showing microorganisms located in the fissure, B) scanning electron micrograph of the contents of a fissure of an erupted tooth	111
30	A) scanning electron micrograph of an erupted tooth cleaved along a fissure, B) scanning electron micro- graph at higher magnification denoting three distinct areas	113
31	A, B, C) scanning electron micrographs demon- strating the steps of progressive mineralization in the fissure	115
32	A, B, C) scanning electron micrographs demonstra- ting total mineralization and crystal formation in	

Figure	Page
	the fissure 118
33	Transmission electron micrograph of a cross section through the contents of an erupted tooth . . . 120
34	Transmission electron micrograph of a cross section through a fissure of an erupted tooth 122
35	Transmission electron micrograph of a section through the fissure contents of an erupted tooth . . . 124
36	A) transmission electron micrograph showing bacteria with dense crystal-like structures inside the bacteria, B) transmission electron micrograph of crystals surrounding the bacterial cell 126
37	A and B) scanning electron micrograph of an unerupted tooth showing the occlusal surface after cleansing with sodium hypochlorite 130
38	A and B) scanning electron micrograph of an unerupted tooth fissure before and after treatment with sodium hypochlorite technique, C) scanning electron micrograph of an occlusal view of a fissure treated with sodium hypochlorite 132
39	A and B) scanning electron micrographs demon- strating the effects of sodium hypochlorite treat- ment on the occlusal surface of erupted teeth 134

Figure		Page
40	A) scanning electron micrograph of the occlusal surface of an erupted tooth demonstrating the cleansing effect of sodium hypochlorite, B, C, D) scanning electron micrograph of a fissure of an erupted tooth after treatment with sodium hypochlorite	137
41	Macrophotographs of erupted teeth demonstrating: A) comparison between treated and untreated teeth, B and C) staining of a fissure with alizarin red	139
42	A and B) macrophotograph of an occlusal view of an erupted tooth treated with sodium hypochlorite, C) scanning electron micrograph showing a "plug" in the centre	141
43	A, B, C) scanning electron micrograph demonstrating the features of the "plug".	143
44	Scanning electron micrograph, A and B) clearcast replica, C) macrophotograph of a Spurr replica, D) scanning electron micrograph of a Spurr replica	145
45	A, B, C, D) macrophotograph demonstrating the adaptability of vinyl resin to the occlusal surface, pits and fissures	148

Figure	Page	
46	Scanning electron micrograph of: A) enamel surface treated with 50% phosphoric acid, B) vinyl resin replica of the etched enamel.	150
47	Scanning electron micrograph of: A) enamel surface treated with 50% phosphoric acid, B) vinyl resin replica of etched enamel	152
48	Scanning electron micrograph of: A) selected area of etched enamel, B) vinyl resin replica of the same area as in A.	154
49	Macrophotographs of a vinyl resin replica, A and B) showing an upper premolar, C and D) showing a lower premolar	157
50	A, B, C) macrophotographs of a vinyl resin replica of lower molars	159
51	A, B, C) macrophotograph of a vinyl resin replica of an upper molar demonstrating various fissure outlines	161
52	A and B) macrophotograph of vinyl resin replicas demonstrating the difference in occlusal surface and fissure outline	163
53	A) scanning electron micrographic stereo pair of a vinyl resin replica of an occlusal surface, B)	

Figure	Page
	scanning electron micrograph of a vinyl resin replicated occlusal surface 165
54	Scanning electron micrograph of a vinyl resin replicated occlusal surface, pits and fissures 168
55	A and B) scanning electron micrographs of a vinyl resin replica of upper molars 170
56	A, B, C) scanning electron micrographs of a vinyl resin replica of premolars..... 172
57	A and B) scanning electron micrographs of a vinyl resin replica demonstrating variance in pits and fissures 170
58	A, B, C) scanning electron micrograph of vinyl resin replica illustrating the effect of visualizing the same pit at different angles..... 174
59	A and B) scanning electron micrographs of vinyl resin replicas illustrating the morphology of buccal pit 176
60	A, B, C, D) scanning electron micrographs of a vinyl resin replica illustrating the morphological appear- ance of different types of pits commonly observed on the occlusal surface 178
61	A, B, C, D) scanning electron micrographs of vinyl

Figure		Page
	resin replicas illustrating modified and combined types of pits	182
62	Scanning electron micrographs of vinyl resin replicas demonstrating A) buccal pit and fissure, B, C, D) illustrate variations between pits	185
63	Diagram representing the steps in preparation of three dimensional replicas of occlusal surfaces, pits and fissures using vinyl resin	216
64	Diagram representing the factors affecting the formation of fissure contents in erupted teeth	220
65	Diagram demonstrating the difference between unerupted and erupted pit and fissure replication ..	224

LIST OF TABLES

Table	Page
1 Effect of different agents (solutions) for cleansing erupted teeth, (occlusal surfaces, pits and fissures).....	127

Introduction

It is paradoxical that dental enamel the hardest of all tissues is so susceptible to lesions in living humans while it is most indestructible in the dead.

As knowledge about dental caries continues to increase, the complexity of the disease becomes more and more evident. Caries is a far from simple process. It involves a large number of inter-relating factors affecting both the tooth and its environment.

We do not know why teeth seem to vary so widely in susceptibility to carious attack, many factors are evidently involved, among them is the relation of tooth form and caries. This has led to adopting a classification based on pit and fissure caries and smooth surface caries, depending on the site of the tooth at which the carious attack occurs.

Since decay often starts in the pit and fissure areas, the presence of deep invaginations of enamel have been thought for many years to be an important predisposing factor. Significantly, however, Black (1895) stated "Imperfections of teeth such as pits and fissures . . . are causes of caries only in the sense of giving opportunity for the action of the causes that induce caries." This

premise is widely held today. Moreover, clinical studies have demonstrated the susceptibility of the areas to caries (Brekhus (1931. a), McCall (1934), Prime (1937), Brucker (1944), Paynter and Grainger (1962)).

Kraus . Jordan and Abrams (1969) define fissures and pits as following:

"A fissure is a cleft or crevice in a tooth surface thought to result from the imperfect fusion of the enamel of adjoining cusp or lobes."

"A pit is a sharp pointed depression usually located at the junction of 2 or more intersecting developmental grooves, or at the termination of a single developmental groove."

As the cause of caries remains an unsolved problem, many investigators devoted deserved attention to the study of the relationship of fissures to susceptibility to dental caries. Different opinions have been expressed as to whether or not fissures are defects.

A capital stand was taken by Kronfeld (1935) who considered them normal, while others considered them as structural defects. Bodecker (1930), Brekhus (1931. b), Hyatt (1936), and Brucker (1944) classified them as faults in the enamel.

Relationship between fissure and caries:

Hyatt (1936) concludes that "the chances are over 2,500 to one that decay will occur in a pit or fissure". Bodecker (1926) also claims that in his extensive studies 99 out of every 100 fissures decay.

Fissures in molar teeth are susceptible to dental caries. It is a clinical and epidemiological fact that caries in pits and fissures produces much of the operative work required in children's teeth. Walsh and Smart (1948) reported that in New Zealand 100% of first molars were filled by the age of eleven. Nonetheless, the probability of caries occurring in pits and fissures is difficult to calculate (Roydhouse 1968).

In Canada, (Grainger and Reid (1954) and Reid and Grainger (1955)) 80% of the occlusal surfaces of the first molars were decayed or filled by nine and a half years and maximum susceptibility was given as 73 to 76 percent. According to Backer Dirks (1963) the addition of 1 p. p. m. of fluoride to water supply reduced occlusal caries rates by approximately 12 percent compared with an overall reduction of 60 to 70 percent for other surfaces.

It is particularly significant that occlusal surfaces represent approximately 12 percent of the total tooth surfaces at risk in young children yet account for better than 50 percent of the caries activity (Ripa 1973).

It is well known that the infectious process which leads to the destruction of teeth is one which is in global epidemic proportions. The cost to rehabilitate and restore mouths ravaged by carious destruction and sequelae is astronomical. The socio-economic implications are immense and touch upon all social strata.

The development of comprehensive caries prevention programs

brings new hope to a profession that is hard pressed to meet the demands for reparative dentistry. With the probable introduction of government sponsored dental plans and greater public demand for dental services one salvation lies in economically viable preventive programs.

Research and technology has brought and will continue to bring new innovations to dental practice. The introduction of materials designed to fill and seal pits and fissures so as to eliminate them as stagnation sites for microbial fermentation is a promising adjunct to existing measures.

The protocol for sealing pits and fissures demands a clean occlusal surface and pits and fissures devoid of contents. To effectively clean the occlusal and fissural sites and for the subsequent conditioning of the enamel to promote sealant bonding it is important to understand the nature of coatings on or contents within such sites. The extent to which sealants penetrate into and fill the deeper regions of pits and fissures depends upon several factors including their geometry and their cleanliness. Our knowledge on pit and fissure morphology and contents is scarce. Accordingly a study was designed; -

1. To provide a general histochemical identification of coatings on occlusal surfaces and contents within pits and fissures.
2. To develop a technique for studying the contents of pits

and fissures of unerupted and erupted teeth.

3. To study occlusal plaque using scanning electron microscopy.
4. To study the contents of pits and fissures using scanning electron microscopy.
5. To develop a method for cleaning pits and fissures.
6. To develop a method for replicating the topography and morphology of pits and fissures.

II HISTORICAL REVIEW

The first written reference to dental caries and other oral disease is to be found in Ebers Papyrus, written in Egypt around 1550 B. C. . These records without doubt are the most voluminous and best preserved writings on medicine and dentistry that have reached us from the remote past. It is claimed that some of the contents may date to 3700 B. C. (Bremner, 1964).

Dental decay occupies a prominent position in dental research nowadays, and the complexity of the disease is becoming more and more obvious. It is not the intent in this thesis to review all the literature on caries, but to restrict the survey to those references closely related to the present investigation which is concerned with the site most frequently attacked in adolescent children, namely; the occlusal surfaces.

1. Occlusal Surface of Erupted and Unerupted Teeth

A. Integument

Integumental structures could be divided into those of embryological origin and those acquired only after tooth eruption.

i) Structures of Embryological origin

In 1839 Nasmyth called it the persistent dental capsule,

later Huxley (1856) named it the Nasmyth membrane. In fact, this layer is divided into two layers:

a) The Acellular Layer: Different names have been given to it.

The inner structureless layer of Nasmyth's membrane, Paul (1894) ; primary enamel cuticle, Gottlieb, (1921a, b); enamel capsule, Hodson, (1949); enamel cuticle, Ussing, (1955); Nasmyth's membrane, Wertheimer and Fullemer, (1962); primary enamel cuticle, Dawes, Jenkins and Tonge, (1963) and recently was considered an artifact by Listgarten, (1966). The acellular layer is about 1μ thick and is not always seen.

It has a structureless refractile appearance. This is now generally known as the "primary enamel cuticle" and is perhaps either the partially mineralized or the non-mineralized last formed product of the ameloblasts. Occasionally beneath the reduced enamel epithelium which consists of ameloblasts and outer enamel epithelium there is present a considerable thicker structureless layer about 4μ thick which stains in a characteristically different way from the somewhat refractile primary enamel cuticle. This is generally known as the secondary enamel cuticle and has been considered to be secreted by the reduced enamel epithelium rather than by the ameloblasts per se, (Gaunt, Osborn, Ten Cate, 1971).

b) The Cellular Layer: When enamel has completely developed and has fully calcified, the ameloblasts cease to be

arranged in a well defined layer and can no longer be differentiated from the cells of Stratum intermedium and outer enamel epithelium. These cell layers then form a stratified epithelial covering of the enamel, Sicher and Bhaskar (1972). Previously the cellular layer was given different names; the outer cellular layer of Nasmyth's membrane, Paul (1894); cuticula dentis, Kronfeld (1930); united enamel epithelium, Kronfeld (1943); reduced enamel epithelium, Aitchison (1949); epithelial attachment cells, Ussing (1955); dental cuticle, Wertheimer and Fullmer (1962); and reduced enamel epithelium, Dawes, Jenkins and Tonge (1963).

The adoption of the term reduced enamel epithelium follows logically since the cellular components of this layer are derived entirely from the enamel organ, and both before eruption and after eruption the layer is related directly to enamel.

ii) Structures Acquired After Eruption

a) The Acquired Pellicle: Following eruption into the mouth the enamel of human teeth acquires a cellular integumental structure. There has arisen both a variable nomenclature and conflicting opinion over its possible nature and origin. The structure has been previously called mucin plaque, Kirk, (1910); Gottlieb(1921); Orban, (1926); Campaigne and Fosdick, (1938), an artificially produced deposit; Acquired cuticle,

von Korff, (1930); plaque and film, Dobbs, (1932); dental cuticle, Lehner and Pleuk, (1936); enamel cuticle, including all cuticles, Darling, (1943); brown pellicle (referring to stained material, Vallatton, (1945); acquired enamel cuticle, Rushton, (1954); dental plaque (including all types of integuments, Winkler and Backer Dirks, (1958); post eruption cuticle, Turner, (1958); and dental plaque referring to structureless, bacteria free deposits on dentures, Millin and Smith, (1961); acquired pellicle, Dawes, Jenkins and Tonge, (1963). Meckel, (1965) described the acquired pellicle as three structures acquired after eruption, namely; a subsurface cuticle (1-3 μ thick) a surface cuticle (0-2 μ) and a stained pellicle (1-10 μ).

While Levine, Glimcher, Bonar, (1964) suggested remnants of a collagenous material occurred on the surface of some human erupted teeth, Hodson, (1966) from a histochemical study on these integumental structures suggested that they may include denatured hemoglobin material.

Kramer and Ramanathan, (1966) adopted the term acquired pellicle following examination of it with fluorescent microscopy. Leach and Saxton, (1966) reported the presence of so-called dendritic processes extending from the acquired pellicle for several microns into the enamel surface, although their observations were restricted to areas of interproximal

enamel.

b) Food Debris (materia alba): This white-yellow deposit consisting of micro organisms, desquamated epithelial cells and blood cells, covering the surface of teeth has been investigated by Winkler and Backer Dirks, (1958) and was given the name materia alba. Dawes, Jenkins and Tonge, (1963) however, adopted the term food debris, because food debris is a product of an incidental accumulation and can be removed with a strong water spray, Mandel, (1966).

B. Plaque

The word plaque was first used by Black, (1898) in the phrase 'gelatinous microbic plaque' to describe the felt-like mass of micro organisms which Williams, (1897) had observed over the surface of carious human enamel. The bacterial nature of dental plaque was discovered by Anton Van Leeuwenhoek in the seventeenth century during the time when he was developing the first microscope. Some two hundred years later investigations were carried out whereby chemical and bacterial analysis was undertaken, Miller, (1883a, 1883b, 1890, 1902, 1904, 1905a, 1905b), Black, (1886a, 1886b, 1887, 1898, 1899) and of Williams, (1897, 1898, 1899).

An excellent review on the topic of plaque was made by Stephan (1953) and Mandel (1966). The term plaque still has no exact meaning and differs according to authors and to some degree according to fashion, Bibby, (1968). Dawes, Jenkins and Tonge,

(1963) have contributed to the clarification of this term which is now normally accepted as plaque. Optical microscope techniques are of important value in elucidating the components of plaque because most staining procedures stain bacterial or matrix components in a similar way.

Bibby, (1931, 1935, 1938) described dental plaque and pellicle and their possible relation to dental caries. Later, Stephan, (1938, 1940, 1944) showed that acids could be produced by bacteria in the plaque provided they are given suitable carbohydrate substrate. Mandel, Levy and Wasserman, (1957) used contoured celluloid strips ligated to the tooth then examined the strips at several intervals. Microscopic examinations of sections of 3 and 5 day specimens showed that the plaque attached to the strip consisted of amorphous and a finely granular matrix in which there were masses of gram positive and gram negative coccoid forms as well as occasional filaments. By the seventh day the character of the plaque appeared to change while the masses of coccoid forms were still obvious. The surface as well as the more central areas now contained masses of filamentous organisms. By the twelfth day the plaque was composed almost entirely of filamentous bacteria. These bacteria appeared as irregularly stained, twisted strands of branching and non-branching filaments. Other investigators obtained similar results on plaque formation using plastic strips, Hazen and Zander, (1959); Muhlemann and Schneider, (1959); and Truesky, Renstrup

and Glickman, (1961). McDougall, (1963) in his studies on interproximal plaque observed after one day of tooth cleaning an immature type of plaque consisting of a non-bacterial plaque, matrix plus an acquired enamel cuticle. Later the proliferation of microorganisms within the plaque matrix soon changed the character of the immature non-bacterial plaque.

The use of the transmission electron microscope in dental plaque investigations has confirmed the presence of the initial cuticle or pellicle. Lenz and Muhlemann (1963) observed a pellicle-like layer covering the surface of etched enamel after two hours exposure. Theilade, (1964) using plastic strips found an electron dense cuticle ranging in thickness from 0.05-0.4 microns. Meckel, (1965) has described three types of film: subsurface cuticle, surface cuticle and plaque, formed on clean pieces of enamel worn in the mouth for approximately ten days. These findings have basically been confirmed in the studies by Frank and Brendel, (1966); Leach and Saxton, (1966); and Armstrong, (1968). Meanwhile, Frank and Brendel, (1966) mentioned that with the use of ultra thin sections studied under the electron microscope it is impossible to perform any taxonomic identification of the organisms present in the plaques. Also they reported the intracytoplasmic polysaccharide vesicles in these studies were present on both carious and normal enamel, in both cases the coccoid, rod-shaped and filamentous bacteria and an inter bacterial matrix variations were

rated.

Bacteriology of the Plaque

Stralfors, (1950) estimated that plaque contained 400 million organisms per milligramme, as counted on smears. The proportion of different types differ markedly from those of saliva e.g., streptococcus salivarius, numerous in saliva, are less than one percent of plaque bacteria and lactobacilli. About 0.1 percent of salivary organisms are less than 0.001 percent of the plaque flora. Anaerobic cultivation of plaque bacteria gives better growth than aerobic conditions, which fits in with the strong probability that the deeper layers of plaque have a very low oxygen tension. Gibbons, Socransky, Araujo and Van houte, (1964) demonstrated and classified bacterial plaques as facultative streptococci 27%, facultative diphtheroids 23%, anaerobic diphtheroids 18%, pepto-streptococci 13%, veillonella 6%, bacteroids 4%, fusobacteria 4%, neisseria 3% and vibrious 2%.

Direct Visual Observation of the Plaque

Bjorn and Carlsson, (1964) studied the morphogenesis of dental plaque directly on the tooth surface by examining plaque with a stereo microscope after staining with a disclosing solution. At first inspection, 24 hours after cleaning, a very weak affinity for fuchsin was regularly observed over large areas of the tooth. At this stage a deposit could be scraped from the teeth. The next feature of the development was the appearance of strongly stainable

material which gradually filled the cracks and later formed ridges protruding over the surface of the tooth. On other areas of the tooth this material had a somewhat different morphology. Discrete, small, hemispherical, intensely-stained accumulations could be seen scattered over the tooth surface, especially along the gingival margin. These accumulations could be seen after 1-4 days. At the stage when they could be detected by means of the optical method used, Bjorn and Carlsson termed them plaque colonies. These increased in size and thickness until many of their morphological characteristics were lost.

It is becoming generally accepted that the accumulation of dental plaque on the surface of human dentitions is a major factor in the development of caries and periodontal disease. In contrast to the rapid increase in knowledge of the chemical and bacteriological composition of mature plaque, relatively little is known about plaque morphogenesis -- particularly how it becomes established on the enamel surface. The introduction of the scanning electron microscope as an investigating tool has proved to be an eminently suitable method for the study and examination of plaque, Boyde and Lester, (1968); Boyde and Williams (1971); Critchley and Saxton, (1970); Huxley, (1971); Gwinnett and Buonocore, (1972); Galil and Gwinnett, (1973a); Galil and Gwinnett, (1973b).

C. White Spots

The variation in structure and mineralization of enamel conforms to a more or less orderly pattern. Nearly every tooth, however, presents some degree of variation, particularly in the form of hypomineralization, G. Gustafson and Gustafson, (1962). It may be said that "normal" enamel does not exist, Gwinnert (1964).

Black, (1908) described white spots as areas which show absence or lack of cementing substance between otherwise normal enamel prisms. All teeth examined by Black were erupted.

Ticke, (1965) describes them as chalky white spots, occasionally found on the surfaces of normal teeth. The most noticeable site is the labial surface of an incisor. A single white spot or several might appear on one or more of the teeth. Such spots are frequently seen near the incisal edge of anterior teeth where they appear as an opaque focus to transillumination of the crown. The cause of these defects is not known. They have been described as focal areas of hypomaturation and as areas of local hypocalcification. As might be expected, they are structural defects lacking the intercementing substance of the enamel. They usually extend only part of the way through the enamel and are easily cut through during operative procedures on the crown. Similar appearing white spots on the crowns of the teeth, sometimes are due to local conditions which alter the index of refraction of this small spot on the surface of the tooth. In other

instances, the appearance of a white spot is evidence of the break down of enamel by dental caries. Bhussry, (1958) and Kostlan and Plackova, (1962), distinguished between white spots as two types: i) white opaque areas of enamel on the approximal surface of young teeth commonly referred to as white spots or early carious lesion, ii) white enamel areas, diffuse in nature and present as large irregularly distributed bands in enamel, commonly referred to as hypocalcified developmentally defective areas. It can be concluded that while caries may manifest clinically as a white spot on enamel it does not necessarily follow that all white spots are carious sites on teeth.

2. Pits and Fissures

Profitable investigations in relation to caries of pits and fissures were made when scientific observations on teeth first started. John Hunter wrote his book "Practical Treatise of the Disease of Teeth" in 1778 in which he mentioned that fissures are cracks or the hollow path of grinding surfaces of molars filled with black substance, Coleman, (1971).

Fox, writing in 1803, described fissures as irregularities of the grinding surface of the molars which leads into a cavity in the centre of the tooth. The chief predisposition to decay is defective formation in either enamel or bony parts of teeth, Andrews, (1889).

In 1835 W. Robertson in his book "A Practical Treatise on the Human Teeth" described the presence of small openings on the occlusal surface which leads to large cavities. He also drew attention to the shape and form which increases the liability of the tooth to decay. He tried to describe the etiology of caries in relation to the form of teeth. His observation on occlusal surfaces and on pits and fissures were remarkable in that he mentioned that the size and depth of fissures differ greatly and that "we rarely meet two molar teeth exactly alike", Andrews, (1889).

William Robertson, (1835), also recognized that decay never occurred on clean, smooth surfaces and that the attack on teeth was made at such points where food is retained. He is considered the first writer to tell us that all decay is the result of chemical action and he believed that pits and fissures often found on teeth were the principal cause of their destruction, Andrews, (1889).

Goddard, (1843), spoke of fissures as original openings in enamel and that carious process is very rapid in them, Andrews, (1889).

Kelly, (1843), described decay as a process commencing in the body of the dentine of the tooth directly beneath the enamel, he even called it internal decay. He also attributes cause of tooth decay to the presence of deep fissures on bicuspid and molars.

In 1853 Alfred Baron Jones described decay as a process

which affects teeth on opposite sides. This he attributes to the same morphology and the same environmental factors and considers decay occurs in pairs, Hyatt, (1930).

In 1870 James Truman advised treatment of depressions and that they should be given promptest attention and if there is a slight doubt the tooth should be given the benefit of the doubt and fissures must be filled. In 1870, Magitot described fissures as congenital imperfections, where forms vary infinitely and consist most commonly of vices of conformations of the enamel with large, dark, colored, irregular grooves on the masticating face of molars and bicuspid. They have been considered "intrafollicular disturbances of their dentification", Andrews, (1889).

J. H. McQuillan, (1871) stressed that a fissure could extend from the bottom of the sulcus on the grinding surface of the tooth through the enamel and up to the dentine and end up in an oval shape cavity. He also suggested that these fissures could be due to the result of defective formation and that enamel prisms have failed to coalesce at that point leading to the formation of the fissure and subsequently its filling with food material. He considered the presence of fissures as an abnormal condition which must be treated. In 1871 Robert Arthur published a book entitled "Treatment and Prevention of Decay of the Teeth" in which he claimed that the source of the agent causing decay, and contaminants at a point which form the lodgment and retention of

particles in the mouth. He points to a rule by saying that wherever there is a defect in the continuity of the enamel of a tooth decay is sure to occur. Hyatt, (1930) suggested that decay would not occur if the defective places could be obliterated by being filled with some substance capable of resisting the action of decomposing agents.

In 1875, Salter thought that defects between cusps of molars and premolars are common. Also that the fissures are deep and at their bottom exists only a "confused" developed enamel that is cracked and porous affording a most incomplete protection of the dentine from external influences. He also considered these depressions could happen on any unused tooth portion leading to the same results. He claimed that imperfectly formed enamel is more or less faulty in structure and this leads to decay. This view was later supported by Andrews, (1889).

Andrews, (1889) reviewed the literature of pits and fissures. He stated that pits and fissures are minute depressions extending from existing natural depressions which separate the cusps of the molars. Such sites he considered to be a predisposing cause to decay. Andrews mentioned that pits are constantly present in the bicuspid as in molars differing with Black who found that pits were very often absent in bicuspid. He believed that fissures were formed due to inherited tendencies although he was not sure of this opinion and claimed they could be caused by

accidents subsequent to birth. Andrews also described an area of imperfectly developed dentine under a deep fissure and believed this to be the real cause of the formation of the fissure itself. He called such areas soft dentine, formed of imperfect global structures.

Johnson, (1898), considered fissures as structural imperfections by which the developing islands of calcification, beginning in the tip of the cusps, failed to properly unite on approaching each other, leaving a crack for the ingress of foreign matter.

In 1897, G. V. Black in his book "Dental Anatomy" defined pits as sharp pointed depressions in the enamel. Pits occur mostly where several developmental grooves join as in the occlusal surface of molars and at the endings of the buccal grooves on the buccal surfaces of the molars. He defined fissures "as faults in the surface of teeth caused by the imperfect joining of enamel of different lobes. Fissures occur along the lines of the developmental grooves." Black's extensive works in operative dental procedures are well known and they always included pits and fissures as sites of decay. Probably the two persons who devoted most of their studies and research to pits and fissure are Hyatt, (1923, 1924, 1925, 1926, 1930, 1931, 1936) and Bodecker, (1924, 1926, 1929, 1944, 1964). Hyatt introduced the term prophylactic odontotomy in which he eradicated caries susceptible fissures by restoring them with conventional filling materials.

Bodecker, (1927), was also an advocate of the same theory of prophylactic odontotomy. A classification was made by Bodecker into complete and incomplete fissures. Complete fissures were considered to be those which extend up to the dentine and incomplete fissures those which extend between the enamel and dentine and have a certain amount of enamel between them. Consequently with Hyatt and Bodecker leading a vanguard of those interested in the prevention of caries, a new field was created in preventative dental procedures.

Brucker, (1944), reviewed the relation between caries and fissures and presented evidence not in favour of the prophylactic odontotomy, i. e., against concepts by Hyatt and Bodecker. In 1956, Miller and Hobson emphasized that clinical diagnosis of pit and fissure caries could be made by a probe and they found "sticky fissures indicate 70 percent caries".

A. Pit and Fissure Morphology

The literature did not reveal any specific and extensive study of the morphology of the pits and fissures. Nevertheless, attempts have been made to show the outlines of fissures. Pincus, (1948), compared the morphological outline of fissures to the end of a dental probe. On the other hand Nagano, (1961), classified the pits and fissures relation to caries and described them in differing forms; namely, V type and U type, I type and I-K type.

Mortimer, (1964), classified fissures as shallow grooves and deep grooves.

B. Histological Studies of Fissures

In 1959 Newbrun studied the occlusal fissures using micro-radiography and showed repeated instances of demineralization at the back and sides of these regions. The pattern of demineralization was such that a radio-opaque surface layer was evident beneath which was a radiolucent subsurface zone.

Gillings and Buonocore, (1961), were the first to report the thickness of enamel at the base of the fissure.

Awazawa, (1963), concluded that most enamel areas at the core of fissures were made of rodless portions of enamel and showed the difficulty of distinction between enamel rods and inter rod substances due to considerable hypomineralization.

Fusuyama, (1964), showed the distribution and differential clinical diagnosis of pits and fissures. A well defined, dull line established a fissure while a broader shade indicated a groove.

Mortimer, (1964), stated that lesions occur bilaterally on the walls of the fissures. Awazawa, (1966), described the E. M. of hypomineralized areas descending to the floor of occlusal fissures.

Recently Awazawa, (1969), introduced a unique concept in which he stated that the presence of genuine fissures is rare and that only 31 of his samples showed fissures. Most important of all

he considers that previous investigations have been of fissures produced only as an artifact due to grinding in section preparation.

C. Pits and Fissure Contents: Erupted Teeth

The literature does not provide any original study on the contents of human fissures but many speculations have been reported on what might be the constituents of fissures.

In 1921, Noyes and Thomas mentioned that grooves on the occlusal surface of erupted teeth may be empty or filled. In some instances this could be cementum being compared with the coronal cementum of Ungulates.

Bodecker, (1926), in his attempt to emphasize the point of prophylactic odontotomy stated that a fissure could accommodate approximately 3×10^9 cocci. He suggested hypothetically that cocci could be present in fissures of erupted teeth and their number will increase according to the diameter of the fissure.

In 1948 Pincus thought that unerupted teeth contained protein in their occlusal grooves.

In 1953, Hodson stated that erupted teeth tend to become filled with bacteria and material from the saliva. In 1964, Levine, Glimcher and Bonar stated that unerupted human teeth are covered by a continuous layer of cement of collagenous origin covering the occlusal surface.

3. In Vitro Tooth Cleaning

Previous work dealing with the removal of plaque from the mouth has been concerned directly with measuring dental cleaning efficiency and the emphasis was always on the In Vivo evaluation. Loe, (1969) concluded the In Vivo mechanical tooth cleansing with a tooth brush must still be regarded as the most effective measure of controlling dental plaque. The literature shows many studies of clinical evaluations of tooth cleaning using a tooth brush. Reports on the relationship between frequency of tooth brushing and state of hygiene are conflicting, Pindborg, (1951); Stanmyer, (1957); Brandt-Zawg, (1964); Curson and Manson, (1965); Zaki and Stallard, (1969). Skinner, (1914) introduced the technique of using a disclosing solution. Since then, several modifications of disclosing solutions have been proposed, Arnim (1953, 1963). The standard procedure for studying the structure of teeth is usually to wash the tooth followed by fixation before routine histological procedures. Researchers who have been interested in studying the integuments on teeth, e. g. cuticle or plaque, Manly, (1943); Vallotton, (1945); Losee and Hess, (1949); Voreadis and Zander, (1958) have used either the technique of scraping or concentrated acids.

With the introduction of scanning electron microscopy the demand for a method which could remove the integument and allow the study of tooth surfaces directly was needed, but still effective techniques for cleaning the teeth were not established.

Hofmann, (1968) used only washing prior to the study of enamel surfaces. In a comparable study, Boyde, (1968) simply dried the specimen in preparation for scanning electron microscopy.

In the present study the interest in tooth cleaning arose from efforts to develop new methods for replication of pits and fissures. An exhaustive literature review of possible techniques for In vitro tooth cleaning proved fruitless. An attempt was therefore made to examine the possibility of using accepted clinical procedures of pulpless tooth bleaching in the In vitro situation, Sommer, Ostrander and Crowley, (1966).

4. Three Dimensional Replica of Pits and Fissures

In the past a large number of the studies on enamel of teeth were done by grinding sections leading to a single section which was of no value for studying the whole tooth. With the advent of serial sectioning machines, Lefkowitz, (1940); Jansen, (1946); Sognaes, (1947); Atkinson, (1948); Fosse, (1954); Hammerlund Essler, (1956); Kropp, (1956) and Gillings and Buonocore, (1959); Gray and Opdyke, (1962) a new era opened in dental research.

Gillings and Buonocore, (1961) studied the thickness of enamel at the base of pits and fissures in human molars using serial sections. Fusyama, (1964) used a serial sectioning technique in which every section was etched and then replicated. Awazawa, (1966) used a similar replica technique.

Three dimensional replicas of the whole tooth have never been attempted. In this present study it was necessary to develop a technique by which pits and fissures could be demonstrated easily in relation to each other and to the occlusal surface. To develop such a method involved experiments with different materials and techniques. It was found possible to develop a method which proved most satisfactory.

III MATERIALS AND METHODS

To the newcomer interested in the microscopic structure of enamel and its structural changes in dental caries, it should be pointed out that the technical difficulties involved in specimen preparation are probably greater than in any other field of microscopy, Quigley, (1968).

1. Occlusal Surface of Teeth

1. a General Histochemical Identification of Materials Covering Occlusal Surface of Erupted Teeth

This study was undertaken in order to gain a general idea of the material covering the occlusal surface and of that found in pits and fissures. Sixty (60) clinically sound permanent human molars and premolars were selected, most of them being extracted either in the course of orthodontic treatment or impaction. They were fixed in 10% neutral formalin and kept at 4° C. All the teeth had erupted not less than three years. The patients' ages varied between 9 years and 60 years.

Observations were made using a dissecting microscope (Zeiss, stereo microscope). After proper fixation the roots

were cut from the crowns on a water cooled rotating carbon-
disc and the roots discarded. The occlusal surfaces
were examined firstly under the dissecting microscope for
the recording of any structural details. Subsequently, the
teeth received a gentle washing and were treated according
to the following histochemical techniques.

Carbohydrate Demonstration:

Ten teeth were prepared according to the Periodic
Acid Schiff Technique, Pearse, (1968).

Ten teeth for Alcian Blue staining, Pearse, (1968).

Protein Demonstration:

Five teeth used for the P.A.S. method, Pearse, (1968).

Five teeth used for the Barnett and Seligman Method,
Pearse, (1968).

Five teeth used for the nin-hydrin-Schiff Method for
Protein Bound NH_2 , Pearse, (1968).

Lipid Demonstration:

Five teeth used for the Oil Red O Method, Carlton, (1967).

Five teeth used for the Sudan III Method, Carlton, (1967).

Five teeth used for the Sudan IV Method, Carlton, (1967).

Calcium Demonstration:

Ten teeth used for the alizarin red-S Method for calcium,

McGee Russel, (1958) written in Carlton, (1967).

Immediately following staining and taking care to keep the teeth moist, four shallow cuts were made in line with the fissures on mesial, distal, buccal and lingual surfaces. Such cuts permitted cleaving of the tooth to expose the pits and fissures in depth for examination of their contents.

The results were analysed according to the degree of staining reaction and to results presented by other similar investigations.

1. b Scanning Electron Microscopy of Occlusal Surface of Unerupted Teeth

173 molar and premolar teeth were selected from approximately 130 patients, mostly between 9 and 25 years of age of which 34 of these were from patients above 25 years of age. The unerupted teeth were known to have been submerged below alveolar periosteum and had not had contact with saliva when surgically extracted. Immediately after extraction the teeth were washed in tap water and fixed in 10% neutral formalin until use. The roots of the teeth were cut from the crowns on a Gillings Hamco thin sectioning machine using a water cooled rotating carborundum disc and then discarded. The occlusal surfaces were examined under the dissecting microscope for recording any structural details. After gentle

washing in water, four shallow cuts were made in line with the fissures on mesial, distal, buccal and lingual surfaces. Such cuts permitted cleaving of the tooth to expose the pits and fissures in depth for examination of their contents. The specimens were subsequently prepared for examination by scanning electron microscopy using simple air drying and then mounted on aluminium studs in order to display occlusal surfaces and/or pits and fissures. The tooth follicle in some of the specimens was either totally or partially removed to expose the underlying structures. The specimens were shadowed with gold/palladium and examined in a Cambridge Instruments Scanning Electron Microscope operated at 20 KV.

1. c Scanning Electron Microscopy of Erupted Teeth

534 molar and premolar teeth from approximately 200 patients of different ages were fixed in 10% neutral formalin immediately following extraction. Taking care to keep the teeth moist the roots were removed and four shallow cuts were made in line with the fissures on mesial, distal, buccal and lingual surfaces. Such cuts permitted cleaving of the tooth to expose the pits and fissures in depth for examination of their contents following examination of occlusal surfaces. The specimens were prepared for examination by scanning electron microscopy using a modified camphene sublimation technique described by Galil and Gwinnett, (1973a). Briefly,

the method involves dehydration, delipidization and imbibition of camphene by the specimen. The camphene, which sublimates at room temperature, provides a simple approach to handling large samples, being first developed by Watters and Buck, (1971). The whole occlusal surface of the tooth was then shadowed with gold/palladium and examined in a Cambridge Instruments Scanning Electron Microscope. Subsequently the teeth were cleaned, reshowed and the fissures and pits examined. In addition, some teeth were also examined by light optical stereomicroscopy following the application of disclosing solution.

1. d Observation on Occlusal Surface Enamel of Unerupted and Erupted Teeth

At some time throughout the present investigations all occlusal enamel was examined by light optical stereomicroscopy. This resulted in examination of 1268 teeth.

2. Pits and Fissures

Because teeth consist of the most highly mineralized tissues in the body they present considerable technical problems in their preparation for histologic examination, Avery, (1964). The preservation of tooth enamel matrix has posed the greatest problems in the preparation of decalcified sections since the mineralized component of enamel quickly passes into solution when subjected

to the action of routine decalcifying fluids, Brain, (1966).

2. a Experimental Trial on Decalcification of Enamel

Different solutions and techniques have been utilized for the decalcification of enamel, including technique of Evans and Karjian (1930), who used 85% formic acid and 20% sodium citrate as decalcifying agents, a technique of formic acid sodium citrate by Ann Morse (1945), a technique of celloidin-decalcifying method by Bodecker, McClung (1950), a technique of Hurst, Nuckolls and Conlon (1953), where agar was used as a supporting material, celloidin nitrocellulose was used as embedding material and nitric acid as a decalcifying agent, a technique of EDTA by Nikiforuk and Sreebny (1953), a technique of sodium acetate, hydrochloric acid buffer solution by Brain (1966).

In the present investigation all these methods were tried in an attempt to select the method most worthy for the aim of this study. Problems were experienced in all of them. Therefore, a modification of a scarcely used method was investigated and it proved to be the method of choice. The technique was based on one developed by Goland, Tagger and Engel (1965), in which reactive halogen compounds (Dichloro-S-Triazines) were used. The technique was performed according to the following schedule where steps 5-9 were

repeated 3 - 4 times.

1. initial fixation in Lissatan PR or Procion dye for 3 - 7 days
2. wash
3. 5% formic acid, 24 hours
4. wash
5. Lissatan PR or Procion dye, 24 hours
6. wash
7. 5% formic acid, 24 hours
8. wash
9. Lissatan PR or Procion dye, 24 hours

Since it was necessary to study the contents of pits and fissures (the main theme of this thesis) a technique was developed whereby pit and fissure contents could be recovered; the idea is based on pellicle floatation.

Technique of Floating the Pellicle

1. erupted teeth fixed in 10% neutral formalin
2. wash gently with tap water
3. trim proximal surface with a stone using water as a cooling agent
4. cut the crown using water cooled carborundum disks
5. embed the crown in wax leaving only the occlusal surface uncovered, (wax must be covering the proximal

surface only)

6. add 5% nitric acid
7. use vacuum
8. observe
9. use a stainless steel embedding basket mesh as a lifter once the pellicle floats
10. the pellicle is fixed again in formalin 10% for 24 hours and processed either in dioxane or alcohol technique and paraffin technique

2. b Light Microscopy of Contents of Pits and Fissures of Unerupted Teeth

Using the technique described by Goland et al. 20 teeth were examined.

2. c Scanning Electron Microscopy of Contents of Pits and Fissures of Unerupted Teeth

Two techniques were used, these were a simple drying technique and the modified camphene technique described by Galil and Gwinnett (1973a) both of which were described in Chapter III-1. b and Chapter III-1. c.

2. d Light Microscopy of Contents of Pits and Fissures of Erupted Teeth

These were studied by two different methods; namely,

the Goland et al. technique and the floating technique described previously. Forty erupted teeth were used (20 for Goland technique and 20 for floating technique).

2. e Scanning Electron Microscopy of Contents of Pits and Fissures of Erupted Teeth

The teeth were studied using a modified camphene technique described by Galil and Gwinnett (1973a) and detailed previously in Chapter III-1. c.

2. f Transmission Electron Microscopy of Contents of Pits and Fissures of Erupted Teeth

Preliminary studies were done only on five teeth. The method of decalcification followed the procedure given by Goland et al. (1965), with subsequent embedding for transmission electron microscopy as follows:

1. fix tissue in 3% buffered gluteraldehyde, 2 hours
2. leave in 5% sucrose wash in water over night, 2 changes
3. post fix in 1% buffered OsO₄, 1-2 hours, dehydrate:
35% alcohol 2-3 changes in 5-15 minutes, 70% alcohol
2-3 changes in 5-15 minutes, 95% alcohol 2-3 changes
5-15 minutes, absolute alcohol 2-3 changes 1 hour
4. equal parts of Spur and absolute alcohol 2-6 hours on rotator
5. pure Spur on rotator over night

6. pure Spur on rotator 2-6 hours
7. embed in Spur
8. cure at 60-70°C 1-3 days, sections are stained with 5% uranyl acetate for 10 minutes and counter stained with lead citrate for 2-4 hours.

3. In Vitro Tooth Cleaning

3. a Experimental Trials with Different Solutions

Agents were tested for their cleaning effect upon teeth prior to replication techniques. Agents used were as follows:

1. water only on 10 erupted teeth
2. water and soap on 10 erupted teeth
3. water and brush on 10 erupted teeth
4. water and pumice on 10 erupted teeth
5. water and sonication using ultrasonic equipment with light activity on 10 teeth (by Crest Ultrasonic Corporation)
6. water and sonication using ultrasonic equipment (Crest Ultrasonic Corporation) with heavy activity on 10 erupted teeth
7. water and ultrasonic treatment and Alconax detergent on 10 erupted teeth
8. ammonium hydroxide on 10 erupted teeth
9. sodium bicarbonate on 10 erupted teeth

10. sodium hydroxide on 10 erupted teeth
11. organic solvent group on 10 erupted teeth
12. hydrogen peroxide as a commercial mouthwash on 10 erupted teeth
13. hydrogen peroxide as 30% concentrate effect on 10 erupted and 5 unerupted teeth
14. ethylenediamine boiled on 10 erupted and 5 unerupted teeth
15. sodium hypochlorite 6% on 10 erupted and 10 unerupted teeth.

The number of teeth used was 170 as an experimental trial of these 150 were erupted and 20 unerupted. All teeth were checked with a disclosing solution to assess cleanliness. As a result of evaluation of the techniques, it was concluded that sodium hypochlorite was preferred and a technique was then developed as follows.

3. b Technique Involving 6% Sodium Hypochlorite Solution

1. wash teeth gently from their fixative
2. add disclosing solution to stain and observe occlusal surface
3. immerse teeth in sodium hypochlorite 6% (commercially known as Javex) amount of solution is 30cc. for every tooth

4. leave tooth for 24 hours
5. change solution of sodium hypochlorite every 24 hours
6. repeat up to a minimum of 72 hours
7. wash in running water for 24 hours.

3. c Scanning Electron Microscopy of Treated Teeth

Twenty erupted and twenty unerupted teeth were treated with sodium hypochlorite and left to dry in air over night and then mounted on a stud in order to display the inclined cuspal planes and fissures. The specimens were shadowed with gold/palladium and examined in a Cambridge Instruments Scanning Electron Microscope operating at 20 KV.

4. Replication of Teeth (three dimensional)

4. a Experimentation with Different Materials

The basic idea is to introduce a fluid monomer material into pits and fissures and then allow it to polymerize in situ.

Subsequently inorganic acids are used to demineralize the tooth substance leaving a detailed impression of occlusal surfaces and of the pits and fissures or any contents therein.

Experimental trials were done with the following materials:

1. Clear Cast (American Hand Craft Co.) using direct technique (10 blocks, erupted teeth).
2. Clear Cast (American Hand Craft Co.) using vacuum

- technique (5 blocks erupted teeth).
3. Wards Bioplastic, Wards Co. using direct technique (5 blocks erupted teeth).
 4. Wards Bioplastic, Wards Co. using vacuum technique (15 blocks erupted teeth).
 5. Spur, using methods similar to T. E. M. technique (50 blocks unerupted teeth).

As a result of evaluation of the techniques described previously it was concluded that they were fruitless and a new technique was developed using vinyl resin (Turtox-CO) which proved to be very successful.

4. b Technique of Vinyl Resin Replication

Materials: Vinyl resin (Turtox Company General Biological Supply), plastic peel boxes, acetone, conc HCl, sodium hypochlorite 6%, 80 unerupted teeth.

Procedure: - with a carborundum wheel using water as a coolant material, roots were cut from crowns of teeth and discarded

- clean the crown with the technique of In vitro cleaning described previously
- after washing 1/2 hour let teeth dry in air for 3-4 hours, preferably over night

- prepare an homogenous mix of acetone and vinyl resin 1:1, mixture must be homogenous in consistency. This is achieved by shaking for 1-2 days
- add resin to the tooth
- use vacuum 1/2 hour
- use a bath of conc HCl for dissolving teeth
- leave 24 hours
- wash with running water
- trim specimen with scissors
- mount on stud
- shadow with gold/palladium and examine in Cambridge Instruments Scanning Electron Microscope operating at 20 KV.

4. c Scanning Electron Microscopy of Vinyl Resin Replicas of Unerupted Teeth (Occlusal Surfaces, Pits and Fissures)

Eighty-one teeth were used, of these 80 were unerupted premolar and molar and one erupted central incisor. The central incisor was used as a control in which the labial surface was etched and replicated according to Gwinnett (1971). All teeth were processed according to the vinyl resin technique described in Chapter III-4. b.

IV OBSERVATIONS AND RESULTS

1. Occlusal Surface of Teeth

1. a General Histochemical Identification of Materials

Covering the Occlusal Surface of Erupted Teeth

The macroscopic appearance of the teeth studied by different procedures revealed specific localized staining reactions upon the occlusal surface. The PAS treated teeth gave, in general, a positive reaction (Fig 1A) and in some cases it was very easily distinguished in fissures against the weaker PAS positive reaction on inclined planes of occlusal surfaces.

Definite alcian blue positive areas were identified (Fig 1B). The amount of stain increased in areas related to the fissures, in which the intensity of the stain varied according to the integumental thickness. Using the Barnett-Seligman technique the occlusal surfaces were stained predominantly blue (Fig 1C) which indicated the presence of proteins and SH groups specifically. Some specimens showed very faint red on the periphery which denoted weak (SH) groups. Proteins also were stained by ninhydrin Schiff (Fig 1D) in which pinkish-red to magenta colours were observed. These colours indicate the presence of amino

Figure 1

Macrophotographs showing general identification of occlusal integument.

A - Carbohydrate demonstration using Periodic-Acid-Schiff technique.

X5

B - Mucopolysacchride demonstration using alcian blue technique .

X5

C - Protein demonstration using Barrnett Seligman technique.

X5


D - Protein demonstration using Nin-hydrin Schiff technique.

X5

A



B



C




D



A



B



C



D



acid (NH₂) proteins covering the occlusal surface. The staining for fat was positive, the colours were less strongly stained (Fig 2A) and varied from bright red to faint red. Alizarin red stained areas showed a heavy orange-red precipitate. Regions of the fissures were highly concentrated, more than the inclined planes (Fig 2B). Also, all teeth showed the presence of a band of uneven width which follows roughly the greatest contour line of the crown. This band was always seen with all previous stains (Fig 2C & D).

1. b Scanning Electron Microscopy of Occlusal Surface of Unerupted Teeth

Prior to tooth eruption the tooth is enclosed in its follicle covered by reduced enamel epithelium with a layer of connective tissue between the tooth, its covering and oral mucosa. The tooth follicle surrounds the coronal part to completely enclose the enamel (Fig 3A&B). Perikymata were easily seen on unerupted tooth enamel as well as ameloblast impressions. One theory holds that in the tissues surrounding teeth prior to eruption, inflammation occurs before piercing of the oral mucosa, Magnusson (1969). A large number of blood elements were observed (Fig 4A&B) in the fissure regions with the red blood cells being connected to each other by fine thread-like strands. The attachment apparatus was seen (Fig 4C&D) in association with the rod

Figure 2

Macrophotographs showing general identification of occlusal integument.

A - Fat demonstration using oil red O technique .

X5

B - Calcium demonstration using alizarin red technique.


X5

C - A stained band following the greatest contour of the teeth .

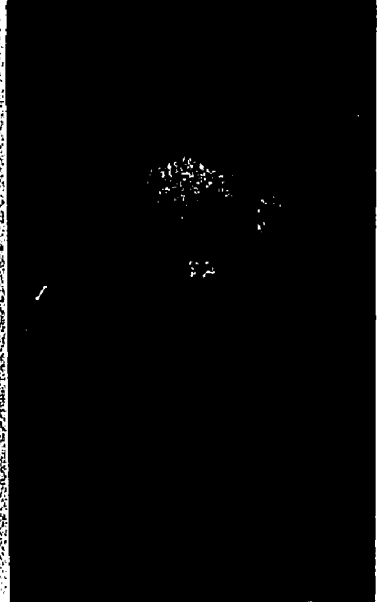
&

D X5


A



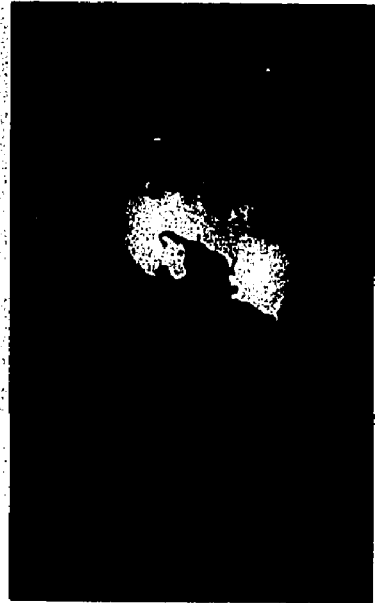
C



B



D



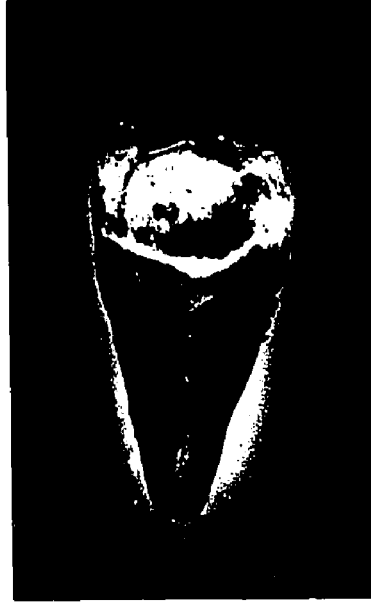A



B



C



D



Figure 3

A - Scanning electron micrograph of the occlusal surface of an unerupted molar showing the follicle in association with the enamel surface.

X 11

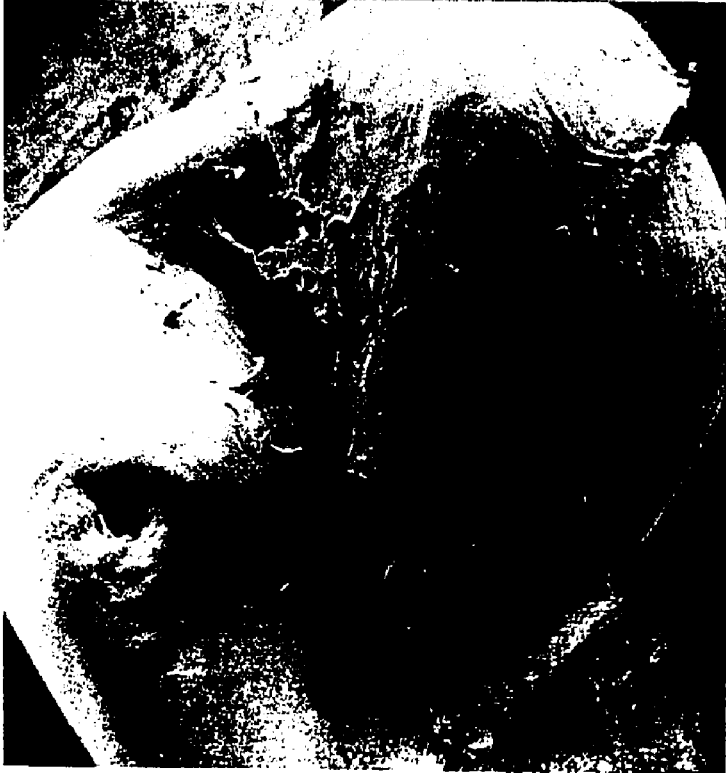B - Scanning electron micrograph of the occlusal surface of a premolar showing the follicle in association with the enamel surface and a pit on the tip of the cusp.

X 11

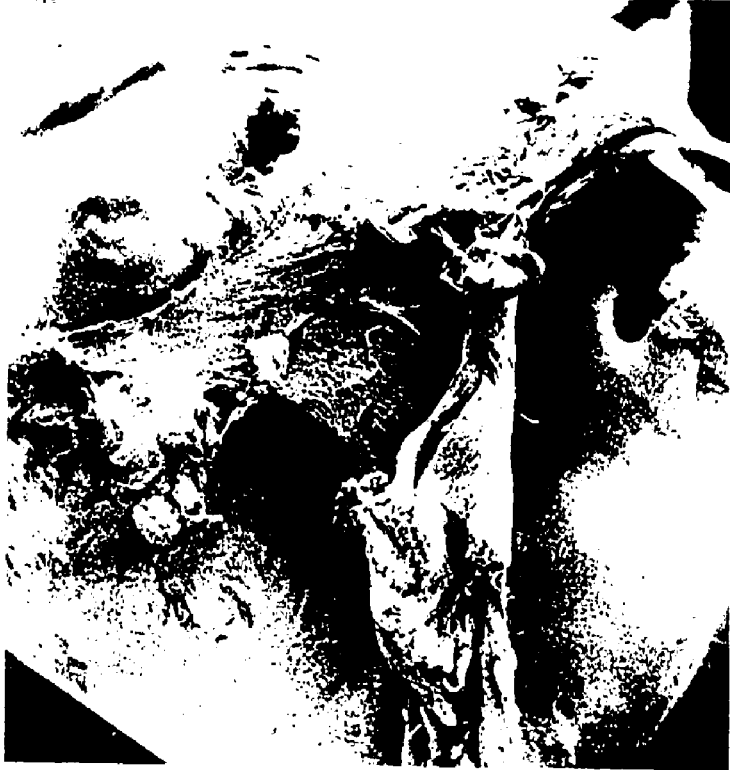A



B



A



B

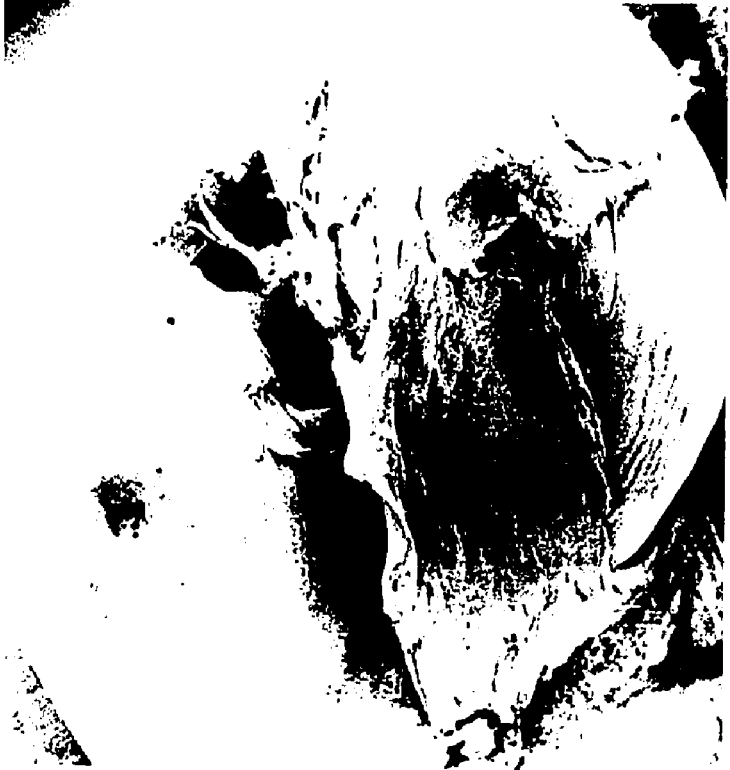

Figure 4

Scanning electron micrographs

A - Unerupted lower molar showing blood elements associated with the fissure.

X10

B - High magnification of a fissure showing predominantly red blood cells and possibly fibrin.

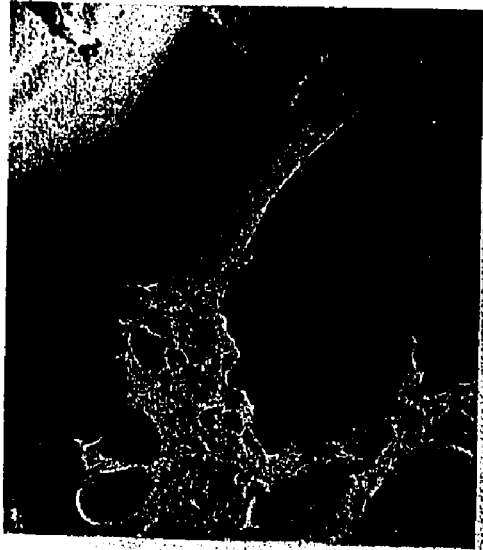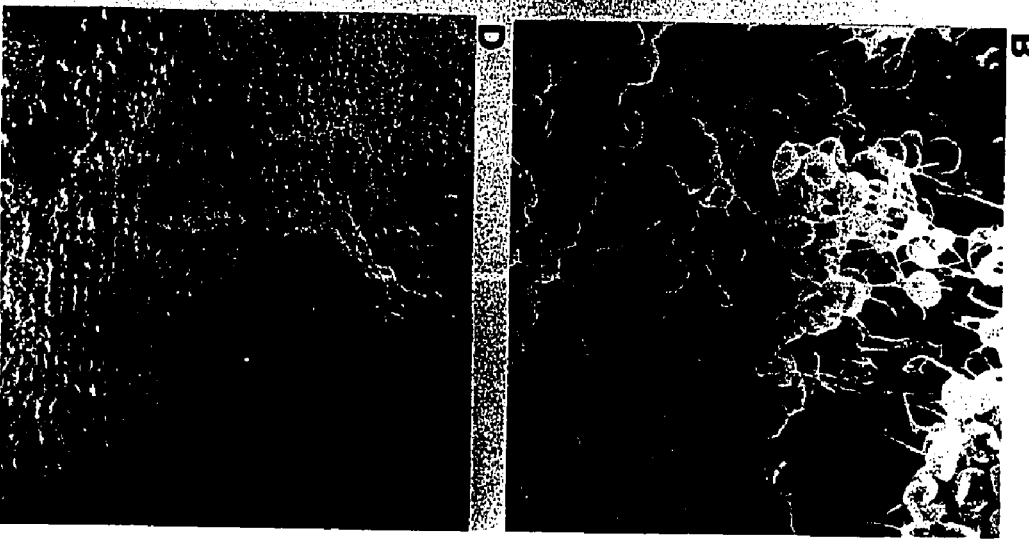
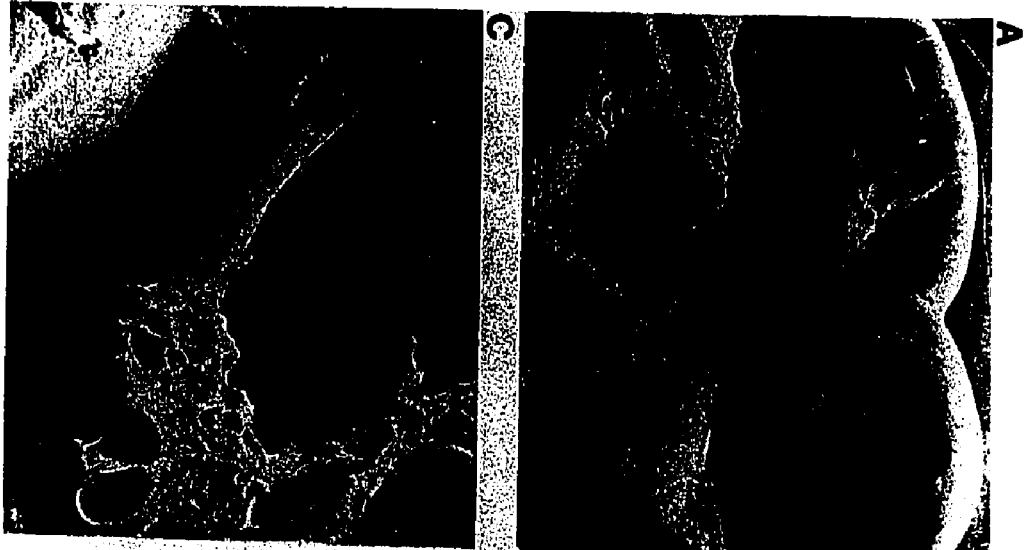
X1050

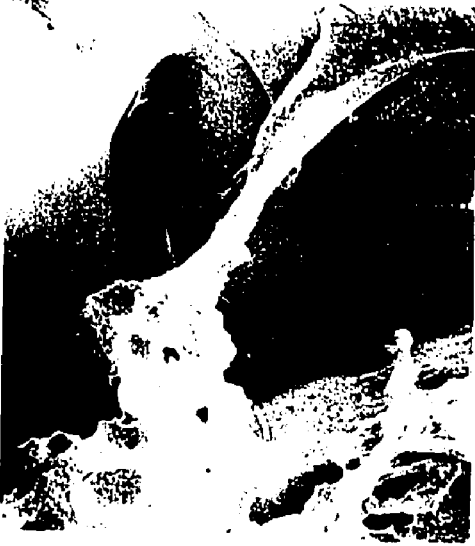C - Attachment of follicular remnants to enamel of a tooth prior to eruption and with the fissure also containing material.

X260

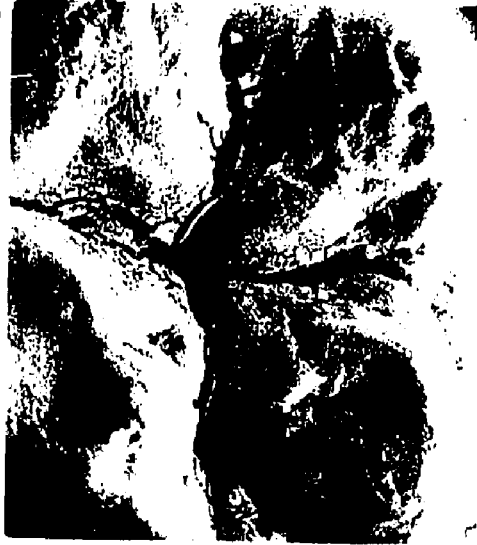D - Rod end pits of different sizes with follicular remnants in association with them.

X260







C



A



D



B

ends.

1. c Scanning Electron Microscopy of Erupted Teeth

In general, all of the erupted teeth showed features which were related to known histological characteristics of plaque. In addition, however, there were also some unusual features. There were differences from specimen to specimen in the amount of structural detail. The specimens showing the least structural detail were those completely covered with material on the occlusal surface (Fig 5A) and were deeply stained with disclosing solution. This could be equated with complete negligence of oral hygiene by the patient. Other samples showing a mild staining affinity with disclosing solution is shown in Fig 5B

At higher magnification the free surface of the tooth was seen to be masked with a thick coat of plaque in which very few structures could be identified (Fig 6A&B). These were seen in areas remote from natural or artificial cleaning. The varied population of microbial plaque is well demonstrated in (Fig 6B&C) in which different types of cocci, bacilli and filamentous organisms are seen together with large unidentified clumps (Fig 6D). Two distinct areas of occlusal plaque were identified by disclosing solutions and by the scanning electron microscope. Such areas were termed heavy and light (Fig 7A) and were equated with the amount of material covering a

Figure 5

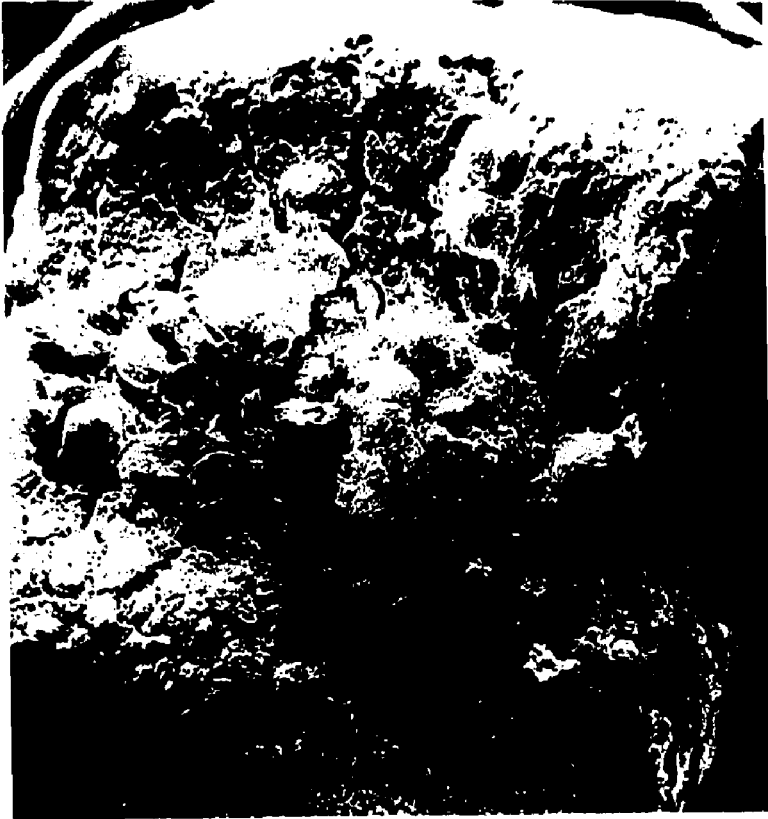A - Scanning electron micrograph of the occlusal surface of a tooth masked with heavy plaque material and having shown previously an intense staining with disclosing solution.

X20

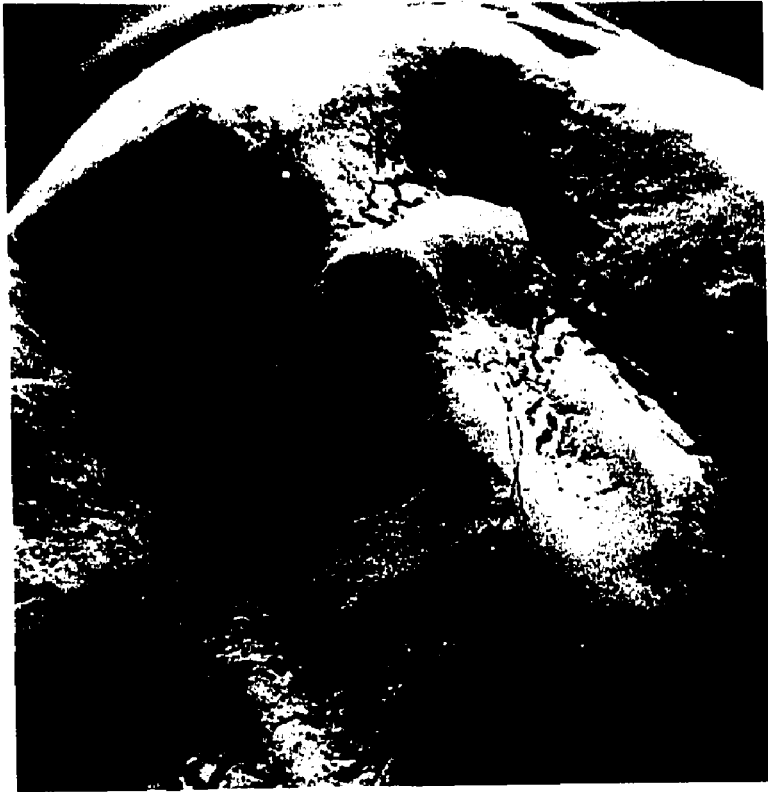B - Scanning electron micrograph of occlusal surface of a tooth masked with plaque but showing a mild reaction to disclosing solution.

X10

A



B



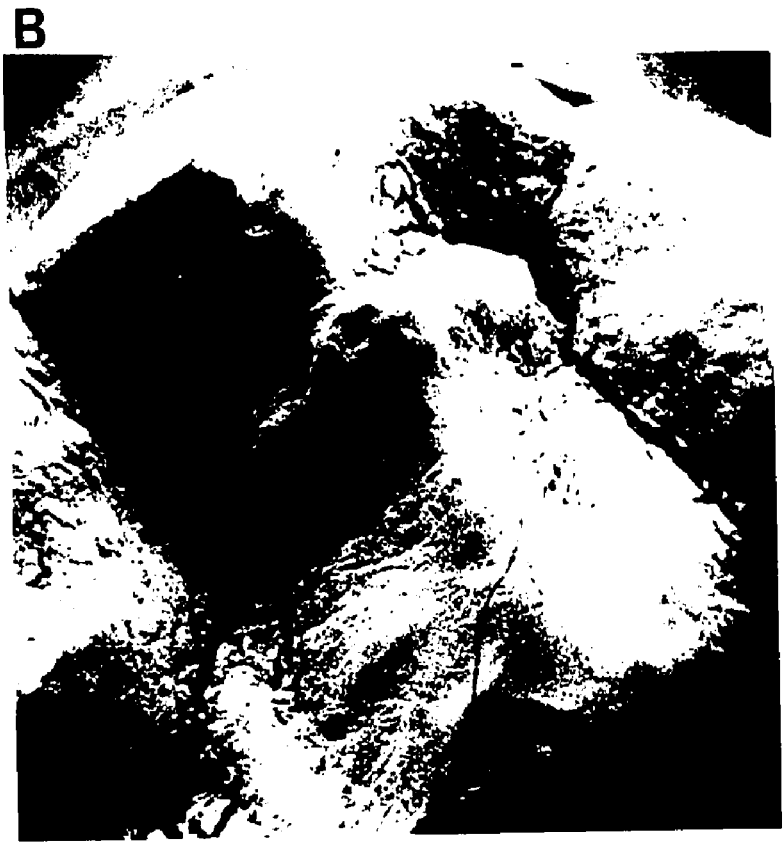
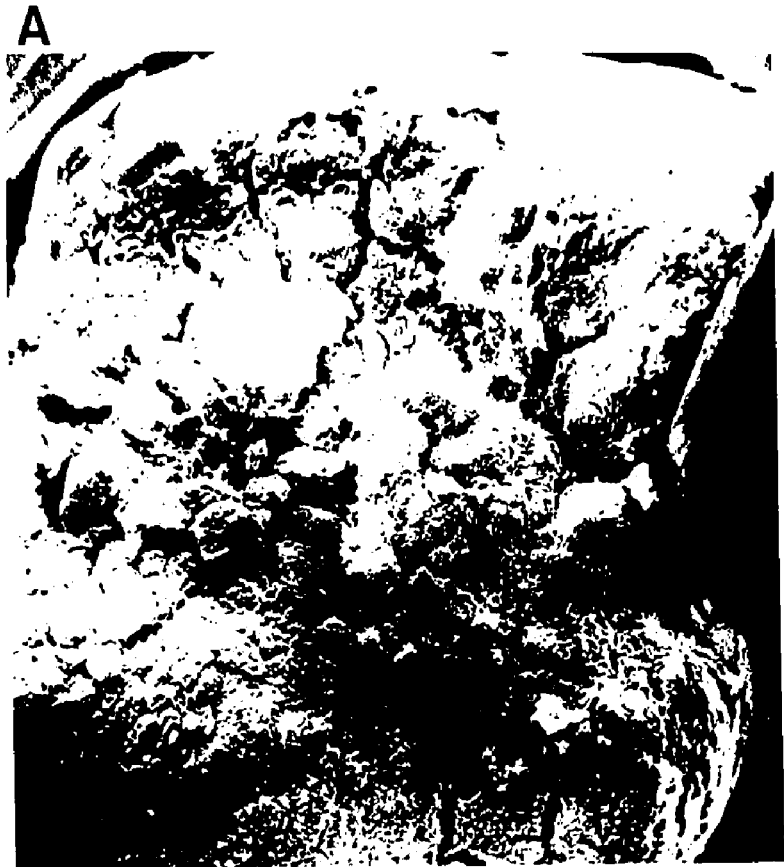
Figure 6

A - Scanning electron micrograph of an occlusal surface totally masked due to a thick coat of integument.

X1000

B - Scanning electron micrograph showing the difference between two areas of plaque. The bottom is light in composition while the top is heavy.


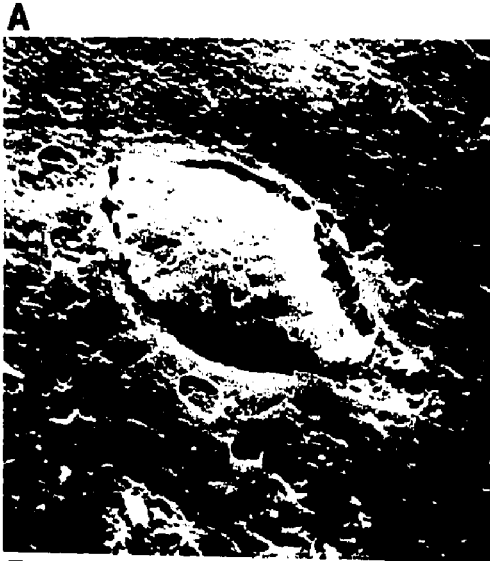
X2000

C - Scanning electron micrograph showing microorganisms, principally short rods, present on the occlusal surface.

X5000

D - Scanning electron micrograph of cocci on the occlusal surface. Note the presence of some globular masses.


X5000




A



C



B



D

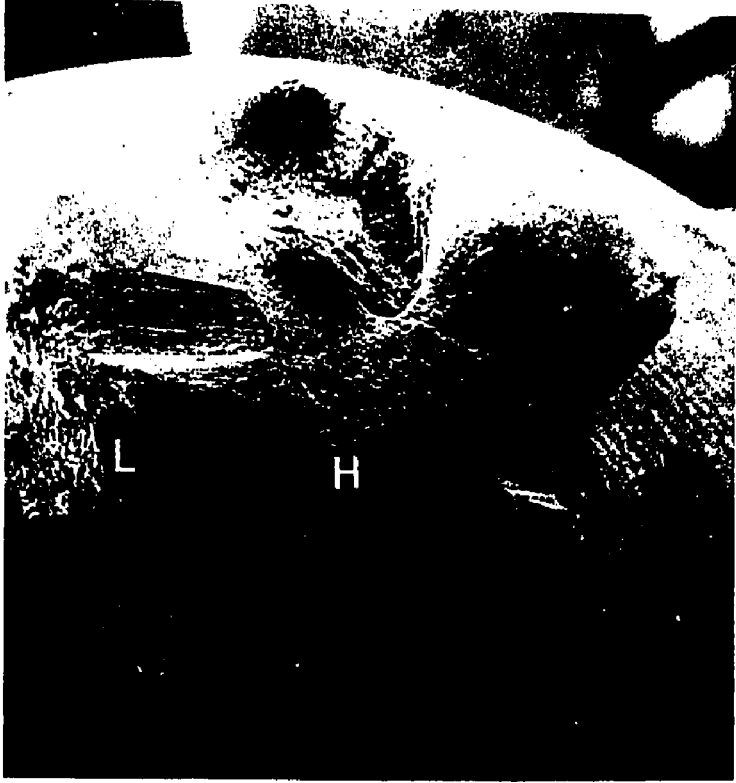

Figure 7

A - Scanning electron micrograph denoting heavy areas (H) and
light areas (L) of plaque
X20

B - Scanning electron micrograph of light areas consisting
predominantly of coccoid microorganisms.
X5000

A



B





particular area of the occlusal surface. Light areas were dominated by coccoid micro-organisms (Fig 7B) whereas heavy areas showed principally filamentous or rod-shaped organisms (Fig 8A). Groups of cocci were commonly observed in shallow depressions in the enamel of the inclined cuspal planes. The heavy filamentous groupings were always located in the region of the orifices to the pits and fissures, though some isolated areas appeared on the inclined cuspal planes. Some parts of the enamel on cuspal planes were devoid of organisms (Fig 8B). The filamentous organisms appeared to be woven together producing a bacterial mat. Within the mat were other organisms and spaces which may have been occupied by inter cellular material lost in the specimen during preparation (e. g. lipids). From the inclined cuspal planes towards the occlusal openings to the pits and fissures a transition in organism type occurred in which appeared a dominant filamentous and rod-shaped group in the region of the fissure orifice. Below this orifice and in the deeper region of the pits and fissures the coccoid variety appeared dominant (Fig 8C).

The transition from inclined planes to fissures also showed changes from light plaque areas to heavy areas containing predominantly cocci and filamentous organisms respectively (Fig 8D). An absence of perikymata is noticeable on the occlusal surfaces of erupted teeth.

Figure 8

A - Scanning electron micrograph of heavy areas of plaque showing a mat woven of filamentous and rod shaped organisms.

X2000

B - Scanning electron micrograph showing some areas of enamel devoid of organisms while in association with small depressions in enamel (D) and the fissural openings, microorganisms can be seen.

X2000


C - Scanning electron micrograph of an area of plaque associated with a fissure in which there is a dominance of coccoid organisms.

X5000


D - Scanning electron micrograph showing the transition in density of microorganisms from the occlusal surface (OC) to the fissure (F).

X5000


A



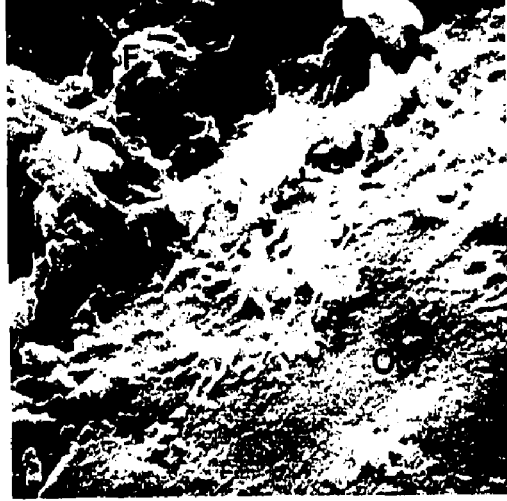
B




C



D




A



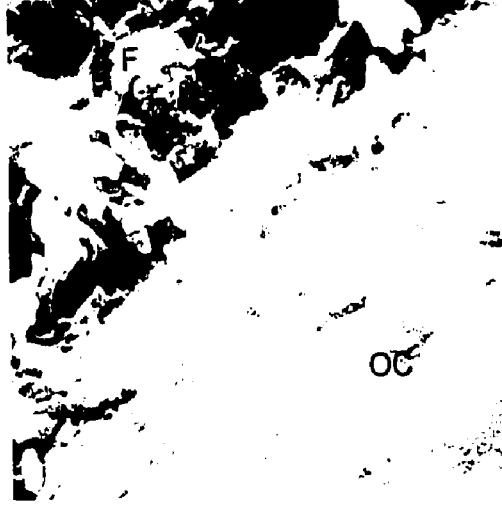
B



C



D



The presence of scratches on the occlusal surfaces of the teeth were also noted and were probably related to food abrasion or tooth brushing.

1. d Observations on Occlusal Surfaces Enamel of Unerupted Teeth and Erupted Teeth

The occlusal surface enamel of erupted teeth was always covered with integumental material (plaque, cuticle and food debris). Disclosing solution showed a positive result. These results varied from one tooth to another according to the amount of material present on the surface.

The majority of erupted teeth showed small polished facets on the enamel of the inclined cuspal planes representing attrition. Teeth extracted from young patients showed distinct perikymata on the occlusal surface and many minute scratches. The same observation was made with the scanning electron microscope.

Observations on unerupted teeth, generally showed distinct perikymata and follicular remnants. The apparent strength of attachment of the follicle to the tooth varied. While some follicles appeared firmly attached and needed scraping to detach them others were easily detached from the crown at the cervical region. One interesting observation was the presence of developmentally hypomineralized areas known as white spots.

i) White Spots

White spots were noticeable on the occlusal surfaces of unerupted teeth as macroscopic areas and were also seen on other surfaces (mesial, distal, buccal and lingual). They exhibit a diffuse hypomineralization with a faint whitish opacity. Twelve percent of the teeth examined (unerupted) showed white spots in relation to occlusal surfaces. These areas have no definite outline. They could be classified according to the following:

- A) Point distribution (Fig 9A)
 - B) Partial area distribution (Fig 9B)
 - C) Total area distribution (Fig 10C)
- A) Point area distribution showed white spot areas involving less than one cusp, usually circular and were the most frequently observed.
- B) Partial area distribution was white spots involving one or more cusps but not all of the occlusal surface. These were uncommon.
- C) Total area distribution was one in which the whole occlusal surface was completely involved. This was not common.

In relation to the fissures on occlusal surfaces of unerupted teeth, white spots were classified into:

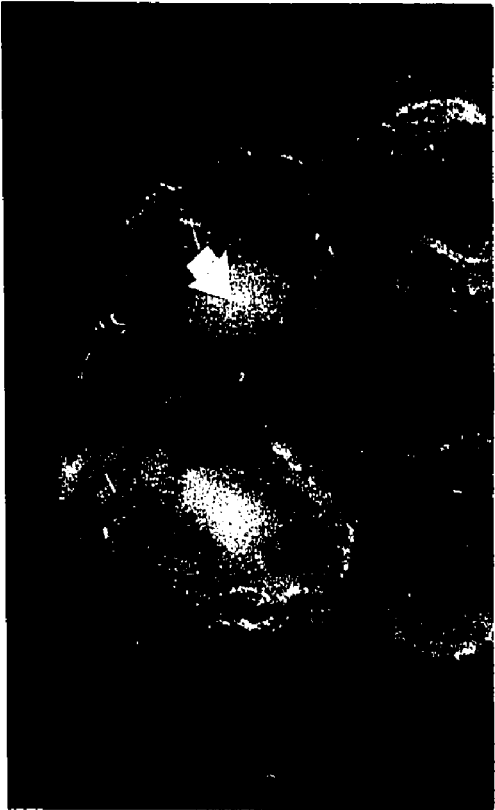- A) Total fissure involvement (Fig 9C, 10A, 10C)

Figure 9

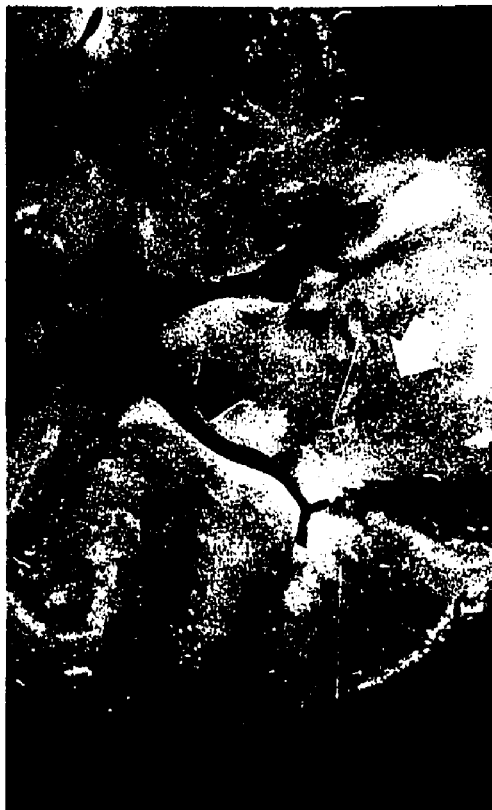Macrophotograph of the occlusal surface of unerupted teeth showing white spots. White arrows are for area distribution, black arrows are for fissure involvement.

- A - Point distribution (white arrow). No fissure involvement (black arrow).
- B - Partial area distribution (white arrow), partial fissure involvement (black arrow).
- C - Partial fissure involvement (large black arrow), total fissure involvement (small black arrow).

A



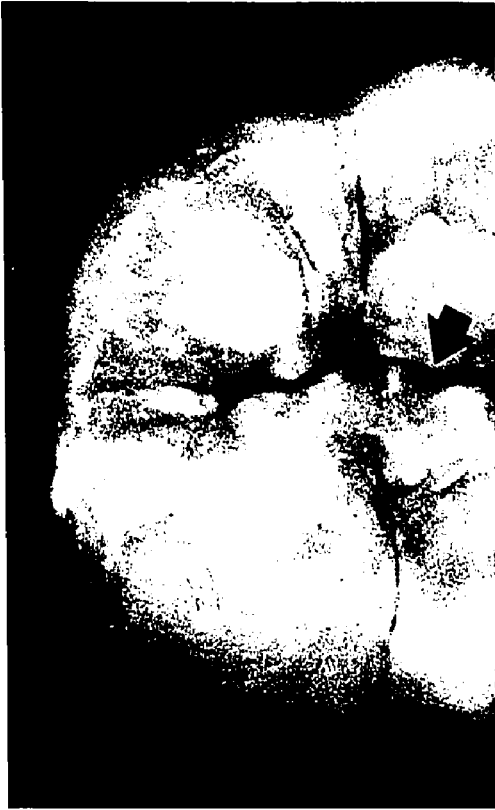B



C



A



B



C



Figure 10

Macrophotograph of the occlusal surface view of unerupted teeth with white spots.


*
A - Total fissure involvement (black arrow).

*
B - No fissure involvement (black arrow).

C - Total area distribution and total fissure involvement (white arrow). The tooth is also compared to "normal" unerupted tooth.

*- The detail in question in Fig 10 A is not to be confused with reflected light or other related phenomena, where as the "high light" seen on the arrow side of Fig 10 B is reflected light


A

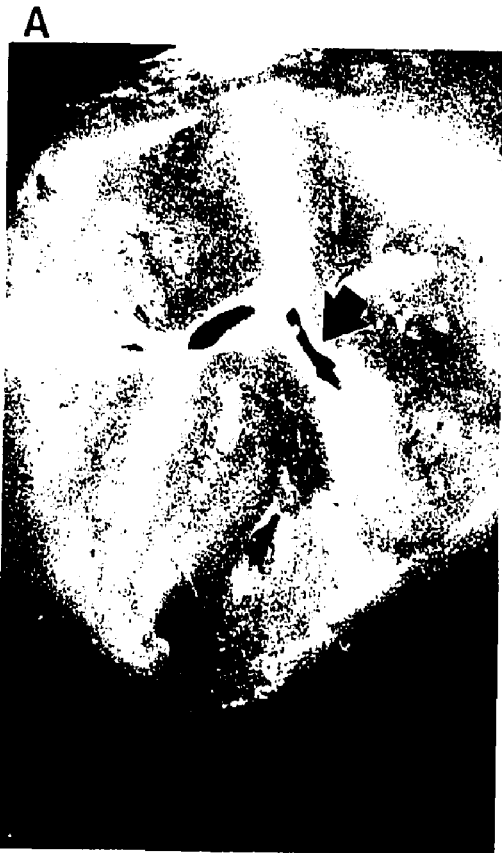

B



C





B) Partial fissure involvement (Fig 9B, 9C)

C) No fissure involvement (Fig 9A, 10B).

Total fissure involvement indicates involvement of a single fissure in which part of the fissure appears totally white. Partial fissure involvement consists of part of a single fissure while the rest of that same fissure is not involved. No fissure involvement is self explanatory. The last category was the most common. Specimens also showed involvement of the enamel of the inclined cuspal planes surrounding the fissures, while the fissures themselves were not involved.

2. Pit and Fissure Content

2.a Experimental Trials on Decalcification

The Goland technique proved to be profitable for both erupted and unerupted teeth (Fig 11A, 11B). Di-chloro-triazine compounds were effective with Lissatan-PR being preferable for its colour transparency in contrast to procion dyes. The latter red or blue usually masked and produced confusing results. The application of the Goland technique for transmission electron microscopy is also of benefit. The development of the floatation technique showed its value in studying the contents of the pits and fissures and the simplicity of the technique should be considered. The floatation technique (Fig 12A, B&C) depends on direct observation and needs continuous observation to

Figure 11

A - Macrophotograph showing, on the left side, a pared unerupted tooth with its follicle attached to the occlusal surface, compared on the right side to an erupted tooth.

X5

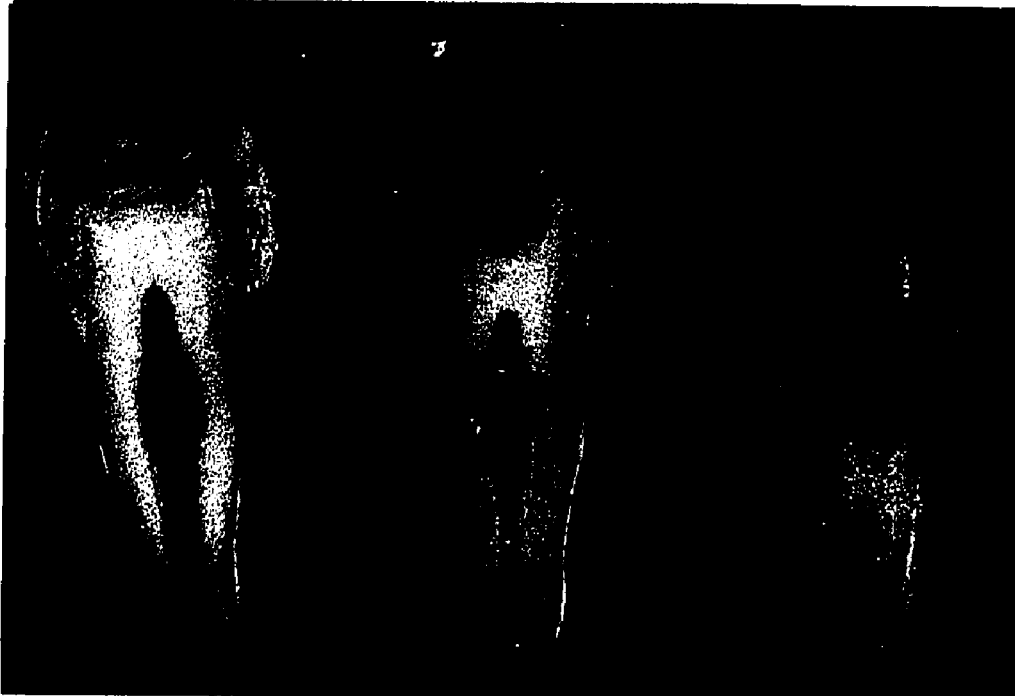B - Decalcification of unerupted teeth using the Goland technique. Notice the follicle completely covering the occlusal surface and the wide apex of the incompletely formed root. Macro-
photograph.

X3

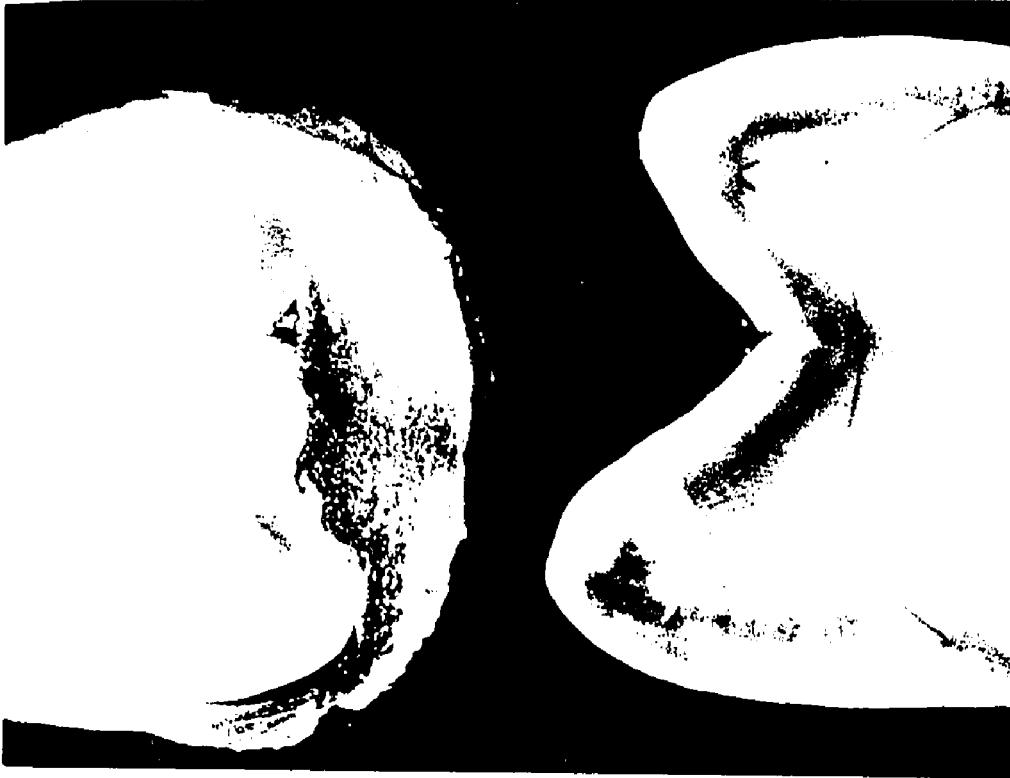A



B



A



B

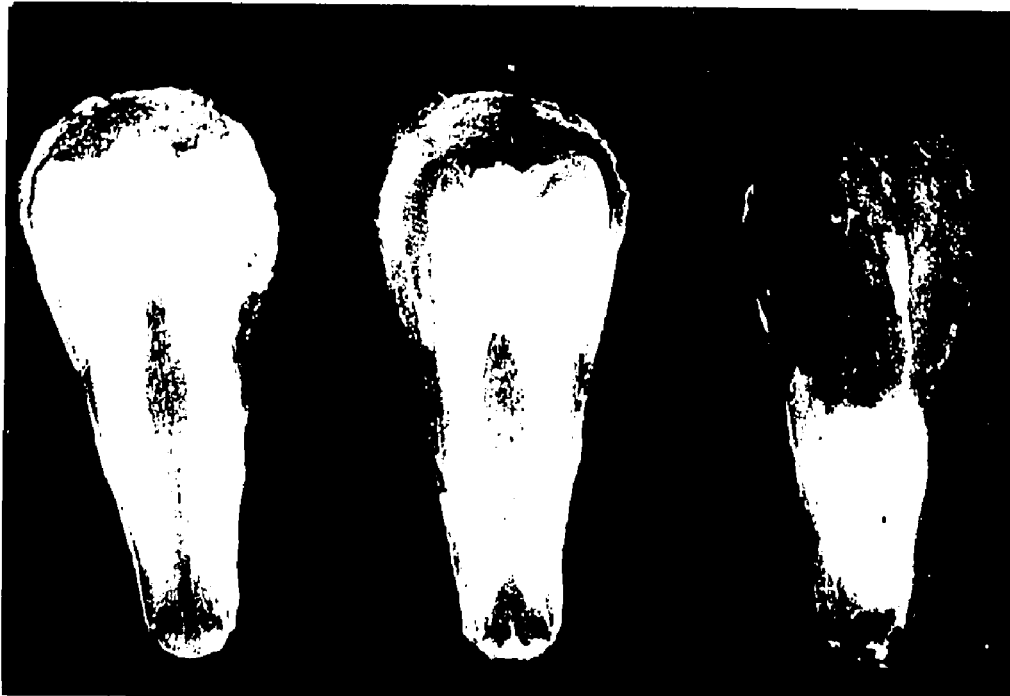

Figure 12

A - Simplicity of the flotation technique, showing tooth, floated material (pellicle), and steel basket.

X2


B - Tooth mounted in paraffin wax for the flotation technique. The fissure indentations can be seen. Macrophotograph.

X4

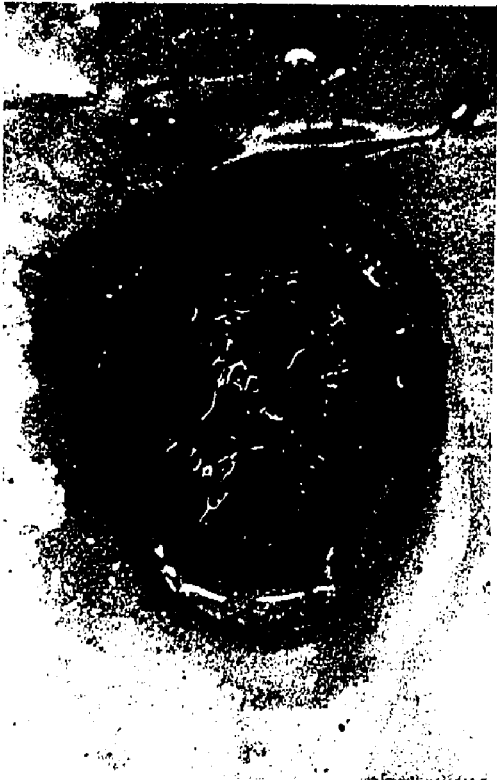C - A floated pellicle.

X8

A




B



C



A



B



C



maintain the experiment.

For deciding upon the end point of decalcification, different methods were used and of these the piercing method was proven unreliable. The bending test was impossible due to the extreme fragility of the teeth. Observing carbon dioxide bubbling during decalcification proved unacceptable. Another method of determining the end point of decalcification is by radiography. This method is considered to be the best by many investigators. The results proved satisfactory in some cases, but in others the inability of x-rays to detect small amounts of mineral later proved to lead to distortion and destruction of tissue during sectioning. This was frustrating since it could prove a waste of two months of preparation. Operating at 75 KV and exposures for 3/20 seconds, x-rays were taken (Fig 13A, B&C). The surface layer of enamel showed its resistance to decalcification in relation to the sub-surface area of enamel (Fig 13D).

2. b Unerupted Teeth


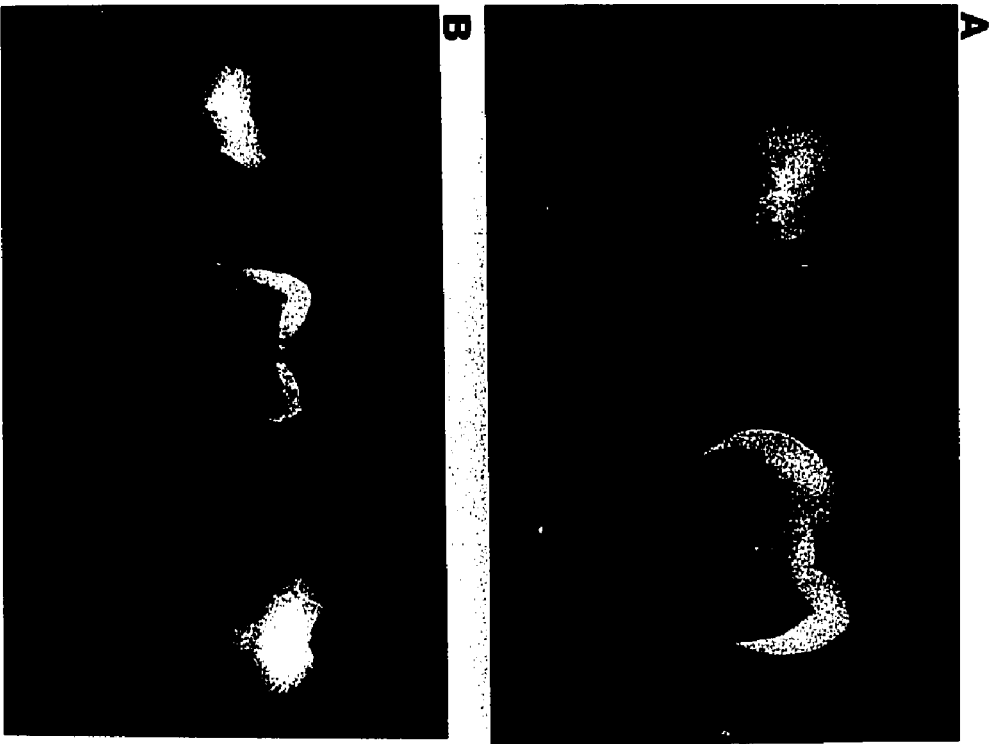
i) Light Microscopy

The tooth follicle attached to (Fig 14A&B) and surrounding the tooth surface contained fibers seen to run parallel to the tooth surface with blood vessels interspersed between them. The reduced enamel epithelium

Figure 13

Radiographs of teeth taken during decalcification.

- A - Teeth prior to decalcification, revealing the presence of calcified tissue in both enamel and dentine.
- B - Teeth during decalcification showing differences in radiopacity.
- C - Final stages of demineralization.
- D - Radiograph showing demineralized subsurface enamel with a resistant surface enamel (arrow).



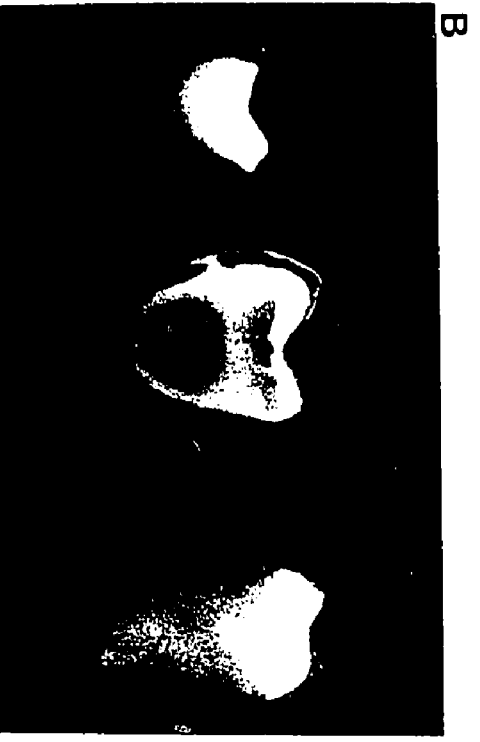
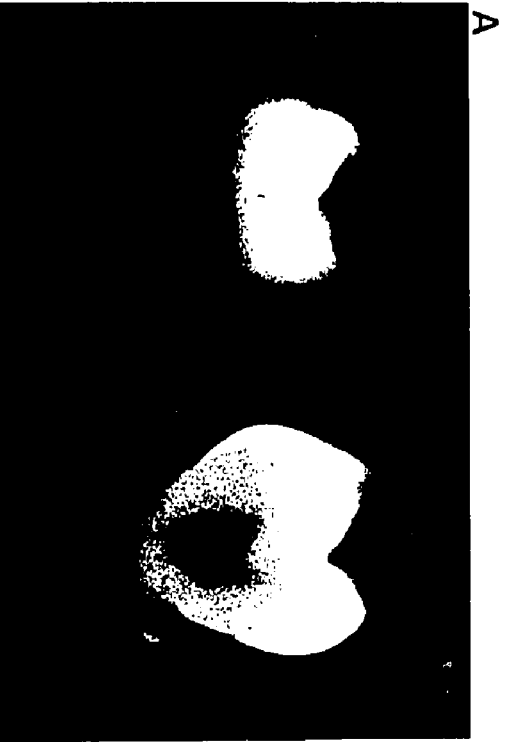

Figure 14


A - Tooth follicle attached to the enamel surface of an unerupted tooth. Notice the arrangement of follicular fibers.

X7

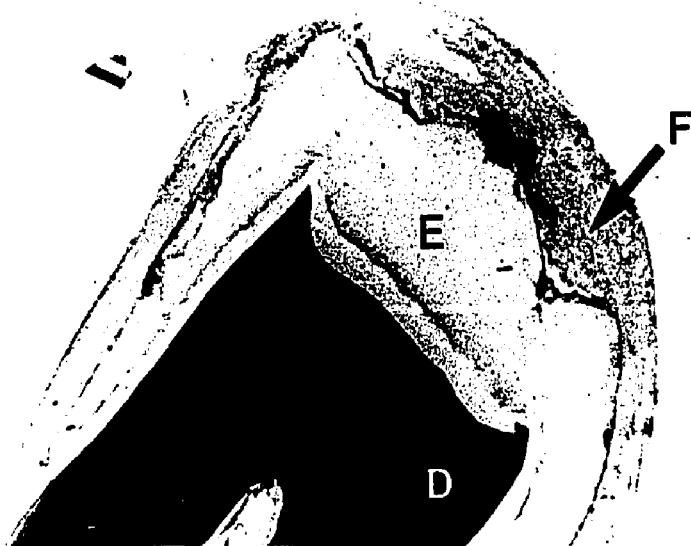
B - Light micrograph section of an unerupted tooth with its follicular remnant (F), decalcified enamel (E) and dentine (D).

X20

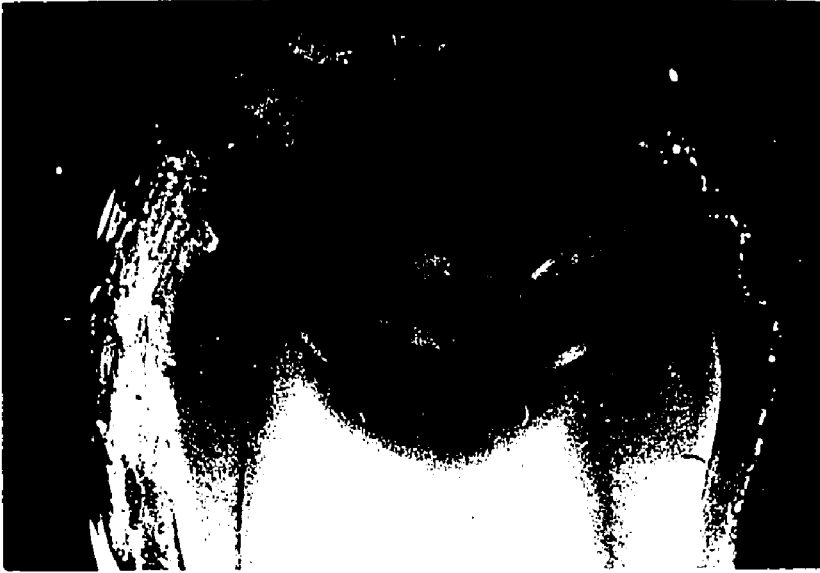A



B



A



B



was also observed. The presence of an acellular layer was also noticed between the enamel surface and ameloblasts. Histological sections through fissures of unerupted teeth were seen to contain ameloblasts lining the fissure wall (Fig 15&16). The ameloblasts usually measured 40 microns in length and their diameter was 5-6 microns. They were seen to be connected with one another possibly by intercellular bridges and their nuclei were either oval or elongated and situated in the distal end of the cell. The cytoplasm was acidophilic. The ameloblasts showed a tendency to orientate towards the occlusal opening of the fissure which indicates a possible directing force pulling on these cells. Also, ameloblasts showed signs of aggregation along the whole length of the fissure. They were also noticed at the base of the fissure. The ameloblast aggregations appeared squeezed within the fissure.

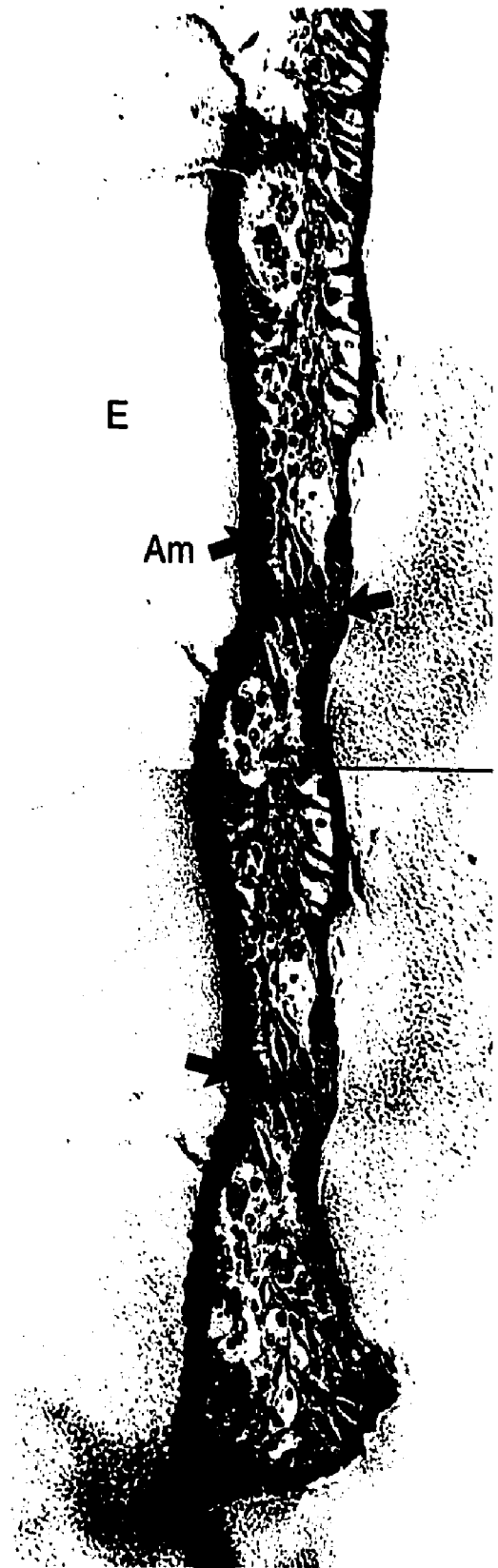
Layers of cells were seen to overlay the ameloblasts. These cells were similar to cells which form the epithelial enamel organ.

Some of the fissures also contained red blood cells and other blood elements within them (Fig 17A&B). These could be attributed to hemorrhage due to eruption forces, or due to the inflammation process of eruption

Figure 15

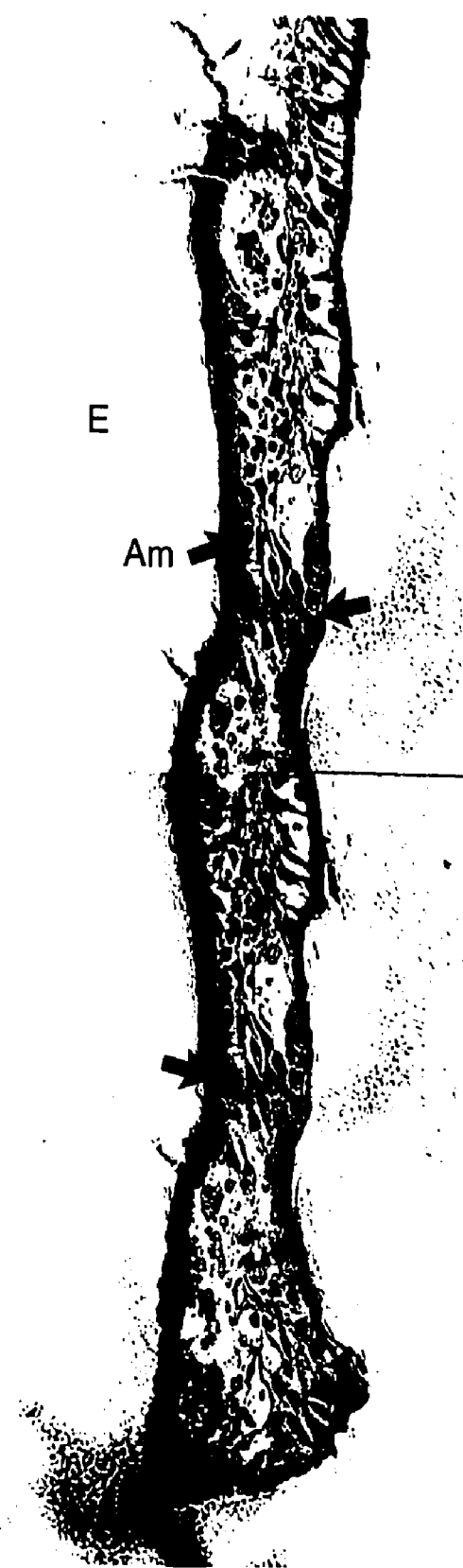
Light micrographic montage of a fissure of an unerupted tooth, stained with H & E and showing enamel matrix (E). Ameloblasts (Am) are shown directly associated with the wall of the fissure. Cells appear crowded in the center and toward the bottom of the fissure (arrow).

X450



E

Am



E

Am

Figure 16

A - Unerrupted fissure, light micrograph. Large spaces (S) are seen in the middle of the fissure along with degenerating cells. Ameloblast (Am) are attached to the enamel (E), together with other remnants of the epithelial enamel organ. Arrow indicates the contentious primary enamel cuticle.
X1000

B - Cells at the bottom of a fissure of a tooth. The arrow indicates a capillary like space, while ameloblasts (Am) line the fissure wall.
X1000

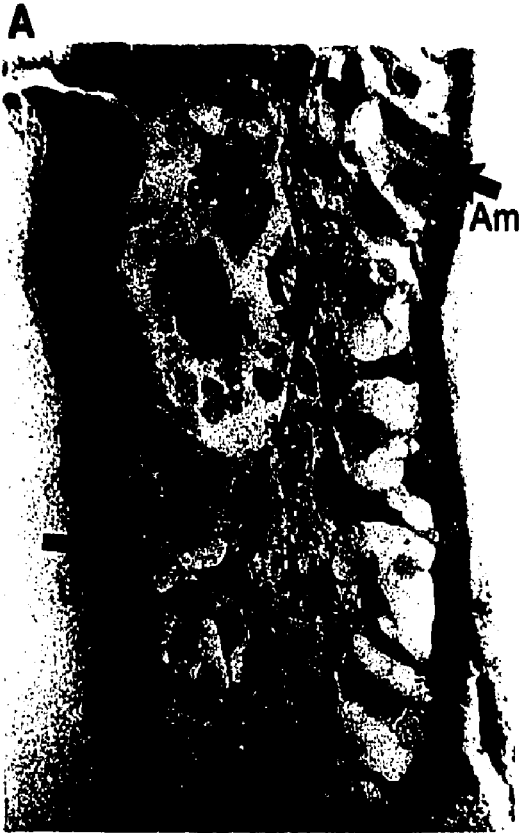

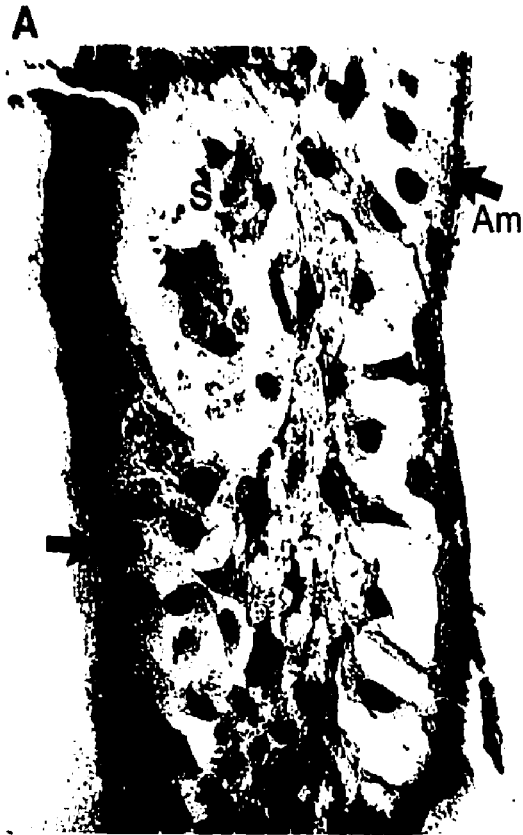


Figure 17

A - Light micrograph of a section through a fissure of an unerupted tooth stained with heamatoxylin and eosin. The fissure is filled with blood elements.

X100


B - Higher magnification shows both erythrocytes and leukocytes in the fissure.

X400

A



B



A



B



which occurs directly before the tooth begins to enter the oral cavity, Magnusson, (1969).

ii) Scanning Electron Microscopy

The tooth follicle was always observed in relation to the fissure. The outline of the fissure was manifested in different forms such as the very shallow type (Fig 18A) or the deep invaginated type (Fig 18B). The contents of the fissures were comprised of red blood cells (Fig 19A& B) and ameloblasts directly attached to the wall of the fissure (Fig 19C). To conclude that the cells were ameloblasts a comparison was made between ameloblasts seen by light microscopy and those seen with the scanning electron microscope (Fig 20A&B). The similarities between them both with respect to direction of orientation and outline suggests a justifiable conclusion.

2. c Erupted Teeth

i) Light Microscopy

Using the floatation technique, the integument was generally seen to be yellowish-brown in colour. It was attached directly to the fissure wall (Fig 21A). On direct examination refractile elements were observed together with streaks or lines along the centre of the material (Fig 21B), running from the top to the bottom of the

Figure 18

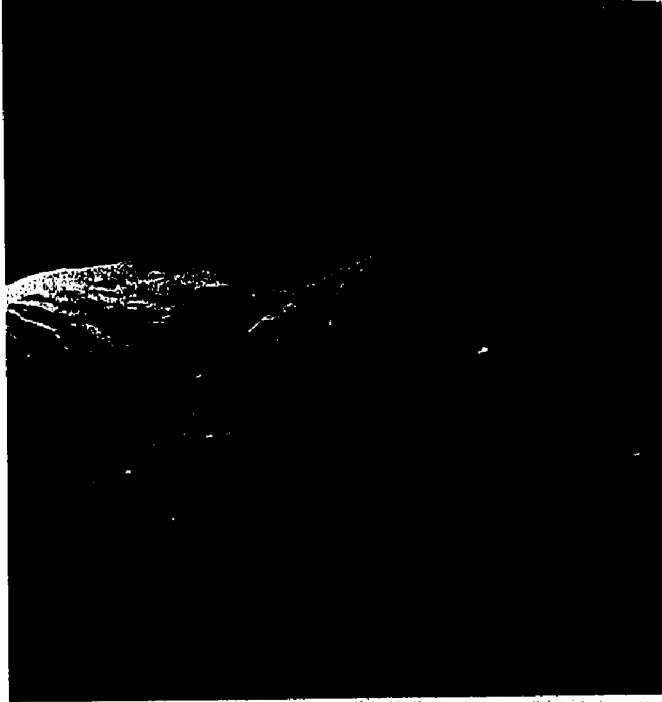A - Scanning electron micrograph of a fractured unerupted tooth demonstrating the follicular remnants in a shallow fissure.

X20

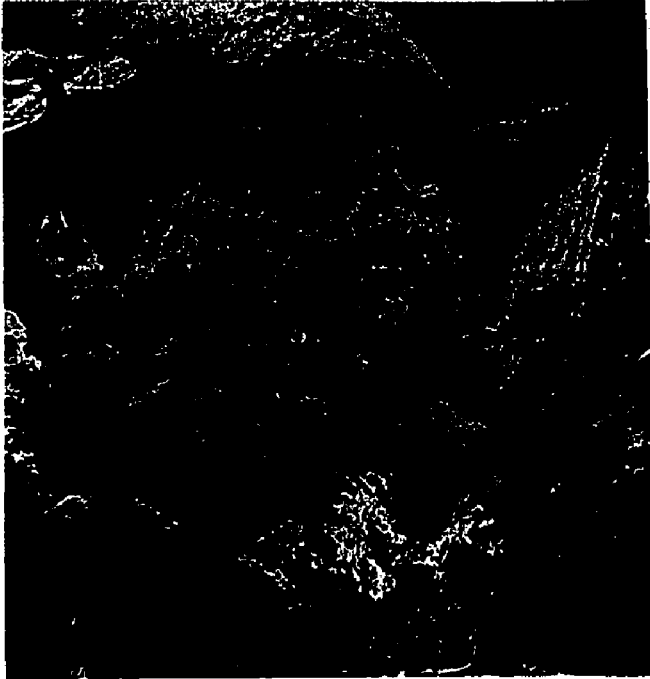
B - Scanning electron micrograph of a fractured unerupted tooth demonstrating follicular remnants in a deep invaginated fissure.

X50

A



B



A



B



Figure 19

A - Scanning electron micrograph showing red blood cells in relation to the wall of the fissure.

X1000

B - Scanning electron micrograph demonstrating red blood cells on top of structures (arrow) directly attached to enamel wall (E).

X1000

C - Scanning electron micrograph of contents of a fissure in an unerupted tooth showing red blood cells*, the enamel of the fissure wall with ameloblasts* attached to it.

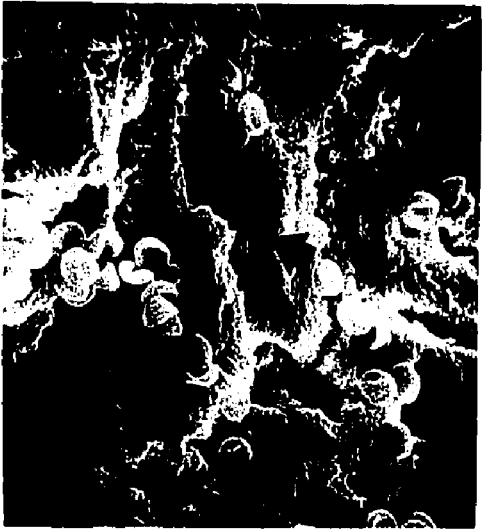X1000

*- Red blood cells(White arrow)


*- Ameloblasts (Black arrow)



A



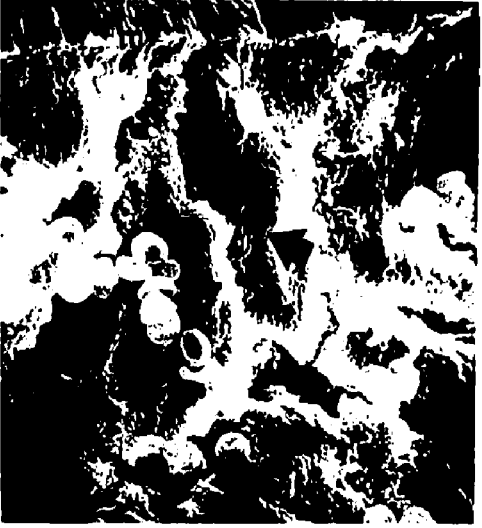B



C



B



C




Figure 20

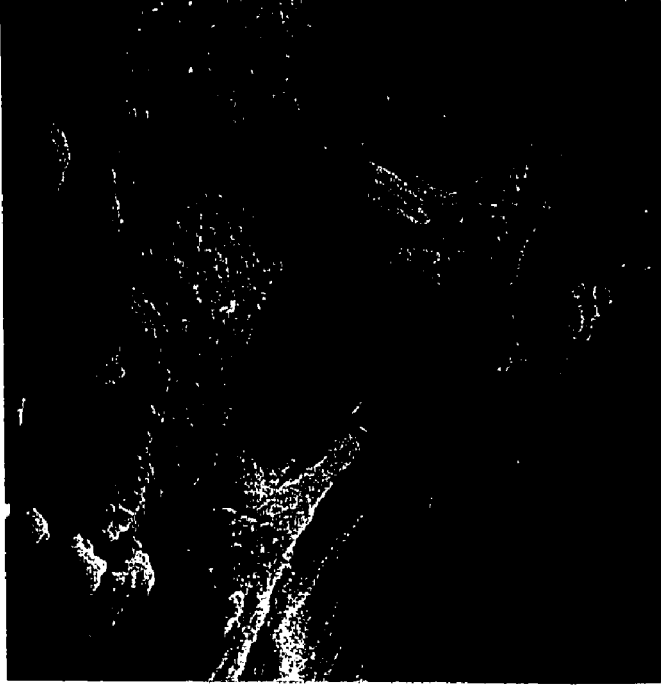
A - Scanning electron micrograph of ameloblasts directly attached to the enamel wall of the fissure. Notice the size of the red blood cells, 7 microns to size of ameloblasts, 40 microns. Also, notice ameloblastic process pointing toward the occlusal surface.

X2000

B - Light micrograph of a decalcified section through the fissure of an unerupted tooth showing ameloblast (Am), related to enamel (E). Notice the nucleus and its apical location, and the pointed shape of the apical part of the cell directed occlusally.

X1700

A



B



A



B



E

Figure 21

A - Light micrograph of the contents of a fissure of an erupted tooth (no staining). Notice the lower part of the contents conforming to the outline of the fissure.

X100

B - Light micrograph of contents of a fissure of an erupted tooth. High magnification of the center of the fissure shows streaks or lines.

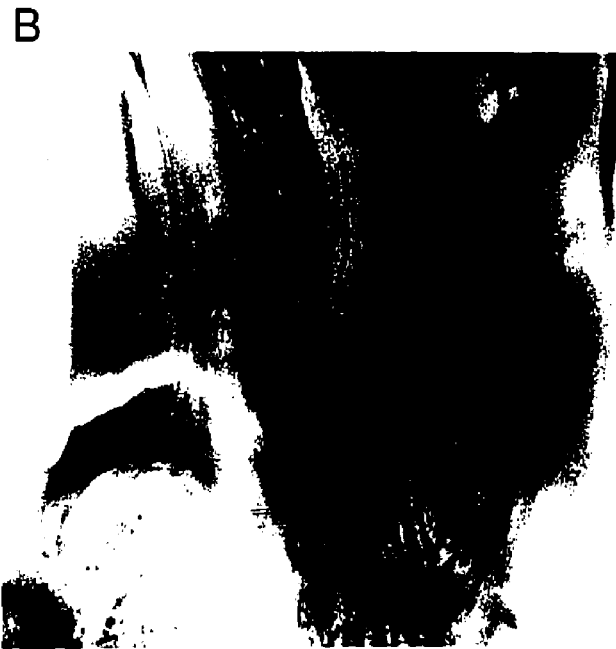X250

A



B





fissure. Junctions between these lines were also noticed. The significance of these features is unknown. On staining, the fissure contents appeared acidophilic (Fig 22), always homogeneous with condensed material filling the lower 1/3 of the fissure. The top 1/3 of the fissure was filled with light yet condensed material and the middle 1/3 showed a transition. The presence of a cuticular structure attached to the enamel surface was noted on the upper 1/3 of the fissure while the middle and lower did not show such structure. When fissure contents were stained using the May-Grunwald-Giemsa method, Luna, (1968), blue areas denoting bacteria were seen in the form of dots. The fissure contents also showed a tendency to stain specifically at the periphery suggesting the keratinous nature of the outer layer of contents. On staining with alizarin red for calcium, the reaction was highly positive in the lower part of the fissure. The staining intensity also increased toward the bottom of the fissure (Fig 23B) following use of the Brown and Brenn method for gram-positive and gram-negative bacteria, Luna, (1968). Filamentous materials as well as streptococci were seen. Both gram-positive and gram-negative organisms were observed (Fig 24A&B). On culturing the fissure contents large numbers of streptococci were seen after 72 hours

Figure 22

Light micrograph of a section through a fissure of an erupted tooth showing dense homogeneous material at the bottom of the fissure and lighter material at the top. Notice cuticular structure (C) on both sides extending from the surface and fading as it approaches the bottom of the fissure.

X400





Figure 23


A - Light micrograph of a section of floated pellicle stained by the May-Grunwald Giemsa method, blue spots (dark in this photograph) denote the presence of bacteria. Refractile material was also noticed.

X750


B - Light micrograph of an erupted tooth showing concentration of the stain at the bottom of a fissure suggesting an increased amount of calcium. Stained with alizarin red.

X400


A



B



A



B

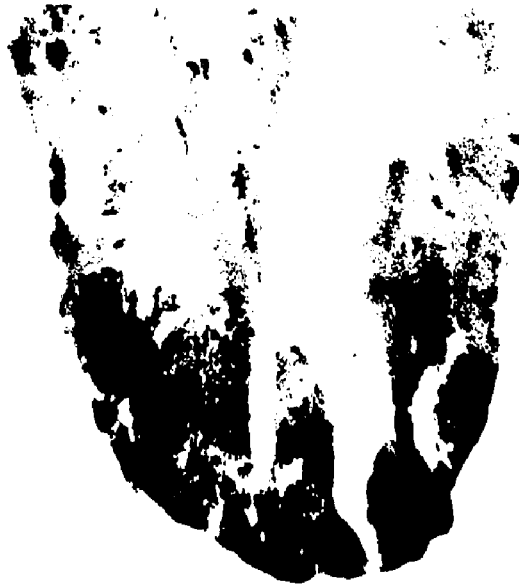

Figure 24

A - Light micrograph of a section of a fissure of an erupted tooth stained by the Brown and Brenn method for gram positive and gram negative bacteria. Total fissure staining denotes the presence of both gram positive, gram negative and filamentous bacteria.

X400

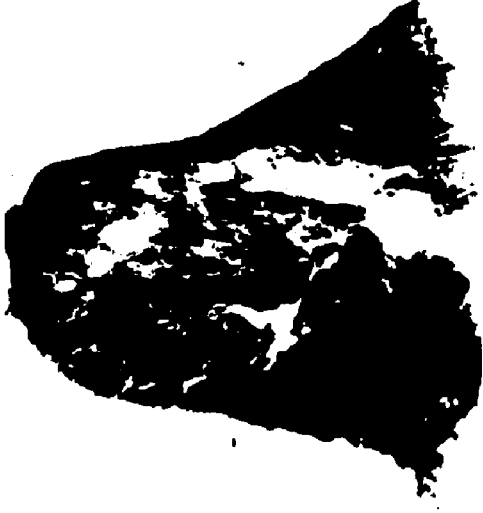B - Light micrograph of a section of a fissure of an erupted tooth stained by the Brown and Brenn method for gram positive and gram negative bacteria.

X1000

C - Light micrograph of organisms cultured from pellicle in which gram positive cocci are seen to be arranged in clusters.

X1000


A



B



C






B



A



C

(Fig 24C). The culture of bacteria was done using blood agar media (Fig 25A, B&C). Strict aseptic conditions were followed preventing any chance of contamination of the fissure content culture.

With the use of the Goland technique, the enamel matrix was recovered including enamel lamellae. The fissure contents were attached inside the fissure and showed different densities (Fig 26A, B&C). The centre of the fissure contents was full of highly dense material with a tendency towards basophilia (Fig 26B) while the outer peripheral material showed an esinophilic tendency. The separation between fissure content and fissure wall was seen in some instances and this probably was due to technical artifacts.

ii) Scanning Electron Microscopy

The general outline of the fissures of erupted teeth corresponded with the general outline of those of unerupted teeth. The differences lay mainly in the contents of the fissures. The fissures of erupted teeth were seen to be filled completely (Fig 27A&B). The presence of fissures running from the main fissure was frequently noticed, i. e. secondary branching of the main fissures were seen (Fig 27C). At higher magnification the fissures of the


Figure 25

- A - Blood agar plate with colonies showing after 48 hours.
- B - Blood agar plate with colonies (shown by arrow) after 48 hours, other colonies are not considered because they are outside the lesion.
- C - Blood agar, arrow indicates colony with hemolysis occurring, other colonies are not to be considered.


A




B




C



A



B



C




Figure 26

A - Light micrograph of a section of a decalcified tooth using the Goland technique and showing enamel (E) with densely homogeneous (DH) and light homogeneous (LH) material. The arrow indicates a cuticular structure related to enamel.
X600

B - Light micrograph of a section of a decalcified tooth using the Goland technique in which enamel (E), enamel lamella (EL) and fissure contents (C) are evident.
X600

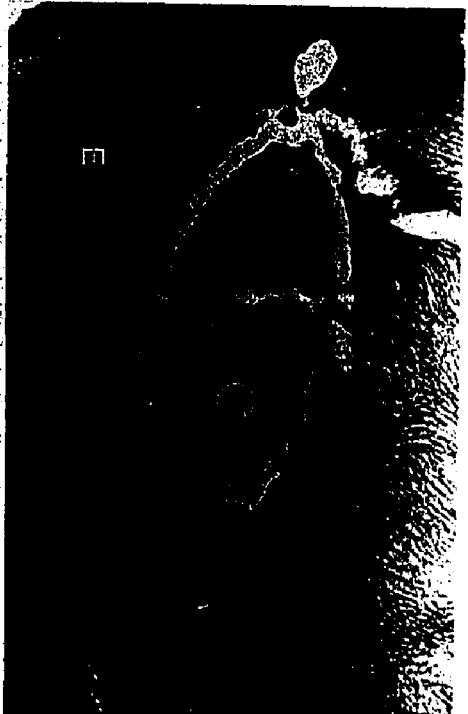
C - Light micrograph of a section of a decalcified tooth using the Goland technique. Longitudinal section showing enamel (E) and fissure contents (C).
X600

Refractile material was also seen in fissures in A, B and C.


A



B



C



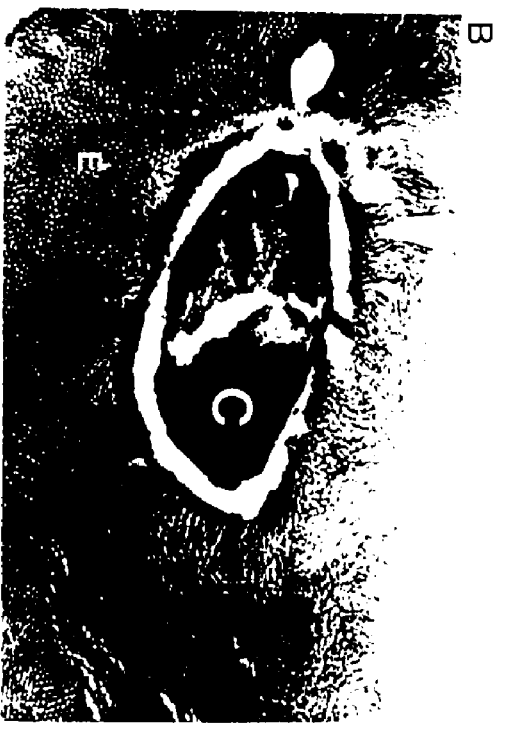


Figure 27

A - Scanning electron micrograph of a "cleaned" erupted tooth, showing plaque material (P) passing from the occlusal surface to the fissure.

X50

B - Scanning electron micrograph of a "cleaned" erupted tooth, showing plaque material (P) passing from occlusal surface up to the bottom of the fissure. Notice the enamel rods (ER).

X100

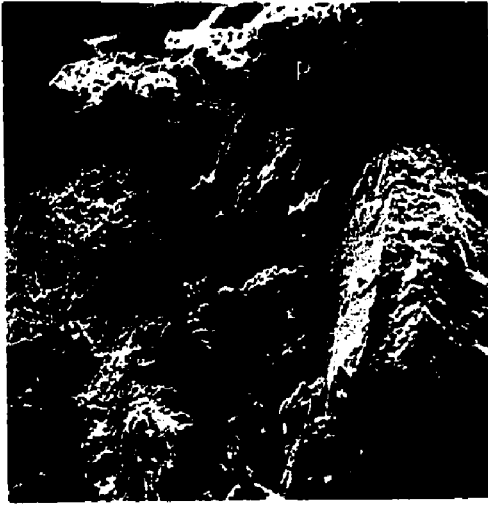C - Scanning electron micrograph of a "cleaned" erupted tooth, showing plaque material (P) filling the fissure. Notice the presence of a fissure in a perpendicular direction to the main fissure.

X50

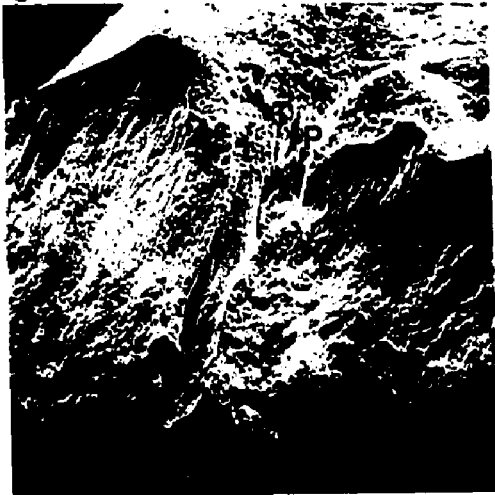A

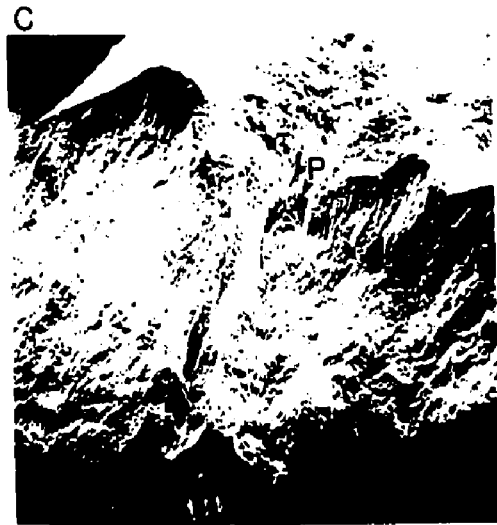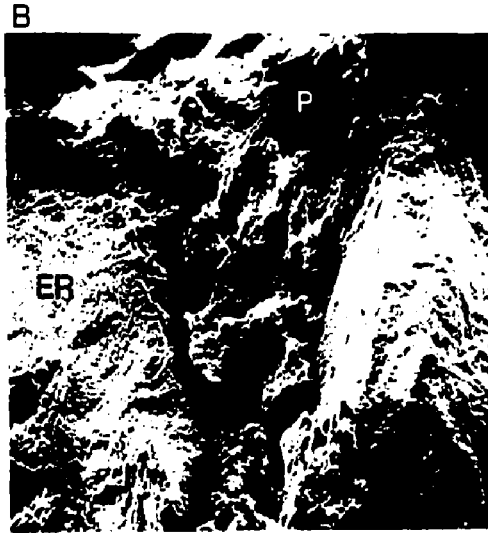


B



C





erupted teeth were seen to contain bacteria of different types (Fig 28A, B&C) e.g. cocci, bacilli and filamentous organisms of different sizes and shapes. The transition from the inclined cuspal planes to the fissures was noted in which cuspal enamel was dominated by coccoid organisms which gradually gave way to a dominant filamentous and rod shaped group in the region of fissure orifice, Galil and Gwinnett, (1973b). These organisms were also demonstrated using stereo pair images (Fig 29A) where a three dimensional display was available.

Progressive Mineralization of Fissure Contents

Evidence was gained for a process by which fissure contents of erupted teeth are transformed. The contents were apparently changed progressively from distinct microbial colonies to a semi-solid, condensed type of colony losing its outline to a completely solid mass with no absolute detail (Fig 30A&B, Fig 31A, B&C). Such a transition was seen to occur from the top to the middle to the bottom of the fissure respectively. Of the 534 teeth examined 70% showed the above phenomenon.

Total Mineralization and Crystal Formation

This is a process by which fissure contents become totally mineralized from top to bottom with no sign of any

Figure 28

A - Scanning electron micrograph of a fissure perpendicular to the main fissure and filled with material.

X200


B - Scanning electron micrograph of fissure wall covered by bacteria and with the fissure contents permeated with bacteria.

Notice the space separating the two, and the inter-connecting bacteria.

X2000

C - Scanning electron micrograph of bacteria seen inside the fissure. The morphology suggests a predominant filamentous group.

X5000

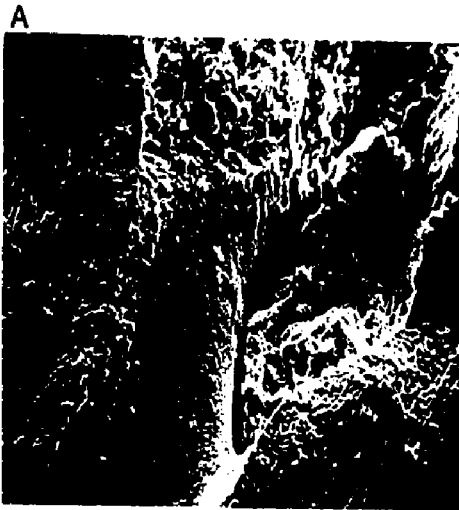




Figure 29


A - Scanning electron micrograph stereo pair of microorganisms located in the fissure. The three dimensional effect is achieved by viewing this figure with stereo glasses adjusted to 65 mm. Under stereo examination the morphology of the bacteria is well demonstrated.

X5000

B - Scanning electron micrograph of contents of a fissure of an erupted tooth showing at higher magnification the morphology of different types of bacteria, and their shape, filamentous (F), cocci (C), and bacilli (B).

X5000 (Original magnification)

A



B

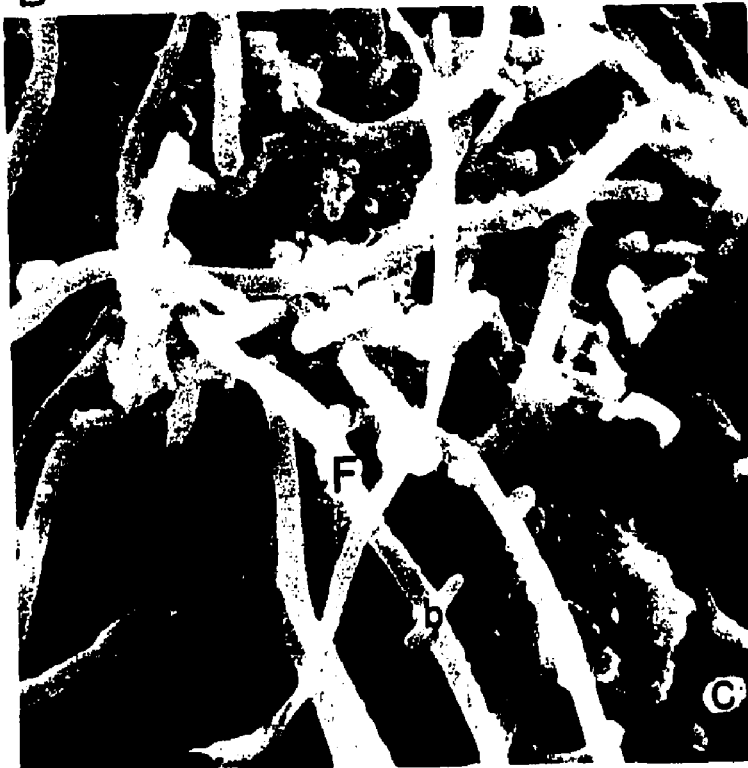




Figure 30


A - Scanning electron micrograph of an erupted tooth cleaved along a fissure, showing plaque (P) extending into the fissure. Notice the morphology of the "double fissure".

X50

B - Scanning electron micrograph at higher magnification of Figure 30A, showing the three distinct areas: top (T), middle (M) and bottom (b). These areas under closer examination showed evidence of progressive mineralization of fissure. EW = enamel wall.

X200

A



B

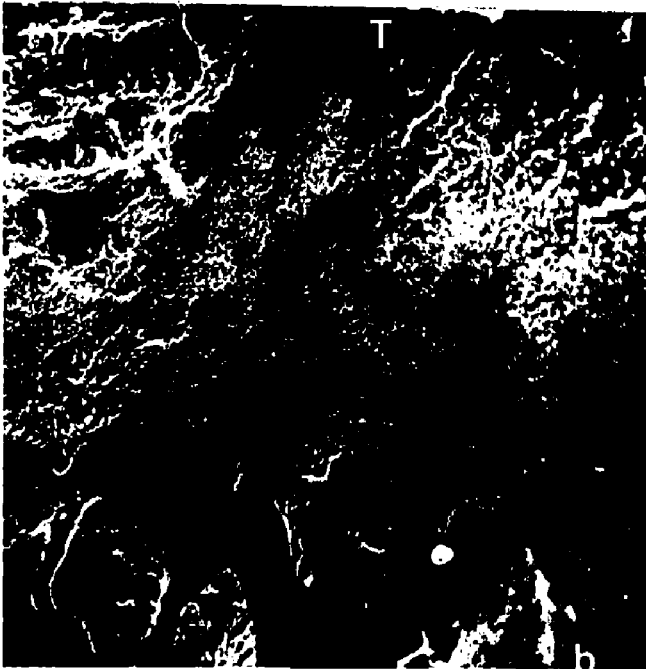



Figure 31

A - Scanning electron micrograph of the top region (most occlusal) of fissure plaque associated with an erupted tooth. Filamentous organisms, cocci and bacilli are clearly visible often separate and easily distinguished.



X5000


B - Scanning electron micrograph of the middle region of the fissure plaque associated with an erupted tooth. The microorganisms are compressed together, losing some of their morphology and appearing coalesced.

X5000

C - Scanning electron micrograph of the bottom region of the fissure showing the absence of microorganism morphology and the appearance of a solid mass.

X5000





micro organisms. The presence of crystal formations of different shapes were seen (Fig 32A, B&C). These resembled a scale or cuboid type.

iii) Transmission Electron Microscopy

The fissure contents were comprised of a condensed microbial layer containing different micro organisms (Fig 33, Fig 34). The coccoid variety were seen in direct relationship to the enamel surface of the fissure while filamentous groups were seen to be perpendicular to enamel surface. A number of degenerated cells were seen either scattered between bacterial groupings or in isolation and surrounded by finely shaped crystallites (Fig 35). The presence of an inter cellular matrix with a fibrillar and granular texture was also noted. Crystallites appeared either intra microbially (Fig 36A) or inter microbially (Fig 36B)

3. In Vitro Tooth Cleaning

3. a Experimental trial

Table 1 shows the effect of different agents used for cleansing the occlusal surface and pits and fissures of teeth. Sodium hypochlorite was found to be preferable.

3. b Technique of sodium hypochlorite is described in

Figure 32

A - Scanning electron micrograph of a fissure of an erupted tooth filled with apparently solid contents.

X100

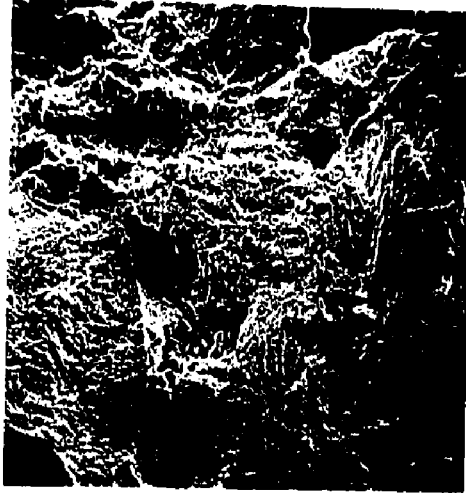
B - Scanning electron micrograph of a fissure of an erupted tooth showing crystal-like formations filling the fissure.

X1000

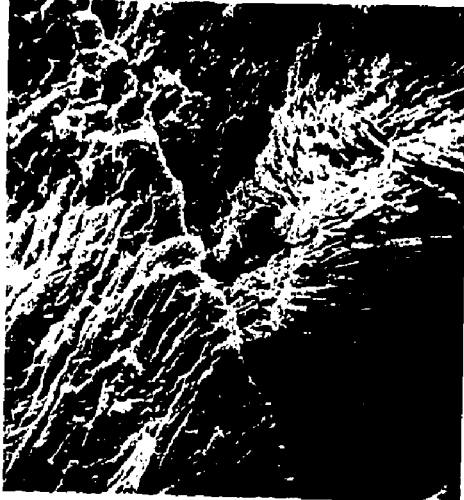C - Scanning electron micrograph of a fissure of an erupted tooth showing distinct crystals filling the fissure.

X5000

A




B



C



A



B



C



Figure 33

Transmission electron micrograph of a cross section through fissure contents of an erupted tooth. The presence of and attachment of bacteria to enamel fissure wall (E) is evident. Notice the different shapes of organisms with the attachment of coccoid organisms to enamel wall while filamentous organisms are oriented more to the center.

X2500






Figure 34

Transmission electron micrograph of a cross section through a fissure of an erupted tooth. Microorganisms can be seen together with intrinsically different densities.

X45000



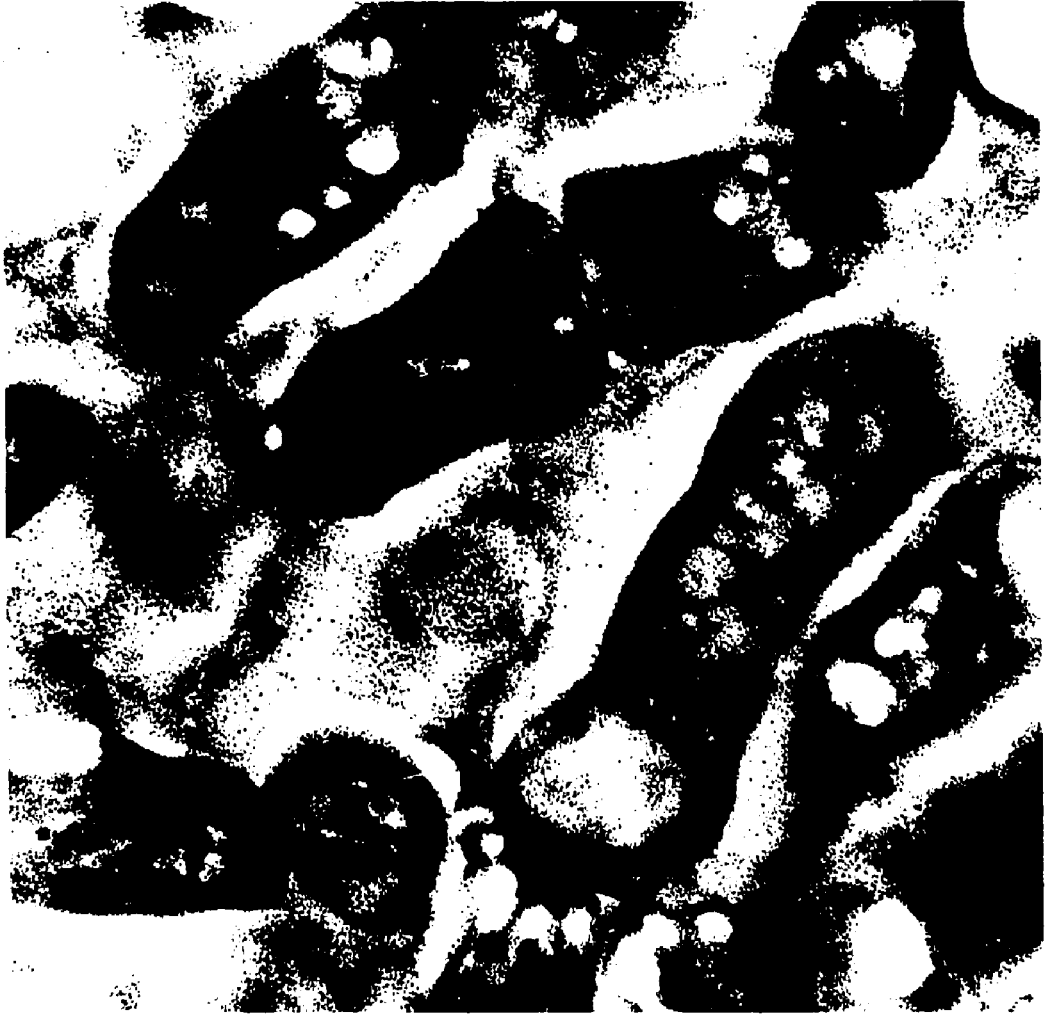


Figure 35

Transmission electron micrograph of a section through the fissure contents of an erupted tooth denoting the presence of ghost (G) like membranes and particles suggestive of crystal like matter (C) as shown by Schroeder (1963) & Kaufman (1973).

X40000

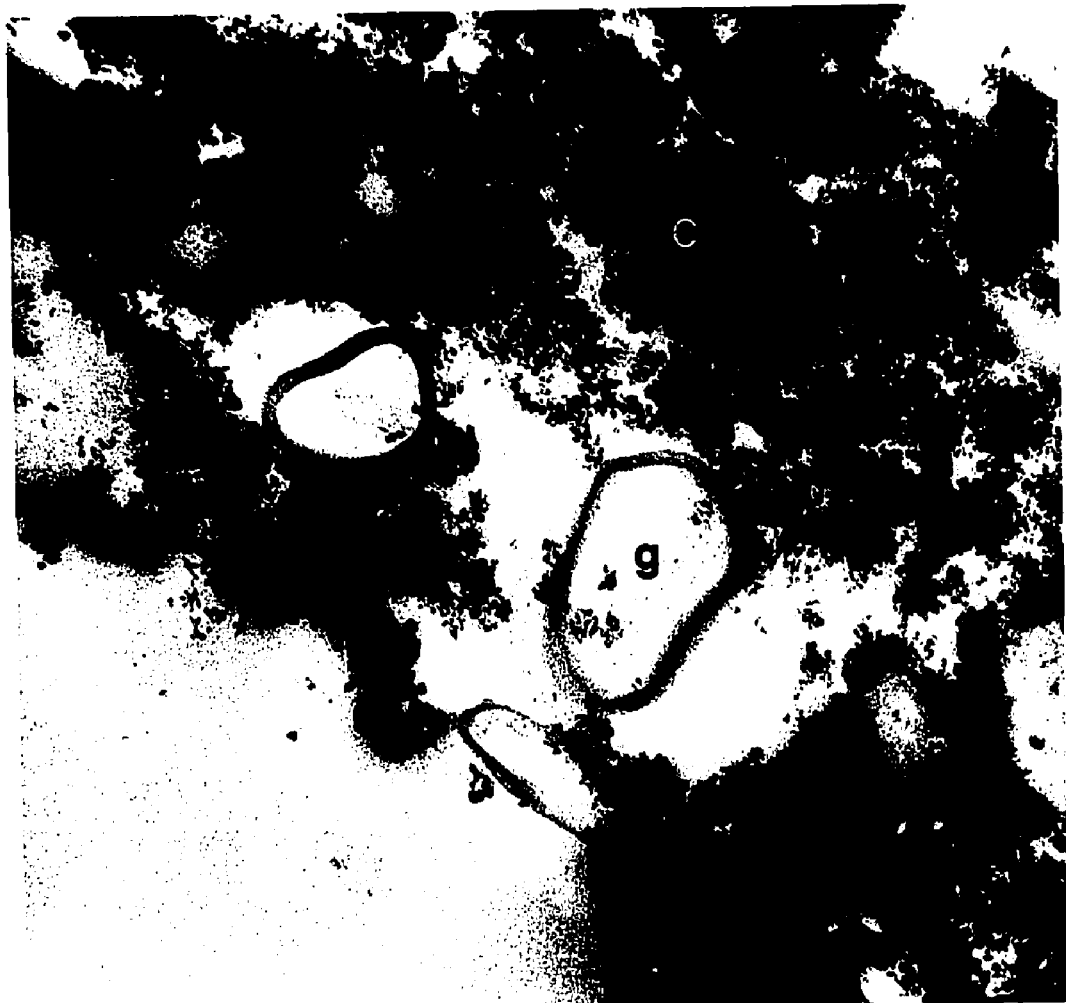




Figure 36

A - Transmission electron micrograph of a section through the fissure contents of an erupted tooth showing dense material within the bacteria.
X45000

B - Transmission electron micrograph of a bacteria with particle surrounding the cell wall. These particles may be similar to the crystalline material described by Schroeder (1963) and Kaufman (1973).
X45000

A



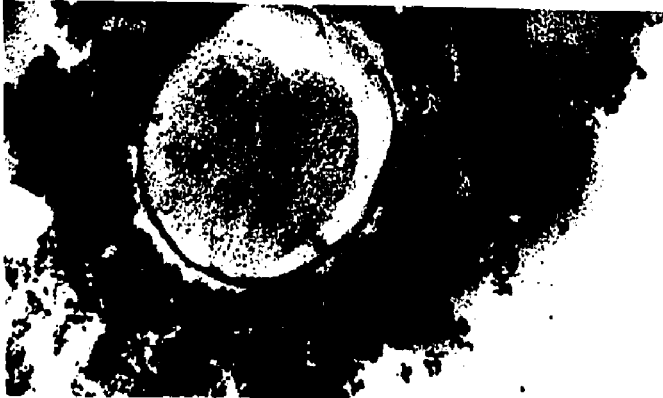
B



A



B



U

EFFECT OF DIFFERENT AGENTS (SOLUTIONS) FOR CLEANSING
ERUPTED TEETH (OCCLUSAL SURFACES, PITS AND FISSURES)

Agent	Time in hours & days												
	1/2	1/2-1	1-2	2-5	5-12	12-24	24-36	36-48	48-60	60-72	72-120	120	10 days
1 Water						2	2	2	2	2	2	2	2
2 Water and Soap						2	2	2	2	2	2	2	2
3 Water and Brush						2	2	2	2	2	2	2	2
4 Water & Pumice						2	2	2	2	2	2	2	2
5 Water & Sonication (light action)						2	2	2	2	2	2	2	2
6 Water & Sonication (heavy action)						2	2	2	2	2	2	2	2
7 Water, Sonication & Alconox						2	2	2	2	2	2	2	2
8 Ammonium Hydroxide						1	2	2	2	2	2	2	2
9 Sodium Bicarbonate							1	1	1	1	1	1	1
10 Sodium Hydroxide													
11 Organic Solvent (GP)													
12 Hydrogen Peroxide (mouth wash)													2
13 Hydrogen Peroxide (30% conc.)		1	1	1	1	2	2	2	2	2	3	3	3
14 Ethylene Diamine						1	2	2	2	3	3	4	4
15 Sodium Hypochlorite	1	2	2	2	2	2	3	4	4	4	4	4	4

* Blank indicates negative results

- 5 Total Cleansing of Both Occlusal Surface and Fissure
- 4 Total Cleansing of Occlusal Surface and Fissure Leaving White Precipitate
- 3 Moderate Cleansing of Occlusal Surface but not the Fissures
- 2 Mild Cleansing of Occlusal Surface but not the Fissures
- 1 Very Mild Removal of Covering Material

Chapter III.

3. c Scanning Electron Microscopy of Occlusal Surfaces of
Teeth Treated with Sodium Hypochlorite

i) Unerupted Teeth

Unerupted teeth responded to the treatment within 36 hours and on examination with disclosing solution showed the occlusal surface to be clean. Scanning electron microscopic examination of occlusal surfaces showed an absence of material upon them (Fig 37A&B). Pits and fissures were also clean following the treatment and examination by S. E. M. (Fig 38A, B&C).

ii) Erupted Teeth

Different reactions were seen on the occlusal surfaces of these teeth. Sodium hypochlorite crystals were observed on drying to be associated with the integumental covering of the enamel surface (Fig 39A). Some of the teeth showed globular masses (Fig 39B) on the surface. These examples point up the importance of following the technique closely making sure the reaction is complete and that the specimens are thoroughly washed. It is significant to adhere to the exact time for treatment which is a minimum of 72 hours. Fissures of erupted teeth were not cleansed completely using sodium hypo-

Figure 37

A - Scanning electron micrograph of an unerupted tooth showing the occlusal surface after cleansing with sodium hypochlorite. Notice the cleanliness of the occlusal surface, its invaginations and the different shapes of fissures.

X12

B - Scanning electron micrograph of an unerupted tooth showing the occlusal surface after cleansing with sodium hypochlorite. Notice cleanliness of the occlusal surface and the number of pits and fissures.

X12

A



B



A



B



Figure 38

A - Scanning electron micrograph of an uncleaned, unerupted tooth which has been split to show a fissure. The fissure is packed with material.

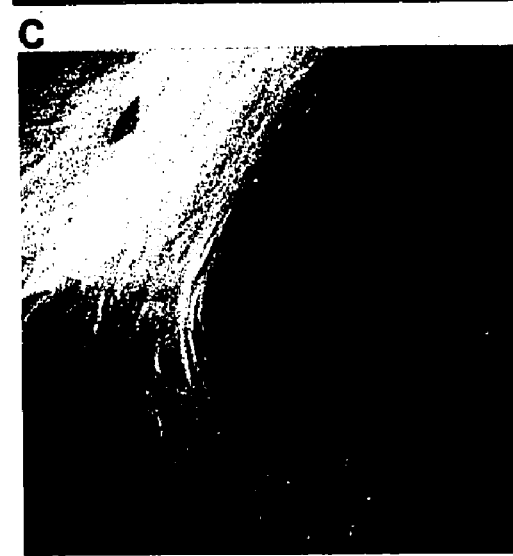
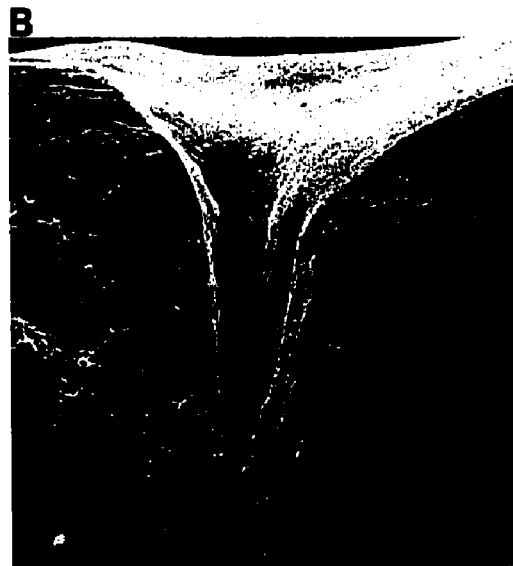

X100

B - Scanning electron micrograph of the same tooth as in A after treatment with sodium hypochlorite in which the fissure is devoid of its contents.

X100

C - Scanning electron micrograph of an occlusal view of a fissure showing it to be clean.

X250



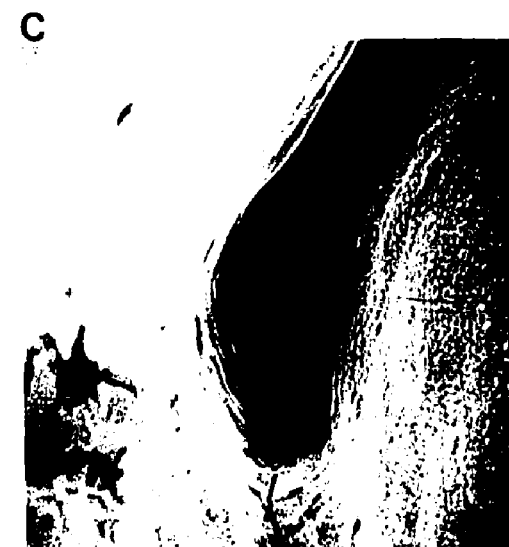
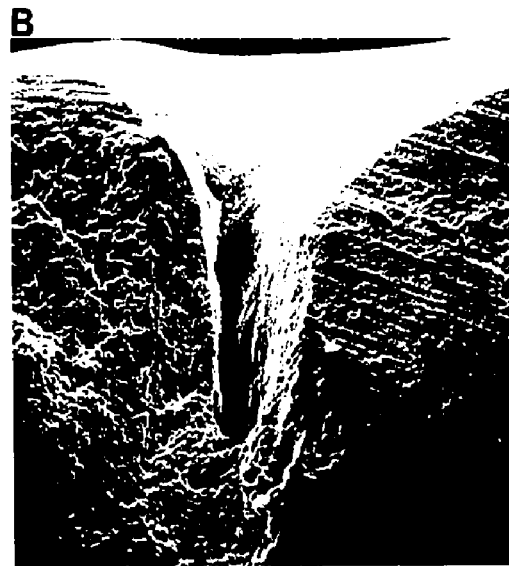

Figure 39

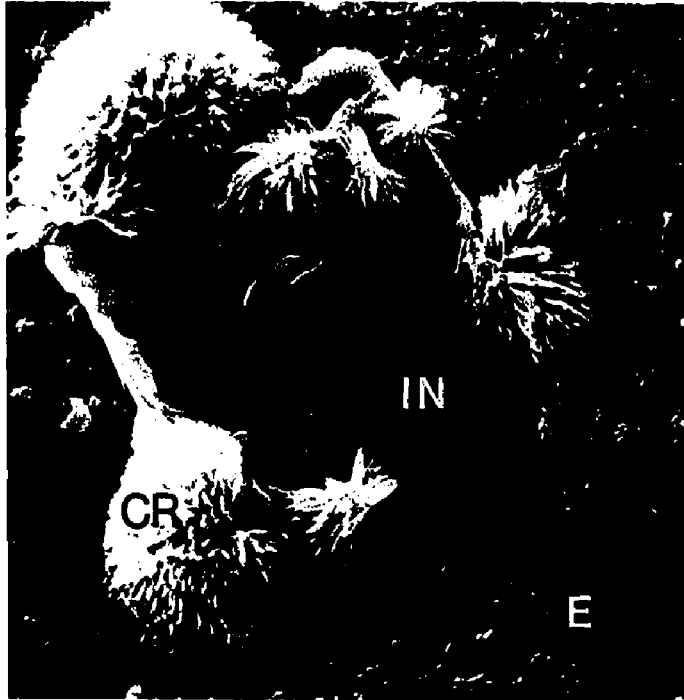A - Scanning electron micrograph of the occlusal surface of an erupted tooth during treatment with sodium hypochlorite. Crystals (CR) can be seen in association with integumental material (IN) located on the enamel (E).

X1200

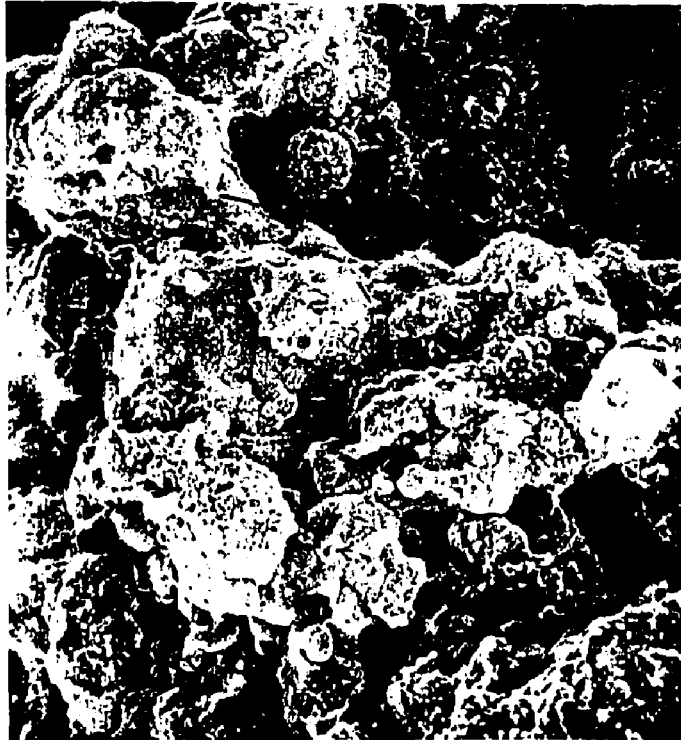
B - Scanning electron micrograph of the occlusal surface of an erupted tooth during treatment with sodium hypochlorite in which globular masses are present.

X550

A



B





chlorite (Fig 40A, B, C&D). Remnants of material were seen in the fissures. Furthermore the fissures cleansed of their superficial contents showed a white precipitate at their base. When stained with alizarin red such a residue showed a positive reaction (Fig 41A, B&C).

The stained residue in the fissures which was commonly seen in erupted teeth (Fig 42A&B) was also examined after cleavage of the crowns. The precipitate appeared to "plug" the center of the fissure (Fig 42C, Fig 43A).

Closer examination of these areas using scanning electron microscopy showed two types of arrangement. In the region situated at the top of the fissure was a globular mass containing many empty spaces (Fig 43B). The mass located at the bottom of the fissure was solid, filling the width of the fissure and exhibiting distinct crystallized or calcified structures (Fig 43C).

4. Replication of Teeth

4.a Experimental Trials

The use of Clear Cast resin as a replicating material was not successful especially due to its inability to penetrate into and totally fill the fissures (Fig 44A). On examining the casts with the scanning electron microscope the end of the pits and

Figure 40

A - Scanning electron micrograph of the occlusal surface of an erupted tooth demonstrating the cleaning effect of sodium hypochlorite. Notice the residues.

X11

B - Scanning electron micrograph of a fissure of an erupted tooth showing residue after treatment with sodium hypochlorite.

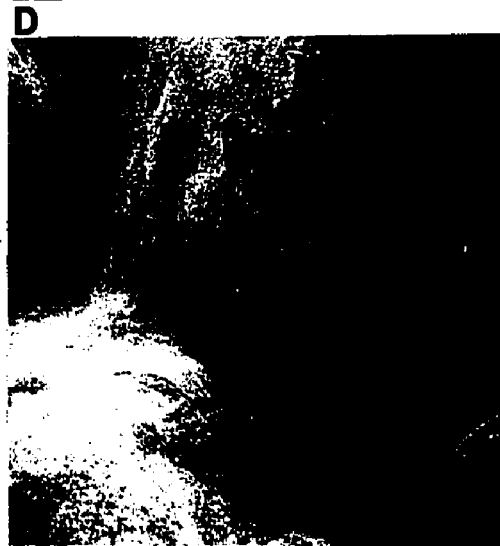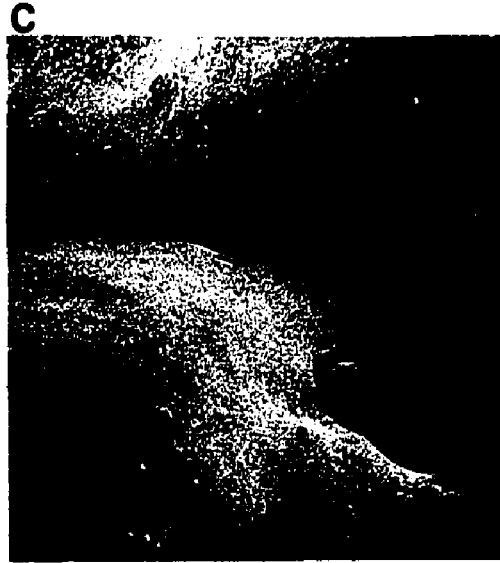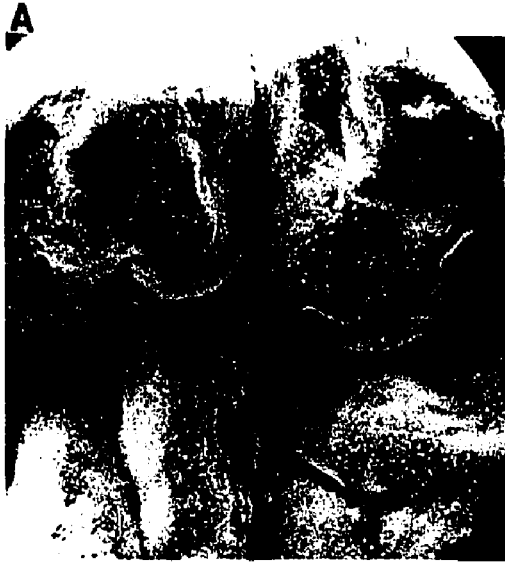X52

C - Scanning electron micrograph of a fissure of an erupted tooth showing residue in the fissure and on the inclined cuspal planes after treatment with sodium hypochlorite.

X50

D - Scanning electron micrograph of a fissure of an erupted tooth showing residue in the fissure and on the inclined cuspal planes after treatment with sodium hypochlorite.

X50



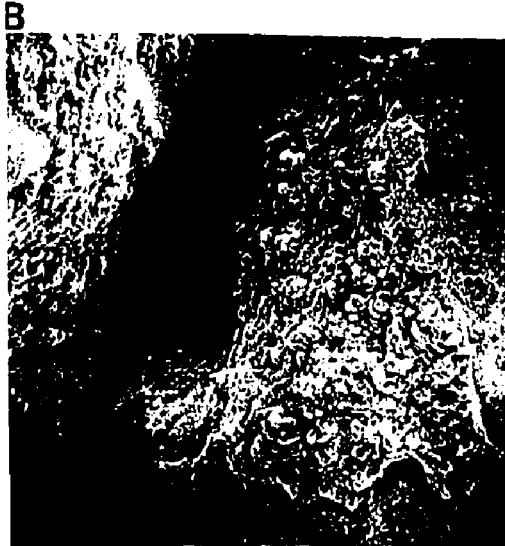


Figure 41

A - Macrophotograph of an erupted tooth treated with sodium hypochlorite solution (arrow) compared to one not treated. Both teeth are stained with alizarin red stain.

X3.5


B - Macrophotograph showing parts of the fissure and the occlusal surface (arrow) stained with alizarin red.

X8

C - Macrophotograph showing parts of the fissure stained with alizarin red (arrow).

X18

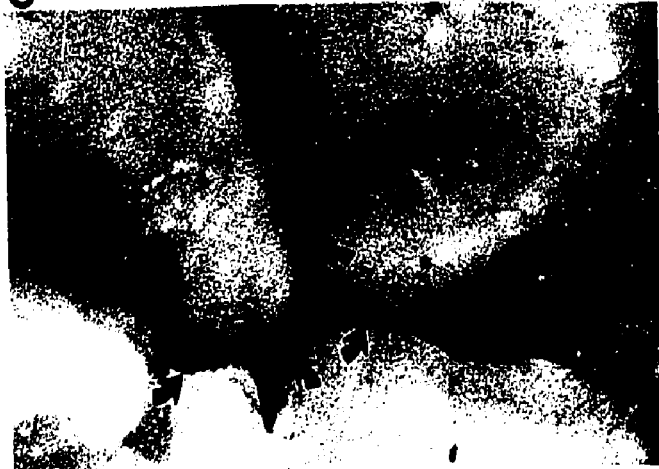A




B



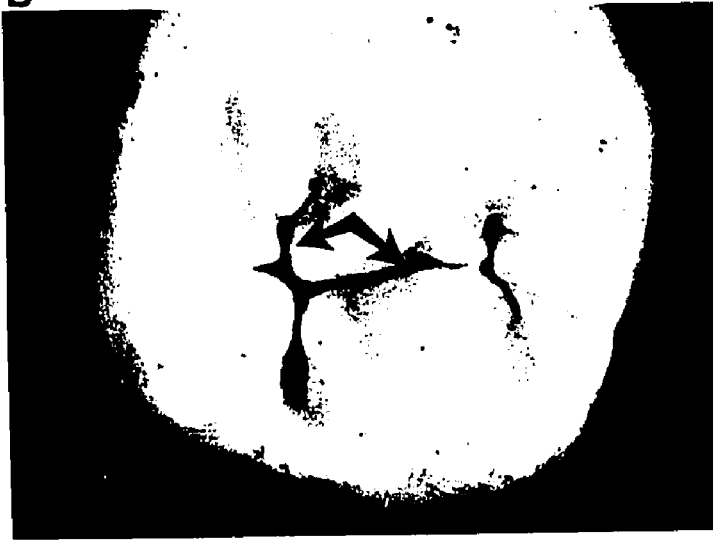C



A



B



C



Figure 42

A - Macrophotograph of an occlusal view of an erupted tooth treated with sodium hypochlorite.

X9

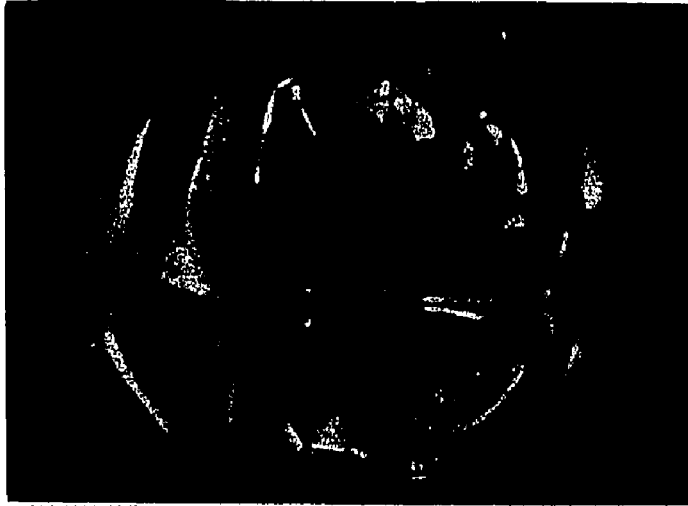B - Macrophotograph of the occlusal surface of an erupted tooth in which the fissure shows stainable material.

X18

C - Scanning electron photomicrograph showing a "plug" in the centre of the fissure (arrow).

X50

A



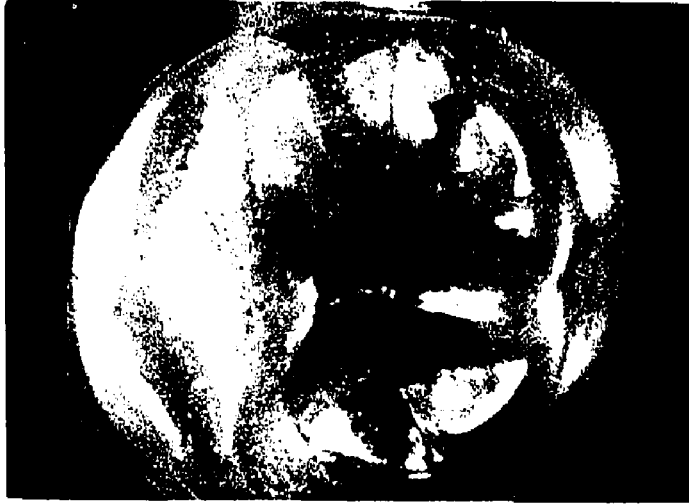B



C



A



B



C



Figure 43

A - A scanning electron micrograph showing a "plug" in the fissure. Notice two types of structures top (T) and bottom (B).

X100

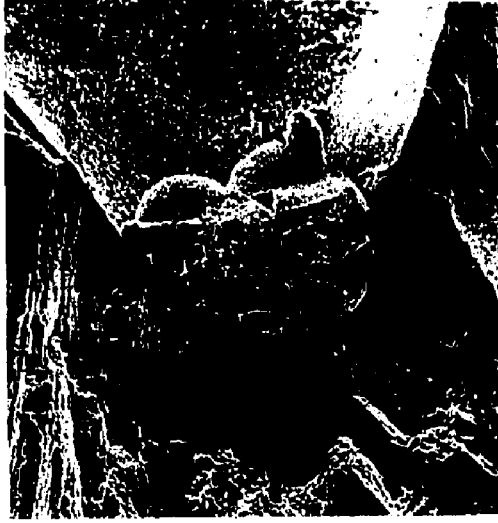B - A scanning electron micrograph of the top part in Figure A showing globular, apparently calcified structures. The globular masses resemble partly calcified bacteria. Notice also the spaces interspersed between them.

X500

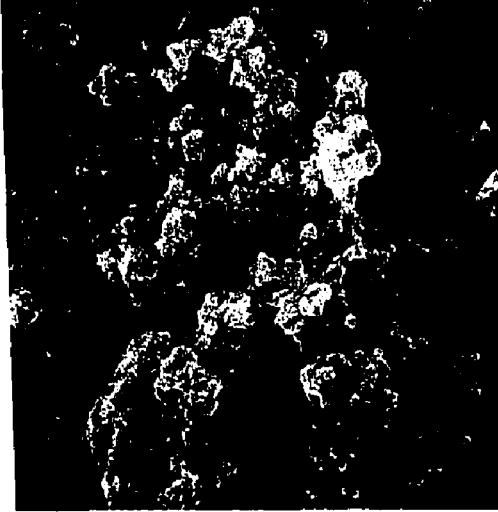C - A scanning electron micrograph of the bottom part of Figure A showing a solid possibly crystalline mass. Notice too the absence of spaces.

X2000

A



B



C







Figure 44

A - Scanning electron micrograph of a Clear Cast replica of a molariform occlusal surface with its pits and fissures.
Notice deficient ends of pits and fissures.

X20

B - High magnification of a replicated pit using Clear Cast.
Notice the deficiency at its extremity.

X100

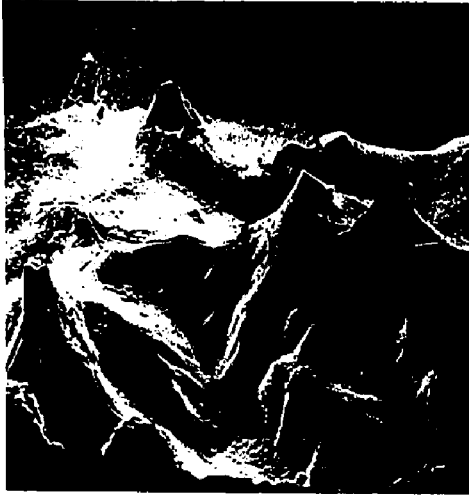
C - Macrophotograph showing a Spurr replica of an occlusal surface with its pits and fissures. Notice the absence of detailed pits and fissures.

X7

D - Scanning electron micrograph of a Spurr replica of an occlusal surface in the region of the pits and fissures.
Observe the incomplete contours or topography.

X20

A



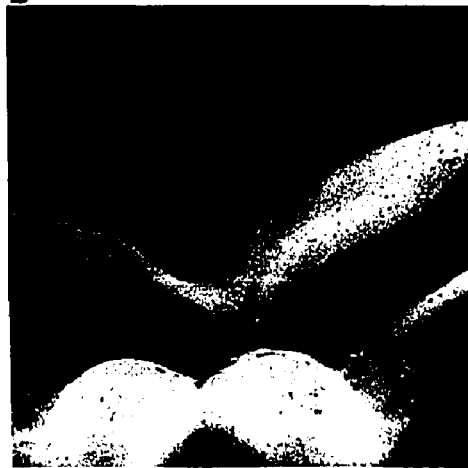
C



B



D



A



C



B



D



fissures were frequently deficient (Fig 44B). The use of Spurr resin in specimen preparation for transmission electron microscopy has proven useful because of its ability to penetrate into tissues. In this study, used for replication, it proved to be of no value (Fig 44C). Scanning electron microscopy of the Spurr replicas were totally featureless with flat incomplete topography (Fig 44D), despite the fact that the teeth were known to have deep fissures before replication.

4. b Technique of Vinyl Resin

For checking the accuracy of the technique, sections were prepared through teeth using the Gillings and Hamco machine. It was subsequently observed that the resin adapted well to shallow fissures and filled completely the deep fissures (Fig 45A, B, C&D). The adaptation and penetration was consistent to provide evidence of the morphology of pits and fissures. Also to check vinyl resin for adaptability and replication, an etching technique was carried out on the labial surface of a lateral incisor. The results of replication following etching were seen as enamel rods (Fig 46A) and were accurately reproduced (Fig 46B). The previous result demonstrated replication and low magnification examination. Closer examination of the etched enamel particularly at high magnification (Fig 47A, B, Fig 48A) and the corresponding replicas

Figure 45

A - Macrophotograph demonstrating the adaptability of vinyl resin to the occlusal surface.

X5

B - Macrophotograph demonstrating the adaptability of vinyl resin to the wall of wide, shallow fissures.


X5

C - Macrophotograph demonstrating the adaptability of vinyl resin to the wall of a deep fissure.

X5

D - Macrophotograph demonstrating the penetrability of vinyl resin into a deep fissure.

X10

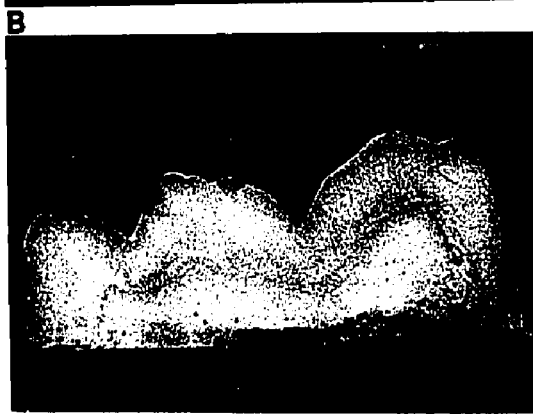




Figure 46


A - Scanning electron micrograph of enamel treated with 50% phosphoric acid. Preferential dissolution of the centers of the prisms is seen leaving the prism peripheries relatively unaffected.

X2000


B - Scanning electron photomicrograph of a vinyl resin replica of the etched enamel seen in A. An accurate representation was achieved.

X2000


A



B



A



B




Figure 47


A - Scanning electron micrograph of enamel treated with 50% phosphoric acid showing enamel prisms demineralized.

X200

B - Scanning electron micrograph of A replicated in vinyl resin.

X200

A



B

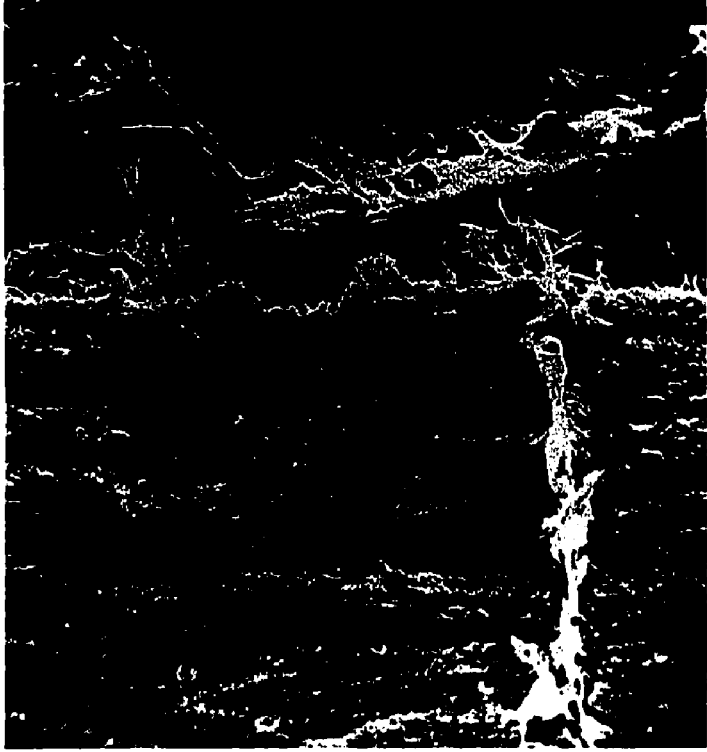

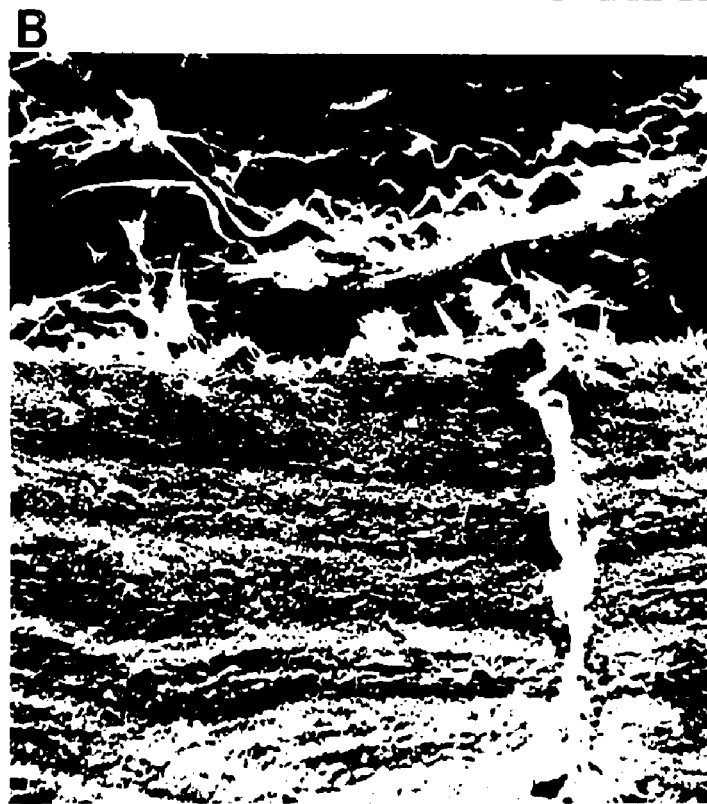


Figure 48


A - Scanning electron micrograph of a selected area of etched enamel. Preferential dissolution of the prism cores is apparent while the peripheries remain relatively unaffected.

X5000


B - Scanning electron micrograph of the selected area in A replicated in vinyl resin. Note the accurate replication of the same structural topography.

X5000


A




B



A



B



showed detailed structure replicated to at least 1 micron (Fig 48B).

4. c Scanning Electron Microscopy of Replicated Occlusal Surfaces and Their Pits and Fissures

The direct visualization of the distribution of pits and fissures of unerupted teeth was made possible, using the vinyl resin replication technique and sodium hypochlorite cleansing. Upper premolars usually exhibited a single straight outline (Fig 49A&C) with pits arising from it. Lower premolars demonstrated a curved outline to the fissure with a number of pits arising from it (Fig 49B&D). In upper and lower molars the outline of the fissures was most variable (Fig 50A, B&C, Fig 51A, B&C) having different types of fissural arrangement and different types of branching together with different pits arising from them. Furthermore, some molars were unique in which the occlusal surfaces had no fissures or pits. The use of stereo images from the scanning electron microscope significantly aided the recording of the above results (Fig 53A). The distribution of the fissures inside the crown was more complex than those seen from the occlusal surfaces. The number of fissures and pits which diverge and branch from the main fissure were abundant and impossible to classify. Frequently fissures having a broad base could give rise to more

Figure 49

A Macrophotograph of a vinyl resin replica of an upper
&
C premolar mounted on a stud for S. E. M. examination.

The fissure outline is seen as a straight type.

X7

B Macrophotograph of a vinyl resin replica of a lower
&
D premolar mounted on a stud ready for S. E. M. examina-

tion. The fissure outline is seen as a curved type.

X7

A



C



B



D



A



C



B



D





Figure 50

A Macrophotographs of vinyl resin replicas of a lower
B molar. The fissure outline is seen to run in different
& directions. Note the vast number of pits arising from
C the fissures.

X7

A



B



C



A



B



C



Figure 51

A - Macrophotograph of a vinyl resin replica of an upper molar.

The fissure outline is seen to bifurcate with the pits arising at the bifurcation.

X7

B - Macrophotograph of a vinyl resin replica of an upper molar.

The fissure outline is curved.

X7

C - Macrophotograph of a vinyl resin replica of an upper molar.

Notice the short fissure and absence of pits.

X7

A



B



C



A



B



C



Figure 52

A - Macrophotograph of a vinyl resin replica of an upper molar.

The occlusal surface is devoid of any deep fissures or pits.

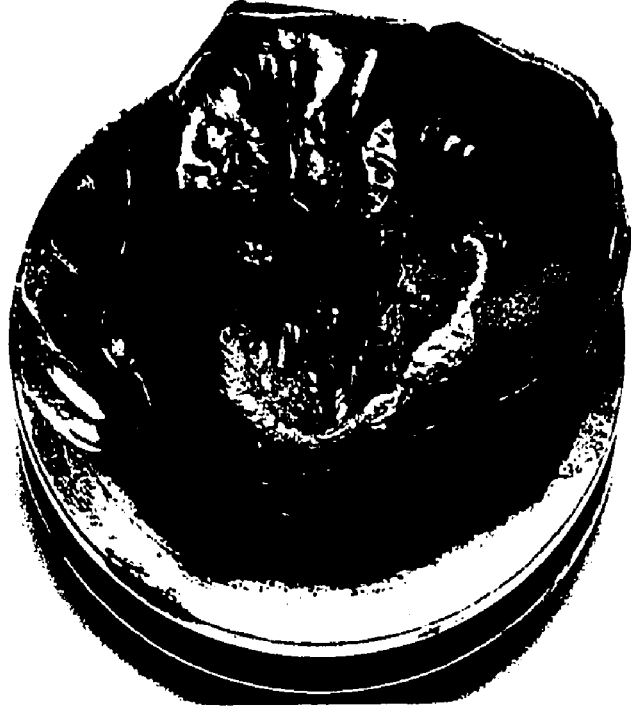X7

B - Macrophotograph of a vinyl resin replica of a lower molar.


The occlusal surface is devoid of any deep fissures or pits.

X7

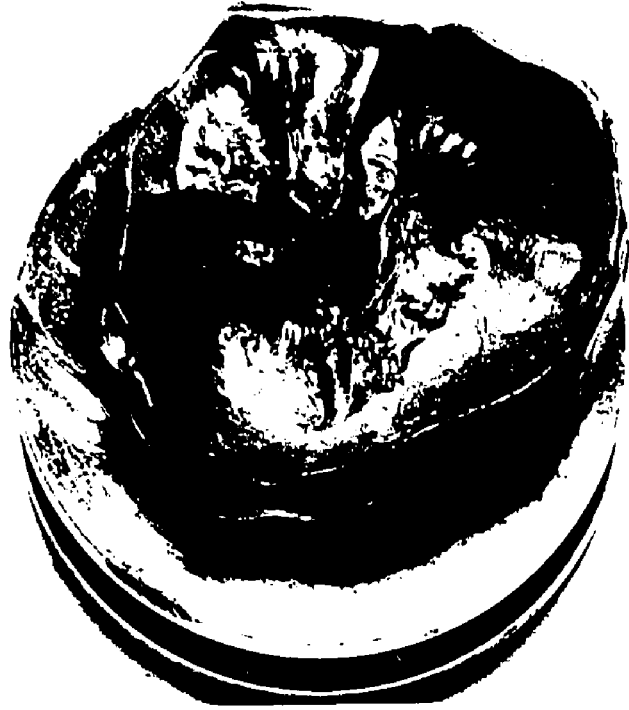A



B



A



B

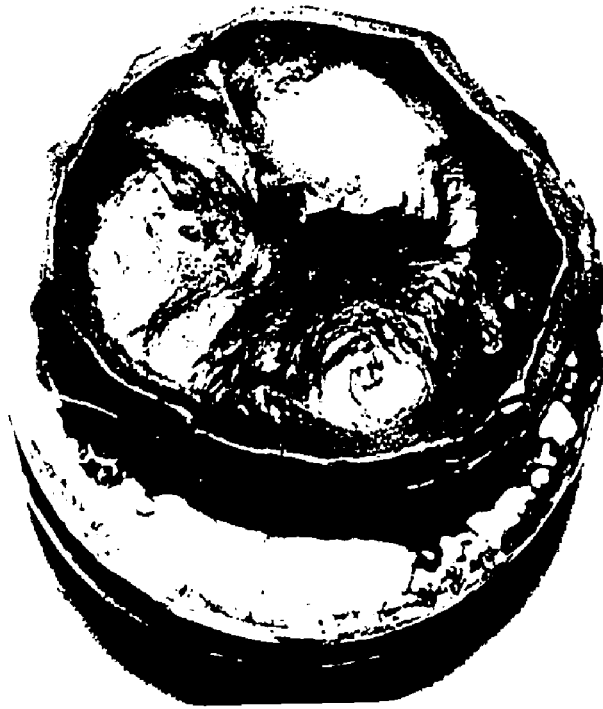


Figure 53

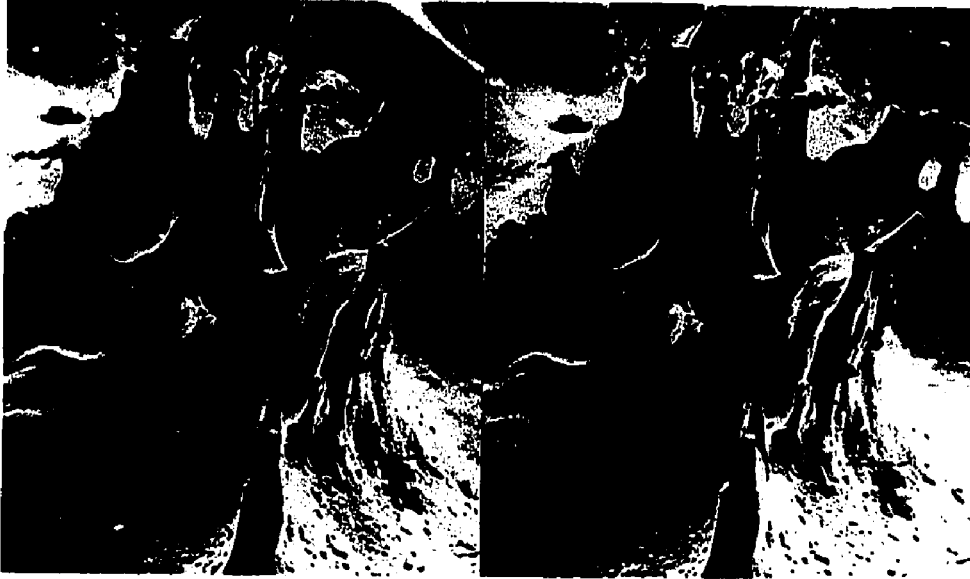A - A scanning electron micrograph stereo pair of a vinyl resin replicated occlusal surface with its pits and fissures. The three dimensional effect is achieved by viewing this figure with stereo glass adjusted to 65 mm.

X20

B - A scanning electron micrograph of a vinyl resin replicated occlusal surface with its pits and fissures. This region is also present in A but the specimen has been rotated to reveal "hidden" features.

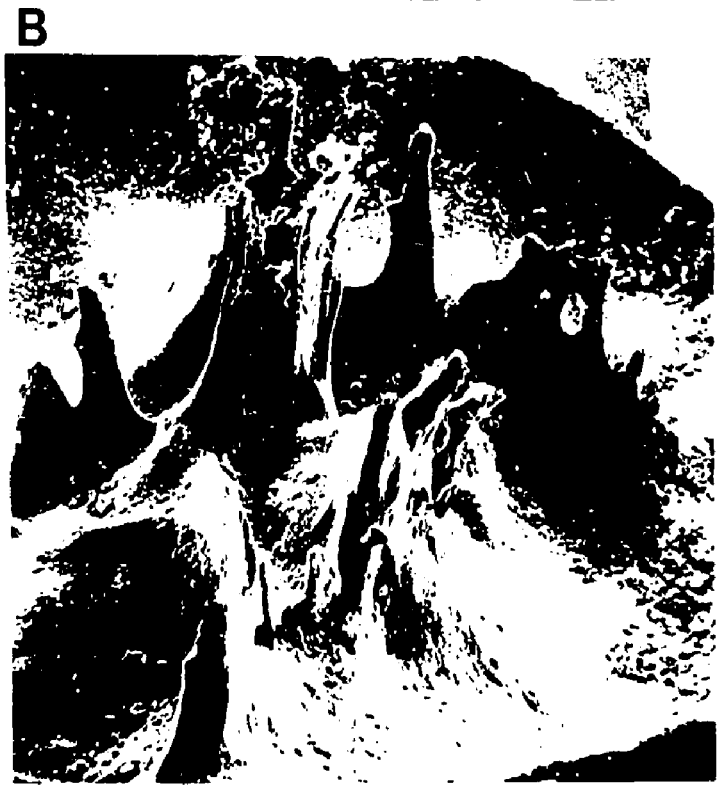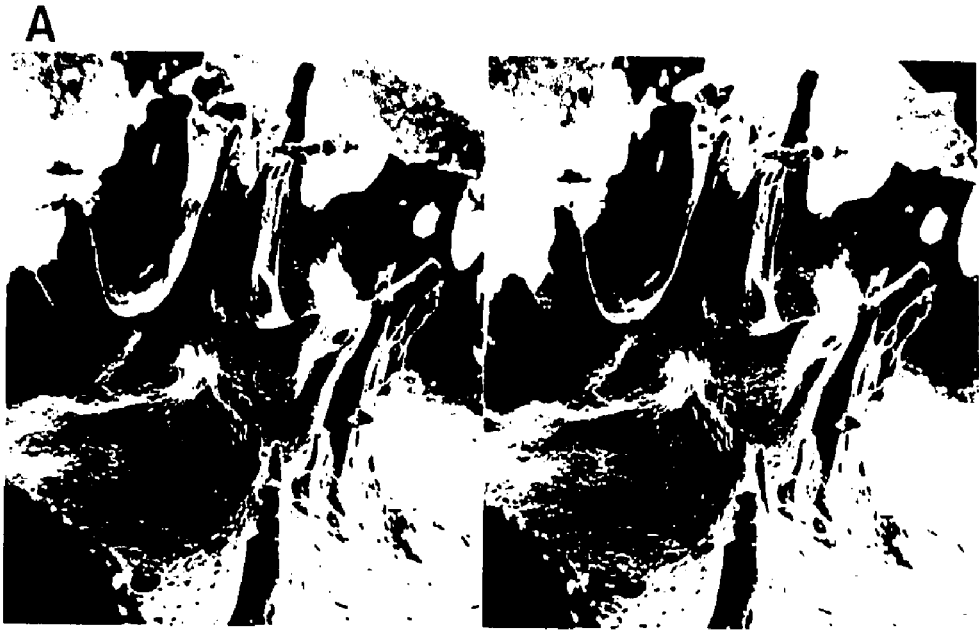
X20

A



B





than one pit (Fig 54). The contours of occlusal replicas showed great diversity (Fig 55 A&B). Generally speaking, the premolars showed a main fissure with a straight outline from which arose 3 or 4 pits (Fig 56A), while those of the lower premolars with their curved outline also showed 3 or 4 pits (Fig 56B&C). The number of pits arising from fissures in molars in some cases was found to be as many as 10 (Fig 57A). On the other-hand some molars showed no pits at all producing a flat replica (Fig 57B). With the use of the scanning electron microscope an attempt was made to clarify and classify the appearance of pits. Where a pit could be seen in a longitudinal section on rotation of the specimen through 90 these same pits proved to be flat fissures (Fig 58A, B&C). This means that interpretation of longitudinal sections of pits and fissures must be made very carefully. Pits at the tip of the cusps of premolars and molars were also seen (Fig 59). They run a short distance into the crown compared to the central pits and fissures, and were the same in premolars and molars.

The terminal portions of the pits resembled different shapes, of these the most common were the pointed, curved, clubbed and rosehead configuration (Fig 60A, B, C&D). There were other shapes often variable and not classified for they were either exceptional or were a combination of other common types (Fig 61A, B, C&D). Buccal fissures were also

Figure 54

Scanning electron micrograph of vinyl resin replicated occlusal surface with its pits and fissures. A fissure (F) is seen running in three different directions. Pits of variable lengths and widths are also seen arising from the wide based fissures.

X20

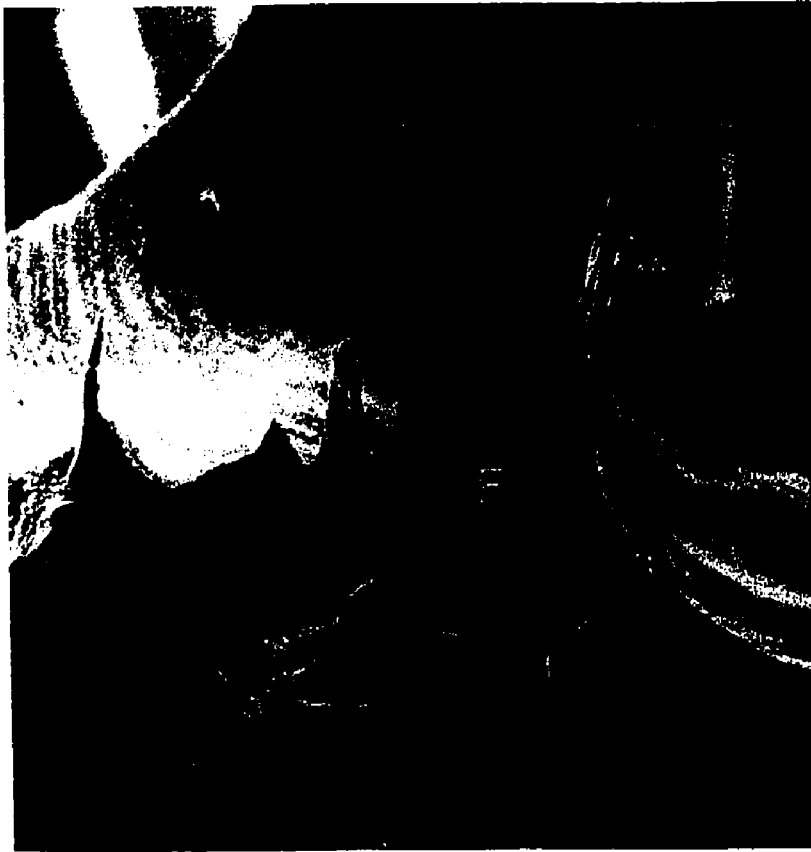



Figure 55

A - A scanning electron micrograph of a vinyl resin replica of an upper molar demonstrating shallow fissures running along the occlusal surface. Note the different pits (P) arising directly from the occlusal surface. Also note the pit (B) arising in the center of the top of a cusp.

X20

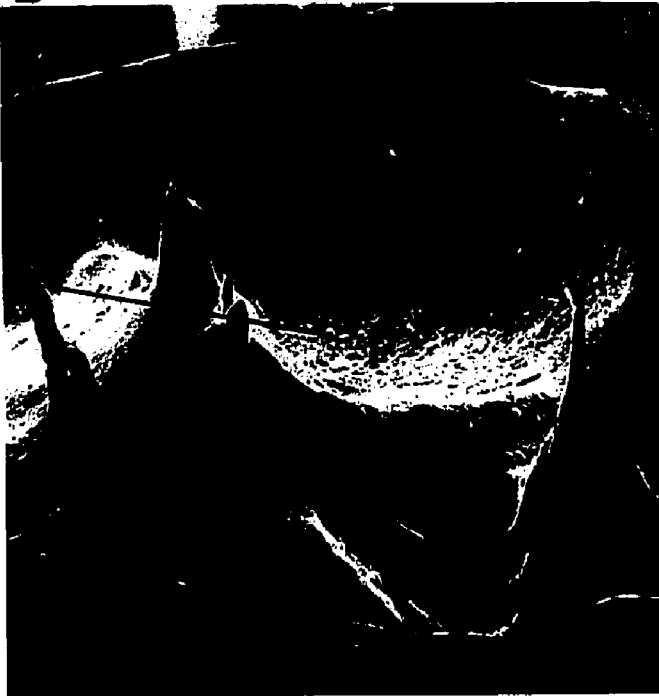B - A scanning electron micrograph of vinyl resin replica of an upper molar demonstrating shallow fissures running along the occlusal surface. Notice the different pits (P) arising directly.

X20

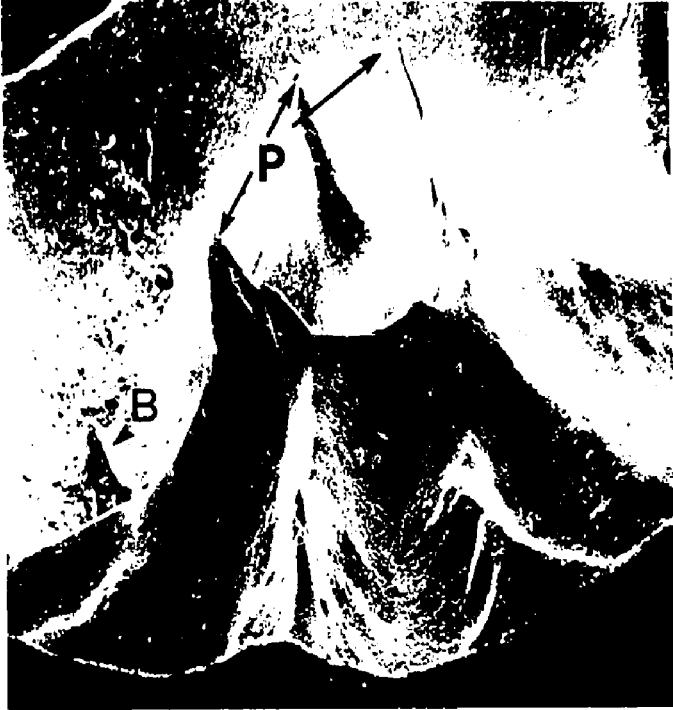A



B



A



B

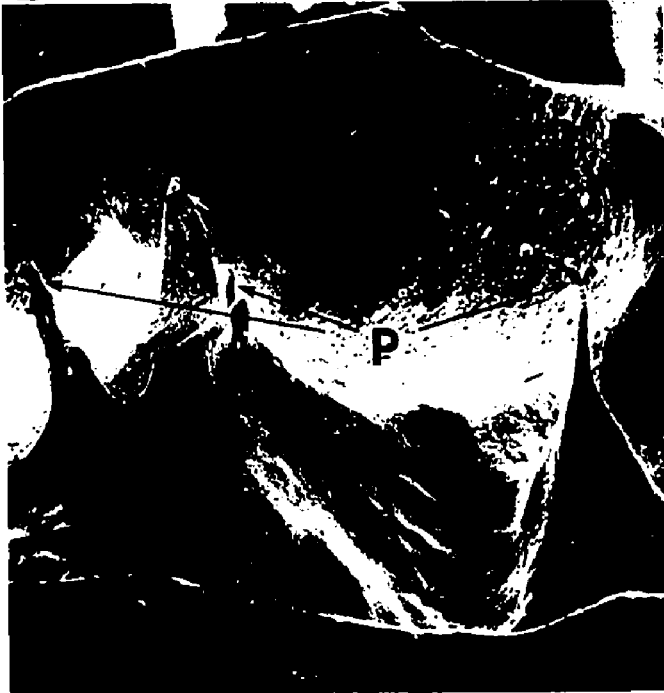

Figure 56

A - A scanning electron micrograph of a vinyl resin replica of an upper premolar demonstrating a straight fissure with three distinct pits arising from it.

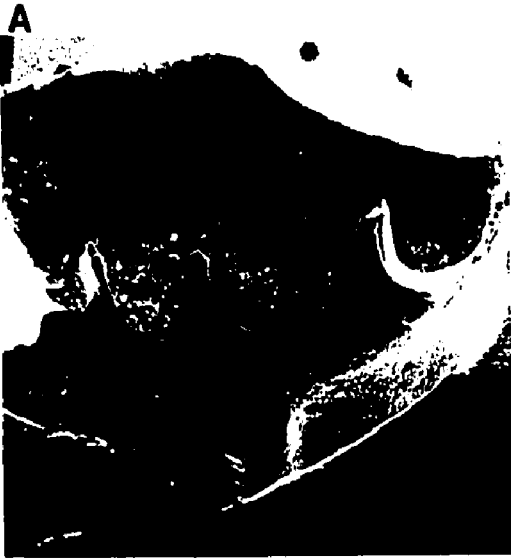X20

B - A scanning electron micrograph of a vinyl resin replica of a lower premolar demonstrating a curved fissure with four pits arising from it.

X20

C - A scanning electron micrograph of a replica of a lower premolar demonstrating a curved fissure with two pits arising from it.

X20

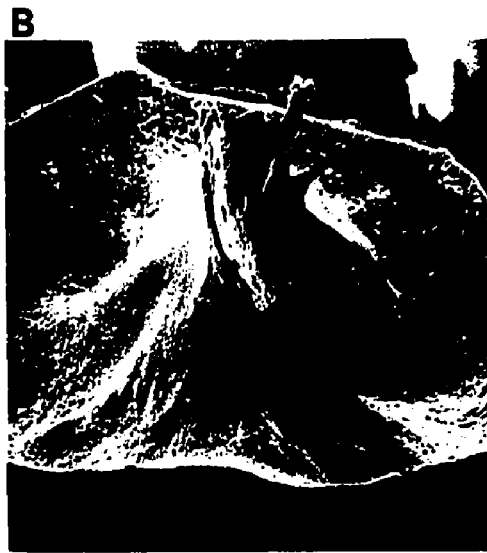

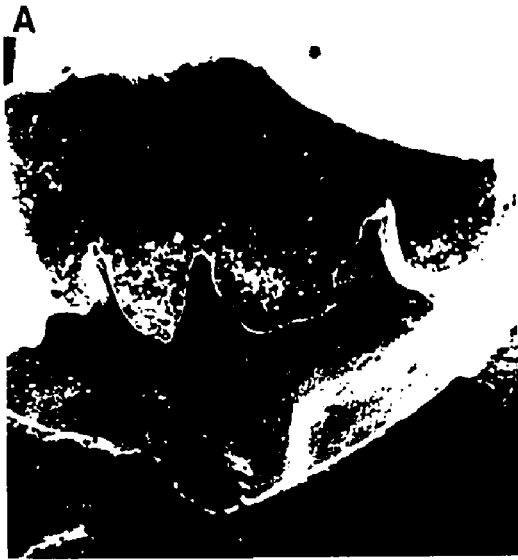


Figure 57

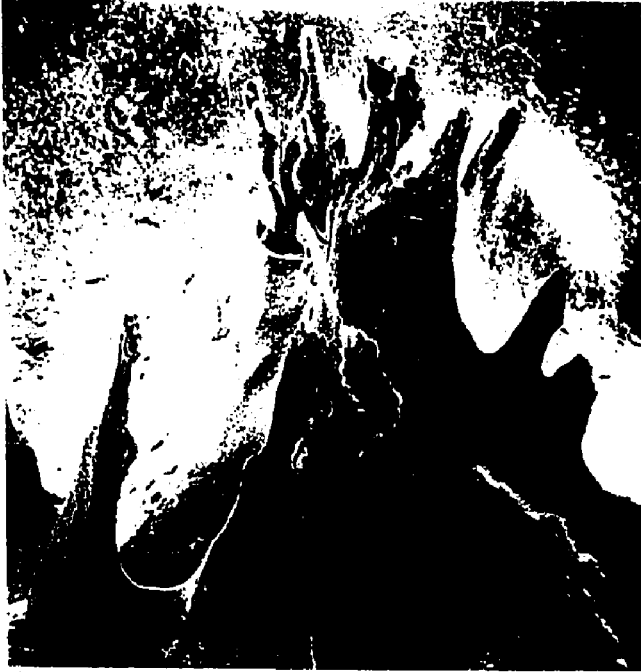A - A scanning electron micrograph of vinyl resin replica of pits arising from one localized area. At least ten pits can be identified.

X20

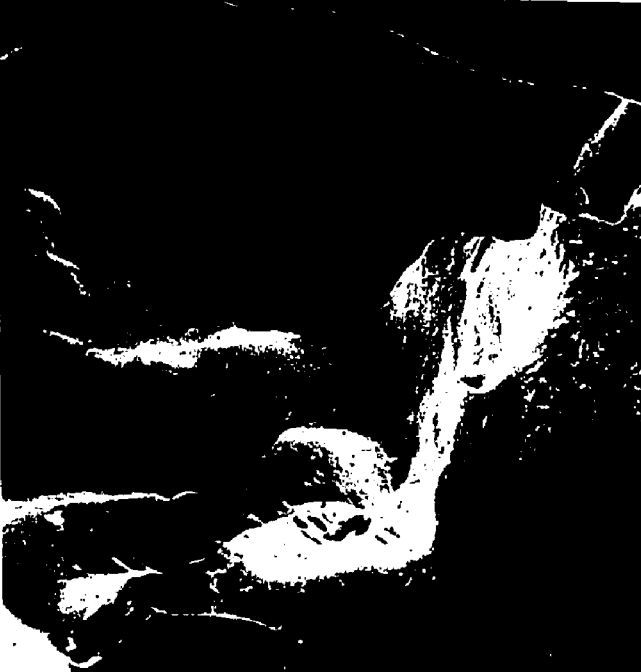B - A scanning electron micrograph of vinyl resin replica of an occlusal surface demonstrating the total absence of pits.

X20

A



B



A



B



Figure 58

A - Scanning electron micrograph of vinyl resin replica apparently of a pit.

X50

B - Scanning electron micrograph of the same region as A but with the replicated specimen rotated through 90° . The pit is seen to be a very wide fissure.

X50

C - Scanning electron micrograph of the vinyl resin replica of the occlusal surface of upper molar pertaining to the A, B.

X20



A



B



C



Figure 59

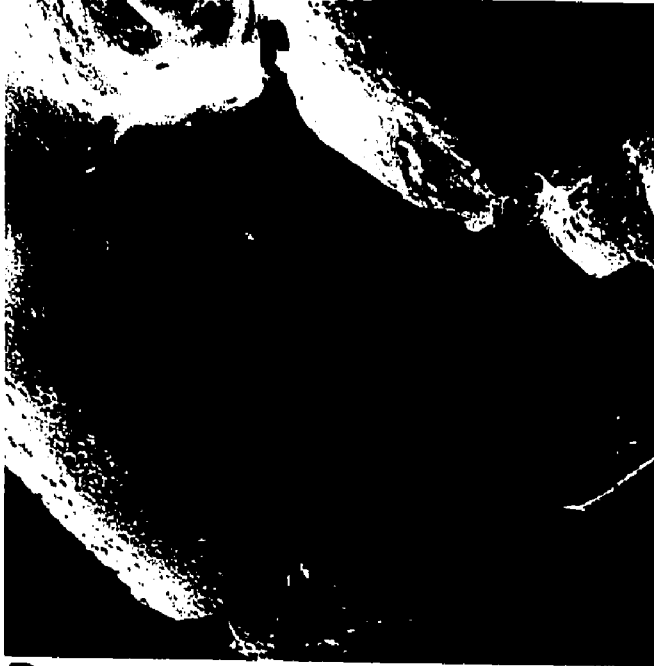A - Scanning electron micrograph of a vinyl resin replica of the occlusal surface of a premolar denoting the presence of a pit on top of the buccal cusp.

X20

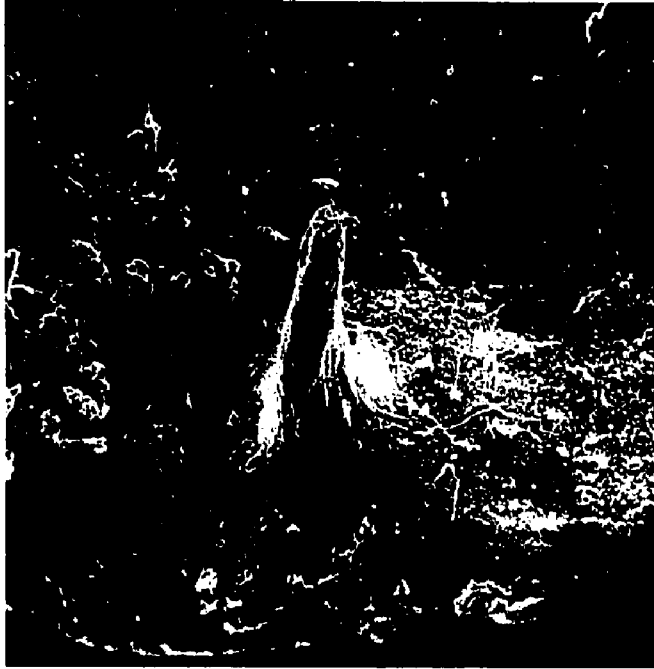B - Scanning electron micrograph of a vinyl resin replica of the buccal cusp pit (higher magnification of A).

X100

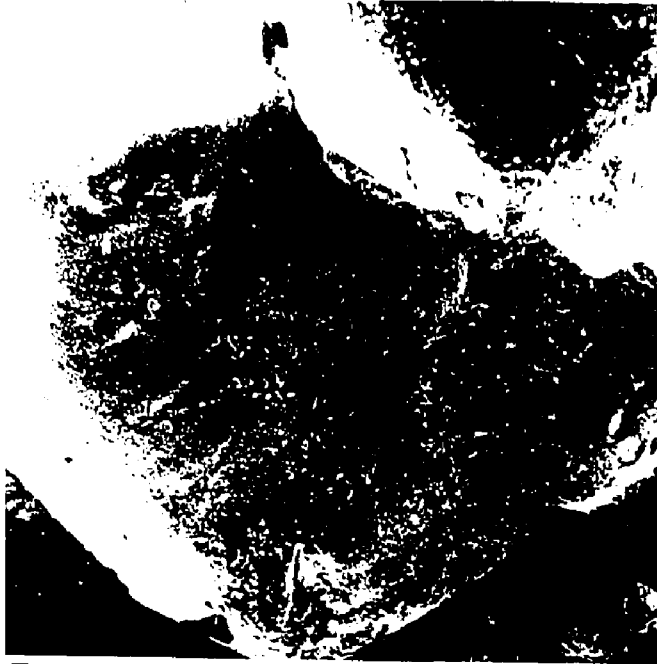
A



B



A



B

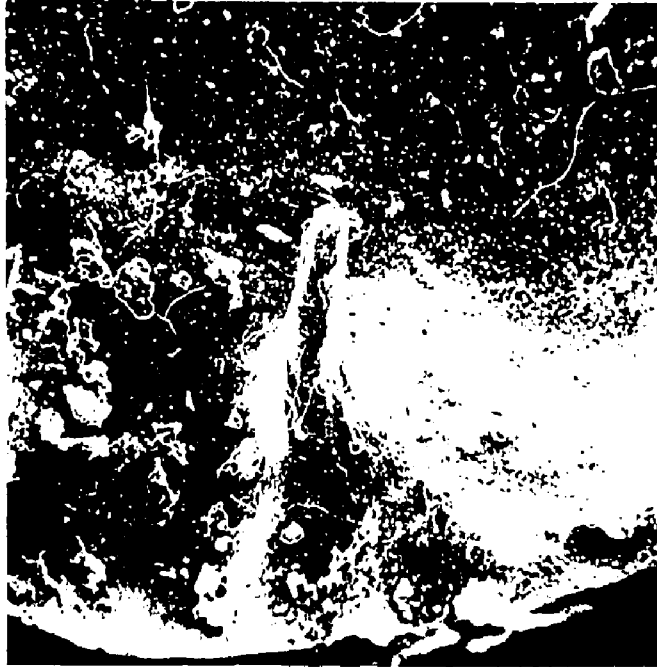

Figure 60

A - Scanning electron micrograph of a vinyl resin replica of a pointed type pit.

X100

B - Scanning electron micrograph of a vinyl resin replica of a curved-type pit.

X100

C - Scanning electron micrograph of a vinyl resin replica of a club-type pit.

X100

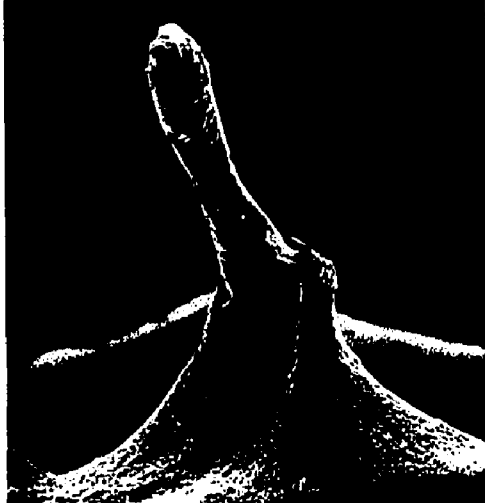D - Scanning electron micrograph of vinyl resin replica of a rose head pit associated with a shallow V-type of pit.

X100

A



C



B



D



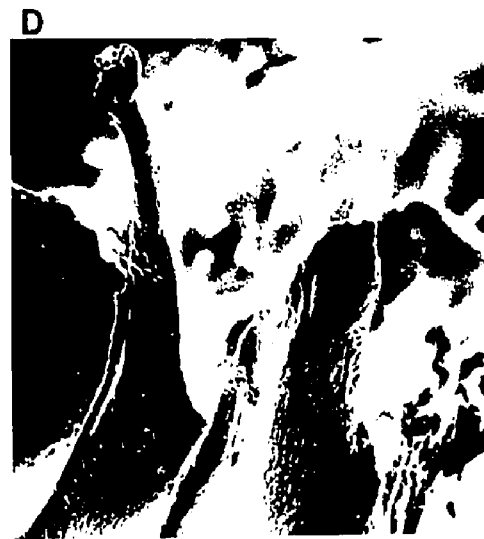
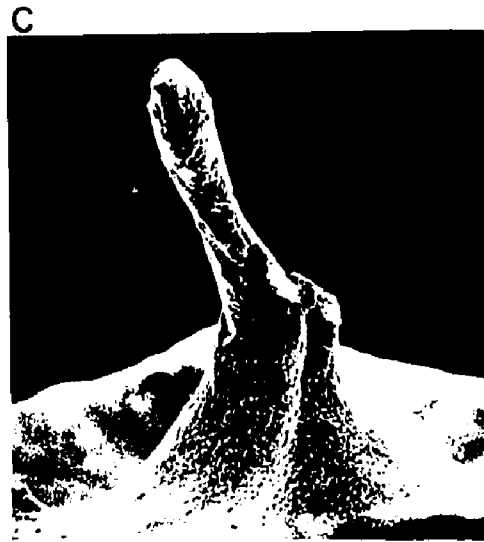
Figure 61

A - Scanning electron micrograph of a vinyl resin replica of a modified pointed type of pit.

X50

B - Scanning electron micrograph of a vinyl resin replica of a wide V-shaped pit.

X50

C - Scanning electron micrograph of a vinyl resin replica of a combination of different shaped pits arising from a common origin.

X50

D - Scanning electron micrograph of a vinyl resin replica of a combination of pit types which cannot be equated with those described previously.

X50

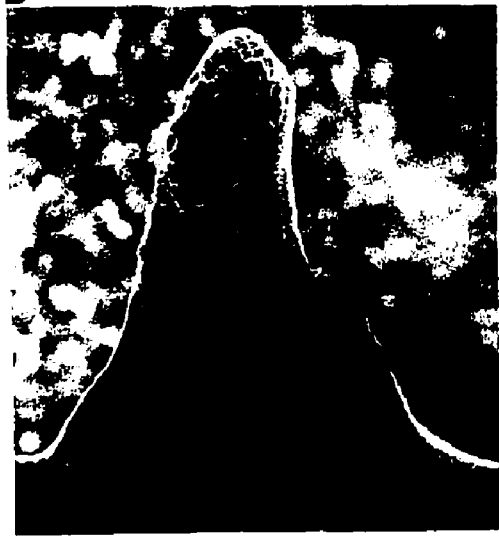A



C



B



D



A



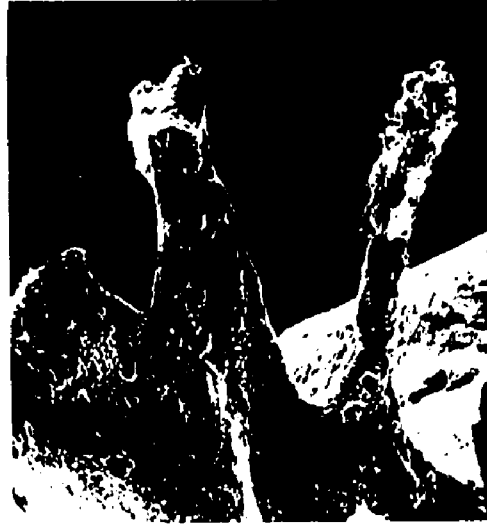C



B



D



replicated and either one or more pits were seen to arise from the buccal fissure (Fig 62A). Also, complex types of pit arrangement were observed where bridging occurred between two pits leading to an arch formation (Fig 62B&C). Others showed evidence of a broken arch arrangement (Fig 62D).

Figure 62

A - Scanning electron micrograph of a vinyl resin replica demonstrating a buccal fissure (BF) and pits (BP). The distribution of different kinds of pits is also seen on the occlusal surface of this lower molar with the type of pits seen non equatable with those described previously.

X20

B - Scanning electron micrograph of a vinyl resin replica demonstrating a junction between pits to form a bridge. Buccal pits are also seen (B).

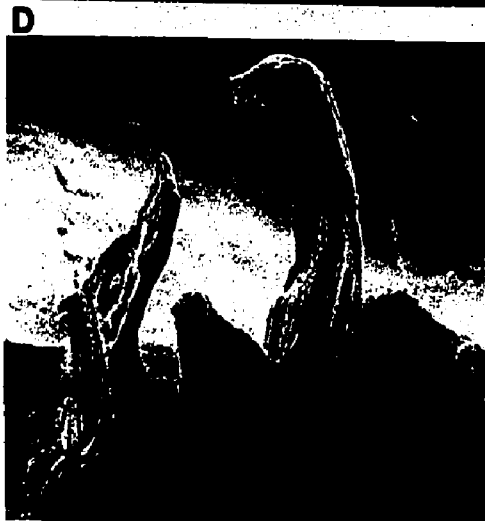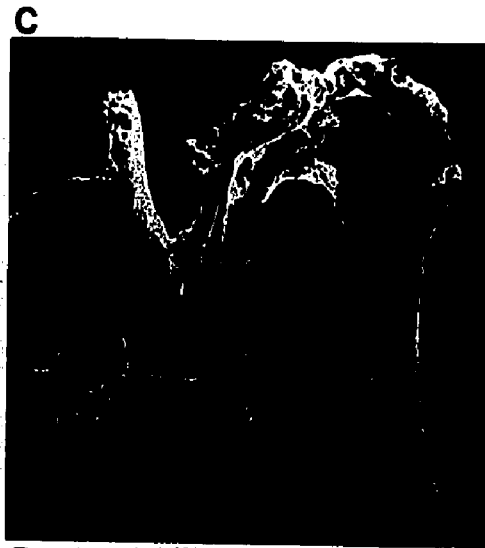
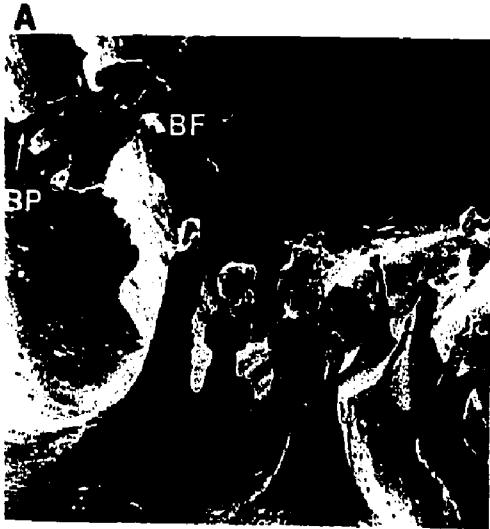X20

C - Scanning electron micrograph of a vinyl resin replica demonstrating the junction of the pits in B.

X100

D - Scanning electron micrograph of a vinyl resin replica demonstrating an incomplete, possibly broken junction between the pits of a lower molar.

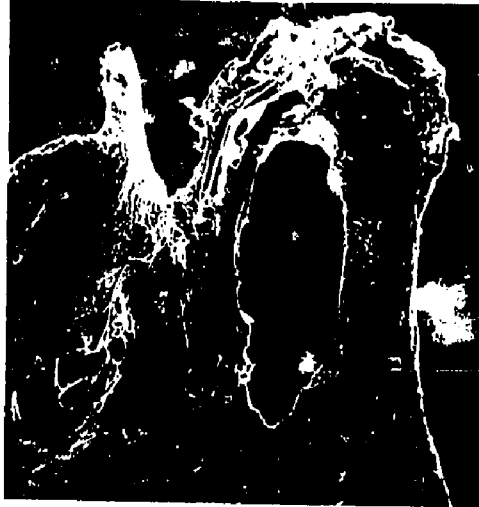X100



A



C



B



D



V DISCUSSION

1. Occlusal Surface of Teeth

1. a General Histochemical Identification of Materials

Covering the Occlusal Surface

Following eruption into the mouth the enamel of human teeth acquires an integumental structure. There have been conflicting opinions over its possible nature and origin and this has been further confounded by a vast nomenclature. Meckel's (1965) work strongly suggests that the first phase in plaque formation is the development of an acquired cuticle, 1-10 μ thick, which is probably derived from saliva. He frequently found this cuticle continuous with fibrils within the surface layer of enamel and called it the sub-surface cuticle. The salivary origin of supra-gingival cuticle is supported by the chemical studies of Hay (1966) and Ericson (1967) who demonstrated absorption of salivary proteins to hydroxyapatite and ground enamel. Hay also reported that cuticular material removed from enamel yielded patterns with disc electrophoresis which were similar to fractioning absorbed hydroxyapatite from saliva in vitro. Salivary mucins consist

of a complex matrix of glyco-proteins. These materials are thought to be responsible for giving saliva its characteristic viscous properties. Glyco-proteins are made essentially from long protein chains containing various sugars. These sugars are primarily responsible for the characteristic histological staining reaction of mucin, acquired pellicle and aqueous extracts of matrix of plaque. All of them have an amino acid composition typical of glyco-proteins but may be absent in the dental plaque, Dawes and Jenkins (1963), Leach (1963), Middleton (1964). Studies done in other fields show that the carbohydrate components of glyco-proteins can be individually and sequentially released from the remainder of the glyco-protein macromolecules by extra cellular induced enzymes of bacterial origin, Barker et al. (1963). A similar mechanism is said to occur in the oral cavity as suggested by Leach (1963). Hexoses and hexosamines occur as typical components of many bacteria, (Cummins and Harris 1965); but destructive analysis of the plaque does not enable the origin of these carbohydrates to be identified. These same carbohydrates however, can be shown to be lost in saliva by bacterial action, Leach (1964) and by analogy, sialic acid and fucose should be present only to a small degree in dental plaque. It has been shown that a large proportion of the plaque matrix is made of bacterially produced polyhexoses, dextran

and levan which are derived from dietary sucrose, Critchley, Wood and Saxton (1967). Leach, Critchley, Kolendo and Saxton (1967) showed that the amino acid composition of the three salivary secretions, the acquired pellicle and the aqueous extract of plaque matrix have a general common pattern in their proportion of amino acids. However, very close agreement is not to be expected since saliva is known to contain some proteins other than glyco-proteins, but the overall composition is sufficiently typical for them to be classified as glyco-proteins.

The question whether there are lipid substances in the tooth integument is an interesting one. The literature shows that two schools of opinion exist. One of them denies the presence of lipids while the other has demonstrated the presence of fat. Our studies indicate that lipid material is present in the integumental covering of teeth. Valloton (1945) thought that the acquired pellicle was free from fat while McDougall (1963) showed that it contains a lipid fraction. Houver and Frank (1967) also showed that accumulated material on teeth has a positive reaction with lipid stain. Chromatography of parotid and whole saliva has detected the presence of many lipids including cholesterol, cholesterol esters, fatty acids, glycerides and phospholipids but these are present in very low concentration. Jenkins (1966) demon-

strated that by comparison of the results for parotid and mixed saliva most of the lipids constituents are present in both, i. e. they are secreted by the salivary glands but the phospholipids were different and fewer in number in the parotid saliva, indicating that much of this material arises from the plaque and food debris.

The amount of calcium present in human saliva according to Jenkins (1966) averages 5.8 mg/100 ml. It has been shown by many investigators that calcium and phosphorous are present in saliva. The amount of calcium in plaque is known to be higher than in saliva. This is also true of very young, namely, one and two day old plaque, Jenkins (1965). Our observations showed that the tooth accumulated material showed a positive reaction with alizarin red denoting the presence of calcium. The literature did not cite that calcium has been detected in the acquired pellicle though plaque has already been known to contain calcium. Frank and Houver (1967) also showed positive reaction to alizarin red.

It would be logical from the previous discussion to suggest that saliva and its constituents probably perform a major role in contributing to the tooth integumental material. Similarly it is undoubtedly preferable to include such factors which might act in conjunction with saliva such as diet, oral hygiene, position of the tooth, bacteria, and exfoliated cells.

Further studies should be directed toward understanding the role performed by these factors other than saliva.

1. b Scanning Electron Microscopy of Occlusal Surfaces of Unerupted Teeth

Perikymata were easily seen using the dissecting microscope or the scanning electron microscope. These are thought to be the ends of rod groups constituting striae of Rezius. They are more numerous (30 per mm) in the cervical region and more distinct than those of the incisal and cuspal region which may contain fewer than 10 per mm. The rod end pits are normally occupied by Tomes' process of the ameloblast. As enamel formation slows down terminally the ameloblasts lose their Tomes' process. They now function on a flat linear formative front, Boyde (1964). The enamel crystals are all oriented perpendicular to the surface, Gwinnett (1967). The depth of rod end pits was known to vary, Boyde (1968) and that they measure about 1-3 μ in depth and do not have a fixed outline. Our observations of the presence of some rod end pits full of organic material poses a question as to whether this was due to technique or to selective enamel maturation.

The demonstration of blood cells in the unerupted fissure is an interesting one. Hudson (1966a)(1966b) suggested on the basis of histochemical data, that the dental cuticle is formed

from hemoglobin through degenerative changes occurring in the erythrocytes. These enter the area as a result of local hemorrhage ultimately leading to the formation of the dental cuticle which he termed "haematogenous paradontal hyaline layer". Hudson (1967) carried out an extensive study providing both experimental and descriptive data to implicate the role of hemorrhage which he found to occur between the enamel surface and ameloblasts. His evidence was gained from in vitro cuticle formation, using erythrocytes hemoglobin and insoluble globulin. Shafer et al. (1963) considered that inflammation and hemorrhage played a significant role in eruption, especially in the formation of eruption cysts. Magnusson (1968) also postulated an inflammatory reaction prior to eruption of teeth, probably due to local irritation or local inflammation. Listgarten (1966) observed that the enamel surface of unerupted teeth was often devoid of ameloblasts and covered with a loose fibrillar layer probably representing serum in which some erythrocytes and fibrin strands were present. Our observations indicate that attachment occurs between follicular tissue and the rod end pits. Presumably, this is mediated by the ameloblasts. The observation of blood elements on the occlusal surface of some of the unerupted teeth could implicate local hemorrhage occurring in the tissue before eruption. Nonetheless one cannot be certain of this

conclusion unless further investigations are undertaken of the tissue morphology around the erupting tooth to gain a better insight into the changing shapes, positions and interplay of various tissues during eruption. Meanwhile the investigations should be undertaken on the behaviour of the dental epithelium during eruption and the changes in connective tissue in advance of the erupting tooth.

1. c Scanning Electron Microscopy of the Occlusal Surface of Erupted Teeth

The presence of light and heavy areas of plaque probably indicates sites of preference of plaque development. The anatomical configuration of the tooth, its position in the arch, occlusion and hygiene are certainly factors influencing plaque development. Sites of heavy plaque were usually located in relatively protected areas, which were not in occlusion in many instances. These areas were known to be isolated from cleansing action whether intrinsic tooth brushing or other prophylactic measures, Gwinnett (1973), Taylor and Gwinnett (1973). Some of the observations made in this study verify those reported by Leach and Saxton (1966), Frank and Brendel (1966), Critchley, Saxton and Kolendo (1968). The observation of a transition in organism type in occlusal plaque appears significant. Huxley (1971) has reported that the gram positive

rods were the dominant organisms in occlusal plaque of rodents. He confirms the doubt of others concerning the extrapolation of information from rodents to humans with respect to caries. Our observations on human plaque show a number of dissimilarities with Huxley's observations on the occlusal plaque of rodents. Of particular significance is the zone of heavy plaque, it is dominated by filamentous and short-rod type organisms. Huxley (1971) observed few filamentous organisms. Furthermore, studies of our own have confirmed the observations of Mortimer (1964) that the site of occlusal caries attack is commonly occlusal to the fissure constriction and is manifested by an opaque white, linear zone of decalcification. This is the very site where heavy plaque was located and in which the filamentous organisms dominated. Whether such organisms initiate or act in an adjunction fashion to caries progression with others present in lesser numbers, e.g. coccoid and rod shaped type, is contentious. Nonetheless, transition was observed and the positive identity of such organisms would appear to be important and worthy of attention to further an understanding of pits and fissures caries. While our results can also be correlated with those of Kalberer et al. (1971) and Huxley (1971) using transmission and scanning electron microscopy respectively, we have not observed any 'corn cob' phenomena as reported by Jones (1972).

Coccoid forms were readily demonstrable as well as rod and filamentous organisms. It may be speculated that the corn cob appearance is related to the presence of lipids. These would be removed in the camphene technique but would persist in the liquid nitrogen method used by Jones (1972). In a study by Boyde and Williams (1971) using scanning electron microscopy to observe a pure culture of bacteria from the mouth, they were able to calculate the mean volume of the cells. By this means they provided a method for interpreting bacterial studies of plaque based on a cell counting method. An example is given where cariogenic streptococci were found to have a mean volume of $0.165 \mu\text{mm}^3$. This suggests that one hundred or more organisms could lodge in a simple enamel rod end pit.

Studies by Bjorn and Carlsson (1964) showed that the globular masses which appear on teeth may probably be microbial colonies. Critchley, Saxton, and Kolendo (1967) showed that squamous epithelial cells also accumulate on tooth surfaces. Saxton (1971) showed that exposure to the oral environment for as little time as 20 minutes resulted in the appearance of the enamel in the crevicular region being considerably altered due to deposition of amorphous material. He also observed globular deposits and bacteria and showed that after 7 hours exposure of enamel to the oral environ-

ment, a film of epithelial cells developed. After 24 hours the total surface of teeth was covered with epithelial cells and bacteria. These epithelial cells have distinct characteristics in that they generally appear degraded unlike epithelial cells examined in isolation.

Our observation on narrow linear structures on occlusal surfaces correspond with the studies by Mannerberg (1960) in which he showed that tooth brushing and food materials of different variety leads to different types of scratches on the occlusal surface.

1. d White Spots

So far the etiology of white spots is unknown. Thoma and Robinson (1960) described white spots as hypocalcification of enamel resulting from disturbances during the calcification or the maturation phase of amelogenesis. The causative factors are believed to be the same as those for hypoplasia, though occurring at a later time. They describe the defects as small opaque white spots. The Kostlan and Plackova (1962) studies on developmentally hypomineralized teeth showed that these areas could be quite different from areas of early carious change by being less radiolucent but well imbibed and showing a negative birefringence in water greater than that of caries. Optical changes caused by

changes in dehydration were also different. It should be pointed out that Kostlan and Plackova's work (1962) did not specify whether the teeth used were erupted or unerupted. Our results differ from those mentioned by Kostland and Plackova (1962), whom mentioned that developmental hypomineralized areas were seen in sites different from those exhibiting caries. Our observations showed that these could be seen in any area of the occlusal surface of erupted teeth. Our study also correlates with that of Crabb (1963) in which he showed that areas of hypomineralization were seen in unerupted teeth associated with dentigerous cysts. He described these areas as areas which show the same outline as lesions of caries. The question whether these white spots in unerupted teeth are carious is most contentious. The main question should be whether these areas are developmentally defective due to attack on enamel by some components of the cyst such as its fluid. This is a very difficult question to answer. Clinically, white spots are most difficult to differentiate between developmental anomaly and early carious lesions, Ticke (1965). Following biochemical studies by Bhussary (1958) on white spots identified by clinical, local and gross appearance he concluded that the areas are macroscopically and microscopically similar and that both types of white spots have high nitrogen content and a lower density than adjacent enamel.

2. Pit and Fissure Content

2. a Experimental Trials on Decalcification

The study showed that successful preservation of enamel matrix has been based on a modification of routine decalcification methods. Since there is no evidence that intact enamel could lend itself to effective fixation by routine fixation procedures, the addition of di-chloro triazine (Lissatan PR) seems to act as a "complexing agent". With these agents endogenous and exogenous skeletons are "irreversibly insolubilized" and rendered resistant to chemical treatments despite the fact that the specific nature of these reactive halogenes remains undetermined, Goland et al. (1965). Some factors were important and considered worthy of mention, namely, 5% formic acid and the addition of 3-4 slabs of teeth (i. e. 1 gm by weight) in a 50 ml solution of formic acid, the daily change of the solution of Lissatan PR and the fixation at 25 °C. The objection to the Goland technique could be raised in case of end point decalcification. He advocated the use of x-rays. While this was in many instances not satisfactory we encourage the extension of decalcification time one week in excess from the minute the x-ray determined end point decalcification. The results could be equated with the work done by Gwinnett (1971) where he showed that clinical radiographs demonstrated only a portion

of the total involvement of enamel and dentine in the carious process compared with that shown by contact microradiography and light microscopy. He further emphasized the relation in sensitivity of the clinical methods to the subtle changes that occur in dental caries and the caution of interpretation of clinical radiographs as an adjunct to caries diagnosis.

Floatation Technique:

The delicacy of manipulating the floating pellicle is of importance since any movement could lead to fragmentation of the sample. The difference between this and the Goland method is that in the floatation technique enamel preservation is not of prime importance but that of material located on the tooth. An advantage of the floatation technique is the short time factor and its simplicity. We think that a most important advantage is that at no time were the floating pellicles destroyed during sectioning. This was in contrast to the Goland technique where unobserved calcified masses after apparent total decalcification may ruin the sample on sectioning.

2. b Unerrupted Teeth: Correlation Between Light Microscopy and Scanning Electron Microscopy

When enamel is completed, ameloblasts no longer

discharge their primary function. They then seem to undergo degenerative changes. The Tomes' process disappears and a thin cuticle, the primary cuticle, marks the boundary between the enamel and the surrounding tissue. The ameloblasts are still cylindrical in shape, but they are shorter and less regular in arrangement than during the phase of enamel matrix synthesis. The nuclei are more centrally situated. The ameloblasts together with the remaining cells of the stratum intermedium and the outer enamel epithelium have fused. At this stage of eruption of the tooth this is referred to as the reduced enamel epithelium and covers the entire crown of the tooth. The observation of erythrocytes in the space between dental sac and reduced enamel epithelium was also seen. However this is a clinically well known observation which in extreme cases may lead to the so called eruption cyst, Shafer, Hine and Levy (1963). An apparently strong bond existed between reduced enamel epithelium and the enamel surface. Such an attachment persists in erupted teeth and forms part of the epithelial attachment. It may remain so even following such traumatic operations as routine dental extraction, Macapanpan (1954).

A review of the literature shows a number of investigators giving a number of synonyms to the primary enamel cuticle and often arguing its presence and absence.

Our observations using light microscopy show that the primary enamel cuticle can be seen in some parts and not in others. Ussing, Scott and Kaplan (1951) and Ussing (1955) argued strongly for its presence. Hudson (1966) showed that it was an acquired structure. On the other hand, Listgarten (1966) showed, with the transmission electron microscope, that no such structure as "enamel cuticle" is present, and supported his studies with those of Rambourg, Neutra and Leblond (1966). They found that certain membrane-like structures, the thickness of which is below the limit of resolution of the light microscope, may nevertheless become visible because of section preparation. In fact such structures are seldom cut in a plane perfectly perpendicular to the membrane surface. In this study we suggest that the primary dental cuticle might likely be an optical phenomenon due to a persistent surface layer of enamel if decalcification is incomplete. It was always observed that if ameloblasts were attached to a partially mineralized surface enamel the primary enamel cuticle appeared as a dark line. In specimens where the enamel prisms were completely lost, then primary enamel cuticle appeared absent. This phenomenon was observed in closely related sites. This is supported by Spiers (1971) who showed that enamel surface mineral content could differ from one area to the other. Our study showed no

support for the idea that cementum or cementum-like coverings exist on unerupted teeth as reported by Levine, Glimcher and Bonar (1964).

It is reasonable to conclude from present evidence that the ameloblasts line the wall of the fissures and terminally appear strangulated or squeezed inside the fissures. One is tempted to speculate that this occurred at the late stages of enamel maturation since the ameloblasts at that time cease to be arranged in a well defined layer and can no longer be differentiated from the cells of the stratum intermedium and outer enamel epithelium. The presence of red blood cells might be due to bleeding associated with operative procedures, but the haemorrhage into the follicular space may be a normal part of tooth eruption. There is no ready explanation to account for its occurrence.

2. c Erupted Teeth

The presence of an acquired cuticle on erupted teeth was verified by Turner (1958), McDougall (1963) and Meckel (1965). Remnants of the developmental cuticles are rather rare in functional teeth, Frank and Brendel (1966).

The nomenclature advocated by Dawes, Jenkins and Tonge (1963) is most applicable. The acquired cuticular structure is cellular, essentially bacteria free and is only

deposited after eruption of the tooth and the loss of the integument of embryological origin. McDougall (1963) noted that all plaques on enamel included an acquired cuticle which appeared homogenous and continuous ranging in width from 0.3 to 0.8 microns. Histological examination of strip material consistently demonstrated the accumulation of microbial masses as early as 1 to 2 days after strip insertion. The micro organisms were mainly coccoidal in the early plaque and appeared to be embedded in an amorphous and fibrillar substance (Mandel, Levy and Wasserman 1957, Muhlemann and Schneider 1959, Turesky, Renstrup and Glickman 1961, and Schroeder 1963). The existence in the inter-microbial matrix of developing calculus was clearly demonstrated by the electron microscopic studies of Zander, Hazen and Scott (1960); Schroeder, Lenz and Muhlemann (1963); and Theilade (1964). The observations on the strip material can be extrapolated to the situation as it exists in fissures. McDougall (1963) showed that a day's deposit on the enamel surface is an immature plaque, almost devoid of bacteria. After the second day the bacteria appeared as low dome-shaped discontinuous clumps. Once the bacteria appeared there was a rapid and progressive invasion and replacement of the "immature plaque" by microbial masses. These observations were also documented by Leach and Saxton

(1966) in which they showed that acquired pellicle becomes thinner and more infiltrated as bacteria massed within it. Frank and Brendel (1966) found two types of structures over the teeth. They found cuticular deposits with no overlying bacterial aggregations and on other teeth they noted bacteria directly in contact with enamel surface. Whether the cuticle has been present and lysed prior to examination is not certain. They considered the first step in dental plaque formation to be the apposition of bacterial mono layers, along the enamel surface. The cell wall of the micro organisms is applied directly to the superficial enamel apatite crystallites. An inter-bacterial matrix in contact with the enamel surface extends laterally but does not cover the first layer of micro organisms. Soon after a second bacterial layer aggregates on the first layer of micro organisms and progressively more and more layers of bacteria pile up each on top of the other.

From the bacteriological point of view, plaque shows changes in its population with time. Howell, Rizzo and Paul (1965) showed that during 14 to 21 day periods, the number of filamentous forms increased from 4% to 18% with a reduction in gram positive coccoid and neisseria. Loe, Theilade and Jensen (1965) and Theilade, Wright, Jensen and Loe (1966) in their study on experimental

gingivitis showed that three bacteriological phases in plaque development are seen during the first two days without tooth brushing. They found initially a proliferation of gram positive cocci and rod. The second phase, occurring during 2-4 days was characterized by a proliferation of fuso-bacteria and filamentous bacteria in addition to the organism already present. During a third phase, after 4-9 days, spirilla and spirochetes are added so that a complex flora is formed. After 7 days the various groups have proliferated to the extent that gram positive cocci and rods which originally predominated now only constitute about 50% of the flora.

Ritz (1967) extended the observations on the shift in microbial population in developing dental plaque to include the cultural characteristics as well as relative numbers. He found that during early stages of plaque deposition, streptococci, neisseria and nocardia were the dominant types. After 9 days there were somewhat fewer streptococci and a large proportion of actinomyces, veillonella, corynebacteria and fuso-bacteria which indicates that plaque development is associated with a decline in proportion of aerobic organisms and increase in number of anaerobic organisms. Ritz also suggested that the changes in the population shift are due, at least in part, to the oxidation

reduction potential occurring in the plaque during development.

The growth of anaerobes such as veillonellae and fusobacteria may be dependant upon prior growth of aerobic and facultative organisms with a resultant increase in plaque thickness yielding conditions suitable for anaerobic growth.

Although several comparisons have been made of the number of the various types of oral bacteria in different regions of the mouth, there is little information regarding the bacterial population of an individual tooth surface.

Handelman and Hess (1968) showed that bacterial profiles of selected tooth sites (lingual and interproximal) could be determined by using culture procedures. They observed that there were differences in the percentage distribution of bacteria on the tooth surface of the lower anterior, upper premolar and molar samples. The profile was essentially the same for all sites. The total anaerobic cultivatable count was also similar.

Bokrass (1969) reviewed the bacteriology of dental plaque and considered it as a mixed culture in a complex natural medium and that the population density is very high and that the frequency of existance of different organisms in the plaque can vary considerably.

Gwinnett and Buonocore (1972) suggested that deposits located at the base of the fissures seemed to contain structures

resembling micro-organisms yet they conceded that their specimen preparation might have modified the geometry of these bodies. Our investigations using the modified camphene technique, (Galil and Gwinnett, 1973a and Galil and Gwinnett, 1973b) showed that the contents of the fissure are partly bacterial in structure and they might be incorporated with other factors which affect the formation of dental plaque. Our observations also showed positive reactions to carbohydrates, proteins, lipids and calcium. It might be speculated that the constituents which may form the contents of the fissures of erupted teeth are bacteria in addition to dietary and/or salivary components in conjunction with the original contents of the fissure existing at the time of eruption in the oral cavity. Precisely what events take place in the fissures shortly after their contact with the oral environment is not known. One might suggest that saliva and micro organisms might play a most significant role.

The mineralization of the fissure contents and the demonstration of a crystalline structure in the fissures is a new observation. The ability of certain types of microorganisms to produce calcified material has been discussed by Rizzo, Scott and Bladen (1963). They illustrated that oral bacteria both in their natural periodontal environment and an in vivo experimental environment seem capable of providing

a matrix for hydroxyapatite formation. Moreover, the electron microscope studies of experimental material indicated that the bacterial cell itself may serve as a nidus for the beginning of crystallization. In some organisms it seems clear that the initial calcification is a true inter-cellular phenomenon, whereas in other organisms early mineralization seems to be related directly to cell surface. It is also known that calcium phosphate precipitation can occur in the immediate external environment of a bacterial cell as a result of alteration of that environment by the cell. Hutchison (1961) detected minute crystals of a "complex calcium phosphate" in old cultures of a coagulase-positive staphylococcus aureus. Wasserman, Mandel and Levy (1958) demonstrated that colonies of Actinomyces israeli could bind calcium into the colony structure independent of metabolic activity. Colonies were cut from blood agar, some were formalin killed and all were immersed in a meta-stable calcium phosphate solution. After 6 days the colonies were sectioned for bound calcium by von Kossa silver substitution technique. All were positive. Zander, Hazen and Scott (1960) found that in areas which were densely calcified there were large apatite crystals both between and within microorganisms. Ennever (1960) tested the hypothesis that Bacterionema matruchotii, a member of the order Actinomycetales, could convert calcium salts to an insoluble

form intracellularly. Harvested cells were washed with water and examined by cytochemical and physical techniques. Cells from 5-day cultures were von Kossa and alizarin red S positive. Those from younger cultures were usually negative and x-ray diffractograms showed patterns identical to calcium hydroxyapatite. Takazoe, Kurhashi and Takuma (1963) found that non-living Bacterionema matruchotii could calcify. Ennver, Vogel and Brown (1969) concluded in their study that at least fourteen microorganisms could be obtained from the mouth of man. These organisms were tested for calcification after growth in a chemically defined medium essentially identical to that in which Bacterionema matruchotii acquires intracellular apatite. Four of the microorganisms, Escherichia coli, Alcalignes marshalli, Aerobacter cloacae and Proteus mirabilis developed intracellular calcification. Smith, Streckfuss and Ennever (1973) showed that variant Bacterionema matruchotii retain the capacity to calcify.

Our results also showed the presence of a calcified material in the fissures of erupted teeth and this was termed "progressive mineralization of the fissures". In addition we also observed a total mineralization and crystal formation in the fissure in varying forms. Obviously, the specific chemical nature of these processes requires further investigation. In a recent publication by Kaufman and

Kleinberg (1973) they showed that with the aging of plaque a transition occurs from an amorphous to a crystalline state. Transition was less in plaques from younger subjects than from older subjects and less in plaques from maxillary than from mandibular teeth. The predominant forms of calcium phosphate observed were brushite and apatite. The incidence of the latter increased with increased crystallinity. The high incidence of crystallinity and especially of apatite occurred in older subjects and in the mandibular plaques exhibiting a high pH.

3. In Vitro Tooth Cleaning

The development and use of the technique of sodium hypochlorite is a relatively new concept. The assessment of the relative efficiency of various means of cleaning teeth was investigated in our work. The amount of debris present varied considerably from tooth to tooth before treatment and after treatment with sodium hypochlorite. It was easy to visualize with disclosing solution. Visual examination showed that observable differences could be seen. The results obtained using sodium hypochlorite depends on a) the amount used, b) the concentration used, c) the duration, d) close adherence to the technique. Sodium hypochlorite is highly caustic when used at a concentration of 5% or more. It is commercially available in 5%-7% as Javex. It is

also used as a denture cleaner (Kutchner, Zegarelli, Hyman, McLean and Kutchner 1967).

Sodium hypochlorite is considered as a chlorine liberating compound. These substances are chiefly used for irrigating infected wounds and their alkalinity is often accompanied by detergent action. They are extensively used for the disinfection of drinking water and are effective against viruses as well as bacteria. A known solution, modified Dakins solution (about 0.48%) is used as an active germicide and deodorant. Its action is not by precipitating proteins but because of its alkalinity it dissolves necrotic tissue and removes foul odour by oxidation. It is also used undiluted for irrigation and diluted with 3-5 parts water as mouth wash or oral spray, Dobbs (1961).

The results showed that enamel surface deposits were affected but apparently not enamel. On a comparative basis with ethylenediamine the latter was not satisfactory, besides ethylenediamine is highly toxic whether as a vapour or liquid and extremely dangerous to manipulate. The ineffectiveness of hydrogen peroxide in three percent concentration was apparent. The highest concentration of hydrogen peroxide (30%) showed slight improvement but did not equal the results obtained by sodium hypochlorite.

The scanning electron microscope observations, after treatment of enamel with sodium hypochlorite, occasionally showed solid

masses of apparently calcified material in the fissures. This remains in the fissure after the soft deposits have been lysed by sodium hypochlorite. This has been discussed under the progressive mineralization of the fissures.

4. Replication of Teeth

To provide a three dimensional display of the pits and fissures is of great importance to understanding their outline and shape. This is a key to a better understanding of selecting preventive and operative procedures associated with them. The literature review indicates that information on the shape of the pits and fissures was gained from two dimensional displays. The development of a technique using vinyl resin demonstrated superiority to the clear cast method in which the latter showed deficiencies due to incomplete replication. The use of a low viscosity resin (SPURR)* did not provide the expected result for under examination with the scanning electron microscope deficiencies were clearly seen. For transmission electron microscopy, this resin is considered superb because of its excellent penetration into soft as well as hard tissues. There are possibly two factors responsible one of them being early polymerization of resin before complete filling of the fissures. The second factor, observed during decalcification of the tooth in hydrochloric acid, was one of solubility of the resin in the acid. Deficiencies may have arisen through resin dissolution.

*Polyscience. Data sheet #127

The vinyl resin technique is very simple and proved to be most effective. There are some important considerations in using the vinyl resin technique. These are as follows:

Unerupted teeth give the best results following cleansing in the sodium hypochlorite. A clean fissure can be assured. On the other hand, erupted teeth, particularly old teeth, do not replicate well due to the fissures being filled with relatively insoluble contents. The vinyl resin should be homogeneous for inhomogeneity leads to faulty results. Homogeneity is achieved by gently agitating the resin and acetone solvent. The dryness of the tooth is also an important factor since any moisture or fluid on the tooth and particularly in the fissures will prevent the complete penetration and adaptability of resin to the fissure walls. Initial attempts to inject the vinyl resin were unsuccessful. However the application of vacuum considerably improved the technique and its results. The use of concentrated hydrochloric acid for tooth decalcification and continuous agitation lead to very satisfactory results. The ability to easily trim the material added to its versatility. Observations on the replicas by scanning electron microscopy (SEM) and stereoscopic displays most adequately showed the value of the technique. The SEM, with its large depth of field, demonstrated directly the otherwise unseen detailed shapes of pits and fissures. This is in sharp contrast to the methods used by other investigators, where the shape was determined by laborious inspection of serial

undecalcified sections. The resin technique was not only useful in replicating the pits and fissures but very adequately replicated microstructural detail, e. g. on previously etched enamel surfaces.

5. Comments on the Preparation of Tooth Material for Scanning Electron Microscopy as Used in this Investigation

With the increasing interest in scanning electron microscopy of biologic tissues, several specimen preparation techniques have been developed. The introduction of simple sublimation techniques, by Buck (1958), Watters and Buck (1971) have shown considerable promise particularly with reference to large tissue samples. A modification of the camphene technique was also developed (Galil and Gwinnett, 1973a) where a desirable minimum time to complete sublimation for a molar tooth is approximately 16 hours. For shorter periods sublimation is incomplete and artifacts are introduced. Clearly, adequate time must be allowed for complete sublimation and volatilization of camphene. The rate of these chemical actions in and from the tooth by virtue of its physical composition and physio-chemical properties compared to soft tissue will vary. In this respect relatively long times are apparently necessary to reach the desired results, e. g. whole tooth crowns - a minimum of 16 hours is recommended.

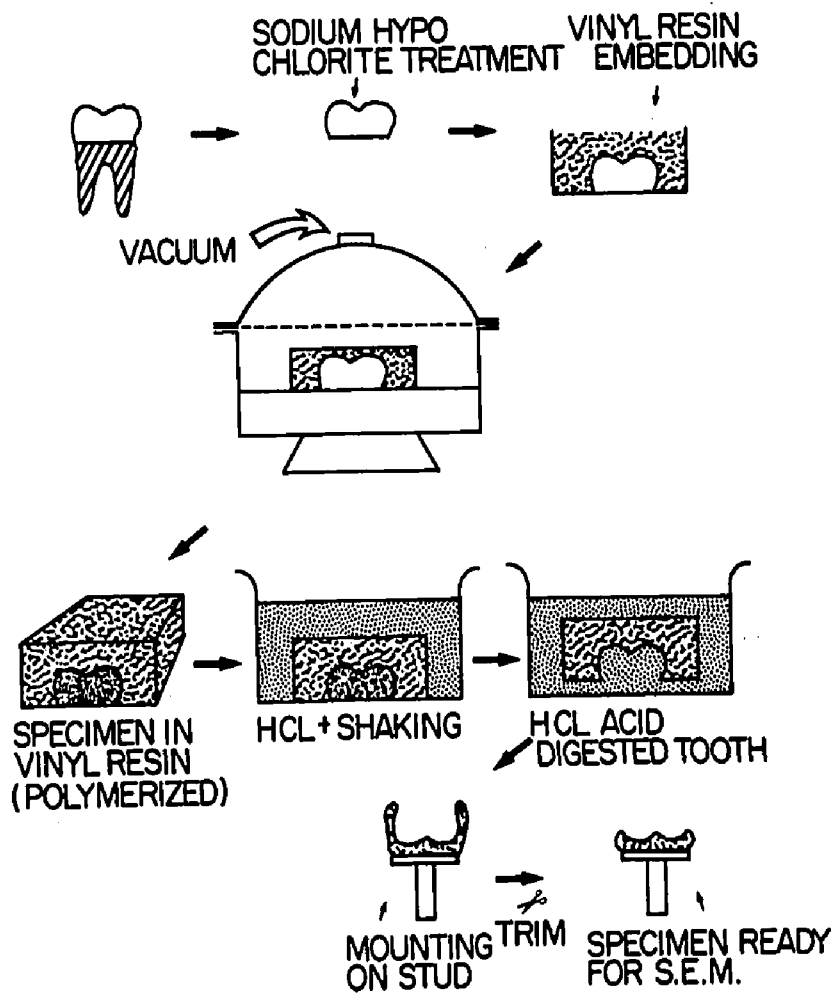
IV SUMMARY AND CONCLUSION

- * 1. A technique was developed using vinyl resin to provide a three dimensional replica of pits and fissures of human molariform teeth. Scanning electron microscopy was used to study the replicas (Fig 63).
- * 2. A technique was developed for studying the contents of the pits and fissures of erupted teeth. This was termed 'floatation technique'. An histologic examination was made of the floated material.
- * 3. A technique was developed for cleansing the occlusal surface, pits and fissures in vitro by the use of sodium hypochlorite. The teeth were examined subsequently with the scanning electron microscope.
- * 4. A modified camphene technique was used in conjunction with scanning electron microscopy to study teeth plaque.
- * 5. A demonstration of the contents of fissures of unerupted teeth was provided using the Goland technique.

Figure 63

Diagram representing the steps in preparation of three dimensional replicas of occlusal surfaces, pits and fissures using vinyl resin.

STEPS FOR PREPARATION OF 3-DIMENSIONAL REPLICAS
OF OCCLUSAL SURFACE PITS & FISSURES USING VINYL RESIN

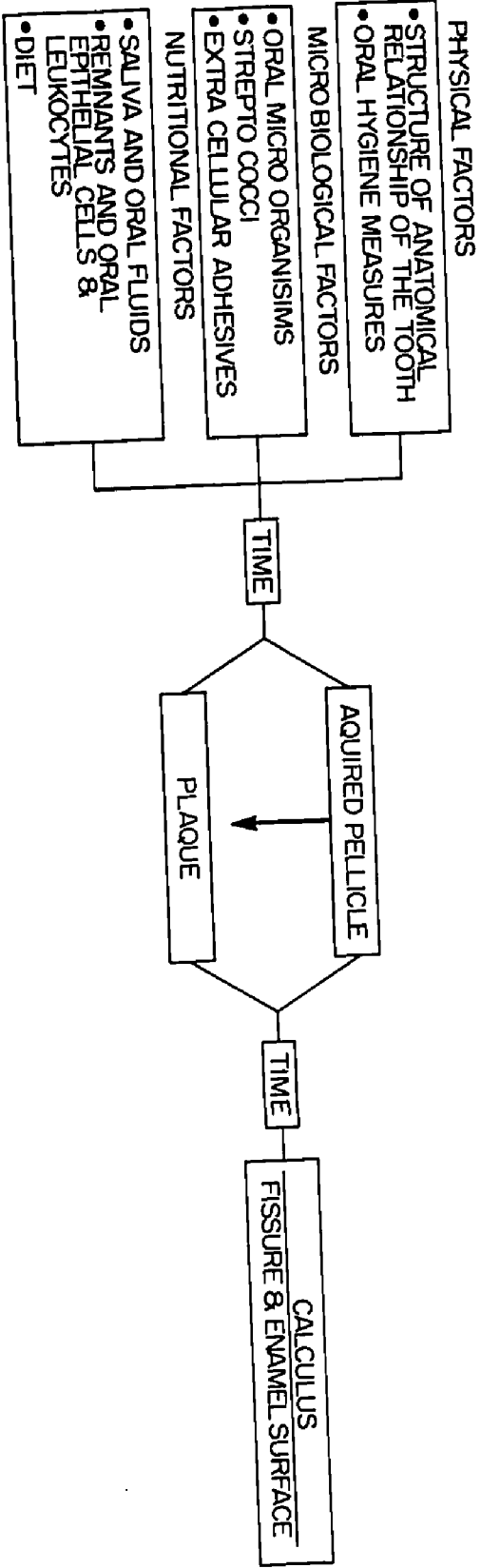


- * 6. The presence of ameloblasts lining the fissure walls of unerupted tooth was shown using the scanning electron microscope.
- * 7. The first demonstration of the results of a process termed progressive mineralization was made in which crystal formation led to plugging of the fissures of erupted teeth.
- * 8. A direct visualization was made for the first time of a three dimensional replica display of occlusal surfaces, pits and fissures.
- * 9. Oral microorganisms were seen to be deposited on the occlusal surfaces of teeth in a specific pattern and different factors appeared to dictate the final outline of the plaque. Coccoid and filamentous organisms were deposited and distributed in light and heavy areas respectively. The heavy areas were almost exclusively located in the region of the occlusal orifice to the fissures, but not extending into the deeper regions of the fissures. Such deeper fissural sites were dominated by coccoidal forms.
- 10. The dental plaque covering a normal occlusal surface was found to be built up of numerous types of bacteria whose taxonomic identification is not yet possible.

11. Coccoid organisms were seen to lie in direct relation to enamel surfaces while filamentous material were seen in perpendicular relation to the enamel surface.
- * 12. The fissures of erupted teeth displayed three types of bacteria within, namely, cocci, bacilli and filamentous microorganisms. The fissure contents also exhibited positive reactions for proteins, carbohydrates, lipids and calcium. The bottom of some fissures often exhibited an affinity for calcium stains.
13. Saliva and its constituents probably perform a major role in the make-up of tooth integumental material with the incorporation of physical, microbiological and nutritional factors. These in addition to the time factor will also affect the constituents and contents of fissures (Fig 64).
- * 14. Fissures of erupted teeth occasionally exhibited a transformation in their contents from a distinct bacterial form to a solid calcified mass. This process was termed "progressive mineralization of the fissures". Also, total mineralization of the fissures of older erupted teeth were observed. It was suggested that the calcified mass might be a calcium phosphate.

Figure 64

Diagram representing the factors affecting the formation of
fissure contents in erupted teeth.



FACTORS AFFECTING THE FORMATION OF FISSURE CONTENT IN ERUPTED TEETH

- * 15. The bacteria in some of the fissures were apparently associated with the formation of crystals both inter cellularly and intra microbially.

- 16. The occlusal surface of unerupted teeth were covered by follicular material. The enamel exhibited perikymata and the presence of rod end pits.

- * 17. Fissures of unerupted teeth showed ameloblast lining the fissure wall. The rest of the fissure contents showed degenerated cells, and remnant of the epithelial enamel organ and blood cells.

- * 18. Some of the fissures of unerupted teeth showed signs of squeezing and strangulation of the ameloblasts probably leading to their death or inevitable entrapment.

- * 19. Developmentally hypomineralized white spots were observed on the unerupted tooth surface. They were classified according to their area distribution; point distribution, partial area distribution and total area distribution. The fissures also exhibited white spots and were classified from a morphological point of view into total fissure involvement, partial fissure involvement and no fissure involvement.

- * 20. Sodium hypochlorite was shown to be effective in

removing organic material covering the tooth or its fissures especially in unerupted and freshly erupted teeth. Direct evidence of suppression of the microorganisms population was observed after 36 hours.

21. Replication of the fissures of erupted teeth proved difficult since an organic or calcified plug often precluded resin penetration (Fig 65).

* 22. The replication technique showed that the morphology of pits and fissures vary from one tooth to another. Caution must be exercised when interpreting the results of the serial sectioning method, for studying fissure morphology.

23. Bacteria in relation to the fissures of teeth have always been a problem to visualize due simply to their location. The scanning electron microscope proved to be most practical for overcoming some of the difficulty. Occlusal human dental plaque as well as contents of pits and fissures was demonstrated.

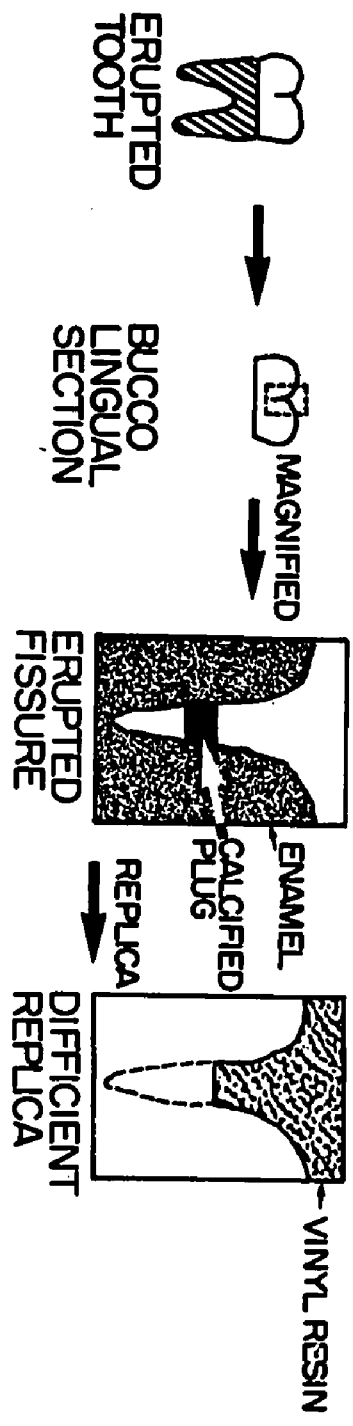
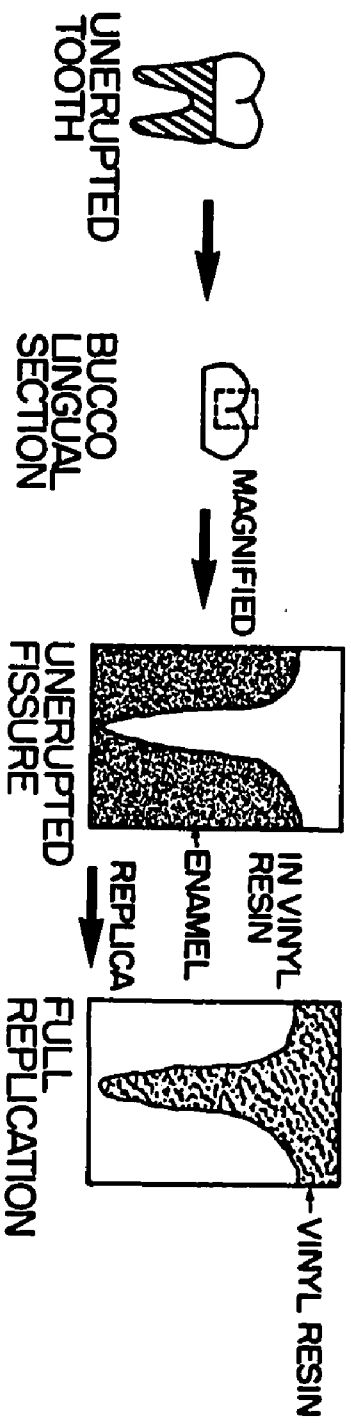
24. Adhesive sealing of pits and fissures of erupted teeth must be assessed in terms of the finding of this study.

25. The conventional methods for cleaning the occlusal surface, pits and fissures from their contents should be

Figure 65

Diagram demonstrating the difference between unerupted and erupted pit and fissure replication.

DIAGRAM DEMONSTRATING THE DIFFERENCE BETWEEN UNERUPTED & ERUPTED PT AND FISSURE REPLICATION



revised.

Note: Those items marked with an asterisk represent new findings not previously reported in the literature.

Possible Avenues for Future Study

1. To examine the role performed by factors other than saliva in the formation of tooth integumental material.
2. To further study the changes which occur in the dental epithelium during tooth eruption.
3. To study the connective tissue and the changes which occur in the oral mucosa in advance of the erupting tooth.
4. To compare isolated and known oral microorganisms by the SEM using them as a standard for further guidance on plaque or caries research.
5. To study the chemical nature of the mineralized structures observed in the fissures using quantitative and qualitative techniques.
6. To pursue the in vitro and in vivo removal of both organic and inorganic accumulated material located on the occlusal surface and in pits and fissures.
7. To develop a technique for decalcification of enamel by means of alizarin red compounds as complexing agents.

BIBLIOGRAPHY

- Aitchison, J. (1949). Dental Anatomy and Physiology for Students.
London: Staples. 77.
- Andrews, A. A. (1889). The Pits and Fissures of the Enamel.
Dent. Cosmos 31: 719-727.
- Armstrong, W. G. (1968). Origin and Nature of the Acquired
Pellicle. Proc. R. Soc. Med. 61: 923-930.
- Arnim, Sumter S. (1959). Microsomes of the Human Mouth. J.
Tenn. D.A. 39: 3-28.
- Arnim, Sumter S. (1963). The Use of Disclosing Agents for
Measuring Tooth Cleanliness. J. Periodont. 34: 227-245.
- Atkinson, H. F. (1948). Section Cutting Machine. Br. Dent. J.
84: 260-261.
- Avery, J. K. (1964). In: Laboratory Technique in Biology and
Medicine. ed. Emmel, V. M. and Cowdry, E. V. 4th ed.
Baltimore: Williams and Wilkins. 411.
- Awazawa, Y. (1963). The Electron Microscope Atlas of Dental
Diseases. 1st ed. Tokyo: Nihon University, School of
Dentistry.

- Awazawa, Y. (1966). Electron Microscopic Study on the Hypo-mineralized Enamel Areas Descending from the Floors of Occlusal Fissures Toward the Amelo-dentinal Junctions. *J. Nihon Univ. Sch. Dent.* 8: 33-44.
- Awazawa, Y. (1969). Re-examination of the Morphology of Caries Susceptible Grooves in the Premolar and Molar. *J. Nihon Univ. Sch. Dent.* 11: 1-15.
- Backer-Dirks, O. (1963). The Assessment of Flouridation as a Prevention Measure in Relation to Dental Caries. *Br. dent. J.* 114: 211-216.
- Barker, S.A., Pardoe, G.I., Stacey, M. and Hopton, J.W. (1963). Sequential Enzyme Induction: A New Approach to the Structure of Complex Mucoprotein. *Nature* 197: 231-233.
- Bhussry, B.R. (1958). Chemical and Physical Studies of Enamel From Human Teeth. III Specific Gravity, Nitrogen Content, and Histologic Characteristics of Opaque White Enamel. *J. dent. Res.* 37: 1054-1059.
- Bibby, B.G. (1931). A Study of a Pigmented Dental Plaque. *J. dent. Res.* 11: 855-872.
- Bibby, B.G. (1935). Neglected Factors in the Study of Dental Caries. *Trans. Am. dent. Ass.* 22: 222-239.
- Bibby, B.G. (1938). The Bacterial Flora in Different Parts of the Mouth. *J. dent. Res.* 17: 471-476.

- Bibby, B. G. (1968). Concerning Dental Plaque. *Caries Res.* 2: 97-103.
- Bjorn, H. and Carlsson, J. (1964). Observation on Dental Plaque Morphogenesis. *Odont. Revy.* 15: 23-28.
- Black, G. V. (1886a). Micro-organisms of the Oral Cavity. *Trans. Ill. State dent. Soc.* 22: 180-208.
- Black, G. V. (1886b). Gelatin Forming Micro-organisms. *Indep. Practitioner* 7: 546-548.
- Black, G. V. (1887). Micro-organisms. *Trans. Ill. State dent. Soc.* 23: 162-173.
- Black, G. V. (1895). An Investigation of the Physical Characters of the Human Teeth in Relation to Their Diseases, and to Practical Dental Operations, Together with the Physical Characters of Filling Materials. *Dent. Cosmos* 37: 353-369.
- Black, G. V. (1897). *Descriptive Anatomy of the Human Teeth.* 1st ed., Philadelphia: S. S. White Dental Manufacturing Co.
- Black, G. V. (1898). Dr. Black's Conclusions Reviewed Again. *Dent. Cosmos* 40: 440-451.
- Black, G. V. (1899). Susceptibility and Immunity to Dental Caries. *Dent. Cosmos* 41: 826-836.
- Black, G. V. (1908). *A Work on Operative Dentistry.* V. 1 Chicago: Medico-Dental Publishing Company. 34-38.
- Bodecker, C. F. (1924). Microscopic Study of Enamel Fissures, with Reference to Their Operative Treatment. *Dent. Cosmos* 66: 1054-1067.

- Bodecker, C.F. (1926a). The Tooth Brush in Relation to Enamel Caries. *Dent. Items* 48: 161-167.
- Bodecker, C.F. (1926b). Bacteria in Relation to Enamel Fissures. *Dent. Items* 48: 797-801.
- Bodecker, C.F. (1929). Eradication of Enamel Fissures. *Dent. Items* 51: 859-866.
- Bokrass, O. (1969). A Review of the Bacteriology of Dental Plaque. In: *Dental Plaque*. ed. McHugh, W.D. Edinburgh and London: Livingston.
- Boyde, A. (1964). The Structure and Development of Mammalian Enamel. Ph.D. Thesis, University of London.
- Boyde, A. (1968). The Depth of Enamel Rod Ends (Abstract). *J. dent. Res.* 47: 1005
- Boyde, A. and Lester, K.S. (1968). Scanning Electron Microscopy of Carious Cavity Plaque after Ethylene Diamine Treatment. *Archs. oral Biol.* 13: 1413-1419.
- Boyde, A. and Williams, R. A. (1971). Estimation of the Volumes of Bacterial Cells by Scanning Electron Microscopy. *Archs. oral Biol.* 16: 259-267.
- Brain, E.B. (1966). The Preparation of Decalcified Sections. Springfield, Ill.: C.C. Thomas. 70.
- Brandtzaeg, P. (1964). The Significance of Oral Hygiene in the Prevention of Dental Disease. *Odontol. Tidskr.* 72: 460-486.

- Brekhus, P.J. (1931a). A Report on Dental Caries in 10445 University Students. *J. dent. Res.* 11: 487-488.
- Brekhus, P.J. (1931b). A Report on Dental Caries in 10445 University Students. (1928-1930). *J. Am. dent. Ass.* 18: 1350-1356.
- Bremner, M.D.K. (1964). *The Story of Dentistry.* 3rd ed. Brooklyn, New York: Dental Items of Interest Publishing Co., Inc.
- Brucker, M. (1944a). Studies on the Incidence and Cause of Dental Defects in Children. VI. Pits and Fissures. *J. dent. Res.* 23: 89-99.
- Brucker, M. (1944b). Studies on the Incidence and Cause of Dental Defects in Children. VII. Fissures and Caries. *J. dent. Res.* 23: 101-103.
- Buck, R.C. (1958). The Fine Structure of Endothelium of Large Arteries. *J. biophys. biochem. Cytol.* 4: 187-190.
- Campaigne, E.E., and Fosdick, L.S. (1938). Production and Characteristics of Synthetic Mucin Plaques. *Northw. Univ. Bull. dent. Res.* 14-17.
- Coleman, A.J. (1971). *A Syllabus in the Study of the History of Dentistry.* Los Angeles: University of Southern California.
- Crabb, H.S.M. (1963). Area Simulating Carious Lesions in Enamel of Teeth from Dentigerous Cysts. *Br. dent. J.* 114: 499-511.

- Critchley, P. and Saxton, C.A. (1970). The Metabolism of
Gingival Plaque. *Int. dent. J.* 20: 408-425.
- Critchley, P., Wood, J.M., Saxton, C.A. and Leach, S.A. (1967).
The Polymerization of Dietary Sugars by Dental Plaque.
Caries Res. 1: 112-129.
- Critchley, P., Saxton, C.A. and Kolendo, A.B. (1968). The
Histology and Histochemistry of Dental Plaque. *Caries Res.*
2: 115-129.
- Cummins, C.S. and Harris, H. (1956). The Chemical Position
of the Cell Wall in Some Gram Positive Bacteria and its
Possible Value as a Taxonomic Character. *J. gener. Microb.*
14: 583-600.
- Curson, I. and Manson, J.D. (1965). A Study of Group of Dental
Students, Including their Diet and Dental Health. *Br. dent. J.*
119: 197-205.
- Darling, A.I. (1943). Distribution of Enamel Cuticle and its
Significance. *Proc. R. Soc. Med.* 36: 449-502.
- Dawes, C. and Jenkins, G.N. (1963). Studies Related to the
Formation of Dental Plaque. 41st Meeting, *Int. ass. dent. Res.*
Abstract # 362.
- Dawes, C., Jenkins, G.N. and Tonge, C.H. (1963). The Nomen-
clature of the Integuments of the Enamel Surface of Teeth. *Br.*
dent. J. 115: 65-68.

- Dobbs, E. C. (1932). Local Factors in Dental Caries. *J. dent. Res.* 12: 853-864.
- Dobbs, E. C. (1961). *Pharmacology and Oral Therapeutics*.
St. Louis: Mosby. 426.
- Dunning, W. B. and Davenport, E. J. (1936). *A Dictionary of Dental Science and Art*. Philadelphia: Blakiston. 215.
- Drury, R. A. B., Wallington, E. A., and Cameron, R. (1967). *Carlton's Histological Technique*. 4th ed. New York, Toronto: Oxford Univ. Press.
- Ennever, J. (1960). Intracellular Calcification by Oral Filamentous Microorganisms. *J. Periodont.* 31: 304-307.
- Ennever, J., Vogel, J.J. and Brown, L.R. (1972). Survey of Microorganisms for Calcification in a Synthetic Medium. *J. dent. Res.* 51: 1483-1486.
- Ericson, T. (1967). Adsorption to Hydroxyl Apatite of Proteins and Conjugated Proteins from Human Saliva. *Caries Res.* 1: 52-58.
- Evans, N. and Karjian, A. (1930). New Method of Decalcification. *Arch. Path.* 10: 447.
- Fosse, G. (1954). An Apparatus and Technique for the Preparation of Ground Sections and the Performance of Serial Surface Grinding. *J. dent. Res.* 33: 139-144.

- Frank, R. M. and Brendel, A. (1966). Ultrastructure of the Approximal Dental Plaque and the Underlying Normal and Carious Enamel. *Archs. oral Biol.* 11: 883-912.
- Fusayama, T. (1964). Diagnosis and Distribution of Pits and Fissures. *J. prosth. Dent.* 14: 117-126.
- Galil, K. and Gwinnett, A.J. (1973a). Application of the Camphene Technique in the Examination of Teeth by Scanning Electron Microscope. *Archs. oral Biol.* (in press).
- Galil, K. and Gwinnett, A.J. (1973b). Some Observations on Occlusal Human Dental Plaque as Seen by Scanning Electron Microscope. *J. Can. dent. Ass.* (in press).
- Gaunt, W. A., Osborn, J.W. and Ten Cate, A.R. (1971). In: *Advanced Dental Histology*. 2nd ed. Bristol: John Wright and Sons Ltd. 122.
- Gibbons, R.J., Socransky, S.S., and De Araujo, W.C. and Van Houte, J. (1964). Studies on the Predominant Cultivable Microbiota of Dental Plaque. *Archs. oral Biol.* 9: 365-370.
- Gillings, B. and Buonocore, M. (1959). An Apparatus for the Preparation of Thin Serial Sections of Undecalcified Tissues. *J. dent. Res.* 38: 1156-1165.
- Gillings, B. and Buonocore, M. (1961). Thickness of Enamel at the Base of Pits and Fissures in Human Molars and Bicuspid. *J. dent. Res.* 40: 119-133.

- Goland, P., Tagger, S. E. and Engel, M. (1965). Enamel Preservation During Decalcification Following Fixation by Some Reactive Halogen Compounds. *J. dent. Res.* 44: 342-349.
- Gottlieb, B. (1921a). Der Epithelansatz. *Am. Zahne Dtsch. Mschr. Zahnheilk.* 39: 142-147.
- Gottlieb, B. (1921b). Asiologie und Prophylaxie der Zahnkaries. *O. Z. Stomat.* 19: 129-152.
- Crainger, R. M. and Reid, D. B. W. (1954). Distribution of Dental Caries in Children. *J. dent. Res.* 33: 613-623.
- Gray, J. A. and Opdyke, D. L. (1962). A Device for Thin Sectioning of Hard Tissue. *J. dent. Res.* 41: 172-181.
- Gustafson, G. and Gustafson, A. G. (1962). Imperfections in Enamel Structure and Their Possible Relation to Caries Susceptibility. *Proceedings of the 6th O. R. C. A. Congr. dent. Caries, Pavia, 1959.* 27-33.
- Gwinnett, A. J. (1964). The Histology of Normal Enamel, Ph. D. Thesis, Univ. of Bristol.
- Gwinnett, A. J. (1967). The Ultrastructure of the "Prismless" Enamel of Permanent Human Teeth. *Archs. oral Biol.* 12: 381-387.
- Gwinnett, A. J. (1971). Morphology of the Interface Between Adhesive Resins and Treated Human Enamel Fissure as Seen by Scanning Electron Microscopy. *Archs. oral Biol.* 16: 237-238.

- Gwinnett, A. J. (1971). A Comparison of Proximal Carious Lesions as seen by Clinical Radiography, Contact Microradiography, and Light Microscopy. *J. Am. dent. Ass.* 83: 1078-1080.
- Gwinnett, A. J. (1971). Histologic Changes in Human Enamel Following Treatment with Acid Adhesive Conditioning Agent. *Archs. oral Biol.* 16: 731-738.
- Gwinnett, A. J. (1973). The Bonding of Sealants to Enamel. *J. Am. Soc. prev. Dent.* 3: 21-29.
- Gwinnett, A. J. and Buonocore, M. G. (1972). A Scanning Electron Microscope Study of Pit and Fissure Surfaces Conditioned for Adhesive Sealing. *Archs. oral Biol.* 17: 415-423.
- Hammarlund-Essler, E. (1956). A Method for Preparing Ground Sections for Micro-Radiography and Auto-Radiography with a Description of Grinding Apparatus. *Acta odont. Scand.* 13: 167-179.
- Handelman, S. L. and Hess, C. (1969). Bacterial Population of Selected Tooth Surface Sites. *J. dent. Res.* 48: 67-70.
- Hay, D. I. (1967). The Absorption of Salivary Proteins by Apatite and Enamel. *Archs. oral Biol.* 12: 937-947.
- Hazen, S. P. and Zander, H. A. (1959). Four-Week-Old Calculus. (Abstract). *J. dent. Res.* 38: 710.
- Hodson, J. J. (1949). Tubular Invagination of Enamel Capsule T-Hypoplasia. A New Factor in the Pathology of Human Enamel Caries. *Br. dent. J.* 87: 167-178.

- Hodson, J.J. (1953). The Structure and Histogenesis of Certain Wedge and Other Shaped Defects in the Surface of Human Enamel with a Note on their Relation to the Carious Process. *Br. dent. J.* 49: 141-152.
- Hodson, J.J. (1966a). Origin and Nature of Cuticula dentis. *Nature*. 209: 990-993.
- Hodson, J.J. (1966b). A Critical Review of the Dental Cuticle with Special Reference to Recent Investigation. *Int. dent. J.* 16: 350-384.
- Hudson, J.J. (1967). The Distribution, Structure, Origin and Nature of the Dental Cuticle of Gottlieb. Parts I and II. *J. Am. Soc. Periodont.* 5: 237-302.
- Hofmann, S., McEwan, W.S. and Drew, C.M. (1969). Scanning Electron Microscope Studies of Dental Enamel. *J. dent. Res.* 48: 242-250.
- Houwer, G., and Frank, R.M. (1967). Ultrastructural Significance of Histochemical Reactions on the Enamel Surface of Erupted Human Teeth. *Archs. oral Biol.* 12: 1209-1210.
- Howell, A., Rizzo, A. and Paul, F. (1965). Cultivable Bacteria in Developing and Mature Human Dental Calculus. *Archs. oral Biol.* 10: 307-313.
- Hurst, V., Nuckolls, J. and Conlon, D. (1953). A Simple Technic for the Histologic Preparation of the Organic Matrix of Tooth Enamel. *J. dent. Res.* 32: 432-434.

- Hutchison, J. G. P. (1961). Crystals in Colonies of Staphylococcus Aureus. *J. Path. Bact.* 82: 214-271.
- Huxley, H. G. (1971). The Histology of Rat Molar Fissure Plaque. *Archs. oral Biol.* 16: 1311-1328.
- Huxley, T. H. (1853). On the Development of the Teeth, and on the Nature of Nasmyth's "Persistent Capsule". *Quart. Jl. Micr. Sci.* 1: 149-164.
- Hyatt, T. P. (1923a). A Statistical Study of Locations of Dental Caries Shows the Practical Value of Prophylactic Odontotomy. *Dent. Dig.* 34: 235-243.
- Hyatt, T. P. (1923b). Prophylactic Odontotomy. *Dent. Cosmos* 65: 234-241.
- Hyatt, T. P. (1923c). Some Further Considerations of the Possibilities of Preventive Measures for Prevention of Entrance of Caries into First and Second Permanent Molars Through Occlusal Pits and Fissures. *Dent. Cosmos* 65: 623-626.
- Hyatt, T. P. (1924). Occlusal Fissures, their Frequency and Danger, how Shall They be Treated. *Dent. Items* 66: 493-506.
- Hyatt, T. P. (1925). Prophylactic Odontotomy. *J. dent. Res.* 6: 389-400.
- Hyatt, T. P. (1926). The Conservation of Non Caries First Permanent Molars. *J. Am. dent. Ass.* 13: 655-661.
- Hyatt, T. P. (1930). A Review of Dental Literature on Pits and Fissures. *J. dent. Res.* Vol 10: 659-673.

- Hyatt, T. P. (1936). Prophylactic Odontotomy, the Ideal Procedure in Dentistry for Children. *Dent. Cosmos* 78: 353-360.
- Hyatt, T. P. and Dwyer, H. S. (1931). A New Aspect of Prophylactic Odontotomy. *J. Am. dent. Ass.* 18: 1356-1360.
- Jansen, M. T. (1946). Serial Sections of Undecalcified Enamel. *J. dent. Res.* 25: 355-365.
- Jenkins, G.N. (1965). The Chemistry of Plaque. *Ann. N.Y. Acad. Sci.* 131: 786-794.
- Jenkins, G.N. (1966). The Physiology of the Mouth. Philadelphia: F.A. Davis. 288-357.
- Jones, S. J. (1972). A Special Relationship Between Spherical and Filamentous Micro-organisms in Mature Human Dental Plaque. *Archs. oral Biol.* 17: 613-616.
- Johnson, C.N. (1898). A Few Considerations in Filling Teeth. *Dent. Cosmos* 40: 723-734.
- Kaufman, H.W. and Kleinberg, I. (1973). X-ray Diffraction Examination of Calcium Phosphate in Dental Plaque. *Calc. Tiss. Res.* 11: 97-104.
- Kirk, E. C. (1910). A Consideration for the Question of Susceptibility and Immunity to Dental Caries. *Dent. Cosmos* 52: 729-737.

- Kostlan, J. and Plackova (1962). The Histological Investigation of the Developmental Hypomineralized Areas of the Enamel and their Comparison with the Carious Lesions. *Archs. oral Biol.* 17: 317-326.
- Kramer, I.R.H. and Ramanathan, K. (1966). The Investigation of Deposits on the Surface of Human Enamel by Means of a Fluorescent Anti-body Technique. *Archs. oral Biol.* 11: 1047-1048.
- Kraus, B.S., Jordan, R.E. and Abrams, L. (1969). A Study of the Masticatory System. *Dental Anatomy and Occlusion*. 1st ed. Baltimore: William and Wilkins.
- Kronfeld, R. (1930). The Epithelial Attachment and so called Nasmyth's Membrane. *J. Am. dent. Ass.* 17: 1889-1907.
- Kronfeld, R. (1935). First Permanent Molar its Conditions at Birth and its Post-natal Development. *J. Am. dent. Ass.* 22: 1113-1155.
- Kronfeld, R. (1943). *Dental Histology and Comparative Dental Anatomy*. London: Kimpton. 104.
- Kropp, B.N. (1956). Preparing Single or Serial Sections of Calcified Bones and Teeth. *Stain Tech.* 31: 253-261.
- Kutcher, A., Zegarelli, E.V., Hymann, G.A. and McLean, P. (1967). In: *Pharmacology for the Dental Hygienist*. Philadelphia: Lea and Febiger. 296.

- Leach, S. A. (1963). Release and Breakdown of Sialic Acid from Human Salivary Mucin and its Role in the Formation of Dental Plaque. *Nature* 199: 486-487.
- Leach, S. A. (1964). Some Observations on the State of Sialic Acid in Human Saliva. *Archs. oral Biol.* 9: 461-467.
- Leach, S. A. and Saxton, C. A. (1966). An Electron Microscopic Study of the Acquired Pellicle and Plaque Formed on the Enamel of Human Incisors. *Archs. oral Biol.* 11: 1081-1094.
- Leach, S. A., Critchley, P., Kolendo, A. B. and Saxton, C. A. (1967). Salivary Glycoproteins as Components of the Enamel Integuments. *Caries Res.* 1: 104-111.
- Leeuwenhoek, A. van. In: The Selected Works of Antony van Leeuwenhoek, translated by Samuel Hoole, 1798. London.
- Lefkowitz, W. (1940). A Planning Machine for Plano-parallel Tooth Sections. *J. dent. Res.* 19: 304.
- Lehner, J. and Plenk, H. (1936). Die Zahne. In: von Mollendorf's Handbuch der Mikroskopischen Anatomie des Menschen. Berlin: Springer. Vol. 5 449-708.
- Lenz, H. and Muhlemann, H. R. (1963). In Vivo and In Vitro Effects of Saliva on Etched or Mechanically Marked Enamel after Certain Periods of Time. *Helv. odont. Acta* 7: 30-33.
- Levine, P. T., Glimcher, M. J. and Bonar, L. C. (1964). Collagenous Layer Covering the Crown Enamel of Unerupted Permanent Human Teeth. *Science* 146: 1676-1678.

- Listgarten, M.A. (1966). Phase-Contrast and Electron Microscopic Study of the Junction between Reduced Enamel Epithelium and Enamel in Unerupted Human Teeth. *Archs. oral Biol.* 11: 999-1016.
- Loe, H. (1969). A Review of the Prevention and Control of Plaque. In: *Dental Plaque*. ed. McHugh, W.D., Edinburgh and London: Livingstone. 259-270.
- Loe, H., Theilade, E. and Jensen, S.B. (1965). Experimental Gingivitis in Man. *J. Periodont.* 36: 177-181.
- Loose, F.L. and Hess, W.C. (1949). The Chemical Nature of Proteins from Human Enamel. *J. dent. Res.* 28: 512-517.
- Luna, L.G. (1968). *Manual of Histologic Staining Methods of the Armed Forces Institute of Pathology*. 3rd ed. New York, Toronto: McGraw-Hill.
- Macapanpan, L.C. (1954). Union of the Enamel and Gingival Epithelium. *J. Periodont.* 25: 243-245.
- Magnusson, B. (1968). Tissue Changes during Molar Tooth Eruption. In: *Transactions of the Royal School of Dentistry*. Stockholm and Umea. No. (13).
- Mandel, I.D. (1966). Dental Plaque, Nature, Formation and Effects. *J. Periodont.* 37: 537-567.
- Mandel, I.D., Levy, B.M. and Wasserman, B.H. (1957). Histochemistry of Calculus Formation. *J. Periodont.* 28: 132-137.

- Manly, R.S. (1943). A Structureless Recurrent Deposit on Teeth.
J. dent. Res. 22: 479-486.
- Mannerberg, F. (1960). Appearances of Tooth Surface as
Observed in Shadowed Replicas. Odont. Revy. 11: Supp. 6.
- McCall, J.O. (1934). Lessons to be Learned in a Children's
Dental Clinic. J. Am. dent. Ass. 21: 1869-1883.
- McClung Jones, R. (1950). McClung's Handbook of Microscopical
Techniques. 3rd ed. New York: Hoeber. 302.
- McDougall, W.A. (1963). Studies on Dental Plaque. I. The
Histology of Dental Plaque and its Attachment. Aust. dent. J.
8: 261-273.
- McDougall, W.A. (1963). Studies on Dental Plaque. II. The
Histology of Developing Interproximal Plaque. Aust. dent. J.
8: 389-407.
- McQuillan, J.H. (1871). Microscopical Fissures in the Mastication
Surface of Molars and Bicuspid. Dent. Cosmos 13: 300-302.
- Meckel, A.H. (1965). The Formation and Properties of Organic
Films on Teeth. Archs. oral Biol. 10: 585-597.
- Middleton, J.D. (1964). Methyl Pentose in Human Saliva and
Dental Plaque. Nature 202: 392-393.
- Miller, J. and Hobson, P. (1956). Determination of the Presence
of Caries in Fissures. Br. dent. J. 100: 15-18.
- Miller, W.D. (1883a). Further Contributions on the Subject of Dental
Caries: Caries of Enamel. Indep. Practitioner 4: 301-311.

- Miller, W.D. (1883b). Agency of Micro-organisms in Decay of Human Teeth. *Dent. Cosmos* 25: 1-12.
- Miller, W.D. (1883c). The Agents of Acids in the Production of Caries in Human Teeth, with Comparative Analysis of Carious Dentine and Dentine Softened by Acids. *Dent. Cosmos* 25: 337-344.
- Miller, W.D. (1890). *Micro-organisms of the Human Mouth*. Philadelphia: S.S. White Manufacturing Co.
- Miller, W.D. (1902). The Presence of Bacterial Plaques on the Surface of Teeth, and their Significance. *Dent. Cosmos* 44: 425-446.
- Miller, W.D. (1904). A Study of Certain Questions Relating to the Pathology of the Teeth. *Dent. Cosmos* 46: 981-1001.
- Miller, W.D. (1905a). A Study of Certain Questions Relating to the Pathology of the Teeth. *Dent. Cosmos* 47: 18-39.
- Miller, W.D. (1905b). New Theories Concerning the Decay of Teeth. *Dent. Cosmos* 47: 1293-1301.
- Morse, A. (1945). Formic Acid-Sodium Citrate Decalcification and Butyl Alcohol Dehydration of Teeth and Bones for Sectioning in Paraffin. *J. dent. Res.* 24: 143-153.
- Mortimer, K. V. (1964). Some Histological Features of Fissures Caries in Enamel. *Adv. Fluorin. Res. Dent. Caries Prevent.* edited for ORCA 2: 85-94.

- Muhlemann, H.R. and Schneider, U.K. (1959). Early Calculus Formation. *Helv. odont. Acta* 3: 22-26.
- Nagano, T. (1961). The Form of Pit and Fissure and the Primary Lesion of Caries. *Dent. Abstract.* 6: 426.
- Nasmyth, A. (1839). On the Structure, Physiology, Pathology of Persistent Capsular Investments and Pulp of the Tooth. *Trans. R. med. Chir. Soc.* 22: 310-318.
- Newbrun, E. (1959). A Microradiographic Evaluation of Occlusal Fissures and Grooves. *J. Am. dent. Ass.* 58: 26-30.
- Nikiforuk, G. and Sreebny, L. (1953). Demineralization of Hard Tissue by Organic Chelating Agents at Neutral pH. *J. dent. Res.* 32: 859-867.
- Noyes, F.B. (1921). A Text Book of Dental Histology. 3rd ed. Philadelphia and New York: Lea and Febiger. 120.
- Orban, B. (1944). Oral Histology and Embryology. London: Kimpton. 88.
- Paul, F.T. (1894). Nasmyth's Membrane. *Br. J. dent. Sci.* 37: 1021-1030.
- Paynter, J.K. and Grainger, R.M. (1962). Relationship of Morphology and Size of Teeth to Caries. *Int. dent. J.* 12: 147-160.
- Pearse, A.G.E. (1968). Histochemistry, Theoretical and Applied. 3rd ed. Boston: Little, Brown.

- Pincus, P. (1948). Further Local Factors Affecting Dental Caries. The Shape and Content of Occlusal Grooves. Br. dent. J. 84: 25-28.
- Pindborg, J.J. (1951). Gingivitis in Military Personnel with Special Reference to Ulcero-membrane Gingivitis. Odont. Tidskr. 59: 403-499.
- Prime, J.M. (1937). Inconsistencies in Operative Dentistry. J. Am. dent. Ass. 24: 82-91.
- Quigley, M.B. (1968). Tooth Histology in Art and Science of Dental Caries Research. ed. Harris, R.S. New York and London: Academic Press. 13.
- Rambourg, A., Neutra, M. and Leblond, C.P. (1966). Presence of a "Cell Coat" Rich in Carbohydrates at the Surface of Cells in the Rat. Anat. Rec. 154: 41-72.
- Reid, D.B.W. and Grainger, R.M. (1955). Variation in Caries Susceptibility of Children's Teeth. Hum. Biol. 27: 1-11.
- Ripa, L.W. (1973). Occlusal Sealing: Rationale of the Technique and Historical Review. J. Am. Soc. Prev. Dent. 3: 32-39.
- Ripa, L.W., Gwinnett, A.J. and Buonocore, M.G. (1966). The Prismless Outer Layer of Deciduous and Permanent Enamel. Archs. oral Biol. 11: 41-48.
- Ritz, H.L. (1967). Microbial Population Shifts in Developing Human Dental Plaque. Archs. oral Biol. 12: 1561-1568.

- Rizzo, A. A., Scott, D. B. and Bladen, (1963). Calcification of Oral Bacteria. Ann. N. Y. Acad. Sci. 109: 14-22.
- Roydhouse, R. H. (1968). Prevention of Occlusal Fissure Caries by Use of a Sealant. A Pilot Study. J. dent. Child. 35: 253-261.
- Rushton, M. A. (1954). Aquired Enamel Cuticle. Br. dent. J. 97: 64-66.
- Saxton, C. A. (1971). Scanning Electron Microscope Study of Bacterial Colonization of the Tooth Surface. In: Tooth Enamel II. eds. Fearnhead, R. W. and Stack, M. V. Bristol: John Wright and Sons, Ltd.
- Saxton, C. A. and Kolendo, A. B. (1967). Light and Electron Histochemical Studies of the Degeneration of Salivary Glycoproteins and their Contributions in Plaque Formation. Archs. oral Biol. 12: 1541-1559.
- Schroeder, H. E. (1963). Inorganic Content and Histology of Early Dental Calculus in Man. Helv. odont. Acta 7: 17-30.
- Schroeder, H. E., Lenz, H. and Muhlemann, H. R. (1963). Mineralization Centres in Early Dental Calculus by Light and Electron Microscopy. Helv. odont. Acta 7: 67-75.
- Shafer, W. G., Hine, M. K. and Levy, B. M. (1963). A Text Book of Oral Pathology. 2nd ed. Philadelphia and London: Saunders.

- Sicher, H. and Bhaskar, S. N. (1972). Orban's Oral Histology and Embryology. 7th ed. St. Louis: Mosby. 236.
- Skinner, F. H. (1914). The Prevention of Phorrhea and Dental Caries by Oral Prophylaxis. *Dent. Cosmos* 56: 299-314.
- Smith, W. N., Streckfuss, J. L. and Ennever, J. (1973). A Calcifiable Bacillary Variant Isolated from *Bacterionema Matruchotti* 19, ATcc 14266. *J. dent. Res.* 52: 186.
- Sognaes, R. F. (1947). Preparation of Serial Ground Sections of Whole Teeth and Jaws and Other Highly Calcified and Brittle Structures. *Anat. Record* 99: 133-144.
- Sommer, R. F., Ostrander, F. D. and Crowley, M. C. *Clinical Endodontics, a Manual of Scientific Endodontics.* 3rd ed. Philadelphia and London: Saunders. 490-499.
- Speirs, R. L. (1971). The Nature of Surface Enamel in Human Teeth. *Calc. Tiss. Res.* 8: 1-16.
- Stanmeyer, W. R. (1957). A Measure of Tissue Response to Frequency of Tooth Brushing. *J. Periodont.* 28: 17-22.
- Stephan, R. M. (1938). Hydrogen Ion Concentration of the Dental Plaque. *J. dent. Res.* 17: 251-256.
- Stephan, R. M. (1940). Changes in Hydrogen Ion Concentration on Tooth Surfaces and in Carious Lesions. *J. Am. dent. Ass.* 27: 718-723.
- Stephan, R. M. (1944). Intra-oral Hydrogen Ion Concentrations Associated with Dental Caries Activity. *J. dent. Res.* 23: 257-266.

- Stephan, R.M. (1953). The Dental Plaque in Relation to the Etiology of Caries. *Int. dent. J.* 4: 180-195.
- Stralfors, A. (1950). Investigation into the Bacterial Chemistry of Dental Plaque. *Odont. Tidskr.* 58: 155-341.
- Takazoe, I., Kurahashi, Y. and Takuma, S. (1963). Electron Microscopy of Intercellular Mineralization of Oral Filamentous Microorganisms in Vitro. *J. dent. Res.* 42: 681-685.
- Taylor, C.L. and Gwinnett, A.J. (1973). A study of the Penetration of Sealants into Pits and Fissures. *J. Am. dent. Ass.* In press.
- Theilade, J. (1964). Electron Microscopic Study of Calculus Attachment to Smooth Surfaces. *Acta odont. Scand.* 22: 379-387.
- Theilade, J., Wright, W.H., Jensen, S.B. and Loe, H. (1966). Experimental Gingivitis in Man. *J. Periodont. Res.* 1: 1-13.
- Thoma, K.H. and Robinson, H.B.G. (1960). Oral and Dental Diagnosis. 5th ed. Philadelphia and London: Saunders. 218.
- Tiecke, R.W. (1965). Oral Pathology. 1st ed. New York: McGraw-Hill. 237.
- Truman, J. (1870). Fissures. *Dent. Cosmos* 12: 1-5

- Turesky, S., Renstrup, G. and Glickman, I. (1961). Histologic and Histochemical Observations Regarding Early Calculus Formation in Children and Adults. *J. Periodont.* 32: 7-14.
- Turner, E. P. (1958). The Integument of the Enamel Surface of the Human Tooth. *Dent. Practit.* 8: 341-348 & 373-382.
- Ussing, M. J. (1955). Development of the Epithelial Attachment. *Acta odont. Scand.* 13: 123-154.
- Ussing, M., Scott, D. B., Kaplan, H. (1951). Microstructure of the Enamel Cuticle and Epithelial Attachment. *J. dent. Res.* 30: 478-479.
- Vallotton, C. F. (1945). An Acquired Pigmented Pellicle of the Enamel Surface. *J. dent. Res.* 24: 161-187.
- von Korf, K. (1930). Die Zusammensetzung und Entstehung der Sogenannten Nasmyth'schen Membrane und der Cuticular Dentis trinitivu. *J. Dtsch. Mschz. Zahnheilk.* 11: 817-830.
- Voreadis, E. G. and Zander, H. A. (1958). Cuticular Calculus Attachment. *Oral Surg.* 11: 1120-1125.
- Walsh, J. P. and Smart, R. S. (1948). The Relative Susceptibility of Tooth Surfaces to Dental Caries and other Comparative Studies. *N. Z. dent. J.* 44: 17-35.
- Wasserman, B. H., Mandel, I. D., and Levy, B. M. (1958). In Vitro Calcification of Dental Calculus. *J. Periodont.* 29: 144-147.

- Watters, W.B. and Buck, R.C. (1971). An Improved Simple Method of Specimen Preparation for Replicas or Scanning Electron Microscopy. *J. Microsc.* 94: 185-187.
- Wertheimer, F.W. and Fullmer, H.M. (1962). Morphologic and Histochemical Observations on the Human Dental Cuticle. *J. Periodont.* 33: 29-39.
- Williams, J.L. (1897). A Contribution to the Study of Pathology of Enamel. *Dent. Cosmos* 39: 169-196, 269-301 & 353-374.
- Williams, J.L. (1898). On Structural Changes in Human Enamel with Special Reference to Clinical Observations on Hard and Soft Enamel. *Dent. Cosmos* 40: 505-537.
- Williams, J.L. (1899). A Contribution to the Bacteriology of the Human Mouth. *Dent. Cosmos* 41: 317-349.
- Winkler, W.C., and Backer-Dirks, O. (1958). Mechanism of Dental Plaque. *Int. dent. J.* 8: 561-585.
- Zaki, H.A. and Stallard, R.E. (1969). An Evaluation of the Effectiveness of Preventive Periodontal Education. *J. Periodont. Res. Suppl.* 3.
- Zander, H.A., Hazen, S.P. and Scott, D.B. (1960). Mineralization of Dental Calculus. *Proc. Soc. Exp. Med.* 103: 257-260.