

Western  Graduate&PostdoctoralStudies

Western University
Scholarship@Western

Electronic Thesis and Dissertation Repository

August 2012

Identifying Gait Abnormalities in Patients with Femoroacetabular Impingement Syndrome

Brook A. Russell
Western University

Supervisor

Dr. Dianne Bryant

The University of Western Ontario Joint Supervisor

Dr. Kevin Willits

The University of Western Ontario

Graduate Program in Kinesiology

A thesis submitted in partial fulfillment of the requirements for the degree in Master of Science

© Brook A. Russell 2012

Follow this and additional works at: <https://ir.lib.uwo.ca/etd>



Part of the [Sports Sciences Commons](#)

Recommended Citation

Russell, Brook A., "Identifying Gait Abnormalities in Patients with Femoroacetabular Impingement Syndrome" (2012). *Electronic Thesis and Dissertation Repository*. 657.

<https://ir.lib.uwo.ca/etd/657>

This Dissertation/Thesis is brought to you for free and open access by Scholarship@Western. It has been accepted for inclusion in Electronic Thesis and Dissertation Repository by an authorized administrator of Scholarship@Western. For more information, please contact wlsadmin@uwo.ca.

IDENTIFYING GAIT ABNORMALITIES IN PATIENTS WITH
FEMOROACETABULAR IMPINGEMENT SYNDROME

(Spine title: Gait Abnormalities in FAI Patients)

(Thesis format: Monograph)

by

Brook A. Russell

Graduate Program in Kinesiology

A thesis submitted in partial fulfillment
of the requirements for the degree of
Master of Science

School of Graduate and Postdoctoral Studies
The University of Western Ontario
London, Ontario, Canada

© Brook A. Russell 2012

THE UNIVERSITY OF WESTERN ONTARIO
School of Graduate and Postdoctoral Studies

CERTIFICATE OF EXAMINATION

Supervisor

Examiners

Dr. Dianne Bryant

Dr. Doug Naudie

Joint Supervisor

Dr. Trevor Birmingham

Dr. Kevin Willits

Greg Alcock

The thesis by

Brook AlexaRussell

entitled:

**Identifying Gait Abnormalities in Patients with Femoroacetabular
Impingement Syndrome**

is accepted in partial fulfillment of the
requirements for the degree of
Master of Science

Date

Chair of the Thesis Examination Board

Abstract

OBJECTIVE: To determine the biomechanical gait characteristics and quality of life of adults with femoroacetabular impingement (FAI) and how their gait compares to the gait of healthy controls. METHODS: Gait analyses were performed on 18 participants (9 FAI, 9 control) while walking barefoot in the Wolf Orthopaedic Biomechanics Lab. In addition, FAI participants completed general and region specific quality of life questionnaires. RESULTS: Hip moment (5.2%BW*ht vs. 4.96%BW*ht), toe out angle (12.36° vs. 8.15°), and lateral (3.55° vs. 2.18°) and forward (4.34° vs. 3.93°) pelvic tilt were not statistically different between groups. Trunk lean (1.33° vs. 0.36°), hip flexion angle (25.74° vs. 24.23°), & hip power (1.22W vs. 0.61W; p-value=0.32) were greater in the control group. CONCLUSION: The small sample size of this study does not allow the authors to make conclusions on the abnormalities in gait biomechanics in FAI patients. Further research with larger sample sizes is warranted.

Keywords: femoroacetabular impingement, gait, hip, biomechanics, quality of life, adduction moment

Co-Authorship Statement

With the assistance of Dr. Dianne Bryant and Dr. Kevin Willits, we designed a prospective cohort study, in which I was responsible for patient recruitment and conducting the gait analysis and ensuring completion of the questionnaires that we collected. I was responsible for data collection, with the help of Ian Jones of the Wolf Orthopaedic Biomechanics Lab, and data analysis. I wrote the original draft of the thesis, including interpretation of the statistical results (with the assistance of Dr. Bryant). The drafts were sent to Dr. Bryant and Dr. Willits for their comments and suggestions for critical revision of the paper.

Acknowledgements

The completion of this project would not have been possible without the tremendous support and assistance I received from so many people along the way.

I would like to thank Dr. Dianne Bryant for her guidance and support throughout my graduate studies. Her expertise in research methods, statistics, and writing was very helpful, and I am sure what I have learned under her supervision will be useful to me not only in the completion of this project, but in my future endeavors.

I would like to thank Dr. Kevin Willits for his supervision and assistance in executing the recruitment of patients for this study, as well as his clinical input in the design and writing of my thesis.

I would like to thank Kathy, Marsha, and Anne as well as the many residents and fellows that were part of the orthopedic department throughout my study who were always willing to answer my questions and help in any way possible.

I would like to thank Ian Jones for all his help in the WOBL in executing data collection as well as post-processing and trouble-shooting. He was an invaluable resource in my journey of learning the way motion-capture works and the useful information we receive from it. His positive, open attitude brightened my days and I am sure that without his assistance I would have not been able to complete this project.

I would like to thank all the other students at the WOBL as well as in the sports medicine program for their support and assistance throughout the project.

I would like to especially thank my parents and brother for their never-ending support as well as my friends for always making sure I never gave up (A.J, B.J, N.S, M.E, K.C).

Table of Contents

CERTIFICATE OF EXAMINATION	ii
Abstract	iii
Co-Authorship Statement	iv
Acknowledgments	v
Table of Contents	vi
List of Tables	viii
List of Figures	ix
List of Appendices	x
Chapter 1	1
1 Introduction	1
Chapter 2	5
2 Literature Review	5
2.1 Introduction	5
2.2 Anatomy of the hip	6
2.3 Etiology and Prevalence	9
2.4 Pathomechanics	11
2.5 Diagnosis	13
2.6 Treatment Options	17
Non-Surgical	17
Surgical	18
2.7 Gait and FAI: Current Research	22
Chapter 3	26
3 Objectives	26
Chapter 4	27
4 Methods	27
4.1 Study design	27
4.2 Eligibility criteria	27
4.3 Subject recruitment	27
4.4 Procedure	28

4.41 Gait Analysis	28
4.42 Marker Placement	29
4.5 Data Reduction.....	29
4.6 Sample Size.....	30
4.7 Outcome Measures.....	30
4.71 Quality of Life.....	31
4.72 Activities and Participation	31
4.73 Pain.....	32
4.8 Follow-up.....	33
Chapter 5.....	34
5 Statistical Analysis	34
Chapter 6.....	35
6 Results	35
Chapter 7.....	41
7 Discussion	41
7.2 Limitations	45
7.3 Strengths.....	46
7.4 Summary	47
References	48
Appendices	64
Curriculum Vitae	72

List of Tables

Table 1: Demographic Data on Study Participants 36

Table 2: Unadjusted Biomechanical Outcomes 38

Table 3: Adjusted Biomechanical Outcomes 39

List of Figures

Figure 1: Anatomy of the hip..... 7

Figure 2: Normal, CAM, and Pincer Movement of the hip joint 12

Figure 3: Clinical tests for Femoroacetabular Impingement 15

Figure 4: Alpha angle as seen on Radiograph 17

Figure 5: Flow diagram of Patient Screening 35

List of Appendices

Appendix A: Letter of Information and Consent 64

Appendix B: Ethics Approval Notice 69

Appendix C: Permission Letter - Nucleus 70

Appendix D: Permission Letter – American Journal of Roentgenology 71

CHAPTER 1: Introduction

Femoroacetabular impingement (FAI) is a common cause of hip pain in young, active adults (Samora et al., 2011; Wisniewski & Grogg, 2006). Although once a mysterious precursor to osteoarthritis, (Beck et al., 2005; Ganz et al., 2003; Wagner et al., 2003) FAI is gaining attention in the medical and research fields as a chronic pathology, and becoming a more frequent and well understood diagnosis. FAI causes abnormal abutment between the femoral head and the acetabular socket (Myers et al., 1999). Accumulation and ossification of bone at the site of contact progressively increases the severity of FAI due to wear over time (Ganz et al., 2003).

Its etiology may be attributed to many factors including developmental issues and environmental factors, although many FAI patients have no history of hip disease (Samora et al., 2011). Many developmental conditions that may predispose individuals to FAI include slipped capital femoral epiphysis (Leunig et al., 2000), asphericity of the femoral head, reduced femoral head-neck offset (Notzli et al., 2002), residual childhood diseases such as Perthes (Kim & Novais, 2011), and mal-oriented or deformed acetabulum, including coxaprofunda and protrusioacetabuli (Siebenrock et al., 2003). Inadequate reduction of femoral neck fractures may also be a contributing factor to the development of FAI in some individuals (Eijer et al., 2001). These morphological conditions have all been associated with impingement, as has subjection of the anatomically normal hip to excessive and supraphysiological range of motion, especially in internal rotation and adduction (Ganz et al., 2003)

Two forms of FAI have been defined; cam impingement and pincer impingement. Cam impingement is described as a femoral abnormality, such as an aspherical head,

lesion, or bump on the head or at the head-neck junction of the femur (Ganz et al., 2003). A decreased offset of the femoral head-neck junction, defined as the difference between the widest diameter of the femoral head and the most prominent part of the femoral neck, is another sign of cam impingement and can be assessed on MRI or radiographs (Pfirrmann et al., 2006).

These abnormalities result in impingement on the acetabular labrum and articular cartilage, due to a reduced clearance distance between the femoral head-neck junction and the anterior acetabular margin when the hip is in flexion and internal rotation (Reid et al., 2010). Shear forces, which are consistently applied to the cartilage, are created by the jamming of the aspherical femoral head into the acetabulum, and may lead to its avulsion from the underlying labrum and subchondral bone. Cam impingement is most commonly seen in young, active male hips (Ganz et al., 2003; Hack et al., 2010; Lavigne et al., 2004).

Pincer type impingement is the type of FAI associated with acetabular abnormalities. It is characterized by general or local over-coverage of the acetabulum on the femoral head and neck (Ganz et al., 2003). At terminal range of motion, the femoral neck is limited by the relatively deep socket. The femoral neck therefore perpetually contacts the acetabulum during daily range of motion. Labral lesions and degeneration occur primarily, prior to articular cartilage damage, due to the impact of the femoral neck (Beck et al., 2004; Beck et al., 2005). Cleavage tears in the labrum and paralabral cysts can result from pincer FAI, as well as damaged articular cartilage behind the labrum, which may worsen the problem when it tries to heal to the bone and ossifies, furthering the over-coverage (Seldes et al., 2001). Although defined separately, more often than not patients present with both forms of impingement simultaneously. Beck and colleagues analyzed

302 hips in 2005, finding that 26 had isolated cam impingement and 16 had isolated pincer impingement, leaving the remaining 260 patients, or 86% of all patients, diagnosed with mixed impingement (Beck et al., 2005). Hong et al., also found mixed impingement to be present in the majority of their study patients (Hong et al., 2010).

Natural hip joint biomechanics and especially range of motion (ROM) have been shown to be negatively affected and/or limited in FAI patients (Clohisy et al., 2007; Ito et al., 2004; Lamontagne et al., 2009; Philippon et al., 2007). This can become a limiting factor in these individuals' ability to perform repetitive, daily activities such as walking, squatting, running, using stairs, and even moving from sitting to standing positions. Decreased ability to perform daily activities and movements due to limited hip mobility can be detrimental to an individual's quality of life.

Since 2009, several studies have investigated the effects of FAI on different aspects of daily living in affected individuals. Since walking is the most common repetitive activity executed by humans (Winter, 1983), it has been the focus of a few studies which seek to investigate the effects of FAI by comparing gait kinematics and kinetics of FAI patients to healthy control subjects. Kennedy et al. compared a group of 17 patients with unilateral cam FAI to a control group of 14 control participants matched for age, sex and body mass index (Kennedy et al., 2009). The FAI group was found to have smaller peak hip abduction angles as well as reduced hip and pelvic frontal plane ROM during level gait compared to the control group. No differences in gait kinetics were noted between the two groups.

Rylander et al. (2011) also studied hip kinematics in 11 FAI patients during level walking both preoperatively and 1 year postoperatively. The authors hypothesized that

post-surgery, the gait of FAI patients would be significantly closer to the normal range and pattern of hip flexion compared to their own pre-surgery gait. The study results showed decrease in pain levels and increase in activity (4.1 ± 1.7 to 6.1 ± 1.9) based on the Tegner activity scale. There were significant increases in sagittal plane hip range of motion ($27.6^\circ \pm 5^\circ$ to $30.7^\circ \pm 4.3^\circ$), maximum hip flexion on the operated hip (19.9° to 22.7°), and overall hip motion pattern was returned to normal post-surgery with fewer reversals being observed. There were no significant differences in hip flexion/extension moments, adduction/abduction angles or moments, or walking speed (Rylander et al., 2011).

A recently published article also compared ten pre-surgery and post-surgery FAI patients to each other and to a control group ($n=13$) while level walking (Brisson, 2011). They found that the FAI group had a lower frontal plane ROM, and smaller peak hip abduction and external rotation moments than the control group. Contrary to their hypothesis, they concluded that patients with FAI who underwent corrective surgery did not return to normal hip biomechanics as seen in the control group.

The biomechanical gait outcomes we chose to analyze were chosen as they may be affected by FAI. Hip adduction moment in particular gives us an idea of the load on the proximal femur and may indicate gait differences between the control and FAI patients, due to joint morphology or adopted pain avoidance gait techniques. Previous studies on hip and pelvis kinematics and kinetics during gait have been small in size. We wanted to expand the literature by studying a larger sample of FAI patients. The purpose of the current study is to determine the biomechanical gait characteristics associated with FAI, how these characteristic values compare to a control group of healthy normal subjects, and how this disorder affects FAI patients' quality of life.

CHAPTER 2: Literature Review

2.1 Introduction

Femoroacetabular impingement (FAI) is a pathologic condition in which there is an abnormal morphology at the hip joint. This leads to atypical contact between the femoral head and the rim of the acetabulum, especially during movements at the hip's end range of motion (ROM) (Ganz et al., 2003).

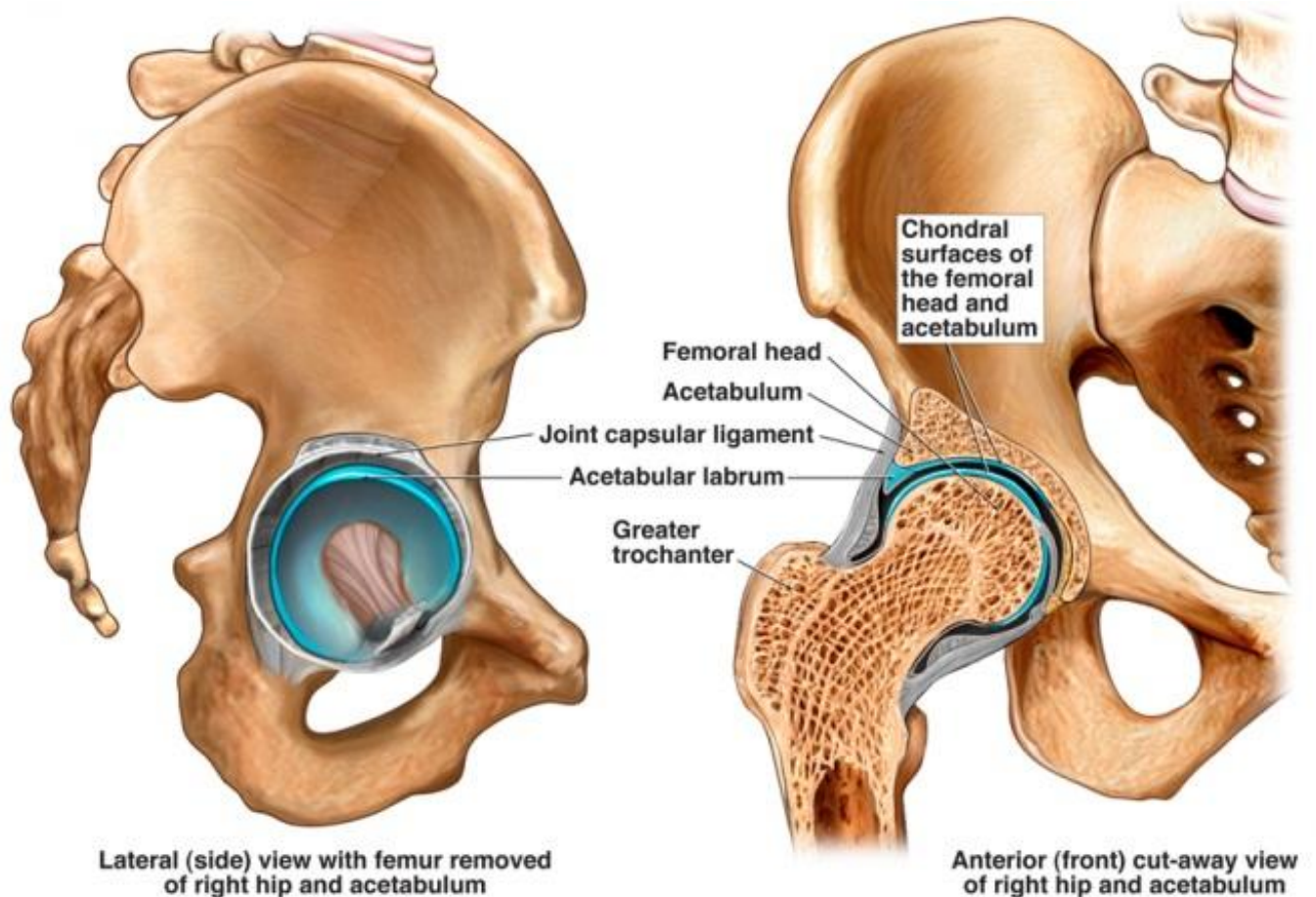
Murray first reported the theory of impingement in 1965 (Murray, 1965). Stulberg's report in 1974 was the first to expand upon this theory and describe the condition presently referred to as FAI, by noting a decreased head-neck offset in FAI patients (Stulberg & Harris, 1974). The head-neck offset describes the difference between the widest diameter of the femoral head and the most prominent part of the femoral neck. He termed this the "pistol grip deformity," as the head and neck of the femur takes on the shape of a pistol grip when viewed on radiographs due to the prominent acetabulum and abnormal femoral-acetabular contact. He noticed that this subset of people developed early osteoarthritis of the hip. In 1986, Harris et al. (Harris, 1986) reviewed 75 OA patients and presented that 80% had a subtle femoral or acetabular abnormality. These studies were the first to recognize FAI, which has been described in greater detail since the 1990s.

Two forms of FAI can be differentiated based on the presence of either a femoral or acetabular abnormality. Cam impingement is characterized by asphericity of the femoral head at the anterosuperior aspect of the head-neck junction caused by an osseous prominence (Ganz et al., 2003; Lavigne et al., 2004). During hip flexion, the femoral head produces shear forces and compresses upon the cartilage. The labrum and cartilage are pushed in opposing directions, which often results in a tear on the undersurface of the

acetabular labrum (Beck et al., 2005). Pincer impingement is characterized by acetabular deformities as a result of an acetabular socket that is too deep for the femoral head or over-coverage of the femoral head by the acetabulum (Ganz et al., 2003; Beck et al., 2005). This limits the ROM available before the femoral head contacts the outer margins of the acetabulum. The first structure to be damaged with this abnormal morphology is the acetabular labrum (Jaberi & Parvizi, 2007). Because of this contact occurring at a smaller ROM than a healthy hip, the labrum can be compressed between the subchondral bone and femoral neck in FAI patients. It must be noted that in some patients, abnormalities of both the femur and acetabulum are present, resulting in what is known as mixed impingement (Beck et al., 2005; Macfarlane & Haddad, 2010).

2.2 Anatomy of the Hip

The hip is a complex anatomical structure which is vital to normal human movement. Many anatomical structures contribute to the stability and mobility of this joint. The pelvis and femur are the bones that articulate to create the hip joint. The head of the femur fits into the acetabulum, which is a crescent moon shaped socket at the union of the pubis, ilium, and ischium bones that fuse to create the pelvis. The acetabulum is lined with a cartilaginous ring called the labrum, which functions in deepening the socket, therefore making it more difficult for the femur to sublux. The labrum also acts as a suction seal, as well as a cushion, distributing contact forces to the cartilage evenly over the hip joint.



Medical Illustration Copyright © 2012 Nucleus Medical Media, All rights reserved. www.nucleusinc.com

Figure 1 The anatomy of the hip, specifically those structures affected by femoroacetabular impingement.

Muscles and ligaments are structurally essential in stabilizing the hip to allow optimal functioning of the joint. The fibrous joint capsule and ligaments act as a tight sleeve around the joint. Four extra-capsular ligaments, the ischiofemoral, iliofemoral, pubofemoral, and annular ligaments, as well as one intra-capsular ligament, the ligamentum teres, all contribute to the stability of the hip joint (Philippon & Schenker, 2005).

Muscles play a large role in the stability, strength, and function of the hip. They act in three planes, allowing three degrees of freedom in the hip joint, and three main directions of motion: flexion and extension about the transverse axis, adduction and abduction about

the sagittal axis, and external and internal rotation about the frontal axis (Friend & Kelly, 2009).

Anteriorly, the joint is reinforced by the iliopsoas, a combination of the iliacus and psoas muscles which act as primary hip flexors. Tensor fascia lata (TFL), pectineus, adductor longus, and adductor brevis are also hip flexors. Hip adductors include adductor brevis, adductor longus, adductor magnus, and gracilis. The hip abductor muscle group stabilizes the posterior aspect of the joint, and includes the gluteus medius, gluteus minimus, and TFL. Piriformis and obturatorinternus assist those larger muscles in hip abduction. These muscles play a significant role in pelvic stabilization during gait, by contracting to maintain the level of the contralateral pelvis during single leg stance (Gray, 1858). The hamstrings, made up of semimembranosus, semitendinosus, and the long head of biceps femoris, function in extending the hip with the help of gluteus maximus and the posterior portion of adductor magnus. Gluteus maximus also works in stabilizing the pelvis during the single leg stance phase of gait and single leg balancing. External rotation of the hip is generated by force from the piriformis, obturatorinternus and externus, superior and inferior gemellus, gluteus maximus and medius, and quadratusfemoris all working together. Internal rotation is powered by the gluteus medius and minimus, TFL, pectineus, and adductor magnus.

Muscle strength may play a role in the symptoms suffered by, and gait patterns of FAI patients. Muscle maximum voluntary contraction (MVC) has shown to be significantly weaker in FAI patients when compared to matched controls (Casartelli et al., 2011). MVC strength for hip adduction, flexion, abduction, and external rotation as well as tensor fascia latae electromyography (EMG) activity were all significantly lower in the FAI

group than the control group. This information may lead surgeons and physiotherapists to further explore the role muscle strength plays in controlling the symptoms FAI patients suffer.

Blood supply to the femoral head is provided by the medial femoral circumflex artery, which must be carefully handled and preserved during open surgical treatment of FAI to prevent avascular necrosis (Crawford & Villar, 2005). Blood flow to the rest of the muscles of this area is supplied by the femoral and deep femoral arteries.

The muscles that surround and move the hip joint are abundant, as are their innervations. Several nerves innervate these muscles including the femoral nerve, obturator nerve, gluteal nerve (superior and inferior), sciatic nerve, nerve to piriformis, nerve to obturatorinternus, nerve to superior gemellus, and the lumbar plexis of nerves.

2.3 Etiology and Prevalence

The etiology of FAI has not been identified. Disease presence may be attributed to many causes including developmental and environmental factors, although many FAI patients have no history of hip disease (Samora et al., 2011). Several developmental conditions that may predispose individuals to FAI include slipped capital femoral epiphysis (Leunig et al., 2000), asphericity of the femoral head, reduced femoral head-neck offset (Notzli et al., 2002), Perthe's disease (Kim & Novais, 2011), and mal-oriented or deformed acetabulum, including coxaprofunda and protrusion acetabuli (Siebenrock et al., 2003). Inadequate reduction of femoral neck fractures may be a contributing factor to the development of FAI in some individuals as well (Eijer et al., 2001). These morphological conditions have all been associated with impingement, as has subjection of the

anatomically normal hip to excessive and supra-physiological range of motion, especially in internal rotation and adduction (Ganz et al., 2003).

FAI is becoming a more common diagnosis in symptomatic hip patients, but is also prevalent in the asymptomatic population. Reichenbach et al. examined 244 young, asymptomatic Swiss males and found a prevalence of definite cam deformity in 24% of those examined (Reichenbach et al., 2010). When stratifying for maximal internal rotation, the prevalence of cam deformity increased to almost 50% in those individuals that had $<30^\circ$ internal rotation (40 of 83 patients) (Reichenbach et al., 2010).

Another study of the radiographic prevalence of FAI in 157 young patients (age range 18-50) with hip complaints showed that 87% of radiographs analyzed showed at least one positive sign of FAI (Ochoa et al., 2010). Signs characteristic of FAI that were observed included herniation pits, pistol grip deformity, abnormal center-edge angle ($>39^\circ$), abnormal alpha angle ($>50^\circ$), and crossover sign. Sixty-five percent with full radiographic review had combined impingement as indicated by abnormal alpha angles or pistol grip deformity combined with abnormal center-edge angles and/or crossover signs (Ochoa et al., 2010).

Hack et al. studied the magnetic resonance images (MRIs) of 200 asymptomatic participants for abnormal alpha angles ($>50.5^\circ$) as well as a positive impingement test on physical examination (Hack et al., 2010). They found 14% of participants had a cam morphology, 79% (22) of which were male. Cam FAI was shown to be most prevalent in males and those with decreased internal rotation in the asymptomatic population. This is consistent with findings from Gosvig et al. after their study of 3203 randomly selected anteroposterior (AP) radiographs (Gosvig et al., 2008). They determined the prevalence of

cam FAI to be 17% in males and 4% in females. Others estimate the prevalence of FAI to be 10-15% (Leunig & Ganz, 2005).

The prevalence of FAI has also been studied in athletes, with the hypothesis that it may be greater in this population than in the general population due to the increased loads on the hip that occur during sport (Kapron et al., 2011). Kapron et al. evaluated the hips of 67 male collegiate football players and measured radiographic signs of impingement such as alpha angle, femoral head-neck offset, lateral centre-edge angle, acetabular index, and crossover sign. Of the 134 hips studied, they found 95% to show at least one sign of cam or pincer impingement and 77% had two signs. In particular, 72% had an abnormal alpha angle, 64% had a decreased femoral head-neck offset, 61% had a positive crossover sign, and 7% had an increased lateral centre-edge angle. They concluded that abnormalities consistent with FAI were common in these athletes and much more prevalent than those values reported for the general population (Kapron et al., 2011).

2.4 Pathomechanics

Cam type FAI produces repetitive jamming of the femoral head-neck junction into the acetabulum creating a site of impingement. This recurrent microtrauma can cause osteophyte formation at the site of impingement, accumulating more bone volume and furthering the severity of the bony bump or “cam lesion” (Ganz et al., 2003). The impinging femurs tend to have wider necks, larger heads, and decreased head-neck ratios when compared to femurs with no impingement occurring (Ellis et al., 2011). Repetitive compression and shear forces between the labrum and cartilage progressively damage the anterosuperior portion of the acetabulum, and may lead to labral tears or detachment (Beck et al., 2005; Eijer et al., 2001; Ganz et al., 2003; Lavigne et al., 2004). Pain and subsequent

damage to the labrum and cartilage may result from frequent sport participation or physical activity, especially those involving hip flexion, adduction, and internal rotation, as these motions cause the abutment of the femur and acetabulum at the site of impingement (Philippon & Schenker, 2006). Labral lesions caused by impingement have been found to be most common in the anterosuperior region of the acetabulum (Guanche & Bare, 2006; Leunig et al., 2003; Tannast, Goricki et al., 2008).

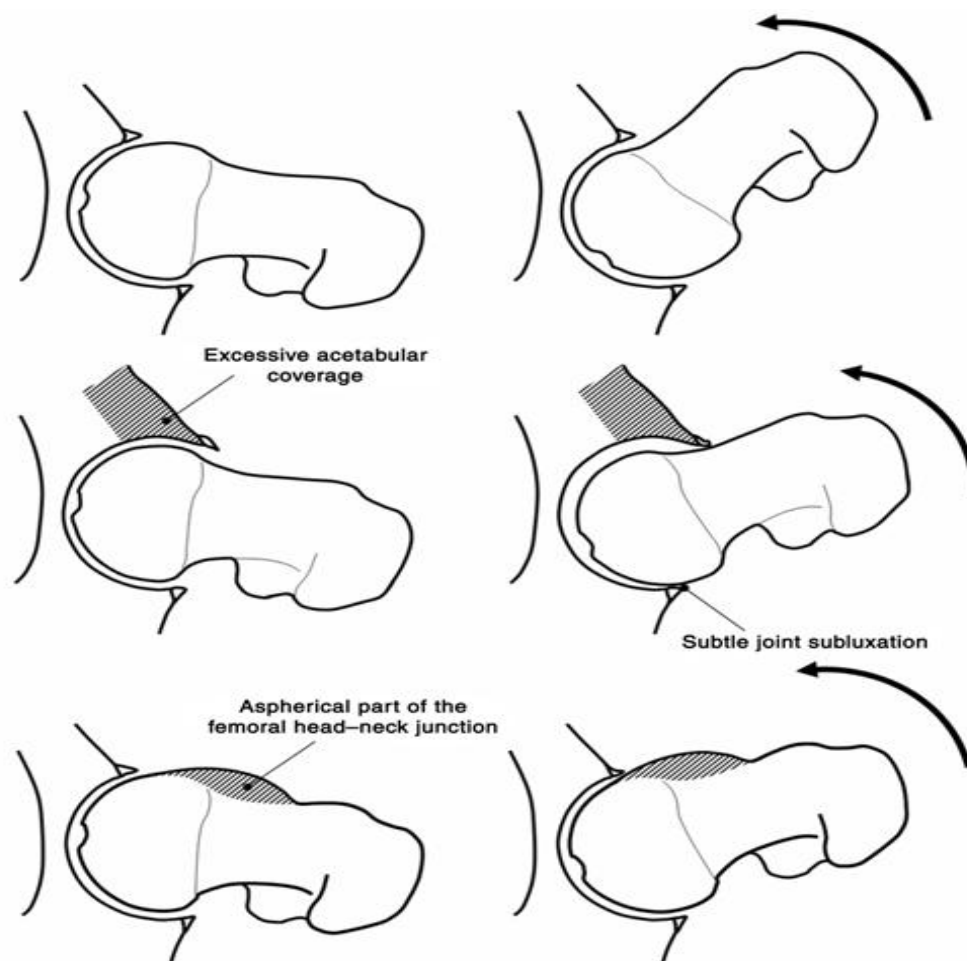


Figure 2 The top image illustrates a normal hip joint with adequate range of motion and joint clearance. In pincer impingement (center image), excessive acetabular over-coverage of the femoral head leads to early contact between the head-neck junction and acetabular rim, which results in labral and cartilage damage, as well as damage to the posteroinferior portion of the joint due to subtle subluxations. In cam impingement (bottom image), the aspherical femoral head-neck junction makes frequent abnormal contact with the superior acetabular rim [Reprinted with permission].

Ganz et al. studied over 600 arthritic hips and concluded that FAI was a mechanism for the development of early osteoarthritis (OA) for most non-dysplastic hips (Ganz et al., 2003). Other research has had similar findings (Beck et al., 2005; Friend & Kelly, 2009; Ganz et al., 2008; Tannast et al., 2008; Tanzer & Noiseux, 2004).

2.5 Diagnosis

A diagnosis of FAI is based on patient history, clinical examination, and confirmed with support from radiographs and MRIs. Patients usually present with no memory of an acute hip injury, but suffer from chronic pain, progressing to more constant and intense pain which may be felt in the groin and possibly the knee, greater trochanter, or buttocks (Ito et al., 2001) during daily living and exacerbated with physical activity and prolonged sitting (Reid et al., 2010). Patients may describe trochanteric pain using the c-sign, wherein they place their thumb and index finger over the area (Dooley, 2008). Clicking or grinding in the hip joint and pain with prolonged hip flexion are also characteristic of FAI. In addition to pain on flexion, it has been observed that hip flexion ROM as well as internal rotation in FAI patients is reduced (Clohisy et al., 2009; Kubiak-Langer et al., 2007; Murphy et al., 2004) due to the abnormal anatomy of the joint, and a reactive attempt to cease the pain caused by their unnatural abutment of the femur and acetabulum.

A thorough physical exam of a patient with hip pain should be undertaken to determine an accurate diagnosis of FAI. Range of motion and observing the patient's gait can be very helpful in addition to specialized physical exams to assist the surgeon in making a diagnosis. The anterior impingement test, the flexion, adduction, and internal rotation test (FADIR), involves positioning the patient supine with the affected hip and knee flexed to 90°, flexed, and then adducted and internally rotated (Leunig et al., 2005). A

positive test occurs when a sudden pain can be felt in the hip or groin as this test mimics the pain the patient feels due to shear and compression forces against the labrum (Dooley, 2008). This test has proven to be positive in 90% of patients later confirmed with the diagnosis of FAI, either through imaging or at the time of surgery (Ito et al., 2004; Murphy et al., 2004). In one study, 99% of 301 FAI patients had a positive anterior impingement test (Philippon et al., 2007).

The posterior impingement test is carried out by placing the hip in extension and external rotation and again, is positive if symptoms are reproduced (Leunig et al., 2005). The flexion, abduction, and external rotation test (FABER), is performed while the patient is supine, the examiner flexes the hip and knee to 90° while passively forcing the hip into adduction and internal rotation with the foot of the affected hip on the opposite knee. A positive test, or pain, is not specific to FAI however lateral hip pain has been a complaint in many FAI patients during this test (Philippon & Schenker, 2006). In addition to pain, a positive FABER test shows an increased vertical distance between the lateral knee and the table in FAI patients in comparison to the contralateral or unaffected hip (Philippon & Schenker, 2006). The Drehmann's sign, originally seen in patients with slipped capital femoral epiphysis, is positive if there is an unavoidable passive external rotation of the hip while in hip flexion, and has shown to be indicative of FAI (Kamegaya et al., 2011).

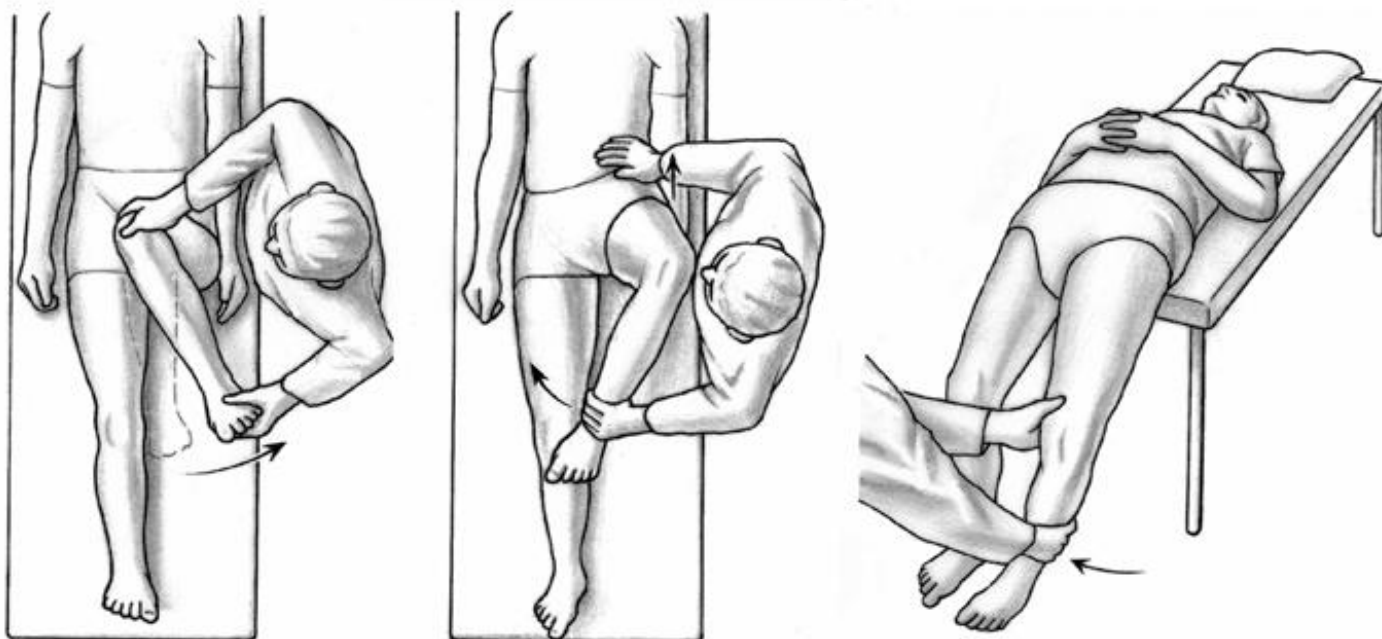


Figure 3 Clinical assessments for FAI. The anterior impingement test (left) is positive if painful upon forced internal rotation in 90° of flexion. Unavoidable, passive external rotation of the hip during flexion, known as the Drehmann sign, is characteristic of many FAI patients (center). The posterior impingement test (right) places the hip in maximum extension, and is positive if forced external rotation elicits pain.[Reprinted with permission]

Imaging plays a vital role in identifying FAI. Anteroposterior and cross-table lateral plain film views are routinely ordered when FAI is suspected. These may show a “pistol grip deformity” or flattening of the femoral head-neck junction which is a sign for CAM impingement (Beall et al., 2005). Any femoral head abnormality such as ossifications and lesions, or insufficient concavity may be seen on x-rays and may indicate impingement (Notzli et al., 2002). Pincer lesions may be detected on anteroposterior radiographs by looking for crossover or posterior wall signs for acetabular retroversion, coxaprofunda, and protrusion acetabuli (Philippon & Schenker, 2006). The crossover sign is seen when the anterior acetabular wall is positioned laterally to the posterior wall at the

proximal acetabulum (Reynolds et al., 1999). The posterior wall sign can be seen when the posterior acetabular wall is medial to the centre of the femoral head (Reynolds et al., 1999). Coxaprofunda exists when the acetabular fossa's floor abuts or overlaps the ilioischial line, and protrusion acetabuli is seen when the femoral head overlaps the ilioischial line medially (Beck et al., 2005). Synovial herniation pits, which are areas of decreased bone density with non-defined borders located in the anterosuperior portion of the femoral neck, are another finding that has been associated with FAI (Ganz et al., 2003). Frog lateral plain radiographs have been ruled not reliable in measuring the alpha angle in FAI patients therefore should not be used to diagnose this disorder (Konan et al., 2010).

Magnetic resonance (MR) arthrography enhanced with gadolinium is ordered in addition to the radiographs to assess the labrum and articular cartilage and confirm some diagnostic measurements. It has been reported that labral tears are commonly found in patients with FAI (Ito et al., 2004). Some measurements are also taken through the MR arthrogram. The alpha angle is a measurement of the degree of asphericity and cam impingement at the anterior portion of the head-neck junction and can be seen on radiographic films (oblique axial view) or MRI/MR arthrography. To calculate this angle, a circle of best fit is placed over the femoral head and a line is drawn from the center of the circle to the head-neck junction outside of the circle. Another line is drawn from the center of the circle to the middle of the femoral neck, and the angle between these two drawn lines is measured and referred to as the alpha angle (Beaule et al., 2005). Alpha angles above 55° are considered to be above the normal range and are associated with FAI (Notzli et al., 2002). A recent study has found that a classic triad of MR arthrography findings, including anterosuperior labral tear, anterosuperior cartilage defect, and abnormal alpha

angle, is present in 88% of patients with cam impingement (Kassarjian et al., 2005). Looking at each parameter individually in cam patients, they concluded that abnormal alpha angle was present in 93%, anterosuperior acetabular chondral abnormalities were present in 95%, and anterosuperior labral tears were present in 100% of those patients (Kassarjian et al., 2005).

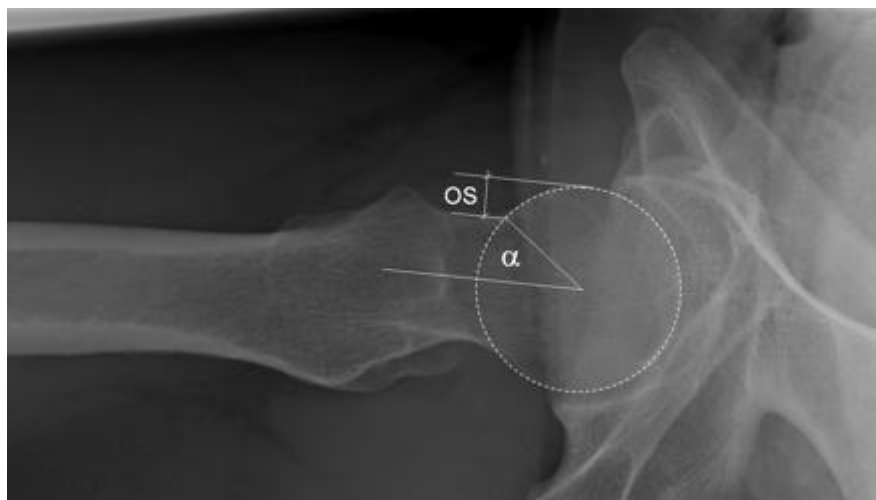

Figure 4: Axial view of normal alpha angle (α) of 50° and normal femoral head-neck offset. [Reprinted with Permission].

2.6 Treatment Options

Non-Surgical Treatment

Emara et al. studied the effects of conservative treatment for 37 FAI patients aged 23-47 years. Treatment included avoiding excessive physical activity and the use of anti-inflammatory drugs for two to four weeks, followed by two to three weeks of physiotherapy. The physiotherapy included 20-30 minutes daily of stretching to improve hip external rotation and abduction in extension and flexion (Emara et al., 2011). Participants' daily activities were modified to try to reduce internal rotation and extreme flexion of the hip. The participants were followed for 25-28 months, at which time only

four of 37 underwent arthroscopic surgery due to failed conservative treatment. The remaining 33 participants had significantly improved function and symptoms as shown by the Harris Hip Score and Non-arthritic Hip Score, but their ROM did not improve (Emara et al., 2011).

If FAI patients are willing to modify their activities, introduce stretching and physiotherapy, and use non-steroidal anti-inflammatory drugs (NSAIDs), symptomatic relief may be possible without undergoing surgery. However, many patients affected with FAI are young, active adults who are not willing to dramatically reduce their physical activity levels. Conservative treatment is a short term fix of symptoms, but does not address the underlying structural problems. Non-surgical treatment or delay of surgical treatment may cause disease progression of OA and increase chondral damage (Macfarlane & Haddad, 2010). These factors come into play to result in the correction of FAI through surgical procedures in many patients (Guanche & Bare, 2006).

Surgical Treatment

It is not fully known if surgical treatment of FAI significantly alters the progression of OA of the hip. However, there is evidence to show that untreated FAI leads to early hip OA (Beck et al., 2005; Ganz et al., 2003). Surgical treatment of this condition may be able to reduce pain in these patients caused by the impingement.

The goal of surgical intervention for symptomatic FAI is pain relief, reducing the bony abnormality(ies) and addressing the intra-articular pathology. This will cease the repetitive trauma to the underlying labrum, cartilage, and bone, stopping the consistent damage and ultimately the progression of OA (Yuan et al., 2008) while providing pain relief to the patient. Several surgical treatment options are available.

Ganz et al. first described an open surgical technique involving anterior dislocation of the hip that has become the gold standard for correcting FAI and associated intra-articular pathologies (Ganz et al., 2001). With the patient in the lateral decubitus position, this approach allows for full 360° visual assessment of the cartilage, acetabulum, labrum, and femoral head-neck junction. A trochanteric osteotomy, which involves removing the greater trochanter of the femur, is performed and the vastuslateralis, gluteus medius and gluteus minimus are mobilized (Ganz et al., 2001). An anterior capsulotomy is executed afterwards followed by anterior surgical dislocation. Blood supply to the femoral head must be carefully preserved, to prevent avascular necrosis of the bone (Beck et al., 2004). When cam FAI is present, femoral osteoplasty is then performed to remove any non-spherical prominent portion of the femoral head or neck, resulting in improved head-neck offset and joint clearance to allow full, impingement-free ROM. Resections of up to 30% of the head-neck junction in cadaver studies have proven to not affect the load-bearing capacity of the femur (Mardones et al., 2005). The aim is to return hip flexion to 120° and rotation to 40° (Parvizi et al., 2007). After the cam impingement is corrected, the acetabulum and labrum can be inspected, and the extent of damage can be identified. If labral tears are present, the injured part of the labrum is debrided while the normal portion is preserved using suture anchors. If pincer impingement is present, periacetabular osteotomy or resection arthroplasty are effective ways to reorient the acetabulum in those suffering from FAI due to acetabular retroversion (Siebenrock et al., 2003). This involves reducing the excessive anterior acetabular over-coverage of the femoral head. Up to 1cm of the acetabular rim may be removed without causing hip instability (Parvizi et al., 2007). When all structures have been corrected, the hip is reduced and ROM is confirmed to be

impingement-free. The hip joint capsule is closed up, the trochanter is fixed into place with two or three cortical screws and the soft tissues are sewed up.

Hip arthroscopy now plays an important, minimally invasive role in the diagnostics and treatment of FAI, especially when there are minimal morphological abnormalities present (Byrd & Jones, 2011; Guanche & Bare, 2006; Ilizaliturri et al., 2008; Philippon & Schenker, 2006; Sampson, M, & D, 2005). The patient may be in the lateral decubitus or supine position, the leg is put into traction, and the joint is viewed under fluoroscopy (Sampson et al., 2005). Standard anterolateral, posterolateral, and anterior portals are used and the hip capsule is decompressed before the arthroscope enters to assess the condition of the structures. A shaver is used to debride and smooth labral or chondral lesions or fraying. Alternatively, the labrum may be repaired if sutured back together. An anterior capsulectomy is performed followed by a femoral resection osteoplasty, to shave down the impingement site, and removal of any acetabular rim osteophytes (Sampson et al., 2005). This procedure has shown comparable results to the open technique with one study reporting 95% of their 158 patients had completely resolved pain by 1 year post-surgery (Sampson et al., 2005).

Beck et al. found 14 of 19 patients with open dislocation correction to have good results post-surgery. They noted that in patients with early degenerative changes, the open approach was beneficial, but in those with advanced degenerative changes or extensive cartilage damage it was not a beneficial procedure (Beck et al., 2004). Damage to the underlying cartilage may be indicative of how effective the surgery may be. Jager et al. reported that the likelihood of surgical failure rises with increased osteoarthritis in FAI patients (Jäger et al., 2011).

In another cohort study including 60 FAI patients, patients were matched to treatment groups with 30 undergoing arthroscopic surgery and 30 undergoing open corrective surgery (Bedi et al., 2011). The open and arthroscopic approaches were found to be equally effective in correcting anterior or anterosuperior femoral osseous lesions, but the posterosuperior loss of femoral offset may be better corrected through the open approach.

Combined arthroscopic and partially open techniques are also being used. Clohisy et al. used a combination of arthroscopy followed by an open femoral osteoplasty in 35 patients (Clohisy et al., 2010). They found significant corrections in lateral alpha angle (63.9° pre-surgery to 37.8° post-surgery) and anteroposterior alpha angle (63.1° pre-surgery to 44.8° post-surgery).

Arthroscopic surgery to correct FAI was specifically studied in 33 young, high-level athletes (Nho et al., 2011). There were statistically significant improvements in the Modified Harris Hip score, the Hip Outcome score, and the alpha angle post-surgery, with 73% of athletes able to play their sport at the two year follow-up (Nho et al., 2011).

A systematic review was undertaken of 970 cases of surgical treatment of FAI to compare treatment methods (Ng et al., 2010). A significant improvement in outcome scores were observed in all the studies reviewed, irrespective of the surgery that was performed, in those without advanced osteoarthritis or chondral damage. Although hip function and symptom severity improved, patient satisfaction was not universally positive. Therefore, there is evidence both open and arthroscopic surgical techniques are helpful in structurally correcting FAI as well as reducing patient symptoms and increasing quality of life in those with low or no osteoarthritis.

2.7 Gait and FAI: Current Research

There have been few studies examining how gait is affected in individuals with FAI. Kennedy et al. (2009) studied 17 FAI patients to determine how the disorder affects hip and pelvis biomechanics during gait. A matched control group (n=14) was used to compare findings. The FAI group had significantly lower peak hip abduction (p=0.009), total frontal hip ROM (p=0.003), total sagittal hip ROM (p=0.047), and pelvic ROM in the frontal plane (p=0.004). There were no significant differences found in walking speed or step length, kinetic variables (peak flexion, extension, adduction, abduction and internal and external moments of force generated at the hip in each plane, and the peak positive and negative hip powers), or kinematic variables (peak hip flexion/extension, adduction, abduction, internal and external rotation, and total transverse ROM) (Kennedy et al., 2009).

Rylander et al. (2011) studied hip kinematics in 11 FAI patients during level walking both preoperatively and 1 year postoperatively following hip arthroscopy. The authors hypothesized that post-surgery, the gait of FAI patients would be significantly closer to the normal range and pattern of hip flexion compared to their own pre-surgery gait. The study results showed decrease in pain levels and increase in activity (4.1 ± 1.7 to 6.1 ± 1.9) based on the Tegner activity scale post-operatively. The center-edge angle was reduced by an average of $4.11^\circ \pm 1.61^\circ$ from pre to post-operative analysis. There were significant increases in sagittal plane hip range of motion ($27.6^\circ \pm 5^\circ$ to $30.7^\circ \pm 4.3^\circ$), maximum hip flexion on the operated hip (19.9° to 22.7°), and overall hip motion pattern was returned to normal post-surgery with less reversals (defined as a reversal in the slope of the hip flexion/extension curve during midstance) being observed post-operatively. There were no significant differences in hip flexion/extension moments, adduction/abduction

angles or moments, or walking speed (Rylander et al., 2011). This study suggests that surgical procedures are beneficial in restoring gait.

Not all data suggests corrective FAI surgery returns gait biomechanics to “normal” post-surgery. In a study by Brisson et al. (2011) on ten FAI participants and thirteen healthy control participants, frontal hip ROM was significantly lower (3.5°) in both the pre and post-operative groups when compared to the control group, and sagittal plane hip ROM actually decreased by 0.6° post-surgery compared with pre-surgery. The postoperative FAI group produced even smaller peak hip abduction and external rotation moments than that preoperatively, differing significantly from that of the control group. Quantitatively, hip biomechanics did not return to normal following open or combined technique surgery, contrary to the authors’ hypothesis. Qualitatively, Western Ontario McMaster Universities Arthritis Index (WOMAC) scores relating to hip pain showed a definite improvement following surgery, but no differences in hip stiffness, function, and overall WOMAC scores were present between the pre and post-surgery groups (Brisson, 2011).

Lamontagne et al. examined the hip and pelvic motion during maximal squatting in 15 FAI patients compared to 11 control subjects with no hip abnormalities, as squatting is a common motion in daily life (Lamontagne et al., 2009). The FAI group had a decreased ($p = 0.005$) sagittal pelvic ROM of 14.7 ± 8.4 compared to 24.2 ± 6.8 in the control group. The control group also squatted to a lower mean maximal squat depth of $32.3 \pm 6.8\%$ of leg length ($p = 0.037$), compared to the $41.5 \pm 12.5\%$ attained by the FAI group. Five (33%) of FAI group individuals reached the lowest attainable squat depth, whereas ten (91%) of control group individuals reached the lowest attainable squat depth (bum touched chair). The study showed no differences in the 3D hip angles at maximal squat depth.

In 2011, Lamontagne et al. studied 10 FAI patients, this time comparing lower extremity joint and pelvic angular displacements during maximal depth squatting preoperative and eight to 32 months postoperative. Kinematic variables were collected such as peak hip, knee, and ankle angles, sum of all joint angles of the affected limb in each plane at maximum depth, maximum pelvic angle in each plane, overall pelvic motion, and maximum squat depth attained. Results showed no significant difference between pre and postoperative kinematic measures at maximum squat depth, pelvic angular displacement, or overall motion of the pelvis during maximum squat. Maximum squat depth attained was significantly greater postoperatively ($36.9\% \pm 12\%$ of leg length from $33.2\% \pm 10.3\%$ pre-surgery). Knee flexion angles at maximum squat increased postoperatively ($141.5^\circ \pm 19.2^\circ$ vs. $130.6^\circ \pm 19.4^\circ$), as did ankle dorsiflexion angles and the sum of all joint angles of the affected limb (Lamontagne et al., 2011). These findings indicate hip flexion angle attainable is limited in FAI patients.

Hip flexion angle (HFA) abnormalities during level walking have been observed in 10 FAI patients in another study when compared to 20 healthy controls (Shu et al. 2010). The HFA is the angle measured between the table and extended leg while the patient is laying supine and extending the knee while lifting the leg as high as possible through hip flexion. This angle can also be measured during gait. FAI patients in this study were found to have a reduced HFA (21° vs. 25° in the control group) during level walking when compared to the control group.

Hip and pelvis kinematics have also been studied in eight FAI patients during over ground running. Decreased hip flexion and pelvic anterior tilt were identified, however

there were no changes in peak hip adduction or internal rotation and there were no differences in frontal or transverse plane hip motions during running (Peterson et al., 2011).

CHAPTER 3: Objectives

The purpose of this study was to determine:

1. the biomechanical gait characteristics associated with femoroacetabular impingement syndrome (FAI) in adults
2. how these gait characteristics compare to healthy controls
3. the quality of life in adults with FAI based on selected quality of life, functional ability, and pain questionnaires

CHAPTER 4: METHODS

4.1 Study Design

This is a prospective cohort study comparing gait characteristics of patients diagnosed with FAI, pre-surgery to of a group of healthy controls.

4.2 Eligibility Criteria

Patients included in this study were between the ages of 18 and 80 years who were diagnosed with FAI, including a history of hip pain, physical evidence of limitations in their range of motion and radiographic or magnetic resonance imaging (MRI) evidence of bony abnormalities defined as an alpha angle that was greater than 55 degrees in the affected hip. We also included patients who had a previous arthroscopic examination of the hip where bony abnormalities were noted but not treated by the surgeon (e.g. femoral head asphericity or lesion). Patients had to be willing to come to the Wolf Orthopaedic Biomechanics lab (WOBL) at Western University for gait analysis pre-surgery. We excluded minors, patients with greater than Grade 2 osteoarthritis based on the Kellgren and Lawrence scale (Kellgren & Lawrence, 1957), and patients who had previous hip surgery, not including arthroscopy.

4.3 Subject Recruitment

All participants were recruited from the orthopaedic clinics of two surgeons (DN and KW) at the London Health Sciences Centre - University Hospital Campus. The study was approved by the Health Sciences Research Ethics Board at Western University. Each patient was informed about the study and their responsibilities as a participant and signed a

consent letter before beginning their participation. Control group participants were chosen based on age, sex, and BMI, to ensure groups were matched and balanced on these factors.

4.4 Procedure

Each subject visited the Wolf Orthopaedic Biomechanics Lab at Western University prior to their hip arthroscopy. Each participant was asked to wear shorts and a t-shirt.

4.41 Gait Analysis

We evaluated gait using an eight-camera motion capture system (Cortex 2; Motion Analysis Corporation, Santa Rosa, CA) synchronized with a floor-mounted force platform (Advanced Mechanical Technology Inc., Watertown, MA) and a modified Helen Hayes 22 passive-reflective marker set. These 22 markers were placed over specific anatomical landmarks, including one on the right scapula which allowed the computer software to determine direction of motion during gait analysis (Kadaba et al., 1990). Additional markers were placed bilaterally on the medial knee joint line and medial malleolus of the ankle to define joint centers of rotation for the knee and ankle. All analysis from here forward was performed with the participant barefoot to reduce any influence of footwear on the individual's gait. Preceding gait analysis, two, three second static measures were taken with the patient standing on the force platform to determine body mass, marker orientation, and positions of joint centers of rotation for the knee and ankle. In addition to these static trials, a dynamic leg movement trial was performed on each leg to determine hip joint centers. The two medial knee and two medial ankle markers were removed prior to gait testing. Patients walked barefoot during testing across the laboratory while three-dimensional kinetic (sampled at 1200 Hz) and kinematic (sampled at 60 Hz) data were recorded during the middle of several strides for at least five trials from each limb. We

calculated the adduction moment about the hip from the kinematic and kinetic data using commercial software (Orthotrak 6.0; Motion Analysis Corporation, Santa Rosa, CA) and custom post-processing and data reduction techniques.

4.42 Marker Placement

A total of 22 passive reflective markers (Helen Hayes marker set), were applied to each participant, which allowed the motion analysis system to record their movements. The markers were attached with double sided tape over the following landmarks: left and right shoulder (tip of the acromion process), right scapula (superior angle), left and right elbow (lateral epicondyle of the humerus), left and right wrist (centered between the styloid processes of the radius and ulna), left and right ASIS (anterior superior iliac spine), sacrum (superior aspect at the L5-sacral interface), left and right lateral knee (along the flexion/extension axis of rotation at lateral femoral condyle), left and right lateral ankle (along the flexion/extension axis of rotation at lateral malleolus), left and right toe (centre of the foot between the 2nd and 3rd metatarsals), left and right heel (posterior calcaneus at same height from floor as toe marker), left and right thigh wand (mid lateral thigh), and left and right shank wand (mid lateral shank). Data collection and reduction to produce the hip adduction moment during each test were performed using Orthotrak Gait Analysis Software (Motion Analysis Corp., Santa Rosa, California).

4.5 Data Reduction

Based on the hip adduction moment waveform, we identified the peak magnitudes in the first and second halves of stance and the area under the curve (impulse) and normalize these values to body weight and height. We also calculated gait speed, toe-out angle, lateral and anterior trunk lean, hip flexion angle, and hip power because of their

influence on the gait patterns of patients with femoroacetabular impingement. Walking speed was calculated as the average walking speed between successive foot contacts of the tested limb. Toe-out (positive angle) was calculated as the angle between a line drawn between the centre of the ankle and the head of the 2nd metatarsal and the forward progression of the body. Lateral trunk lean over the stance limb (positive angle) was calculated as the angle of a line drawn from the midpoint of the anterior superior iliac spines to the midpoint of the anterior tips of the acromion processes. We also measured hip flexion angle and pelvic tilt both lateral and anterior. All gait variables were calculated by averaging across five trials for each patient. We have previously confirmed excellent test-retest reliability of these methods (Birmingham et al., 2007). The minimum detectable change for the first peak hip extension moment (95% confidence level) is 1% body weight x height (BW*Ht).

4.6 Sample Size

Based on a dependent groups comparison of hip adduction moment values in the FAI and control groups, an estimated effect size = 0.5, power = 80%, and two sided $\alpha=0.05$, 34 subjects are required per group.

4.7 Outcome Measures

The primary outcome measure is the hip adduction moment. Other biomechanical measurements of primary interest include trunk lean, toe out angle, pelvic tilt (lateral and anterior), peak hip power, gait speed, and hip flexion angle. Secondary outcomes include patient self-reported questionnaires including the Non-Arthritic Hip Score (Christensen et al., 2003), Modified Harris Hip Score (Harris, 1969), 12-Item Short-Form Health Survey (SF-12) (Ware et al., 1996), Hip Outcome Score (Martin et al., 2006), and the NRS Pain

scale. Patients were asked to complete questionnaires online at home or in the laboratory, or on paper in the laboratory.

4.71 Quality of Life

The Non-arthritic hip score is a validated, region-specific questionnaire consisting of 20 questions, with the same five response options for each (Christensen et al., 2003). The questions are divided over four domains including pain, mechanical symptoms, physical function, and level of activity, with a maximum high score of 100, indicating normal hip function (Christensen et al., 2003).

The Modified Harris Hip Score is a short eight item, validated, region-specific questionnaire divided into three sections including pain, function: gait, and functional activities (Harris, 1969). The sections are scored out of 44, 33, and 14 respectively, for an overall total of 91, signifying maximal normal hip function (Harris, 1969).

The SF-12 health survey is a validated, shortened version of the SF-36 generic health questionnaire, consisting of 12 items (Ware et al., 1996). The response options are dichotomous (yes/no), ordinal (excellent to poor), or expressed as a frequency (always to never), and result in a physical component summary (PCS-12) and a mental component summary (MCS-12), there is no overall score (Ware et al., 1996).

4.72 Activities and Participation

The Hip Outcome Score (HOS) is a validated, region-specific questionnaire consisting of 28 items over two subscales; activities of daily living (ADL), and sports (Martin & Philippon, 2007). The ADL portion is scored out of 68 if all 17 of the scored questions are answered, as each question has a maximum score of four (four being “no

difficulty” and zero being “unable to do”) (Martin & Philippon, 2007). Item scores are added together, and the total score is divided by the highest potential score. This value is then multiplied by 100 to obtain a percentage (Martin & Philippon, 2007). A higher score represents a higher level of physical function, where 100 percent is the best possible score. The sports subscale is scored similarly, with the highest possible value being 36 (Martin & Philippon, 2007). This measure has been shown to be reliable and responsive for individuals who undergo arthroscopic hip surgery (Martin & Philippon, 2008).

4.73 Pain

We collected pain information on the day of gait analysis for each participant according to the Numeric Rating Scale (NRS-11). This scale allows us to measure participants’ pain levels on an 11 point scale from 0-10; 0 being no pain, and 10 being the worst pain imaginable. Pain level was recorded before and after the gait analysis.

On the Modified Harris Hip Score, there is a question that asks whether the participant experiences pain in the contralateral hip. This is reported along with the overall score in the results section.

We also collected the following demographic information: date of birth, operative hip, contralateral hip symptoms, dominant side, gender, height, weight, smoking status, occupation, if work duties have been modified due to hip condition, acute event or gradual onset of injury, duration of symptoms, previous health care providers seen, and previous treatment received.

Each FAI participant was asked to report any medications taken on the day of analysis. This information was included as it could potentially affect the NRS-11 pain score reported, and/or the participant's gait.

4.8 Follow-up

Patients attended the usual schedule of follow-up appointments for any surgical hip patient at London Health Sciences Centre. These appointments fall at two weeks, six weeks, three months, six months, one year, and two years post-surgery.

CHAPTER 5: Statistical Analysis

There were 9 participants included in the control group for this study. These individuals were taken from a previous study on the gait of healthy normals in the Wolf Orthopaedic Biomechanics Lab (WOBL) (Richardson, 2012). We recruited 9 patients into the prospective cohort FAI study group, all of which were used in the analysis.

We used dependent-group t-tests to make between group statistical comparisons, where the dependent variable was the group, and the independent variable was the continuous outcome measure (i.e. hip moment, trunk lean, lateral pelvic tilt, toe out angle, hip flexion angle, anterior pelvic tilt, peak hip power, and speed) at baseline values. Because gait speed has been shown to affect measurements of gait pattern (Bejek et al., 2006; Landry et al., 2007), we also performed an analysis of covariance (ANCOVA) to adjust for gait speed, where the independent variable was group, the dependent was the outcome of interest and the covariate was gait speed (m/s). A p-value of 0.05 was considered significant. Outcome data for each group are presented as the mean and standard deviation and mean differences, with the 95% confidence interval (CI), between groups being reported as well. Since all data was collected at one time point, we have no missing data points or incomplete data. All statistical analyses were completed using SPSS 19 (SPSS, Chicago, IL).

CHAPTER 6: Results

Between 2011 and 2012, we screened 98 patients who attended clinic for their first consultation for pain and disability possibly related to their hip joint. Of these, 89 patients were excluded; 76 patients were not eligible and 13 patients declined participation (See Figure 4).

Figure 5: Flow diagram of patient screening

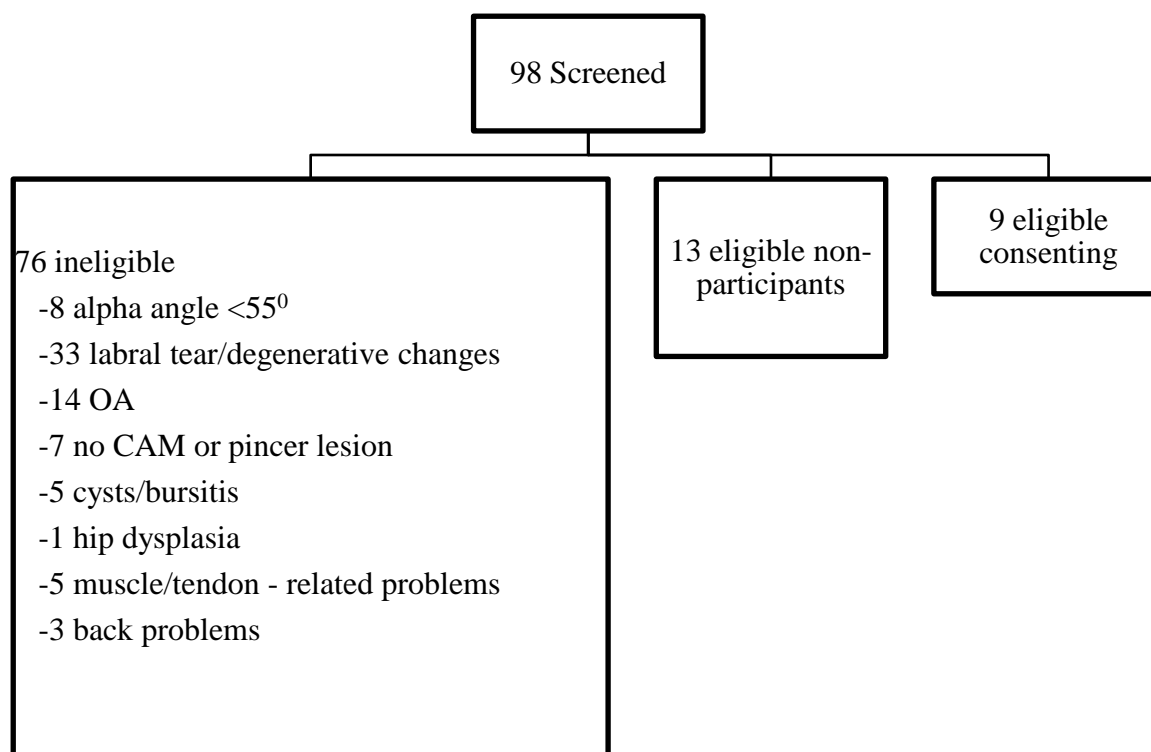


Table 1 provides descriptive characteristics of the 18 participants in our study. Patients were balanced for characteristics of gender, age, and body mass index (BMI). The mean age of participants was 31.7 years with a mean BMI of 25.4.

Table 1 Demographic data on the study participants

Characteristic	FAI (n=9)	Control (n=9)
Gender (male:female)	7:2	7:2
Age* (years)	31.6 ± 12.4	31.8 ± 11.8
Height* (cm)	182.2 ± 7.8	175.6 ± 10.2
Mass* (kg)	84.7 ± 18.3	78.7 ± 17.0
Body Mass Index (kg/m ²)*	25.4 ± 4.5	25.3 ± 4.3

* Mean ± standard deviation

Characteristics of the FAI Group

The mean alpha angle was 60.2° (± 5.9). The mean duration of symptoms of 7.06 years (± 9.52). Eight participants stated that the onset of their symptoms was gradual, whereas one participant could recall a precipitating event three months prior to gait analysis. The average number of health care providers each participant had seen prior to being referred to the surgeon was 2.22 (±1.2). Five participants claimed no change in work, two participants claimed they have had to reduce their hours or duties due to their hip condition, and two participants were students and thus currently unemployed. Eight participants reported taking no medications for pain on the day of their gait analysis, and one participant, who was scheduled to have his surgery immediately following the gait analysis, reported haven taken 300mg Gabapentin; a drug to reduce neuropathic pain and narcotic use post-operatively.

Quality of Life in FAI group

The individual scores on the Non-Arthritic Hip Score ranged from 21.25 to 86.25, with a mean value of 62.36 (\pm 22.29). For the Modified Harris Hip Score, the mean score was 58.56 (\pm 15.68) with individual scores ranging from 32 to 75. For the SF-12 general health survey, the FAI group scored an average of 41.4 (\pm 8.4) on the PCS with a range of 25.6 to 52.9 and an average of 50.8 (\pm 13.2) on the MCS with a range of 26.0 to 65.3.

Activities and Participation in FAI group

The mean ADL score for Hip Outcome Score was 69.4 (\pm 19.6) with values ranging from 36.8 to 94.1, and the mean Sports Subscale score was 46.9 (\pm 29.8) with values ranging from 2.8 to 86.1.

Pain in FAI group

The NRS pain scale varied between individuals (range: 1-6) and the average across the nine participants remained unchanged from pre to post analysis (2.8/10). On the Modified Harris Hip Score, there is a question that asks whether the participant experiences pain in the contralateral hip, to which five responded 'no', three reported 'slight pain', and one reported 'mild pain'.

Comparisons between FAI and Control Group

Table 2 presents the biomechanical outcomes for the FAI and control groups. The hip adduction moment was greater in the FAI group (5.26 %BW*ht; 80.05Nm \pm 26.07) compared to the control group (4.89 %BW*ht; 65.81Nm \pm 15.74). The toe out angle was greater in the FAI group (12.01° vs. 8.49°), as was the pelvic tilt angle (3.34° vs. 2.38°). The FAI group had a smaller trunk lean (0.15°) when compared with the control group (1.55°). Speed of normal, self-selected walking was slower in the FAI group (1.11m/s)

than the control group (1.26m/s). Hip flexion angle was smaller in the FAI group ($23.38^{\circ} \pm 11.08$) when compared to the control group ($26.58^{\circ} \pm 8.72$). Forward pelvic tilt was also smaller in the FAI group ($3.61^{\circ} \pm 10.41$) than the control group ($4.65^{\circ} \pm 6.51$). Peak hip power generated was decreased in the FAI group ($0.57W \pm 0.17$) when compared to the control group ($1.26W \pm 0.65$). Only hip power was significantly different between groups ($p=0.02$).

Table 2 Unadjusted biomechanical outcomes compared between groups

	FAI	Control	MD	95% CI	p-value
Hip adduction moment (%BW*ht)	5.26 ± 1.00	4.89 ± 0.86	0.37	-0.51 to 1.24	0.36
Hip adduction moment (Nm)	80.05 ± 26.07	65.81 ± 15.74	14.24	-33.82 to 5.35	0.13
Toe out angle (degrees)	12.01 ± 6.96	8.49 ± 5.00	3.52	-0.24 to 7.27	0.06
Trunk lean (degrees)	0.15 ± 1.53	1.55 ± 1.24	-1.4	-2.35 to -0.46	0.009
Pelvic tilt lateral (degrees)	3.34 ± 1.73	2.38 ± 2.11	0.96	-0.61 to 2.52	0.195
Speed (m/s)	1.11 ± 0.14	1.26 ± 0.16	-0.15	-0.32 to 0.19	0.009
Hip Flexion Angle (degrees)	23.39 ± 11.08	26.58 ± 8.72	-3.19	-11.87 to 5.47	0.42

Pelvic tilt forward (degrees)	3.61 ± 10.41	4.65 ± 6.51	-1.04	-10.52 to 8.44	0.81
Peak hip power (W)	0.57 ± 0.17	1.25 ± 0.65	-0.68	-1.23 to -0.14	0.02

Mean ± standard deviation

Table 3 presents the results adjusted for walking speed during gait. The hip adduction moment was greater in the FAI group (5.2 %BW*ht; 84.09Nm ± 7.37) compared to the control group (4.97 %BW*ht; 61.77Nm ± 7.37). The toe out angle was greater in the FAI group (12.36° vs. 8.15°), as was the pelvic tilt angle (3.55° vs. 2.18°). The FAI group had a smaller trunk lean (0.36°) when compared with the control group (2.18°). The hip flexion angle (HFA) was still smaller in the FAI group (24.23° vs. 25.74°) after adjustment, as was peak hip power (0.61W vs. 1.22W). Pelvic forward (or anterior) tilt was found to be greater in the FAI group than the control group (4.34° vs. 3.92°).

Table 3 Adjusted biomechanical outcomes between groups

	FAI	Control	MD	95% CI	p-value
Hip adduction moment (%BW*ht)	5.2 ± 0.34	4.97 ± 0.34	0.23	-1.32 to 0.86	0.66
Hip adduction moment (Nm)	84.09 ± 7.37	61.77 ± 7.37	22.32	-1.26 to 45.89	0.06

Toe out angle (degrees)	12.36 ± 2.21	8.15 ± 2.21	4.21	-11.28 to 2.86	0.22
Trunk lean (degrees)	0.36 ± 0.49	1.33 ± 0.49	-0.97	-0.58 to 2.52	0.20
Pelvic tilt lateral (degrees)	3.55 ± 0.69	2.18 ± 0.69	1.38	-3.59 to 0.84	0.20
Hip Flexion Angle (degrees)	24.23 ± 3.61	25.74 ± 3.61	-1.51	-13.04 to 10.02	0.78
Pelvic tilt forward (degrees)	4.34 ± 3.14	3.93 ± 3.14	0.41	-9.636 to 10.45	0.93
Peak hip power (W)	0.61 ± 0.17	1.22 ± 0.17	-0.61	-1.16 to -0.6	0.03

Mean ± standard error. Values adjusted for walking speed during gait.

CHAPTER 7: Discussion

The aim of this study was to determine the biomechanical gait abnormalities and quality of life scores in patients diagnosed with femoroacetabular impingement (FAI) who are awaiting hip arthroscopy. Using 3D motion capture equipment, we found no significant differences between the FAI and control groups in hip adduction moment, toe out angle, lateral pelvic tilt, forward pelvic tilt, hip flexion angle, or trunk lean, when adjusting for speed of walking. Speed of walking itself was significantly different between groups, with the FAI group walking slower ($1.11\text{m/s}\pm 0.14$) than the control group ($1.26\text{m/s}\pm 0.16$). Peak hip power generated was significantly different between groups with the FAI group generating decreased power ($0.57\text{W}\pm 0.17$) compared to the control group ($1.26\text{W}\pm 0.65$).

Four previous studies have found differences in gait characteristics between FAI and control groups. Differences include a reduced hip flexion angle (Shu, 2010), smaller sagittal pelvic range of motion (ROM) (Lamontagne et al. 2009; Kennedy et al., 2009), smaller maximum squat depth (Lamontagne et al., 2009), smaller hip abduction angle, smaller total frontal and sagittal hip ROM, and smaller pelvic ROM in the frontal plane (Kennedy et al., 2009). Kennedy et al conducted a study in 17 FAI patients (alpha angle >50.5 degrees) and compared them to 14 healthy control participants. They found that the hip abduction angle was smaller ($p=0.009$) and their hip adduction moment was no difference in the control group compared to the FAI group which is in keeping with our observations of hip adduction moment (FAI group 5.2 ± 0.34 compared to control group 4.97 ± 0.34 ; $p=0.66$). However, contrary to Kennedy's findings, our measure of pelvic tilt in the FAI group ($3.55^\circ\pm 0.69$) was larger than that of the control group ($2.18^\circ\pm 0.69$) although not statistically significant (Kennedy et al., 2009). In our study, we observed bilateral side

to side pelvic motion in our FAI patients, which may represent a compensation mechanism, perhaps to reduce pain; by shifting their pelvis, their upper body weight shifts over their stance leg during gait. The mean trunk lean of our FAI patients ($0.36^{\circ} \pm 0.49$) was less than that of the control group ($1.33^{\circ} \pm 0.49$). This could explain the increased pelvic tilt that we observed in the FAI group; their pelvises are moving laterally to position the upper body over the stance hip, therefore the trunk does not need to lean to position the upper body weight over the stance hip. Thus, it is possible that if Kennedy and Lamontagne had measured trunk lean in their FAI patients, they would find results in keeping with our results. Another possible explanation is that the pelvic tilt or frontal pelvic ROM was small in their FAI patients which could mean that their patients had a greater trunk lean. Finally, because our studies are all relatively small samples of the population, it is possible that our studies represent different subgroups of individuals with FAI.

We measured hip flexion angle (HFA) during gait and found the FAI group to have a smaller HFA ($23.38^{\circ} \pm 11.08$) than the control group ($26.58^{\circ} \pm 8.72$) although not statistically significantly different. FAI patients tend to avoid hip flexion as it is a position that is uncomfortable for them, and limited, due to their impingement (Lamontagne et al., 2011). Our findings of a decreased HFA agree with those of previously published gait studies (Kennedy et al., 2009; Shu et al., 2011; Peterson et al., 2011). If sagittal pelvic ROM is decreased, the individual is not advancing their hip as much during gait because doing so means increased hip flexion in their advancing hip. To avoid any increase in hip flexion, FAI patients may walk with less rotation in their hips, producing smaller range of motion than a control individual would produce.

Hip flexion angle is also directly related to stride length; the greater the hip flexion angle, the greater the stride length. Although we would hypothesize that stride length would be smaller in our FAI group to reduce hip flexion, the stride length between groups was equal ($1.3\text{m/s} \pm 0.13$). This could be because the FAI individuals walk with a greater hip extension angle to make up for their smaller flexion angle, thus maintaining a similar stride length to those with “normal” gait.

Peterson et al conducted a study in eight individuals with FAI during level running and reported a smaller hip flexion angle and lower pelvic anterior tilt, but no changes in moments or frontal/transverse hip motions compared to a control group ($n=8$) (Peterson, 2011). We measured forward pelvic tilt and found the FAI group to have a smaller forward pelvic tilt (3.61 ± 10.41) compared to the control group (4.65 ± 6.51), although the difference was not statistically significant. This could be the result of the FAI patients avoiding hip flexion by making changes in their pelvic anterior tilt.

Kennedy et al. also found no significant differences in other kinetic and kinematic variables between an FAI group ($n=17$) and control group ($n=14$) during level walking. Our findings are in keeping with those of Kennedy et al., (Kennedy et al., 2009) who found no differences in kinetic variables (adduction moment) during level walking gait analysis with one exception. We measured peak hip power in the affected hip and found significantly less power in the FAI group ($0.61\text{W} \pm 0.17$) compared to the control group ($1.22\text{W} \pm 0.17$). This finding suggests FAI patients generated less power in the hip during gait. This could be explained by their slower walking speed, as a faster walking speed requires more power generation from the hip.

It has been proposed that the greater the alpha angle, the more symptomatic the individual. Sutter et al compared alpha angle measurements in FAI patients and asymptomatic volunteers (n=106) (Sutter et al., 2012) and showed that although the maximal alpha angle was significantly different between the FAI and control groups, there was substantial overlap, with as many as 38-62% of the 53 asymptomatic volunteers having alpha angles over 55° (Sutter et al., 2012). The authors suggest that increasing the diagnostic alpha angle for FAI patients from 55° to 60° may reduce false positives while still maintaining reasonable sensitivity. Johnston et al. noted increased alpha angles in FAI patients are correlated with increased chondral damage, labral injury, and decreased range of motion (Johnston et al., 2008). Our eligibility criteria was an alpha angle of 55° which is consistent with the currently accepted cutoff angle in the diagnosis of FAI (Notzli et al., 2002). The average alpha angle in our study was 60.2 degrees with six of nine patients with alpha angles below 60 degrees. Thus, it is possible that our results would be different had our eligibility criteria restricted entrance to patients with an alpha angle of at least 60 degrees.

The secondary outcomes we studied gave us a better understanding of the quality of life of patients with FAI. A study in Alberta, Canada reported that in the general population, who report they have no medical problems, the average Physical Component Score (PCS) from the SF-12 is 52.5 and the average Mental Component Score (MCS) is 52.6 (Johnson & Pickard, 1998). In our study, patients with FAI reported an average PCS value of 41.4 (range from 25.6 to 59.2) and 50.8 (range from 26 to 65.3). These results suggest that our sample of patients with FAI experience reduced physical ability than the general population.

7.2 Limitations

A limitation to this study is its small sample size. Due to a low number of patients presenting with FAI who were willing to participate, we did not meet our target sample size of 34 patients. A larger sample size would contribute to the precision about the differences in gait characteristics between groups.

The marker system we used involved attaching the hip, sacrum, and shoulder marker to the participants' clothing, ultimately to represent the underlying rigid bones. The skin or clothings' movements may shift the markers and not truly represent the movement of the bone. This movement is referred to as an artifact and these changes in position of the markers may consequently affect the estimate of joint kinematics (Leardini, 2005).

Artifacts vary between participants and may produce relatively large errors (Leardini et al., 2005) reducing the precision of these measurements and resulting comparisons.

Joint centers of the knees, ankles, and hips are crucial in calculating angular kinematics. These are calculated based on the placements of the markers at those joints, and standard algorithms as well as some of the participants' personal anthropometric measurements. Every individual's anatomy differs, however slightly it may be, therefore there may be a margin of error around the calculated values. If markers are not placed on the specified landmarks accurately, this adds to the potential calculation errors.

Several variables of our patient population could influence the biomechanics, and therefore our results, such as age, gender, weight, height, and severity of impingement. These variables were controlled as best as possible through matching the control group sample to the FAI group sample to minimize differences in those variables between groups.

7.3 Strengths

This study's prospective design allowed us to have full control over the participants who were invited to participate in the study based on their exam, history, and imaging. This study design also allowed us to study multiple outcomes within the cohort of interest. The non-invasive protocol and minimal time commitment required of participants was emphasized and was of assistance in the recruitment of patients.

Validated questionnaires were used to assess the participants' quality of life, and a validated, reliable marker set, camera system, and software system was utilized for motion capture and post-processing analysis. Participants were asked to complete self-report questionnaires based on how they were feeling at the time of completion, minimizing any potential for recall bias.

Our patient reported results were similar to those reported by other pre-operative FAI patients (Byrd et al., 2011; Chiron et al., 2012; Fabricant et al., 2012). Specifically, the average score on the Modified Harris Hip Score was 58.56, which is similar to the average score of 60 reported by Byrd et al. in their study of 100 patients with FAI (Byrd et al., 2011). The average scores on the Hip Outcome Score Activities of Daily Living (ADL) component and Sports Subscale component were 69.4 and 46.9 respectively, which are similar to the average ADL score of 77 and Sports Subscale score of 49 reported by Fabricant et al. in their study of 27 hips in 21 patients with FAI (Fabricant et al., 2012). The average score on the Non-Arthritic Hip Score was 62.4 which is similar to the average score of 58.9 reported by Chiron et al. in their study of 106 patients with FAI (Chiron et al., 2010). Therefore, although our study is small, we believe the sample to be representative of patients with FAI.

7.4 Summary

The results of this study conclude there were no significant differences in hip adduction moment, lateral pelvic tilt, forward pelvic tilt, hip flexion angle, toe out angle, and trunk lean during level walking in patients with FAI compared to healthy controls when gait speed was adjusted for. Peak hip power generated ($p=0.03$) and gait speed ($p=0.009$) were significantly different between groups, with the FAI group having decreased measures in both variables. When gait speed was not controlled for, trunk lean was also significantly smaller in the FAI group than the control group ($p=0.009$). Suggestions for further study include continuing this study to include a greater number of participants, and to measure these same gait characteristics post-surgery to determine whether surgery returns gait patterns to those that mimic asymptomatic individuals. Future studies could also expand the types of outcomes that are measured to include more dynamic, functional movements (i.e. stair climbing, jumping, squatting) and how those resulting biomechanical characteristics compare to a control group.

References

- Beall, D. P., Sweet, C. F., Martin, H. D., Lastine, C. L., Grayson, D. E., Ly, J. Q., & Fish, J. R. (2005). Imaging findings of femoroacetabular impingement syndrome. *Skeletal Radiology*, *34*(11), 691-701.
- Beaulé, P., Zaragoza, E., Motamedi, K., Copelan, N., & Dorey, F. (2005). Three-dimensional computed tomography of the hip in the assessment of femoroacetabular impingement. *Journal of Orthopaedic Research*, *23*(6), 1286-1292.
- Beck, M., Kalhor, M., Leunig, M., & Ganz, R. (2005). Hip morphology influences the pattern of damage to the acetabular cartilage: Femoroacetabular impingement as a cause of early osteoarthritis of the hip. *Journal of Bone & Joint Surgery - British Volume*, *87*(7), 1012-1018.
- Beck, M., Leunig, M., Parvizi, J., Boutier, V., Wyss, D., & Ganz, R. (2004). Anterior femoroacetabular impingement: Part II. midterm results of surgical treatment. *Clinical Orthopaedics & Related Research*, (418), 67-73.
- Bedi, A., Chen, N., Robertson, W., & Kelly, B. T. (2008). The management of labral tears and femoroacetabular impingement of the hip in the young, active patient. *Arthroscopy*, *24*(10), 1135-1145.
- Bedi, A., Zaltz, I., De La Torre, K., & Kelly, B. T. (2011). Radiographic comparison of surgical hip dislocation and hip arthroscopy for treatment of cam deformity in femoroacetabular impingement. *American Journal of Sports Medicine*, *39*(Suppl), 20S-8S.

- Bejek, Z., Paroczai, R., Illyes, A., & Kiss, R. M. (2006). The influence of walking speed on gait parameters in healthy people and in patients with osteoarthritis. *Knee Surgery, Sports Traumatology, Arthroscopy*, *14*(7), 612-622.
- Birmingham, T. B., Hunt, M. A., Jones, I. C., Jenkyn, T. R., & Giffin, J. R. (2007). Test-retest reliability of the peak knee adduction moment during walking in patients with medial compartment knee osteoarthritis. *Arthritis & Rheumatism*, *57*(6), 1012-1017.
- Brisson, M. (2011). A Comparison of Preoperative and Postoperative Lower-Extremity Joint Biomechanics of Patients with CAM Femoroacetabular Impingement (Master's Thesis). Retrieved from http://www.ruor.uottawa.ca/en/bitstream/handle/10393/20256/Brisson_Nicholas_2011_thesis.pdf?sequence=3.
- Byrd, J. W., & Jones, K. S. (2011). Arthroscopic management of femoroacetabular impingement: Minimum 2-year follow-up. *Arthroscopy*, *27*(10), 1379-1388.
- Casartelli, N. C., Maffiuletti, N. A., Item-Glatthorn, J. F., Staehli, S., Bizzini, M., Impellizzeri, F. M., & Leunig, M. (2011). Hip muscle weakness in patients with symptomatic femoroacetabular impingement. *Osteoarthritis & Cartilage*, *19*(7), 816-821.
- Chiron, P., Espie, A., Reina, N., Cavaignac, E., Molinier, F., & Laffosse, J. M. (2012). Surgery for femoroacetabular impingement using a minimally invasive anterolateral approach: Analysis of 118 cases at 2.2-year follow-up. *Orthopaedics & Traumatology, Surgery & Research*, *98*(1), 30-38.

Christensen, C. P., Althausen, P. L., Mittleman, M. A., Lee, J. A., & McCarthy, J. C.

(2003). The nonarthritic hip score: Reliable and validated. *Clinical Orthopaedics & Related Research*, 406, 75-83.

Clohisy, J. C., Nunley, R. M., Otto, R. J., & Schoenecker, P. L. (2007). The frog-leg lateral radiograph accurately visualized hip cam impingement abnormalities. *Clinical Orthopaedics & Related Research*, 462, 115-121.

Clohisy, J. C., St John, L. C., & Schutz, A. L. (2010). Surgical treatment of femoroacetabular impingement: A systematic review of the literature. *Clinical Orthopaedics & Related Research*, 468(2), 555-564.

Clohisy, J. C., Zebala, L. P., Nepple, J. J., & Pashos, G. (2010). Combined hip arthroscopy and limited open osteochondroplasty for anterior femoroacetabular impingement. *Journal of Bone & Joint Surgery - American Volume*, 92(8), 1697-1706.

Clohisy, J. C., Knaus, E. R., Hunt, D. M., Leshner, J. M., Harris-Hayes, M., & Prather, H. (2009). Clinical presentation of patients with symptomatic anterior hip impingement. *Clinical Orthopaedics and Related Research*, 467(3), 638-644.

Crawford, J. R., & Villar, R. N. (2005). Current concepts in the management of femoroacetabular impingement. *Journal of Bone and Joint Surgery-British Volume*, 87B(11), 1459-1462.

- Czubak, J., Sionek, A., & Czwojdzinski, A. (2010). New concepts in the aetiology of primary osteoarthritis of the hip caused by femoroacetabular impingement. *Ortopedia Traumatologia Rehabilitacja*, 12(6), 479-492.
- Dooley, P. J. (2008). Femoroacetabular impingement syndrome: Nonarthritic hip pain in young adults. *Canadian Family Physician*, 54(1), 42-47.
- Eijer, H., Myers, S. R., & Ganz, R. (2001). Anterior femoroacetabular impingement after femoral neck fractures. *Journal of Orthopaedic Trauma*, 15(7), 475-481.
- Ellis, A. R., Noble, P. C., Schroder, S. J., Thompson, M. T., & Stocks, G. W. (2011). The cam impinging femur has multiple morphologic abnormalities. *The Journal of Arthroplasty*, 26(6, Supplement), 59-65.
- Emara, K., Samir, W., Motasem, E. L., & Ghafar, K. A. (2011). Conservative treatment for mild femoroacetabular impingement. *Journal of Orthopaedic Surgery*, 19(1), 41-45.
- Fabricant, P. D., Heyworth, B. E., & Kelly, B. T. (2012). Hip arthroscopy improves symptoms associated with FAI in selected adolescent athletes. *Clinical Orthopaedics & Related Research*, 470(1), 261-269.
- Friend, L., & Kelly, B. T. (2009). Femoroacetabular impingement and labral tears in the adolescent hip: Diagnosis and surgical advances. *Current Opinion in Pediatrics*, 21(1), 71-76.
- Ganz, R., Gill, T. J., Gautier, E., Ganz, K., Krugel, N., & Berlemann, U. (2001). Surgical dislocation of the adult hip a technique with full access to the femoral head and

acetabulum without the risk of avascular necrosis. *Journal of Bone & Joint Surgery - British Volume*, 83(8), 1119-1124.

Ganz, R., Leunig, M., Leunig-Ganz, K., & Harris, W. H. (2008). The etiology of osteoarthritis of the hip: An integrated mechanical concept. *Clinical Orthopaedics & Related Research*, 466(2), 264-272.

Ganz, R., Parvizi, J., Beck, M., Leunig, M., Notzli, H., & Siebenrock, K. A. (2003). Femoroacetabular impingement: A cause for osteoarthritis of the hip. *Clinical Orthopaedics & Related Research*, 417, 112-120.

Gosvig, K. K., Jacobsen, S., Sonne-Holm, S., & Gebuhr, P. (2008). The prevalence of cam-type deformity of the hip joint: A survey of 4151 subjects of the Copenhagen osteoarthritis study. *Acta Radiologica*, 49(4), 436-441.

Guanche, C. A., & Bare, A. A. (2006). Arthroscopic treatment of femoroacetabular impingement. *Arthroscopy: The Journal of Arthroscopic & Related Surgery*, 22(1), 95-106.

Gray, H. (1918). *Anatomy of the Human Body*. Lea & Febiger, Philadelphia, PA, USA.

Hack, K., Di Primio, G., Rakhra, K., & Beaulé, P. E. (2010). Prevalence of cam-type femoroacetabular impingement morphology in asymptomatic volunteers. *Journal of Bone & Joint Surgery - American Volume*, 92(14), 2436-2444.

Harris, W. H. (1969). Traumatic arthritis of the hip after dislocation and acetabular fractures: Treatment by mold arthroplasty. an end-result study using a new method of

result evaluation. *Journal of Bone & Joint Surgery - American Volume*, 51(4), 737-755.

Harris, W. H. (1986). Etiology of osteoarthritis of the hip. *Clinical Orthopaedics & Related Research*, 213, 20-33.

Hong, S., Shon, W. Y., Lee, C. Y., Myung, J. S., Kang, C. H., & Kim, B. H. (2010). Imaging findings of femoroacetabular impingement syndrome: Focusing on mixed-type impingement. *Clinical Imaging*, 34(2), 116-120.

Ilizaliturri Jr, V. M., Orozco-Rodriguez, L., Acosta-Rodríguez, E., & Camacho-Galindo, J. (2008). Arthroscopic treatment of cam-type femoroacetabular impingement: Preliminary report at 2 years minimum follow-up. *The Journal of Arthroplasty*, 23(2), 226-234.

Ito, K., Minka, M. A., 2nd, Leunig, M., Werlen, S., & Ganz, R. (2001). Femoroacetabular impingement and the cam-effect. A MRI-based quantitative anatomical study of the femoral head-neck offset. *Journal of Bone & Joint Surgery - British Volume*, 83(2), 171-176.

Ito, K. S. C. D., Leunig, M., & Ganz, R. (2004). Histopathologic features of the acetabular labrum in femoroacetabular impingement. *Clinical Orthopaedics & Related Research*, 429, 262-271.

Jaberi, F. M., & Parvizi, J. (2007). Hip pain in young adults: Femoroacetabular impingement. *The Journal of Arthroplasty*, 22(7, Supplement 1), 37-42.e1.

- Jäger, M., Bittersohl, B., Rosenthal, D., Hefter, H., Westhoff, B., Krauspe, R., & Zilkens, C. (2011). The intertwining pathways in biology and biomechanics in femoro-acetabular impingement (FAI) patients. *Procedia IUTAM*, 2(0), 82-85.
- Johnson, J. & Pickard, A.S. (2000). Comparison of the EQ-5D and SF-12 Health Surveys in a General Population Survey in Alberta, Canada. *Medical Care*, 38(1), 115-121.
- Johnston, T. L., Schenker, M. L., Briggs, K. K., & Philippon, M. J. (2008). Relationship between offset angle alpha and hip chondral injury in femoroacetabular impingement. *Arthroscopy: The Journal of Arthroscopic & Related Surgery*, 24(6), 669-675.
- Kadaba, M. P., Ramakrishnan, H. K., & Wootten, M. E. (1990). Measurement of lower extremity kinematics during level walking. *Journal of Orthopaedic Research*, 8(3), 383-392.
- Kamegaya, M., Saisu, T., Nakamura, J., Murakami, R., Segawa, Y., & Wakou, M. (2011). Drehmann sign and femoro-acetabular impingement in SCFE. *Journal of Pediatric Orthopedics*, 31(8), 853-857.
- Kapron, A. L., Anderson, A. E., Aoki, S. K., Phillips, L. G., Petron, D. J., Toth, R., & Peters, C. L. (2011). Radiographic prevalence of femoroacetabular impingement in collegiate football players: AAOS exhibit selection. *Journal of Bone & Joint Surgery - American Volume*, 93(19), e111(1-10).

- Kassarjian, A., Yoon, L. S., Belzile, E., Connolly, S. A., Millis, M. B., & Palmer, W. E. (2005). Triad of MR arthrographic findings in patients with cam-type femoroacetabular impingement. *Radiology*, *236*(2), 588-592.
- Kellgren, J. H., & Lawrence, J. S. (1957). Radiological assessment of osteo-arthritis. *Annals of the Rheumatic Diseases*, *16*(4), 494-502.
- Kennedy, M. J., Lamontagne, M., & Beaulé, P. E. (2009). Femoroacetabular impingement alters hip and pelvic biomechanics during gait walking biomechanics of FAI. *Gait & Posture*, *30*(1), 41-44.
- Kim, Y. J., & Novais, E. N. (2011). Diagnosis and treatment of femoroacetabular impingement in Legg-Calvé-Perthes disease. *Journal of Pediatric Orthopedics*, *31*(2 Suppl), S235-40.
- Konan, S., Rayan, F., & Haddad, F. S. (2010). Is the frog lateral plain radiograph a reliable predictor of the alpha angle in femoroacetabular impingement?. *Journal of Bone & Joint Surgery - British Volume*, *92*(1), 47-50.
- Kubiak-Langer, M., Tannast, M., Murphy, S. B., Siebenrock, K. A., & Langlotz, F. (2007). Range of motion in anterior femoroacetabular impingement. *Clinical Orthopaedics & Related Research*, *458*, 117-124.
- Lamontagne, M., Brisson, N., Kennedy, M. J., & Beaulé, P. E. (2011). Preoperative and postoperative lower-extremity joint and pelvic kinematics during maximal squatting of

patients with cam femoro-acetabular impingement. *Journal of Bone & Joint Surgery - American Volume*, 93(Suppl 2), 40-45.

Lamontagne, M., Kennedy, M. J., & Beaulé, P. E. (2009). The effect of cam FAI on hip and pelvic motion during maximum squat. *Clinical Orthopaedics & Related Research*, 467(3), 645-650.

Landry, S. C., McKean, K. A., Hubley-Kozey, C. L., Stanish, W. D., & Deluzio, K. J. (2007). Knee biomechanics of moderate OA patients measured during gait at a self-selected and fast walking speed. *Journal of Biomechanics*, 40(8), 1754-1761.

Lavigne, M., Parvizi, J., Beck, M., Siebenrock, K. A., Ganz, R., & Leunig, M. (2004). Anterior femoroacetabular impingement: Part I. techniques of joint preserving surgery. *Clinical Orthopaedics & Related Research*, 418, 61-66.

Leardini, A., Chiari, L., Della Croce, U., & Cappozzo, A. (2005). Human movement analysis using stereophotogrammetry: part 3. soft tissue artifact assessment and compensation. *Gait & Posture*, 21(2), 212-225.

Lerner, D., Reed, J. I., Massarotti, E., Wester, L. M., & Burke, T. A. (2002). The work limitations questionnaire's validity and reliability among patients with osteoarthritis. *Journal of Clinical Epidemiology*, 55(2), 197-208.

Leunig, M., Beck, M., Woo, A., Dora, C., Kerboull, M., & Ganz, R. (2003). Acetabular rim degeneration: A constant finding in the aged hip. *Clinical Orthopaedics & Related Research*, 413, 201-207.

- Leunig, M., Casillas, M. M., Hamlet, M., Hersche, O., Notzli, H., Slongo, T., & Ganz, R. (2000). Slipped capital femoral epiphysis: Early mechanical damage to the acetabular cartilage by a prominent femoral metaphysis. *Acta Orthopaedica Scandinavica*, 71(4), 370-375.
- Leunig, M., & Ganz, R. (2005). [Femoroacetabular impingement. A common cause of hip complaints leading to arthrosis]. *Unfallchirurg*, 108(1), 9-10.
- Leunig, M., Beck, M., Dora, C., & Ganz, R. (2005). Femoroacetabular impingement: Etiology and surgical concept. *Operative Techniques in Orthopaedics*, 15(3), 247-255.
- Macfarlane, R. J., & Haddad, F. S. (2010). The diagnosis and management of femoroacetabular impingement. *Annals of the Royal College of Surgeons of England*, 92(5), 363-367.
- Mardones, R. M., Gonzalez, C., Chen, Q., Zobitz, M., Kaufman, K. R., & Trousdale, R. T. (2005). Surgical treatment of femoroacetabular impingement: Evaluation of the effect of the size of the resection. *Journal of Bone & Joint Surgery - American Volume*, 87(2), 273-279.
- Martin, R. L., & Philippon, M. J. (2007). Evidence of validity for the hip outcome score in hip arthroscopy. *Arthroscopy*, 23(8), 822-826.
- Martin, R. L., Kelly, B. T., & Philippon, M. J. (2006). Evidence of validity for the hip outcome score. *Arthroscopy: The Journal of Arthroscopic & Related Surgery*, 22(12), 1304-1311.

- Martin, R. L., & Philippon, M. J. (2008). Evidence of reliability and responsiveness for the hip outcome score. *Arthroscopy: The Journal of Arthroscopic & Related Surgery*, 24(6), 676-682.
- Murphy, S., Tannast, M., Kim, Y. J., Buly, R., & Millis, M. B. (2004). Debridement of the adult hip for femoroacetabular impingement: Indications and preliminary clinical results. *Clinical Orthopaedics & Related Research*, 429, 178-181.
- Murray, R.O. (1965). The Aetiology of Primary Osteoarthritis of the Hip. *British Journal of Radiology*, 38, 810-824.
- Myers, S. R., Eijer, H., & Ganz, R. (1999). Anterior femoroacetabular impingement after periacetabular osteotomy. *Clinical Orthopaedics & Related Research*, 363, 93-99.
- Ng, V. Y., Arora, N., Best, T. M., Pan, X., & Ellis, T. J. (2010). Efficacy of surgery for femoroacetabular impingement: A systematic review. *American Journal of Sports Medicine*, 38(11), 2337-2345.
- Nho, S. J., Magennis, E. M., Singh, C. K., & Kelly, B. T. (2011). Outcomes after the arthroscopic treatment of femoroacetabular impingement in a mixed group of high-level athletes. *American Journal of Sports Medicine*, 39(Suppl), 14S-9S.
- Notzli, H. P., Wyss, T. F., Stoecklin, C. H., Schmid, M. R., Treiber, K., & Hodler, J. (2002). The contour of the femoral head-neck junction as a predictor for the risk of anterior impingement. *Journal of Bone & Joint Surgery - British Volume*, 84(4), 556-560.

- Ochoa, L. M., Dawson, L., Patzkowski, J. C., & Hsu, J. R. (2010). Radiographic prevalence of femoroacetabular impingement in a young population with hip complaints is high. *Clinical Orthopaedics & Related Research*, 468(10), 2710-2714.
- Parvizi, J., Leunig, M., & Ganz, R. (2007). Femoroacetabular impingement. *Journal of the American Academy of Orthopaedic Surgeons*, 15(9), 561-570.
- Peterson, J., Giordano, B., Meyer, J., Snibbe, J. & Powers, C. (2011, June). Alterations in hip and pelvis kinematics during running in persons with femoroacetabular impingement. Presented at the American College of Sports Medicine (ACSM) 58th Annual Conference, Denver, CO.
- Pfarrmann, C. W., Mengiardi, B., Dora, C., Kalberer, F., Zanetti, M., & Hodler, J. (2006). Cam and pincer femoroacetabular impingement: Characteristic MR arthrographic findings in 50 patients. *Radiology*, 240(3), 778-785.
- Philippon, M. J., Maxwell, R. B., Johnston, T. L., Schenker, M., & Briggs, K. K. (2007). Clinical presentation of femoroacetabular impingement. *Knee Surgery, Sports Traumatology, Arthroscopy*, 15(8), 1041-1047.
- Philippon, M. J., & Schenker, M. L. (2006). Arthroscopy for the treatment of femoroacetabular impingement in the athlete. *Clinics in Sports Medicine*, 25(2), 299-308.
- Philippon, M., Schenker, M., Briggs, K., & Kuppersmith, D. (2007). Femoroacetabular impingement in 45 professional athletes: Associated pathologies and return to sport

following arthroscopic decompression. *Knee Surgery, Sports Traumatology, Arthroscopy*, 15(7), 908-914.

Philippon, M. J., Yen, Y. M., Briggs, K. K., Koppersmith, D. A., & Maxwell, R. B. (2008). Early outcomes after hip arthroscopy for femoroacetabular impingement in the athletic adolescent patient: A preliminary report. *Journal of Pediatric Orthopedics*, 28(7), 705-710.

Philippon, M. J., & Schenker, M. L. (2005). Athletic hip injuries and capsular laxity. *Operative Techniques in Orthopaedics*, 15(3), 261-266.

Reichenbach, S., Juni, P., Werlen, S., Nuesch, E., Pfirrmann, C. W., Trelle, S., Leunig, M. (2010). Prevalence of cam-type deformity on hip magnetic resonance imaging in young males: A cross-sectional study. *Arthritis Care & Research*, 62(9), 1319-1327.

Reid, G. D., Reid, C. G., Widmer, N., & Munk, P. L. (2010). Femoroacetabular impingement syndrome: An underrecognized cause of hip pain and premature osteoarthritis? *Journal of Rheumatology*, 37(7), 1395-1404.

Reynolds, D., Lucas, J., & Klaue, K. (1999). Retroversion of the acetabulum. A cause of hip pain. *Journal of Bone & Joint Surgery - British Volume*, 81(2), 281-288.

Richardson, Sara. (2012). Normal data for proposed compensatory gait patterns, muscle strength, and muscle activation in healthy individuals with no knee symptoms. Unpublished manuscript.

- Rylander, J. H., Shu, B., Andriacchi, T. P., & Safran, M. R. (2011). Preoperative and postoperative sagittal plane hip kinematics in patients with femoroacetabular impingement during level walking. *American Journal of Sports Medicine*, 39(Suppl), 36S-42S.
- Shu, B., Rylander, J.H., & Andriacchi, T.P. (2010). Femoroacetabular Impingement Patients Exhibit Hip Flexion Angle Abnormalities During Level Walking. *Medicine and Science in Sports and Exercise*, 42(5), 21.
- Samora, J. B., Ng, V. Y., & Ellis, T. J. (2011). Femoroacetabular impingement: A common cause of hip pain in young adults. *Clinical Journal of Sport Medicine*, 21(1), 51-56.
- Sampson, T. G., M, & D. (2005). Arthroscopic treatment of femoroacetabular impingement. *Techniques in Orthopaedics.Hip Arthroscopy*, 20(1), 56-62.
- Seldes, R. M., Tan, V., Hunt, J., Katz, M., Winiarsky, R., & Fitzgerald, R. H., Jr. (2001). Anatomy, histologic features, and vascularity of the adult acetabular labrum. *Clinical Orthopaedics & Related Research*, 382, 232-240.
- Siebenrock, K. A., Schoeniger, R., & Ganz, R. (2003). Anterior femoro-acetabular impingement due to acetabular retroversion. *Journal of Bone & Joint Surgery, American Volume*, 85(2), 278.
- Stulberg S D, Harris W H. Acetabular dysplasia and development of osteoarthritis of hip. Proceedings of the second open scientific meeting of the hip society. St.Louis, C.V.Mosby. 1974: 82-93.

Sutter, R., Dietrich, T., Zingg, P., & Pfirramann, C. (2012). How Useful Is the Alpha Angle for Discriminating between Symptomatic Patients with Cam-type Femoroacetabular Impingement and Asymptomatic Volunteers? *Radiology*. Epub ahead of print, Retrieved June 5th, 2012 from:

<http://radiology.rsna.org/content/early/2012/05/24/radiol.12112479.short>.doi:

10.1148/radiol.12112479

Tannast, M., Goricki, D., Beck, M., Murphy, S. B., & Siebenrock, K. A. (2008). Hip damage occurs at the zone of femoroacetabular impingement. *Clinical Orthopaedics & Related Research*, 466(2), 273-280.

Tanzer, M., & Noiseux, N. (2004). Osseous abnormalities and early osteoarthritis: The role of hip impingement. *Clinical Orthopaedics & Related Research*, 429, 170-177.


Wagner, S., Hofstetter, W., Chiquet, M., Mainil-Varlet, P., Stauffer, E., Ganz, R., & Siebenrock, K. A. (2003). Early osteoarthritic changes of human femoral head cartilage subsequent to femoro-acetabular impingement. *Osteoarthritis & Cartilage*, 11(7), 508-518.

Ware, J., Jr, Kosinski, M., & Keller, S. D. (1996). A 12-item short-form health survey: Construction of scales and preliminary tests of reliability and validity. *Medical Care*, 34(3), 220-233.

Winter, D.A. (1984). Kinematic and Kinetic Patterns in Human Gait: Variability and Compensating Effects. *Human Movement Science*, 3, 51-76.

- Winter, D. A. (1989). Biomechanics of normal and pathological gait: Implications for understanding human locomotor control. *Journal of Motor Behavior*, 21(4), 337-355.
- Wisniewski, S. J., & Grogg, B. (2006). Femoroacetabular impingement: An overlooked cause of hip pain. *American Journal of Physical Medicine & Rehabilitation*, 85(6), 546-549.
- Yuan, B. J., Sierra, R. J., & Trousdale, R. T. (2008). Femoral-acetabular impingement. *Orthopedics*, 31(9), 890-892.

Appendix A Letter of Information and Consent



Letter of Information

Title of Research: Identifying Gait Abnormalities in patients with Femoroacetabular Impingement Syndrome

Principal Investigator

Dr. Kevin Willits, Fowler Kennedy Sports Medicine Clinic, 3M Centre, UWO, London, Ontario, N6A 3K7

Phone: 519 xxx-xxxx Ext. xxxxx

The purpose of this letter is to provide you with the information you require to make an informed decision about participating in this research.

Hip pain is a common condition. Abnormal bone contact and pinching of the soft tissue in the hip has been identified as a frequent cause of hip pain. This condition is called Femoroacetabular Impingement (FAI). A diagnosis of FAI is usually made following physical examination by a clinician and imaging, such as x-rays and an MRI. Some clinicians suggest that patients diagnosed with FAI show abnormal gait (i.e. walking patterns) and range of motion. However, no study has directly measured whether people who are diagnosed with FAI show gait abnormalities during level walking when compared to individuals without hip complaints.

You are being invited to participate in this study because you are between the ages of 18 and 80 years old, and you have been diagnosed with FAI. This research study will assess the walking patterns in patients with FAI and compare them to the walking patterns of individuals without any history of problems about the hip. We expect that 34 patients will participate in this study.

Procedure

As part of your normal clinic visit, you will undergo x-rays of your hip and a physical examination by one of the orthopaedic surgeons. If the surgeon suspects FAI, he will recommend an MRI of your hip prior to surgery. The MRI is part of usual care.

If you agree to participate in this study you will be asked to undergo a walking test (also called a gait analysis). The gait analysis will take place prior to your surgery and again 6 months after your surgery. These gait analyses will take place in the Wolf Orthopaedic Biomechanics lab located at the Fowler Kennedy Sports Medicine Clinic. Each gait analysis will require approximately 60 minutes of your time. We will evaluate your gait using an eight-camera motion capture system that is connected to plate in the floor that measures force. You will be asked to walk barefoot approximately 8 meters at a

self-selected pace across the laboratory during testing. The cameras will follow several reflective markers that will be placed on your skin over your feet, knees, hips, arms, and shoulders. These markers are fastened to your skin with double sided tape and are removed easily, but may cause some pulling if the tape becomes stuck to your hair. To assist in the placement of the markers, it is asked that you wear shorts or tights and a t-shirt or tank top to the lab.

Participation in this study will require you to complete 5 short questionnaires, as well as allowing us to gather some demographic information like your birth date, height and weight. The questionnaires for this study and the Hip Arthroscopy Registry are identical – so if you are already participating in the Hip Arthroscopy Registry, we will not require you to complete the questionnaires again. Instead, the only additional task will be the gait analyses.

Risks

There are no known health risks associated with participating in this study. The data that is collected from you is protected by a username and password. It travels in a scrambled format to a server (storage computer) that is located in Toronto. The company that houses the server is a professional company with extremely high standards of physical and virtual security. We want to let you know however, that even with this high level of security, there is always a remote chance that your information could be accessed or “hacked” by someone who is not supposed to have your information. If we became aware that this had happened, we would inform you immediately.

Benefits

There are no direct benefits to you for participating in this study; however your participation may help inform surgeons and physiotherapists about areas to focus on during surgery or rehabilitation either before or after surgery.

Compensation

We will reimburse your parking expenses at the Fowler Kennedy Sport Medicine Clinic during your study participation.

Voluntary Participation:

Your participation in this study is voluntary. You may refuse to participate, refuse to answer any questions or withdraw from the study at any time with no effect on your future care. Should you choose to withdraw from this study, we will keep all data obtained up to the point that you chose to withdraw.

Participation in this study does not prevent you from participating in any other research studies at the present time or future. If you are participating in another research study, we ask that you please inform of us of your participation. You do not waive any legal rights by signing the consent form.

Request for Study Results:

Should you decide to participate and want to receive a copy of the study results, please provide your contact information on a separate piece of paper. Once the study has been published, a copy will be mailed to you. Please note that the results of this study are not expected for at least 5 years. Should your mailing information change, please let us know.

Confidentiality:

All information will be kept in strict confidence. Upon agreeing to participate in this study, you will be assigned a unique number that will be used for all your information and data collection. Data that is collected will be username and password protected and stored on a server located in Toronto through a scrambled format. Your identifying information will not appear on the database used to analyze data. In any publication, presentation or report, your name will not be used and any information that discloses your identity will not be released or published. Representatives of The University of Western Ontario Health Sciences Research Ethics Board may require access to your study related records or may follow up with you to monitor the conduct of the study.

Questions:

If you have questions about the conduct of the study or your rights as a research participant, you may contact Dr. David Hill, Scientific Director, Lawson Health Research Institute (519) xxx-xxxx.

If you have questions or concerns about your surgery or physiotherapy, please contact your orthopaedic surgeon. If you have any questions about this research, please contact Brook Russell at [REDACTED] or Dr. Dianne Bryant at 519-xxx-xxxx ext. xxxxx or [REDACTED] or your orthopaedic surgeon.

This letter is yours to keep.

Sincerely,

Dr. Kevin Willits, MD, FRCSC
Dr. Douglas Naudie, MD, FRCSC
Brook Russell, BSc, MSc Candidate



Letter of Consent

Identifying Gait Abnormalities in patients with Femoroacetabular Impingement Syndrome

I have read the accompanying letter of information and have had the nature of the study explained to me and I agree to participate. All questions have been answered to my satisfaction.

Printed Name of the Participant	Signature of the Participant	Date

Printed Name of the Person Responsible for Obtaining Informed Consent	Signature of the Person Responsible for Obtaining Informed Consent	Date

- I would like to receive a copy of the results of this study.

Please mail to:

Appendix C Permission letter – Nucleus Inc.

Hi Brook,

Thank you for your interest in Nucleus Medical Media. Based on your inquiry, your institution would be an excellent candidate for licensing the Scientific & Medical Art (SMART) Imagebase as a library resource. Under our annual license agreement, all faculty and students at your school may download any of the 20,000+ medical illustrations and animations in our database to use in classroom presentations, slide shows, web sites, handouts, poster sessions, and other educational, non-commercial projects.

The SMART Imagebase is ideal for educators and students of biology, anatomy, physiology, pathology, molecular biology, trauma, embryology, histology, surgery and other life science topics. In addition to the images, there are online editing and publishing tools for sharing projects. I urge you to contact your library/media services department to let them know about this valuable resource, and to request them to sign up for a free 30 day trial from our distributor, EBSCO Publishing.

You can find more information, including contact information from EBSCO Publishing, by visiting this web address:

<http://www.smartimagebase.com/contact>

The illustration requested and Nucleus copyright line are attached for your thesis. If you have any questions, please do not hesitate to contact me directly.

Best Regards,

Niky Jones

.....
Content Licensing Coordinator
nscragg@nucleusinc.com
<http://www.nucleusinc.com>
<http://www.linkedin.com/in/nikyj>

Toll free: 800.333.0753
Phone: 770.953.6566
Fax: 770.805.0430

Nucleus Medical Media, Inc.
1275 Shiloh Road
Suite 3130
Kennesaw, GA 30144

Appendix D Permission letter – American Journal of Roentgenology

04/11/2012 10:13 7037295913

ARRS

PAGE 02/02

American Roentgen Ray Society

Brook Russell
 University of Western Ontario
 1996 Riverbend Road
 London ON N6K0A1

04/10/12

Invoice No: **C 07663**

Canada

Thank you for your request for permission to reproduce the following material from the
American Journal of Roentgenology.

0

AJR
 2007;188:1540-
 1552

Tannast M., Siebenrock
 K.A., Anderson S.E., et al.

Femoroacetabular Impingement: Radiographic
 Diagnosis—What the Radiologist Should Know
 Figure 1, 2, & 3

3

0


Order Total \$0.00

Permission is effective when signed below by ARRS authorized representative. Payment if applicable, may be made by check or credit card. Tax is not included in the price, if your country requires a tax, you will have to calculate the tax separately. Permission will not be granted until invoice is paid in full. Please return this form with payment.

The following conditions apply:

1. Use of the following credit line: Reprinted with permission from the American Journal of Roentgenology.
2. One-time, non-exclusive use only to include on-line versions and/or CD-ROMS. This permission does not include revisions or future editions.
3. Translations of copyrighted text is prohibited.

We regret that ARRS cannot supply original or digital material for reproduction.

ARRS authorized signature:  Date 4/11/12

Payment Options

Check (made out to ARRS in U.S. funds drawn on a U.S. bank)

 Visa American Express Master Card

Card # _____ Exp. Date _____

Signature: _____ Phone # _____

Send remittance to: 44211 Slatestone Court Leesburg, VA 20176-5109
 Or fax Credit Card # to 703-729-5913

Curriculum Vitae

NAME: Brook A Russell

ACADEMICS
Post-Secondary
Education and
Degrees

University of Western Ontario
London, Ontario, Canada
2006-2010
BSc Honors Kinesiology

University of Western Ontario
London, Ontario, Canada
2010-Present
MSc. (c) Kinesiology – Sports Medicine

Honours and
Awards:

Western Graduate Research Scholarship (WGRS)
2010-2012

Graduate Teaching Award Nominee
2012

Related Work
Experience:

Teaching Assistant
Anatomy
University of Western Ontario
2010-2012

Teaching Assistant
Athletic Injuries
University of Western Ontario
2010-2012