

2005

Robot Assisted Ultrasound Imaged Guided Interstitial Lung Brachytherapy in a Porcine Model

Richard A. Malthaner

University of Western Ontario, richard.malthaner@lhsc.on.ca

Edward Yu

University of Western Ontario, edward.yu@lhsc.on.ca

Jerry J. Battista

University of Western Ontario, j2b@uwo.ca

Chris Blake

Robarts Research Institute, cblake@imaging.robarts.ca

Donal Downey

London Health Sciences Centre, London, ON

See next page for additional authors

Follow this and additional works at: <https://ir.lib.uwo.ca/oncpres>



Part of the [Bioimaging and Biomedical Optics Commons](#), [Oncology Commons](#), and the [Surgery Commons](#)

Citation of this paper:

Malthaner, Richard A.; Yu, Edward; Battista, Jerry J.; Blake, Chris; Downey, Donal; and Fenster, Aaron, "Robot Assisted Ultrasound Imaged Guided Interstitial Lung Brachytherapy in a Porcine Model" (2005). *Oncology Presentations*. 6.

<https://ir.lib.uwo.ca/oncpres/6>

Authors

Richard A. Malthaner, Edward Yu, Jerry J. Battista, Chris Blake, Donal Downey, and Aaron Fenster

Robot Assisted Ultrasound Imaged Guided Interstitial Lung Brachytherapy in a Porcine Model

Richard A. Malthaner, Edward Yu, Jerry J. Battista, Chris Blake, Donal Downey, Aaron Fenster

CSTAR and the University of Western Ontario, London, Ontario, Canada

1. Introduction

We set out to see if permanent interstitial brachytherapy seeds could be safely and reproducibly inserted thoracoscopically with the ZEUS Robotic system and intraoperative ultrasound into in-vivo porcine lungs.



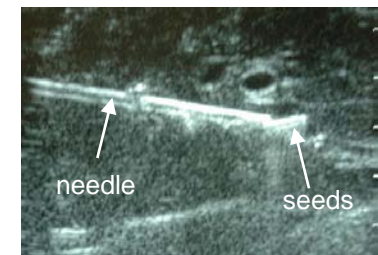
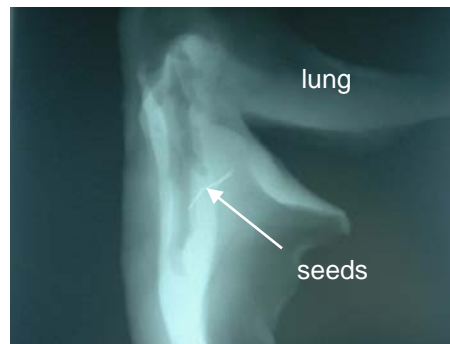
The L9-5 thoracoscopic ultrasound transducer was inserted through the anterior thoracoport and manipulated with the other robotic arm. The images were captured using the HDI 5000 sonogram (ATL, Bothell, WT). Non-radioactive “dummy” seeds were deployed into the left lung using a custom designed hydraulic injector. Two chronic animals were followed with serial radiographs at one week, one month and three months to assess the long term safety of potential seed migration. Computed tomograms were also performed at three months .

3. Results

All 8 animals survived the procedures without intraoperative bleeding or air leaks. The ZEUS system performed well and was able to remotely manipulate the ultrasound transducer and needle to allow deployment of the seeds. The ultrasound images were of good quality and visualized the needle insertion and seed deployment. There was no evidence of seed migration in the two chronic animals.

2. Methods

Six acute pigs underwent robot assisted thoracoscopy using the ZEUS™ system. A 30° endoscope with video camera was manipulated using the voice activated AESOP™. The Cook brachytherapy needle was inserted into the lung parenchyma using one of the ZEUS robotic arms.



4. Conclusion

We have demonstrated that interstitial brachytherapy seeds can be safely inserted into lungs using the ZEUS robotic system with ultrasound image guidance.