

| | |
|------------------------------------|--|
| Title | Clinical evaluation of narrow platform Roxolid™ implants in patients with hypodontia at 1 year |
| Author(s) | Allen, P. Finbarr; Anweigi, Lamyia; Brady, Paul; Sleeman, Duncan |
| Publication date | 2014-04 |
| Original citation | ALLEN, P. F., ANWEIGI, L., BRADY, P., & SLEEMAN, D. (2014) 'Clinical evaluation of narrow platform Roxolid™ implants in patients with hypodontia at 1 year'. International Team for Implantology (ITI) World Symposium. Geneva, 24-26 April. |
| Type of publication | Conference item |
| Link to publisher's version | http://www.iti.org/worldsymposium2014/ Access to the full text of the published version may require a subscription. |
| Item downloaded from | http://hdl.handle.net/10468/2528 |

Downloaded on 2017-02-12T11:42:36Z



UCC

University College Cork, Ireland
Coláiste na hOllscoile Corcaigh



CORK UNIVERSITY
DENTAL
SCHOOL AND HOSPITAL

Clinical evaluation of narrow platform Roxolid™ implants in patients with hypodontia at 1 year

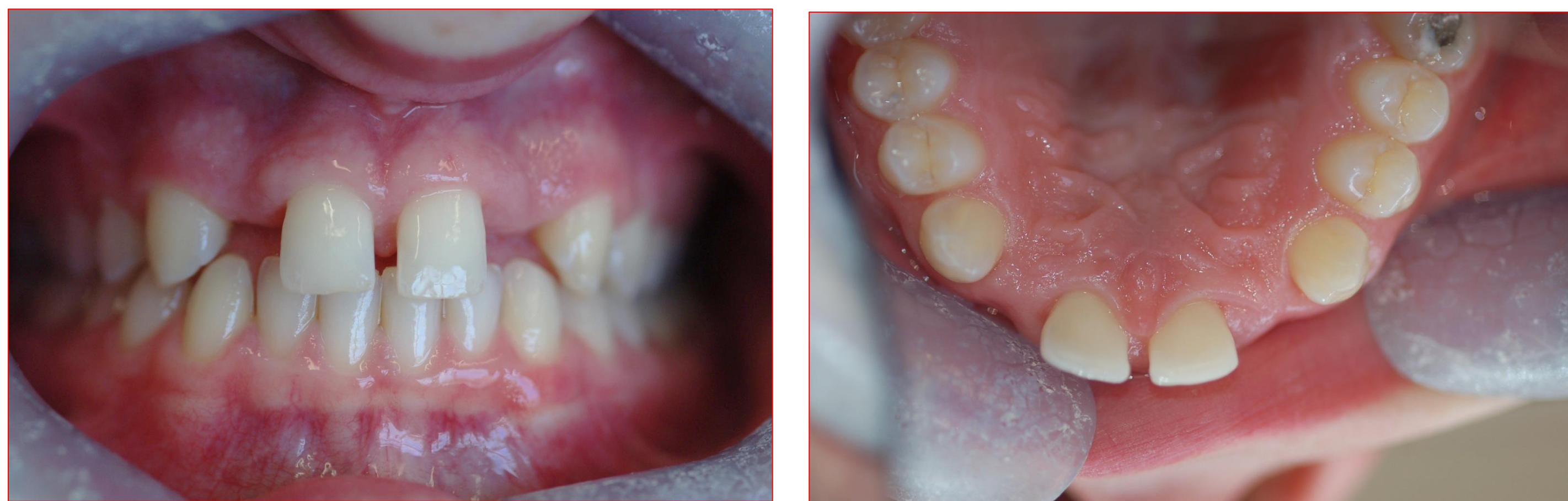Allen PF¹, Anweigi L¹, Brady P², Sleeman D²

¹Restorative Dentistry, ²Oral Surgery, Cork University Dental School and Hospital, University College Cork, Ireland



Background: Congenital absence of teeth, commonly known as hypodontia, has a reported prevalence of between 2 and 6%. It presents many clinical challenges, and it has a significant impact on psycho-social well being of patients. A typical presentation of mild hypodontia is shown in **Figure 1**. Rehabilitation of these patients with implants is complicated by small bone volume, and it requires multi-disciplinary input. Potential sites for implants in the anterior maxilla are compromised by low bone volume. A novel narrow implant made with TiZr alloy, Roxolid™ (Straumann AG), has been developed which offers the potential to place implants in these patients with minimal or no requirement for bone augmentation surgery.

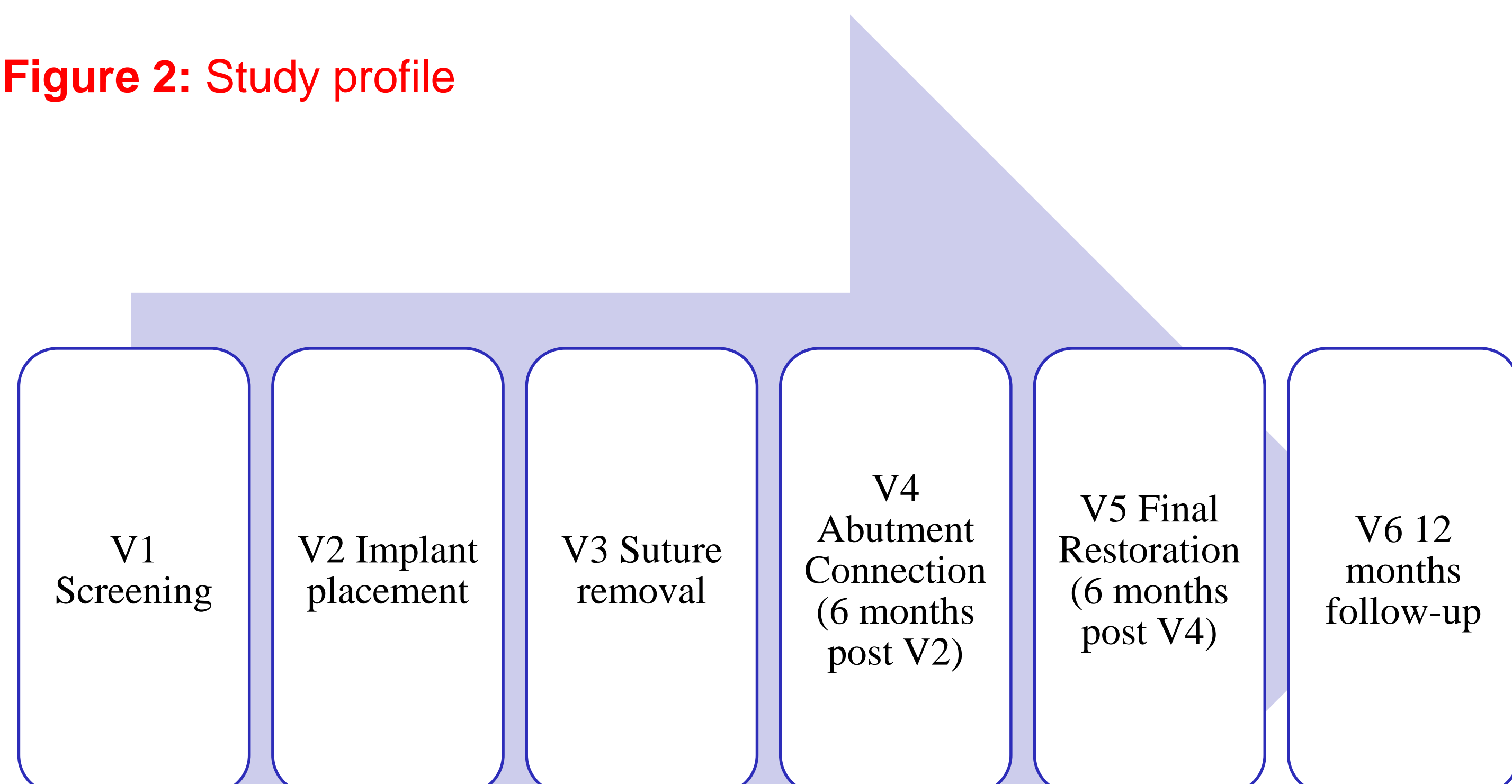
Figure 1: Patient with congenital absence of maxillary lateral incisors



Objectives: To undertake a prospective clinical study to evaluate the clinical performance of the Roxolid™ bone level, narrow platform implant in the restoration of missing teeth in the anterior maxilla of patients with mild hypodontia.

Method: Sixteen patients (9 female, 7 male; age range 18-27 years) with congenital absence of teeth in the anterior maxilla who met inclusion criteria were invited to participate in the study. All of the patients were recruited at Cork Dental School and Hospital, Ireland. Prior to treatment, details of dental status, plaque and bleeding scores were recorded. Patients also completed an oral health related quality of life measure (OHIP-20), and satisfaction with appearance was measured using a visual analogue scale (VAS). Upon completion of orthodontic treatment and detailed restorative treatment planning, implants were placed using a standardized two stage surgical protocol. Surgical stents modelled on a diagnostic wax-up were used in all cases. Implant stability was recorded at the time of implant placement (T0) using a resonance frequency analyser (Ostell™) and measured using implant stability quotients (ISQ). Standardised periapical radiographs were recorded using customized Rinn holders at each data collection point. These measurements were repeated at abutment connection (T1) and at the time of placement of the final restoration (T2). At the 12 month post treatment follow-up review (T3), patients had a full dental and periodontal examination and completed an OHIP-20 questionnaire and a VAS (**Figure 2**). The outcomes of interest in the study were implant survival, radiographic bone changes and the impact of treatment on quality of life.

Figure 2: Study profile



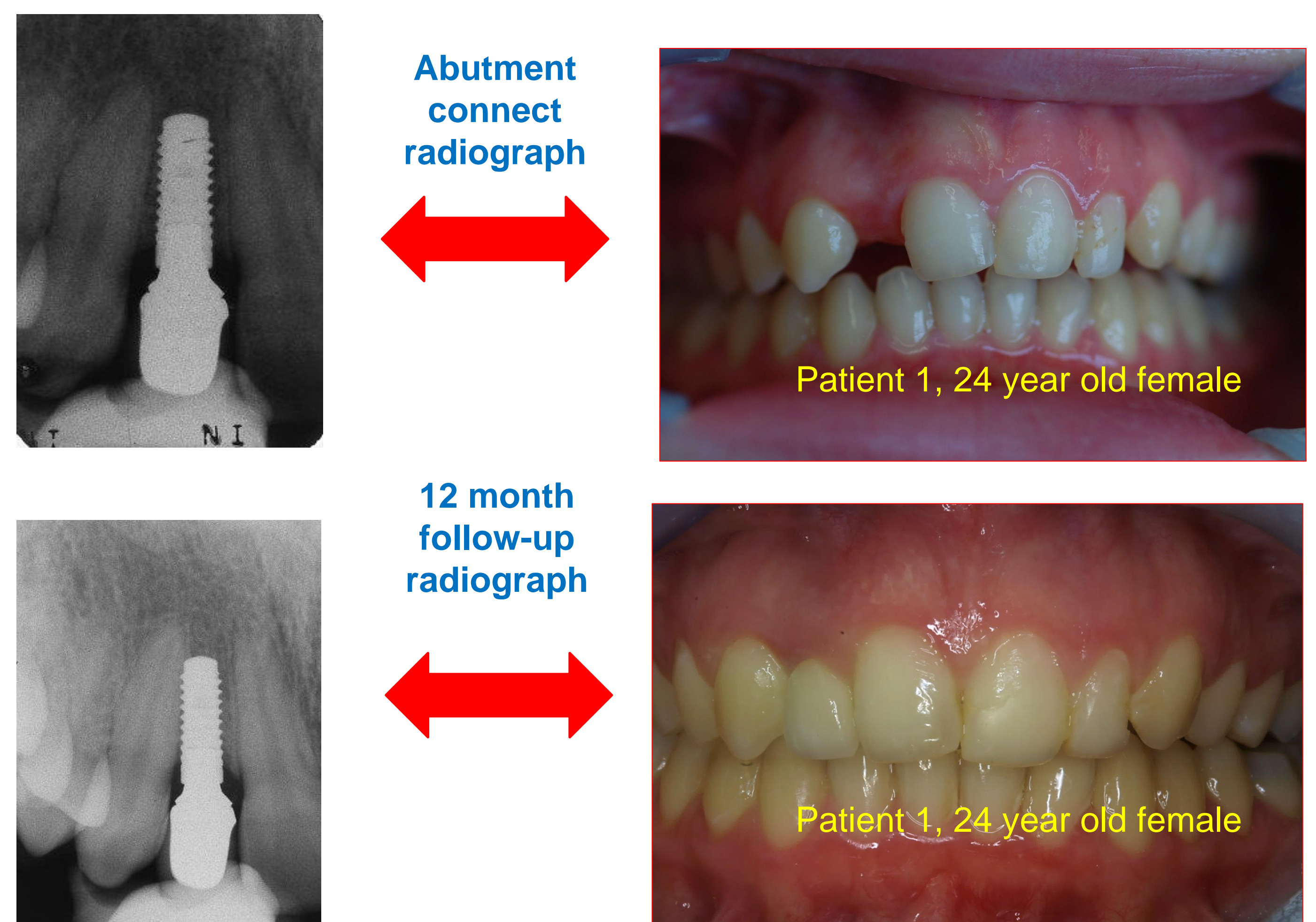
Results: Of the 16 patients currently enrolled in the study, 12 have so far completed one year of follow up. 18 Roxolid™ bone level SLActive, 3.3mm diameter implants were placed in these patients. The implants used were 10mm and 12mm in length. All surgical procedures proceeded uneventfully, although alveolar ridge augmentation was required at four surgical sites (**Figure 3**).

Mean **implant stability values** measured using resonance frequency analysis increased from 69.6 at surgical placement to 73.8 at time of placement of the restoration. Bone loss around the implants was minimal during the first year of function, and a typical profile is shown in **Figure 4**.

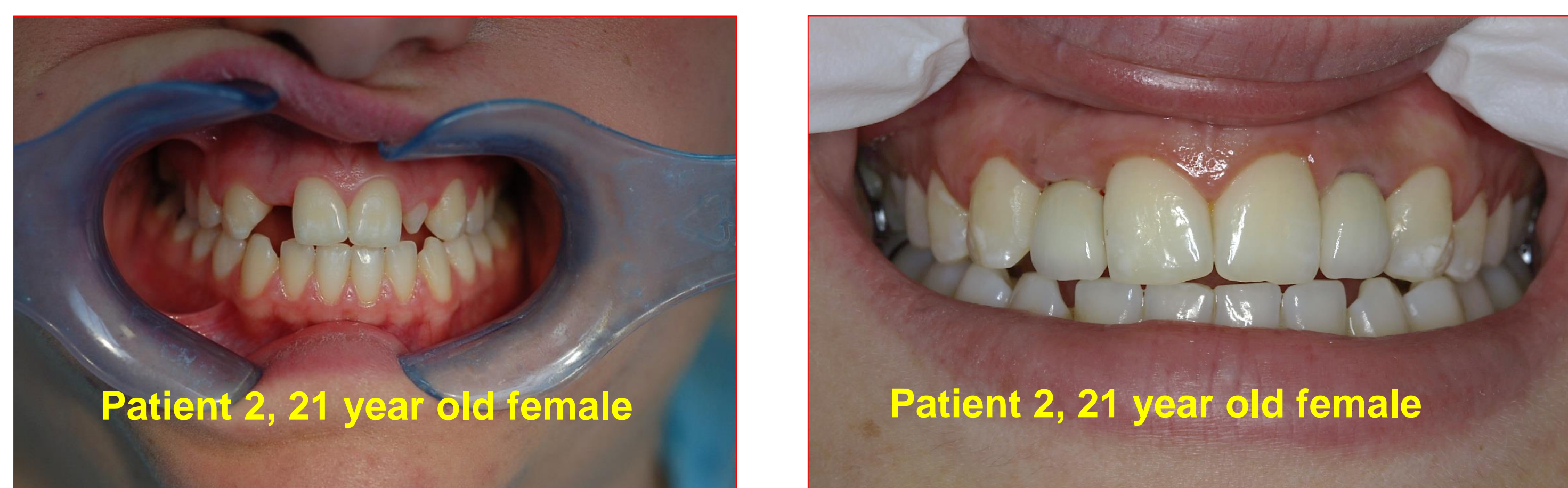
Figure 3: Surgical placement left lateral incisor region

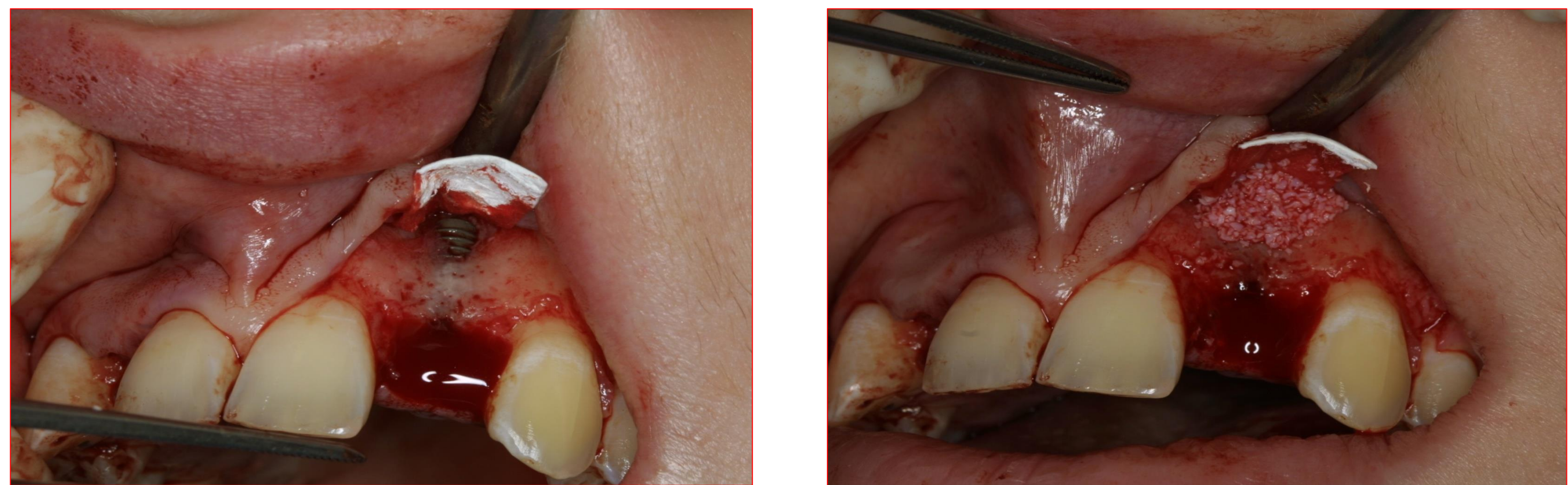

Figure 4: Radiographic images of implant at V4 and V6



Patient satisfaction with the cosmetic outcomes from treatment was very high, with satisfaction scores at one year ranging from 85/100 to 98/100. In terms of **oral health related quality of life**, there was a significant improvement in pre-post treatment OHIP -20 scores ($P < 0.05$, paired t-test).



Conclusions: It was possible to place narrow platform Roxolid™ implants in all of the patients with minimal or no ridge augmentation. Good implant stability values were achieved. There has been minimal bone loss after 12 months. Patients reported a high level of satisfaction with the cosmetic outcome of treatment, and oral health related quality of life improved following treatment.

This study was supported by Institut Straumann AG, (study protocol number IIS 11/09)