

## Case Report

# A Case of Medical Malpractice; Misdiagnosis of Methamphetamine-related Cardiac Complications



Shayesteh Ashrafi Esfahani<sup>1\*</sup> , Masoud Ghadipasha<sup>1</sup> , Babak Salahshour<sup>1</sup> , Maryam Akhgari<sup>1</sup> 

1. Legal Medicine Research Center, Iranian Legal Medicine Organization, Tehran, Iran.



**Citation:** Esfahani SA, Ghadipasha M, Salahshour B, Akhgari M. A Case of Medical Malpractice; Misdiagnosis of Methamphetamine-related Cardiac Complications. *International Journal of Medical Toxicology and Forensic Medicine*. 2024; 14(2):E44066. <https://doi.org/10.32598/ijmtfm.v14i2.44066>

 <https://doi.org/10.32598/ijmtfm.v14i2.44066>

### Article info:

**Received:** 10 Dec 2023

**First Revision:** 15 Jan 2024

**Accepted:** 24 Jan 2024

**Published:** 29 May 2024

### Keywords:

Medical negligence,  
Malpractice,  
Methamphetamine abuse,  
Cardiac complication

## ABSTRACT

**Background:** Professional neglect is a civil responsibility for any specialist or individual with a specific skill, including therapists, and is not limited to any particular profession.

**Case Presentation:** A man 41-year-old drug abuser was diagnosed with a heart problem due to methamphetamine abuse. Despite his drug history, he was once admitted to the emergency room for chest pain, where acetaminophen and diazepam were prescribed. For the second time, he went to another medical center due to continued chest pain, and due to the suspicion of contracting COVID-19, a CT scan of the chest was performed, yielding negative results, and then he was discharged. The patient was found deceased in his bed the following day. An autopsy revealed a thinned heart wall, subendocardial hemorrhages, and severe atherosclerosis. Methamphetamine, amphetamine, and acetaminophen were detected in urine samples, and ethanol was detected in blood and vitreous humor samples.

**Conclusion:** The case highlights the importance of medical negligence in treating patients with drug abuse.

### \* Corresponding Author:

**Shayesteh Ashrafi Esfahani, MD.**

**Address:** Legal medicine Research Center, Legal medicine Organization, Tehran, Iran.

**Tel:** +98 (21) 5516 2288

**E-mail:** [sh.ashrafi.es@gmail.com](mailto:sh.ashrafi.es@gmail.com)



Copyright © 2024 The Author(s).  
This is an open access article distributed under the terms of the Creative Commons Attribution License (CC-BY-NC: <https://creativecommons.org/licenses/by-nc/4.0/legalcode.en>), which permits use, distribution, and reproduction in any medium, provided the original work is properly cited and is not used for commercial purposes.

## Introduction

**P**rofessional neglect is not limited to a particular profession. It is a civil responsibility, in which any specialist or individual with a particular skill may be responsible for the implementation of that skill, and the therapist is not an exception to this rule [1].

If the doctor has not performed the necessary diagnostic, treatment, examination, follow-up, counseling, or guidance processes in accordance with the scientific and technical standards of medicine and this omission leads to harm to the patient, it is medical malpractice [2, 3].

In dealing with medical negligence, it is necessary to consider the difference between unwanted complications and medical errors. A side effect refers to harm that occurs during medical management, whereas malpractice involves failing to meet the standard level of care or providing substandard care [4].

The [World Health Organization \(WHO\)](#) considers healthcare safety to be a major global concern, with 3–16% of hospitalized patients worldwide experiencing an injury as a result of some type of medical intervention [5].

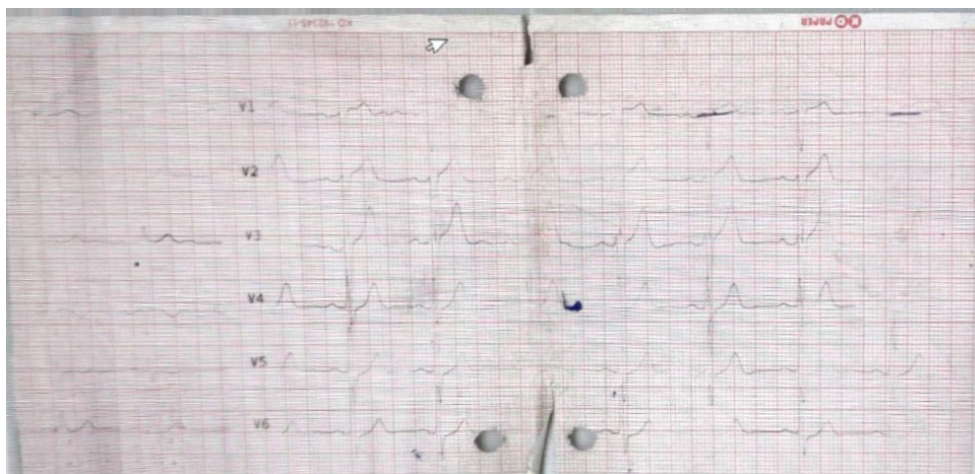
International reports indicate that medical complaints have been on the rise. There has been an increase in medical complaints internationally. Specifically, the [Tehran Forensic Medicine Organization](#) has seen a notable rise in complaints against medical personnel over a decade, with an annual increase of 95% from 134 cases in 1995 to 1270 cases in 2005 [6]. This trend has accelerated over the last ten years, culminating in a 27.2% increase in 2015 [7].

Medical negligence can have negative effects on the injured patient, such as physical and mental injuries, financial problems, job loss, reduced quality of life, and even death [8].

Given the growing concern over medical negligence in recent years and its significance, reducing malpractice litigation is imperative. Learning from previous malpractice claims can offer valuable insights into errors related to malpractice in clinical practice. Therefore, the purpose of this study was to identify a case of medical negligence that led to the death of a patient.

## Case Presentation

A 41-year-old man presented to the emergency department of the hospital with chest pain complaints. During his initial visit, it was determined that he did not have underlying diseases, such as diabetes, blood pressure, or blood lipids. He was not taking any special medicine but had a history of using methamphetamine and amphetamine. The physical examination revealed the following results: Blood pressure at 14.9 mm Hg, pulse rate at 80 b/min, respiratory rate at 14 breaths/minute, temperature at 37°C, slight sweating, and chest pain that did not radiate to other organs. To rule out a heart attack, the troponin level was measured and an electrocardiogram (ECG) ([Figure 1](#)) was performed. Diazepam and an intravenous acetaminophen infusion were administered to alleviate the pain. The patient was discharged based on the normal level of troponin and the absence of abnormalities found in the ECG. He returned to the emergency department once more due to ongoing central chest pain. A com-



**Figure 1.** ECG results at the patient's first visit

puted tomography (CT) scan of the chest was conducted to check for a COVID-19 infection, which reported no abnormal pulmonary findings, leading to his discharge again. Tragically, he was found deceased in his bed the following morning.

Following the patient's death, his family filed a complaint. Although the cause of death was not immediately evident, an autopsy was performed to determine the cause.

The autopsy findings were as follows:

**Anatomical characteristics:** The man was overweight and his height was 170 cm. His brain was edematous. The heart weight was 450 grams. Examination of the coronary arteries revealed severe and nearly complete blockage in the left coronary artery and severe but slightly less blockage in the right coronary artery. We found the hypertrophy of the heart's left ventricular muscles, dilatation of the right ventricle, thinning of the right ventricular wall, and a tiger skin pattern in the septum between the ventricles and the nucleus. There was evident hyperemia in the free wall of the left ventricle and subendocardial hemorrhage in the inner layer of the left ventricle.

**Pathology:** Old extensive infarction was seen in the myocardium in the context of chronic ischemic heart disease and also overall morphological changes in favor of the onset of acute infarction.

**Toxicology:** The urine contained methamphetamine, amphetamine, and acetaminophen, and the vitreous fluid included 4 mg/dL of ethanol. Urine, blood liver, gastric content, and bile samples were negative for other drugs.

**Cause of death:** The cause of death of the case was determined as an acute heart attack in the context of coronary artery disease, compounded by the history of methamphetamine and amphetamine use, as concluded by forensic medicine.

Following a thorough review of the case by the Forensic Medical Commission and the analysis of the patient's autopsy results, it was determined that the first medical center committed medical malpractice by inadequately following up with the patient and discharging him prematurely. The second medical center also committed medical malpractice due to neglecting the patient's cardiac symptoms and making an incorrect diagnosis (Table 1).

## Discussion

In this case study, we described a case of methamphetamine-induced cardiac disorder and fatality. The patient, presenting with chest pain and a history of methamphetamine and drug abuse, was not provided with appropriate care and clinical management. Methamphetamine use was proved by the patient and his family and further supported by forensic toxicology analysis results.

Drug abuse is a global issue, with 250 million people aged 15-64 years using illicit drugs. Methamphetamine is the second most frequently used drug, with 33,900,000 users in 2013. Cardiovascular complications are significant, leading to malignant hypertension, arrhythmias, and stroke, and are the leading causes of death [9, 10]. In the current study, the patient should have received more attentive care during his first hospital visit, including a re-evaluation of his ECG and heart enzymes. If these tests were normal, then discharge could be considered. Unfortunately, the focus at the second treatment center was solely on the suspicion of COVID-19 infection, completely overlooking the patient's cardiac symptoms, which may have been exacerbated by methamphetamine use.

Previous studies showed that major cardiac histopathology findings in methamphetamine-associated death cases were mild atherosclerosis, moderate to severe atherosclerosis, congestion, microscopic hemorrhage, myocardial fiber hypertrophy, perivascular fibrosis, focal degeneration/necrosis, myocardial ischemia, acute myocardial infarction, old subendocardial myocardial infarction, mural thrombosis, endocarditis and pericarditis [11]

In a systematic review study by Raeissi et al. regarding medical malpractice in Iran, the second and third types of complaints against physicians were negligence (29.2%) and imprudence or indiscretion (3.26%) [12].

As it was indicated in the present study, Alimohammadi et al. also reported a significant number of complaints due to the death of the patient [13, 14].

Alimohammadi et al. investigated the frequency of complaints and causes of malpractice among emergency medicine physicians in Tehran province between 2012 and 2015. They reported that acute myocardial infarction was the most frequent and chief complaint that caused death [13]. Thomas et al. found that failures in diagnosis or treatment were the predominant reasons for litigation against neurosurgeons involved in medical malpractice claims [14]. Gundogmus et al., in their analysis of medical malpractice cases in Turkey, identified diagnostic and therapeutic mistakes as the primary contributors to

**Table 1.** The legal medicine organization report of patient autopsy

Toxicological results
1. The urine contained methamphetamine, amphetamine, and acetaminophen and the result is negative immunochromatography for the presence of drugs and methadone. 2. In the vitreous fluid, 4 mg of ethyl alcohol (ethanol) was found by two tests by headspace method.
Pathology
480 gr, which has already been cut diagonally in the blood flow and transversely at the thickness of the myocardium. In the cuts that are made in the blood flow of the valves with a normal view of the coronary arteries and neck veins, there are atherosclerotic changes that lead to severe narrowing along the coronary arteries until the lumen of the vessel is closed.
Microscopic and diagnostics
1- In the examination of myocardial tissue, old infarction was seen. 2- Recent infarction 3- A set of morphological changes in favor of the onset of acute infarction was observed. 4- An evidence of epicarditis was seen. 5- coronary arteries have atherosclerotic changes in neovascularization and bleeding in atheroma plaque with severe lumen of the vein. 5- Hypertrophic cardiomyopathy
Cause of death
The cause of death of the case was determined as acute heart attack in the context of coronary artery disease, compounded by the history of methamphetamine and amphetamine use, as concluded by forensic medicine

medical failures. They suggested that retraining courses and collaboration with scientific associations could help reduce these errors. The study also highlighted that a lack of knowledge about legal issues and patient responsibilities contributed to an increase in complaints [15].

The Medical Council in Iran addresses professional misconduct among physicians and related professions through a significant legal regulation, titled “disciplinary regulation for investigating guild and professional misconduct of medical and associate professions”. This document stands as the most significant official document available on examples of healthcare malpractice claims in Iran. The solution to prevent medical negligence and malpractice lies first and foremost in educating healthcare professionals. Additionally, ongoing training to acquaint physicians with medical regulations and malpractice should be integrated into educational programs [16].

One of the most important strategies in preventing malpractice is the disclosure of malpractice in the workplace [17] even when this may be unpleasant or disappointing. Only in the context of genuine transparency, it is possible to find solutions to the acceptable concern about medical responsibility.

## Conclusion

Health policymakers should monitor the quality of healthcare services and emphasize the prevention of health risks. By advocating for ethical, technical, and legal training on medical and legal issues, they can further

mitigate medical malpractice by minimizing errors and failures.

## Ethical Considerations

### Compliance with ethical guidelines

There were no ethical considerations to be considered in this research.

### Funding

This research did not receive any grant from funding agencies in the public, commercial, or non-profit sectors.

### Authors' contributions

Conceptualization: Shayeṣṭeh Ashrafi Esfahani; Methodology, software, data analysis, investigation, resources, data correction, writing the original draft, supervision and project administration: All authors.

### Conflict of interest

The authors declared no conflict of interest.

## References

- [1] Sinamo N, Sibarani S, editors. Medical malpractice in the legal view. Paper presented at: Proceedings of the Tarumanagara International Conference on the Applications of Social Sciences and Humanities (TICASH 2019); 20 May 2020; Jakarta, Indonesia. [DOI:10.2991/assehr.k.200515.006]
- [2] Schiffrin BS, Cohen WR. The effect of malpractice claims on the use of caesarean section. *Best Practice & Research. Clinical Obstetrics & Gynaecology*. 2013; 27(2):269-83. [DOI:10.1016/j.bpobgyn.2012.10.004] [PMID]
- [3] Bury M, Gabe J. *The sociology of health and illness: A reader*. London: Routledge; 2013. [DOI:10.4324/9781315013015]
- [4] Sohn DH. Negligence, genuine error, and litigation. *International Journal of General Medicine*. 2013; 6:49-56. [DOI:10.2147/IJGM.S24256] [PMID] [PMCID]
- [5] Oyeboode F. Clinical errors and medical negligence. *Medical Principles and Practice*. 2013; 22(4):323-33. [DOI:10.1159/000346296] [PMID] [PMCID]
- [6] Ghadipasha M, Shirzad J, Toufighi H. [Assessment of medical negligence leading to death in legal medicine organization sessions between 1995 and 1999 (Persian)]. *Scientific Journal of Forensic Medicine*. 2002; 8(27):5-8. [Link]
- [7] Kazemi S, Riahi MA. [Sociological analysis of medical malpractice in Tehran: A mixed method study (Persian)]. *Journal of Social Problems of Iran*. 2020; 10(2):243-69. [Link]
- [8] Thomas J. The effect of medical malpractice. *Annals of Health Law Advance Directive*. 2010; 19:306-15. [Link]
- [9] Paratz ED, Cunningham NJ, MacIsaac AI. The cardiac complications of methamphetamines. *Heart, Lung & Circulation*. 2016; 25(4):325-32. [DOI:10.1016/j.hlc.2015.10.019] [PMID]
- [10] Won S, Hong RA, Shohet RV, Seto TB, Parikh NI. Methamphetamine-associated cardiomyopathy. *Clinical Cardiology*. 2013; 36(12):737-42. [DOI:10.1002/clc.22195] [PMID] [PMCID]
- [11] Akhgari M, Mobaraki H, Etemadi-Aleagha A. Histopathological study of cardiac lesions in methamphetamine poisoning-related deaths. *Daru*. 2017; 25(1):5. [DOI:10.1186/s40199-017-0170-4] [PMID] [PMCID]
- [12] Raeissi P, Taheri Mirghaed M, Sepehrian R, Afshari M, Rajabi MR. Medical malpractice in Iran: A systematic review. *Medical Journal of the Islamic Republic of Iran*. 2019; 33:110. [DOI:10.47176/mjiri.33.110] [PMID] [PMCID]
- [13] Alimohammadi H, Hatamabadi H, Khodayari A, Doukhtehchi Zadeh Azimi M. Frequency and causes of complaints against emergency medicine specialists in forensic medicine files; A cross-sectional study. *Archives of Academic Emergency Medicine*. 2019; 7(1):e11. [PMID] [PMCID]
- [14] Thomas R, Gupta R, Griessenauer CJ, Moore JM, Adeeb N, Motiei-Langroudi R, et al. Medical malpractice in neurosurgery: A comprehensive analysis. *World Neurosurgery*. 2018; 110:e552-9. [DOI:10.1016/j.wneu.2017.11.051] [PMID]
- [15] Gundogmus UN, Erdogan MS, Sehiralti M, Kurtas O. A descriptive study of medical malpractice cases in Turkey. *Annals of Saudi Medicine*. 2005; 25(5):404-8. [DOI:10.5144/0256-4947.2005.404] [PMID] [PMCID]
- [16] Rynecki ND, Coban D, Gantz O, Gupta R, Ayyaswami V, Prabhu AV, et al. Medical malpractice in orthopedic surgery: A westlaw-based demographic analysis. *Orthopedics*. 2018; 41(5):e615-20. [DOI:10.3928/01477447-20180621-06] [PMID]
- [17] Safdari R, Masuri N. [The importance of electronic proprietary registration system for referral complaints due to medical malpractice in the country's forensic medicine organization (Persian)]. *Iranian Journal of Forensic Medicine*. 2005; 11(2):99-106. [Link]