



## Ukrainian Journal of Nephrology and Dialysis

Scientific and Practical, Medical Journal

### Founders:

- State Institution «Institute of Nephrology NAMS of Ukraine»
- National Kidney Foundation of Ukraine

ISSN 2304-0238;  
eISSN 2616-7352

Journal homepage: <https://ukrjnd.com.ua>

### Clinical case reports

Desai A, Bennikal M, Bangari G, Janaky M, Manjunath R

doi: 10.31450/ukrjnd.4(76).2022.02

### Malpositioned dialysis catheters: A case series

SDM College of Medical Sciences and Hospital, SDM University,  
Karnataka, India

### Citation:

Desai A, Bennikal M, Bangari G, Janaky M, Manjunath R. Malpositioned dialysis catheters: A case series. Ukr J Nephrol Dial. 2022;4(76):10-15. doi: 10.31450/ukrjnd.4(76).2022.02.

### Article history:

Received July 25, 2022  
Received in revised form  
August 19, 2022  
Accepted August 28, 2022

**Abstract.** Hemodialysis catheters (HDC) are the commonly used vascular access for hemodialysis. Functioning access is essential for adequate dialysis. Dialysis catheter insertion under ultrasound guidance is now standard practice and has reduced the incidence of mechanical complications during catheter insertion. However, complications such as tip misplacement and puncture of the mediastinum cannot be prevented by ultrasound-guided procedures alone. We report four cases of abnormal positioning of HDC insertion and emphasize the importance of fluoroscopy or radiography after the procedure to verify the position of the catheter.

**Key words:** hemodialysis catheters, ultrasound-guided catheter placement, fluoroscopy.

**Conflict of interest statement.** The authors declare no competing interest.

© Desai A., Bennikal M., Bangari G., Janaky M., Manjunath R., 2022.

Correspondence should be addressed to Manjunath Revanasiddappa: [doc.r.manjunath@gmail.com](mailto:doc.r.manjunath@gmail.com)



© Десай А., Беннікал М., Бангарі Г., Джанакі М., Манджунат Р., 2022

УДК: 616.61-085.38-073.27: 616.14-089

Десай А., Беннікал М., Бангарі Г., Джанакі М., Манджунат Р.

**Неправильно розташовані діалізні катетери: серія випадків**

Медичний коледж та лікарня CDM, Університет CDM, Карнатака, Індія

**Анотація.** Двопросвітні гемодіалізні катетери часто використовуються для забезпечення судинного доступу. Інсерція діалізного катетера під ультразвуковим контролем є стандартною практикою, яка зменшує частоту механічних ускладнень. Однак, навіть ультразвуковий контроль не може запобігти неправильному розташуванню наконечника та пункції середостіння. У цій статті ми повідомляємо про чотири випадки неправильного розташування катетера і наголошуємо на важливості флюорографії або рентгенографії після процедури для перевірки його положення.

**Ключові слова:** гемодіалізні катетери, інсерція, ультразвуковий контроль, рентгенографія.

**Introduction.** Hemodialysis catheters (HDC) provide temporary or long-term vascular access to dialysis support [1]. HDC is a large-caliber catheter designed for sustaining high flow rates. While non-tunneled catheters are used for short-term/ acute dialysis, tunneled catheters are used for long-term dialysis [1]. Most HDCs are inserted via the internal jugular vein (IJV) or the femoral vein.

Ultrasound-guided (USG) placement of the catheters is preferred over the classical landmark technique because of tremendous first-attempt success and minimal vessel punctures [2]. However, the position of the catheter tip post-insertion cannot be visualized, limiting its usage in preventing mediastinal punctures and associated complications. It is recommended that dialysis catheters be inserted under fluoroscopy or equivalent imaging by Kidney Disease Outcomes Quality Initiative (KDOQI). However, in the intensive care setting or resource-limited settings, insertion may have to be unaided by imaging.

We present the complications observed in four cases of real-time ultrasound-guided HDC placement.

**Case reports.**

**Case 1.** A sixty-four-year aged hemodialysis patient presented with thrill loss in the arteriovenous fistula (AVF). He was noted to have long-segment chronic AVF thrombosis on a Doppler scan. He underwent hemodialysis via a femoral non-tunneled dialysis catheter. Later, the left IJV tunneled dialysis catheter (Palindrome™ Chronic Dialysis Catheter, Insertion Length 23 cm, COVIDENTM) was placed. The procedure was uneventful. In the post-procedure x-ray, the catheter

had a straight course rather than a curved course of the brachiocephalic vein. Chest X-RAY (Fig. 1a) showed the catheter to be malpositioned.

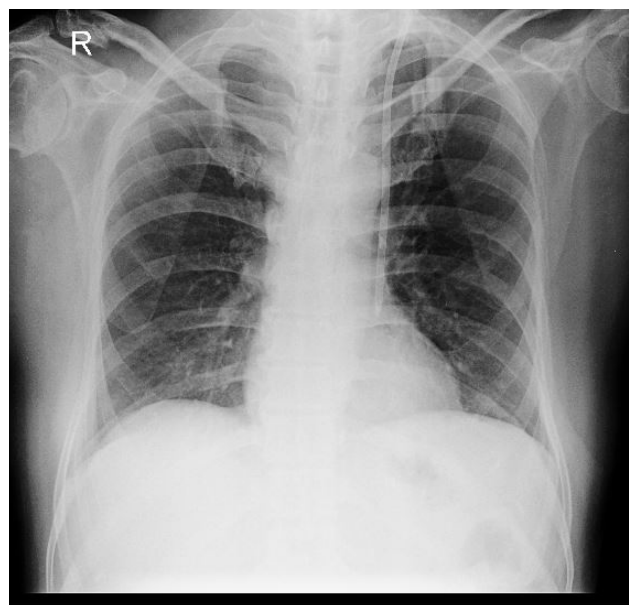


Fig. 1a. Chest radiograph of the patient showing the straight course of the catheter through persistent SVC.

Possible catheter locations may be in the mediastinum, superior intercostal vein, or a hemizygous vein. However, the patient remained asymptomatic. A computed tomography (CT) scan was done, which showed the catheter to be in the persistent left superior vena cava (SVC) (Fig. 1b, 1c, 1d).

**Manjunath Revanasiddappa**  
doc.r.manjunath@gmail.com

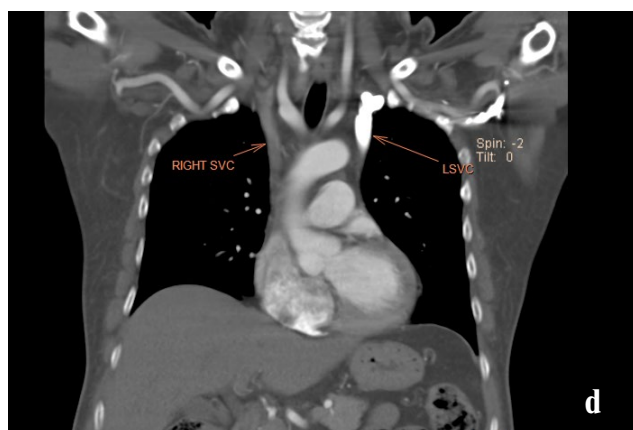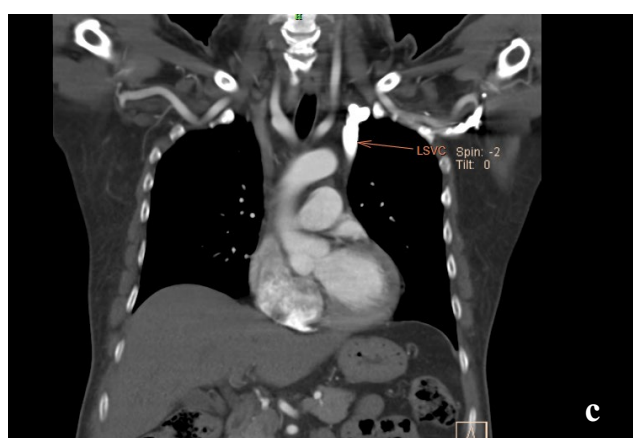
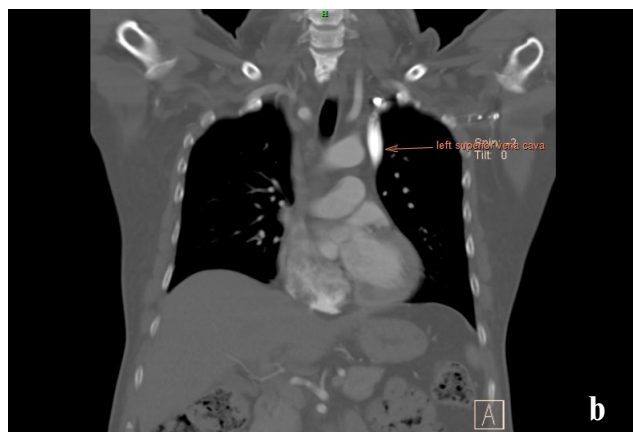


Fig. 1b-d. CT chest images reveal persistent left SVC and Right SVC.

Cardiac echocardiography did not reveal any other congenital heart defects. Blood flow of 350 ml per minute and adequate clearance were noted during hemodialysis using the catheter placed in the left SVC. Hence, the patient continued dialysis from the catheter and transitioned to right brachiocephalic AVF over the next five months.

**Case 2.** An elderly male with a history of diabetes mellitus, hypertension, and CKD-5D had multiple failed vascular accesses and presented features suggestive of catheter-related bloodstream infection. His right IJV tunneled catheter was removed. He underwent left IJV non-tunneled catheter insertion under ultrasound guidance. The patient complained of retrosternal chest pain after the procedure, and the post-procedure Chest radiograph was inconclusive. A CT scan of the chest revealed that the left IJV catheter was in the pericardial space, following which it was removed (Fig. 2).

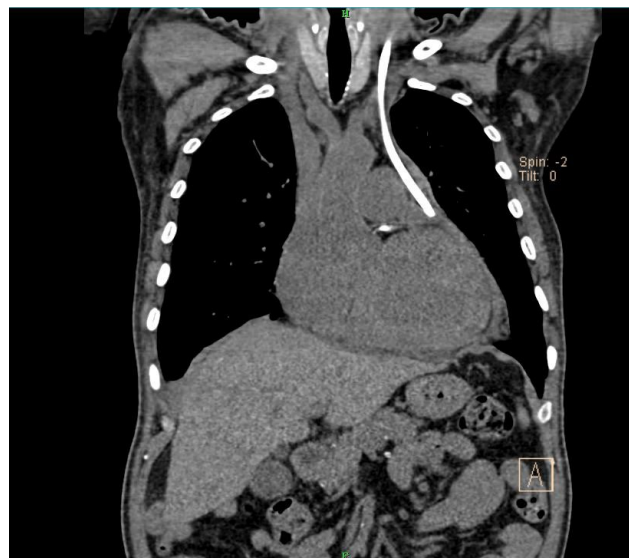


Fig. 2. CT chest revealing the left IJV catheter in the pericardial space

The time to remove it from insertion was 50 minutes. A suitable femoral catheter was secured, and the patient underwent heparin-free dialysis uneventfully. The patient remained hemodynamically stable with stable hemoglobin levels, assessed every sixth hour. A repeat CT and cardiac echo scan after 12 hours and 24 hours later did not show any mediastinal or pericardial collection. Later after one week, the patient underwent a Left Tunnelled catheter under fluoroscopy and continued dialysis via the same

**Case 3.** An elderly male with a known history of HTN, CKD-5 not on dialysis, with primary failure of left brachiocephalic AVF, presented with uremic complaints and volume overload. As he was scheduled for a right brachiocephalic AVF, a dialysis catheter was inserted into the left IJV (MAHURKAR™\* 12 Fr High-Pressure Triple Lumen Acute Dialysis Catheter, 13 cm). The patient complained of retrosternal chest pain during insertion. As the X-ray chest was not conclusive, a CT chest was done. CT chest revealed that the catheter had punctured the brachiocephalic vein (BCV). There was also a mediastinal hematoma (Fig. 3a, 3b, and 3c). The catheter was immediately removed, and a femoral dialysis catheter was inserted.

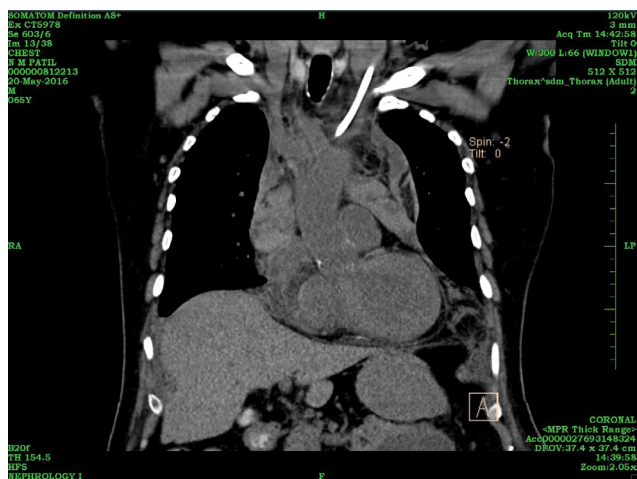


Fig. 3a. The left IJV catheter crossing over to the right.

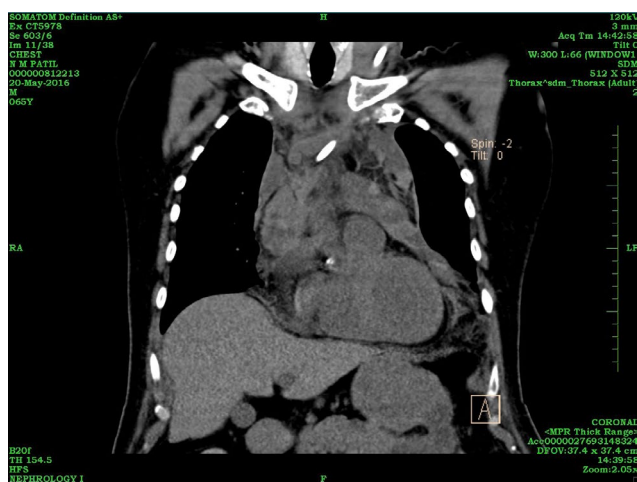


Fig. 3b. The left IJV catheter piercing the brachiocephalic vein.

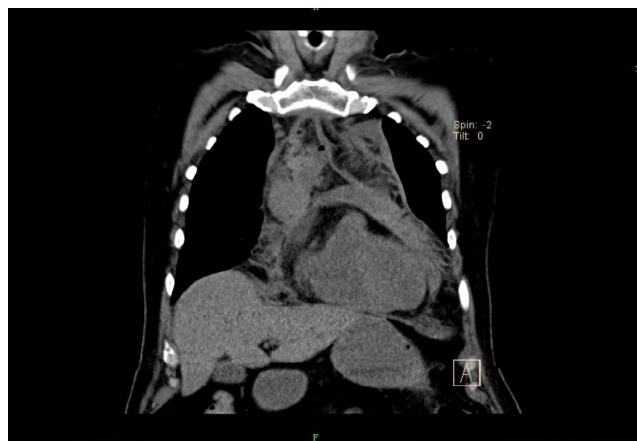

Fig. 3c. A mediastinal hematoma formed after the piercing of the brachiocephalic vein by the left IJV dialysis catheter.

**Case 4.** An elderly female with no past medical illness was admitted for sepsis and septic shock. Hemodialysis was planned as the patient was diagnosed with acute kidney injury stage III. Right IJV double-lumen HDC(MAHURKAR™\* 11.5 Fr Dual Lumen Acute Dialysis Catheter) was inserted under ultrasound guidance. The right IJV HDC had traversed into the right

subclavian vein, as evidenced by the post-procedure radiograph (Fig. 4). The patient received hemodialysis via the same access without blood flow issues.

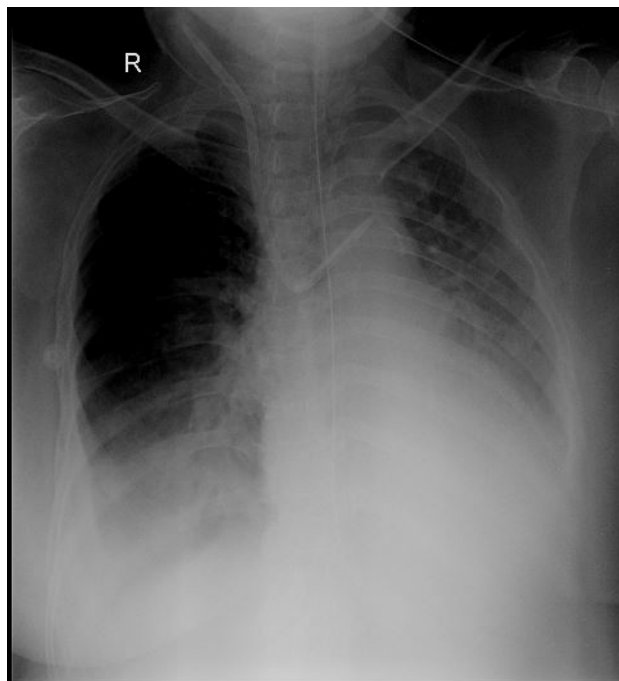


Fig. 4. The right IJV dialysis catheter traversing into the right subclavian vein.

**Discussion.** The Internal Jugular Vein (IJV) is the most preferred insertion route. However, post-insertional complications- bleeding and hematoma, arterial puncture, pneumothorax, and others- occur despite ultrasound guidance [1]. Moreover, vessel injuries are more significant for an HDC insertion via the left IJV than the right IJV because of the angulations within the former's coronal and transverse planes [3]. Three of the four cases in our study had their HDCs inserted into the left IJV.

Venous anomalies may become apparent after HDC insertion due to an unexpected line position. Persistent left-sided SVC or duplicated SVC occurs with an incidence of 2.1%. It often drains into the right atrium via an enlarged coronary sinus. Embryologically, the right anterior cardinal and common cardinal veins typically form the right SVC, and the left anterior cardinal vein regresses. If the left anterior cardinal vein persists, it forms a double SVC. In addition, if the usual right anterior cardinal vein regresses, it results in only a left SVC [4].

Persistent left superior vena cava is the most common abnormality of systemic venous circulation, with an incidence of 0.3% in the general population. This congenital anomaly is not usually associated with other cardiac defects [5]. In one of the patients, the left IJV catheter was found entering the persistent left SVC. Since the flow was good, the patient continued dialysis via the same catheter.

Internal mammary veins (IMV) drain into the brachiocephalic vein behind the sternal end of the clavicle and the first costal cartilage. The orifice of the left IMV

is more remote from the right-sided veins and can be accessed by a catheter from the left brachiocephalic vein. In patients with portal hypertension, the portal to systemic collateral circulation dilates the IMV and thus has a higher risk of malpositioning the catheter [6].

Even checking an x-ray after the procedure may not be foolproof. Dorsally or ventrally positioned catheters may be projected over BCV and appear as a well-positioned intravascular HDC. Aspiration of venous blood or blood gas analysis to show a venous sample can again be masqueraded by aspiration of pooled blood or unclotted hematoma [7].

Bleeding and hematoma formation associated with CVCs are usually resolved by placing icepacks and compressions, but an invasive surgical procedure to close the bleed site might sometimes be needed. The left IJV pierced the innominate vein causing mediastinal hematoma in one of our cases. The catheter was removed, and the right IJV was secured. Previous studies have reported favorable fatal outcomes after the malpositioning of the HDC into the mediastinum [8-10]. Treatment options for complications are primarily based on the position of the injured vessels, the stability of the patient, and available expertise. While ballooning and surgical repair were advocated for injured more prominent veins, treatment for smaller superficial veins included close observation and manual compression [9, 10]. Under close surveillance, stable patients with left BCV puncture and even with an anterior mediastinal hematoma up to 5 cm in size may be managed conservatively.

However, emergency surgery is warranted if there are any signs of instability.

The incidence of pneumothorax is higher with the insertion of CVC into the subclavian vein than the IJV, and the treatment includes inserting a chest drain. The published incidence of pneumothorax ranges from 0-3.3% with the radiological placement of tunneled CVC [1]. The suitable IJV catheter for one patient in our study went into the right subclavian vein. The patient succumbed to the disease.

Complications during the placement of HDCs can ensue due to the anatomical anomalies within the patient. Sometimes, it also depends on the operator's expertise and the inherent risk within the procedure. In-

experienced operators repeated HDC insertions, central vein stenosis, thrombosis, non-cooperative patient, and abnormal anatomy all increase the chances of vascular puncture and arterial puncture [11]. Whereas the number of complications with an ultrasound procedure is minimal because the position of the needle is readily visible, and the site of the target veins is quite clear [11], some complications are inevitable, owing to the unclear final position of the catheter tip. Immediate X-ray chest after the intervention or fluoroscopy-guided catheterization help in determining the catheter position. Therefore, the incidence of accidental punctures and further complications is drastically reduced by better control of the venipuncture depth [3, 12].

Dialysis Catheter Insertion with extended Ultrasound Monitoring for detection of the guide wire has been proposed as an alternative to fluoroscopy to confirm the guidewire position. Hence in facilities where fluoroscopy is unavailable, ultrasound can be used for guidewire and catheter position [13].

**Conclusion.** The above case scenarios highlight the importance of immediate identification of the position of the catheter tip after an HDC placement. A designated intervention room that includes ultrasound and fluoroscopy during the insertion of the catheters helps minimize the complications.

**Ethical approval, and consent to publish.** The study followed the tenets of the Helsinki declaration. All the patients' consents were obtained before publication.

**Conflicts of interest.** All authors report no conflicts of interest

#### Authors' contribution.

**AD, MR:** contributed to the study design, preparation of the manuscript, and final revision;

**MR, JM:** retrieval of data, and wrote parts of the paper;

**GB, MR:** data analysis and interpretation;

**MB, MR, GB:** critical review of the manuscript.

All authors have read and approved the content of the manuscript and confirmed the accuracy or integrity of any part of the work.

**Financial support:** none

#### References:

1. Nayeemuddin M, Pherwani AD, Asquith JR. Imaging and management of complications of central venous catheters. *Clinical Radiology*. 2013 May 1;68(5):529-44. DOI: 10.1016/j.crad.2012.10.013.
2. Oulego-Erroz I, Gonzalez-Cortes R, Garcia-Soler P, Balaguer-Gargallo M, Frases-Perez M, Mayordomo-Colunga J, Llorente-de-la-Fuente A, Santos-Herraz P, Mendez-Suso JJ, Sanchez-Porras M, Palanca-Arias D. Ultrasound-guided or landmark techniques for central venous catheter placement in critically ill children. *Intensive care medicine*. 2018 Jan;44(1):61-72. DOI: 10.1007/s00134-017-4985-8.
3. Ahn SJ, Kim HC, Chung JW, An SB, Yin YH, Jae HJ, Park JH. Ultrasound and fluoroscopy-guided placement of central venous ports via internal jugular vein: retrospective analysis of 1254 port implantations at a single center. *Korean Journal of Radiology*. 2012 Jun 1;13(3):314-23. DOI: 10.3348/kjr.2012.13.3.314.

4. *Farrell J, Walshe J, Gellens M, Martin KJ.* Complications associated with insertion of jugular venous catheters for hemodialysis: the value of postprocedural radiograph. *American journal of kidney diseases.* 1997 Nov 1;30(5):690-2. DOI: 10.1016/s0272-6386(97)90494-7.
5. *Stylianou K, Korsavas K, Voloudaki A, Patrianakos A, Vardaki E, Tzenakis N, Daphnis E.* Can a left internal jugular catheter be used in the hemodialysis of a patient with persistent left superior vena cava?. *Hemodialysis International.* 2007 Jan;11(1):42-5. DOI: 10.1111/j.1542-4758.2007.00152.x.
6. *Ghafoor H, Sh F, Ali M.* Unusual malposition of dialysis catheter in the left internal mammary vein—a case report. *Middle East journal of anaesthesiology.* 2011 Feb 1;21(1):139-41. Available from: <https://pubmed.ncbi.nlm.nih.gov/21991749/>.
7. *Winkes MB, Loos MJ, Scheltinga MR, Teijink JA.* Dialysis catheter placement via the left internal jugular vein: risk of brachiocephalic vein perforation. *J Vasc Access.* 2016;17(4):e75-e78. DOI: 10.5301/jva.5000566.
8. *Zhang W, Liu T, Wang X, et al.* Hemothorax caused by replacement of hemodialysis catheter: A case report. *Hemodial Int.*2016; 20:E7-E10. DOI: 10.1111/hdi.12428.
9. *Kusumoto T, Mitsushio K, Kajiwara N.* A double-lumen catheter for hemodialysis dislocated into the mediastinum. *Clin Case Rep.*2019;7:1817-1818. DOI: 10.1002/ccr3.2326.
10. *Li CC, Zhang W, Wu XJ, Bu Y, Zheng ZP.* Therapeutic strategy of central vein perforation accompanied by a mediastinal lesion after catheterization. *J Int Med Res.* 2019; 47:2702-2708. DOI: 10.1177/0300060519843686.
11. *Brass P, Hellmich M, Kolodziej L, Schick G, Smith AF.* Ultrasound guidance versus anatomical landmarks for subclavian or femoral vein catheterization. *Cochrane Database Syst Rev.* 2015 Jan 9;1(1):CD011447. DOI: 10.1002/14651858.CD011447.
12. *Pang H, Chen Y, He X, Zeng Q, Ye P.* Fluoroscopy-guided subclavian vein catheterization in 203 children with hematologic disease. *Medicine.* 2018 Dec;97(50). :e13527. DOI: 10.1097/MD.00000000000013527.
13. *Letachowicz K, Go dzik A, Go biowski T, et al.* Dialysis Catheter Insertion with Extended Ultrasound Monitoring. *Blood Purif.* 2020;49(1-2):102-106. DOI: 10.1159/000503057.