View metadata, citation and similar papers at core.ac.uk
brought to you by CORE
provided by Repositório Institucional dos Hospitais da Universidade de Coimbra

CASE REPORT

Cast nephropathy: an extremely rare renal presentation of Waldenström's macroglobulinaemia

Tânia Santos,[1] Susana Machado,[1] Vítor Sousa,[2,3] Mário Campos[1]

[1]Department of Nephrology, Coimbra's Hospital and University Center, Coimbra, Portugal
[2]Department of Pathology, Coimbra's Hospital and University Center, Coimbra, Portugal
[3]Coimbra's Medical College, Coimbra, Portugal

Correspondence to
Dr Tânia Santos,
taniasantos.ts@gmail.com

Accepted 22 September 2015

SUMMARY

Renal involvement in Waldenström's macroglobulinaemia (WM) is very unusual when compared to multiple myeloma. We report a case of a patient who developed anuric acute kidney injury secondary to cast nephropathy, dependent on high-flux haemodialysis. Complementary study revealed the presence of blood IgM monoclonal gammopathy and a massive bone marrow lymphoplasmacytic infiltration. There were no osteolytic lesions and no clinical signs/symptoms of hyperviscosity syndrome. The diagnosis of WM was established and a dexamethasone plus cyclophosphamide regime was started, in addition to plasmapheresis. The patient partially recovered renal function allowing haemodialysis and plasmapheresis withdrawal. He remained asymptomatic with a good response to chemotherapy and 12 months after his renal function remained stable. This is a rare clinical case in which WM presented as an IgM cast nephropathy, which in turn is an extremely rare renal presentation of this equally rare haematological disorder.

BACKGROUND

Waldenström's macroglobulinaemia (WM) is a rare, low-grade malignant lymphoplasmacytic proliferative disorder accounting for <5% of all non-Hodgkin lymphomas and for approximately 2% of all haematological malignancies.[1 2] It is a distinct clinicopathological entity characterised by bone marrow (BM) infiltration of a lymphoplasmacytic lymphoma (LPL), responsible for immunoglobulin M (IgM) monoclonal gammopathy in the blood.[2] Other organs can be infiltrated, especially liver and spleen. Renal involvement in WM is unusual when compared to multiple myeloma (MM) and results in monoclonal IgM deposition in the glomerular basement membrane (GBM) (±cryoglobulinaemia), interstitial infiltration of neoplastic lymphoplasmacytic cells and/or amyloid light-chain (AL)-amyloidosis typically causing nephrotic syndrome.[3] Cast nephropathy can be seen more frequently in MM (commonly referred to as 'myeloma kidney', a myeloma-defining event) and is otherwise extremely rare in WM.[3 4] We report a case of WM where cast nephropathy with acute kidney injury (AKI) was not only its renal manifestation but also its initial presentation.

CASE PRESENTATION

An 80-year-old Caucasian man was referred to our nephrology department after a 24 h history of anuric AKI. Concurrently, he presented with an acute respiratory infection and was treated with antibiotics, bronchodilators and oxygen.

The patient's medical history was notable for diabetes mellitus (for 20 years, without evidence of diabetic retinopathy), arterial hypertension, glaucoma and asymptomatic cholelithiasis. There was no known renal disease and his last known serum creatinine, 3 years earlier, was 1.1 mg/dL. His outpatient medication was composed exclusively of metformin, glibenclamide, enalapril, clopidogrel and ophthalmic drops.

On admission, he was afebrile with a blood pressure of 139/56 mm Hg, bilateral pulmonary ronchi but no respiratory distress. Cardiac and abdominal examinations were unremarkable and there were no cutaneous lesions, peripheral oedema or adenopathies.

Initial laboratory studies yielded the following: normocytic and normochromic anaemia (Hb=9.3 g/dL) with normal leucocyte and platelet blood count, elevated C reactive protein (6.48 mg/dL, normal range (NR) <0.5 mg/dL), serum creatinine 7.91 mg/dL, blood urea nitrogen 89 mg/dL, hyperkalaemia 5.8 mmol/L, hyperglycaemia 263 mg/dL with borderline hyponatraemia of 135 mmol/L and non-compensated metabolic acidosis (pH=7.22, bicarbonate 15.1 mmol/L, carbon dioxide pressure 37 mm Hg, oxygen pressure 69 mm Hg and normal serum lactate). Chest X-ray was negative for pneumonic foci or pleural effusions. Renal ultrasound revealed normal kidneys with no signs of obstruction or nephrolithiasis.

During the first few hours, the patient remained anuric and was started on high-flux haemodialysis.

Additional and relevant studies included: total protein/albumin of 7.3/2.9 g/dL, normal lactic acid dehydrogenase, corrected calcium 9.2 mg/dL, hyperphosphoremia of 5.3 mg/dL and parathormone of 120 pg/mL (NR 9–72 pg/mL). Glycated haemoglobin was 6%, uric acid 3.9 mg/dL (NR 3.5–7.2 mg/dL) and folic acid 3.6 ng/mL (NR >5.4 ng/mL). The levels of rheumatoid factor, complement C3 and C4 and anti-streptolysin O titre were normal. Antinuclear antibodies were also normal and cryoglobulins were absent. Viral serologies were negative for hepatitis B surface antigen, hepatitis C antibody, HIV 1 and 2 antibodies, Epstein-Barr virus, cytomegalovirus and herpes simplex virus. Peripheral blood cultures were sterile. Serum electrophoresis revealed a monoclonal spike in the β region, which was identified by immunoelectrophoresis and immunofixation as an IgM M component bearing κ light chains: IgM 35.40 g/L (NR 0.40–2.30 g/L), κ light chains

To cite: Santos T, Machado S, Sousa V, *et al*. *BMJ Case Rep* Published online: [*please include* Day Month Year] doi:10.1136/bcr-2015-211210

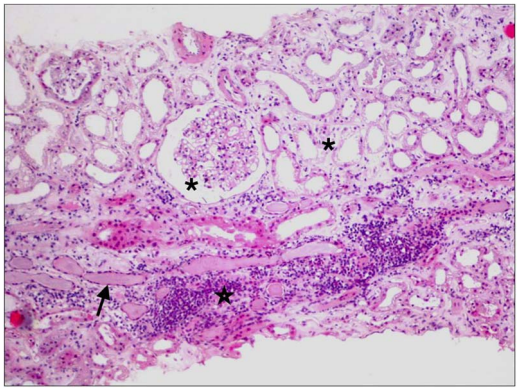

Figure 1 Glomeruli with mild thickening of the capillary wall and ischaemic tubulopathy with nuclei loss and cytoplasm vacuolisation (asterisk). There are also intratubular casts (arrow) and tubulointerstitial nephritis (star) (H&E, ×100).

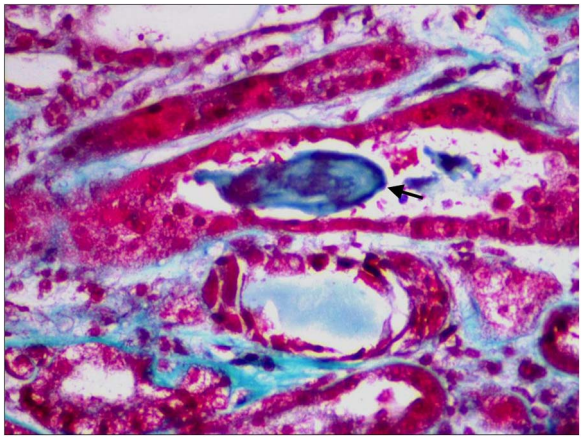

Figure 3 Polychromatic intratubular casts (arrow) (Masson's Trichrome, ×400).

16.78 g/L (NR 6.66–14.65 g/L), κ/λ relation 3.94 (NR 1.35–2.65), IgG 6.56 g/L (NR 7.0–16.0 g/L), IgA 0.65 g/L (NR 0.70–4.00 g/L) and IgE 24 UI/mL (NR 0–100 UI/mL). Serum viscosity was not performed, as signs/symptoms of hyperviscosity were absent. Serum β2-microglobulin was 16.70 mg/L (NR 1.09–2.53 mg/L).

Urine sediment (when the patient recovered urine output) contained many erythrocytes, leucocytes and pathological cylinders. Urine microbiological examination was negative. Proteinuria was 4058 mg/g. Urine immunoelectrophoresis revealed albumin and κ light chains (0.98 g/1 L urine/24 h).

BM aspirate revealed 75% of lymphoplasmacytic cells with 7% of plasmocytes and BM biopsy showed a massive infiltration (90%) by lymphoplasmacytic cells. Flow cytometry demonstrated 35% of IgM and κ light chain clonal B cells with the following immunophenotype: CD19+, CD20+, CD79b+, CD38+ (heterogeneous expression), IgM and κ light chains, CD10−, CD5− and CD23−. This immunophenotype was compatible with LPL/WM and no chromosomal abnormalities were explored. Skeletal X-ray was negative for osteolytic lesions, and a CT scan revealed multiple thoracic and abdominal lymphadenopathies without hepatosplenomegaly.

During the first week, the patient remained dependent on haemodialysis and a renal biopsy was performed (figures 1–6). Light microscopy showed mild thickening of the capillary wall and a slight mesangial expansion, PAS positive, without hypercellularity. Double contoured basement membranes were absent. There was mild interstitial fibrosis, signs of ischaemic tubulopathy and mild multifocal tubulointerstitial nephritis. Many renal tubules showed PAS-positive casts, which became polychromatic on Masson's Trichrome stain. Immunohistochemical stain revealed IgM deposits along the GBM and mesangium. Tubular casts and peritubular capillaries also stained intensively for IgM and moderately for κ light chains. Congo red and Wright staining were negative. Immunofluorescence study revealed a strong staining of casts and glomeruli for IgM, at this level granular, mesangial and subepithelial. Electron microscopy was not performed.

The patient was diagnosed with an AKI secondary to cast nephropathy due to WM and was started on intravenous cyclophosphamide 750 mg/m^2 every 21 days, plus oral dexamethasone 10 mg twice a week. Also, plasmapheresis guided by serum paraprotein levels was performed on alternate days (therapeutic plasma exchange using a centrifuge, with an exchange of 1.0 plasma volume and using 5% human albumin plus fresh-frozen plasma as replacement fluids) as well as MESNA protocol and antibiotic prophylaxis. During hospitalisation, the patient was

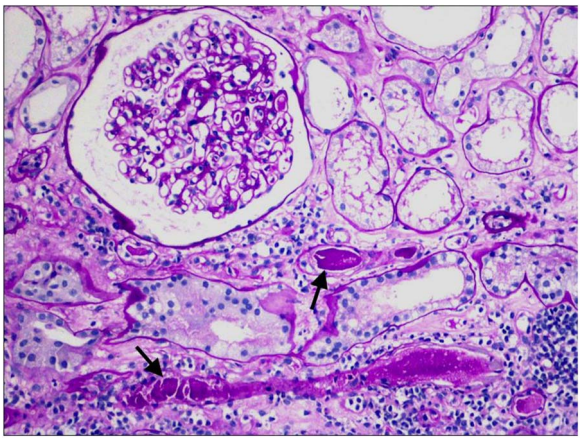

Figure 2 Periodic acid-Schiff (PAS)-positive casts (arrows) surrounded by reactive epithelial cells and some mononucleated cells (PAS, ×200).

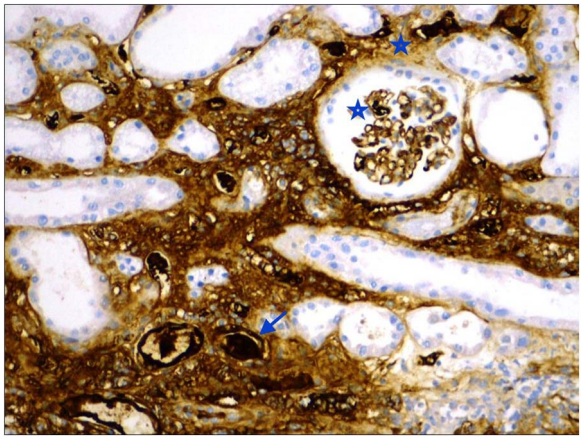

Figure 4 Casts with IgM intense expression by immunohistochemistry (arrow). IgM is also expressed in peritubular capillaries lumina and in the glomeruli (stars) (IgM, ×200).

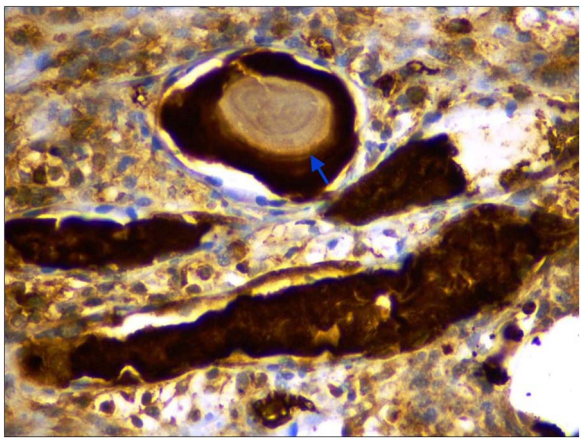

Figure 5 The κ light chain immunohistochemical expression in the casts, some of them showing lamination (arrow). (κ light chain, ×400).

started on insulin therapy and submitted to 14 plasmapheresis treatments plus three cycles of chemotherapy. There was a significant reduction in serum IgM and κ light chains to 7.74 and 5.56 g/L, respectively. The patient's renal function slowly recovered, becoming independent of haemodialysis, with a stable serum creatinine of 4.5 mg/dL. His hospital admission was otherwise uneventful and he was discharged after 56 days, dialysis free. He was maintained on regular surveillance and a year later remained asymptomatic with a serum creatinine of 2.68 mg/dL, a bland urine sediment and proteinuria of 463 mg/g.

DISCUSSION

Our patient presented with a serum IgM monoclonal gammopathy and an AKI secondary to a myeloma-like cast nephropathy, with unusual and strong staining for IgM in addition to κ light chains. In this case, and in general, the differential diagnosis between rare diseases such as WM and classical MM with an IgM paraprotein (IgM-MM) is challenging. The distinction is made on clinical and cellular grounds. Classical MM is associated with lytic bone lesions and AKI. Symptoms of hyperviscosity, the presence of lymphadenopathy and/or splenomegaly, and the absence of osteolytic lesions support the diagnosis of WM. Moreover, lymphoplasmacytic cells in the BM of patients with WM are immunophenotypically different from plasma cells seen in the BM of patients with MM. The clonal population in WM appears to derive from a B-cell arrest before terminal differentiation to a plasma cell and a surface IgM-positive CD5−CD10−CD19+CD20+CD23− immunophenotype in association with an intra-trabecular monoclonal lymphoplasmacytic infiltrate is diagnostic of WM.[2] Cytogenetic studies are optional in the diagnostic approach of a suspected case of WM but sometimes helpful in patients with MM who may have lymphoplasmacytic or small mature plasma cell morphology, also expressing CD20. In these cases, cytogenetic analysis to search for t(11;14) chromosomal translocation may help establishing the diagnosis, and its presence is in favour of an IgM-MM as WM is not associated with specific chromosomal abnormalities. In the present case, there was no cytogenetic analysis as the clonal population had a characteristic immunophenotype that, along with the clinical criteria, led to the diagnosis of WM.

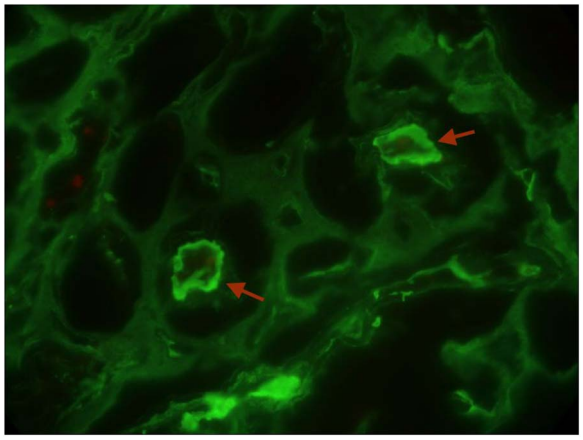

Figure 6 IgM 3+ deposits in casts (arrows) (IgM immunofluorescence, ×400).

According to the literature, there are few case reports describing patients with WM with cast nephropathy.[5–8] Ours was unique in two ways: (1) AKI was the clinical manifestation that led to the diagnosis of WM, which is in itself a rare event in WM and (2) renal biopsy documented the presence of cast nephropathy with tubular casts expressing IgM and κ light chains on immunohistochemical staining, which is also very unusual in WM.

It is widely known that light-chain cast nephropathy, commonly referred to as myeloma cast nephropathy or myeloma kidney, is the most common cause of AKI in MM, and is related to a high tumoural burden.[9] In MM, monoclonal free light chains (FLC) are easily filtered through the glomerular filtration barrier (Bence-Jones proteinuria). However, the high FLC concentration overwhelms proximal tubule reabsorption capacity, allowing for large amounts of FLC to reach the loop of Henle, where Tamm-Horsfall protein (THP) is produced. Here, they form obstructing tubular casts, which are the result of FLC's binding and aggregation to THP.[4] The tubulopathic FLC typically incite accompanying tubulointerstitial nephritis.

Urinary monoclonal light chains can be detected by immunofixation in 80–90% of patients with WM, but significant Bence-Jones proteinuria (>1,0 g/day) only occurs in a small fraction of those patients (<5%).[3 9] This may help to explain why cast nephropathy (and AKI) is so rare in WM.

Possible pathological patterns of renal involvement in WM are: (1) glomerular lesions and (2) tubulointerstitial lesions. The first, which are most frequently encountered, consist of intracapillary monoclonal deposit disease (intraglomerular periodic acid-Schiff (PAS)-positive hyaline pseudothrombi occluding the capillary lumens corresponding to monoclonal IgM aggregates), membranoproliferative glomerulonephritis (±cryoglobulinaemia), light chain amyloidosis, light-chain deposition disease (LCDD) and minimal change disease. The second are related to lymphomatous infiltrate, acute tubular necrosis, cast nephropathy, Fanconi syndrome and, also, LCDD.[9–11]

In our patient, glomerular and tubulointerstitial compartments were both affected. Immunohistochemical stain and immunofluorescence pattern may suggest a deposit disease. However, a definite diagnosis is not possible, as electronic microscopy was not performed. Had it been confirmed, there would be a combination of cast nephropathy and deposit disease, an even rarer histopathology in WM.[11] But it is important to stress that patients' staining patterns may represent nonspecific 'trapping' of the circulating M component in basement membrane, which might be a reflection of high serum levels as opposed to real deposits.[11]

It was also very interesting to find IgM staining in tubular casts. At first sight, this might be difficult to understand due to its pentameric form and high molecular mass.[12] However, IgM has important physiochemical properties, such as aggregability, polymerisation and cryoprecipitation, which may predispose to its GBM trapping particularly where protein concentration is especially elevated by glomerular ultrafiltration. It may somehow induce glomerular damage (without triggering glomerular proliferation) and non-selective proteinuria, explaining the occurrence of IgM in tubular casts and, ultimately, AKI.[3 9 13]

Another relevant issue in our patient's renal dysfunction was his long history of type 2 diabetes mellitus. However, renal histopathology excluded co-existent diabetic nephropathy, which could otherwise justify his residual renal dysfunction after cast nephropathy treatment.

WM's immunosuppressive treatment is the same as for MM, and includes alkylating agents, purine analogues and monoclonal antibody anti-CD20 (rituximab). The latter may be regarded as a reasonable option in patients with IgM autoantibody-related neuropathies (anti-myelin-associated glycoprotein antibodies), which were absent in our patient.[2] Moreover, plasmapheresis is indicated for the acute management of symptoms of hyperviscosity (generally present when IgM>50 g/L), and, in cast nephropathy, as an adjunct to chemotherapy, as it helps remove the toxic circulating paraproteins (while their production is being impaired by chemotherapy). However, there are conflicting data regarding its effectiveness in patients with AKI secondary to cast nephropathy.[14–16]

Despite having cast nephropathy, renal prognosis in this patient with WM was better than for most patients with MM with similar renal involvement. Even so, median survival of patients with WM, from the time of diagnosis, is approximately 5 years and the majority die of disease progression (eg, transformation to large cell lymphoma). The remaining succumb to unrelated causes, as they are generally elderly.[1 2]

Learning points

- Compared to multiple myeloma (MM), renal involvement in Waldenström's macroglobulinaemia (WM) is very unusual, with glomerular lesions being the most frequently observed abnormality.
- Cast nephropathy is extremely rare in WM since significant Bence-Jones proteinuria occurs in <5% of these patients.
- In rare cases, IgM trapping in glomerular basement membrane may induce glomerular damage with the appearance of IgM in tubular casts.
- WM treatment is the same as that for MM.
- Management of cast nephropathy with acute kidney injury includes chemotherapy with or without plasmapheresis, according to the current literature.

Competing interests None declared.

Patient consent Obtained.

Provenance and peer review Not commissioned; externally peer reviewed.

REFERENCES

1 Vitolo U, Ferreri AJ, Montoto S. Lymphoplasmacytic lymphoma—Waldenstrom's macroglobulinemia. *Crit Rev Oncol Hematol* 2008;67:172–85.
2 Vijay A, Gertz MA. Waldenström macroglobulinemia. *Blood* 2007;109:5096–103.
3 Veltman GA, van Veen S, Kluin-Nelemans JC. Renal disease in Waldenström's macroglobulinaemia. *Nephrol Dial Transplant* 1997;12:1256–9.
4 Leung N, Nasr SH. Myeloma-related kidney disease. *Adv Chronic Kidney Dis* 2014;21:36–47.
5 Isaac J, Herrera GA. Cast nephropathy in a case of Waldenstrom's macroglobulinemia. *Nephron* 2002;91:512–15.
6 Perez NS, Garcia-Herrera A, Rosiñol L, *et al*. Lymphoplasmacytic lymphoma causing light chain cast nephropathy. *Nephrol Dial Transplant* 2012;27:450–3.
7 Ramachandran R, Rathi M, Malhotra P. Light chain cast nephropathy in Waldenstrom's macroglobulinaemia. *Nephrol Dial Transplant* 2012;27:1687–8.
8 Bashir Q, Lee CK, Stuart RW, *et al*. Phenotypic evolution of Waldenstrom's macroglobulinemia to extramedullary plasmacytoma. *J Clin Oncol* 2008;26:2408–10.
9 Dimopoulos MA, Panayiotidis P, Moulopoulos LA. Waldenstrom's macroglobulinemia: clinical features, complications, and management. *J Clin Oncol* 2000;18:214–26.
10 Audard V, Georges B, Vanhille P, *et al*. Renal lesions associated with IgM-secreting monoclonal proliferations: revisiting the disease spectrum. *Clin J Am Soc Nephrol* 2008;3:1339–49.
11 Gnemmi V, Leleu X, Provot F, *et al*. Cast nephropathy and light-chain deposition disease in Waldenstrom macroglobulinemia. *Am J Kidney Dis* 2012;60:487–91.
12 Davies DR, Metzger H. Structural basis of antibody function. *Annu Rev Immunol* 1983;1:87–117.
13 Morel-Maroger L, Basch A, Danon F. Pathology of the kidney in Waldenstrom's macroglobulinemia. Study of sixteen cases. *N Engl J Med* 1970;283:123–9.
14 Durie BG, Kyle RA, Belch A, *et al*. Myeloma management guidelines: a consensus report from the Scientific Advisors of the International Myeloma Foundation. *Hematol J* 2003;4:379–98.
15 Clark WF, Stewart AK, Rock GA, *et al*. Plasma exchange when myeloma presents as acute renal failure: a randomized, controlled trial. *Ann Intern Med* 2005;143:777–84.
16 Gertz MA. Managing myeloma kidney. *Ann Intern Med* 2005;143:835–7.

Copyright 2015 BMJ Publishing Group. All rights reserved. For permission to reuse any of this content visit http://group.bmj.com/group/rights-licensing/permissions.
BMJ Case Report Fellows may re-use this article for personal use and teaching without any further permission.

Become a Fellow of BMJ Case Reports today and you can:
- Submit as many cases as you like
- Enjoy fast sympathetic peer review and rapid publication of accepted articles
- Access all the published articles
- Re-use any of the published material for personal use and teaching without further permission

For information on Institutional Fellowships contact consortiasales@bmjgroup.com

Visit casereports.bmj.com for more articles like this and to become a Fellow